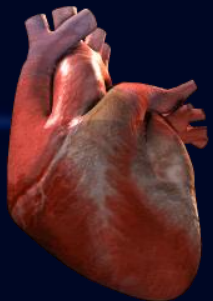

# Advanced Interpretation of the 12- Lead – Let's Do This!

Ben Taylor PhD, PA-C,  
DFAAPA



# Disclosures

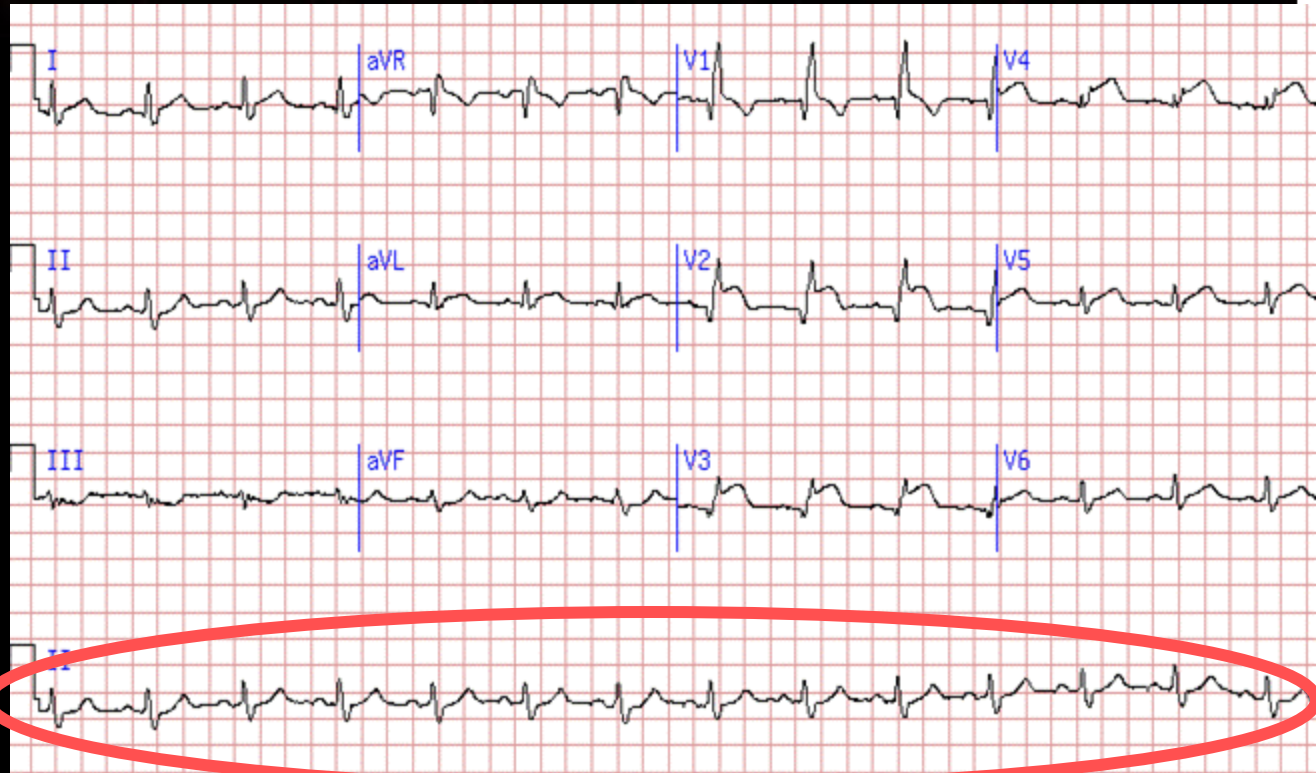
I have no relevant commercial relationships to disclose

# Learning Objectives

- At the conclusion of the session participants should be able to:
  - Apply a systematic approach to the interpretation of EKG's
  - Identify dysrhythmias and their relevant implications from the cases presented
  - Determine the mean QRS axis and state the common causes of axis deviation (LAD, RAD)
  - Describe 12-lead EKG features of infarction & ischemia

# Assessing the EKG Rate

If you use the rhythm strip portion of the 12-lead EKG the total length of it is always 10 seconds long. So you can count the number of R waves in the rhythm strip and multiply by 6 to determine the beats per minute.

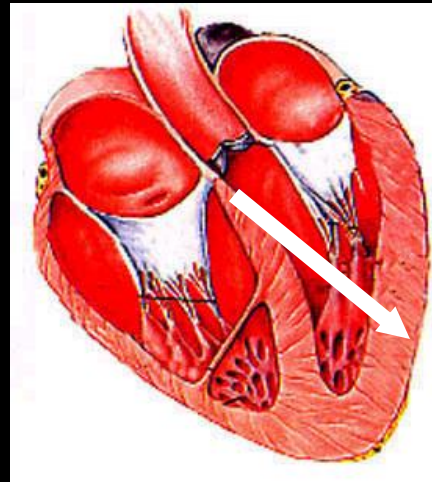


Rate?

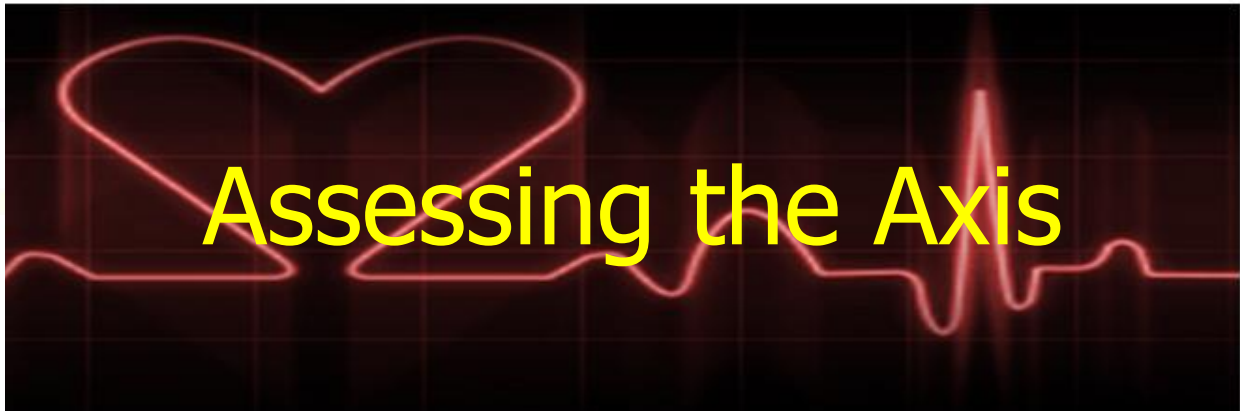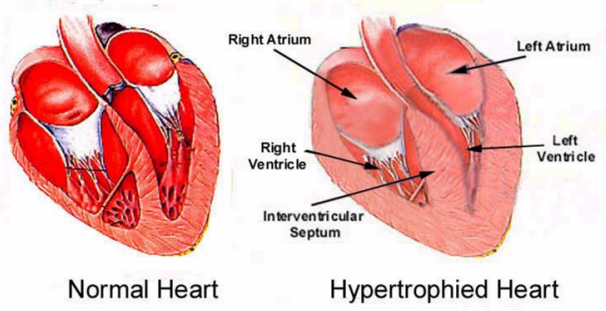
$$14 (R \text{ waves}) \times 6 = 84 \text{ bpm}$$

# Assessing the Axis

**Axis** refers to the **mean QRS axis** (or vector) during ventricular depolarization. As you recall when the ventricles depolarize (in a normal heart) the direction of current flows leftward and downward because most of the ventricular mass is in the left ventricle. We like to know the QRS axis because an abnormal axis can suggest disease such as pulmonary hypertension from a pulmonary embolism.



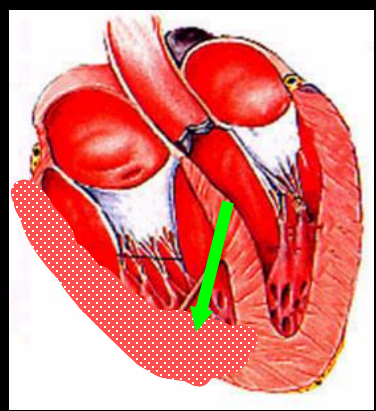
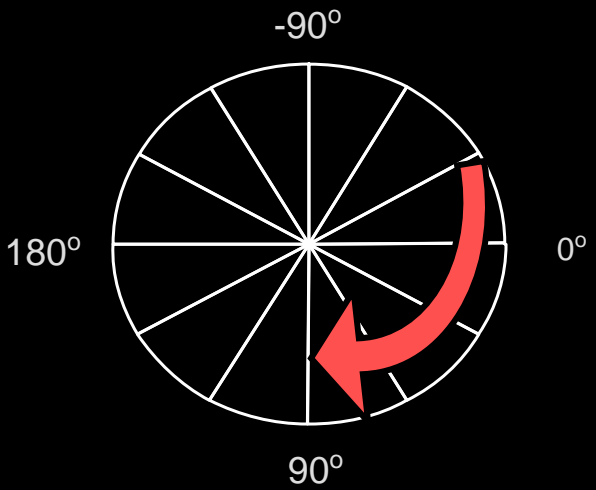
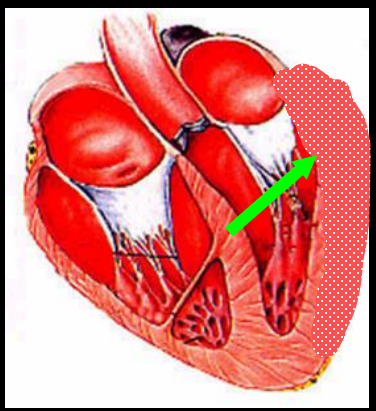
# Hypertrophic Cardiomyopathy



# Assessing the Axis

- Causes of left axis deviation include:
  - Left ventricular hypertrophy
  - Inferior wall MI
  - Left bundle branch block
  - Left anterior fascicular block

- Causes of right axis deviation include:
  - Right ventricular hypertrophy
  - Lateral wall MI
  - Right bundle branch block
  - Pulmonary hypertension

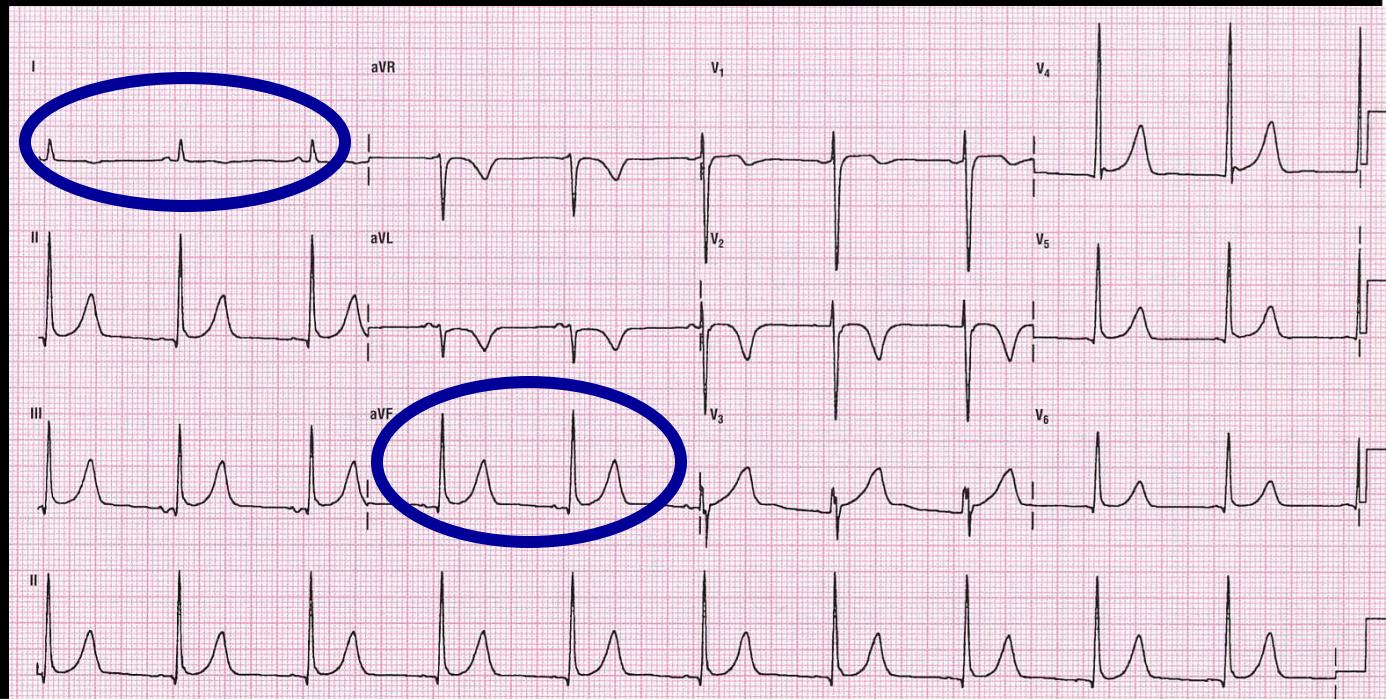


# Assessing the Axis

We can quickly determine whether the QRS axis is normal by looking at leads I and aVF.

If the QRS complex is overall **positive** in **leads I** and **aVF**, the QRS axis is **normal**.

Both R-waves are more + than the S-waves



# Assessing the Axis

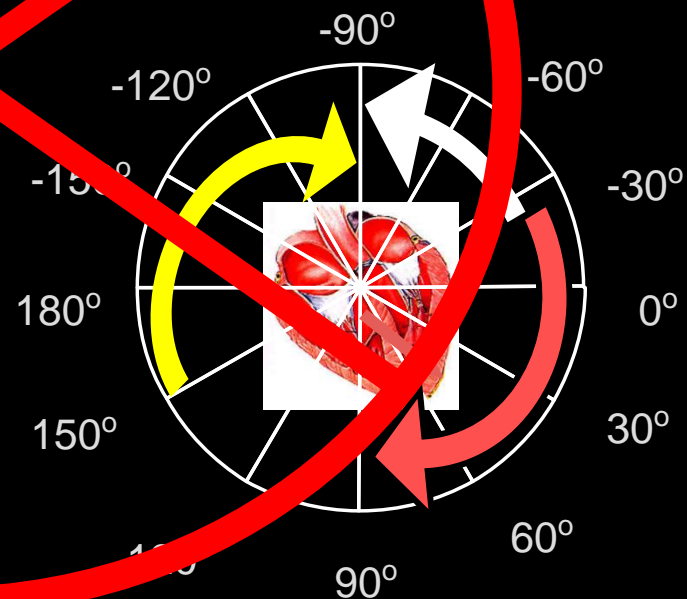
The QRS axis is determined by overlying a circle, in the horizontal plane. By convention, the degrees of the circle are as shown

The **normal QRS axis** lies between  $-30^{\circ}$  and  $+90^{\circ}$ .

A QRS axis that falls between  $-30^{\circ}$  and  $-90^{\circ}$  is abnormal and called **left axis deviation**.

A QRS axis that falls between  $+90^{\circ}$  and  $+150^{\circ}$  is abnormal and called **right axis deviation**.

A QRS axis that falls between  $+150^{\circ}$  and  $-90^{\circ}$  is abnormal and called **extreme right axis deviation**.

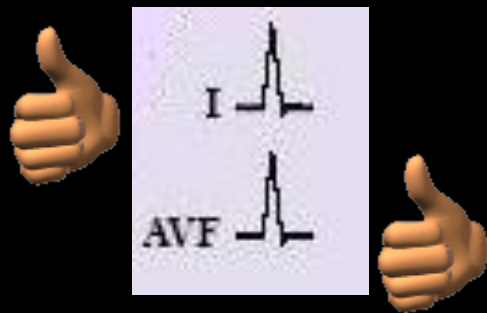





# Assessing the Axis

The thumb method

Always go with the positive thumb!!!!



**Normal Axis**



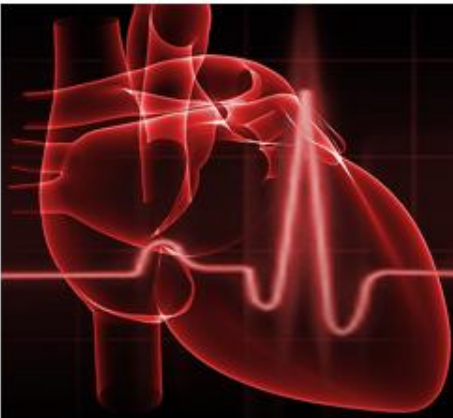
**Right Axis**



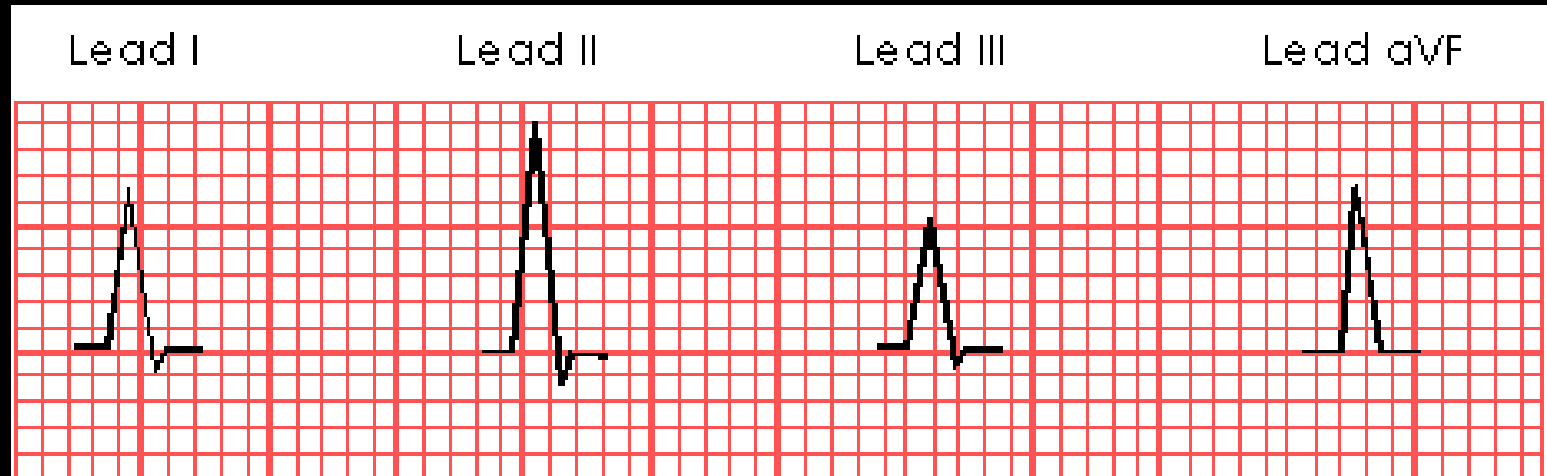
**Left Axis**



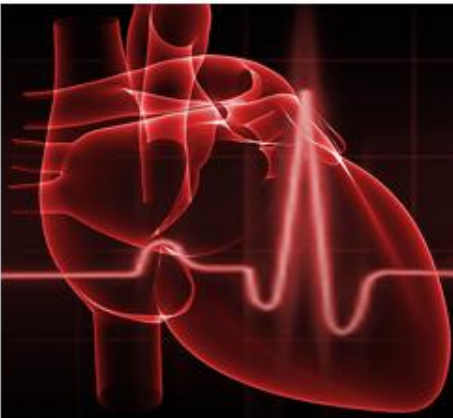
**Extreme Right Axis**



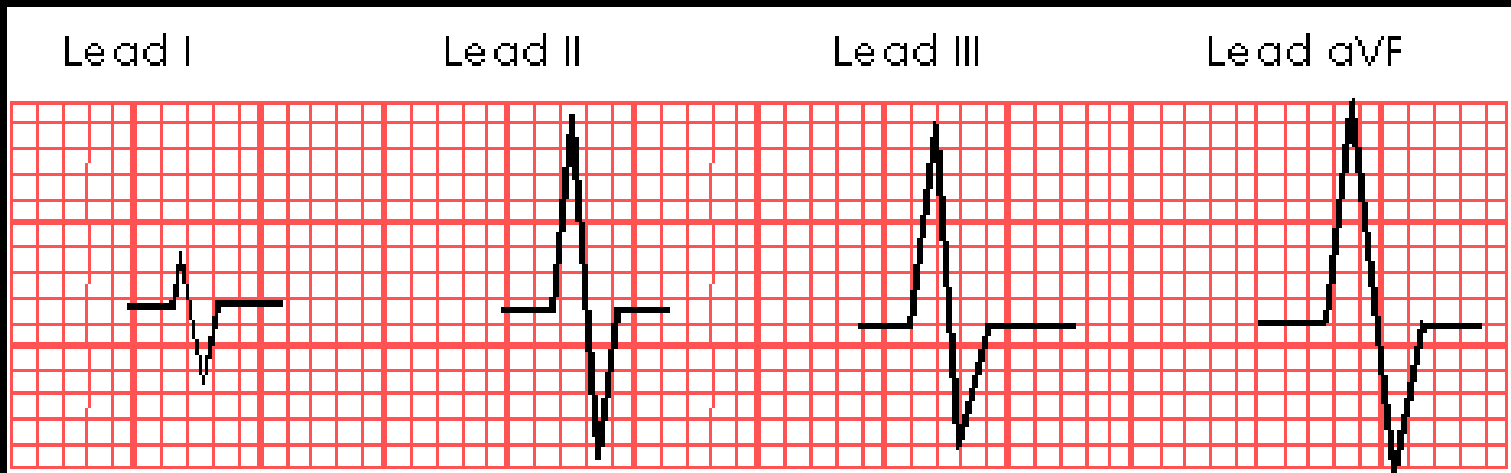
# Normal, Right or Left Axis?



**Normal**



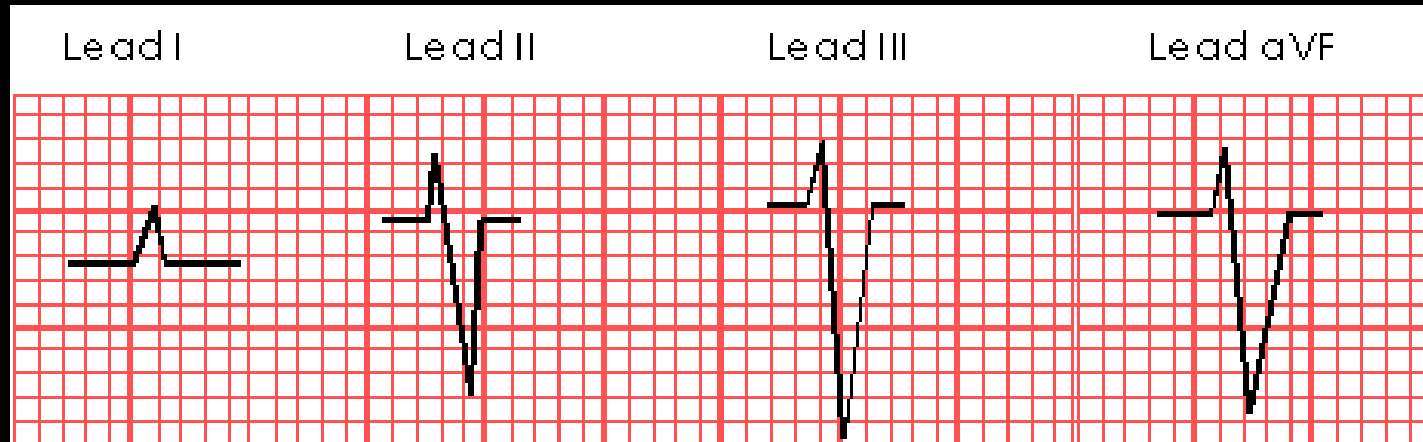
# Normal, Right or Left Axis?



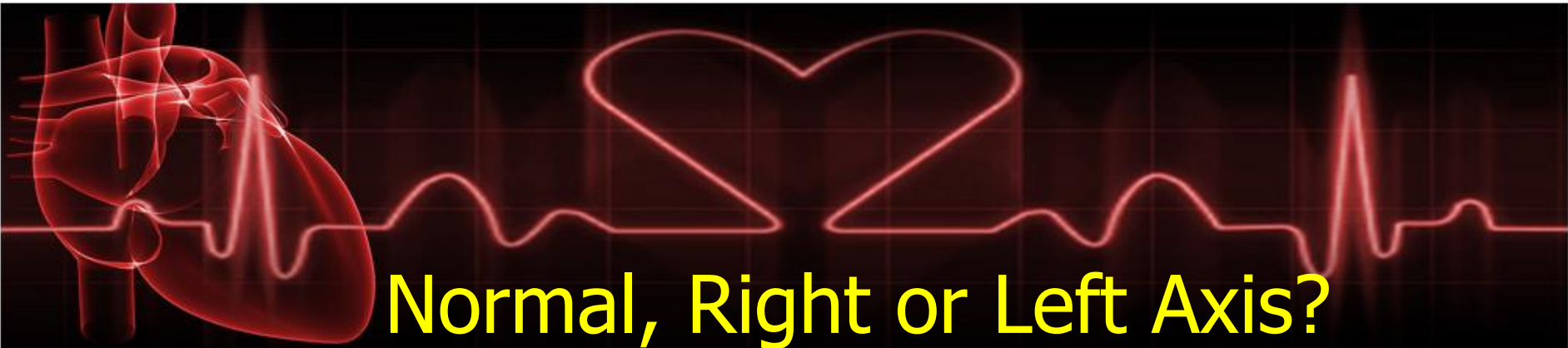**Right**



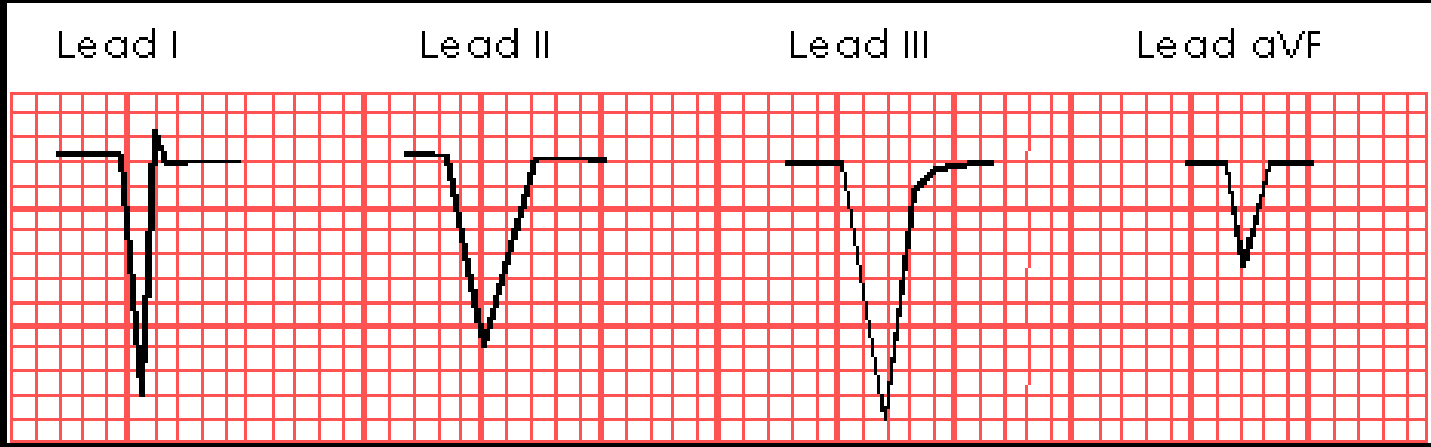
# Normal, Right or Left Axis?



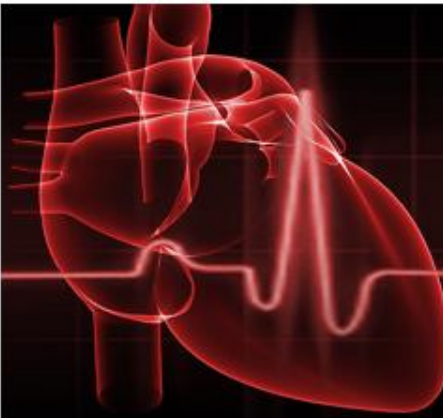
**Left**



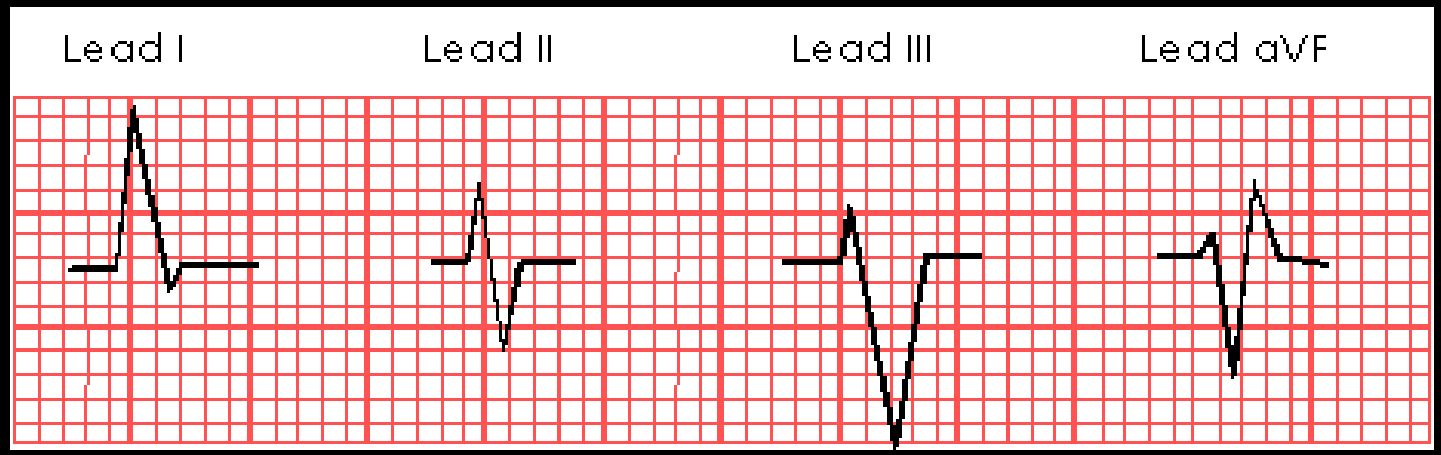
# Normal, Right or Left Axis?



**Extreme Right**



# Normal, Right or Left Axis?

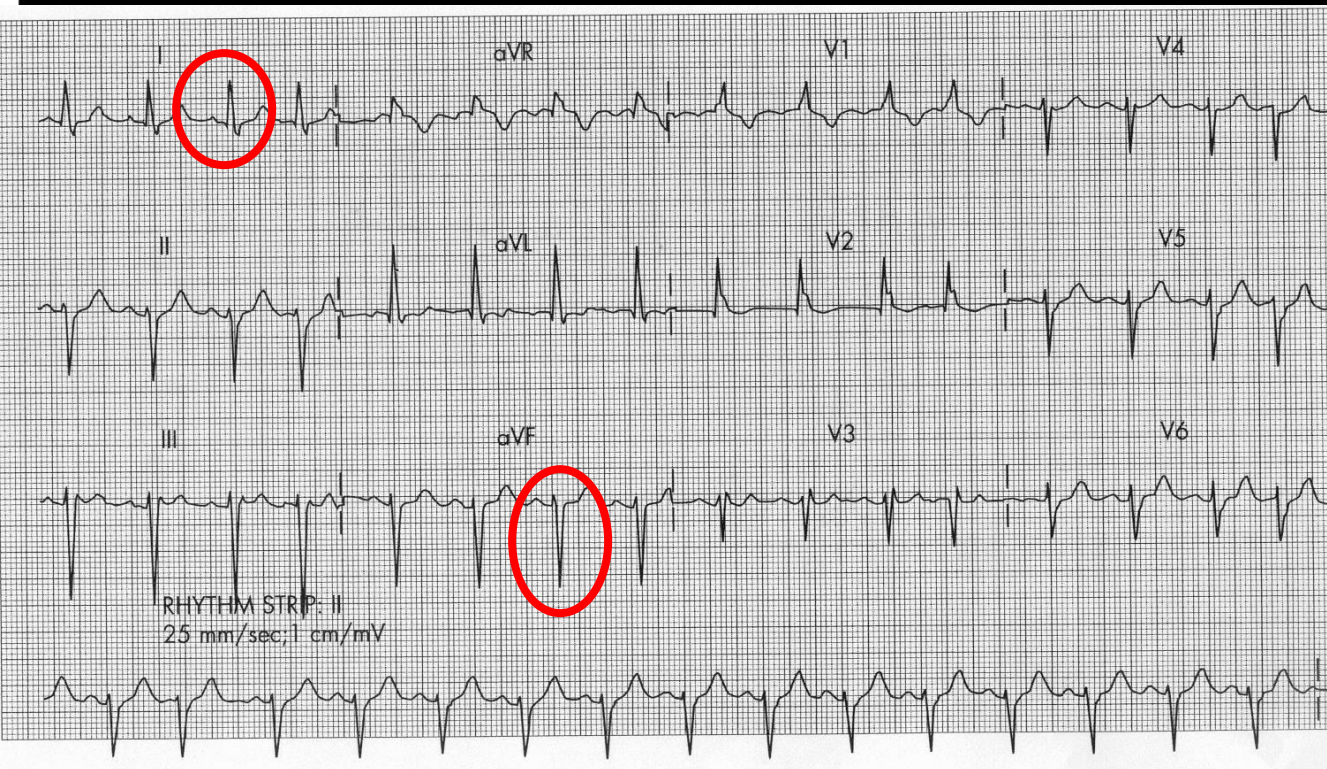


**Left**

# Assessing the Axis

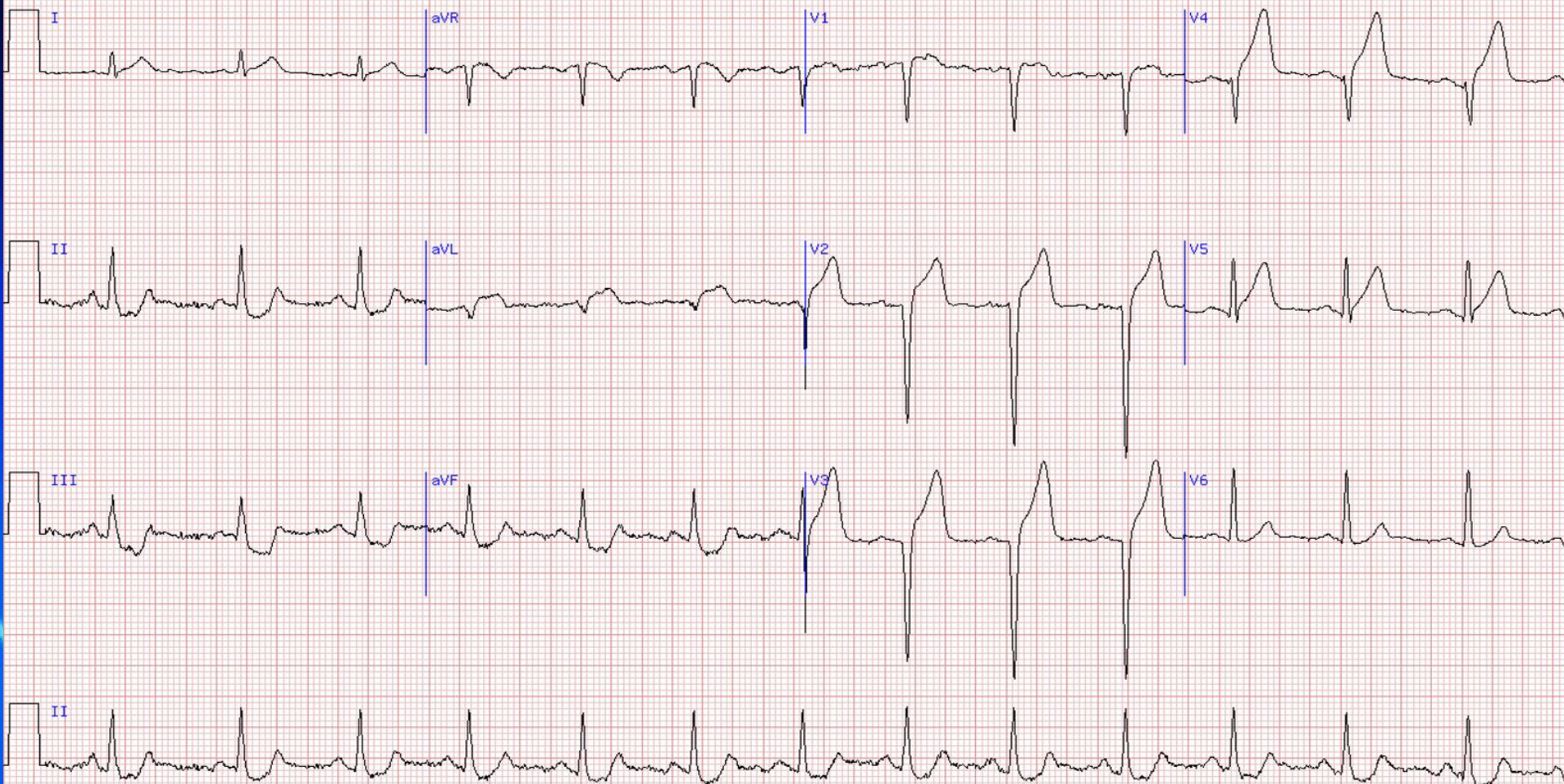

Is the QRS axis normal in this EKG?

*No, there is left axis deviation.*



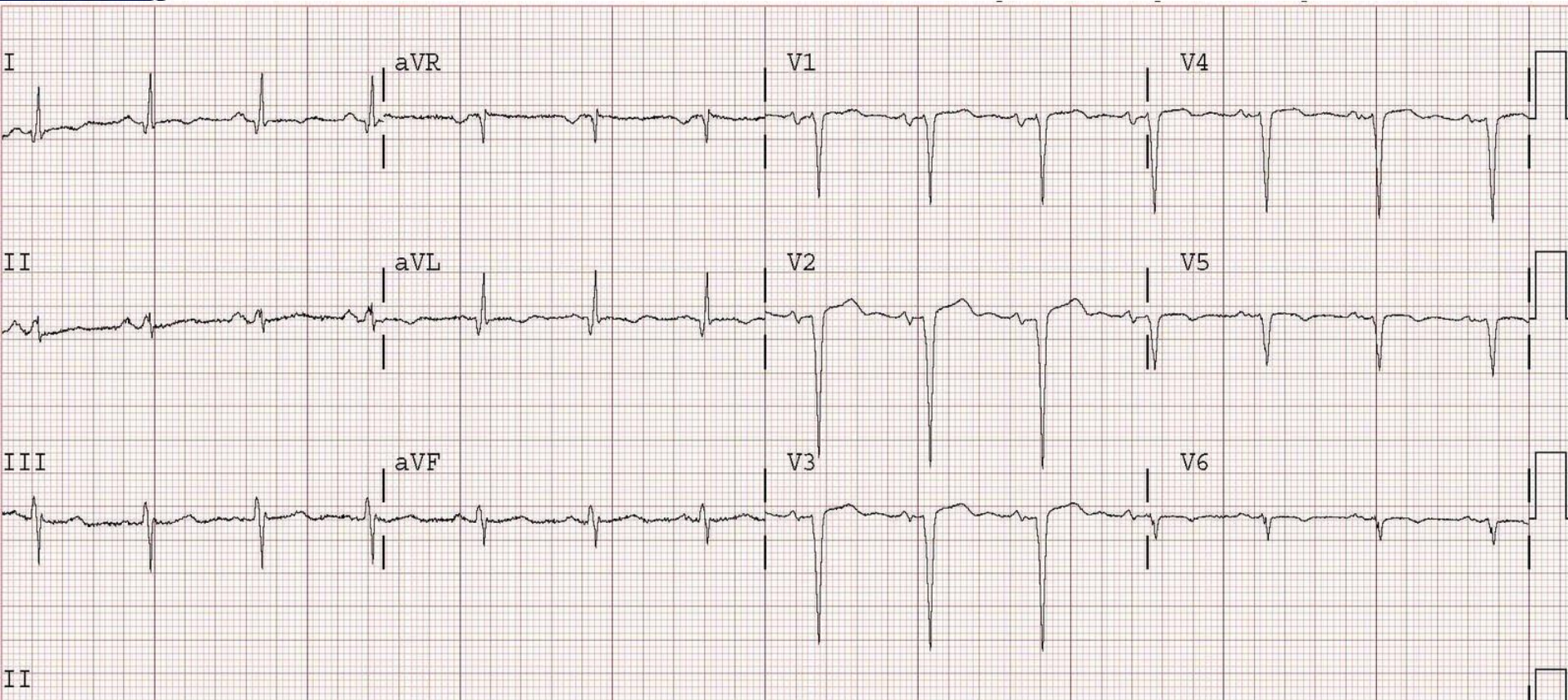
*The QRS is positive in I and negative in aVF.*

# We Wish!!





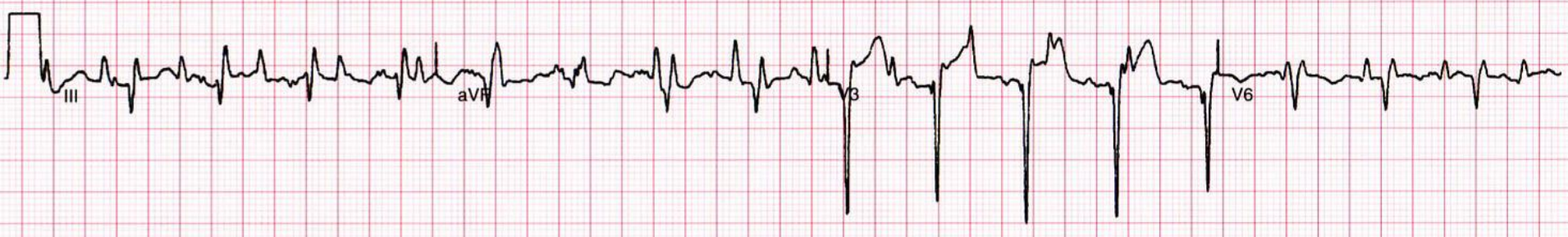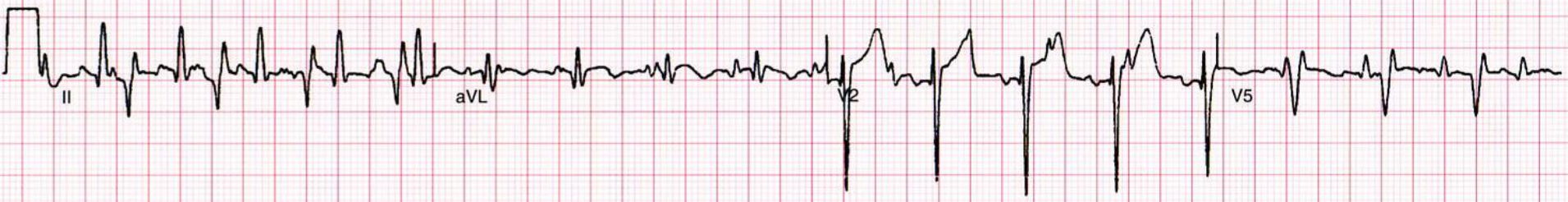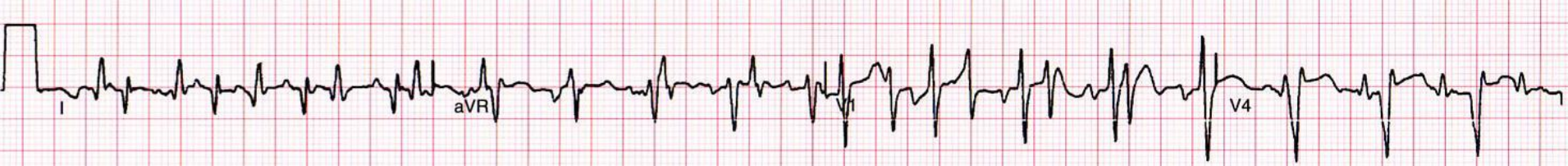# But Sometimes it Looks Like This....




This MI was missed by the medical provider b/c of pts age (29)

## This is a good Starting point

- 42-year-old male presents to the ED with a complaint of chest congestion and cough. He has a history of a heart transplant for ischemic cardiomyopathy 1 year ago. He has been afebrile, but his chest hurts from coughing.
- No tobacco, alcohol, or drugs.

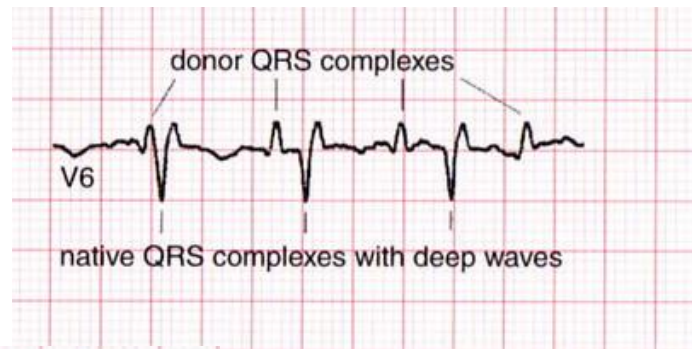


# Auxiliary (Heterotopic or 'Piggyback') Heart Transplant



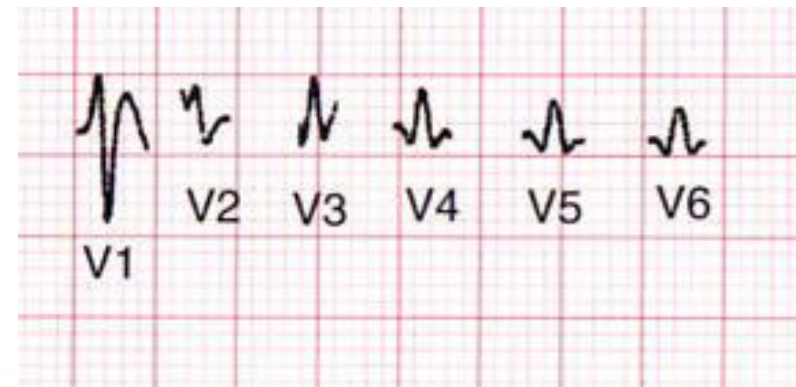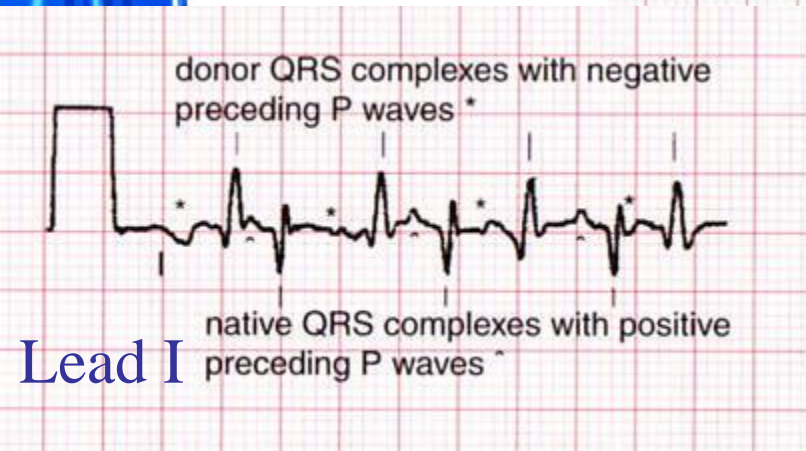
- Native heart

- S. Tach, extreme RAD
- Features of old anterolateral MI with deep Q-waves in leads I & V3-6



- Donor heart

- S. rhythm, normal axis
- Features of Dextrocardia
  - Negative P in lead I
  - Small QRS complexes decreasing in size from V1 to V6



# How It's Done

## How surgeons connect two hearts

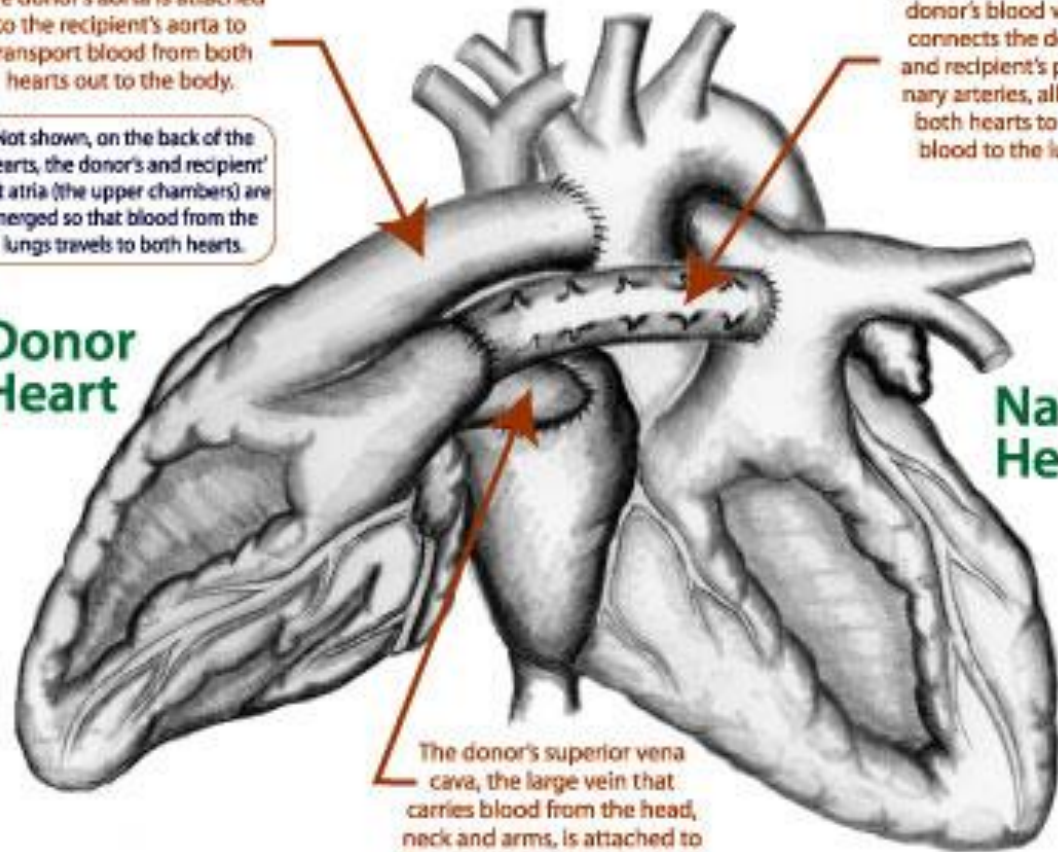
The donor's aorta is attached to the recipient's aorta to transport blood from both hearts out to the body.

Not shown, on the back of the hearts, the donor's and recipient's left atria (the upper chambers) are merged so that blood from the lungs travels to both hearts.

A graft from one of the donor's blood vessels connects the donor's and recipient's pulmonary arteries, allowing both hearts to send blood to the lungs.

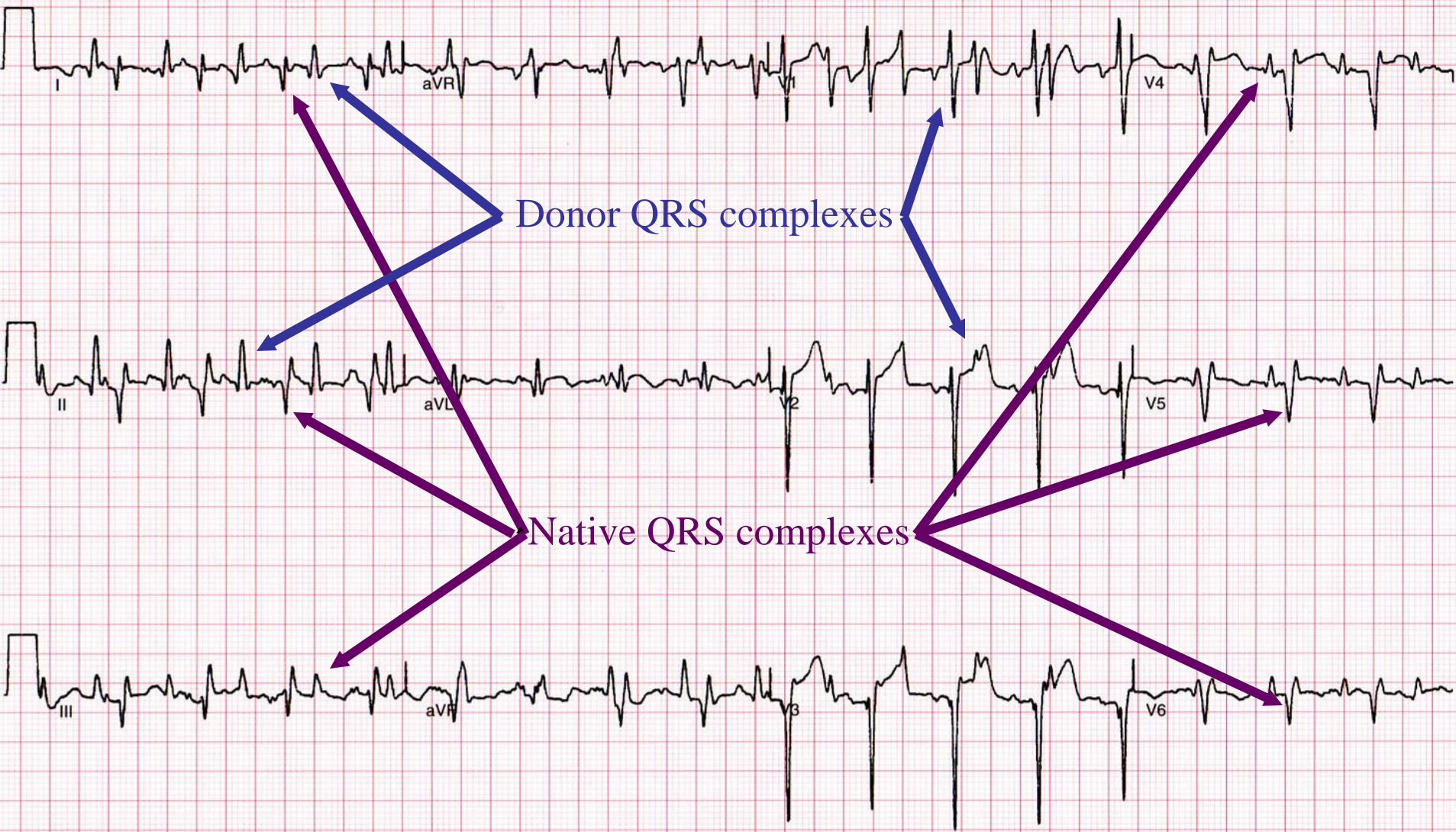
**Donor Heart**

**Native Heart**

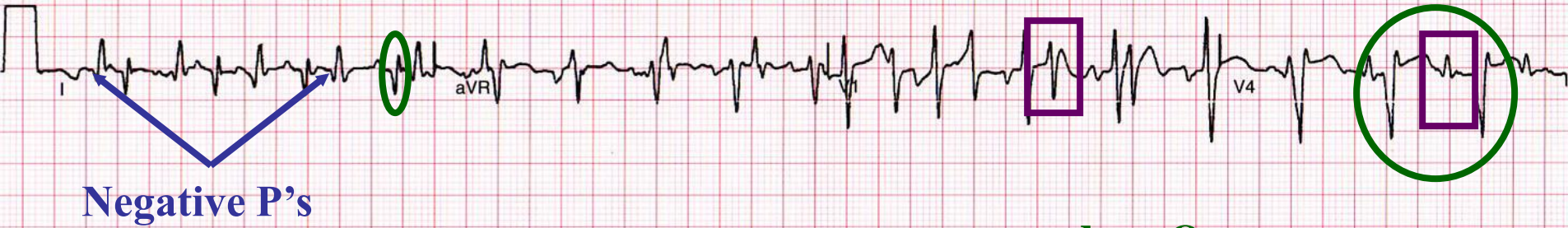

The donor's superior vena cava, the large vein that carries blood from the head, neck and arms, is attached to the recipient's right atrium so that blood from the body now flows to both hearts.

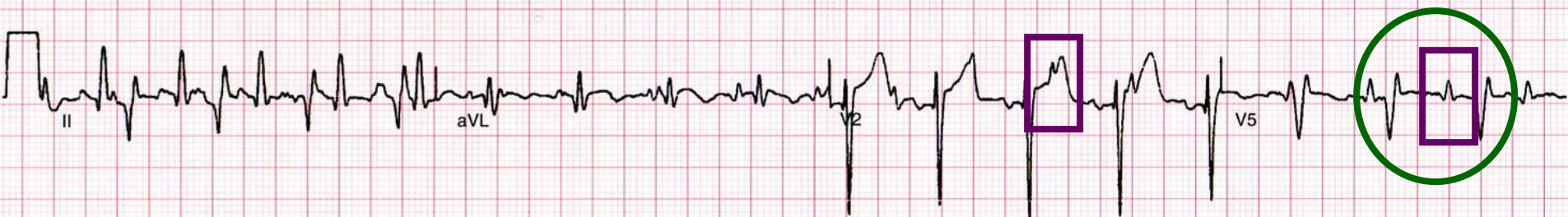# Auxiliary (Heterotopic or 'Piggyback') Heart Transplant



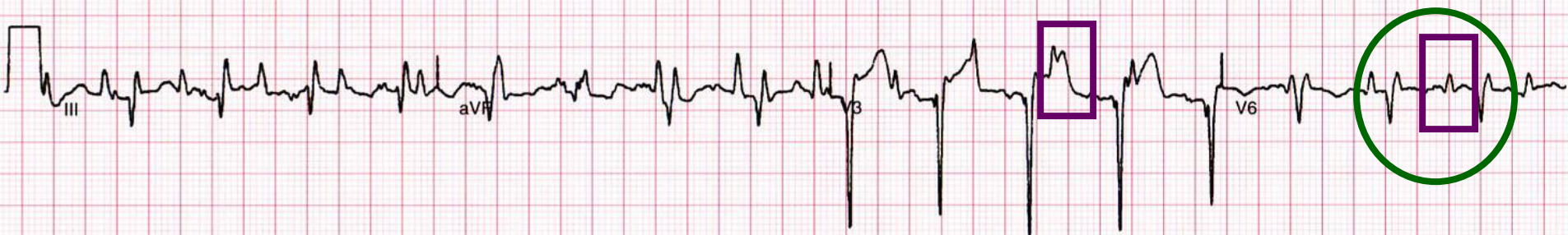# Auxillary Heart Transplant



**deep Q-waves**



**Small QRS complexes V1 to V6**

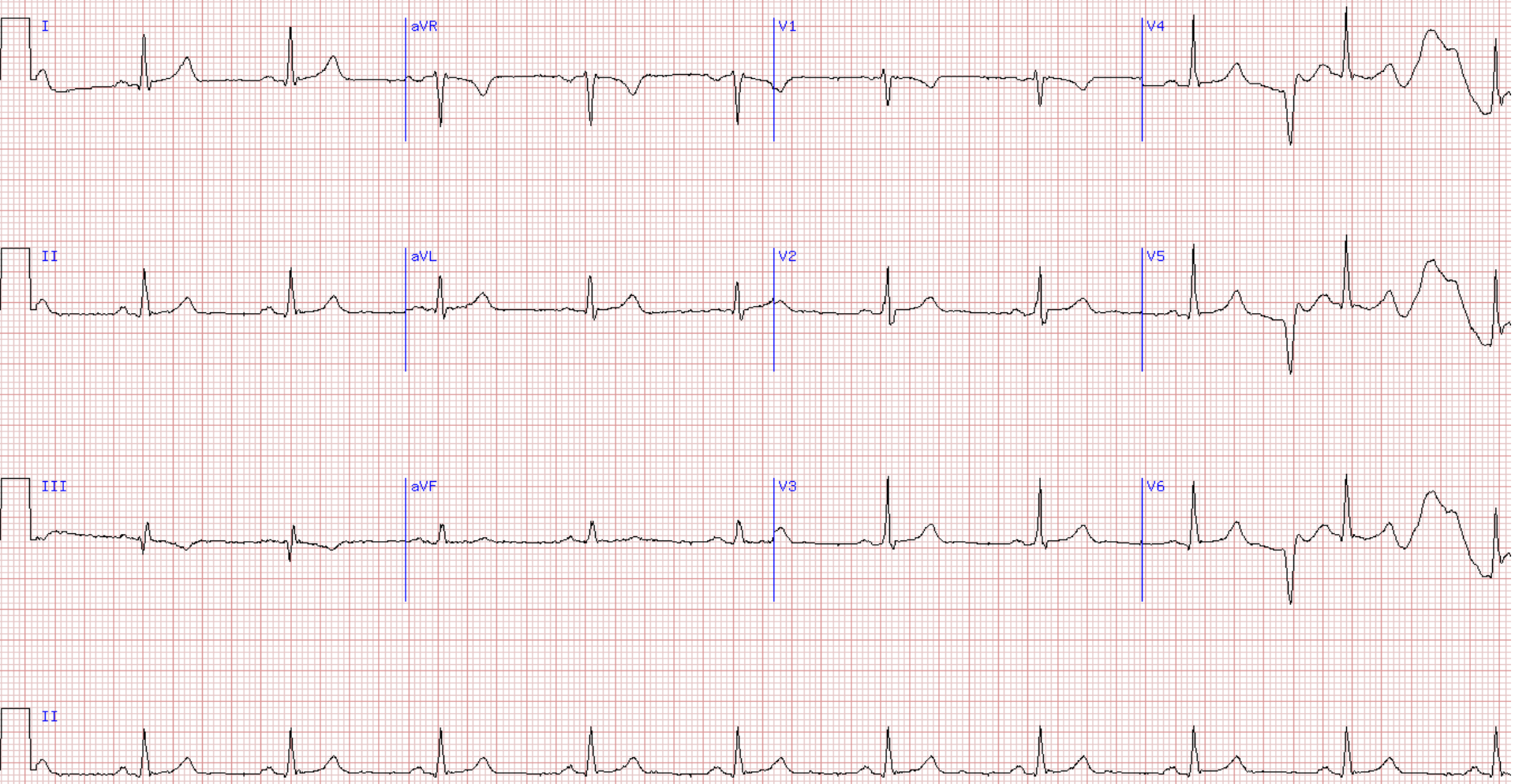


# Our Next Patient.....

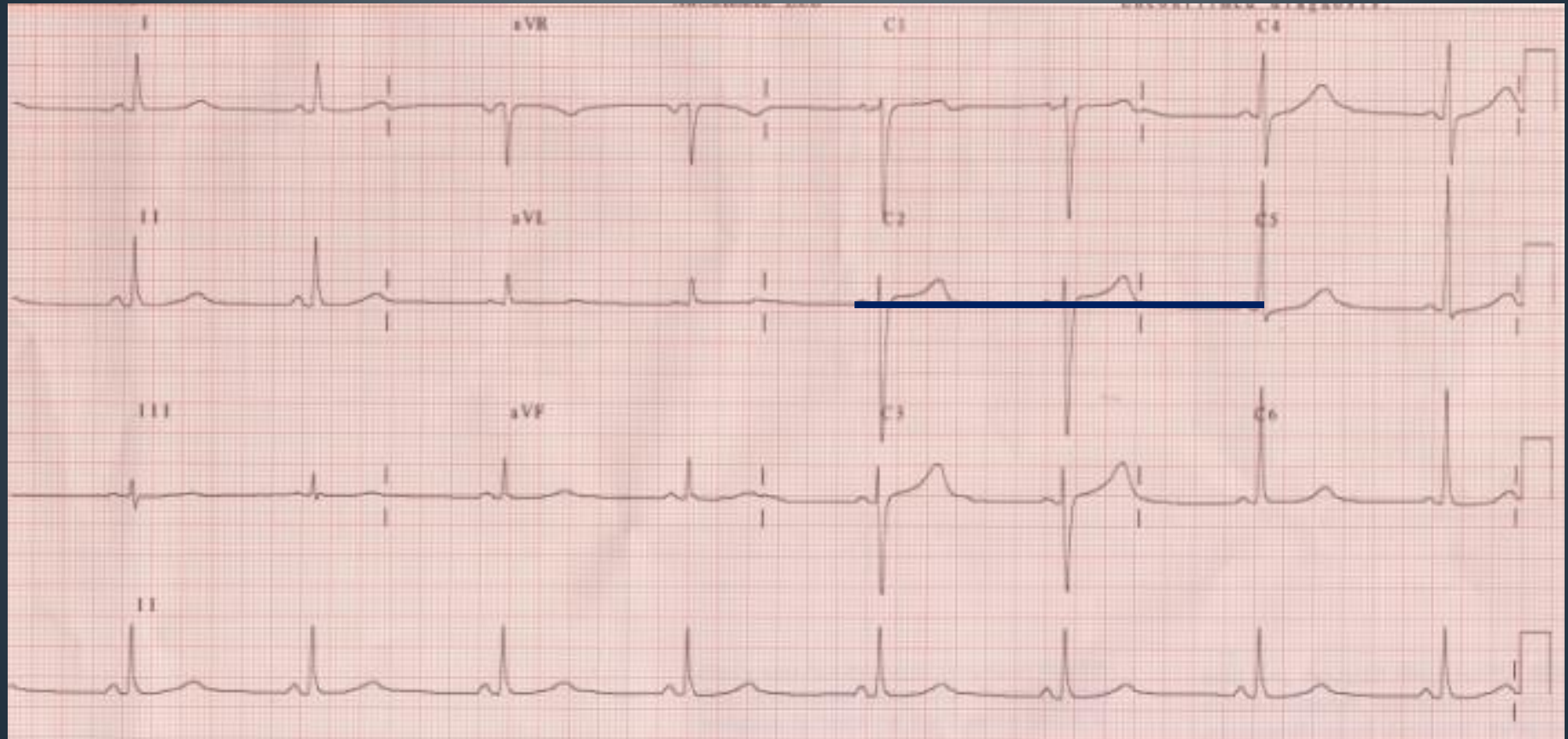
- **A 58-year-old male calls EMS complaining of chest discomfort that awoke him out of his sleep. Upon EMS arrival, the patient is found sitting on the edge of the bed. He is anxious but alert and oriented to person, place, time, and event.**
- **Onset: 30 minutes ago while sleeping**
- **Provoke: Nothing makes the pain feel better or worse**
- **Quality: Severe pressure or “ache”**
- **Radiate: The pain does not radiate**
- **Severity: 10/10**
- **Time: He has had chest pain before but “not this bad”**
  
- **Past medical history: HTN, dyslipidemia**
  
- **Medications: Lipitor, Norvasc, ASA**
  
- **Vital signs:**
  - **RR: 24**
  - **Pulse: 60**
  - **BP: 160/98**
  - **SpO2: 96 on RA**
  - **Temp: 99.1**
  - **BGL: 138**
  
- **Breath sounds: basilar rales**
  
- **The patient admits to mild dyspnea. He states that he has “gained a little weight” recently and his doctor was getting ready to put him “on a water pill.”**



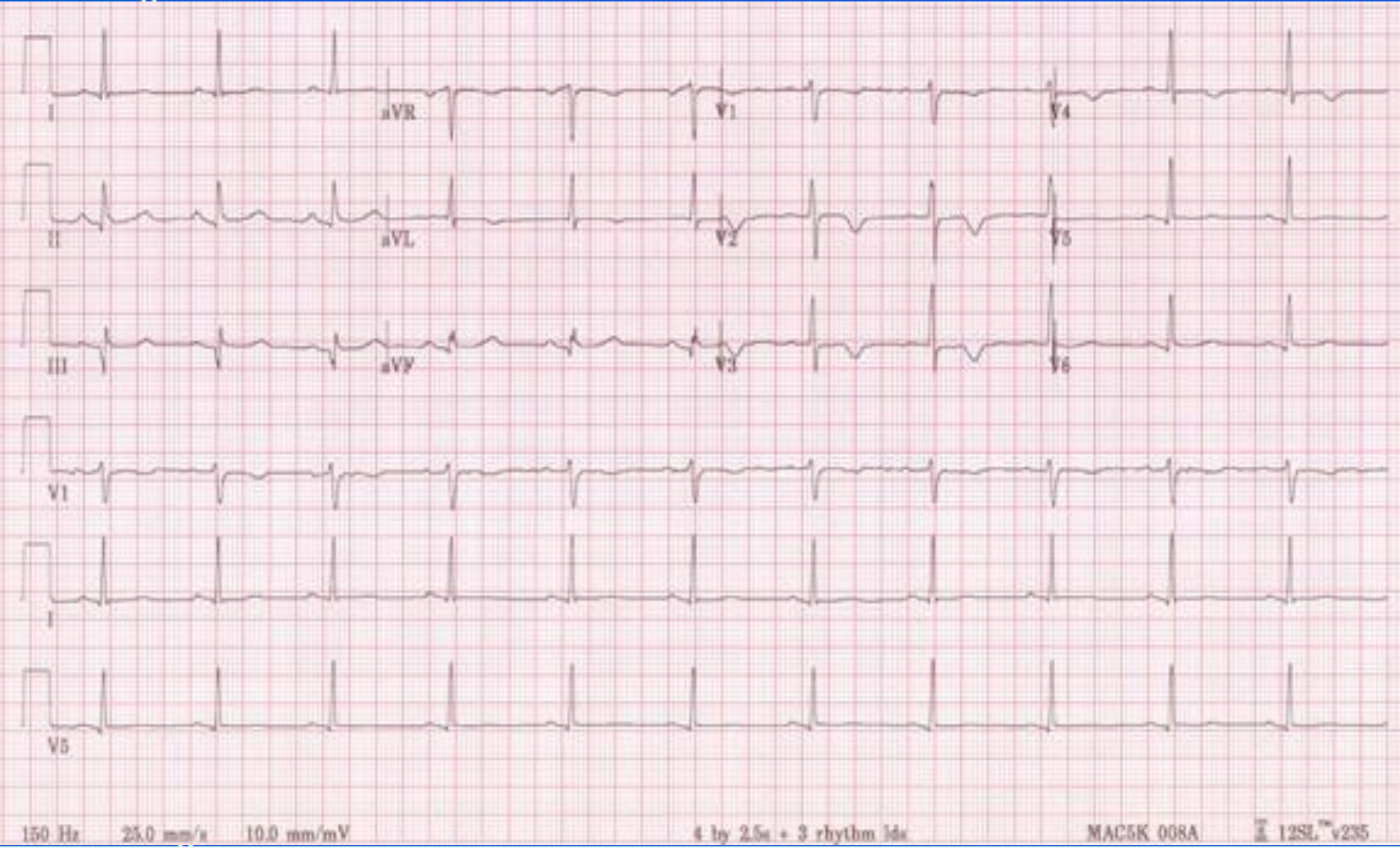# Can I Send Him Home?



# One Hour Later

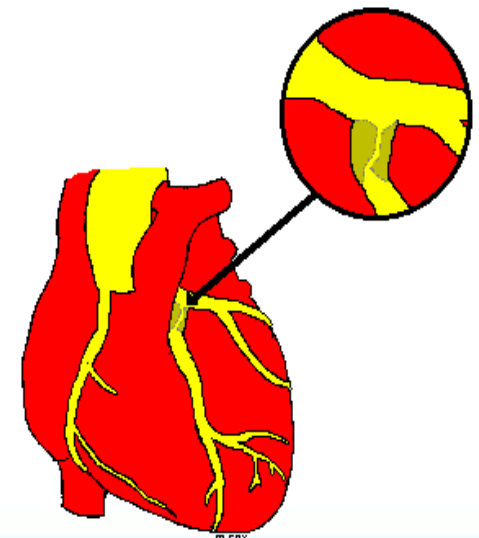


# His EKG 4 days Later What Do You See?



# Wellens Syndrome

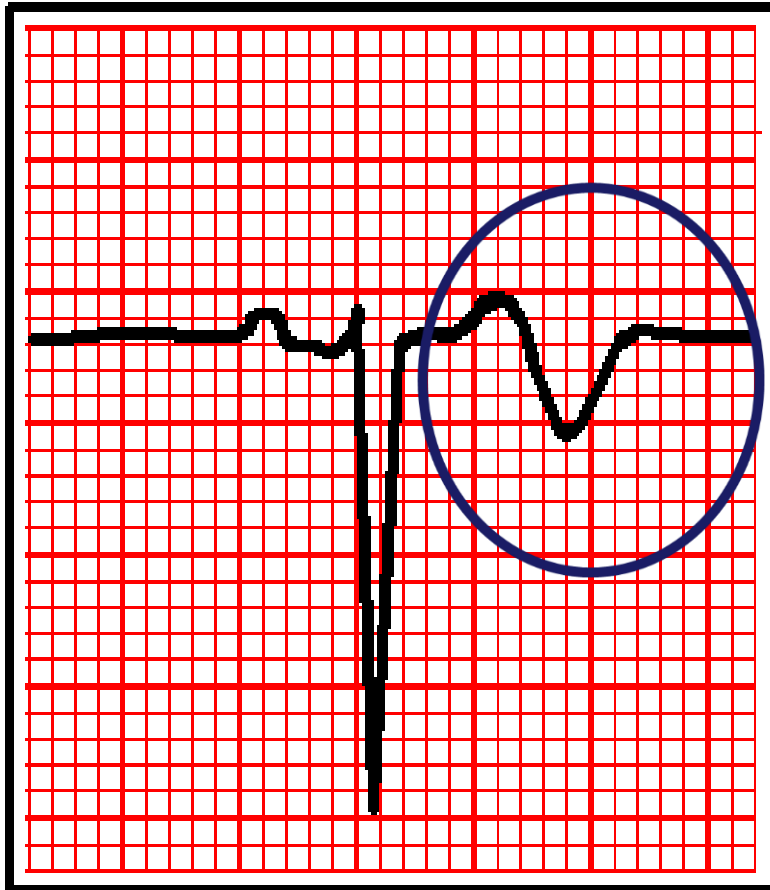
**Wellens Syndrome** is an easy to identify cardiac syndrome which indicates a critical high grade occlusion of the proximal LAD. If not identified and properly treated **the mean time from onset of symptoms to extensive anterior wall MI is 8.5 days**



# Criteria of Wellens Syndrome

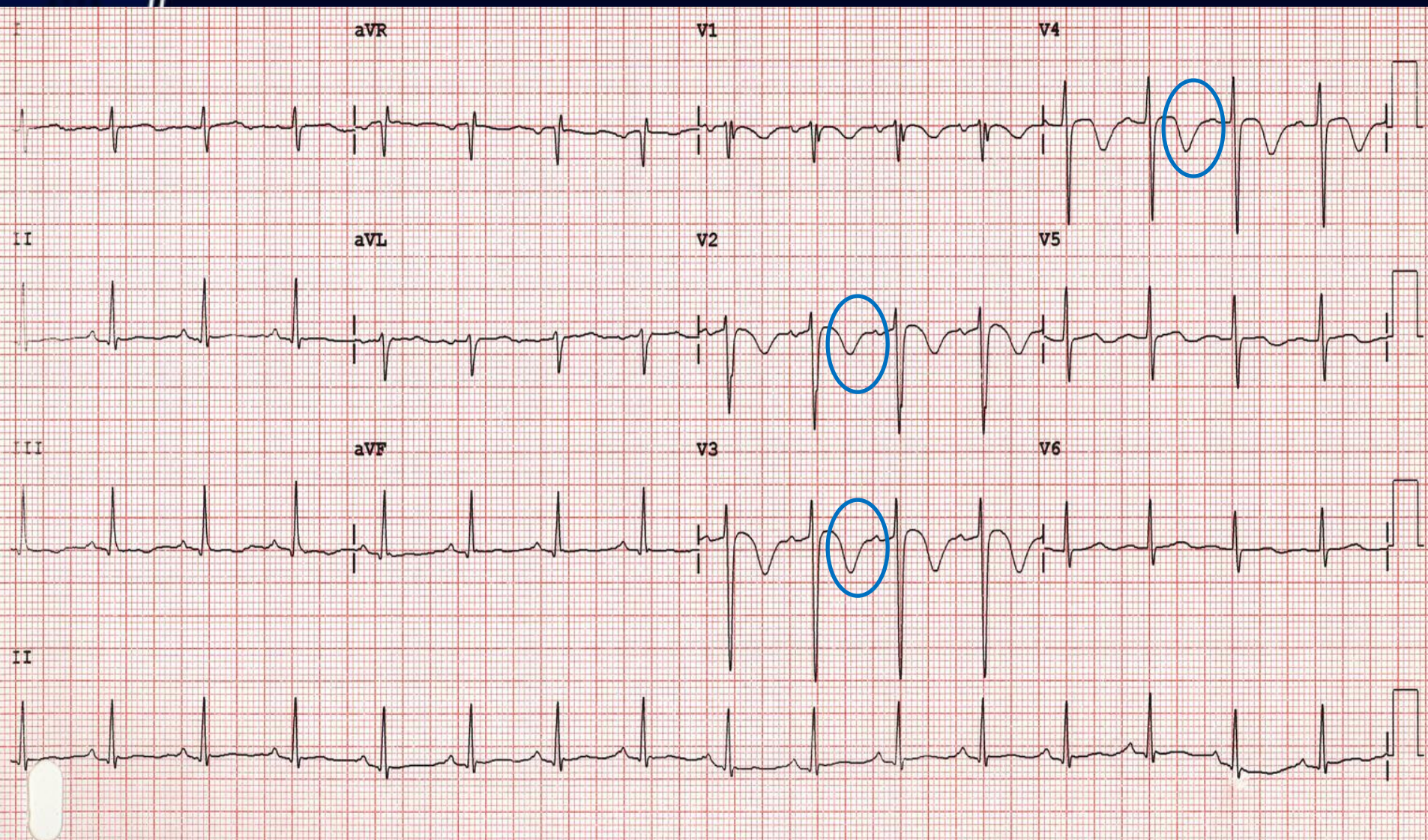
- Prior history of chest pain/angina
- Chest pain with normal EKG
- Normal or minimally elevated cardiac enzymes
- No pathologic precordial Q waves or loss of R waves
- ST segment in V2 and V3 that is isoelectric or minimally elevated (1mm), concave or straight
- Symmetric and deep T-wave inversion or biphasic T-waves in V2-V5 or V6 in pain free periods
- Proximal LAD stenosis

# Wellens Syndrome

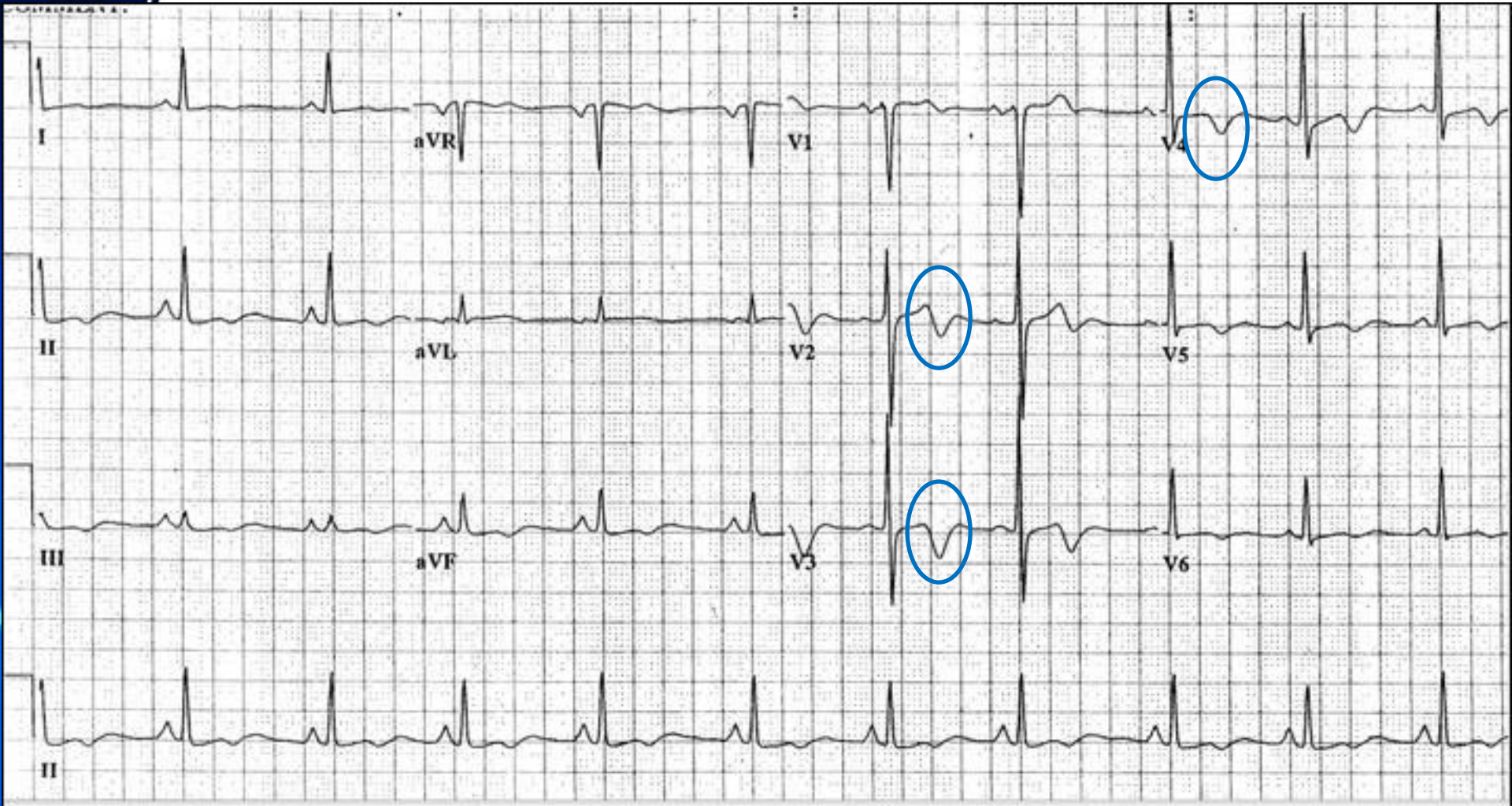

Biphasic T-wave

# Wellens Syndrome Type I



# Wellens Syndrome (Type II)





# Wellens Syndrome Management

Transport to a facility capable of:

- ✓ Prompt percutaneous transluminal angioplasty
- ✓ Cardiac catheterization or
- ✓ CABG surgery

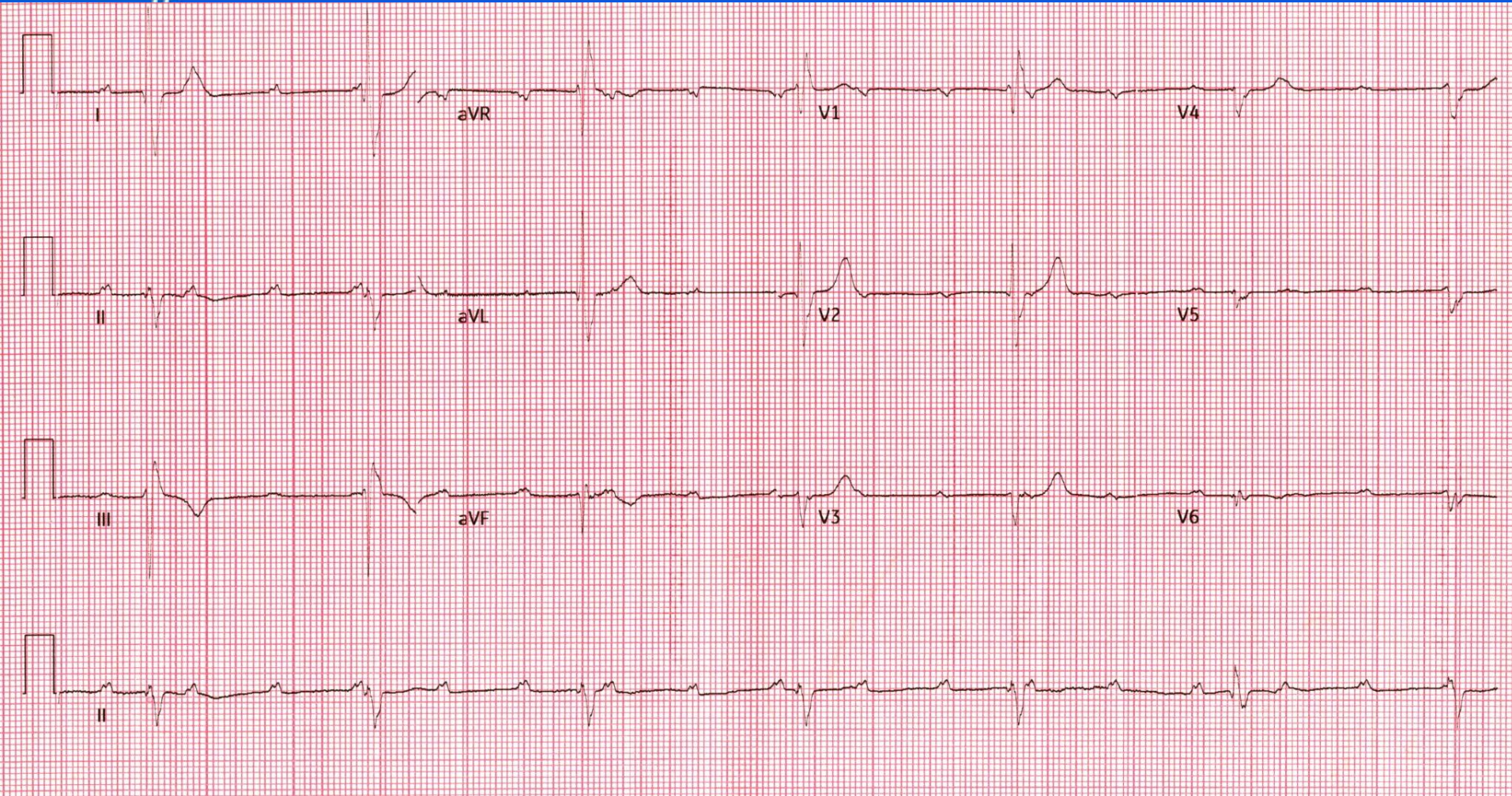
# Which of the following are included in the criteria for Wellens Syndrome?

- a. No history of chest pain, abnormal EKG during pain, ST segment elevation in I-AVF
- b. History of abdominal pain, Nausea, dyspnea, with Left upper extremity paresthesias
- c. Prior history of chest pain/angina, normal EKG during pain, normal or minimally elevated cardiac enzymes
- d. Prior history of MI, Significant Q-waves inferiorly, elevated cardiac enzymes

## What Do you Do Next?

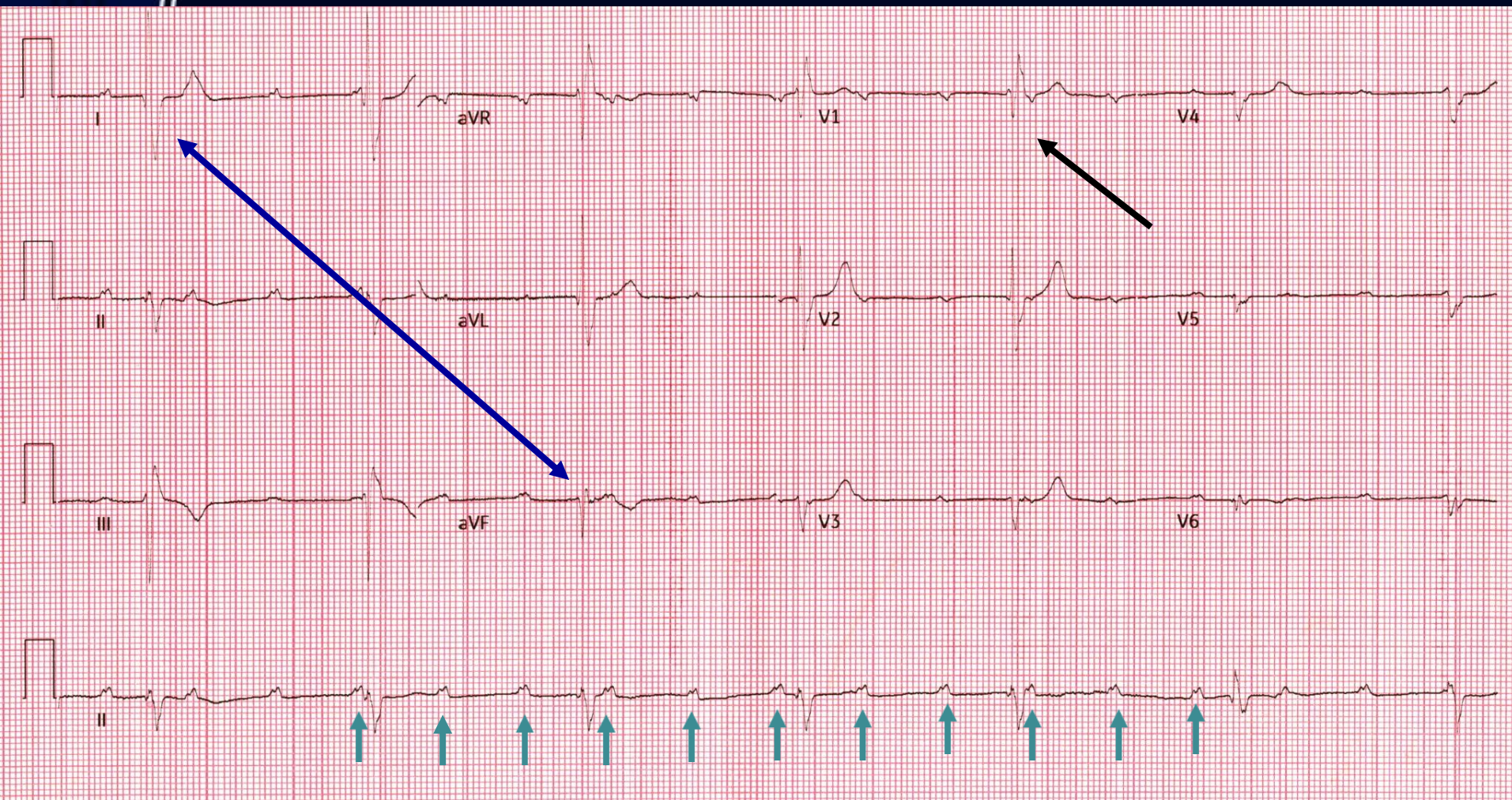
A 78-year-old male has been transported to your facility via EMS. You observe his skin is cyanotic, blue and diaphoretic. His level of consciousness is severely reduced. He is only responding to uncomfortable stimulation. The paramedics report his blood pressure was 42/0 with a weak radial pulse of 28. IV fluids were initiated.

When placed on the EKG monitor, you see the following.....



What do you see and do at this time?

# 3rd AVB LAD RBBB Marked Sinus



Heart rate of about 40 on this EKG

# Why was atropine not given?

- Atropine's ability to accelerate heart rate is due to its parasympatholytic action. By blocking vagal tone, atropine may increase the rate of sinus node discharge and enhance AV-nodal conduction.
- This patient had an infra-nodal 3rd degree AV block. Atropine does not work below the AV node, thus, in this case, a poor choice.

# Why weren't dopamine or epinephrine infusions used?

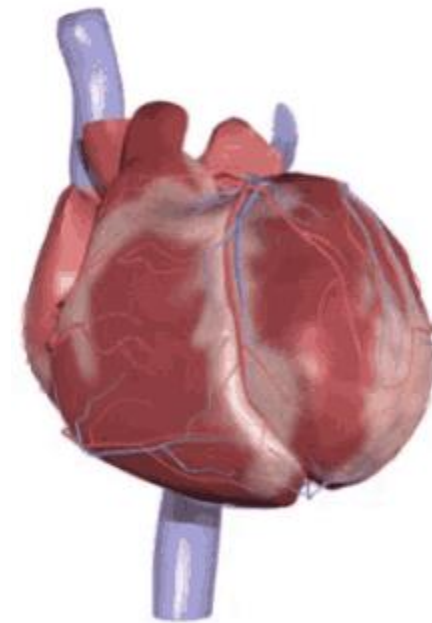
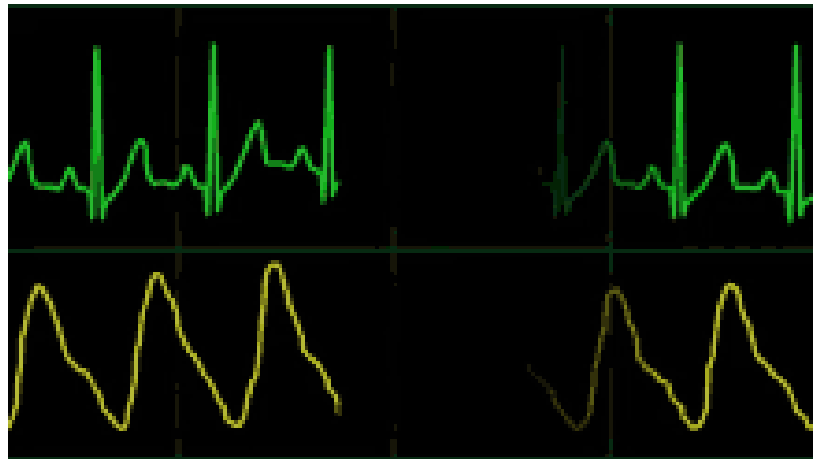
- Both dopamine and epinephrine have beta adrenergic stimulating properties and can speed all cardiac pacemaker sites. (sinus, junction and ventricular) Thus, if the pacing was not available, these agents would be recommended. When considering therapeutic options, consideration should be given to common side-effects, which in this case may include:
  - Unwanted tachycardia
  - Increased myocardial oxygen consumption
  - Pro-arrhythmia (may promote malignant arrhythmogenesis)

# Why was transcutaneous cardiac pacing employed as the first measure?

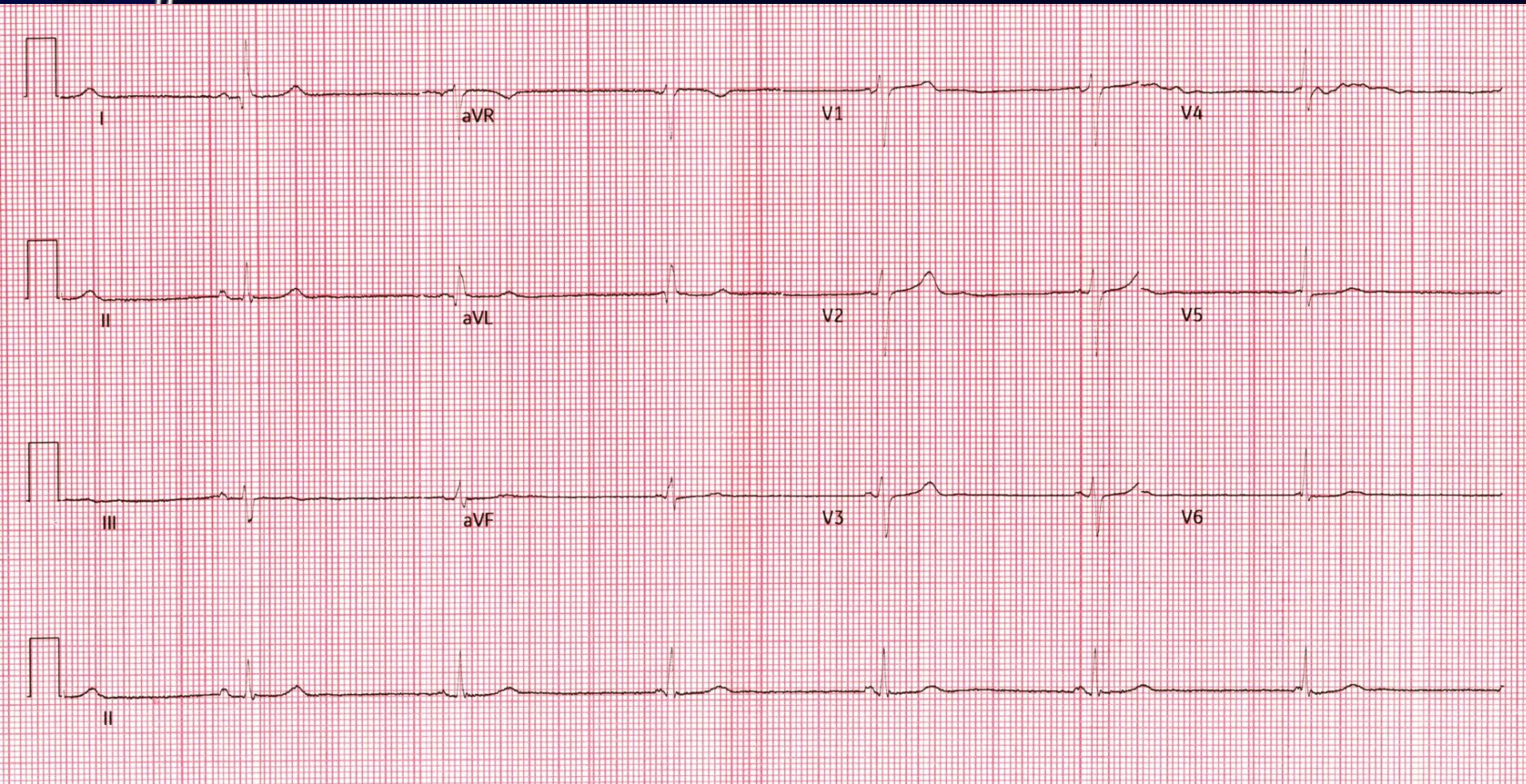
- TPC was the best option in this case. Practitioners should remember that treatment algorithms usually leave out the patient, and, provide a number of treatment options without reference to the underlying clinical causes.



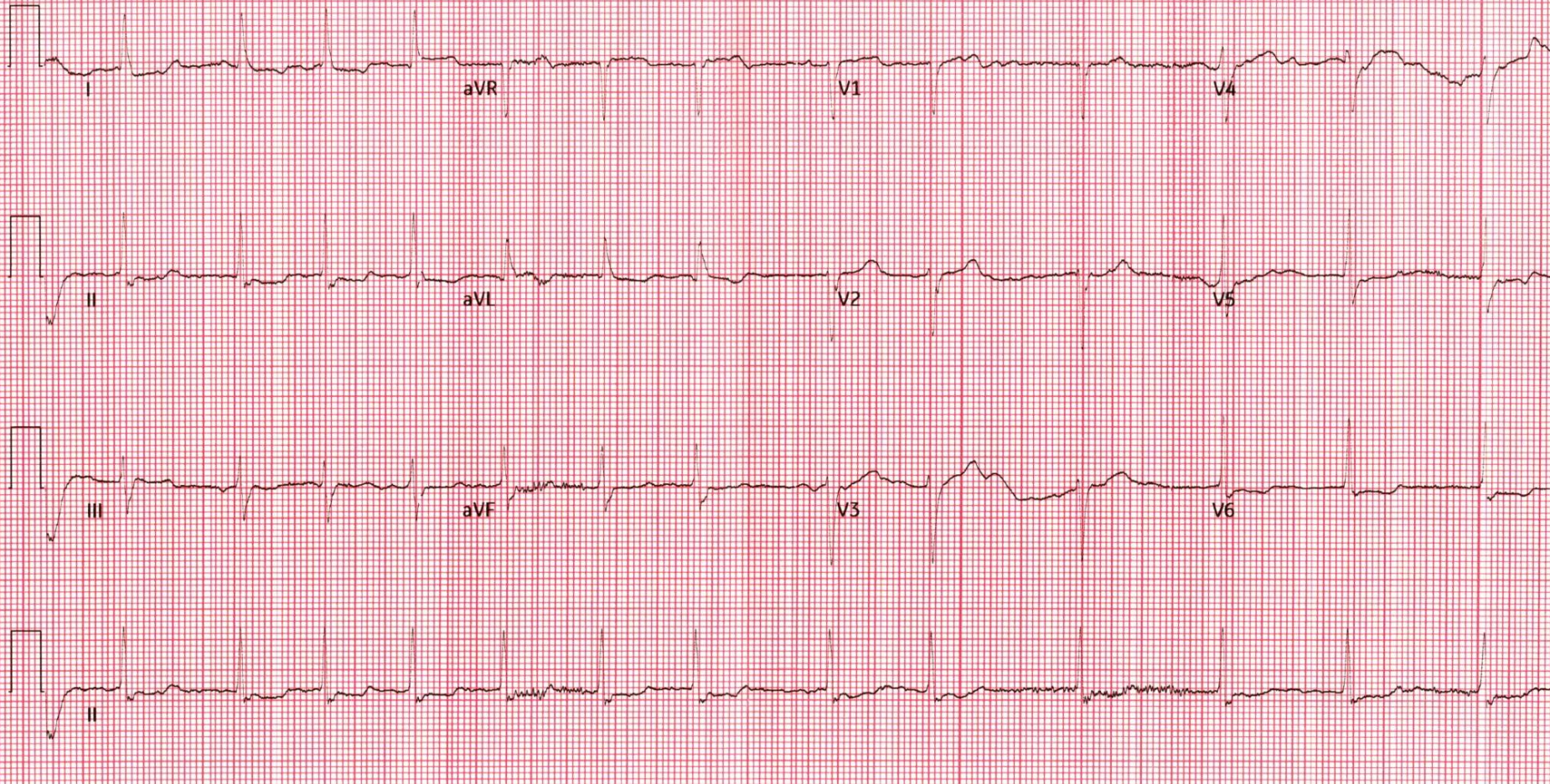
Let's read some EKG's



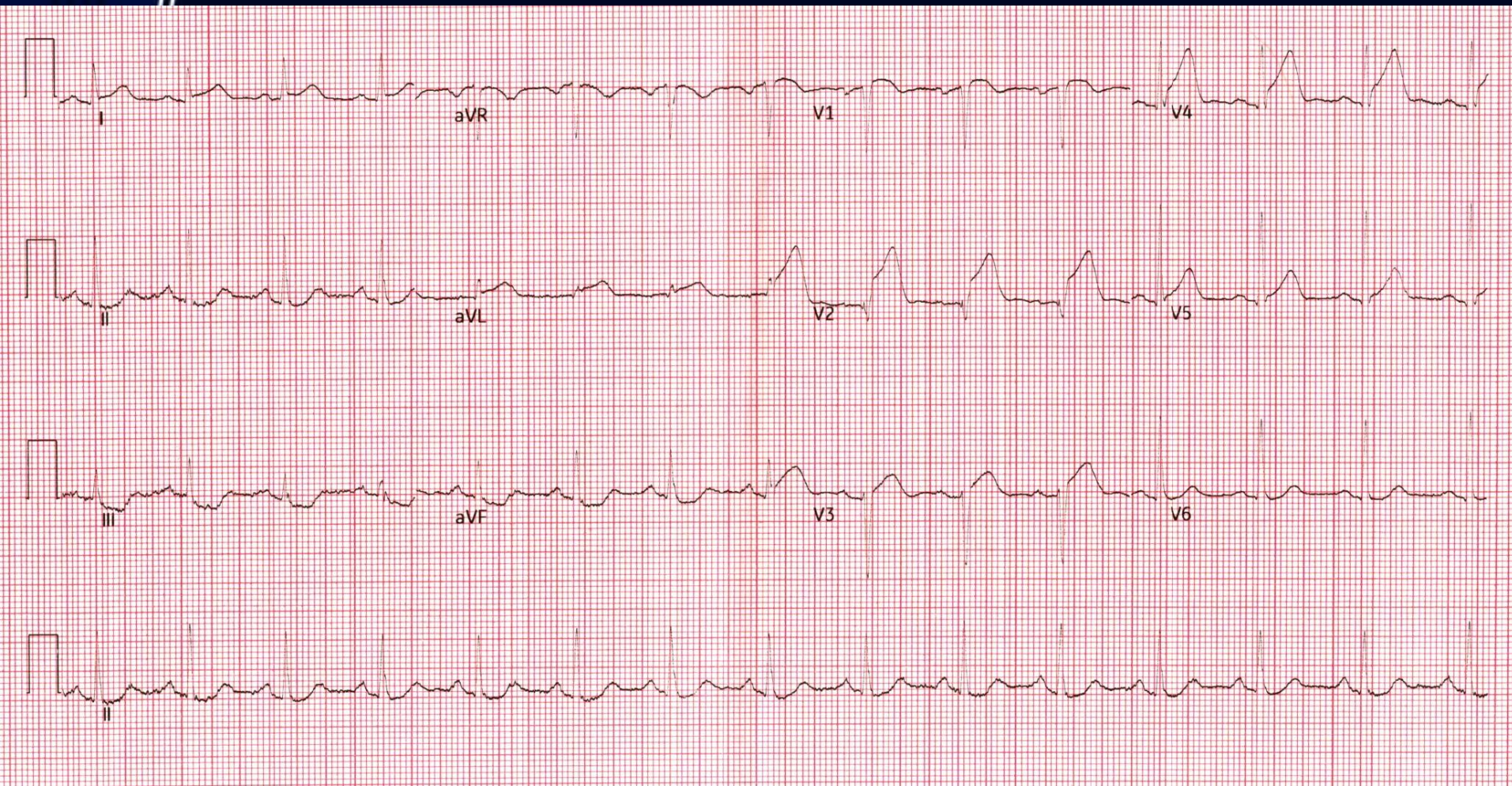
# Junctional Bradycardia



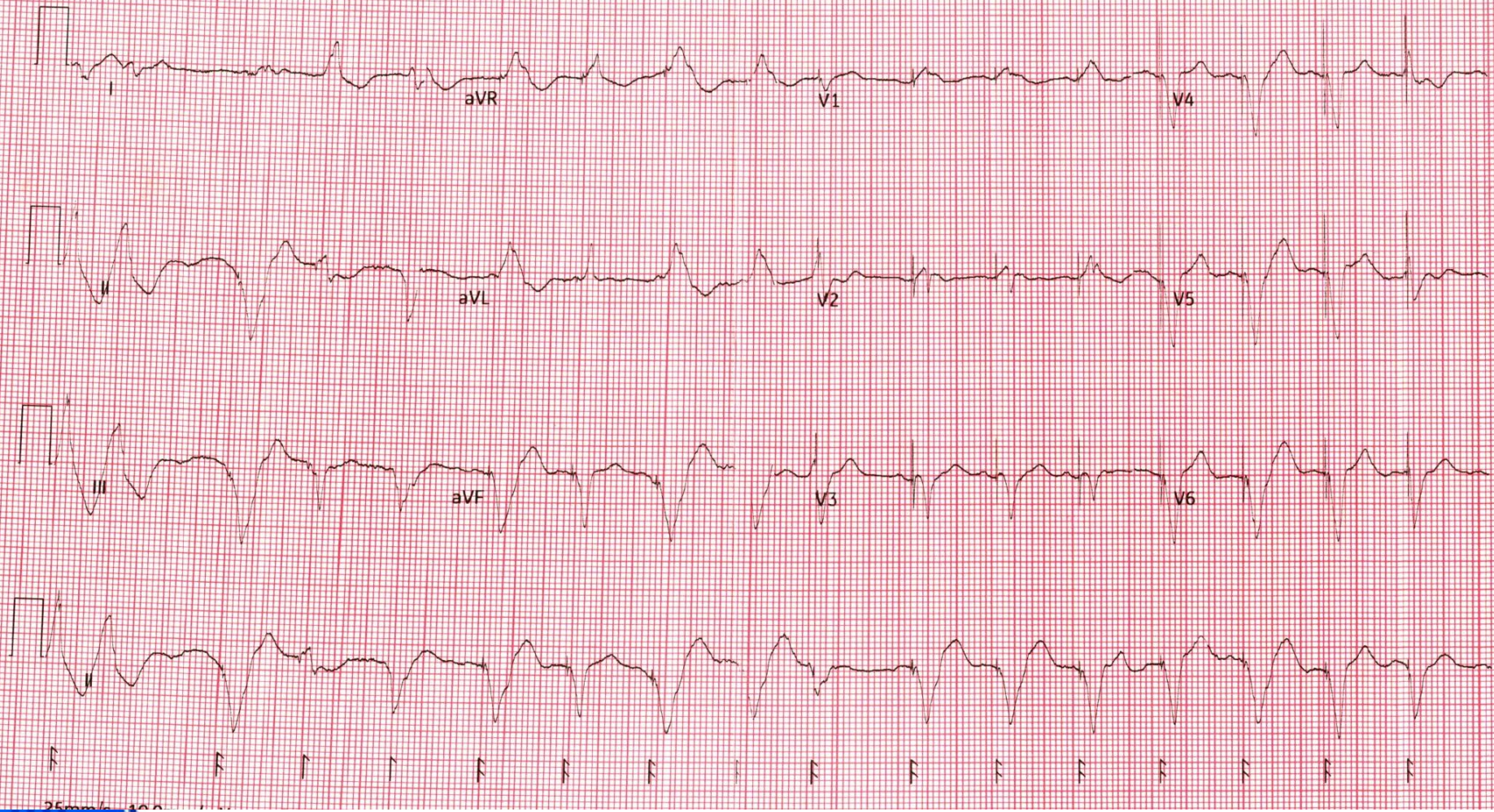
# Atrial Fib w/Lateral Ischemia



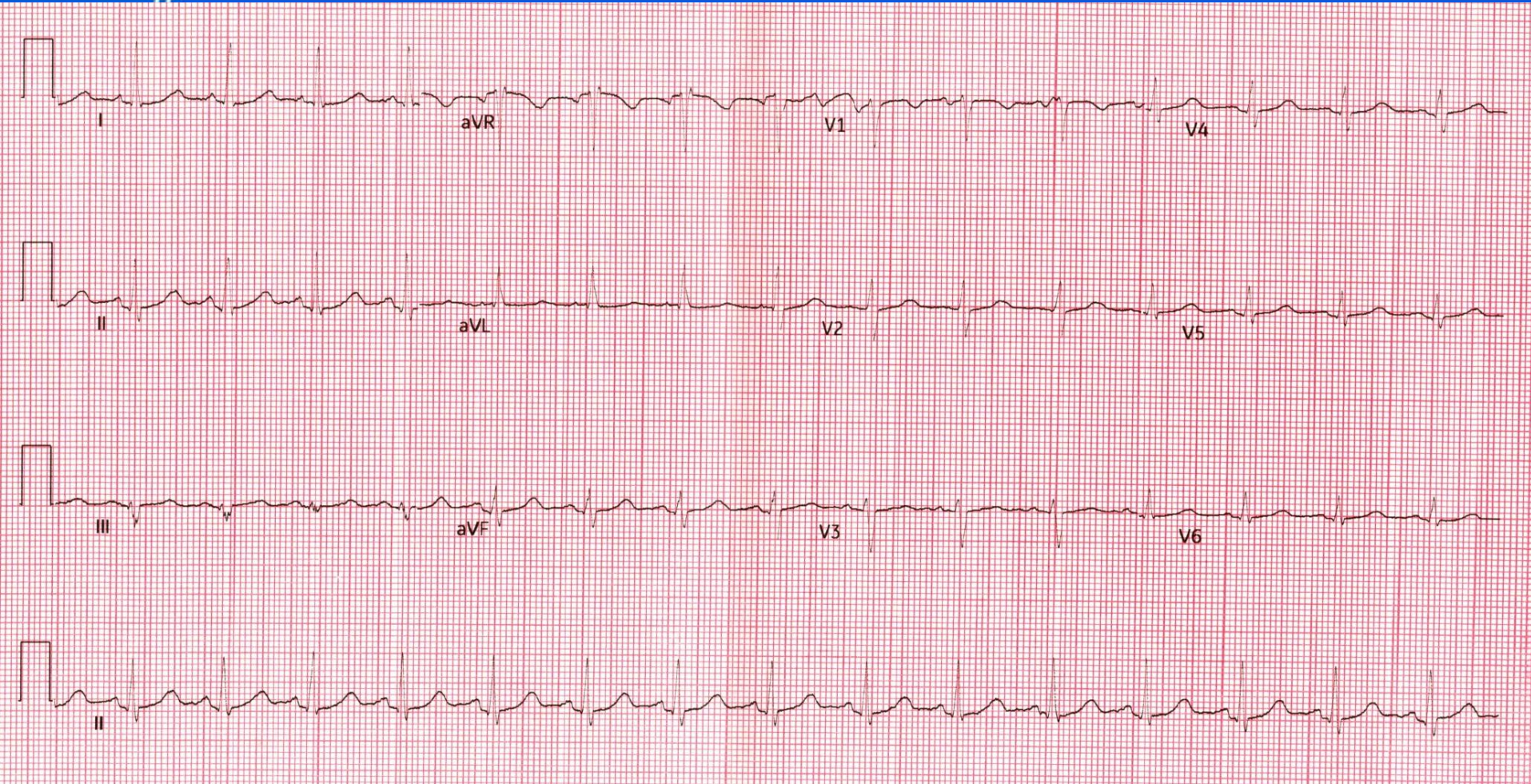
# Anterior Wall STEMI



# Atrial Sensed Ventricular Paced Rhythm

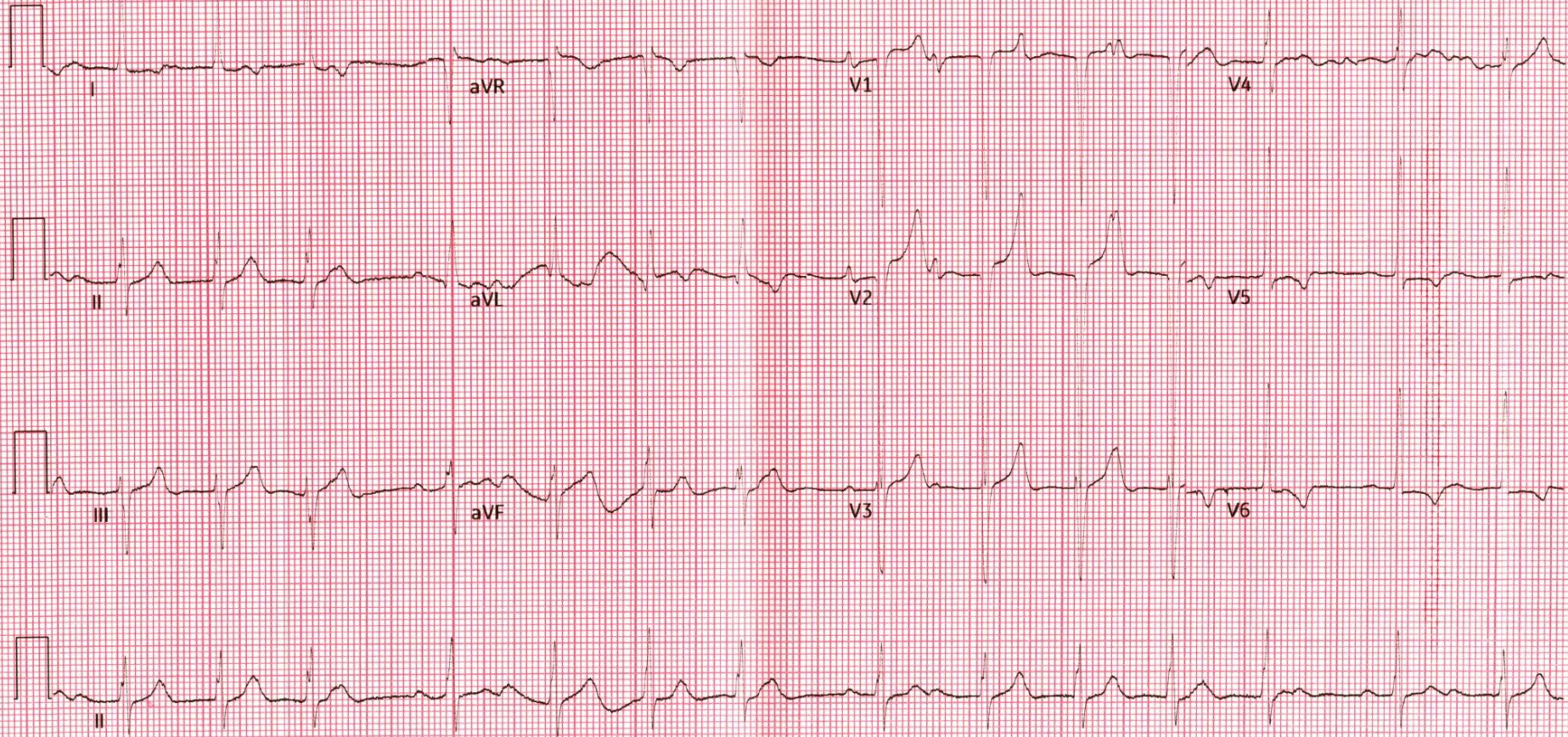


# Prolonged QT



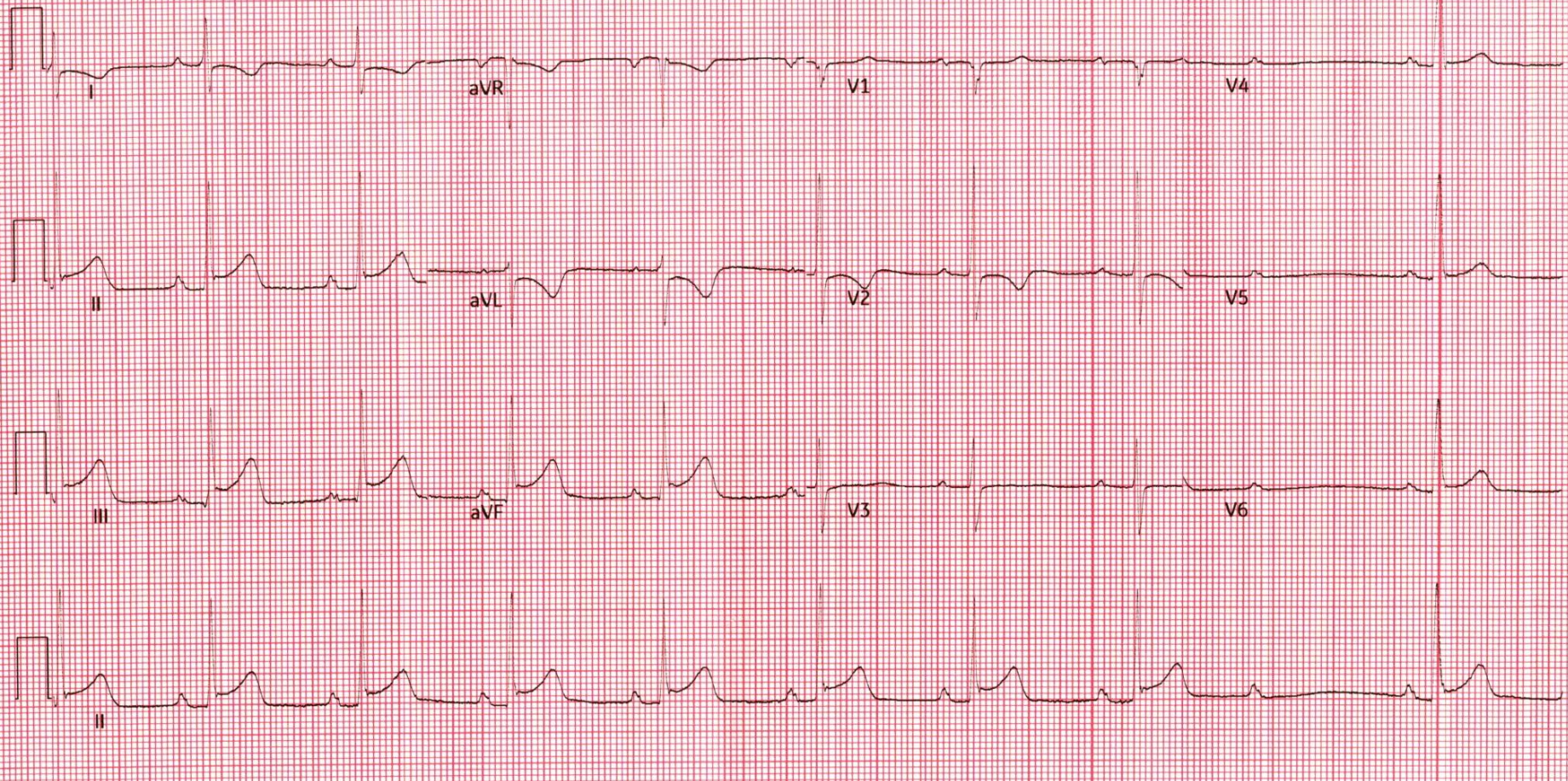
NSR w/prolonged QT (505ms)

# Septal Infarct 2nd AVB & Sinus Tach



HR:86, lateral ischemia seen also

# Sinus Brady (HR 52) w 2nd AVB Inferior STEMI



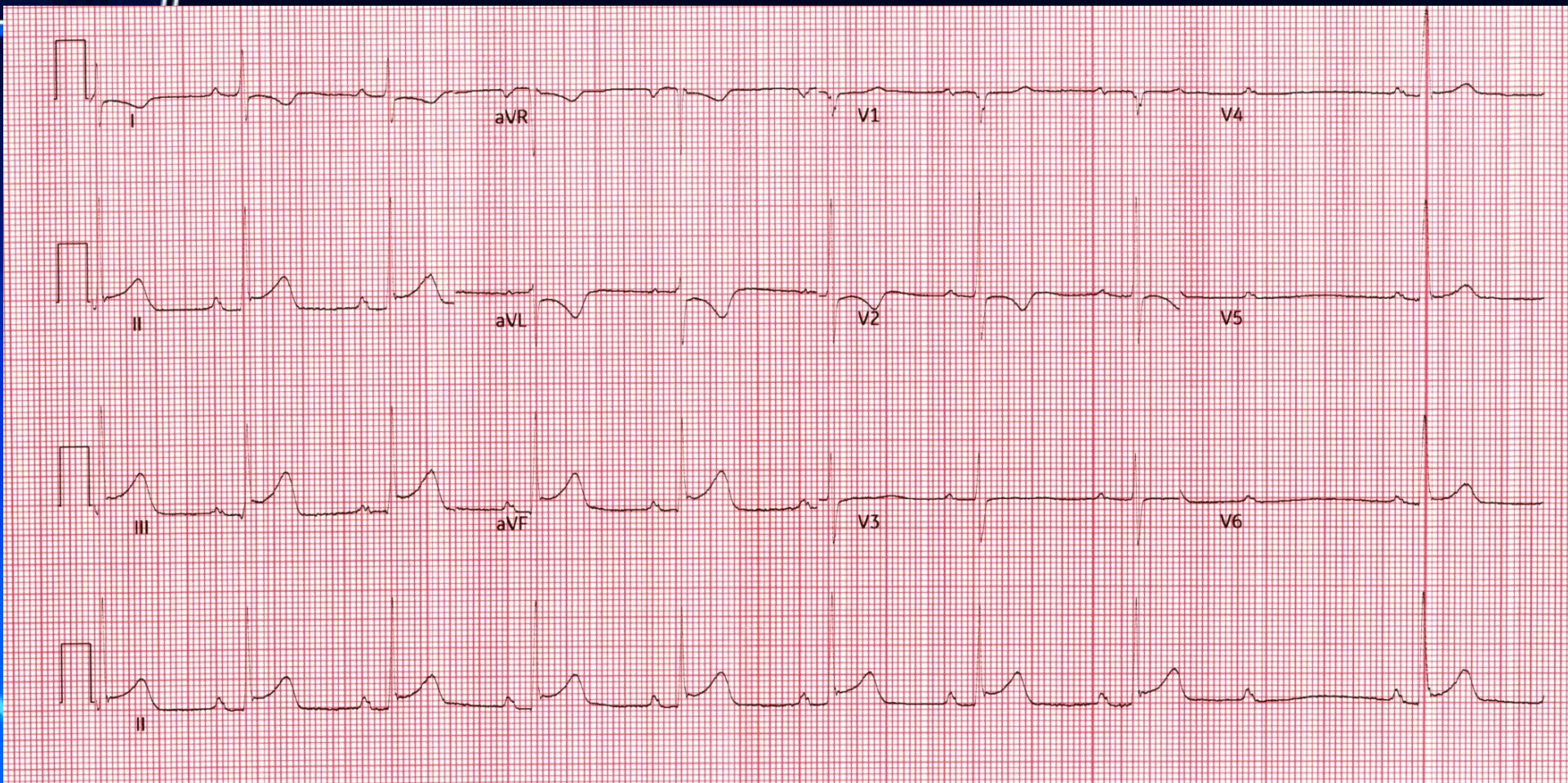


# Elderly Lady Scared of Covid

An 84-year-old female presents to your clinic for evaluation after experiencing severe chest pain over the past 24 hours. She didn't want to go to the ER out of fear of contracting covid. She has a history of hypertension and heart failure but under regular care by you. She also has not stopped smoking (1ppd) as you recommended. Her medications included aspirin, digoxin, and Norvasc. Except for surgical treatment of gallstones several years earlier, the remainder of the patient's medical history is unremarkable.

On physical exam, the patient was found to be well nourished, well developed, and in no acute distress. Her blood pressure was 198/90 with a pulse rate of 52. Her skin was warm and dry and there was no jugular venous distention noted. She had normal S1 and S2 sounds; no rubs, gallops, or murmurs were heard. Except for surgical scars, her abdomen was normal. Her distal pulses were all full and equal.

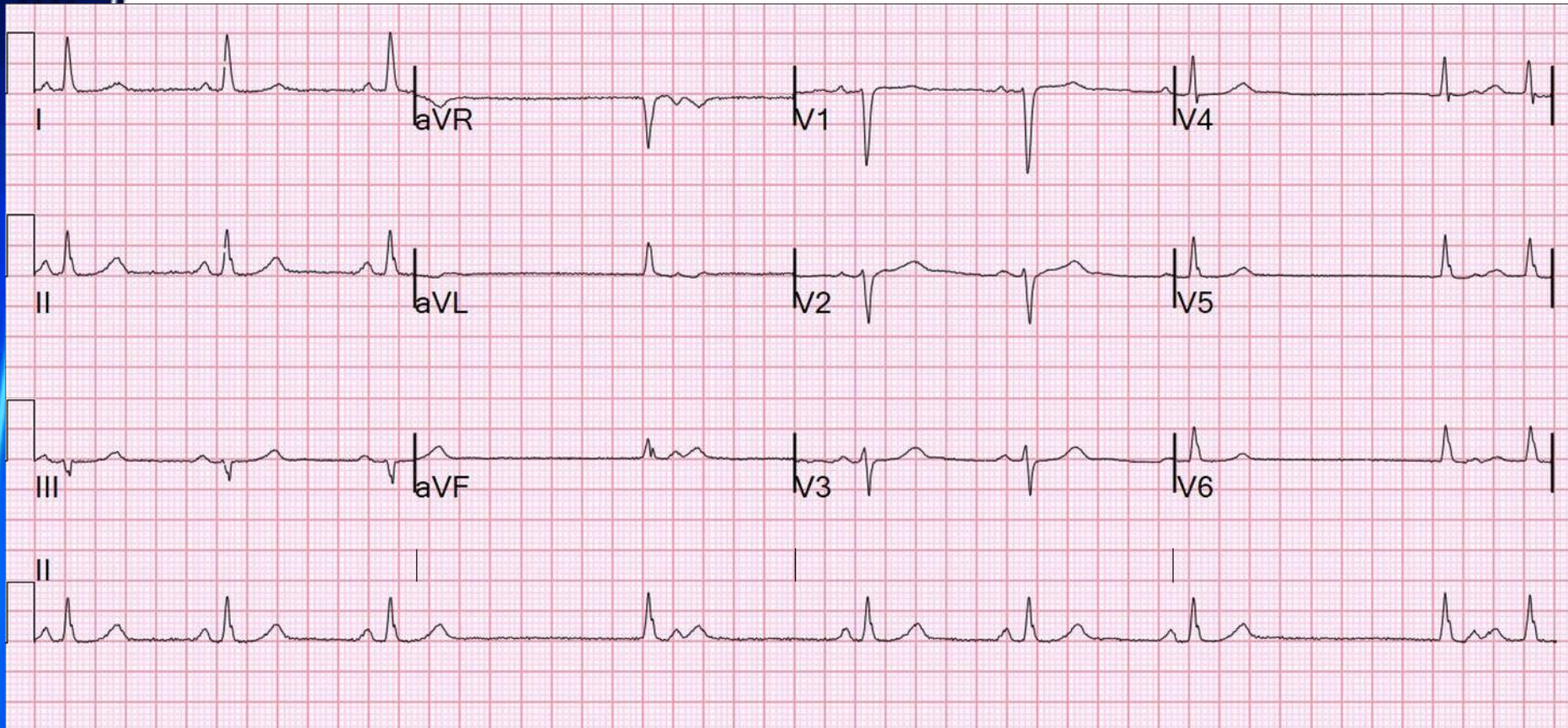
You perform a stat ekg.....



ST elevation inferiorly, lateral/anterior ST depression noted

# Just Prior to Transfer to the ER

The patient experienced a syncopal episode. Another EKG was performed as her heart rate is erratic at this time.



What do you see and what is the cause of this?

# Sinus Arrest/Sick Sinus Syndrome

- Sick sinus syndrome is a group of heart rhythm problems due to problems with the sinus node, such as:
- The heartbeat rate is too slow, called sinus bradycardia
- The heartbeat pauses or stops, called sinus pauses or sinus arrest
- Episodes of a fast heart rate
- Slow heart rhythms that alternate with fast heart rhythms, called bradycardia-tachycardia or "tachy-brady syndrome"

# Alternative Names

- Bradycardia-tachycardia syndrome
- Sinus node dysfunction
- Slow heart rate - sick sinus
- Tachy-brady syndrome
- Sinus pause - sick sinus
- Sinus arrest - sick sinus



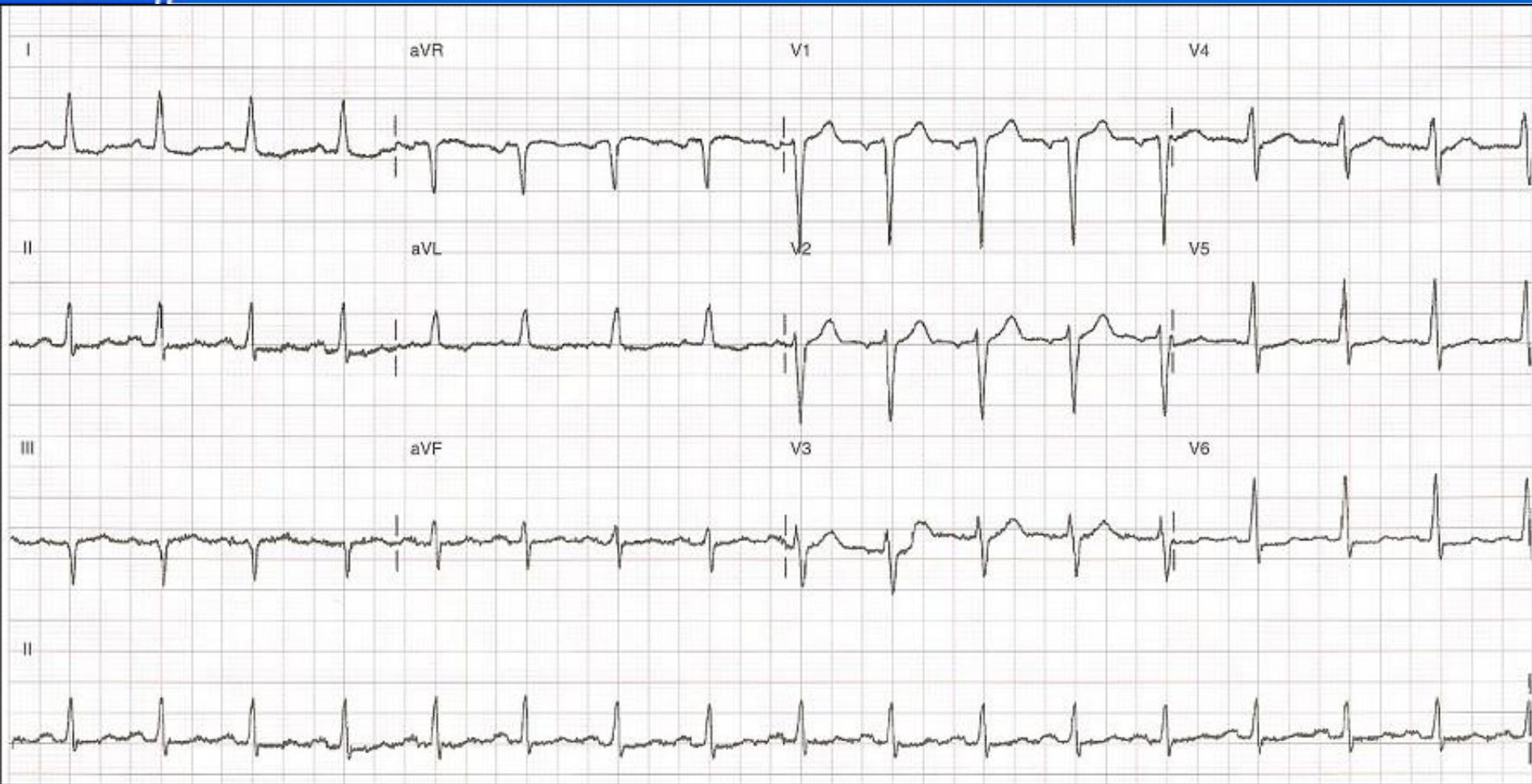
# Etiology

- Most often occurs in people older than age 50 due to scar-like damage to electrical pathways in the heart muscle tissue.
- In children, heart surgery on the upper chambers is a common cause of sick sinus syndrome.
- Coronary heart disease, high blood pressure, and aortic and mitral valve diseases may occur with sick sinus syndrome. However, these diseases may have nothing to do with the syndrome.
- Tachycardias that start in the atria may be part of the syndrome. These include atrial fibrillation, atrial flutter, atrial tachycardia. A period of fast heart rates is often followed by very slow heart rates.
- Some medicines can make abnormal heart rhythms worse, especially when doses are high. These include digitalis, calcium channel blockers, beta-blockers, and antiarrhythmics.
  - The patient's digoxin level was 7ng per ml (normal 0.8 ng per mL to 2 ng per mL)

# Middle Aged Male with Chest Pain

A 63-year-old man complained of pain in his substernal and epigastric region for the past three weeks. The pain occurred after walking a great distance or after he ate, and it resolved with rest. He experienced no radiation of the pain, and no shortness of breath, nausea, or diaphoresis. The patient reported no cardiac history or family history of coronary artery disease. His medical history was notable for type 2 diabetes mellitus for which he took metformin. Other medications included an antacid and omeprazole. He stopped smoking 10 years ago, but he did have a 20 pack-year history. He was pain-free at the time of the interview. Physical examination was unremarkable. An electrocardiogram was obtained

# His EKG - What Do You See?





# Left Bundle Branch Block

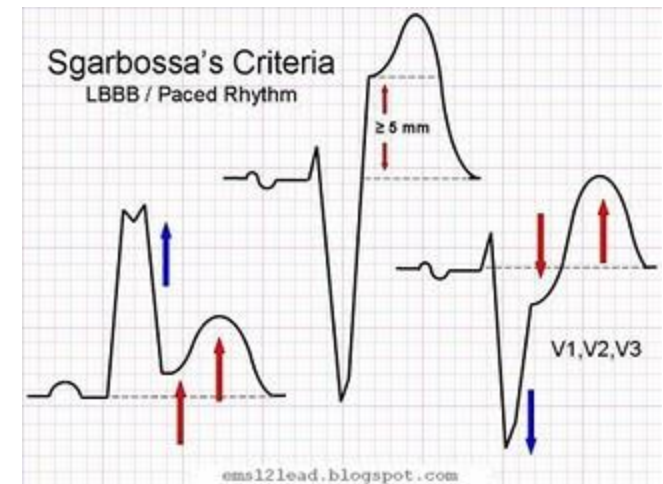
- left bundle branch block (LBBB) usually indicates widespread cardiac disease.
- In (LBBB), the QRS usually has the same general shape as the normal QRS, but is much wider and may be notched or deformed. Voltage (height of the QRS complex) may be higher.
- Look for wide (possibly notched) R waves in I, L, or V5-V6, or deep broad S waves in V1-V3. There is left axis deviation. “Septal Q waves” sometimes seen in I, L, and V5-V6 disappear in LBBB.
- T waves in LBBB are usually oriented opposite the largest QRS deflection. That is, where large R waves are seen, T waves will be inverted. ST segment depression may occur.

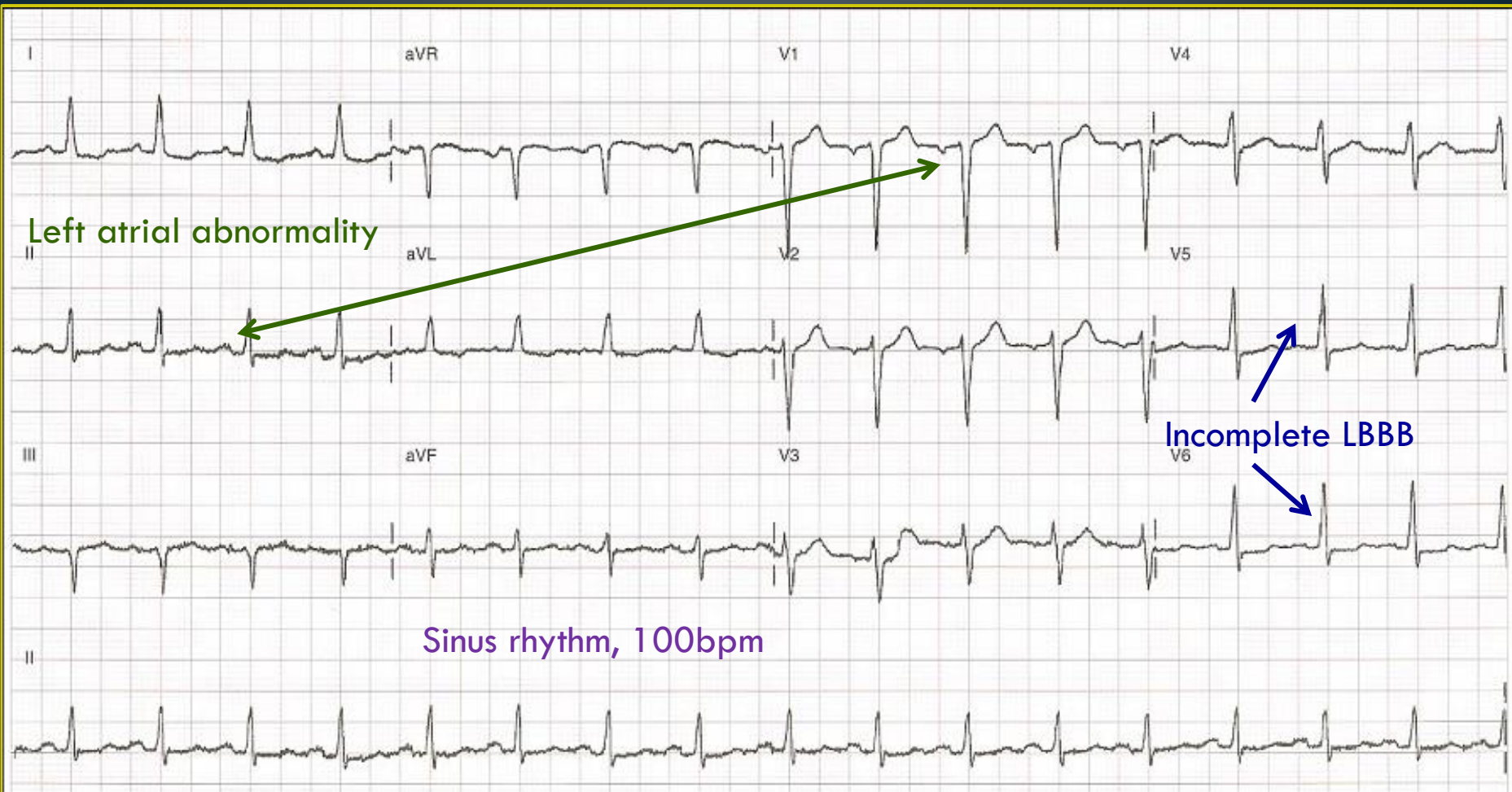
# Diagnosis of Infarction with BBB

- The baseline ST segments and T waves tend to be shifted in a discordant direction with LBBB, which can mask or mimic acute myocardial infarction.
- This is difficult, but not necessarily impossible. Look for ST-T wave changes or new Q waves in left-sided leads (I, aVL, V6) with LBBB.
- **New onset of LBBB is typically representative of an MI** which must be R/O.
- Evidence of infarction (Q waves, ST-T changes) is easier to see with RBBB.

# Sgarbossa Criteria- To Diagnose AMI in LBBB

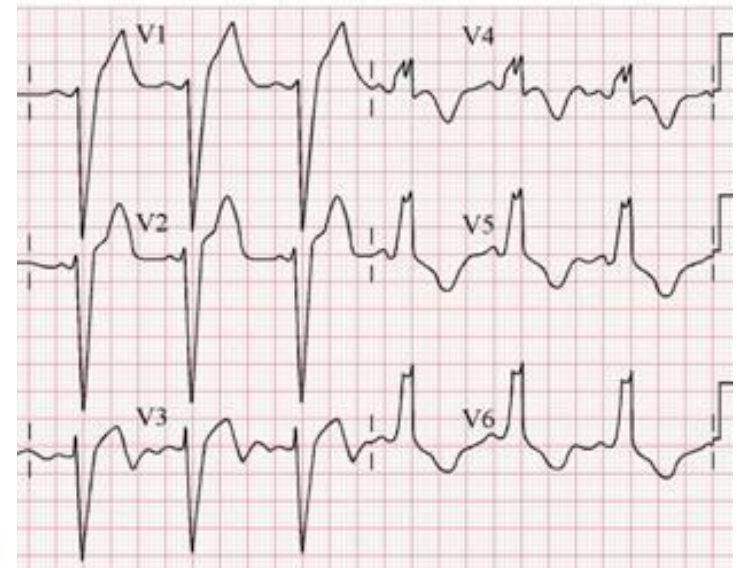
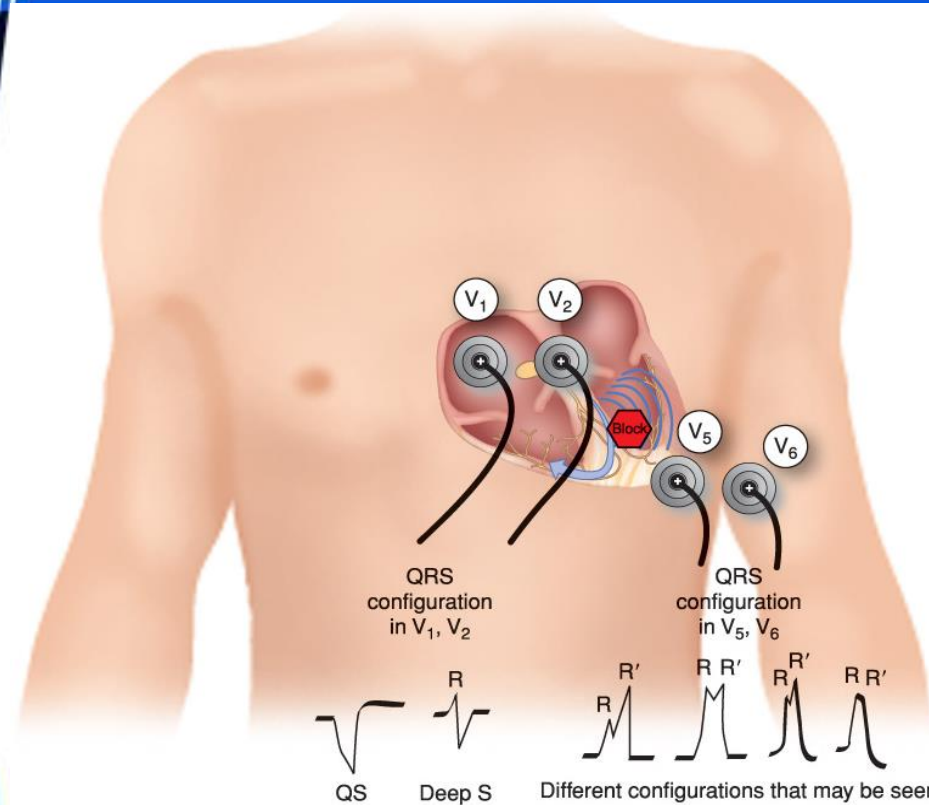
- 5 points for concordant 1 mm ST elevation. (any lead)
- 3 points for concordant 1 mm ST depression in v1 to v3
- 2 points for discordant 5 mm ST elevation. (any lead)
- Score of 3 predicts AMI.





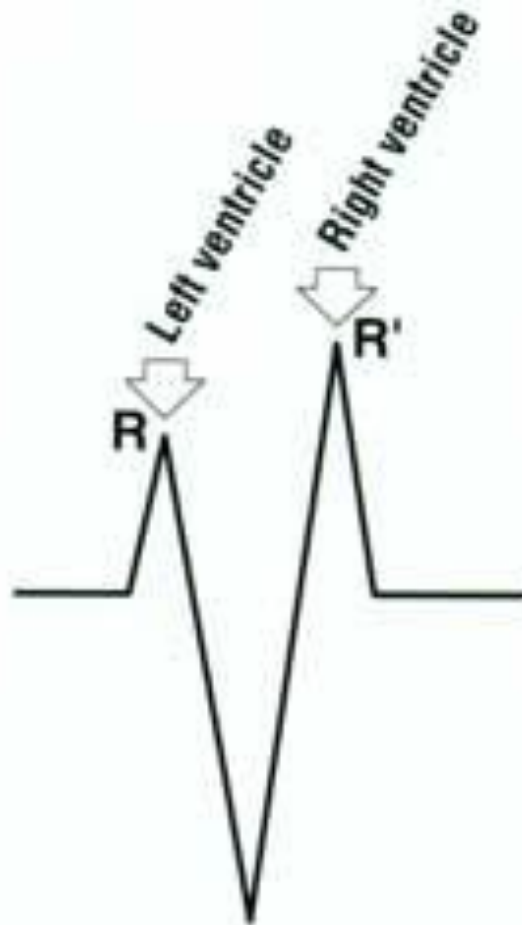
This pt was determined to have mitral regurgitation and a significantly enlarged left ventricle at echocardiography with a lateral wall MI

# Left Bundle Branch Block

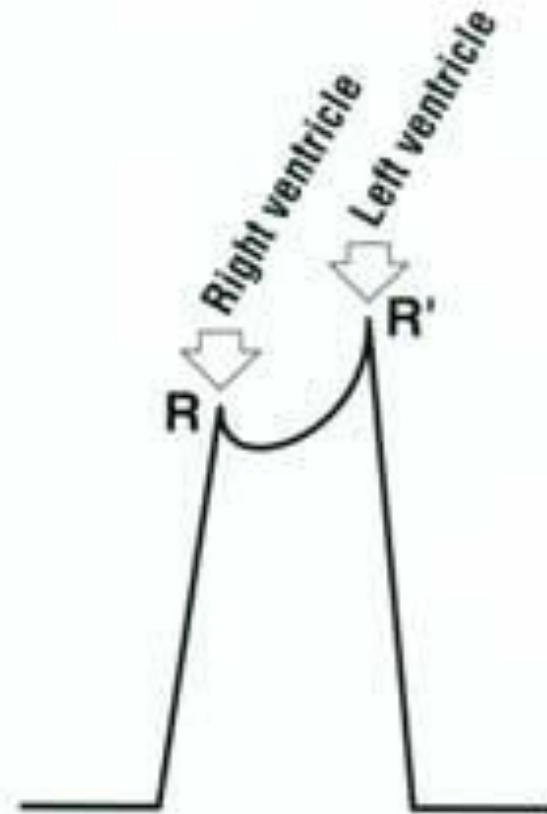


Look for RR' in leads V<sub>5</sub> or V<sub>6</sub>

# Appearance Differences – Right vs. Left



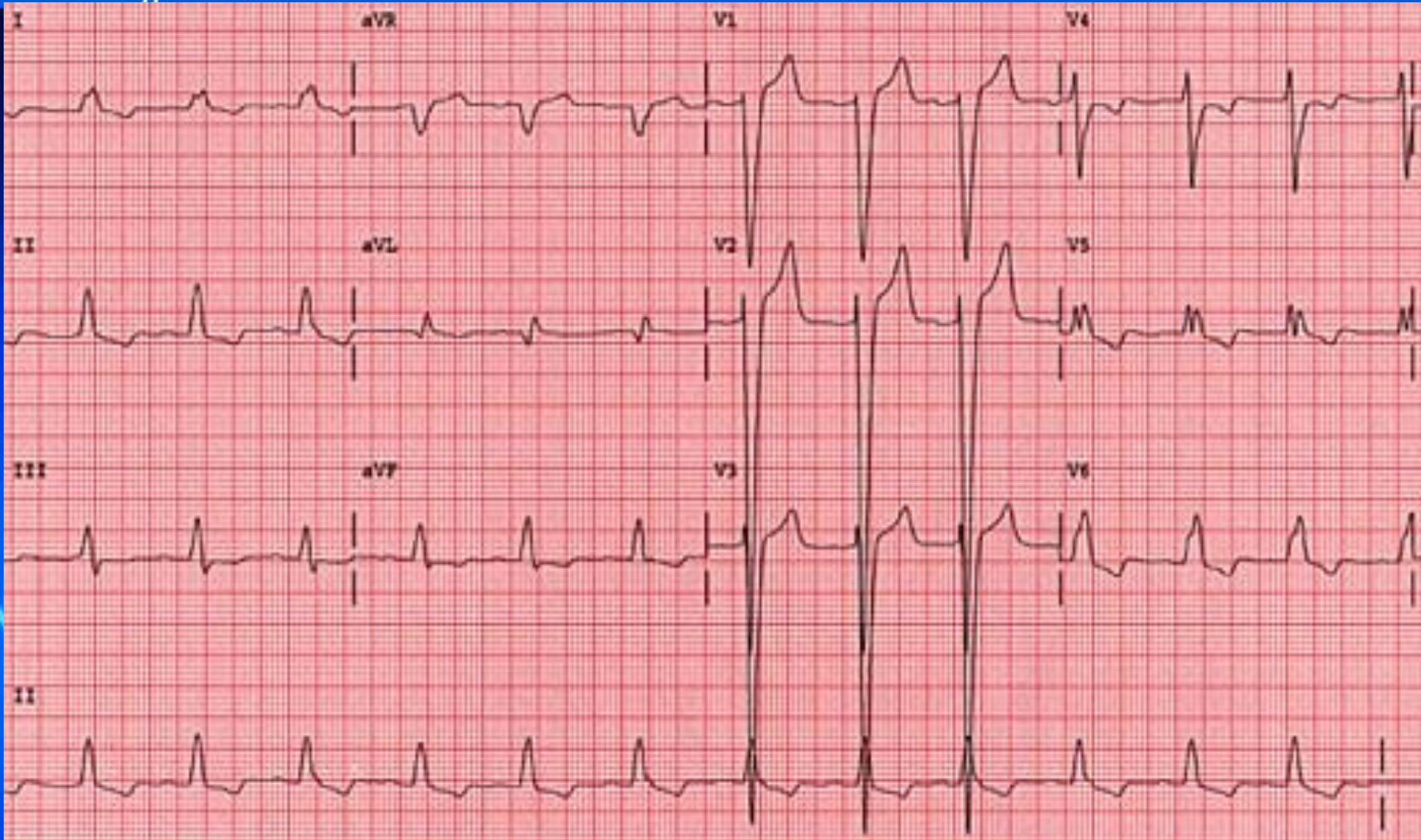
**Right BBB**



**Left BBB**

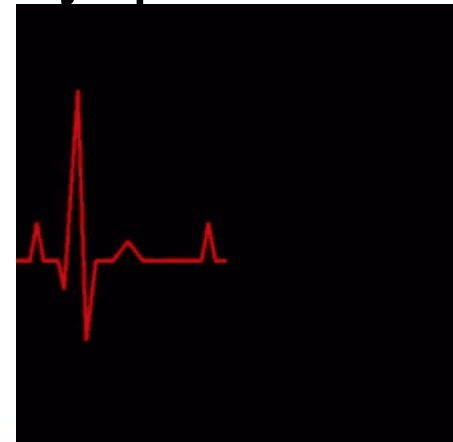**R and R' in Right and Left BBB often look like above**

# LBBB



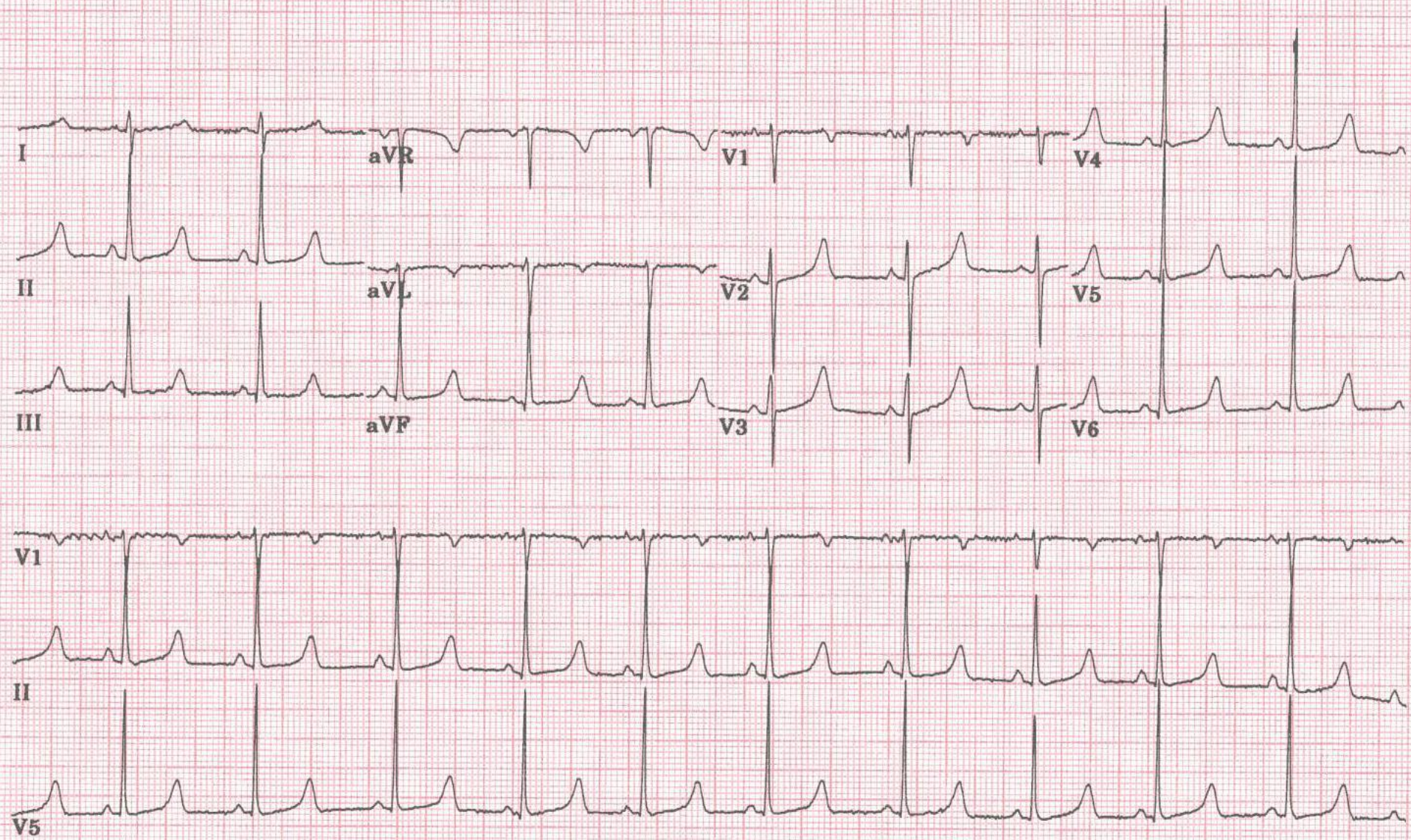
# Nursing Home Resident with AMS

A 64-year-old male with multiple medical problems including heart disease is brought into the ED from the nursing home as a medical precaution. The floor nurse in the nursing home reports that he had a change in mental status today. On exam, the patient is minimally responsive. He appears moderately dyspneic. An EKG is taken. What is wrong?






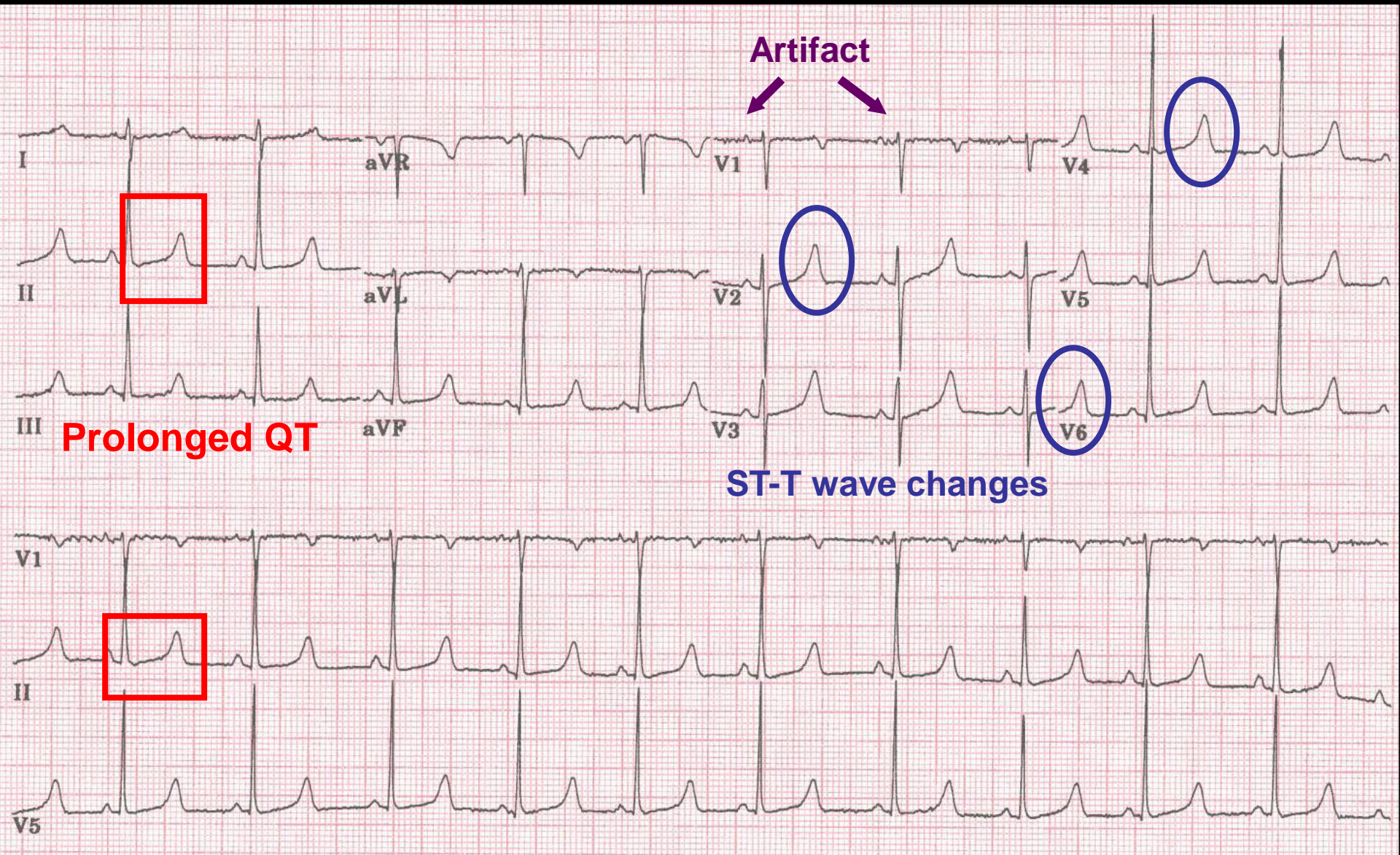
# His EKG - What Do You See?



# Interpretation

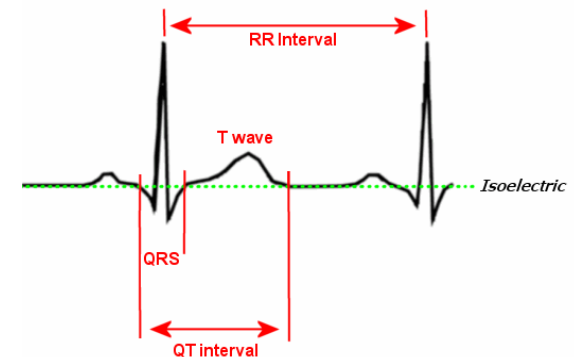


- This EKG demonstrates sinus rhythm at a rate of 65.
- Several abnormalities:
  - Artifact in V1
  - ST-T wave suggesting electrolyte disturbance
  - Prolonged QT interval (0.52 seconds)\*\*\*\*\*
- DX: Hypocalcemia. This pt's serum calcium level was 5.9mg/dl (N=8.5 to 10.2 mg/dL)

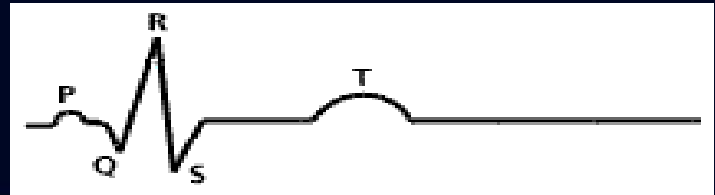


# LQTS :Facts

- Abnormalities of ion channels that result in long QT intervals (prolongation of phase III-time for repolarization) and predispose to polymorphous ventricular tachycardia (“Torsade de Pointe”)
- Common cause of sudden death in children and young adults
- 1:7000 births
- In the US it causes ~ 5% of the SCD/year
- Symptoms include syncope or SCD usually with physical activity or emotional stress



# LQTS:Facts



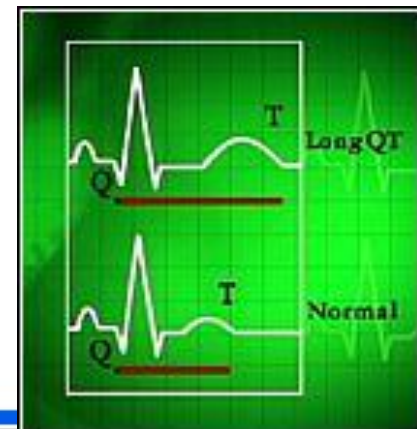
- Syncope often misdiagnosed as vasovagal or epilepsy
- Family history is important; ask about deafness and SCD <30 years of age
- Men have shorter QT intervals (0.39 sec) vs. women (0.41 sec)
- 1/3 of patients with LQTS are asymptomatic
- 10% of patients will have an intermittent normal QT interval
- Rule out drug induced LQT and other causes of SCD in young patients(HCM, Brugada, ARVD)
- Treatment is BB +/- ICD
- Competitive sports should be avoided

# Four Major causes of Prolonged QT Interval

- **Electrolyte abnormalities:**
  - Hypocalcemia
  - Hypokalemia
- **Drugs: (associated with torsades de pointes)**
  - Class Ia antiarrhythmic agents, amiodarone, phenothiazine's, Tricyclic antidepressants, sotalol
- **Congenital or idiopathic prolonged QT syndromes**
  - **Romano-Ward syndrome:** autosomal dominant inherited cardiac disorder characterized by abnormalities affecting the electrical system of the heart.
  - **Sporadic long QT syndrome:** disorder of cardiac repolarization caused by alterations in the transmembrane potassium and sodium currents.

# Four Major causes of Prolonged QT Interval

- **Miscellaneous group, including patients with:**
  - Third-degree and sometimes second-degree AV block
  - At the cessation of ventricular pacing
  - Left ventricular hypertrophy (usually minor degrees of lengthening)
  - Myocardial infarction (in the evolutionary stages where there are marked repolarization abnormalities)
  - Significant active myocardial ischemia
  - Cerebrovascular accident (subarachnoid hemorrhage)
  - Hypothermia



Which of the following is **NOT** a common cause of prolonged (or Long) QT Interval?

1. **Sarcoidosis**
2. Hypocalcemia
3. Amiodarone
4. Hypothermia

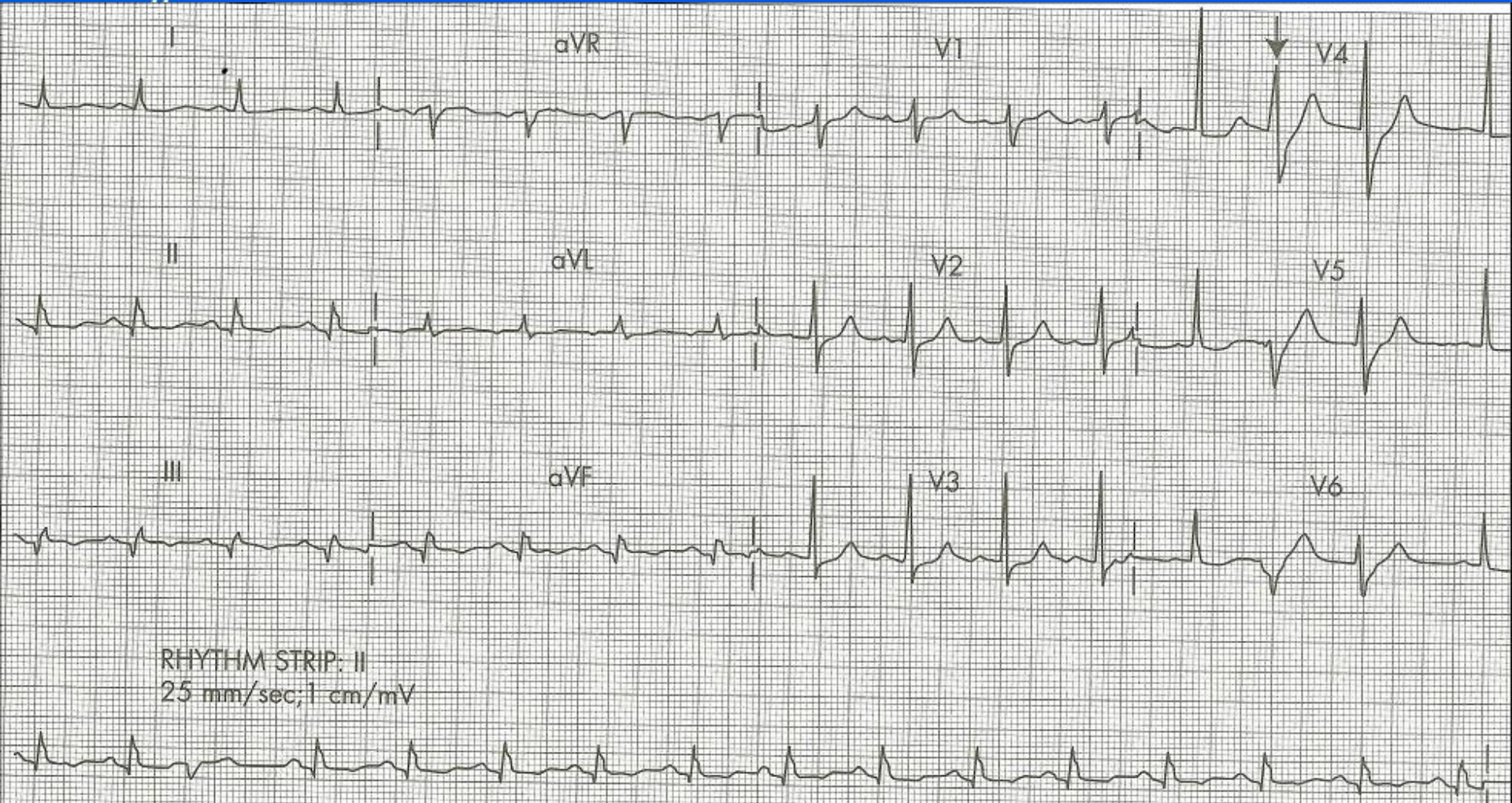


# Not Always What You Think

A 72 y/o woman is brought to the ER by a neighbor with intermittent chest pain for three days, which became severe and continuous for what was perceived as four hours before presentation. This was associated with diaphoresis. She did not want to go to the ER thinking that she was bothering her family and she did not call her family prior to reporting. The neighbor was in her back yard and flagged by the patient. She did not speak English very well. Her blood pressure was 148/74 mmHg, pulse rate was 94/min, respiratory rate 28-30 breaths per minute, and oxygen saturation 83% on room air. The rest of the examination was delayed secondary to the patient's English and ability to verbalize her symptoms. An ECG is immediately performed. What is the diagnosis?

The patient was given SL nitro and her Bp dropped to 70/30 (hint).

# Her EKG - What Do You See?

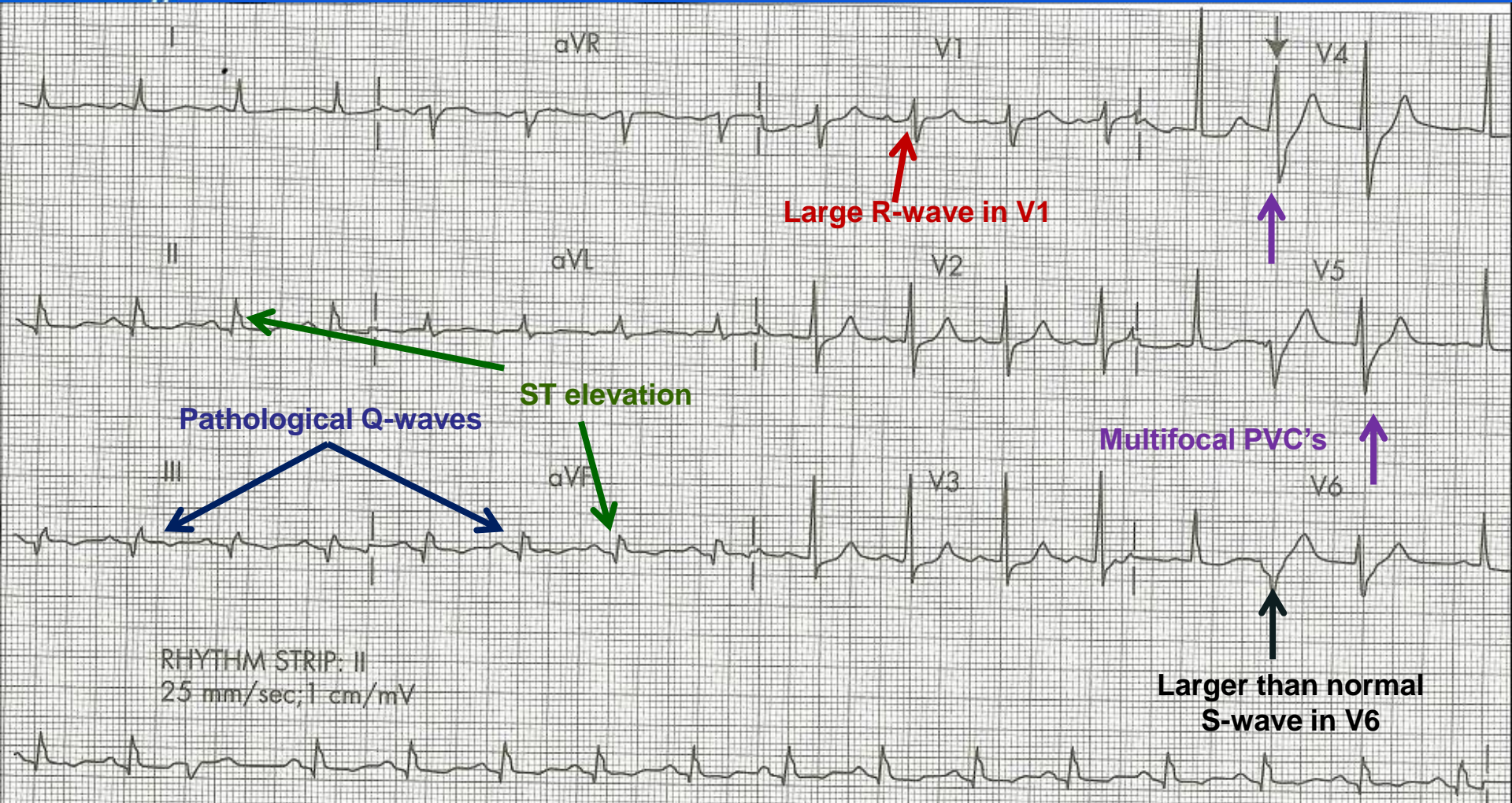


# Inferior/posterior Wall MI

The dx was delayed/worsened due to her lack of English.

Her EKG reveals the following:

- Pathological Q-waves are noted in inferior leads.
- Mild ST elevation inferiorly (II & Avf)
- R-wave is equal to the S in V1, indicating either borderline RVH or a true posterior MI.
  - The axis is normal thus no RVH
- Beats 2 & 3 in V4-6 are early and wide, thus ventricular in origin representing coupled multifocal pvc's.



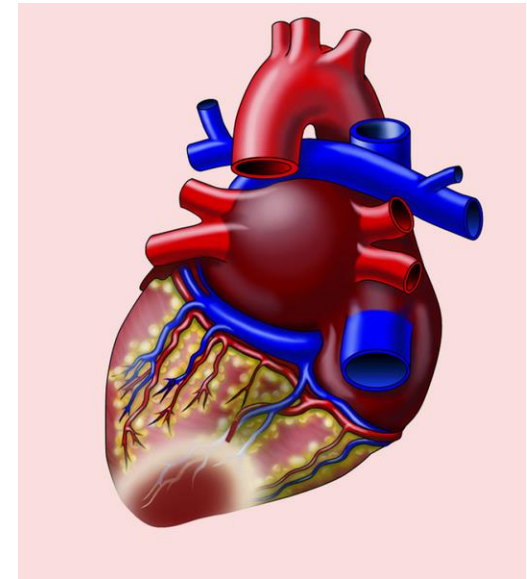
The ST elevation inferiorly was deemed to be insignificant

# Posterior Wall Infarctions

- Occur when posterior myocardial tissue, usually supplied by the posterior descending artery (a branch of the right coronary artery in 80% of people), infarcts secondary to thrombosis. This frequently occurs along with an inferior wall MI.
- PWMI can be differentiated from anterior wall ischemia by the presence of ST segment elevations in the inferior (II, III, aVF) and posterior leads V7 to V9.
- Relatively tall R waves may also appear in leads V1-V3, corresponding to the appearance of pathologic Q waves (loss of depolarization forces) in the posterior leads.

# Posterior Wall MI (PWMI)

- Usually an extension of an inferior or lateral MI
- Common with proximal RCA occlusions
- Occurs with LCX occlusions
- Look for PWMI when
  - V1 -V4 show ST depression
  - The ECG is normal
  - The story is convincing



# Posterior Wall MI's

- Treatment
  - Restoration of the balance between the oxygen supply and demand to prevent further ischemia
  - Pain relief
  - Prevention and treatment of any complications that may arise
  - Fluid resuscitation
  - Avoid drugs that decrease preload
    - Esp if you suspect concomitant RV wall infarction
  - Call cardiology ASAP

Posterior wall MI's rarely occur alone, they are usually an extension of a lateral or.....

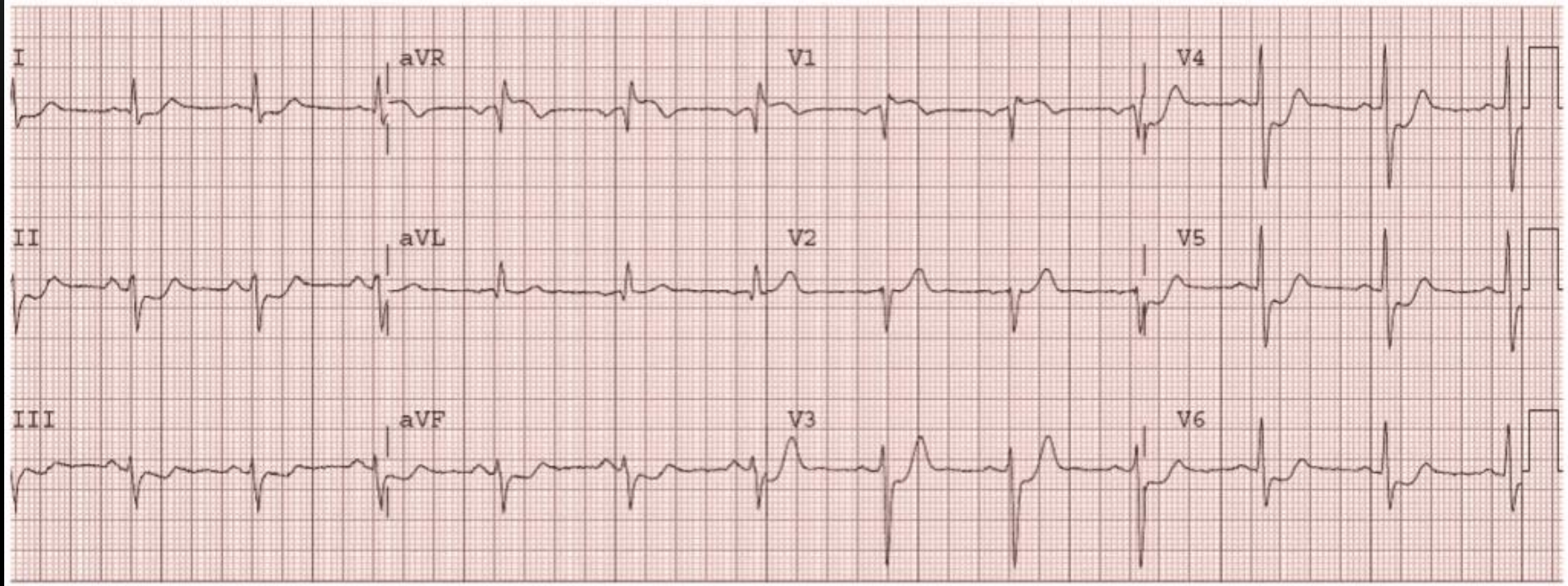
1. Anterior wall MI
2. Inferior wall MI
3. Basal ganglia stroke
4. Hypertensive emergency



# Would Have Never Guessed

- A 59-year-old man with a history of hypertension, smoking 1 ppd for 40 years, and body mass index (BMI) of 43 developed severe persistent central chest pain at rest that started this AM. His temperature is 100.0, blood pressure is 140/90 mm Hg, respirations are 22 per minute, heart rate is 70 beats per minute and O<sub>2</sub> Sat is 92% on room air. His EKG from EMS while in route is presented to you upon arrival. What do you do?

# His EKG - What Do You See?




# Left Main STEMI

- Lead aVR has often been called the “forgotten lead”, but it is worth paying attention to because ST-segment elevation in aVR portends a worse prognosis in ACS.
- ST elevation in aVR  $\geq 1$ mm is the strongest independent predictor of either severe LMCA or triple-vessel disease requiring CABG in patients with NSTEMI.
- Elevation in aVR of  $\geq 0.5$  mm is an independent predictor of mortality in patients with STEMI.

# Left Main Coronary Artery Disease

- Early identification of LMCA disease is critical because acute occlusion can cause rapid hemodynamic and electrical deterioration.
- LMCA insufficiency due to critical stenosis of the left main artery is important to recognize because these patients can progress to complete occlusion and are likely to require surgical intervention (such as CABG).

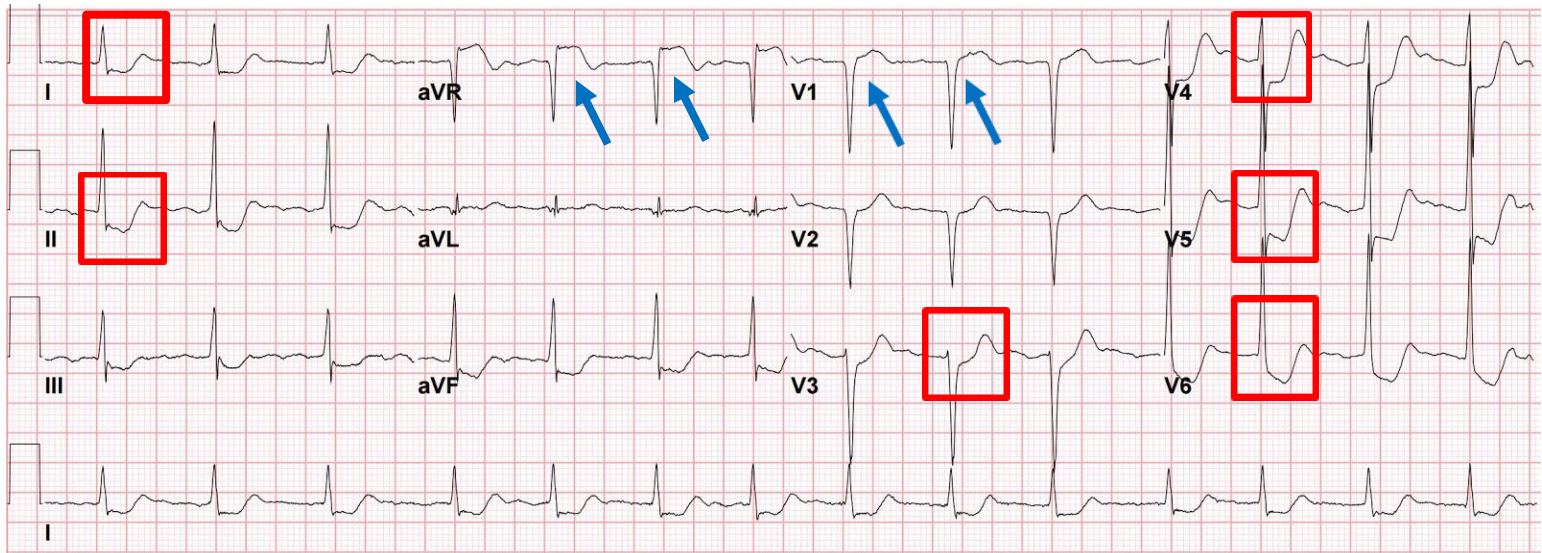


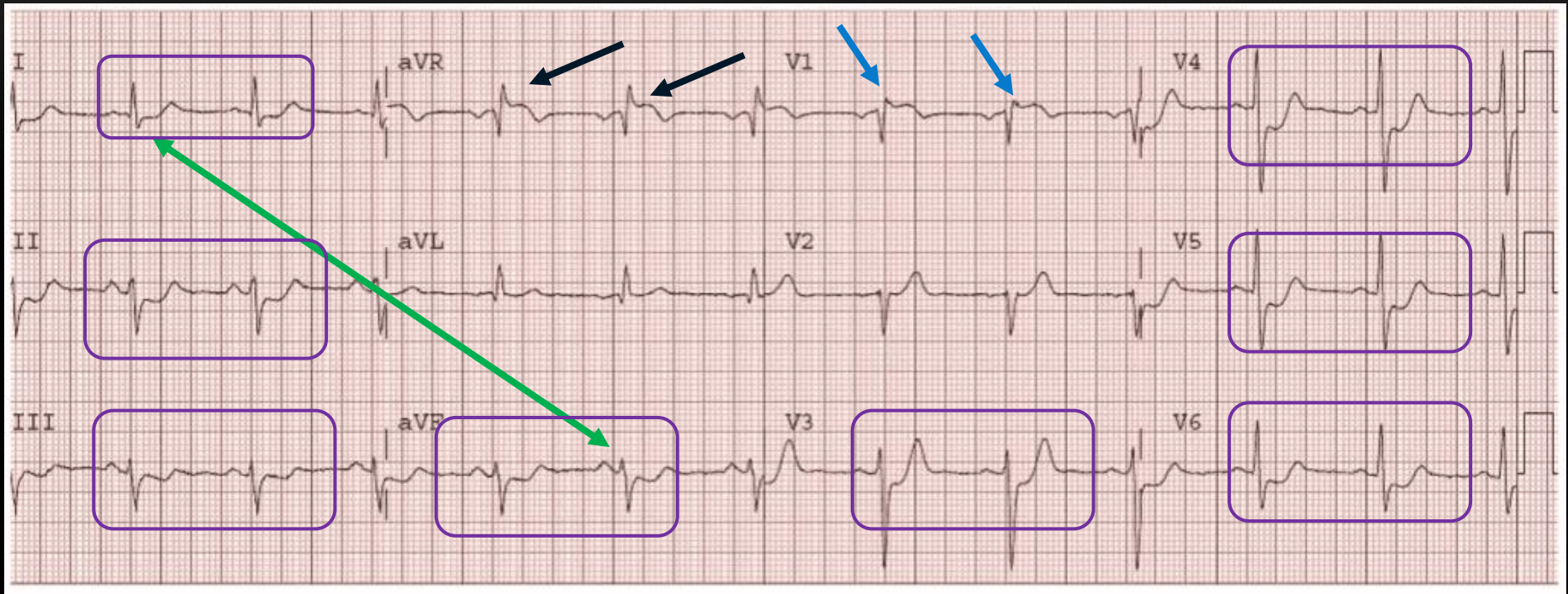
# How it Occurs

- ST-elevation in aVR occurs by the following mechanisms:
  - Critical narrowing of the LMCA causing subendocardial ischemia due to insufficient blood flow.
  - Transmural infarction of the basal septum due to a very proximal LAD occlusion or complete LMCA occlusion.
  - Severe multi-vessel coronary artery disease. \*\*
  - Diffuse subendocardial ischemia from oxygen supply/demand mismatch.

# Classic Findings on EKG

- ST depression in leads I, II, aVL and V4-6
- ST elevation in aVR  $\geq 1$ mm
- ST elevation in aVR  $\geq$  V1





# A Few Tips on Left Main Presentation

- STE  $\geq 1$  mm in aVR or V1 with STD  $\geq 1$  mm in  $\geq 6$  leads can suggest left main coronary artery insufficiency, proximal LAD insufficiency, or triple vessel disease, especially if accompanied by pathologic Q-waves, hemodynamic compromise, and/or refractory symptoms.
- STD are most prominent in the inferior and lateral leads and thought to represent subendocardial ischemia.
- This EKG pattern is not specific to LMCA/proximal LAD insufficiency and can be seen in other conditions (eg, pulmonary embolism, aortic dissection, LVH with strain pattern).



# Take Home Pointers

1. Use a Systematic Approach
  - a. Approach your analysis to the 12 lead EKG the same way every time.
2. Identify Lethal Rhythms first (Find all STEMI's)
3. Cover up the computer interpretation
4. Determine if the rhythm regular or irregular
5. Don't take forever trying to read the EKG
6. Look at every EKG you can to get more comfortable reading them

# References

- <https://litfl.com/ecg-library/ecg-references/>
- <https://www.uptodate.com/contents/ecg-tutorial-basic-principles-of-ecg-analysis>
- <https://www.healio.com/cardiology/learn-the-heart/ecg-review/ecg-interpretation-tutorial/stemi-mi-ecg-pattern>

Questions?

