

Wellens syndrome: An important consideration in patients with chest pain

Joshua Alexander, PA-C; Denise Rizzolo, PhD, PA-C

ABSTRACT

Coronary artery disease (CAD) is the number one cause of death in the United States, and it is estimated that every 40 seconds one person experiences a heart attack. Among patients with chronic CAD, many will experience a potentially fatal complication known as acute coronary syndrome (ACS). Wellens syndrome is a rare form of ACS that indicates critical left anterior descending coronary artery occlusion and can be identified by its characteristic T-wave patterns on ECG. This syndrome also may go unrecognized by clinicians because of a lack of familiarity with the ECG findings. This article describes the Wellens ECG pattern and its significance in patients with chest pain.

Keywords: Wellens syndrome, T-wave inversion, chest pain, acute coronary syndrome, cardiac ischemia, electrocardiography

Learning objectives

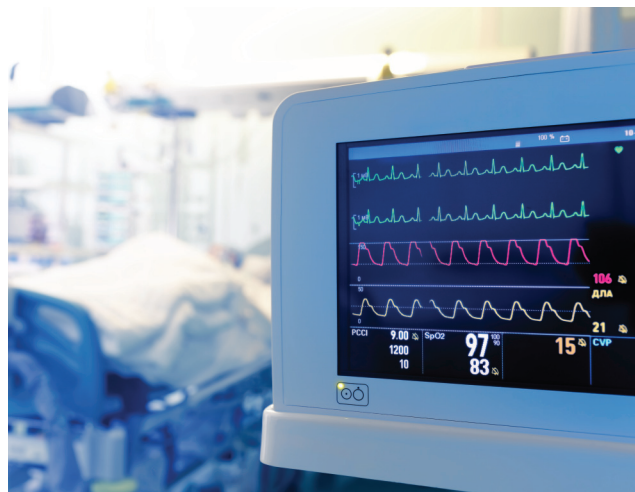- Discuss the incidence and prevalence of Wellens syndrome.
- Review the signs and symptoms of Wellens syndrome and what differentiates this syndrome from other ischemic events.
- Compare and contrast the ECG findings of Wellens syndrome with those of other coronary syndromes.
- Describe treatment strategies for Wellens syndrome.

Wellens syndrome was initially observed in a subset of patients hospitalized with acute coronary syndrome (ACS) in the Netherlands.¹ Patients with this condition often have subtle ECG abnormalities signifying critical disease of the left anterior descending (LAD) coronary artery.¹⁻³ The syndrome can easily be missed because clinicians may not be familiar

Joshua Alexander practices in internal medicine and emergency medicine at Northwell Health-Long Island Jewish Medical Center in New Hyde Park, N.Y. **Denise Rizzolo** is practicum coordinator for the master's of public health program at Fairleigh Dickinson University of New Jersey. The authors have disclosed no potential conflicts of interest, financial or otherwise.

DOI:10.1097/01.JAA.0000911188.18646.31

Copyright © 2023 American Academy of PAs



© SFAM_PHOTO/SHUTTERSTOCK.COM

with its ECG pattern. Although many patients experience pain relief with antianginal medications, they remain at high risk for developing an anterior wall myocardial infarction (MI), so prompt recognition, hospital admission, and early consultation with an interventional cardiologist for coronary intervention are imperative.^{1,2,4}

CAUSES

Blood flow to the myocardium is supplied by the left and right coronary arteries. The left main coronary artery divides into the left circumflex and the LAD arteries, the latter of which branches into the septal perforator and diagonal arteries.^{5,6} The LAD is the largest coronary artery, with a length between 10 and 13 cm.^{6,7} It perfuses both ventricles, most of the anterior interventricular septum, the bundle of His, left and right bundle branches, and Purkinje fibers.⁵⁻⁸

The LAD is divided into three parts.⁹ The proximal segment starts at the origin of the LAD and ends distal to the first septal perforator branch. The middle segment extends from the end of the proximal segment to the second diagonal branch. The distal portion follows the middle segment and terminates past the cardiac apex.⁹ Because of the large area of tissue supplied by the LAD, a proximal occlusion in this vessel can jeopardize a significant portion of myocardium, as is the case in patients with Wellens syndrome.

Key points

- Wellens syndrome is a rare form of ACS that indicates critical LAD coronary artery occlusion.
- Patients may have a normal ECG during chest pain, with the Wellens pattern appearing only in a pain-free period. Cardiac biomarkers may be normal or minimally elevated.
- Avoid stress testing, which can induce MI and death.
- T waves may become upright (pseudo-normalization) if pain returns after the initial episode.
- Prompt recognition and early cardiac catheterization is key to preventing progression to an anterior wall MI.

A critical occlusion of the proximal LAD is the hallmark of Wellens syndrome, although the culprit lesion also may involve the vessel's midsegment.^{1,2,10,11} In the initial study by de Zwaan and colleagues, all but one patient with Wellens patterns on ECG who underwent coronary angiogram had greater than 90% stenosis in the LAD.¹ In a follow-up study performed 6 years later by the same investigators, all patients had at least 50% stenosis in the LAD, with an average of 85% stenosis among study participants.² If a total LAD occlusion is present, anterior wall MI occurs.^{1-4,12}

PATHOPHYSIOLOGY

The most common trigger for ACS in a patient with underlying coronary artery disease (CAD) is rupture of an unstable intraluminal coronary plaque.^{13,14} Similarly, vessel occlusion by a ruptured coronary plaque causes most cases of Wellens syndrome. When a plaque ruptures, it exposes its highly thrombogenic lipid core to the vessel lumen, triggering an inflammatory cascade that leads to platelet aggregation, thrombus formation, occlusion, ischemia, and potential infarct.¹³

Patients with coronary ischemia typically experience angina. If the occluding thrombus lyses, restoring perfusion through the affected vessel, the pain subsides. However, if the vessel remains occluded and perfusion is not restored, MI occurs. Cardiac ischemia is represented on ECG in the form of ST-segment or T-wave deviations.

In a patient with Wellens syndrome, the onset of angina coincides with sudden occlusion of the LAD artery. This occlusion may be transient and the pain subsides if perfusion through the vessel is restored. The 12-lead ECG may appear normal while the patient has pain, and classic Wellens ECG patterns may only manifest once the patient is pain-free.^{1,15} The exact mechanism behind the ECG changes in Wellens syndrome is unknown and more research is needed in this area. Some studies suggest myocardial stunning and reperfusion injury as the primary cause, while others suggest myocardial edema.¹⁶⁻¹⁸

RISK FACTORS

No risk factors are specific for developing disease of the LAD itself, but patients with a history of underlying CAD in general are at higher risk for Wellens syndrome. Similarly, older age and a past medical history of hypertension, hyperlipidemia, diabetes, chronic kidney disease, or obesity convey greater risk.¹⁹ A family history of CAD and/or personal history of previous MI are contributing factors. Lifestyle factors including cigarette smoking, physical inactivity, unhealthful diet, and heavy alcohol use also increase the risk of developing coronary disease.¹⁹

EPIDEMIOLOGY

When it was first described in the literature, Wellens syndrome was found in 14% to 18% of patients admitted to hospitals with ACS.^{1,2} Newer studies with larger sample sizes suggest that the incidence may be lower.^{10,11} Typically, ACS tends to be more common in men.²⁰ De Zwaan and colleagues found a higher incidence of Wellens syndrome among men in their predominantly Dutch male study demographic, but other studies suggest that it may present more frequently in women.^{1,2,11} No difference has been found in the occurrence of Wellens syndrome among ethnicities.¹⁰

CLINICAL PRESENTATION

No clinical symptom is specific to Wellens syndrome. Patients with acute coronary occlusion may present with several different symptoms, most often angina, or chest pain or pressure. Retrosternal chest pressure that occurs with exertion and is relieved with rest is regarded as the classic presentation of ACS.¹⁹ Radiation of pain to the jaw, neck, or either arm is common, and may be accompanied by nausea, vomiting, or diaphoresis. Atypical symptoms include shortness of breath; pleuritic chest pain; epigastric pain; indigestion; fatigue; isolated pain of the jaw, neck, or arm; and syncope. Special populations including women, patients with diabetes, and older adults are more likely to present with atypical manifestations of ACS, so maintain a low threshold to obtain a 12-lead ECG if indicated in these groups. Some patients may delay seeking medical care and may present without active pain on arrival.

Physical examination findings are variable in ACS and are nonspecific to Wellens syndrome. Patients with significant ischemia or infarction may exhibit signs of hemodynamic instability and shock.⁹ Abnormalities in vital signs can include hypotension, tachycardia or bradycardia, and hypoxia.²¹ Patients may develop dysrhythmias.²² Physical examination findings may include basilar crackles, diaphoresis, and cool clammy extremities.²¹ Patients also may develop heart failure due to ventricular dysfunction.^{1,2,19} Chest auscultation may reveal a new S₄ gallop, paradoxical splitting of the S₂ sound, or new mitral regurgitation.¹⁹ Conversely, the physical examination can appear unremarkable.

DIAGNOSTIC WORKUP

The diagnostic workup of angina should include a 12-lead ECG, laboratory tests including serum cardiac enzyme levels, and chest imaging. Obtain a 12-lead ECG and vital signs immediately upon patient presentation or complaint of pain. A focused history and physical examination help guide the workup, assess risk factors, and rule out differential diagnoses. During the patient interview, assess for the presence of underlying ACS risk factors and use of illicit substances, especially cocaine.

Electrocardiography All patients being evaluated for ACS should have a baseline 12-lead ECG, which should be repeated every 4 to 6 hours, with the next troponin level, or when the pain subsides. Wellens syndrome presents with two classic ECG patterns: type A presents as biphasic T waves in leads V_2 and V_3 and type B presents as deep T-wave inversions in leads V_2 and V_3 (Figure 1). Although cardiac ischemia in other vessels can also present with inverted T waves, in Wellens syndrome the amplitude of

the inversion usually is more negative. The type B pattern is more common than type A and may occur more frequently in women.^{1,2,10} Although these patterns are most frequently seen in leads V_2 and V_3 , they can manifest in any precordial lead (V_1 through V_6). ECG criteria for the diagnosis of Wellens syndrome are listed in Table 1 and exclude the presence of pathologic Q waves, left or right bundle branch blocks, left or right ventricular hypertrophy, or poor R-wave progression. ST segments usually are isoelectric but may have slight elevation; ST-segment depression is not commonly seen.^{1,2,11}

The Wellens ECG patterns have a high specificity for the presence of LAD occlusion. The type A and type B patterns have a specificity of 99% and 97% respectively, and the presence of either ECG pattern in leads V_2 and V_3 has a 96% specificity for an LAD lesion.¹¹ In the type B pattern, specificity increases proportionately with the depth of T-wave inversion, but the overall sensitivity of each pattern for LAD occlusion is lower.¹¹ Likewise, the positive and

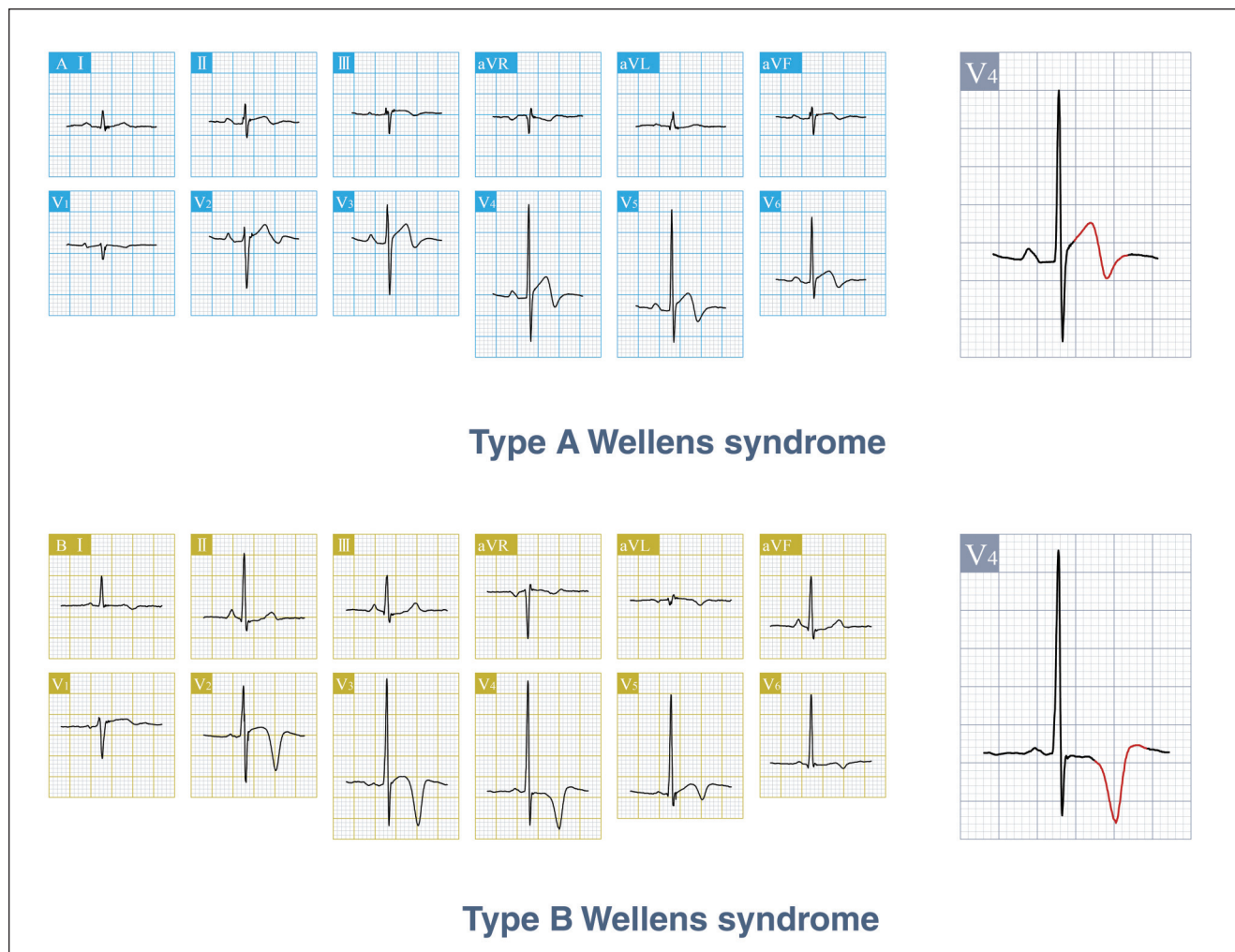


FIGURE 1. Wellens pattern types, showing the positive and negative biphasic T wave in type A, and inverted T wave in type B

negative predictive values of each pattern for LAD occlusion are also low, so clinicians should apply their best judgment when evaluating patients.

Although most clinicians can detect overt ECG signs of ischemia when present, a false sense of security can set in when the initial ECG appears normal. The caveat in Wellens syndrome is that many patients have a normal-appearing ECG during chest pain and only exhibit the characteristic ECG patterns when they are pain-free.^{1,12,15} If the pain returns, pseudo-normalization of the ECG can occur as precordial T-wave morphology changes from inverted to upright.² Additionally, ECG findings in patients with Wellens syndrome often are dynamic, and a type A pattern can evolve into type B (Figure 2) or progress to ST-segment elevation myocardial infarct (STEMI).^{1,3,4,12,23} Trending the ECG at frequent intervals, especially after pain resolution, is crucial to detecting this syndrome.

Serum biomarkers Troponin, the most sensitive and specific biomarker for cardiac injury, rises in the first few hours following infarct and can remain detectable for days to weeks.¹⁹ As with ECGs, measure troponin levels in all patients at the onset of symptoms and trended at serial intervals.¹⁹ Troponin levels reflect myocardial damage but are normal or minimally elevated in patients with Wellens syndrome.^{1,2,12,24} Clinicians should not be misled even if troponin levels are normal.

Additional laboratory work should include a complete blood cell count, comprehensive metabolic panel, brain natriuretic peptide level, and coagulation panel. If pulmonary embolus is suspected, obtain a D-dimer level. In women of childbearing age, a pregnancy test may be required before radiologic studies.

Imaging Echocardiography is a useful tool to evaluate cardiac structure and function. Decreased left ventricular (LV) systolic function is common in patients with Wellens syndrome.^{1,2,11} LV systolic wall motion abnormalities involving the anteroseptal, apical, and anterolateral walls can occur and may be reversible.¹² CT coronary angiography is a noninvasive method that can be performed to detect the presence of coronary artery occlusions based on patient risk assessment.¹⁹ Avoid cardiac stress testing in patients with a Wellens ECG pattern because this can precipitate MI, dysrhythmia, and death.^{3,12}

Further radiologic studies should be guided by the patient's history and physical examination findings. Chest radiography can be performed to rule out pneumonia, pneumothorax, or pleural effusion. CT angiography of the pulmonary arteries or aorta can be obtained if pulmonary embolism or aortic dissection is suspected.

DIFFERENTIAL DIAGNOSES

The list of differentials in a patient with chest pain is broad and can include nonischemic cardiac conditions, and respiratory, gastroenterologic, musculoskeletal and psychiatric conditions.¹⁹ Similarly, inverted T waves on ECG

TABLE 1. ECG criteria for Wellens syndrome^{2,3,12}

Inclusion criteria

- Biphasic T waves in leads V₂ and V₃ in type A pattern (15% to 25%)
- Deep, symmetric T-wave inversions (greater than 1 mm) in leads V₂ and V₃ in type B pattern (75% to 85%)
- Isoelectric or minimally elevated (less than 1 mm) ST-segment elevation
- ST-segment depression (uncommon)

Note: Patterns are more common in leads V₂ and V₃ but can include any precordial lead from V₁ to V₆.

Exclusion criteria

- Pathologic Q waves
- Left or right bundle branch block
- Left or right ventricular hypertrophy
- Poor R-wave progression

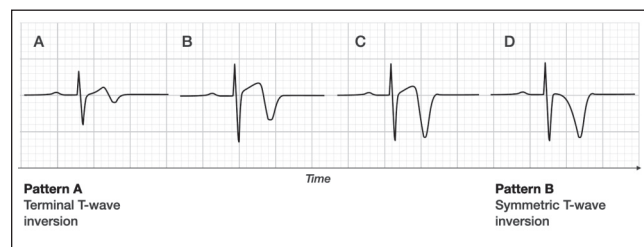


FIGURE 2. Wellens T-wave evolution

Reproduced with permission from Smith SW, Zvosec DL, Sharkey SW, Henry TD. *The ECG in Acute MI: An Evidence-Based Manual of Reperfusion Therapy*. Philadelphia, PA: Lippincott, Williams, and Wilkins; 2002.

can have several causes, including pulmonary embolism, intracranial hemorrhage or stroke, pericarditis, myocarditis, Takotsubo cardiomyopathy, ventricular hypertrophy, bundle branch block, mitral valve prolapse, spontaneous coronary artery dissection, coronary vasospasm, persistent juvenile T waves, or digitalis effect.^{1,10,12,25} Clinicians can differentiate Wellens from non-Wellensoid T-wave inversions by the patient's clinical presentation as well as the depth of the negative portion of the T wave, which generally is deeper in Wellens syndrome.¹² Although T-wave inversions can represent many noncardiac causes, the patient's clinical presentation will suggest the likely cause.

MANAGEMENT

After the diagnosis is made, patients with Wellens syndrome require hospital admission and urgent cardiology consultation even if the pain has subsided or cardiac enzymes are normal. If the patient is hemodynamically unstable, the initial goal is to stabilize the patient with IV fluids or vasopressors as required. Begin treatment with antianginal, antiplatelet, and anticoagulant medications and closely monitor the patient in a unit with capacity for continuous vital sign and telemetry monitoring.¹⁹ Definitive treatment

involves early coronary intervention through stent placement or bypass graft creation to relieve the LAD occlusion and restore perfusion. In the original study by de Zwaan and colleagues, 75% of patients with a Wellens pattern on ECG who did not undergo cardiac catheterization developed

The initial ECG can be normal, and ischemic changes often manifest only after pain resolution.

an anterior wall MI in about 8.5 days.¹ These patients will fare poorly with medical management alone because the natural progression of LAD occlusion leads to anterior wall MI.^{1,2,4,12}

CONCLUSION

Wellens syndrome is a rare manifestation of ACS that precedes an anterior wall MI. Patients with this syndrome have severe LAD occlusion and require early coronary intervention to prevent significant morbidity and mortality. The diagnosis is challenging. The initial ECG can be normal, and ischemic changes often manifest only after pain resolution. The type A pattern often is subtle and may not manifest at the onset of symptoms. Additionally, troponin levels often are normal and can give false reassurance. Given these challenges, all patients with chest pain should undergo serial ECGs to detect dynamic ECG changes that occur over time. **JAAPA**

Earn AAPA Category 1 CME credit by reading both CME articles in this issue, reviewing the post-test, then taking the online test at <https://cme.aapa.org>. Successful completion is defined as a cumulative score of at least 70% correct. This material has been reviewed and is approved for 1 AAPA Category 1 CME credit. The term of approval is for 1 year from the publication date of February 2023.

REFERENCES

- de Zwaan C, Bär FW, Wellens HJ. Characteristic electrocardiographic pattern indicating a critical stenosis high in left anterior descending coronary artery in patients admitted because of impending myocardial infarction. *Am Heart J*. 1982;103(4 Pt 2):730-736.
- de Zwaan C, Bär FW, Janssen JH, et al. Angiographic and clinical characteristics of patients with unstable angina showing an ECG pattern indicating critical narrowing of the proximal LAD coronary artery. *Am Heart J*. 1989;117(3):657-665.
- Tandy TK, Bottomy DP, Lewis JG. Wellens' syndrome. *Ann Emerg Med*. 1999;33(3):347-351.
- Suryawan IGR, Bakhriansyah J, Puspitasari M, et al. To reperfuse or not to reperfuse: a case report of Wellens' syndrome with suspected COVID-19 infection. *Egypt Heart J*. 2020;72:58.
- Moore KL, Dalley AF, Agur AMR. Thorax. In: *Clinically Oriented Anatomy*. 7th ed. Baltimore, MD: Lippincott, Williams & Wilkins; 2014:145,148-149,160.
- Rehman I, Kerndt CC, Rehman A. Anatomy, thorax, heart left anterior descending (LAD) artery. In: StatPearls. Treasure Island, FL: StatPearls Publishing; 2022. www.ncbi.nlm.nih.gov/books/NBK482375. Accessed October 19, 2022.
- Weber C, Brown KN, Borger J. Anatomy, thorax, heart anomalous left anterior descending (LAD) artery. In: StatPearls. Treasure Island, FL: StatPearls Publishing; 2022. www.ncbi.nlm.nih.gov/books/NBK538162. Accessed October 19, 2022.
- Ogoburo I, Wehrle CJ, Tuma F. Anatomy, thorax, heart coronary arteries. In: StatPearls. Treasure Island, FL: StatPearls Publishing; 2022. www.ncbi.nlm.nih.gov/books/NBK534790. Accessed October 19, 2022.
- Austen WG, Edwards JE, Frye RL, et al. A reporting system on patients evaluated for coronary artery disease. Report of the Ad Hoc Committee for Grading of Coronary Artery Disease, Council on Cardiovascular Surgery, American Heart Association. *Circulation*. 1975;51(4 suppl):5-40.
- Arshad S, Ferrick NJ, Monrad ES, et al. Prevalence and association of the Wellens' sign with coronary artery disease in an ethnically diverse urban population. *J Electrocardiol*. 2020;62:211-215.
- Kobayashi A, Misumida N, Aoi S, Kanei Y. Prevalence and clinical implication of Wellens' sign in patients with non-ST-segment elevation myocardial infarction. *Cardiol Res*. 2019;10(3):135-141.
- Rhinehardt J, Brady WJ, Perron AD, Mattu A. Electrocardiographic manifestations of Wellens' syndrome. *Am J Emerg Med*. 2002;20(7):638-643.
- Davies MJ. Coronary disease: the pathophysiology of acute coronary syndromes. *Heart*. 2000;83(3):361-366.
- Falk E, Shah PK, Fuster V. Coronary plaque disruption. *Circulation*. 1995;92(3):657-671.
- Schears MR, Sleigh BC, Ganti L. Wellen's syndrome: is one electrocardiogram good and plenty? *Cureus*. 2019;11(4):e4394.
- Abulaiti A, Aini R, Xu H, Song Z. A special case of Wellens' syndrome. *J Cardiovasc Dis Res*. 2013;4(1):51-54.
- Nisbet BC, Zlupko G. Repeat Wellens' syndrome: case report of critical proximal left anterior descending artery stenosis. *J Emerg Med*. 2010;39(3):305-308.
- Migliore F, Zorzi A, Marra MP, et al. Myocardial edema underlies dynamic T-wave inversion (Wellens' ECG pattern) in patients with reversible left ventricular dysfunction. *Heart Rhythm*. 2011;8(10):1629-1634.
- Amsterdam EA, Wenger NK, Brindis RG, et al. 2014 AHA/ACC guideline for the management of patients with non-ST-elevation acute coronary syndromes: a report of the American College of Cardiology/American Heart Association Task Force on practice guidelines. *Circulation*. 2014;130(25):e344-e426.
- Virani SS, Alonso A, Aparicio HJ, et al. Heart disease and stroke statistics—2021 update. *Circulation*. 2021;143(8):e254-e743.
- Kumar A, Cannon CP. Acute coronary syndromes: diagnosis and management, part I. *Mayo Clin Proc*. 2009;84(10):917-938.
- Chu S, Liu L, Shi L, et al. Arrhythmia associated with acute coronary syndrome: occurrence, risk factors, therapy and prognosis: a single-centre study. *Heart*. 2012;98(suppl 2):E275.
- Ngan ATL, Yeung C, Chiang L, et al. Atypical electrocardiographic manifestations of ischemia: a case of dynamic Wellens patterns. *J Geriatr Cardiol*. 2018;15(11):710-712.
- Singh B, Singh Y, Singla V, Nanjappa MC. Wellens' syndrome: a classical electrocardiographic sign of impending myocardial infarction. *BMJ Case Rep*. 2013;2013:bcr2012008513.
- Sheng F-Q, He M-R, Zhang M-L, Shen G-Y. Wellens syndrome caused by spasm of the proximal left anterior descending coronary artery. *J Electrocardiol*. 2015;48(3):423-425.