



# Treatment of Proximal Humerus Fractures

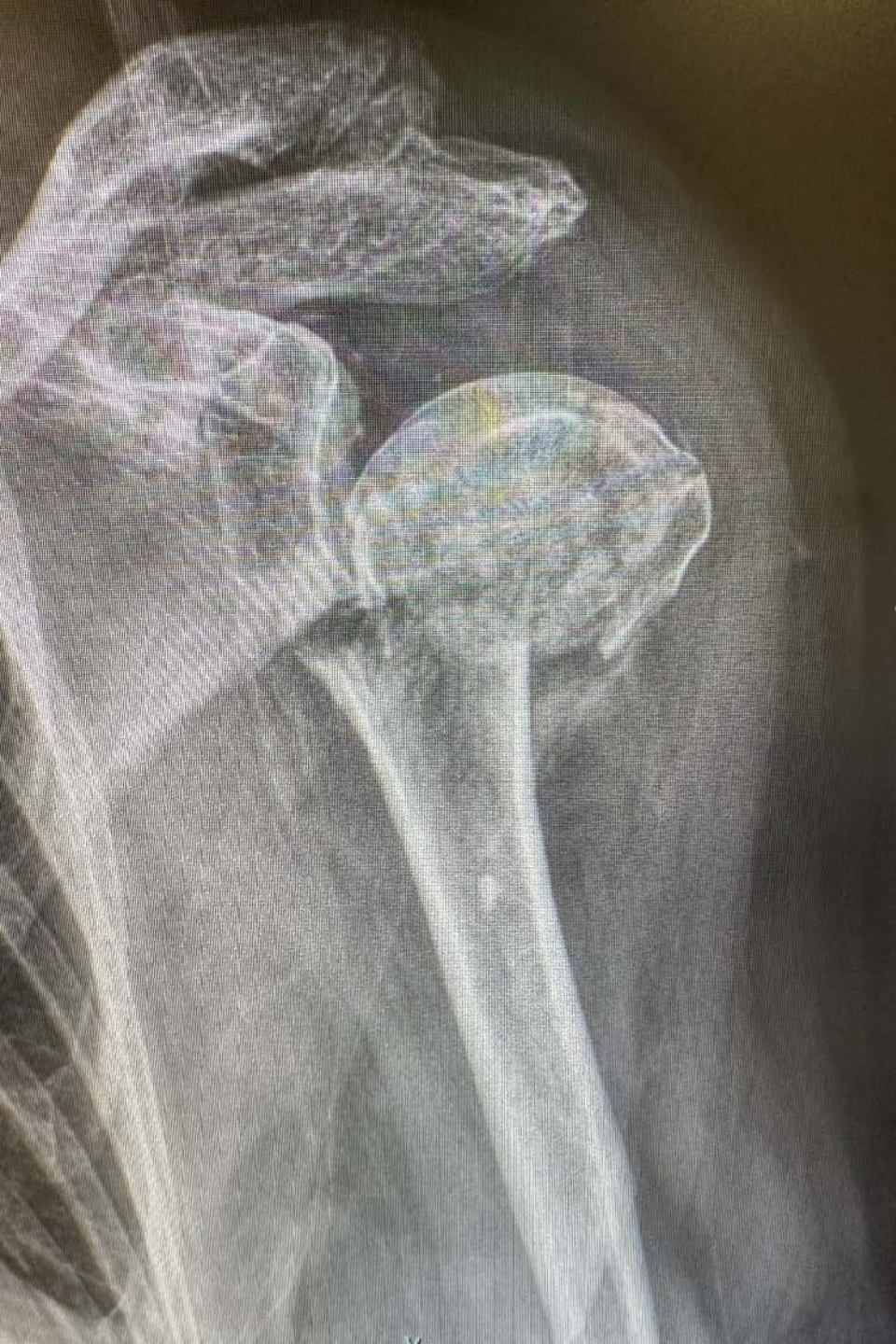Timothy J. Thompson, PA-C, MBA

PAOS - Ortho in the West

February 17, 2023



# Treatment of Proximal Humerus Fractures

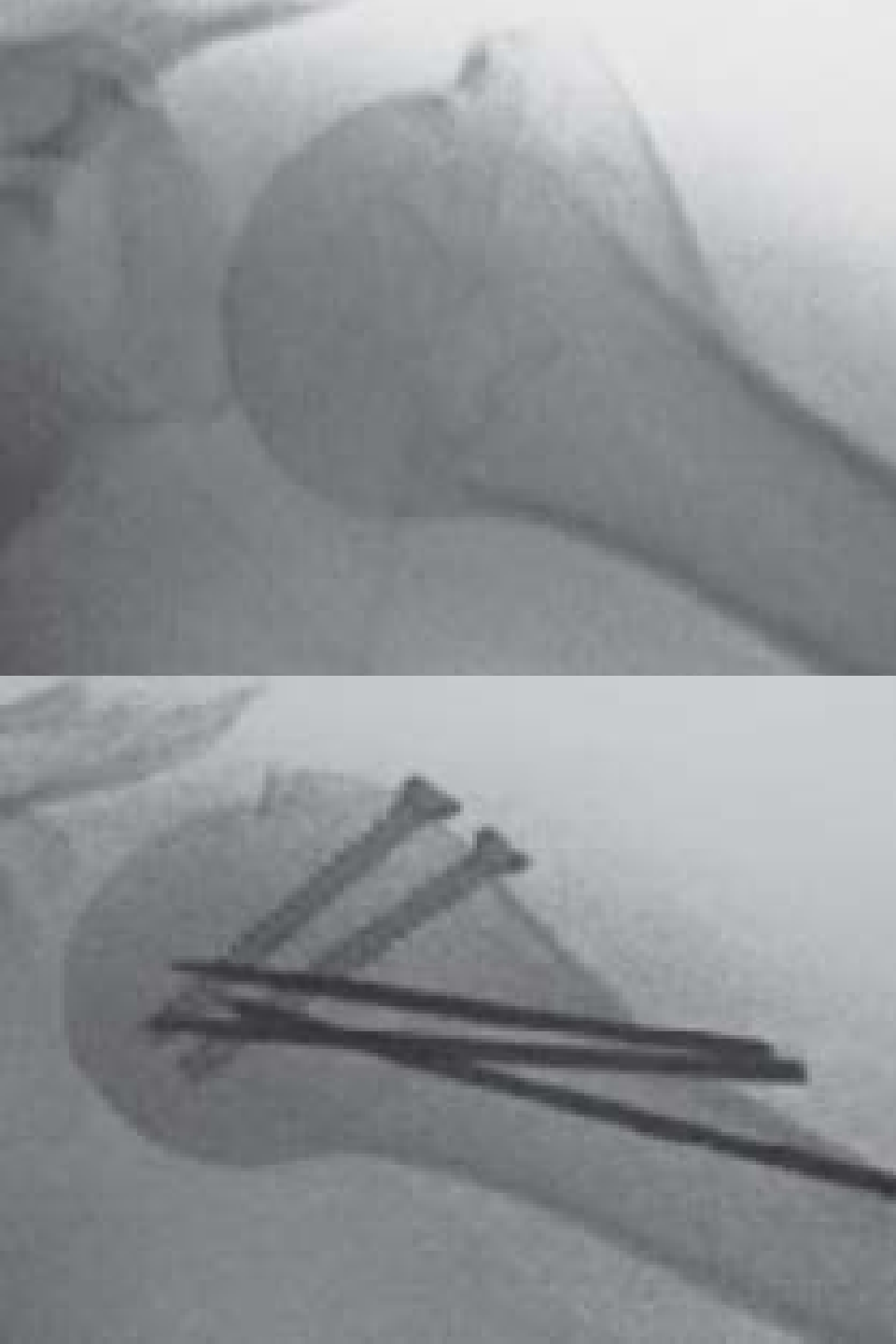


- A. Percutaneous Pin
- B. ORIF
- C. IM Nail
- D. Arthroplasty
- E. None of the Above

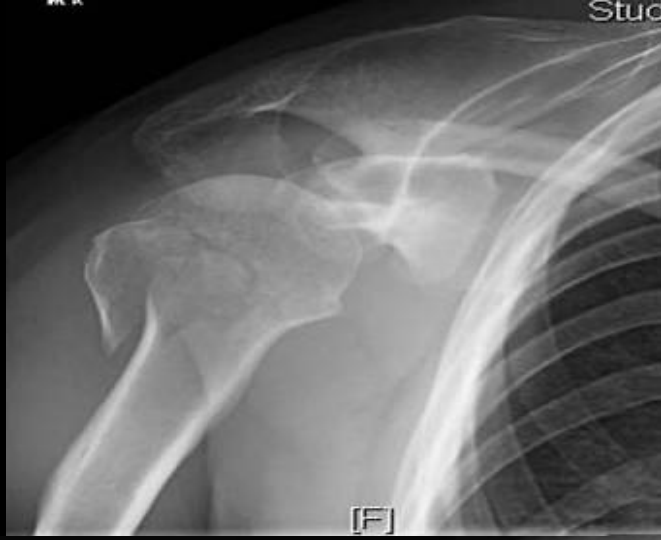

# Treatment of Proximal Humerus Fractures

- A. Percutaneous Pin
- B. ORIF
- C. IM Nail
- D. Arthroplasty
- E. None of the Above



# Treatment of Proximal Humerus Fractures

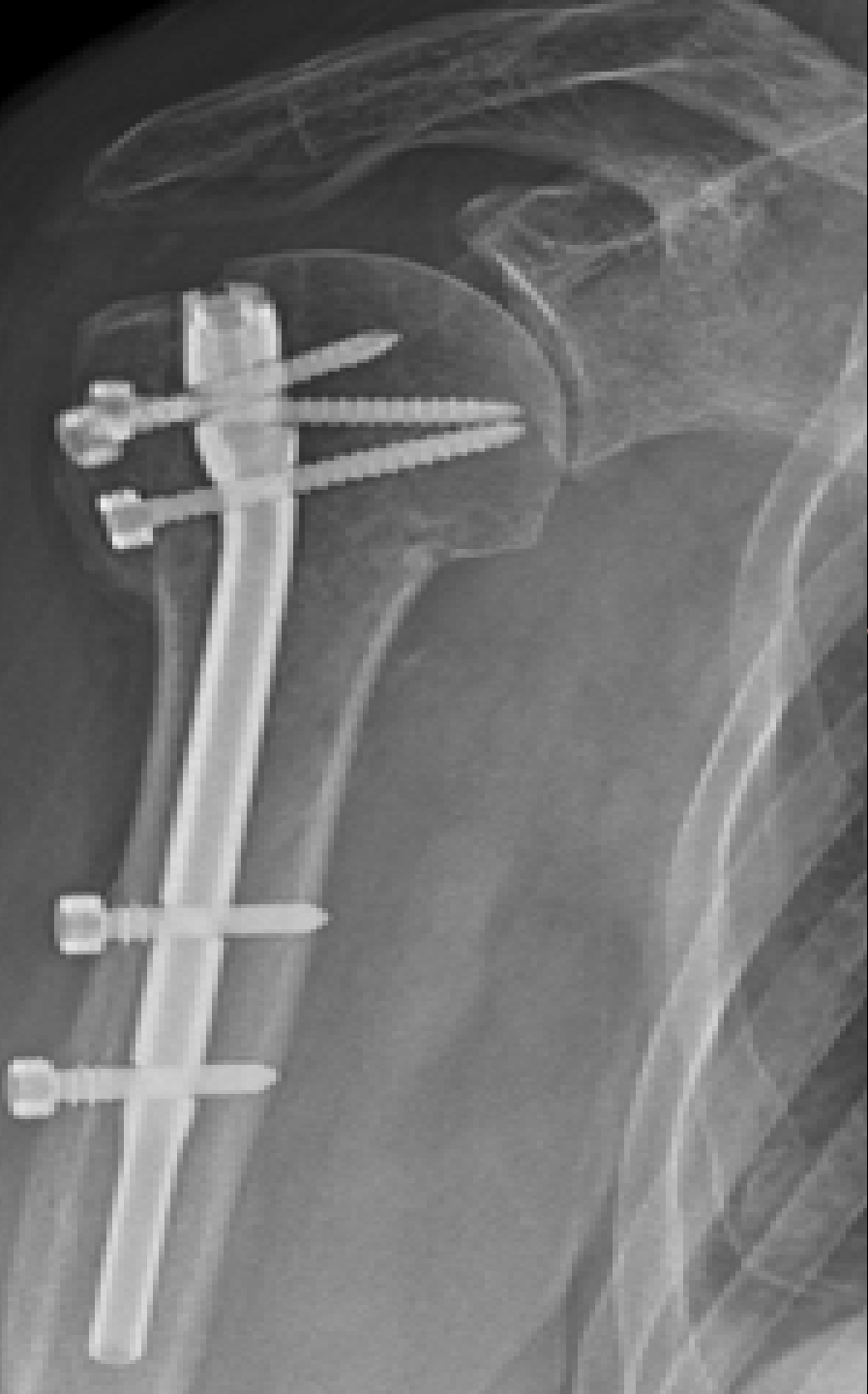

- A. Percutaneous Pin
- B. ORIF**
- C. IM Nail
- D. Arthroplasty
- E. None of the Above





# Treatment of Proximal Humerus Fractures

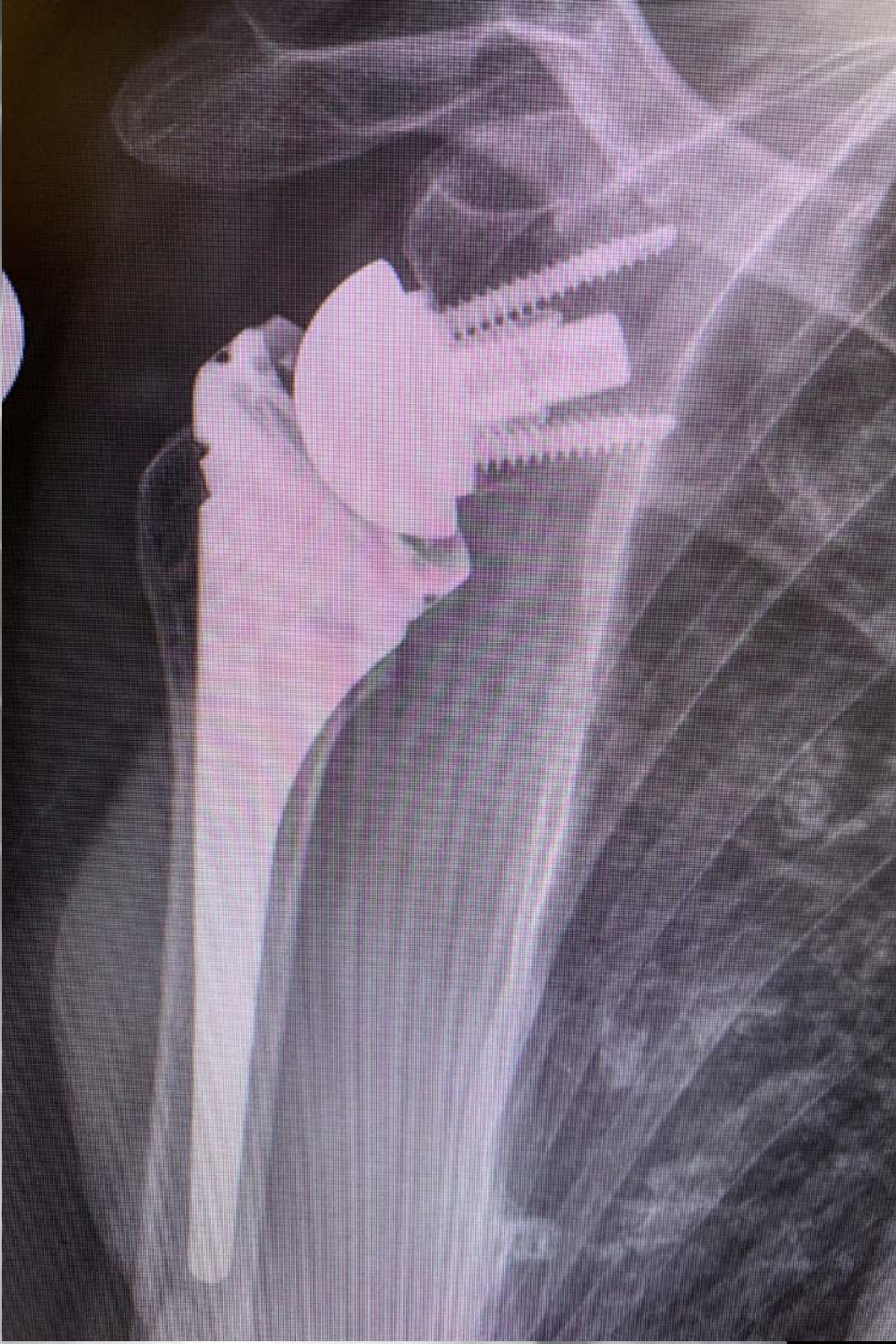

- A. Percutaneous Pin
- B. ORIF
- C. IM Nail
- D. Arthroplasty
- E. None of the Above



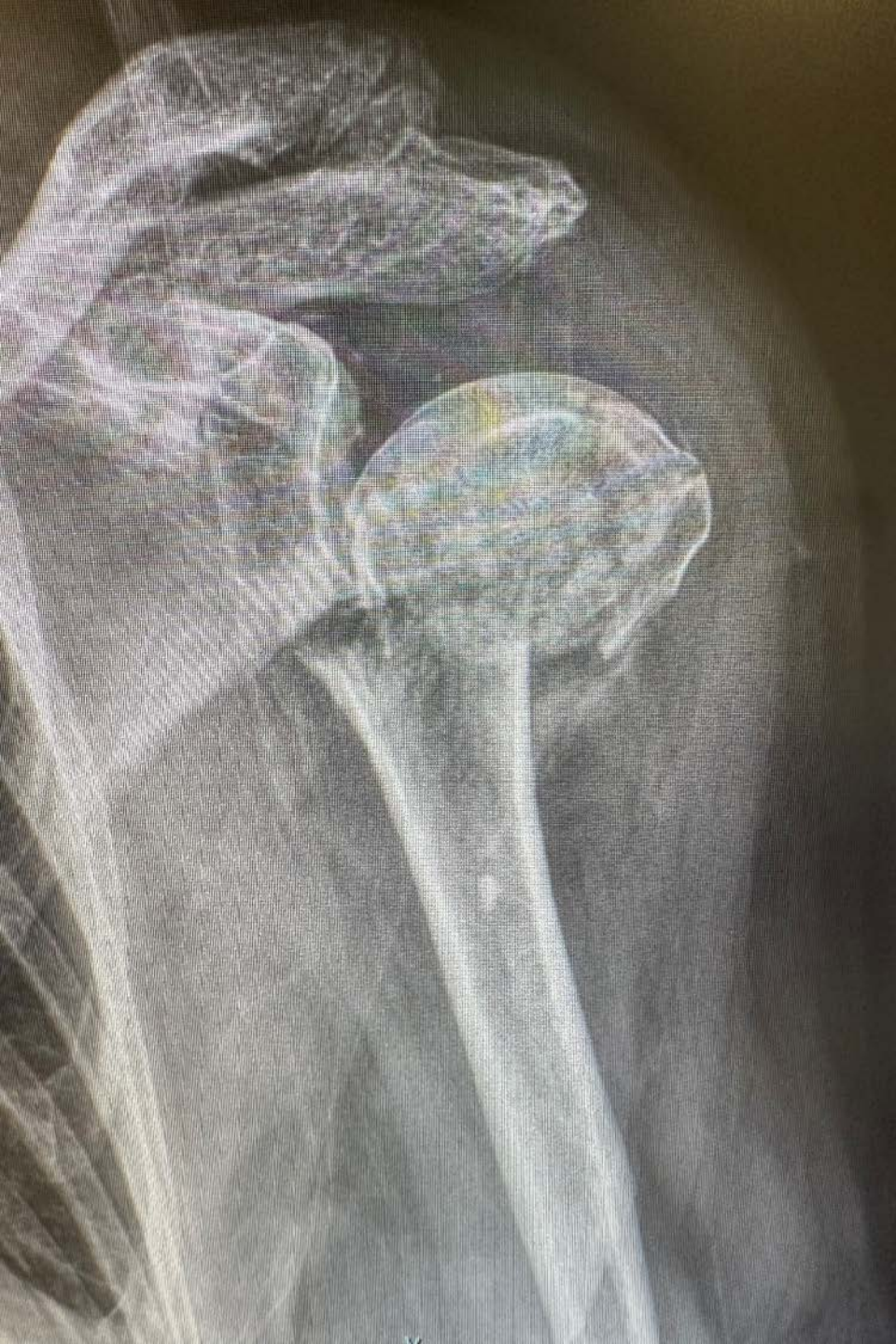# Treatment of Proximal Humerus Fractures

- A. Percutaneous Pin
- B. ORIF
- C. IM Nail
- D. Arthroplasty
- E. None of the Above





# Treatment of Proximal Humerus Fractures



- A. Percutaneous Pin
- B. ORIF
- C. IM Nail
- D. Arthroplasty
- E. None of the Above



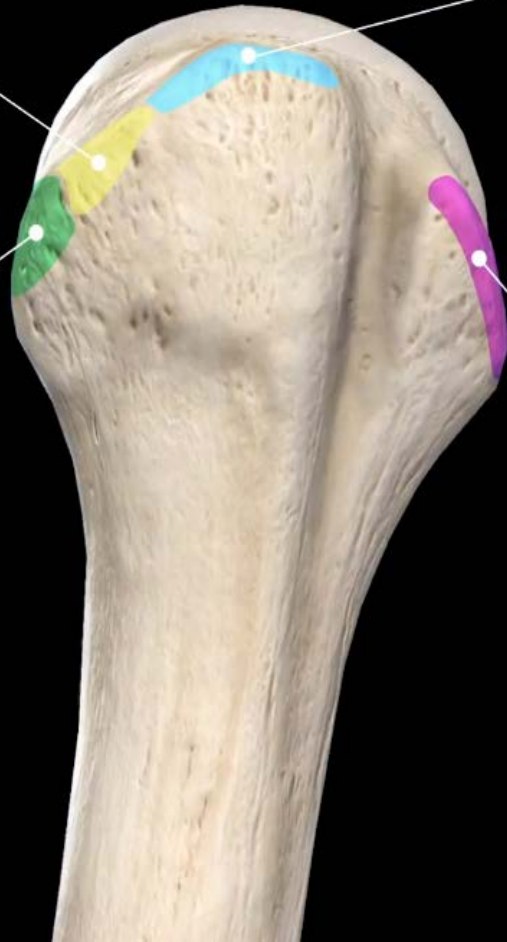
# Treatment of Proximal Humerus Fractures

Infraspinatus

Supraspinatus

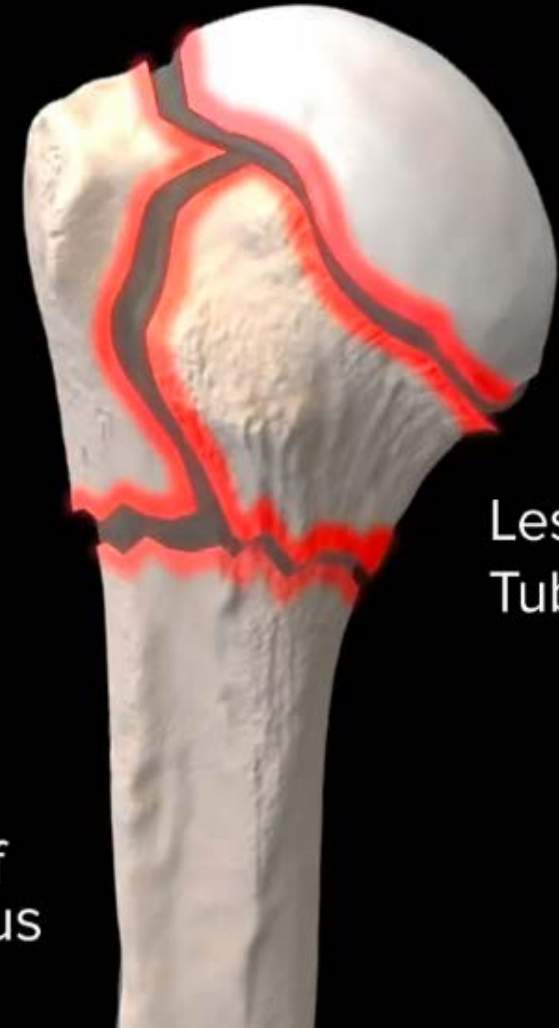Teres Minor

Subscapularis



Greater Tuberosity

Head



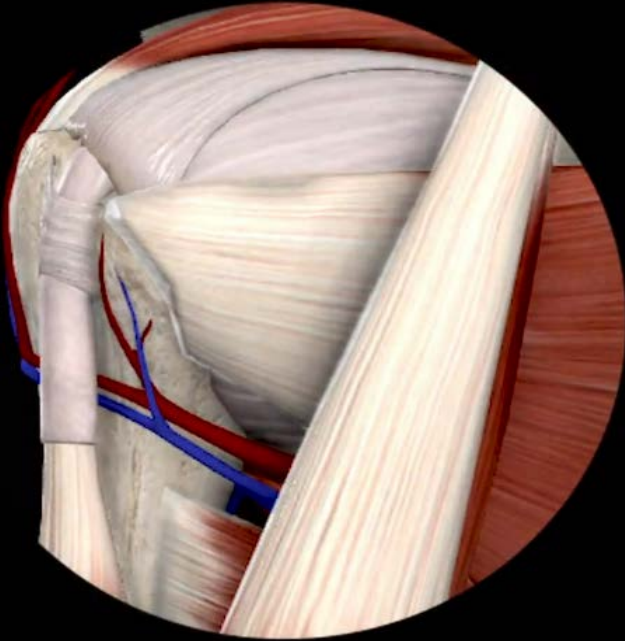
Lesser Tuberosity

Shaft of Humerus

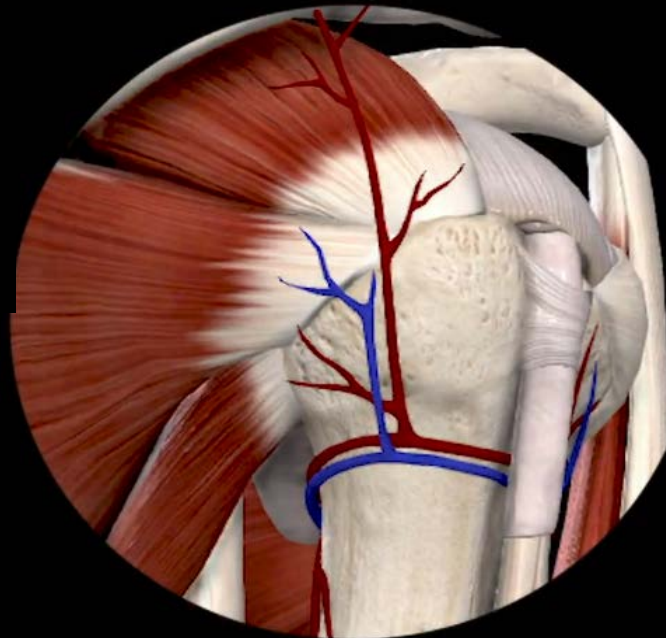




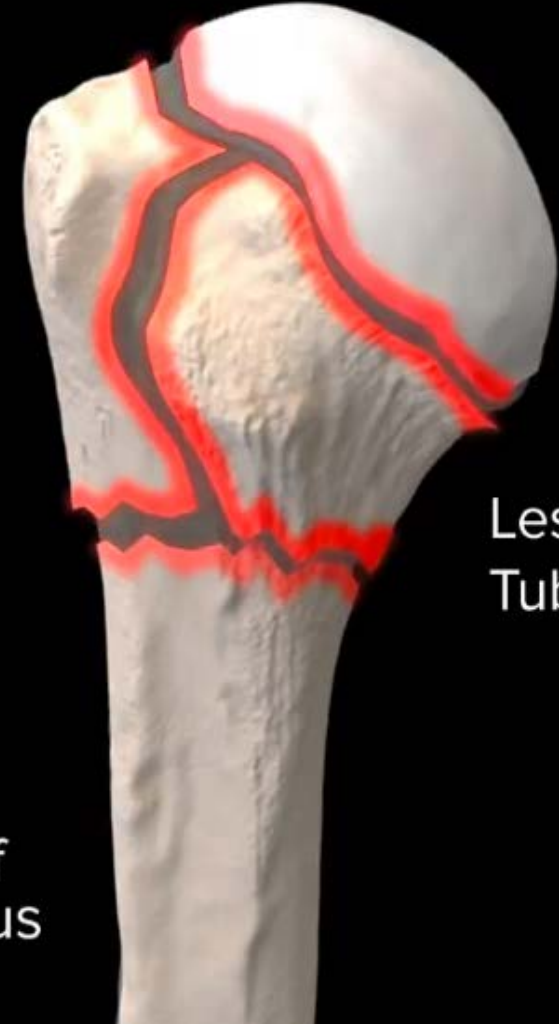# Treatment of Proximal Humerus Fractures



Greater  
Tuberosity



Shaft of  
Humerus



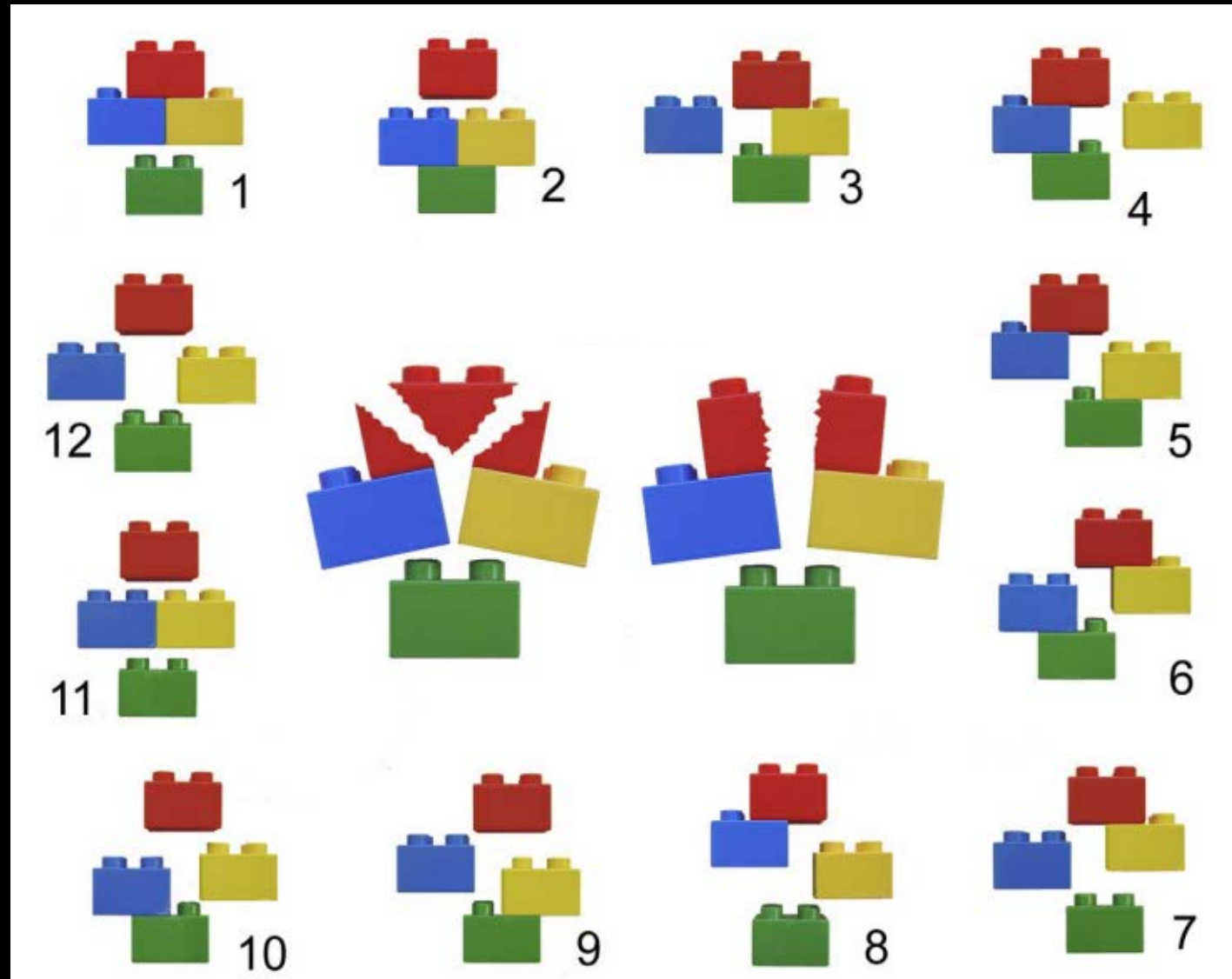
Head

Lesser  
Tuberosity















# Treatment of Proximal Humerus Fractures

## Hertel Classification



# Treatment of Proximal Humerus Fractures

## AO Classification

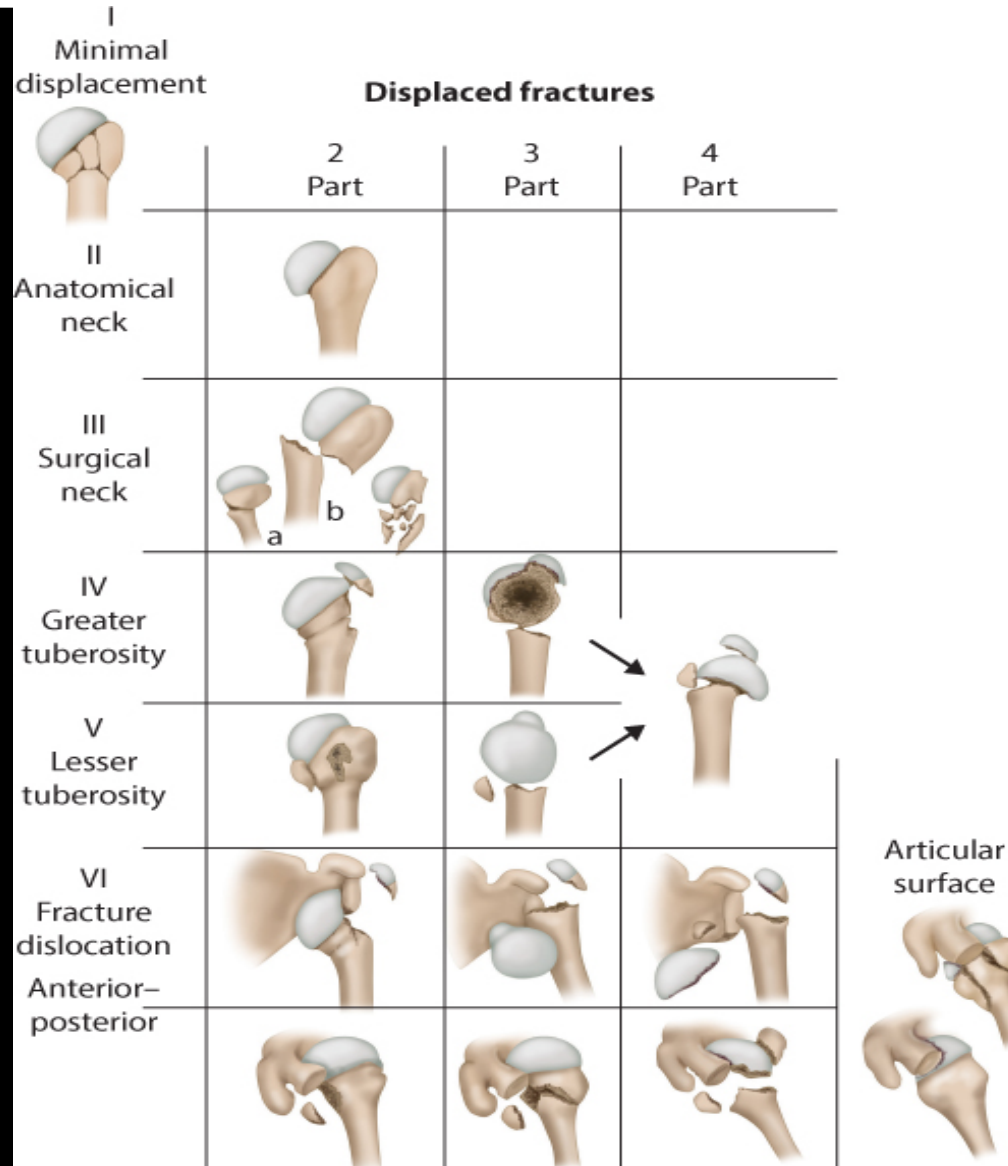
<p><b>A:</b></p> <p>Unifocal Extra-articular 2-Part Fracture Intact Blood Supply</p>				
<p><b>B:</b></p> <p>Bifocal Extra-articular Possible injury to blood supply</p>				
<p><b>C:</b></p> <p>Articular fracture involving the anatomic neck high likelihood of necrosis</p>				





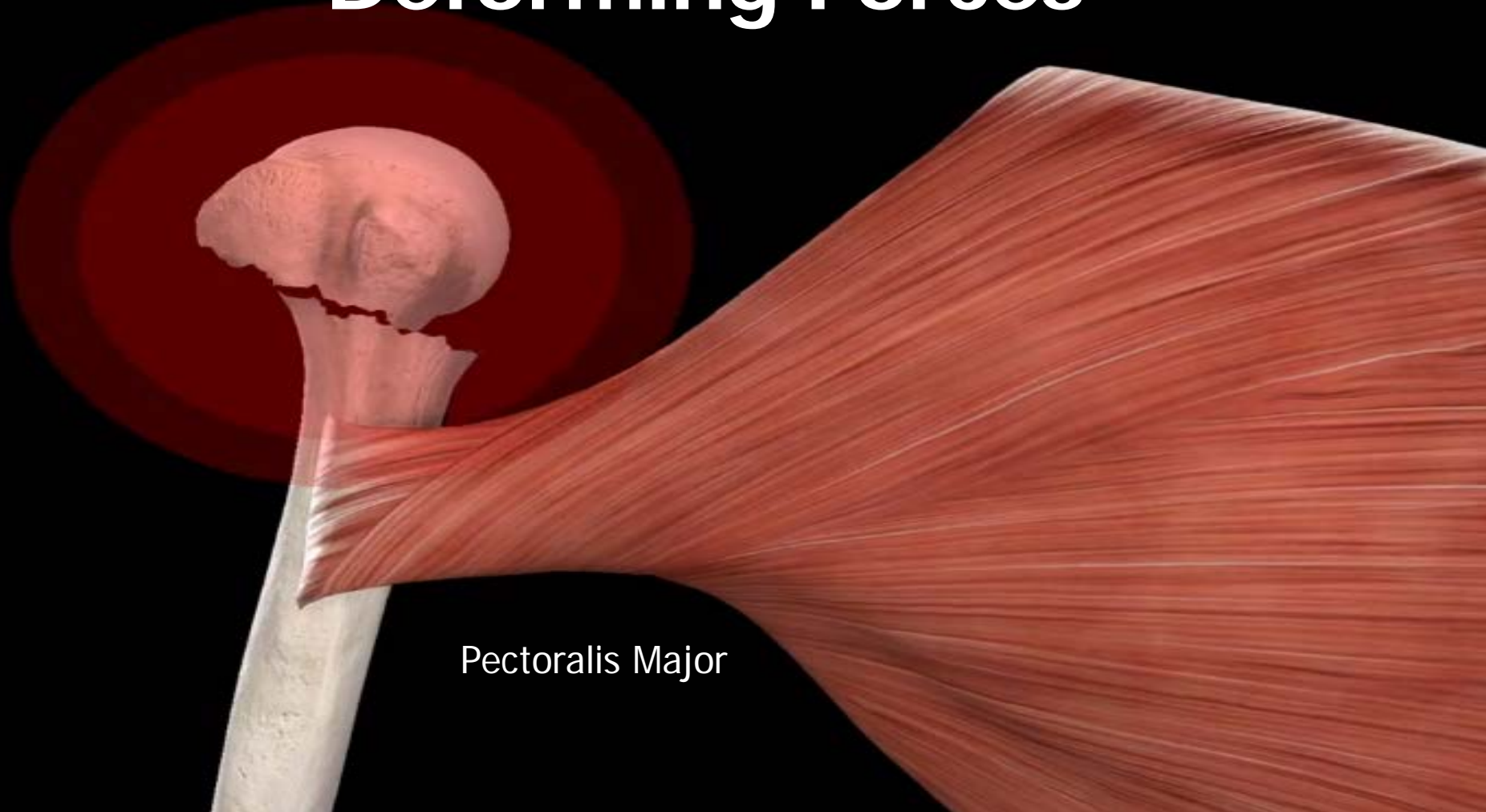
# Treatment of Proximal Humerus Fractures

## Neer Classification



# Treatment of Proximal Humerus Fractures

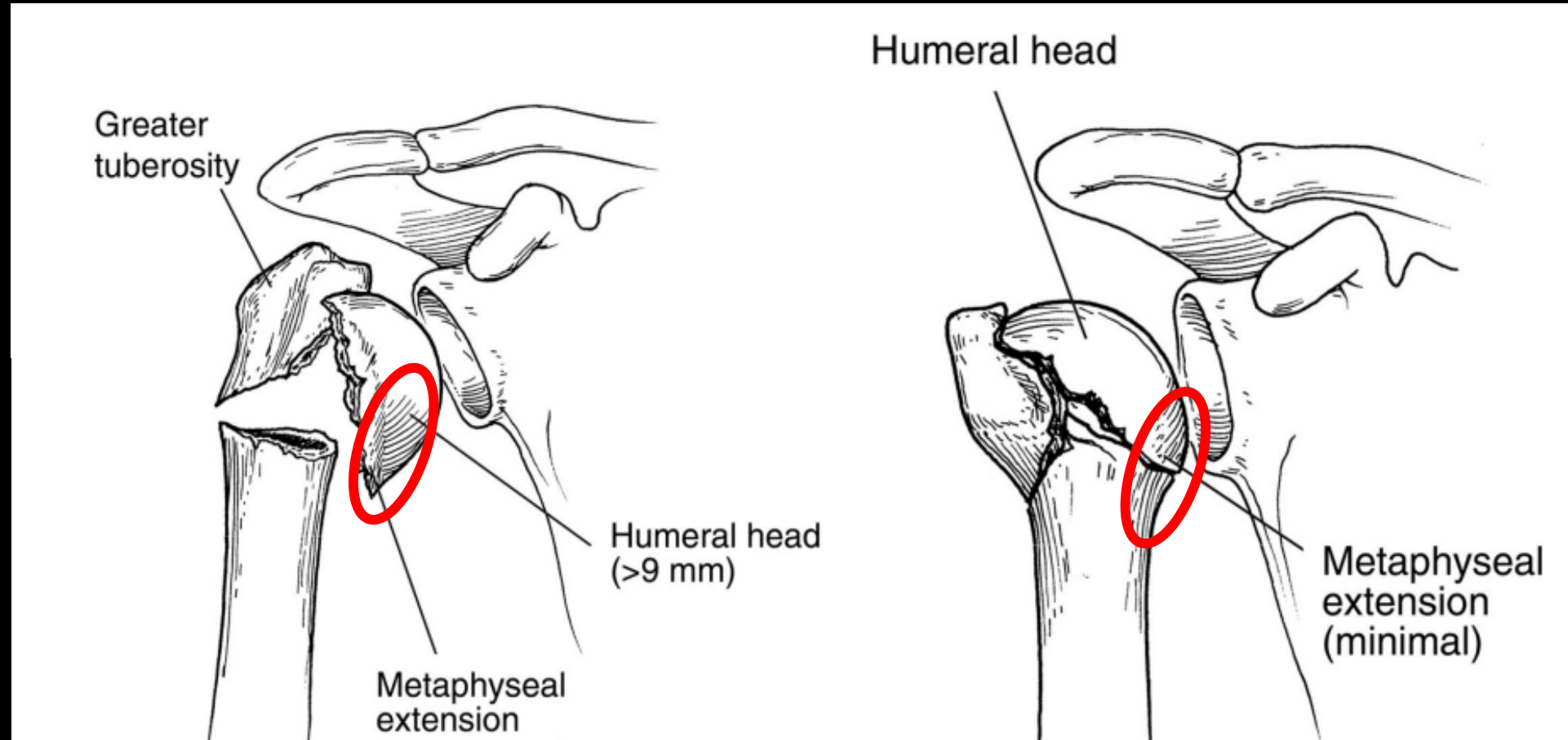
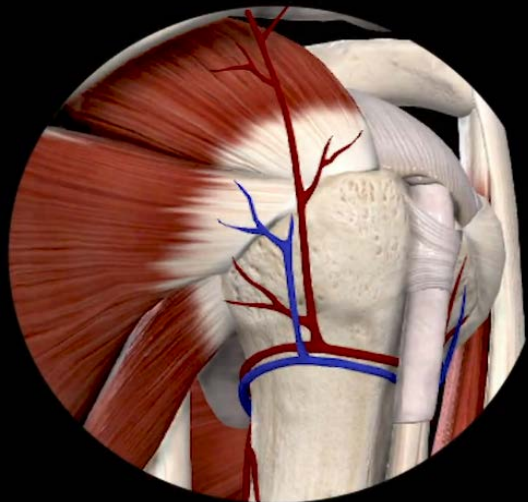
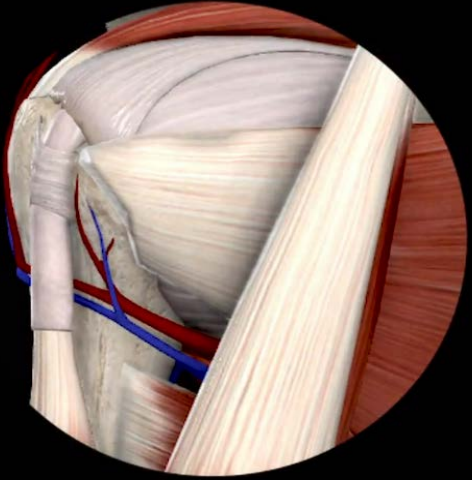
## Deforming Forces



Pectoralis Major

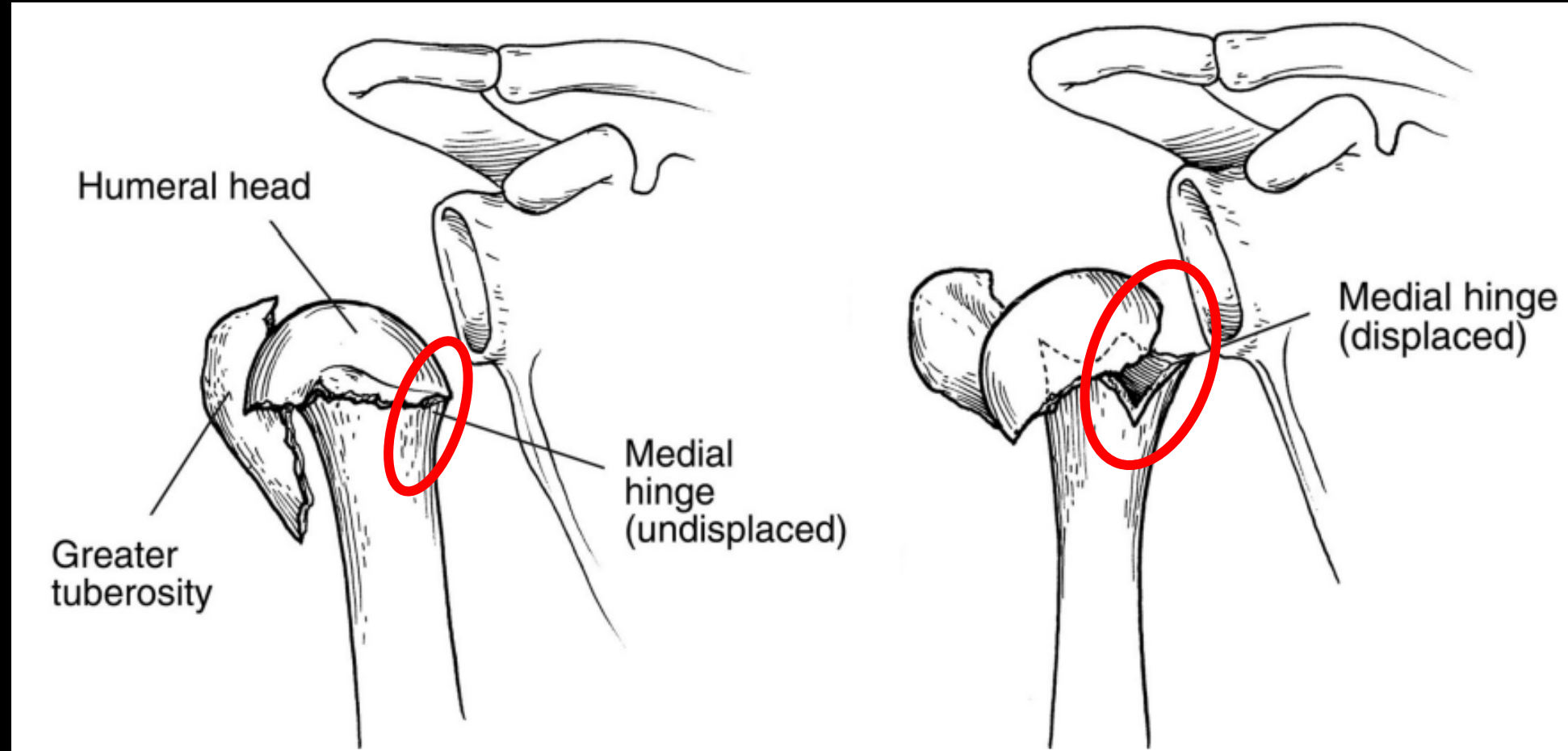
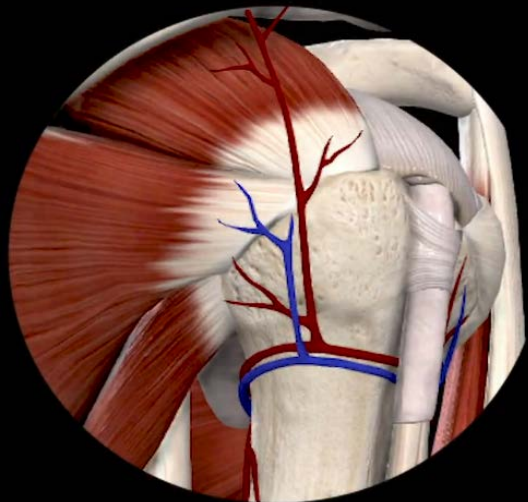
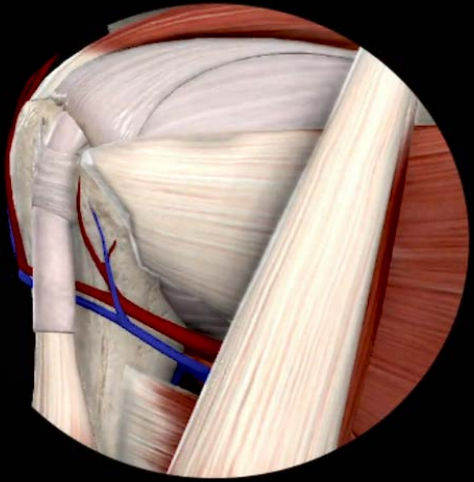


# Treatment of Proximal Humerus Fractures





# Treatment of Proximal Humerus Fractures


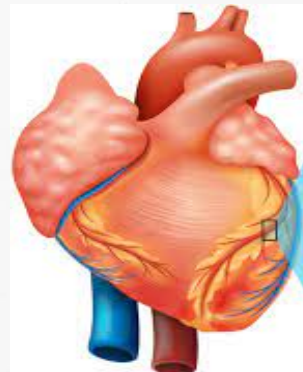


# Treatment of Proximal Humerus Fractures


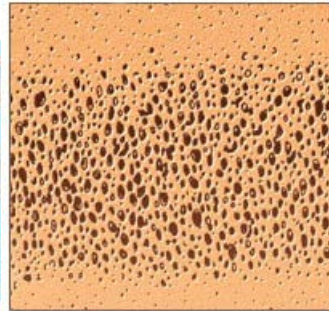




# Treatment of Proximal Humerus Fractures



Normal bone



Osteoporotic bone



**A1c Test Results**

**Diabetes**  
6.5% or higher

**Prediabetes**  
5.7 to 6.4%

**Normal**  
Below 5.7%

## CONSIDERATIONS

Cardiovascular Disease

Diabetes Mellitus

Tobacco Use

Thyroid Dysfunction

Seizure Disorder

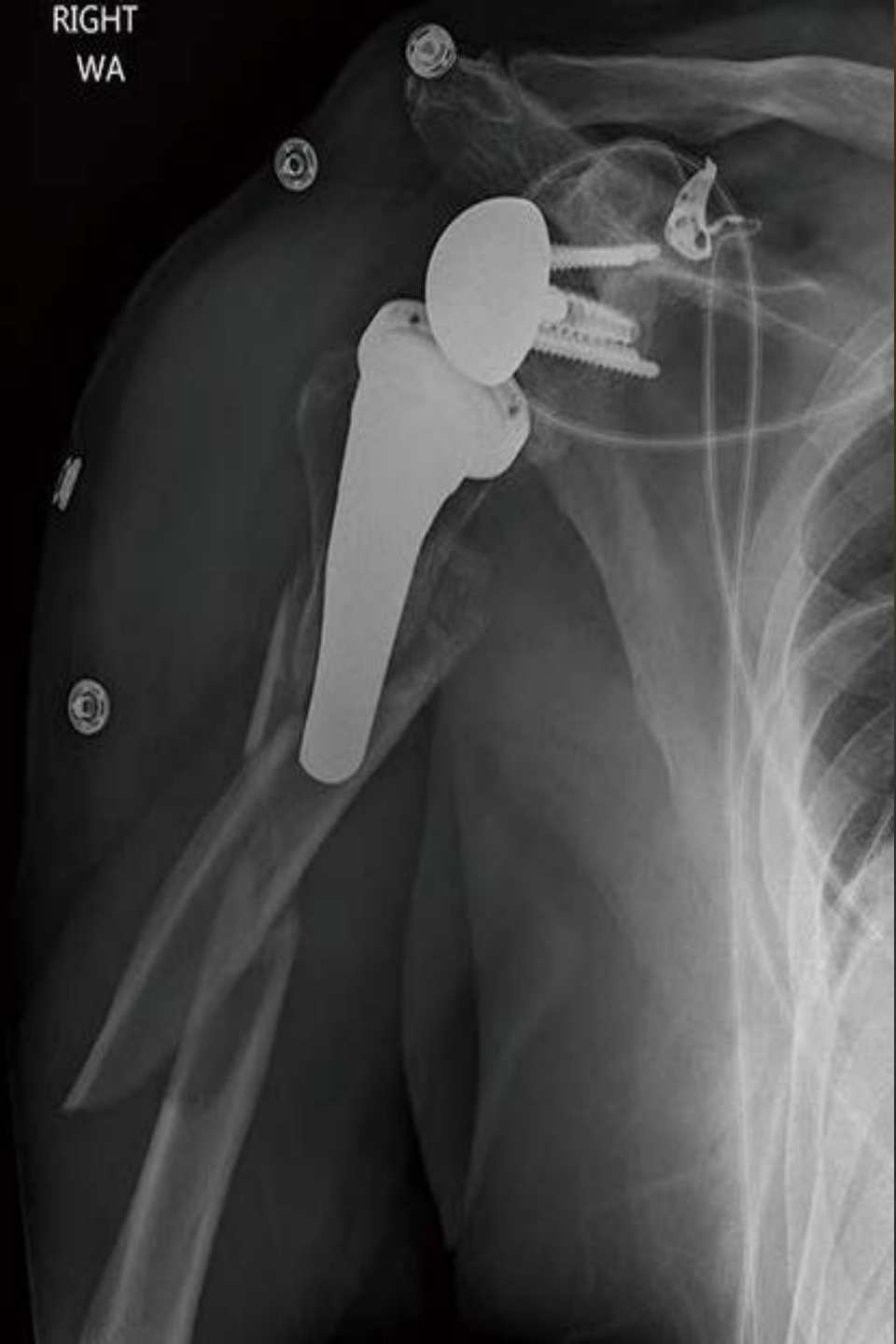Immunocompromised

Osteoporosis





RIGHT  
WA



# Treatment of Proximal Humerus Fractures

## DESCRIPTION

# of Parts

Displacement

Metaphyseal Hinge

Valgus or Varus

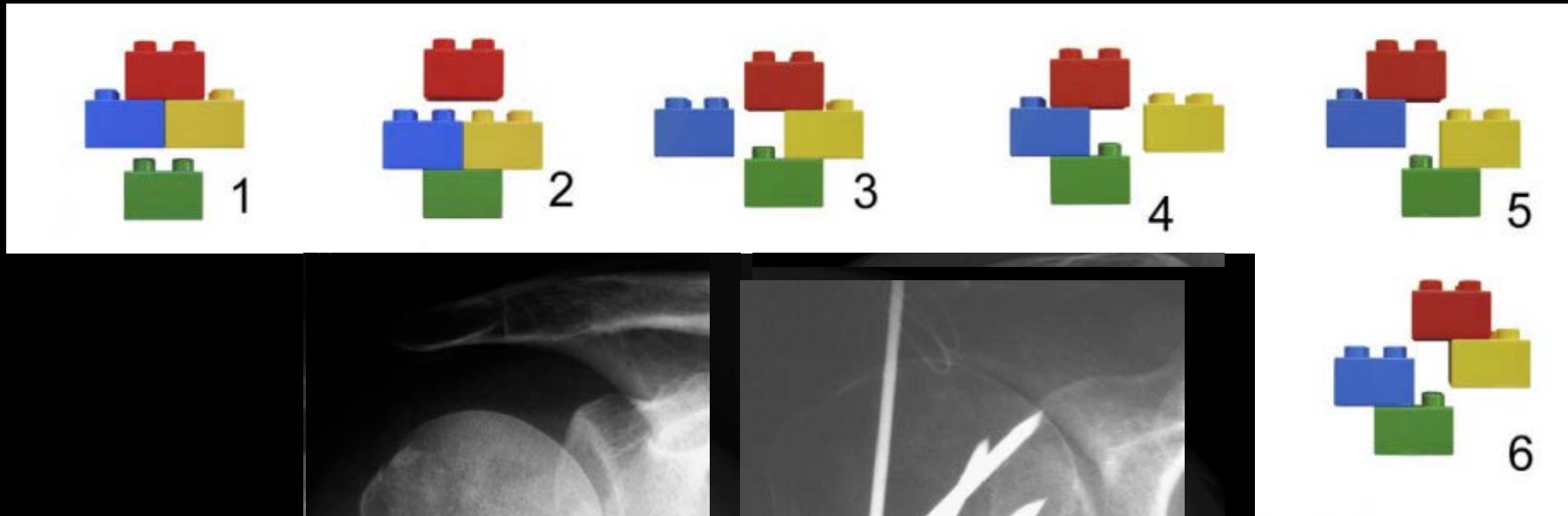
Dislocation

Periprosthetic

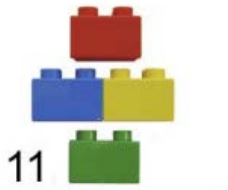


# Treatment of Proximal Humerus Fractures

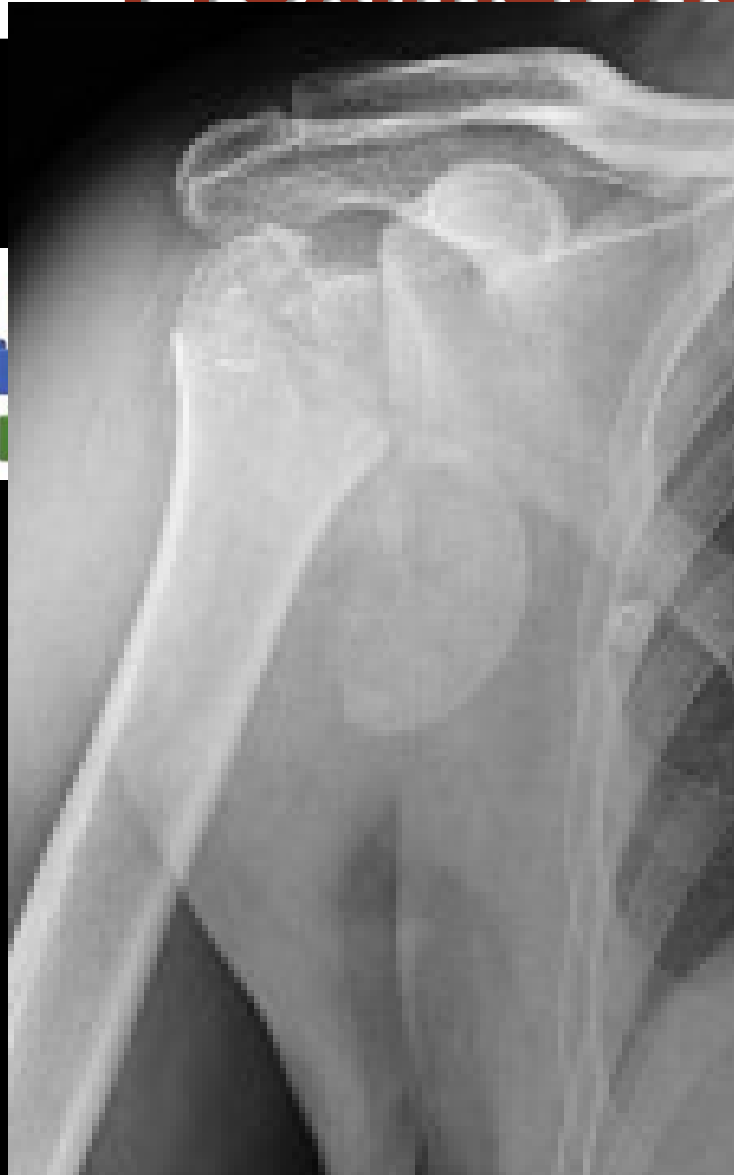## 2 Part Fractures



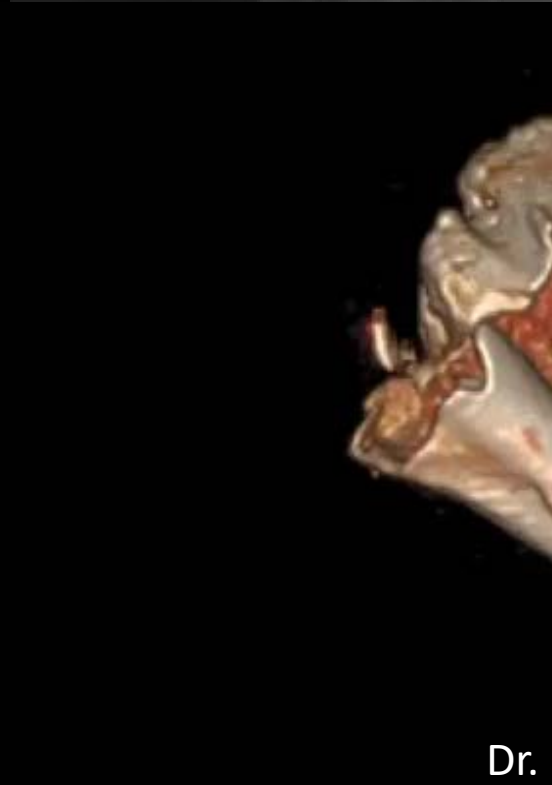
# Treatment of Proximal Humerus Fractures



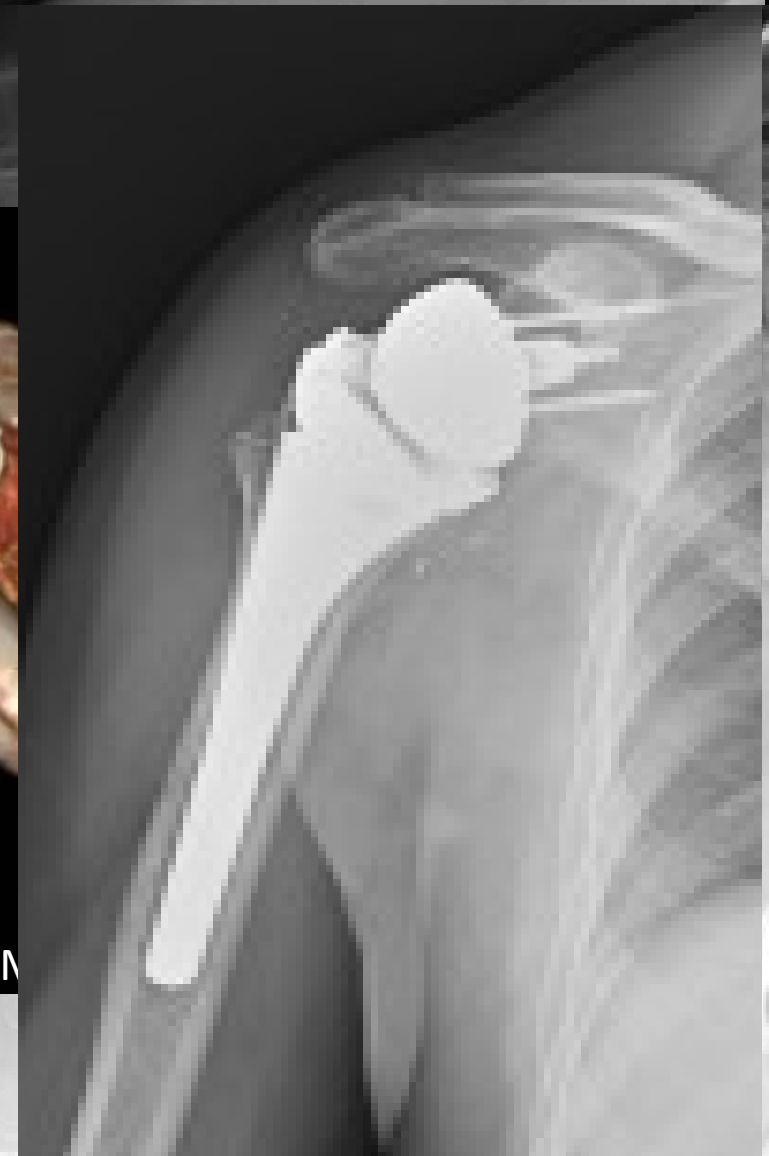3



S



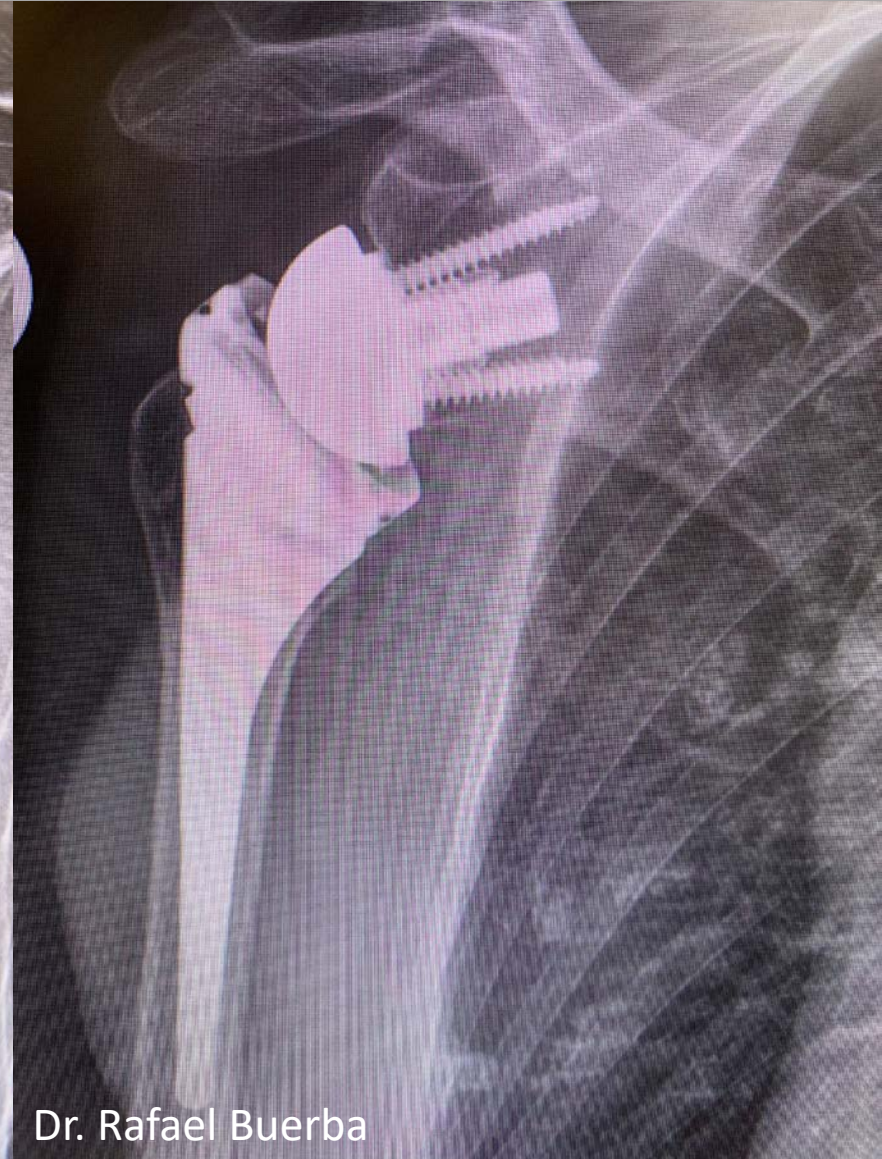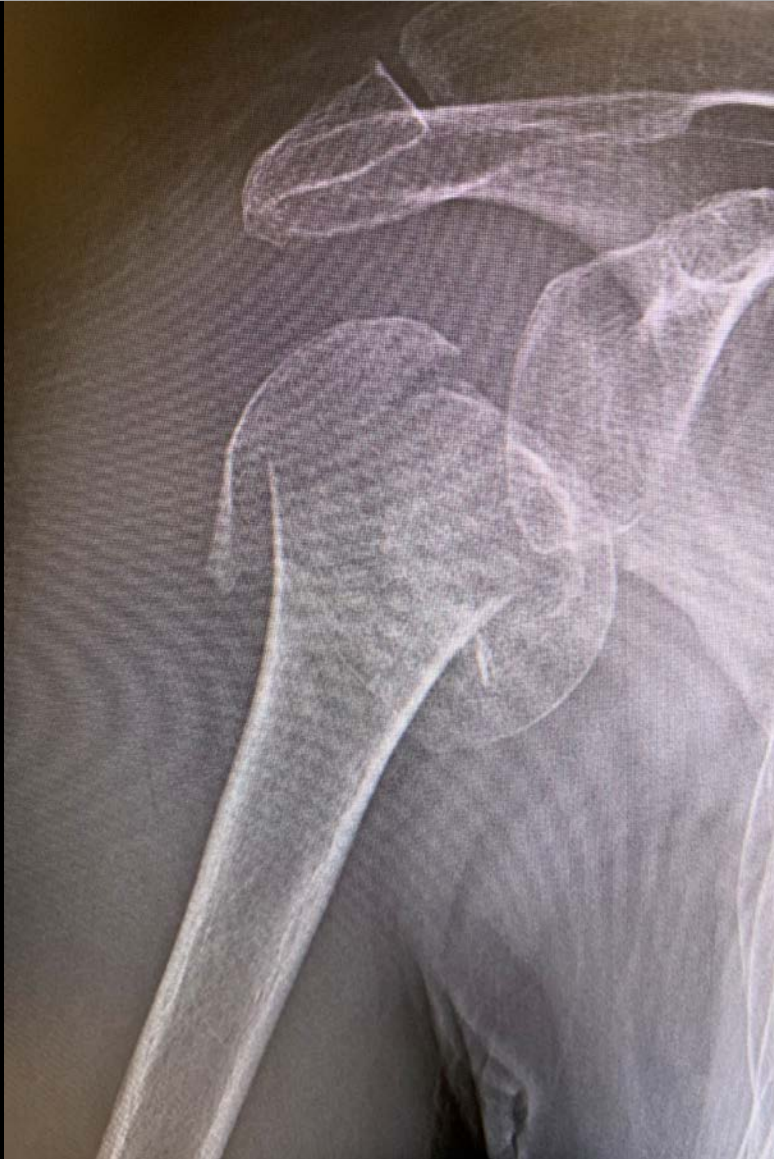Dr. M





# Treatment of Proximal Humerus Fractures

## 4 Part Fractures



# Treatment of Proximal Humerus Fractures

## 2 – Part Fractures

### Greater Tuberosity

Conservative

ORIF/Screws

Percutaneous Pin

### Surgical Neck

Conservative

Percutaneous Pin

ORIF

IM Nail

## 3 – Part Fractures

Conservative

ORIF

IM Nail w/ ORIF

Hemiarthroplasty

rTSA

## 4 – Part Fractures

Conservative

ORIF

Hemiarthroplasty

rTSA

# Treatment of Proximal Humerus Fractures

## Optimizing Outcomes

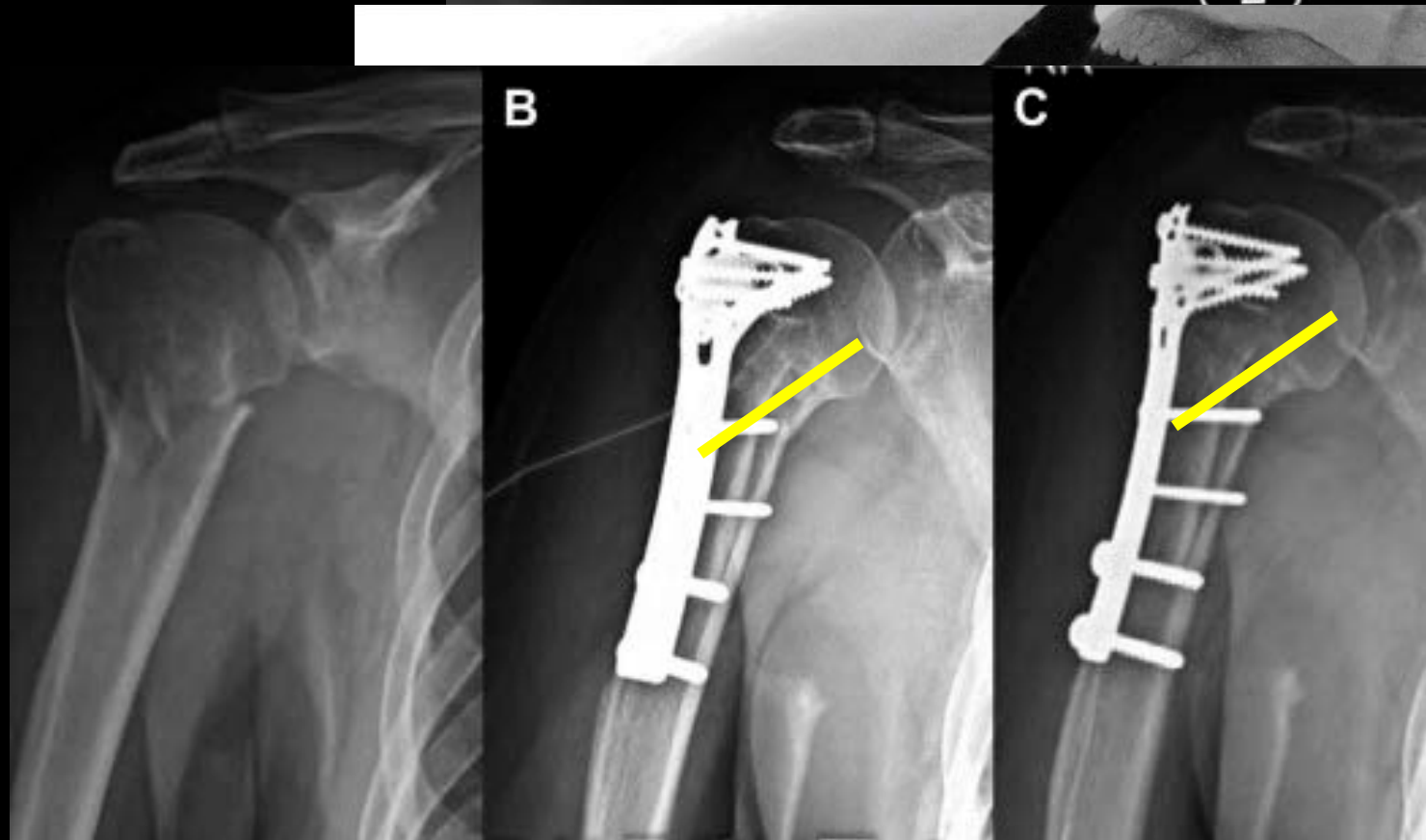
### ORIF

Reduction

Kick Stand Screw

IM Strut Graft

Recognize AVN Early



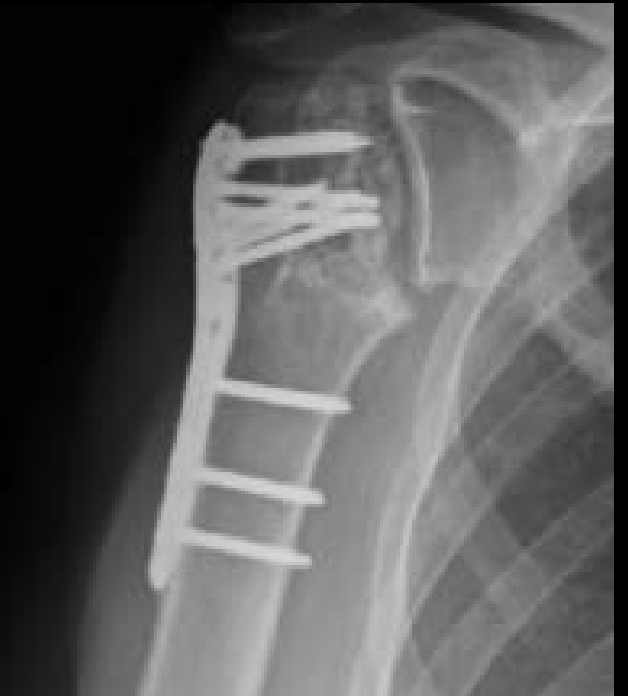
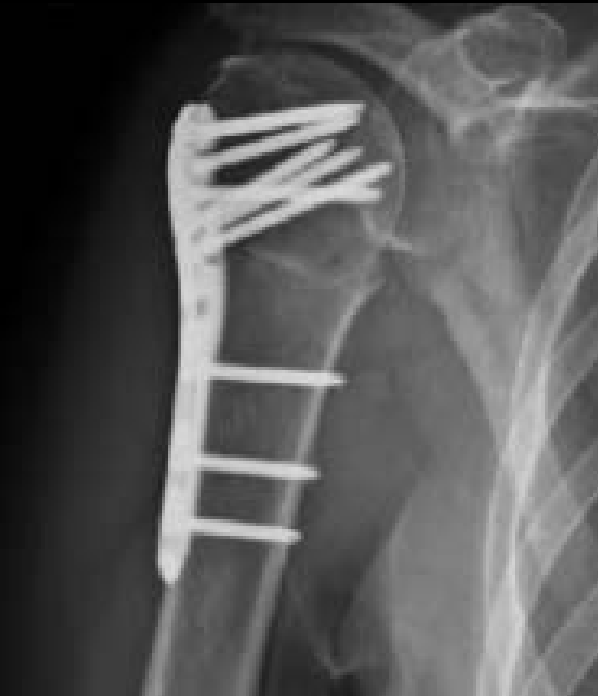
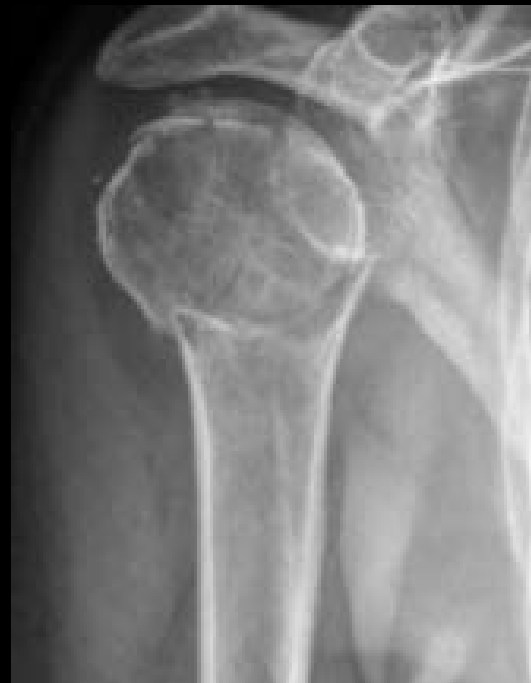# Treatment of Proximal Humerus Fractures

## Complications

### ORIF

Malreduction  
AVN  
Screw Cut Out  
Glenoid Destruction  
Non-Union  
Malunion  
Infection

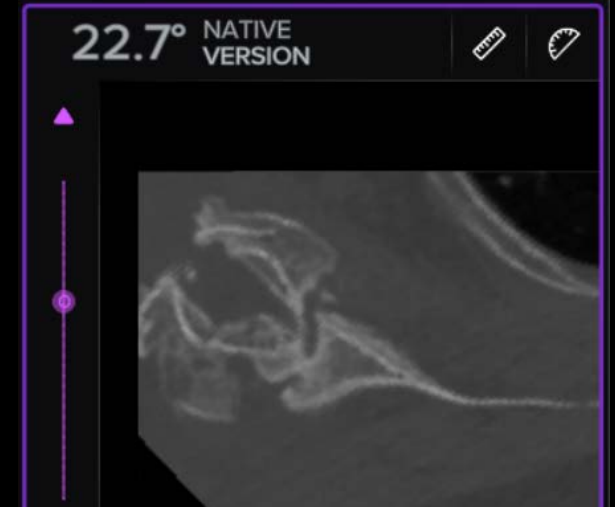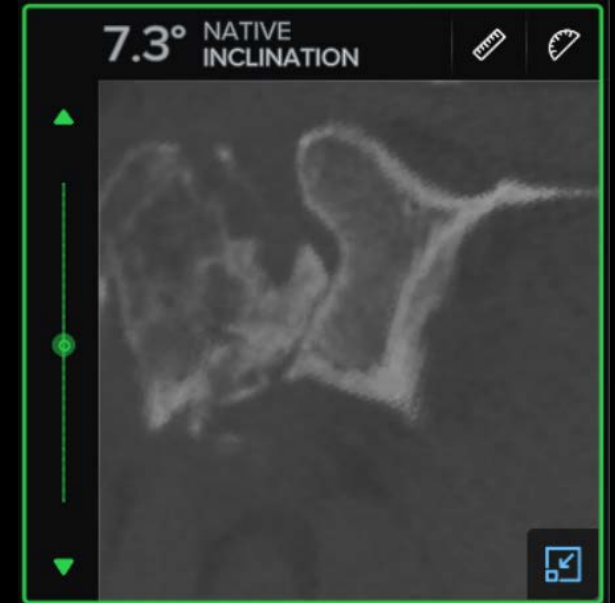

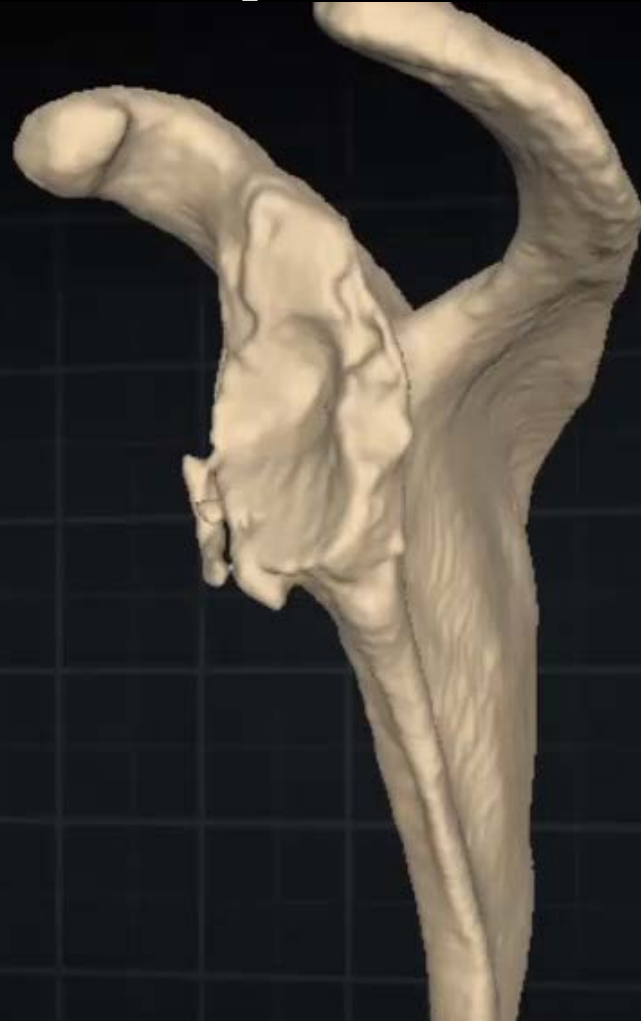
# Treatment of Proximal Humerus Fractures

## Complications

### ORIF

Malreduction  
AVN  
Screw Cut Out  
Glenoid Destruction  
Non-Union  
Malunion  
Infection

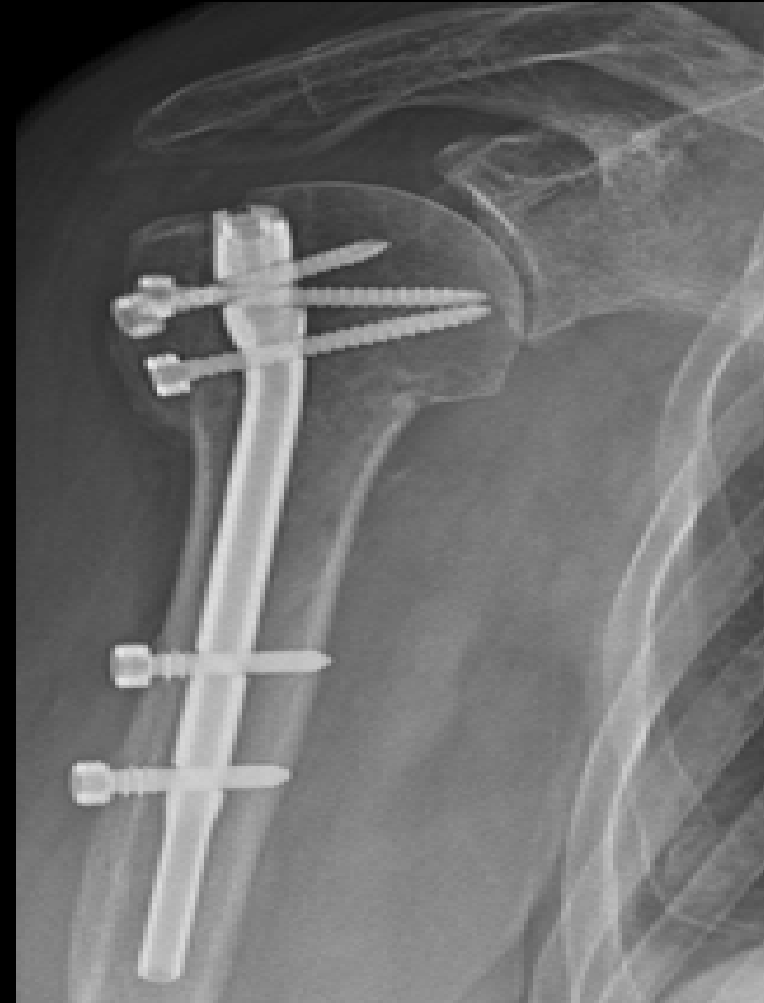

# Treatment of Proximal Humerus Fractures

## Optimizing Outcomes

### IM Nail

Next Gen Nail  
Avoid RC Insertion  
Surgical Technique





# Treatment of Proximal Humerus Fractures

## Complications

### IM NAIL

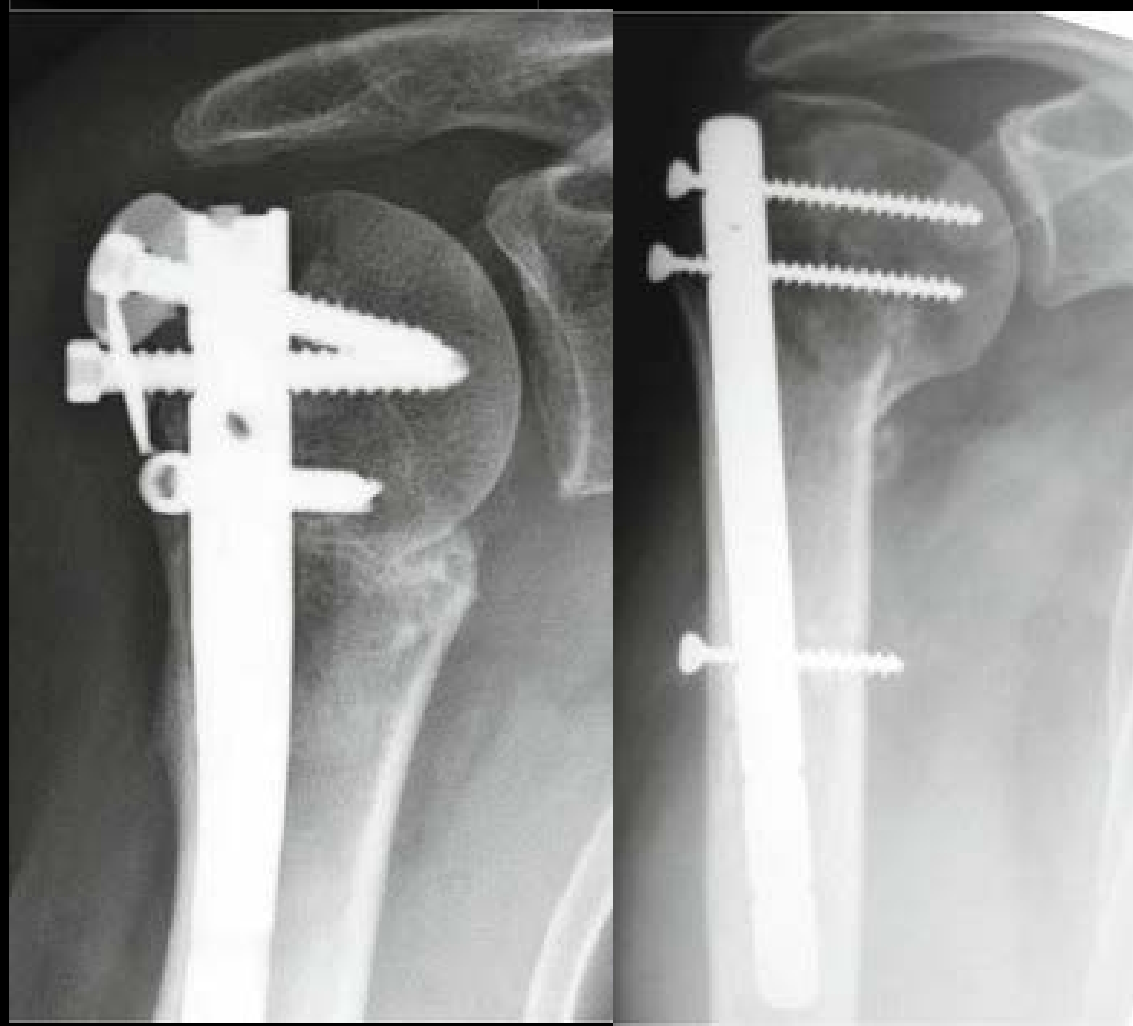
Malreduction

AVN

Rotator Cuff Tear

Non-Union

Malunion



# Treatment of Proximal Humerus Fractures

## Optimizing Outcomes

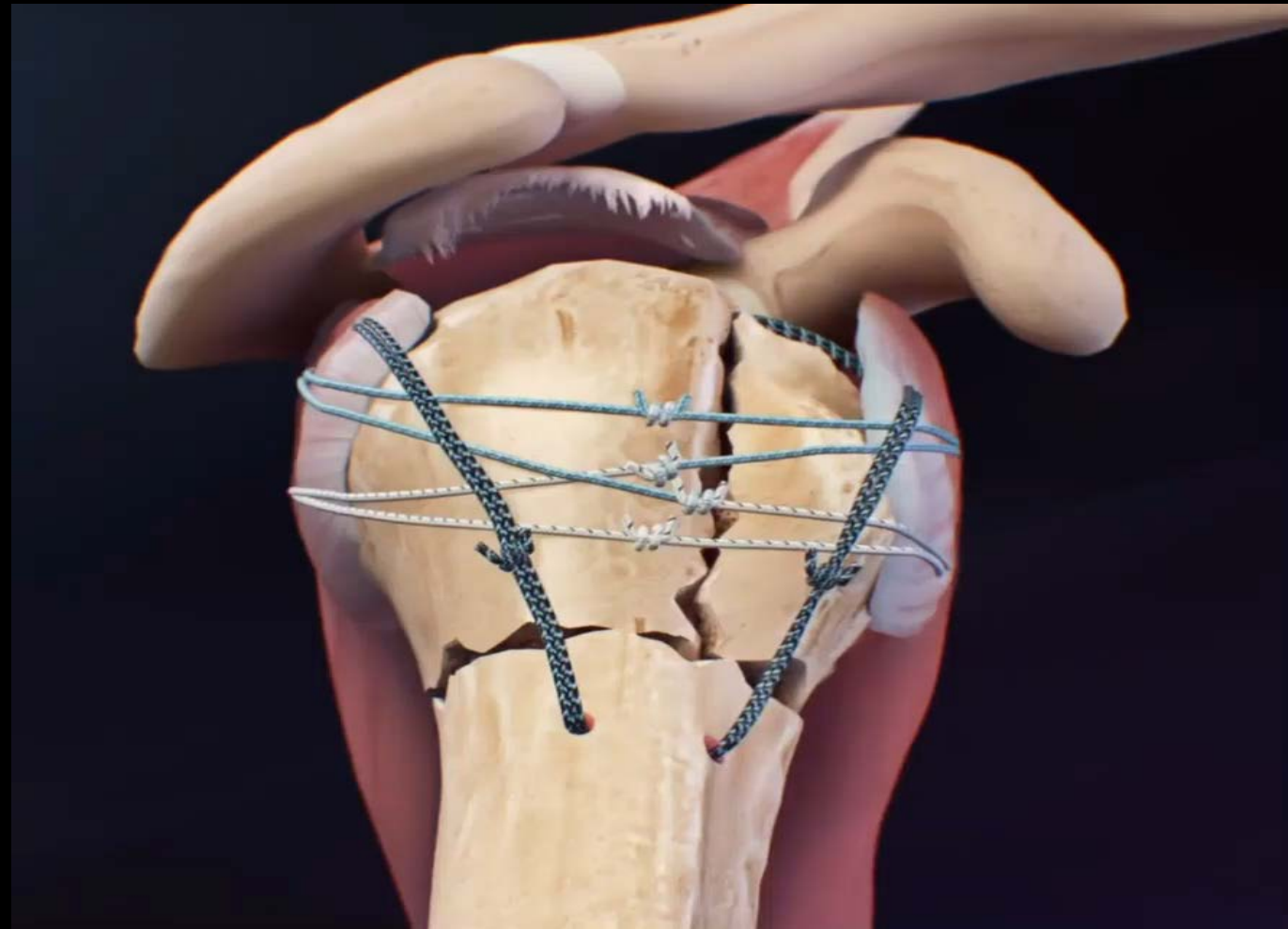
rTSA

Press Fit

135° Neck Shaft Angle

Tuberosity Repair

Bone Graft



# Treatment of Proximal Humerus Fractures

## Complications

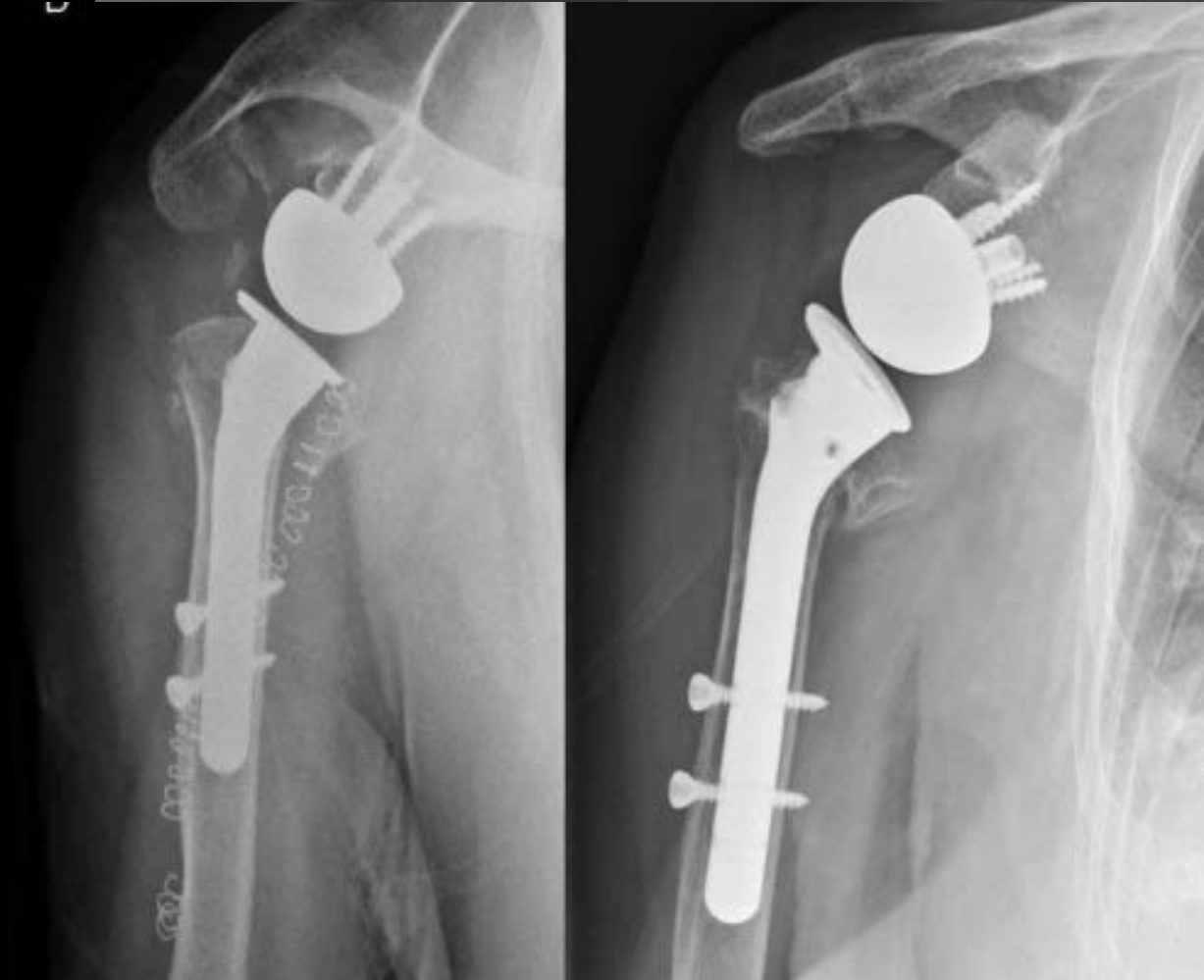
### Hemiarthroplasty & rTSA

Non-Union

Malunion

Tuberosity Resorption

Infection





# Treatment of Proximal Humerus Fractures



- A. Percutaneous Pin
- B. ORIF
- C. IM Nail
- D. Arthroplasty
- E. None of the Above





# Treatment of Proximal Humerus Fractures

- A. Percutaneous Pin
- B. ORIF
- C. IM Nail
- D. Arthroplasty
- E. None of the Above**





# Treatment of Proximal Humerus Fractures



Timothy J. Thompson, PA-C, MBA

