

Pearls of Pediatric Urology



Meredith Alley, PA-C
Children's Hospital of Philadelphia

Division of Urology





Disclosures

- I have nothing to disclose.



Learning Objectives

- At the conclusion of this session, participants should be able to:
 - Recognize common pediatric urologic conditions
 - Discuss how to accurately diagnose these
 - Identify appropriate treatment and referral for pediatric patients with common urologic diagnoses



Genitourinary Exam

- Child may be nervous
- Need for efficient and thorough exam
- Important to complete at well visits or if chief complaint indicates (exams can change)
- Consider chaperone for sensitive exams
 - Parent or other chaperone



Genitourinary Exam

- How to examine?
 - Laying down (and sometimes standing up)
 - Pants to ankles or removed
 - Privacy drape for older children/adolescents
 - Legs in frog-leg position
 - Often need assistance to hold legs

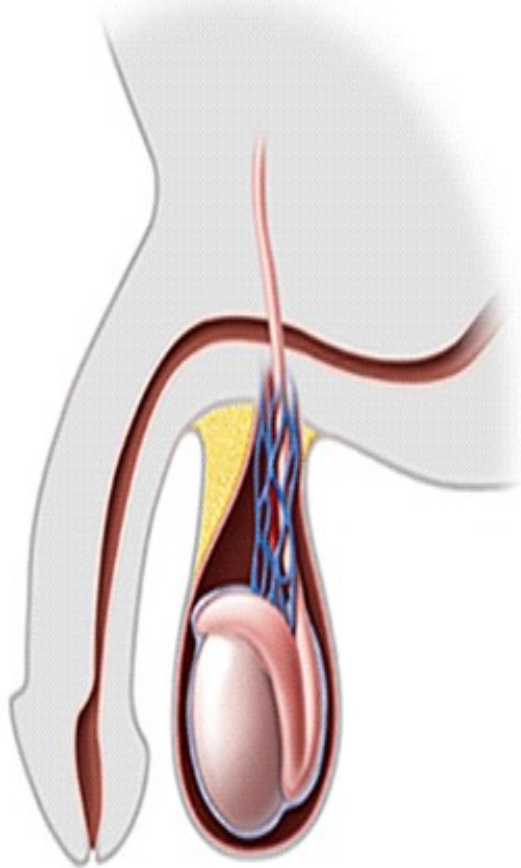


Groin Abnormalities: Male

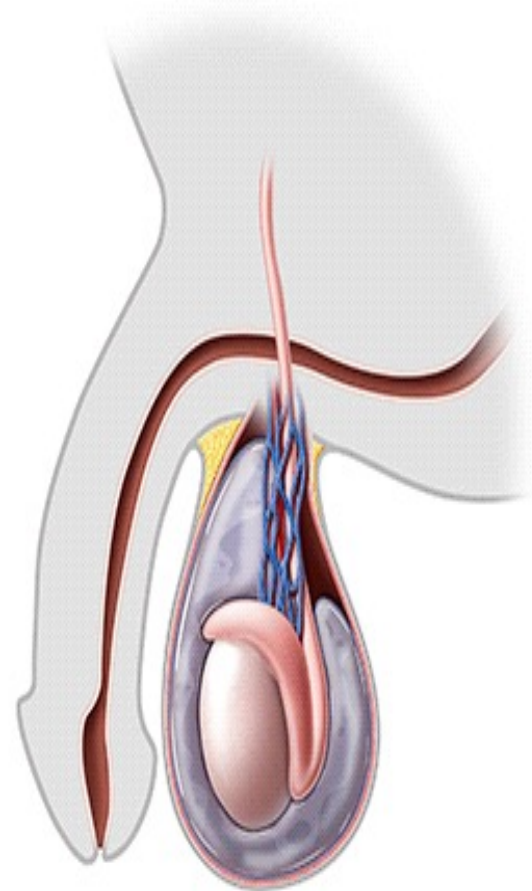
- Hydrocele
- Hernia
- Testes
 - Retractable Testes
 - Undescended Testes
 - Ascending Testes
- Varicocele



Normal Groin



Hydrocele



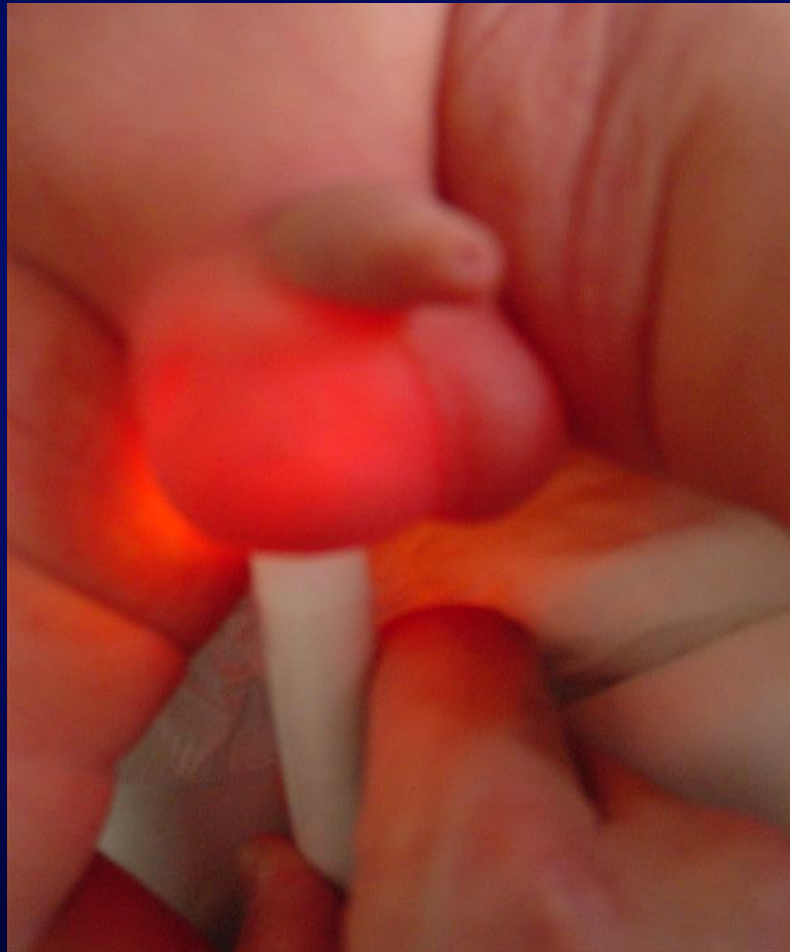


Non-communicating Hydrocele

- No connection to the peritoneum
- The fluid comes from the lining of the tunica vaginalis or may be trapped as testes descend
- Occurs mainly in the newborn period or in adolescence
- Can occur as a reactive hydrocele
- Abdominoscrotal hydrocele



Newborn Hydrocele





Non-communicating Hydrocele

- Physical Exam:
 - Swelling in the scrotum
 - Scrotum does NOT fluctuate in size
 - Fluid cannot be reduced
 - Often tense to palpation



Non-communicating Hydrocele

- Can occur in adolescents
 - Unilateral or bilateral scrotal swelling
 - Usually painless
 - Can gradually enlarge

- Rate of secretion of fluid $>$ reabsorption



Non-communicating Hydrocele

- When to refer:
 - Hydrocele persists past a year of age
 - Testis is not palpable
 - Scrotal size continues to increase
 - Adolescent complains of discomfort or is bothered by appearance
- Ensure not a mass

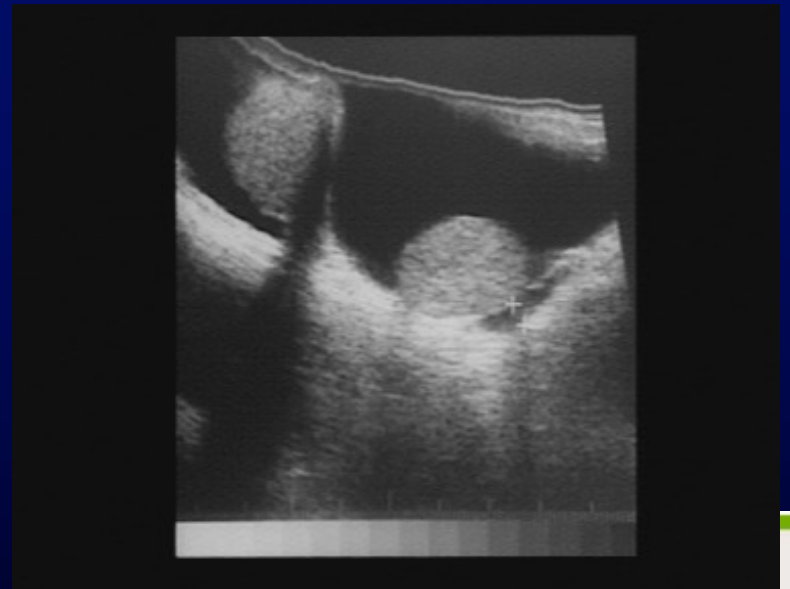
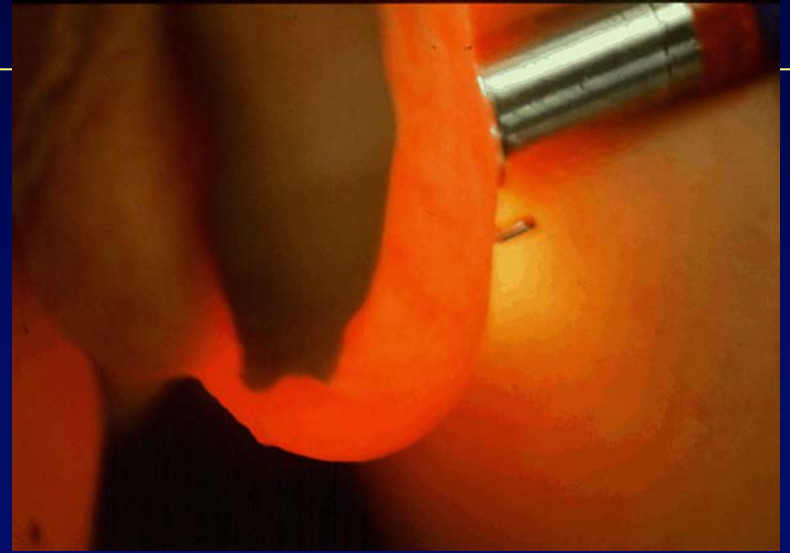
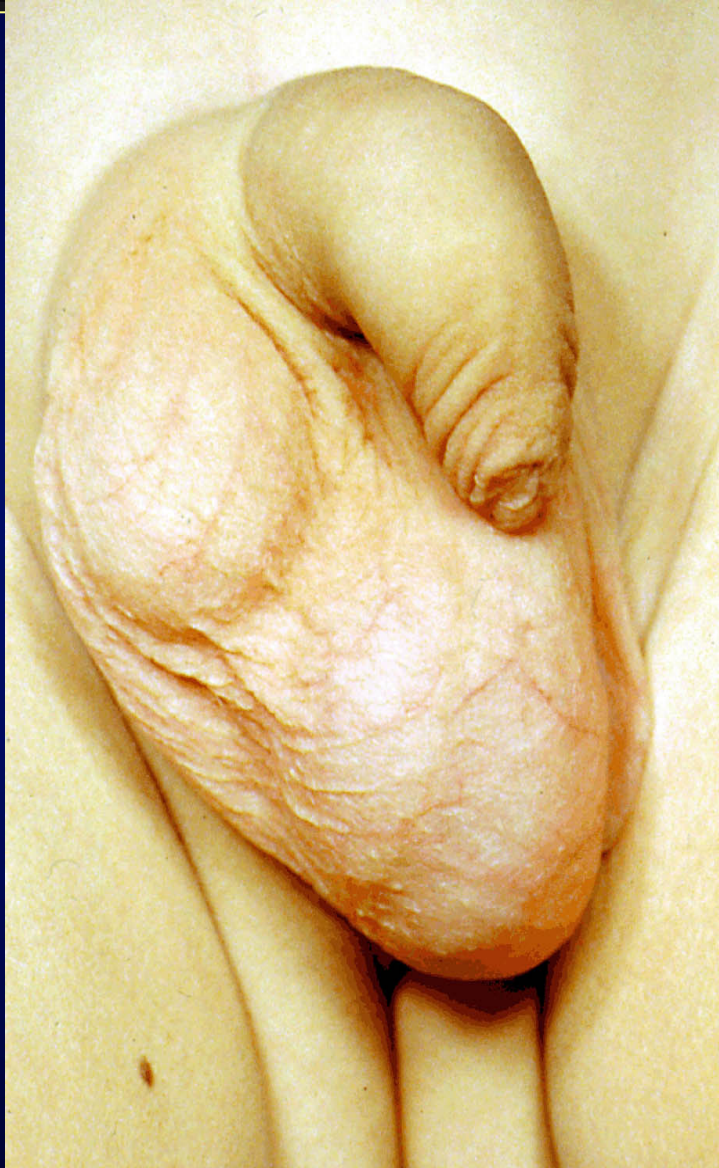

Communicating hydrocele

- Persistence of patent processus vaginalis
- Processus vaginalis typically closes after testes descend into scrotum



Hydrocele





Communicating Hydrocele

- Physical exam:
 - Examine patient laying down and standing up/valsalva
 - Fluid can often be decompressed
 - Silk glove sign
- A scrotal ultrasound is NOT routinely recommended



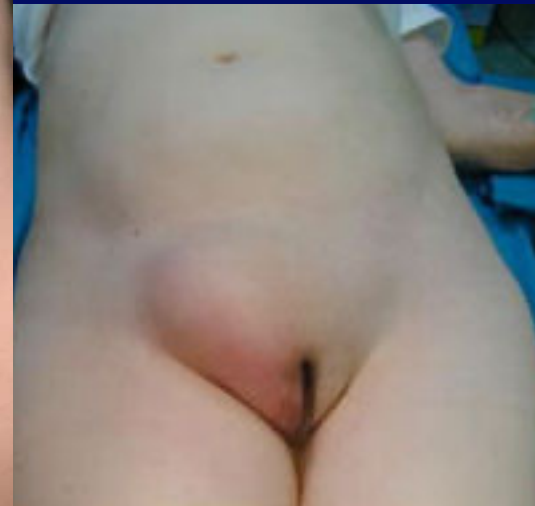
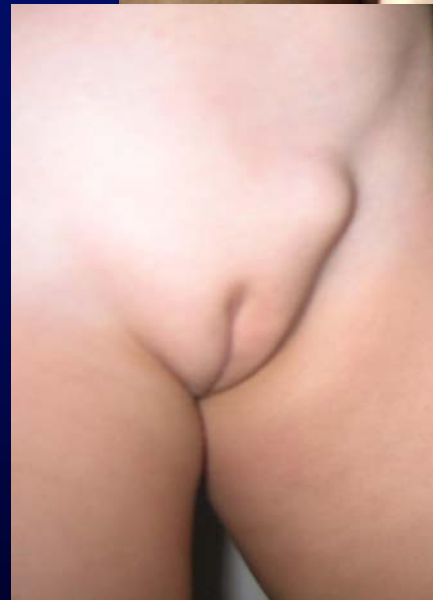Communicating Hydrocele

- Risks:
 - Incarcerated/strangulated hernia
 - Higher risk in emergency situation
- Recommend hernia/hydrocele repair



Inguinal Hernia

- Bulge in groin
- Unilateral or bilateral
- Increased risk in preemies





Inguinal Hernia

- Can occur in males and females
- Occurs most often in males
- If bilateral in females- feel for palpable gonads/pelvic US

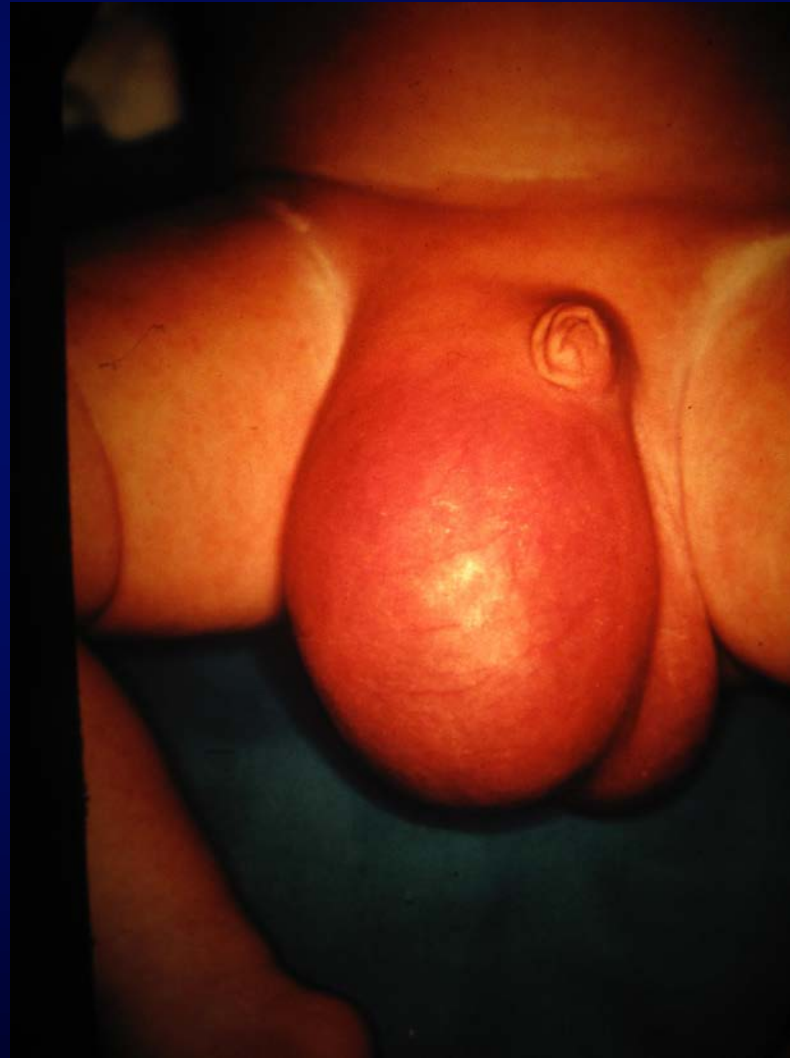

Incarcerated/Strangulated Hernia

- Hard bulge in groin
- Painful
- Infant inconsolable
- At risk for losing bowel and testicle
- If not reducible, requires emergent surgery



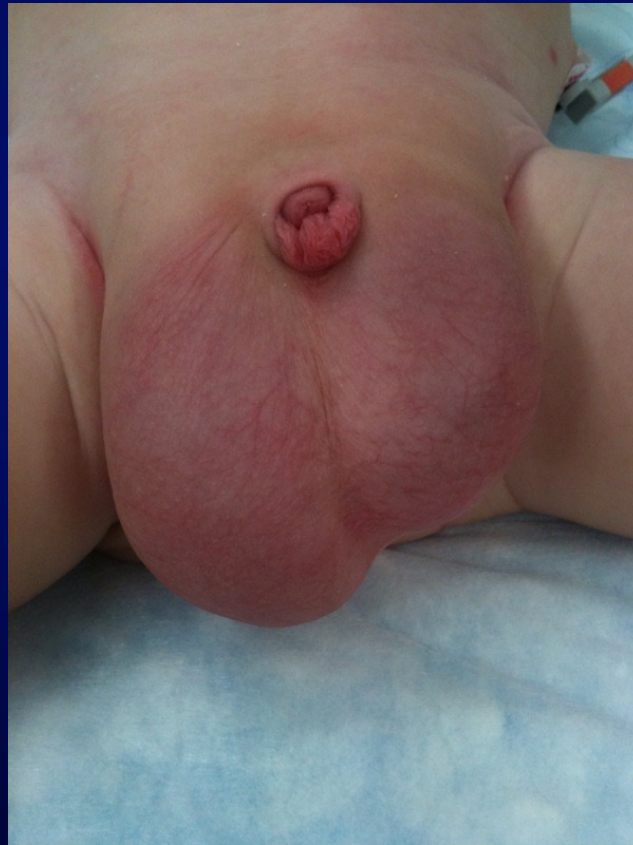Incarcerated Inguinal Hernia





Abdominoscrotal Hydrocele

- Large scrotal hydrocele that extends into abdomen without communication with peritoneum





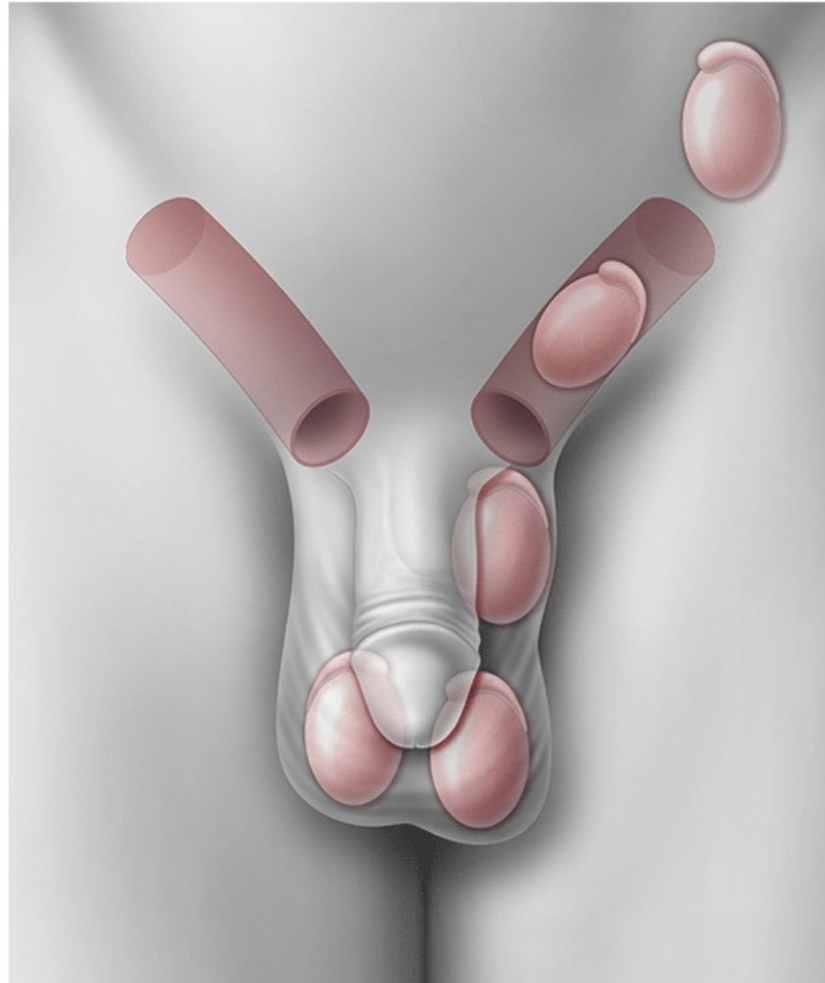
Descent of Testes

- Testicular descent occurs
 - 28-40 weeks gestation
- If testis not fully descended at birth, may descend by six months adjusted age



Location of Testis

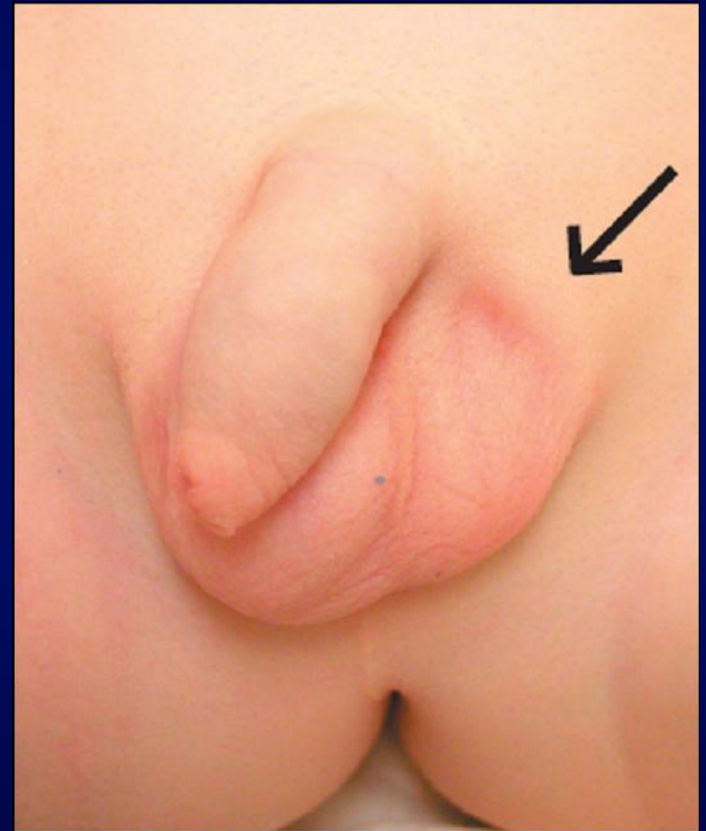Undescended Testes





Undescended Testis

- Usually diagnosed at birth
- Sometimes delayed diagnosis or delayed referral
- Hypoplastic scrotum



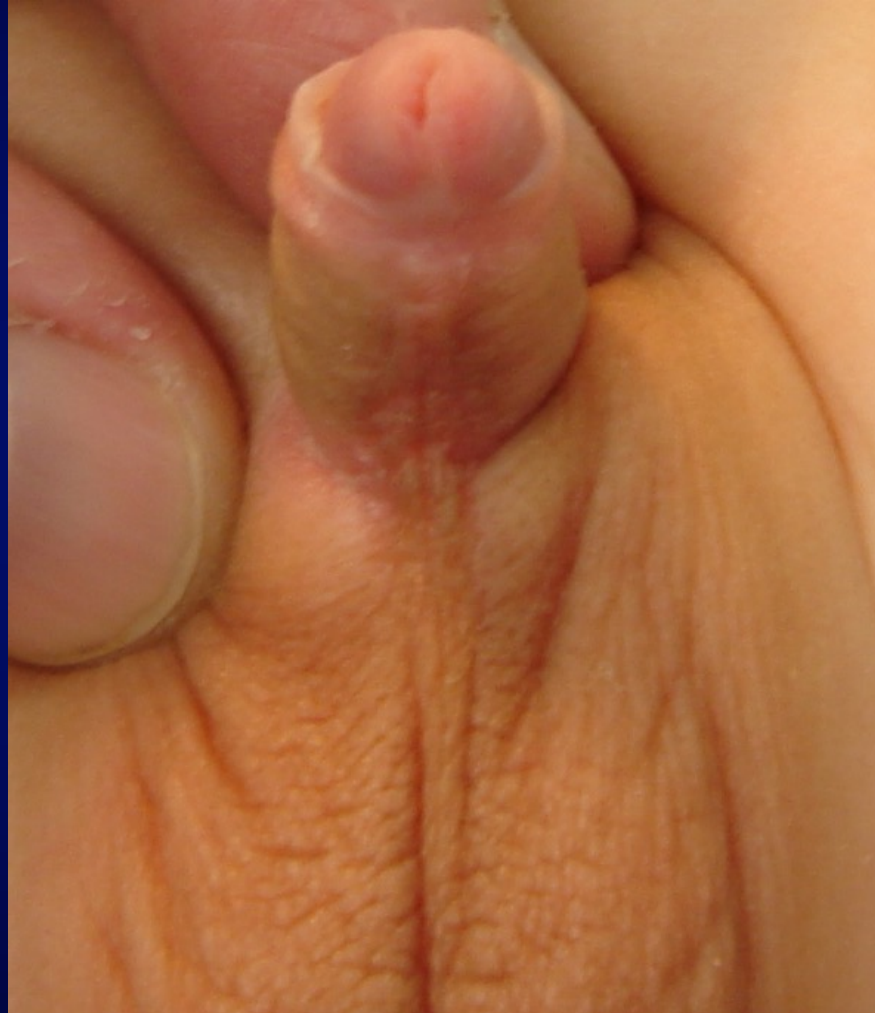

Undescended Testes

- Undescended palpable
- Undescended non-palpable
 - could be in abdomen
 - could be testicular nubbin
- If bilateral non-palpable testes---needs work-up for DSD/urology consult



Bilateral Non-palpable Testes





AUA UDT Guidelines (2014, confirmed 2018)

- Palpate testes for quality and position at each recommended well-child visit
- Refer infants with history of cryptorchidism if not descended by six months (corrected for gestational age)
- Should not perform ultrasound in evaluation of boys with cryptorchidism prior to referral



AUA UDT Guidelines

- Retractable testes should be monitored at least annually to monitor for secondary ascent
- Should not use hormonal therapy to induce testicular descent
- In absence of testicular descent by six months, surgery within the next year
- Should counsel boys with hx of UDT regarding potential long-term risks and education on infertility and cancer risk



Undescended Testes

- Physical Exam:
 - Exams can be difficult- laughing/tense/cold child
 - Look before physical exam
 - Trap testes at inguinal inlet
 - Liquid hand soap can help locate testis
 - Testis can “pop” under fingers



Retractile Testis

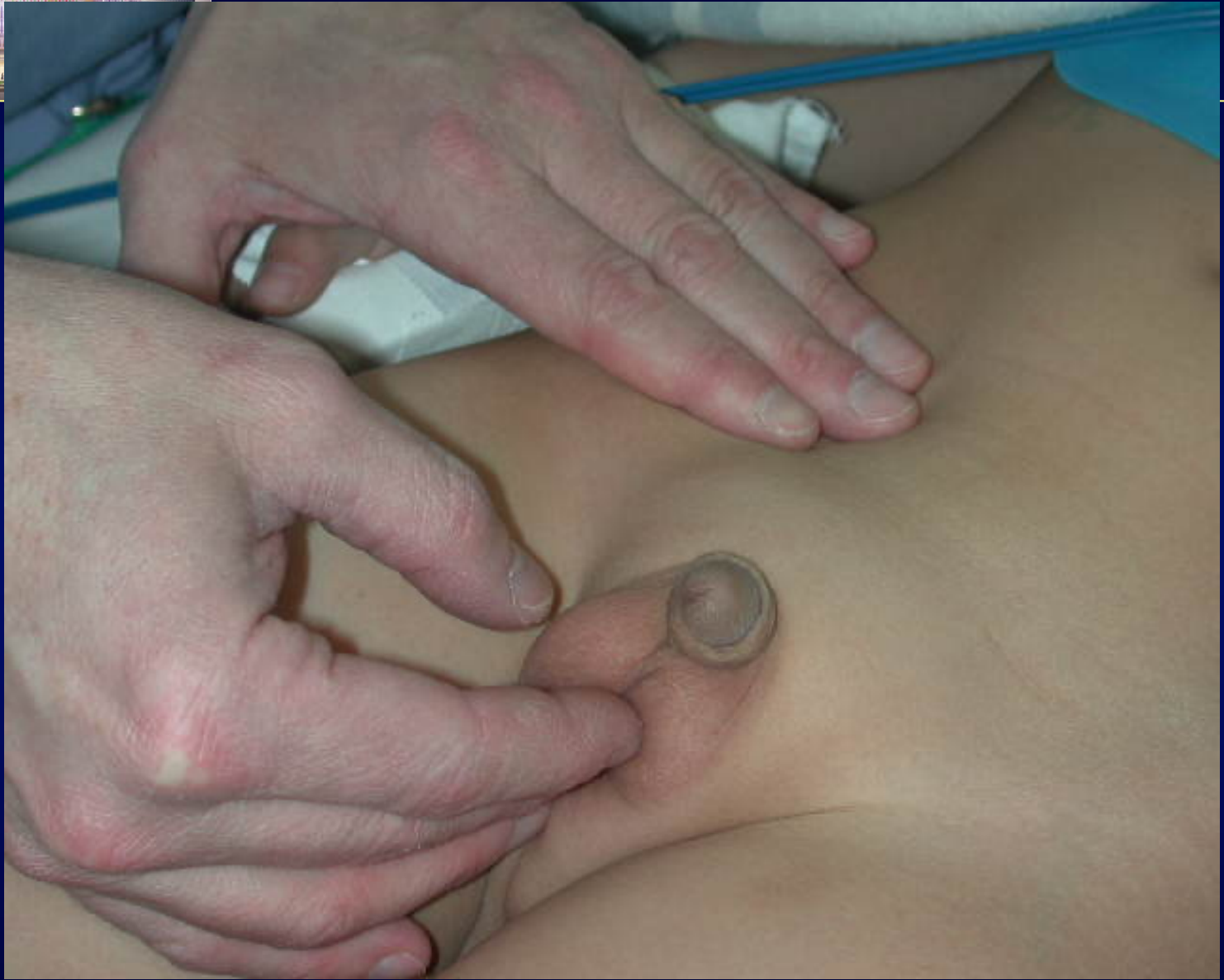- Cremasteric reflex controls position of testis
- Fight or flight response
- Elicited when cold/anxious/on examining room table
- If retractile, then testes stay in scrotum once cremaster muscle is relaxed/fatigued



UDT vs Retractable Testis

- Catcher's position
- Criss-cross applesauce
- Frog-legged position







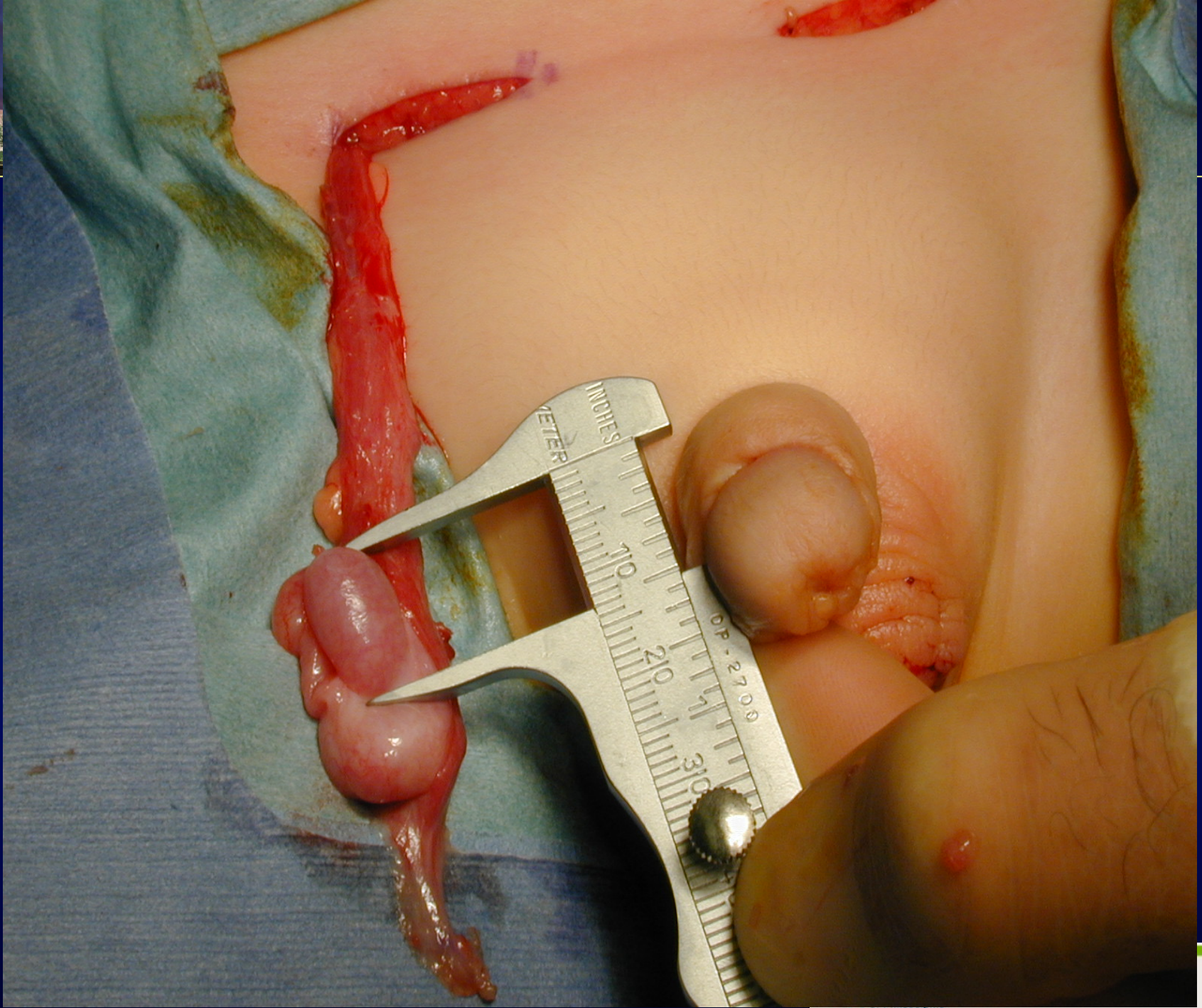
Undescended Testes

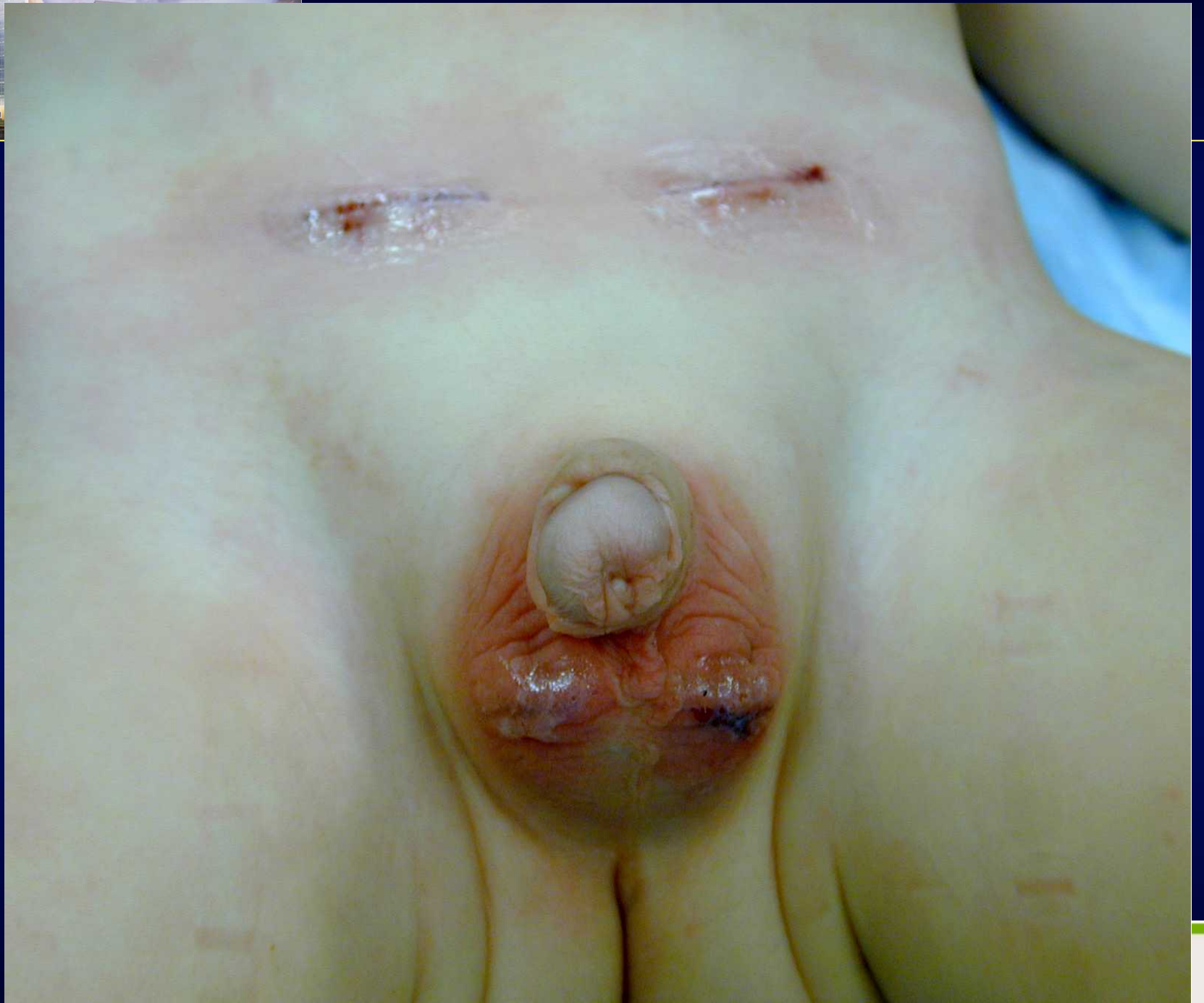- Refer if testis not descended by 6 months of age (adjusted)
- UDTs associated with:
 - Abnormal semen analysis
 - Testicular cancer
 - Inguinal hernia



Undescended Testes

- Surgery (orchiopexy with possible hernia repair) recommended
 - Testis develop as normally as possible
 - Testis can be palpated for testicular self exam



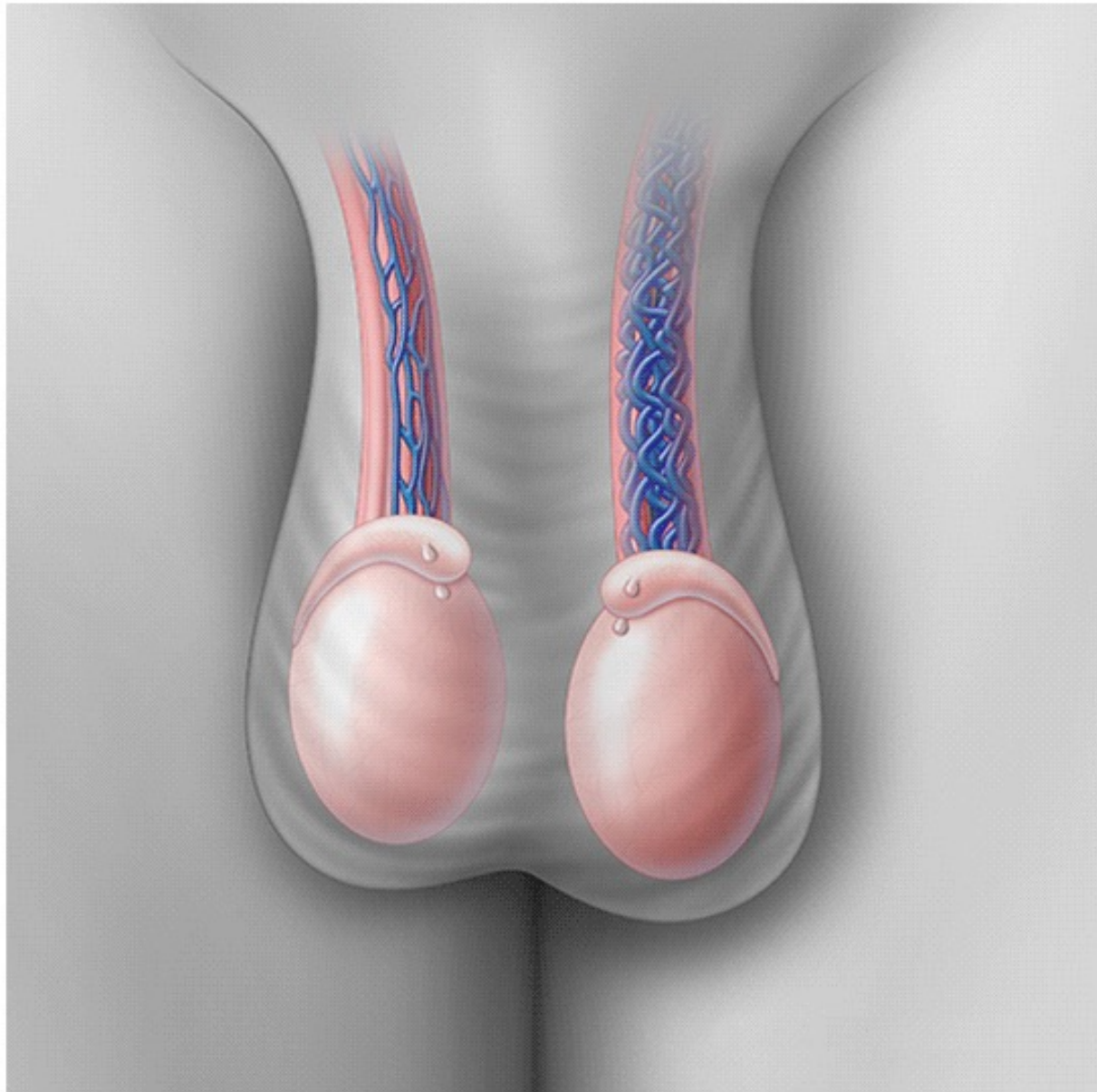




Ascending Testis

- Testis previously palpated in the scrotum
 - no longer able to be palpated
- Usually occurs during growth spurt (often age 8-10 years)
- Should be treated as undescended testis

Variocoele





Varicocele

- Dilated pampiniform plexus
- Usually on left side
- Often in tall/skinny males
- Approximately 10-15% incidence in adolescent boys
- Can be bilateral (if right only, especially if does not decompress, consider retroperitoneal mass)



Varicocele

- Physical Exam
 - Palpated with the patient standing and then supine (should decompress)
 - “Bag of worms”
 - Usually asymptomatic
 - Graded from 1 to 3



Varicocele





Varicocele

- 10-15 % of men have a varicocele
- Up to 40% of men presenting for infertility work-up have a varicocele
- Majority of men with a varicocele do not have an issue with fertility
- Need to treat the small percentage that do
- Semen analysis and hormonal work-up
- Can address surgically with varicocelectomy or embolization



Acute Scrotum

- Torsion of testis
- Torsion of appendix testis
- Scrotal trauma
- Incarcerated/strangulated hernia



Testicular Torsion

- Bimodal age distribution---neonatal torsion and adolescent torsion
- Can occur antenatally or soon after birth
- Baby can have bruised/purplish hemiscrotum
- Needs emergent scrotal US

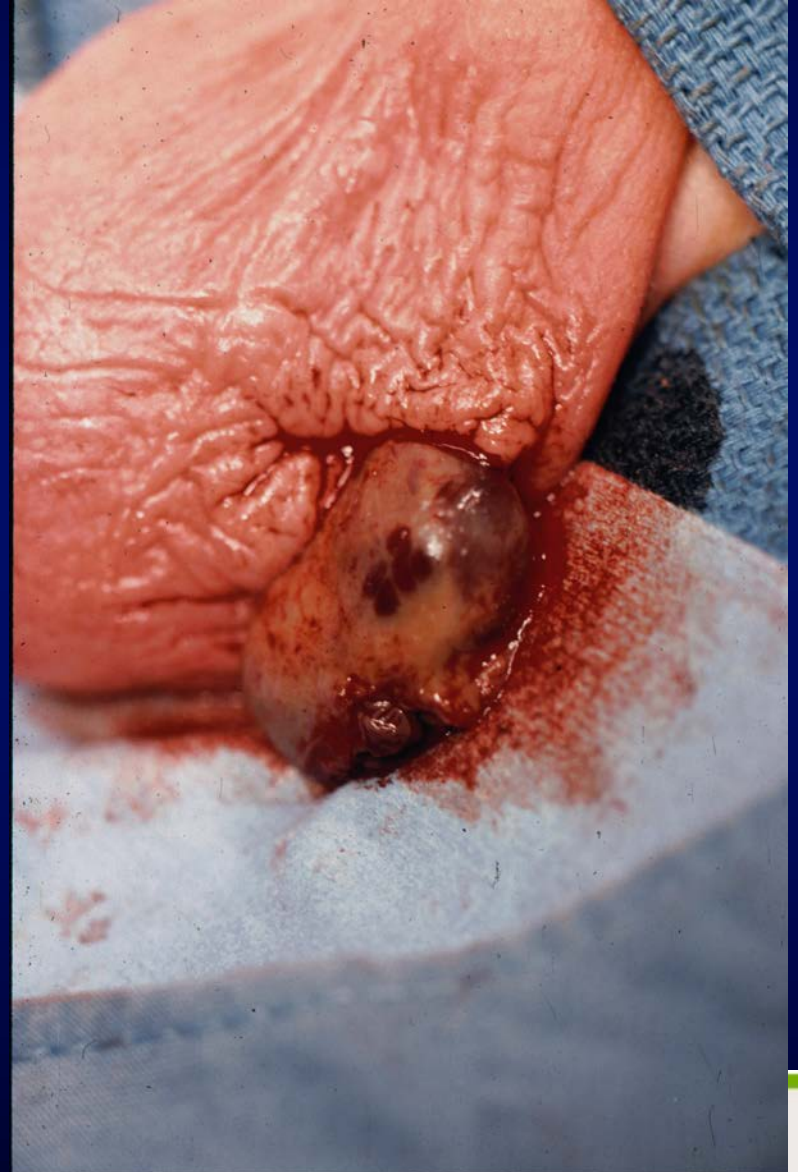
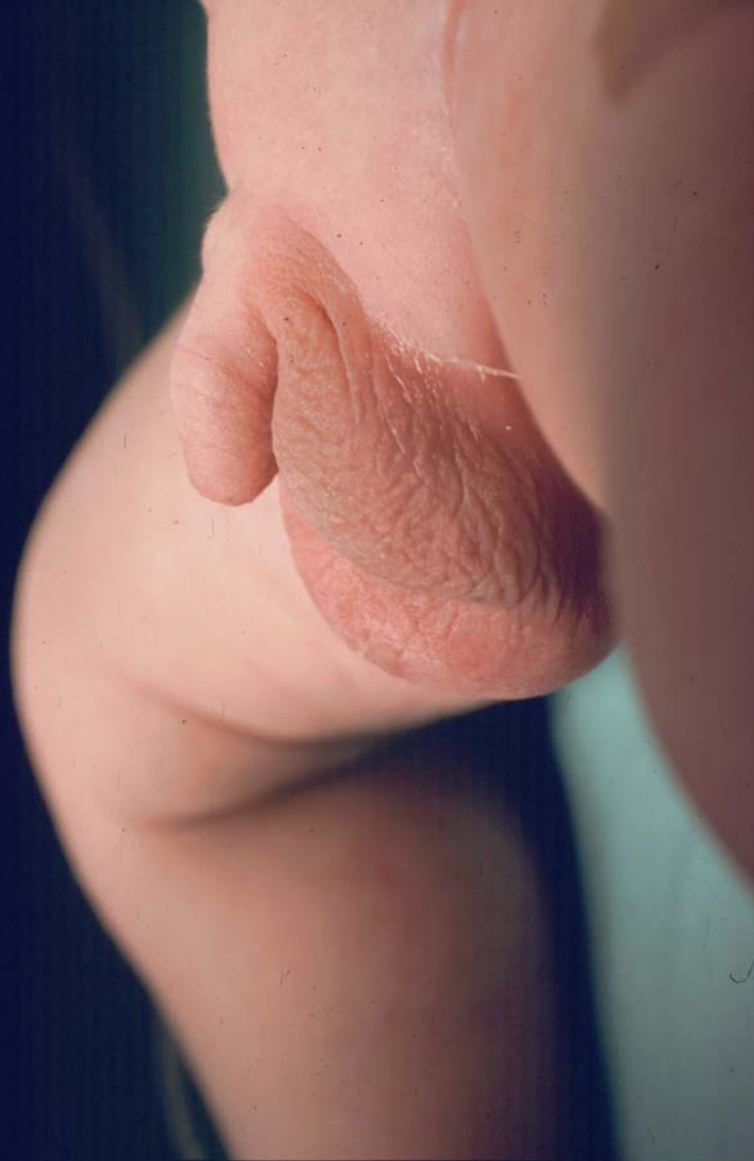
Testicular Torsion

- Ultrasound confirms lack of blood flow
- Sometimes testis already appears very echogenic depending on when the torsion occurred



Newborn Torsion



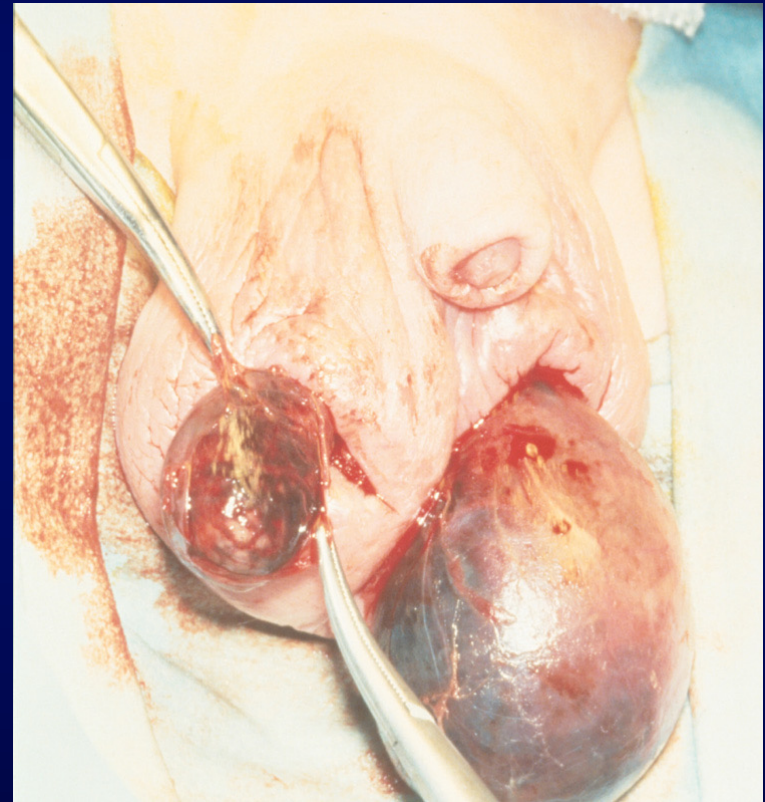
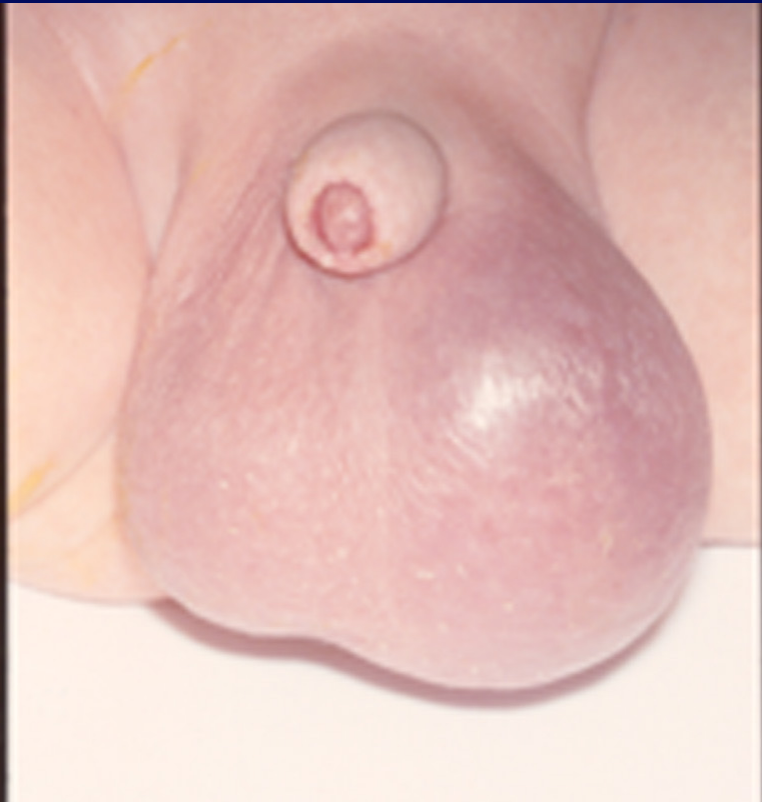
Newborn Torsion

- Treatment controversial
- Risk of metachronous torsion
- Anesthetic risk



Bilateral Neonatal Torsion

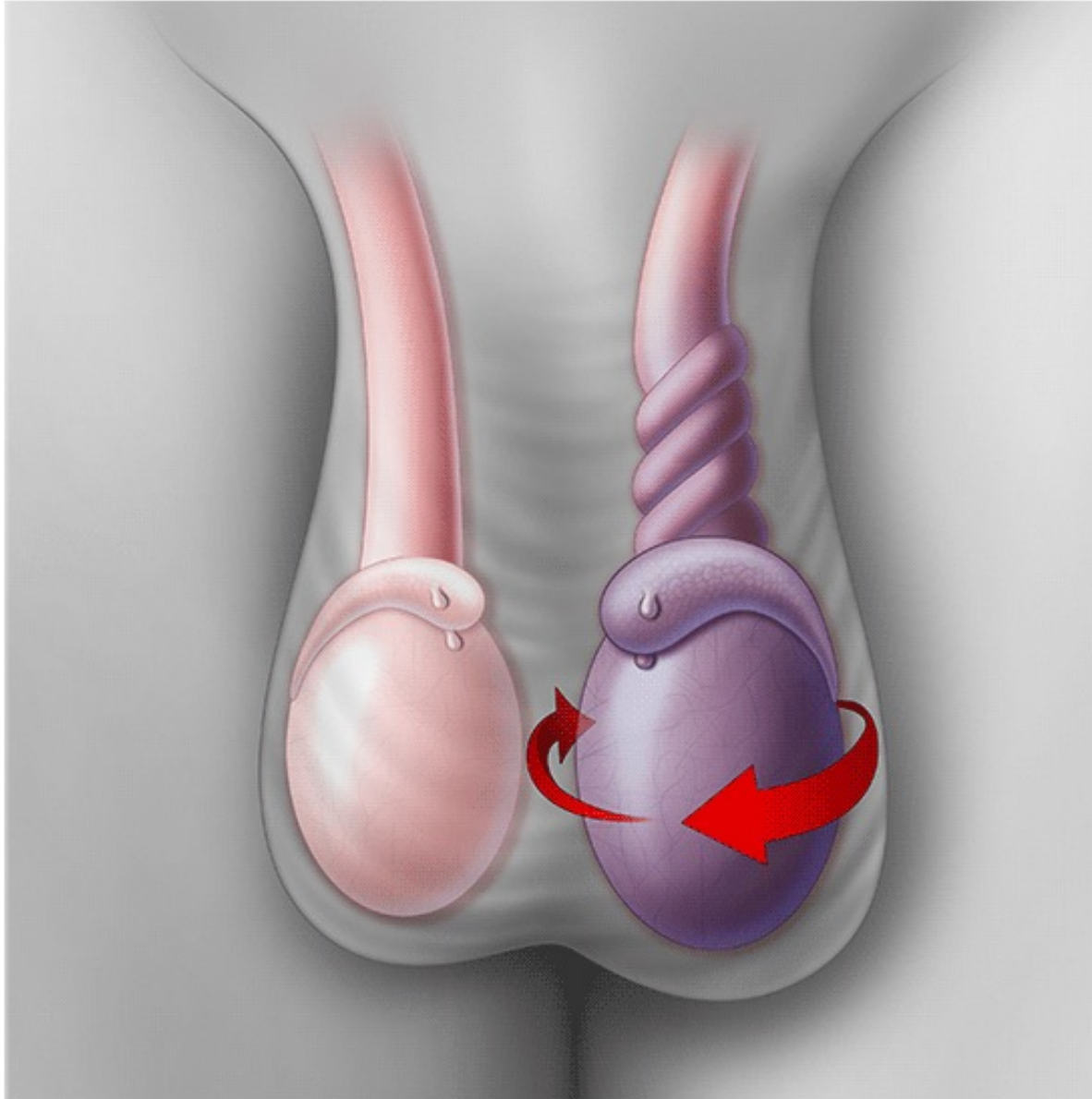




Testicular Torsion

- Occurs mainly in adolescents
- Present with unilateral significant scrotal pain, usually acute onset/can wake from sleep
- Pain can radiate to groin/abdomen
- Nausea/vomiting

Torsion





Testicular Torsion

- Physical Exam:
 - Testis can be high-riding/horizontal lie
 - Scrotal edema/erythema
 - No cremasteric reflex
 - If adolescent male complains of abdominal pain, scrotal exam is prudent



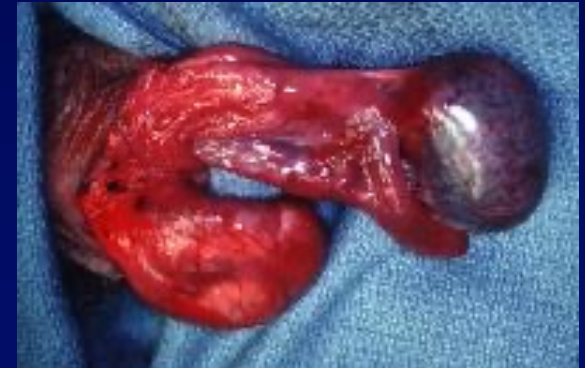Testicular Torsion

- An adolescent male with acute onset scrotal pain has suspected testicular torsion until proven otherwise, needs scrotal US with Doppler
- Do not typically recommend manual detorsion




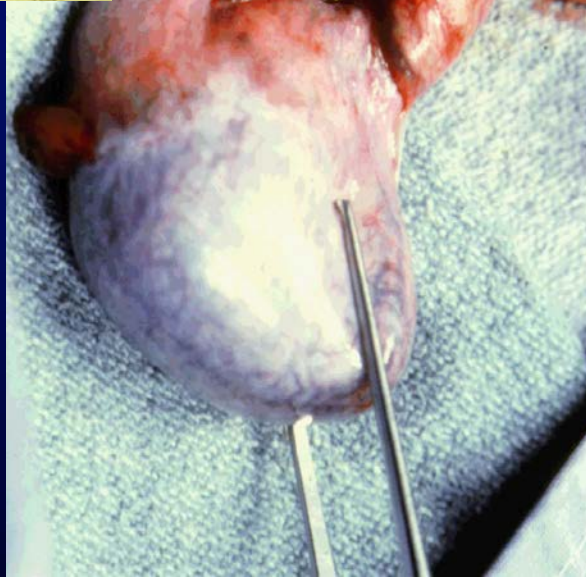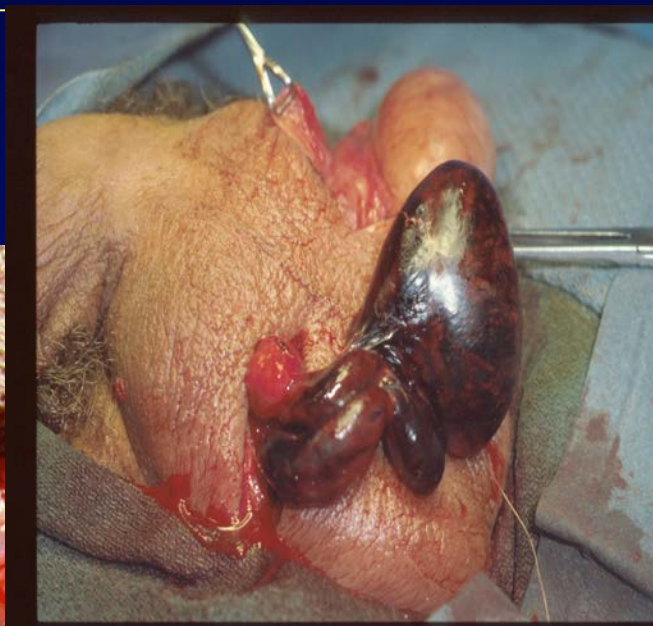
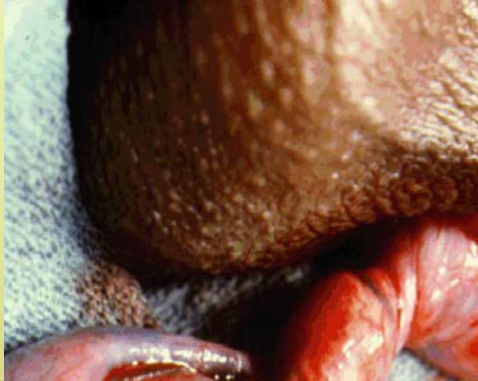
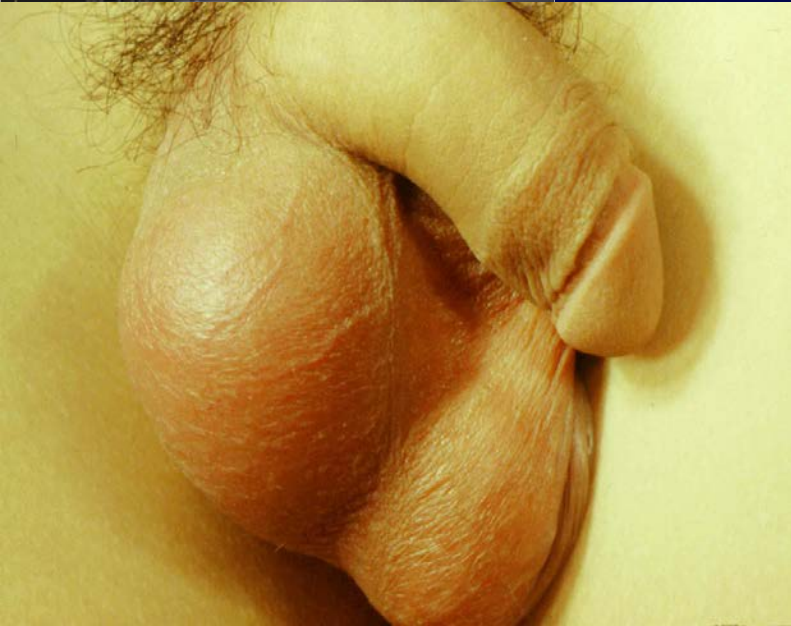Testicular Torsion

- 1 in 4,000 males <25yrs
- Time is of the essence
 - Salvage rates:
 - 90% <6hrs
 - 50% <12hrs
 - <10% >24hrs
 - Irreversible ischemic injury can occur after 4 hrs





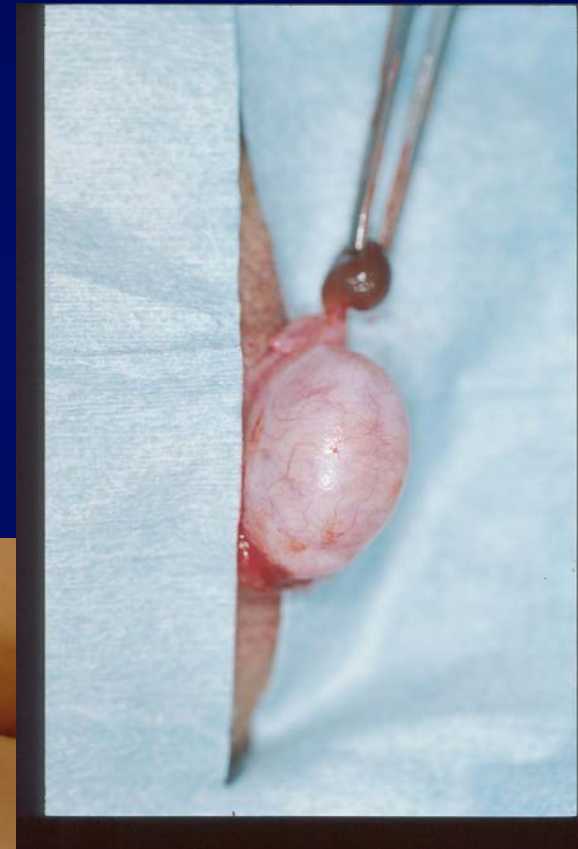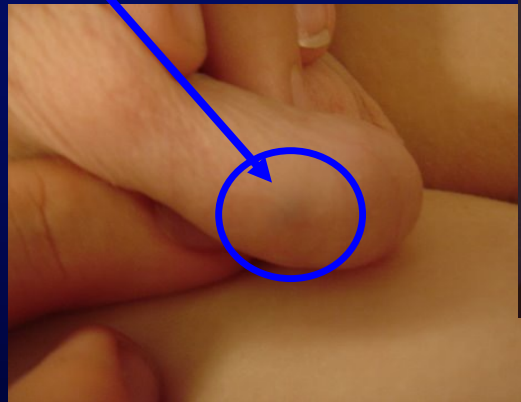
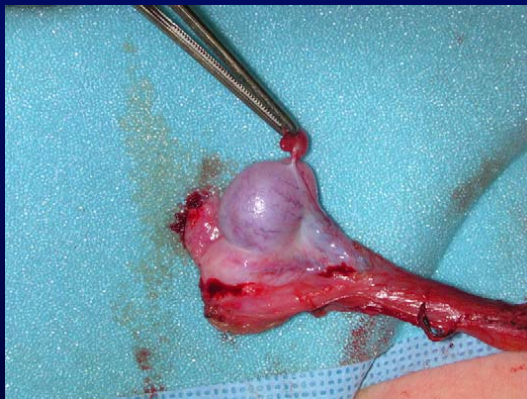Testicular Torsion





Torsion of Appendix Testis

- Torsed appendix testis
 - Vestigial müllerian remnant which twists, loses blood supply
 - Often misdiagnosed as epididymitis based on scrotal US findings
 - “Blue dot” sign
 - Point tenderness/walk like a cowboy



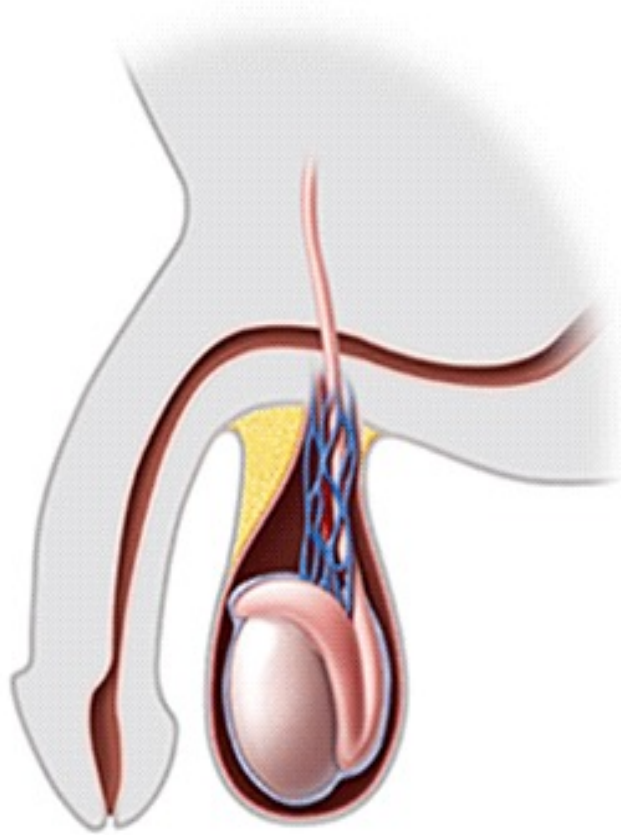


Torsion of the Appendix Testis

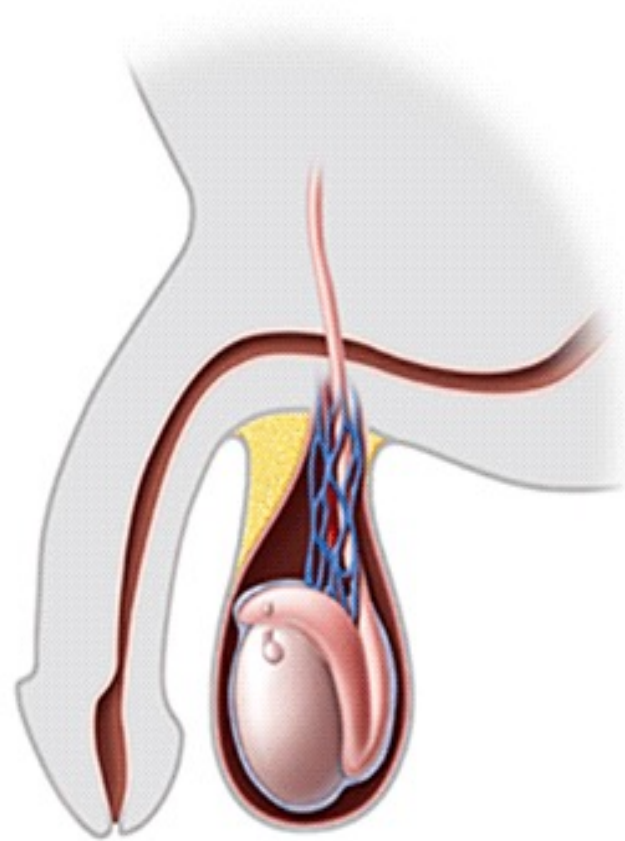
- Less severe pain
- Usually has gradual onset
- Pain worse with movement
- Usually no nausea/vomiting
- Cremasteric reflex is PRESENT



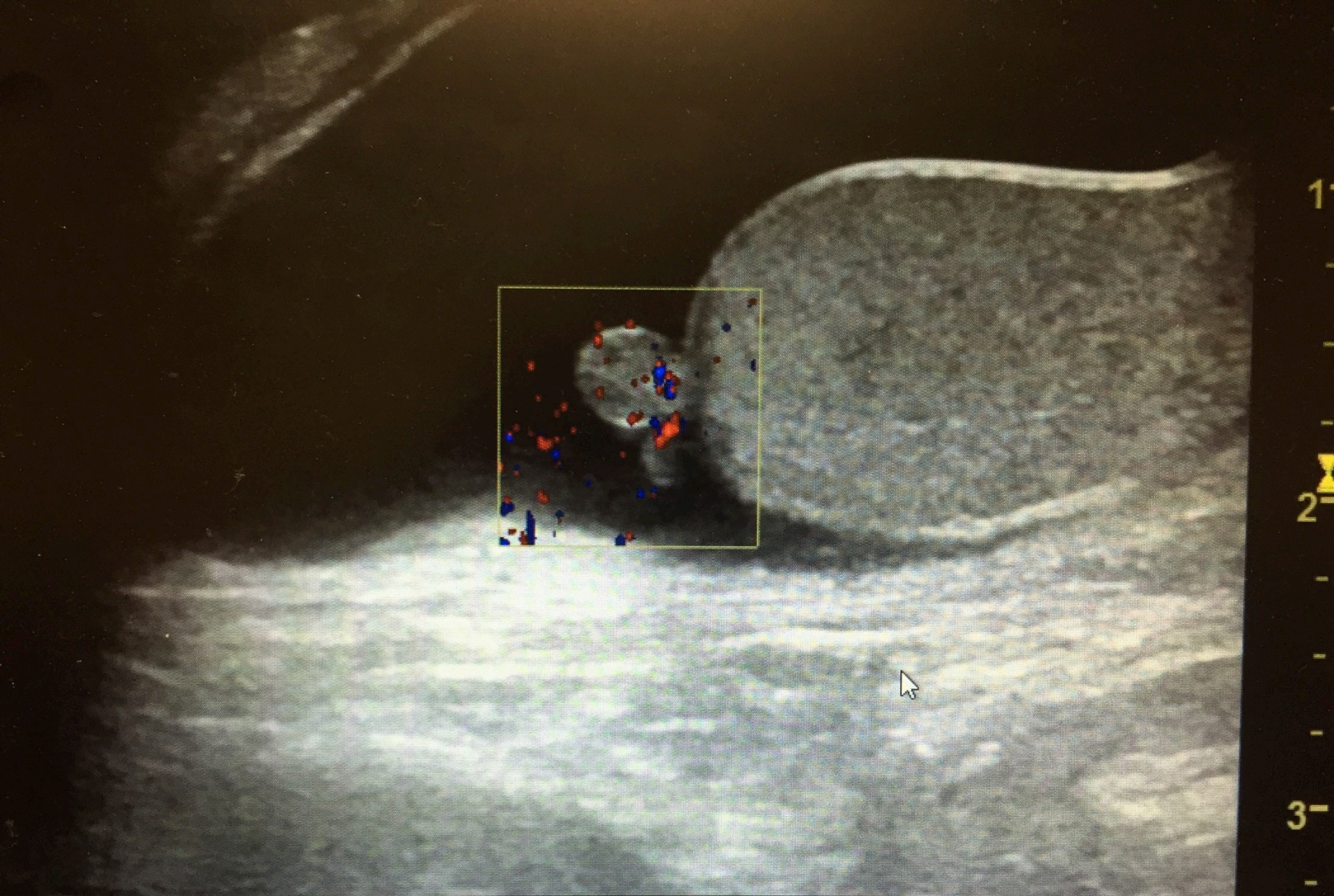Normal Groin



Torsion of the Appendix Testis



© 2014 The Children's Hospital of Philadelphia



RT EPIDIDYMIS SAG



Torsion of Appendix Testis

- Usually self-limited
- Treatment is rest and ibuprofen
- If recurs then can surgically remove bilateral appendix testes/appendix epididymi
- Scrotal US often will show normal Doppler flow to testis, scrotal wall edema/hyperemia of epididymis

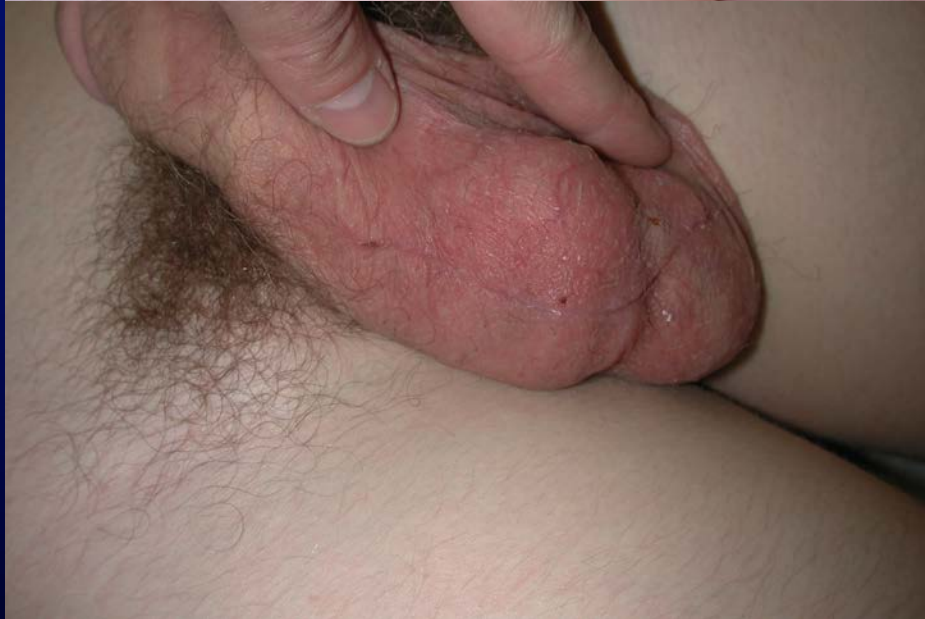
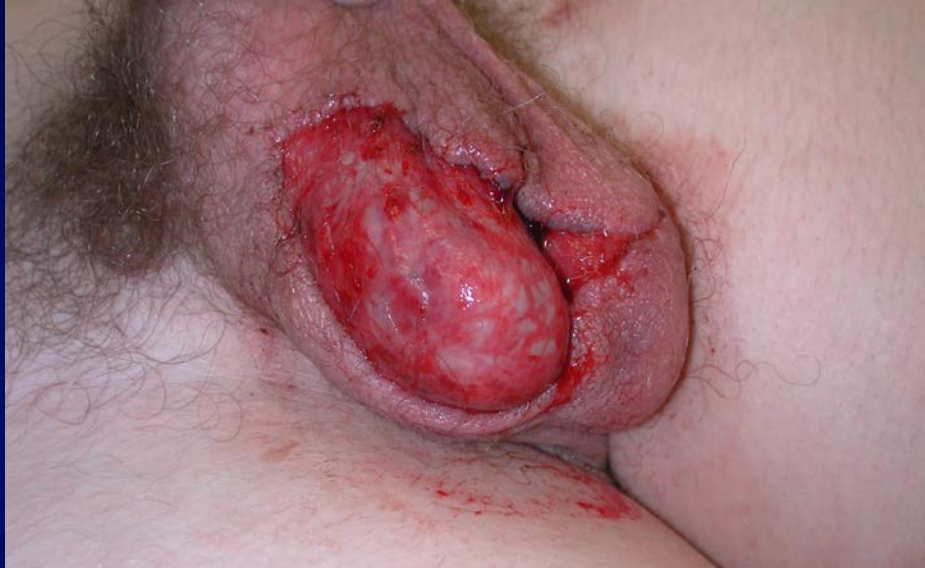
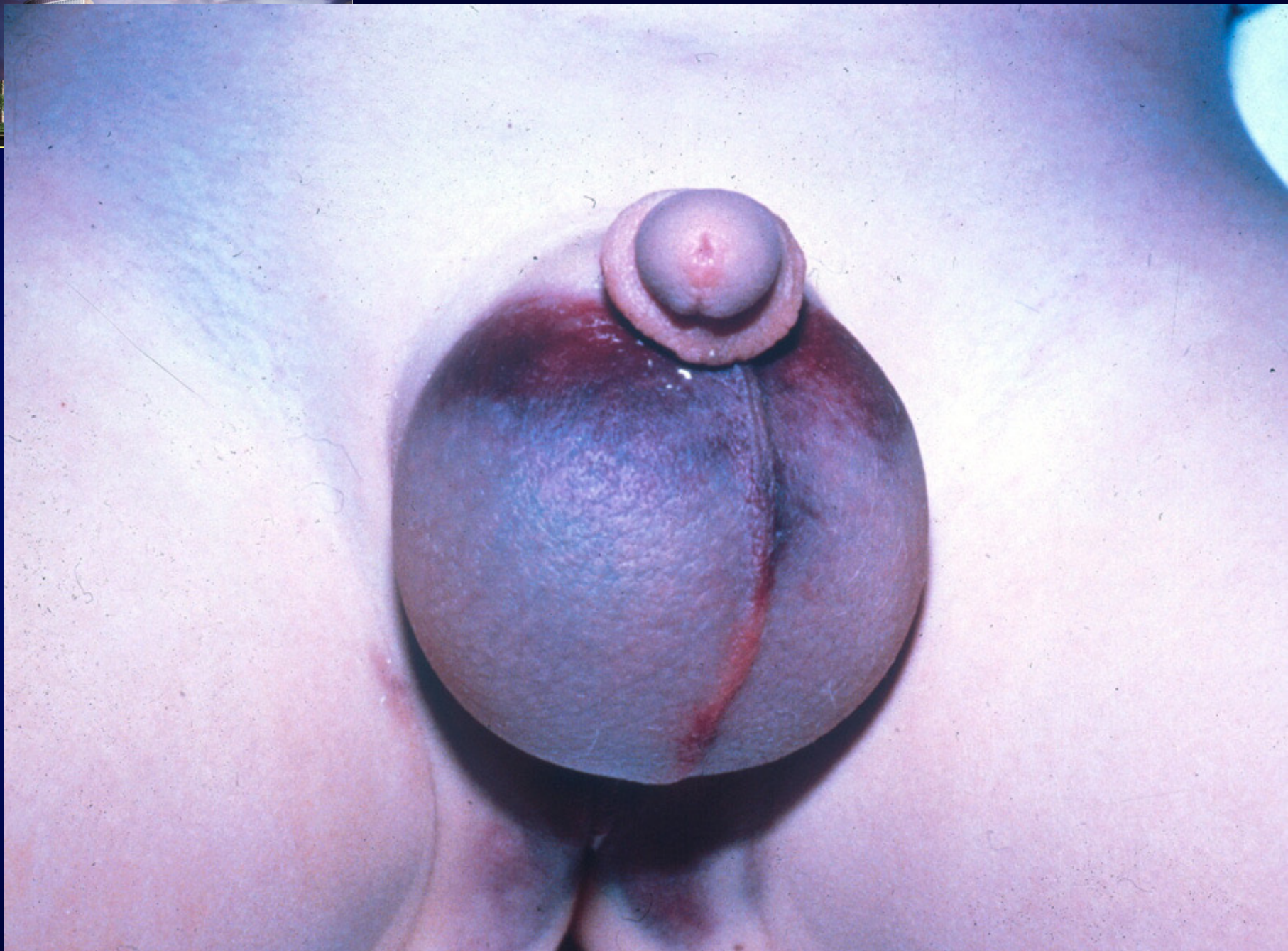Scrotal Trauma

- Determine degree of trauma:
 - Scrotal skin only (disruption or degloving)
 - Hematoma
 - Testicular rupture



Scrotal Degloving

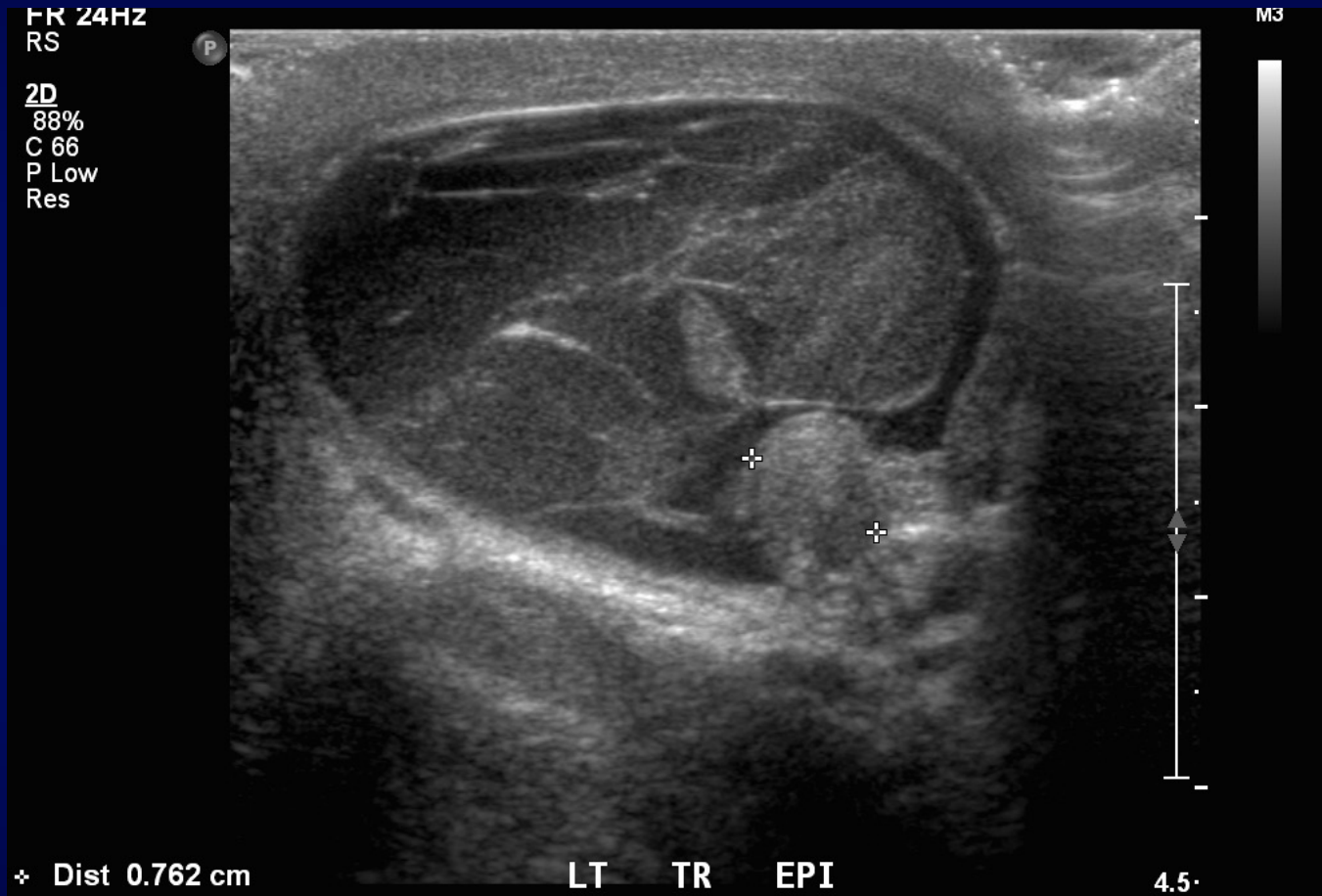






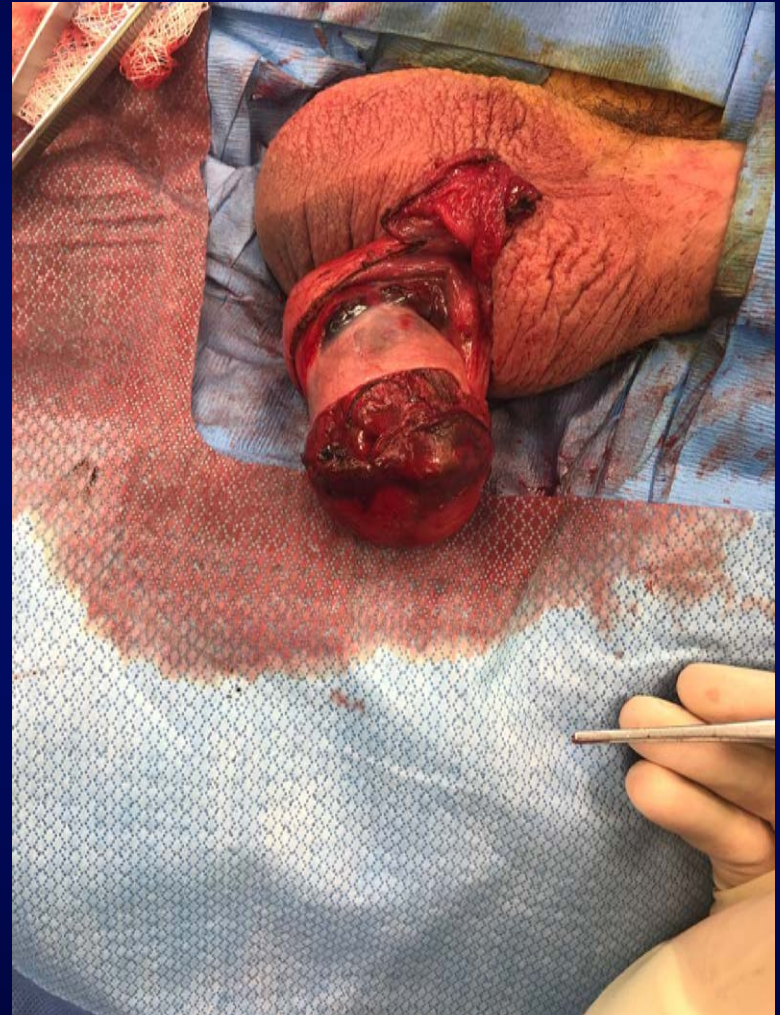
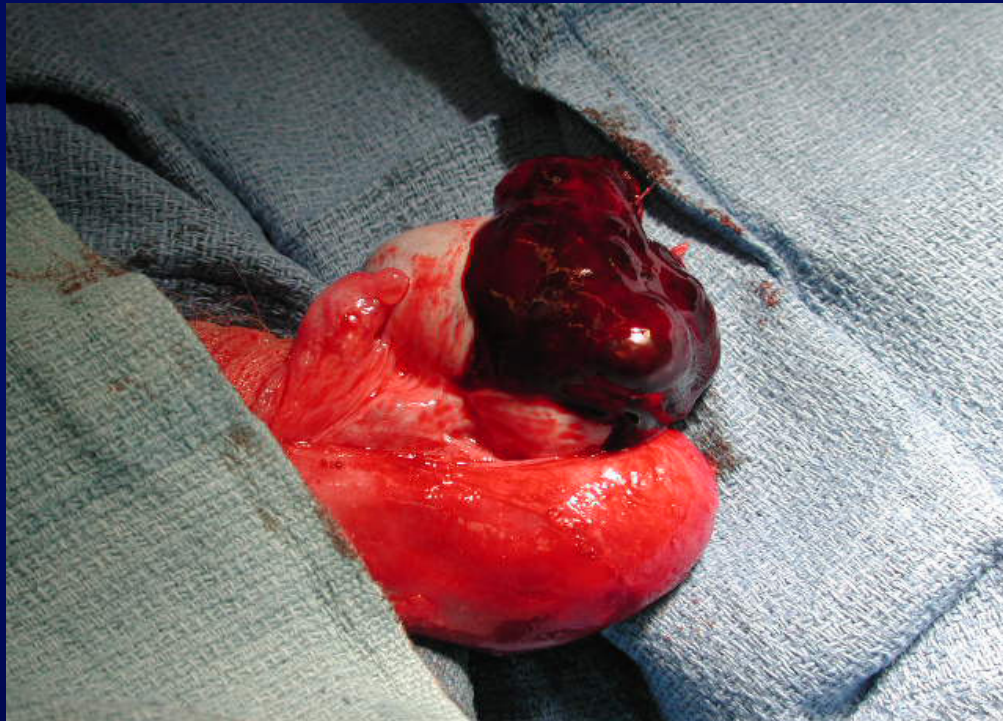Testicular Rupture





Testicular Rupture



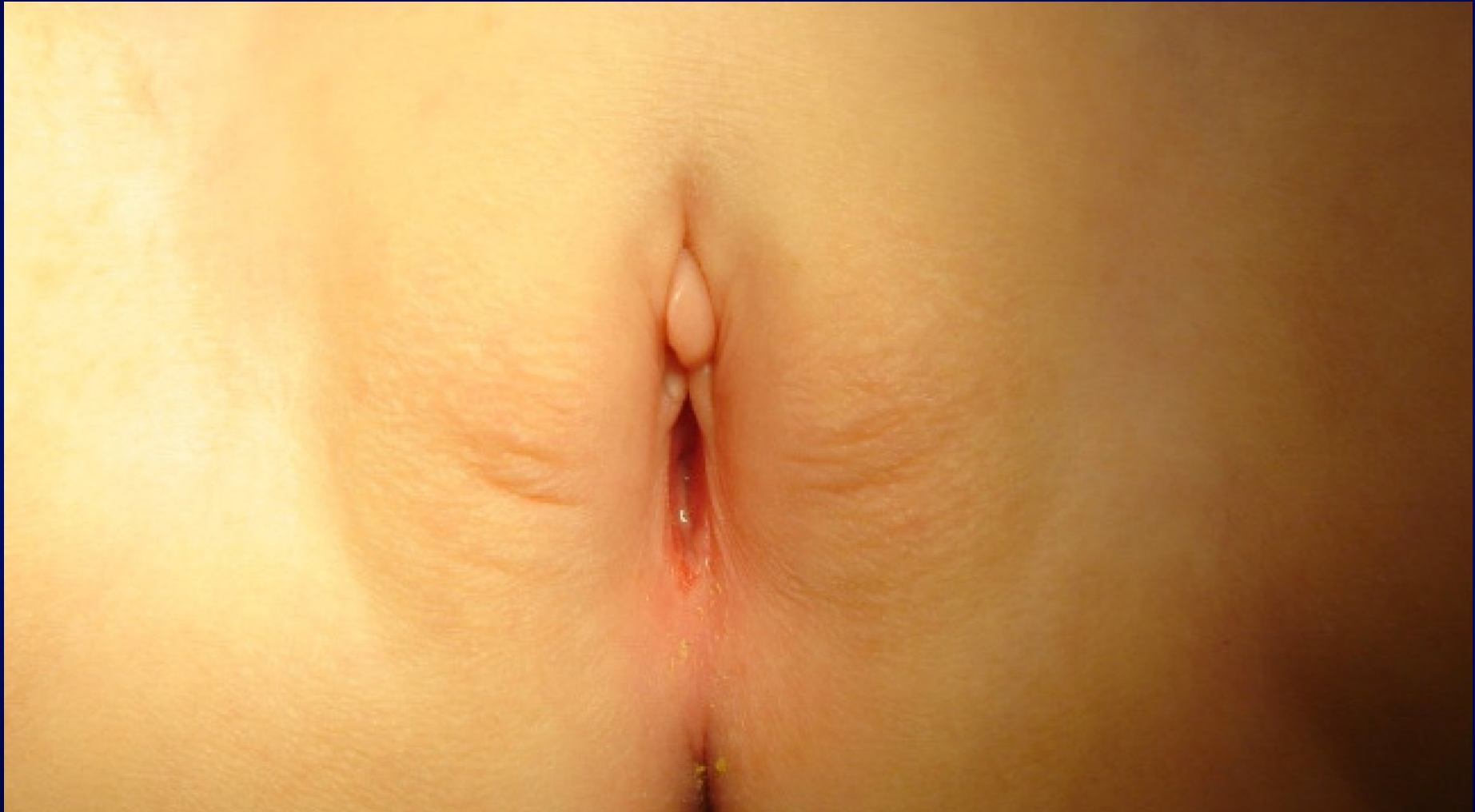

Female Exam

- Labia majora should gently be pulled outward and laterally to see urethral meatus and vaginal introitus



Normal External GU exam





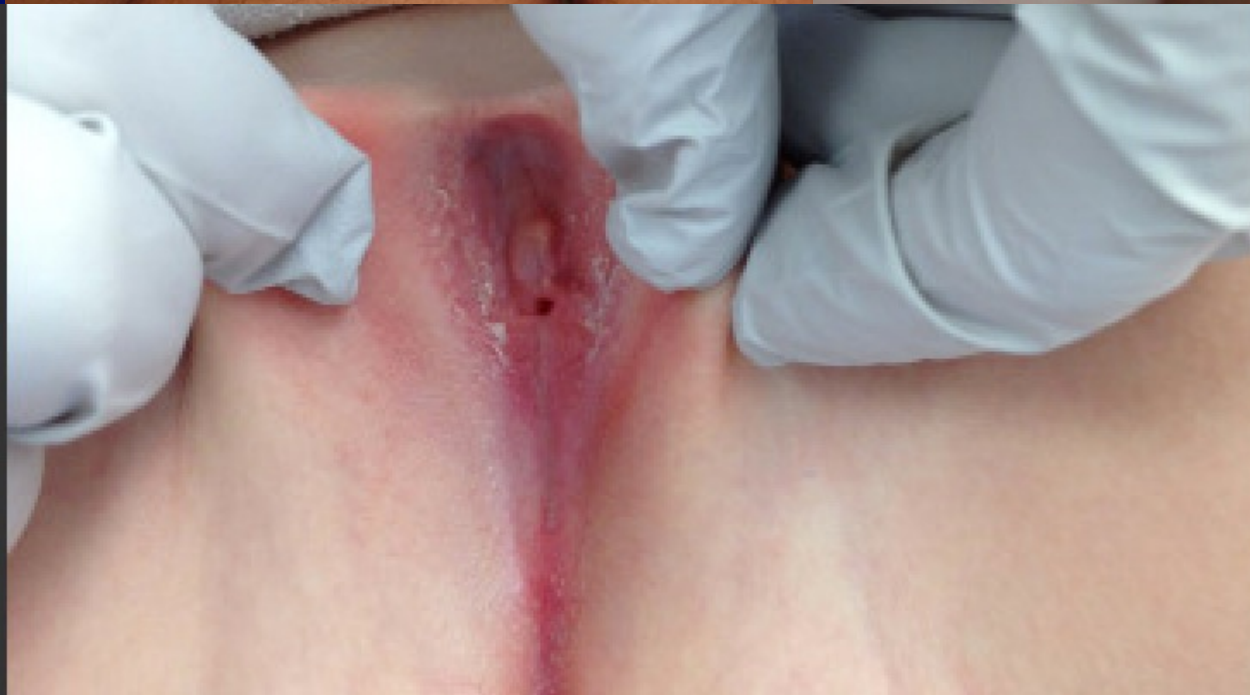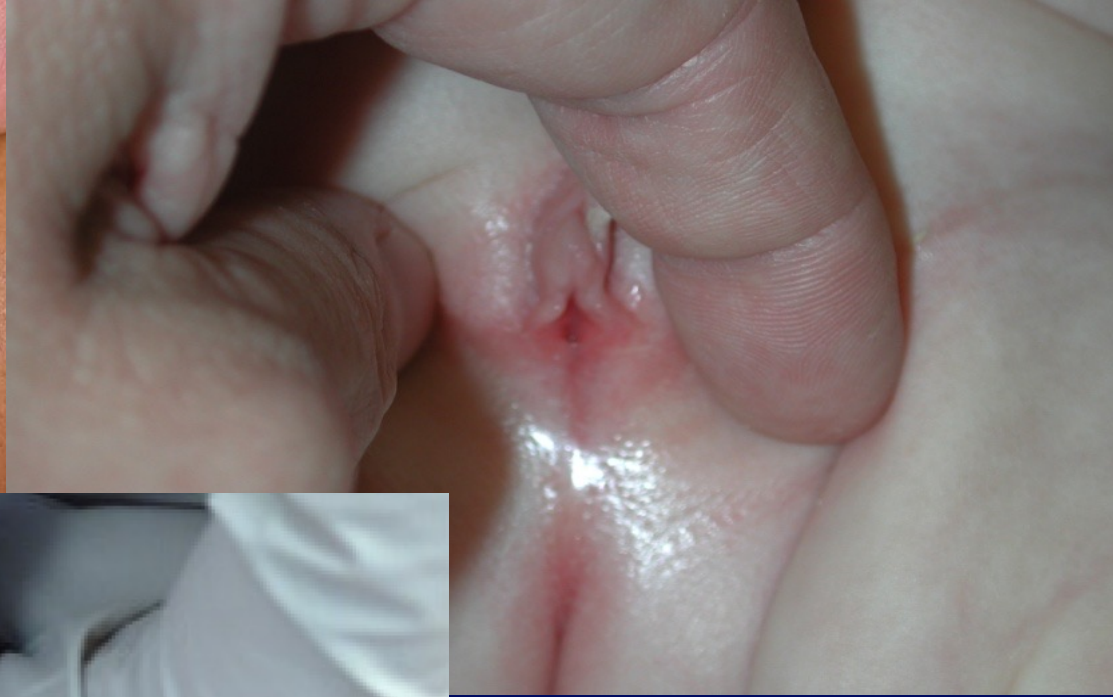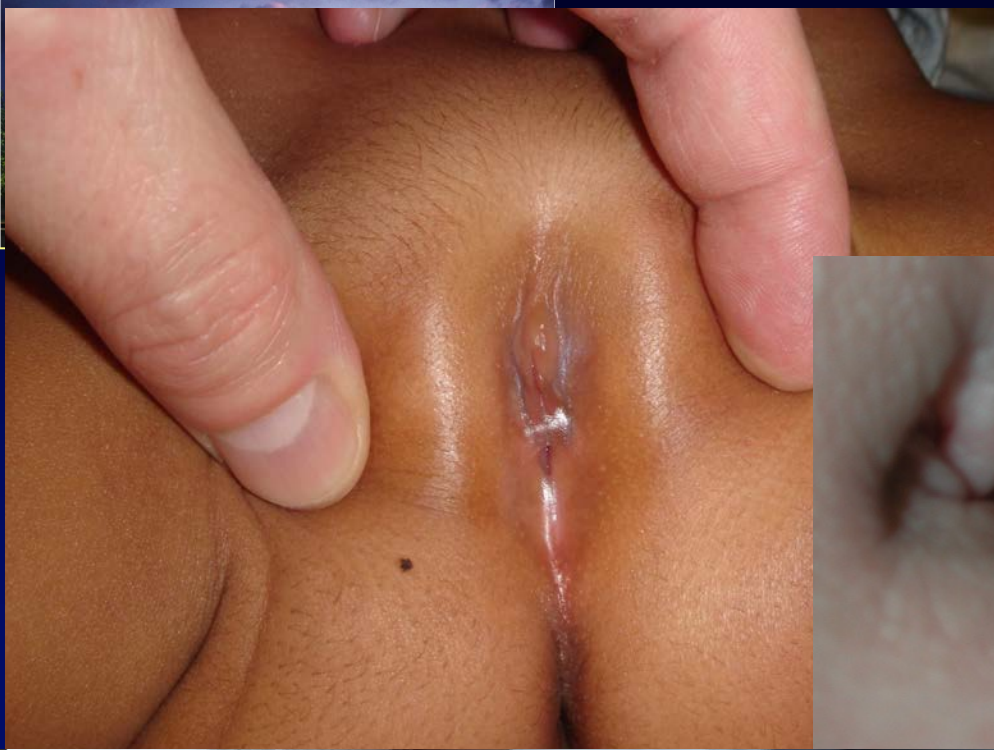Labial Adhesions

- Usually asymptomatic
- Can cause post-void dribbling, perineal irritation, difficulty catheterizing
- If asymptomatic, can defer treatment



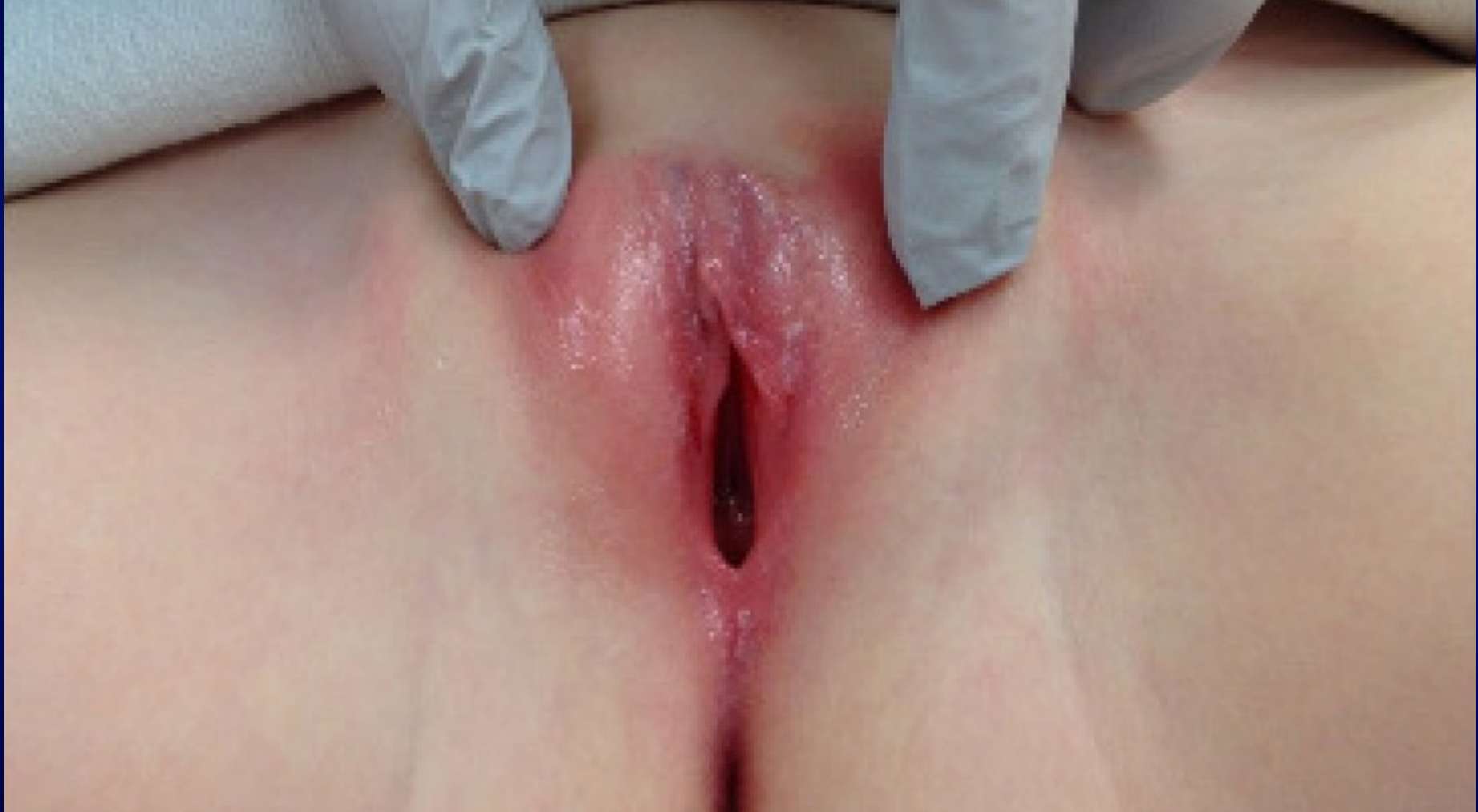Labial Adhesions

- Treatment options include:
 - Topical estrogen cream or steroid cream- can have side effects
 - Manual lysis after topical numbing application or in OR
- Should refer if dense adhesions or needs surgical intervention
- Can be mistaken for UG sinus or genital anomaly



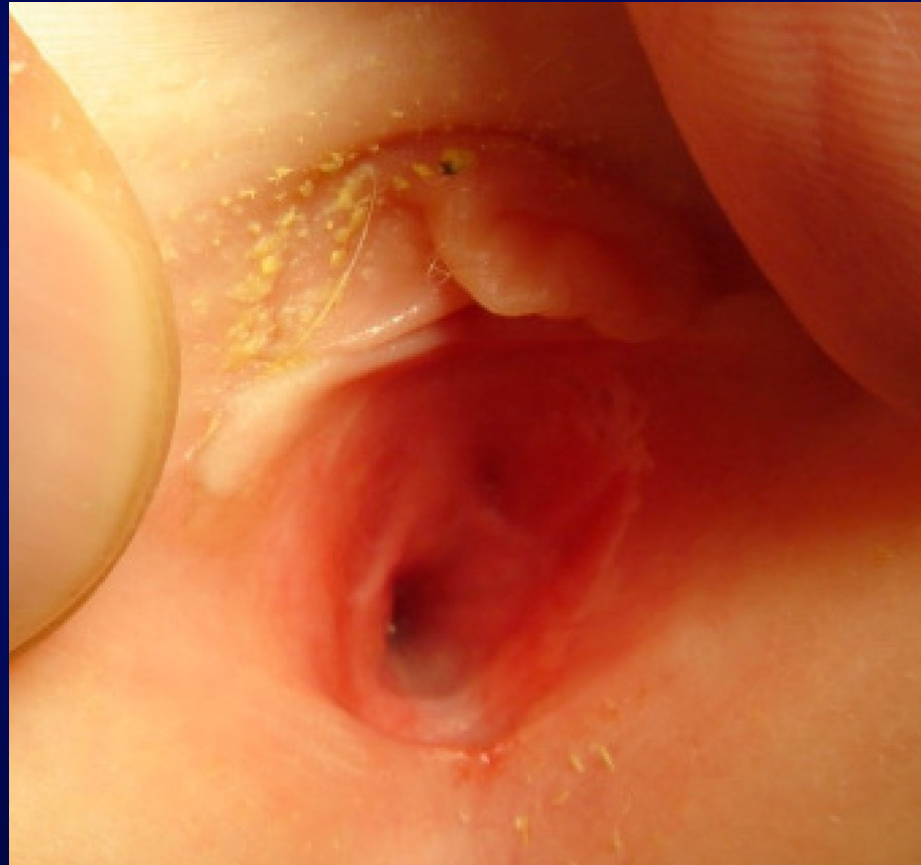

S/p Lysis of adhesions



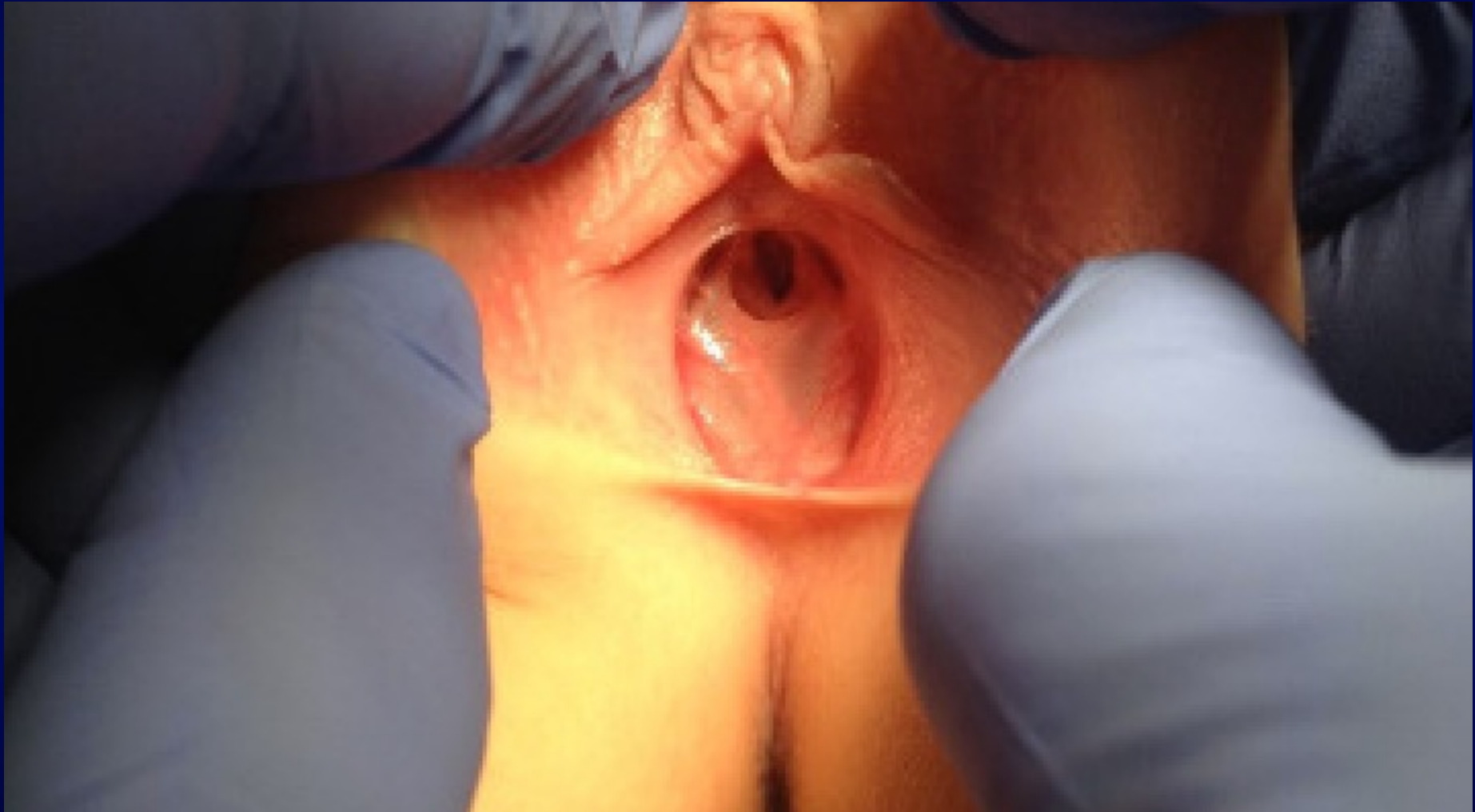

Urogenital Sinus



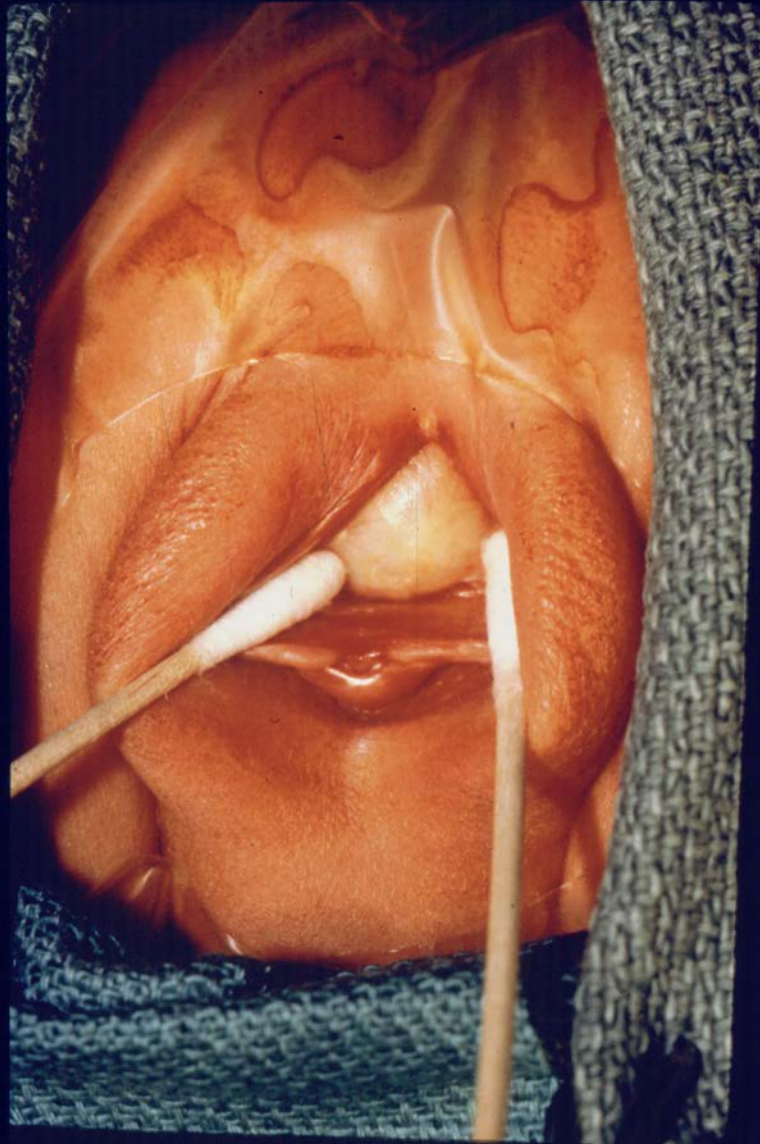


Imperforate Hymen



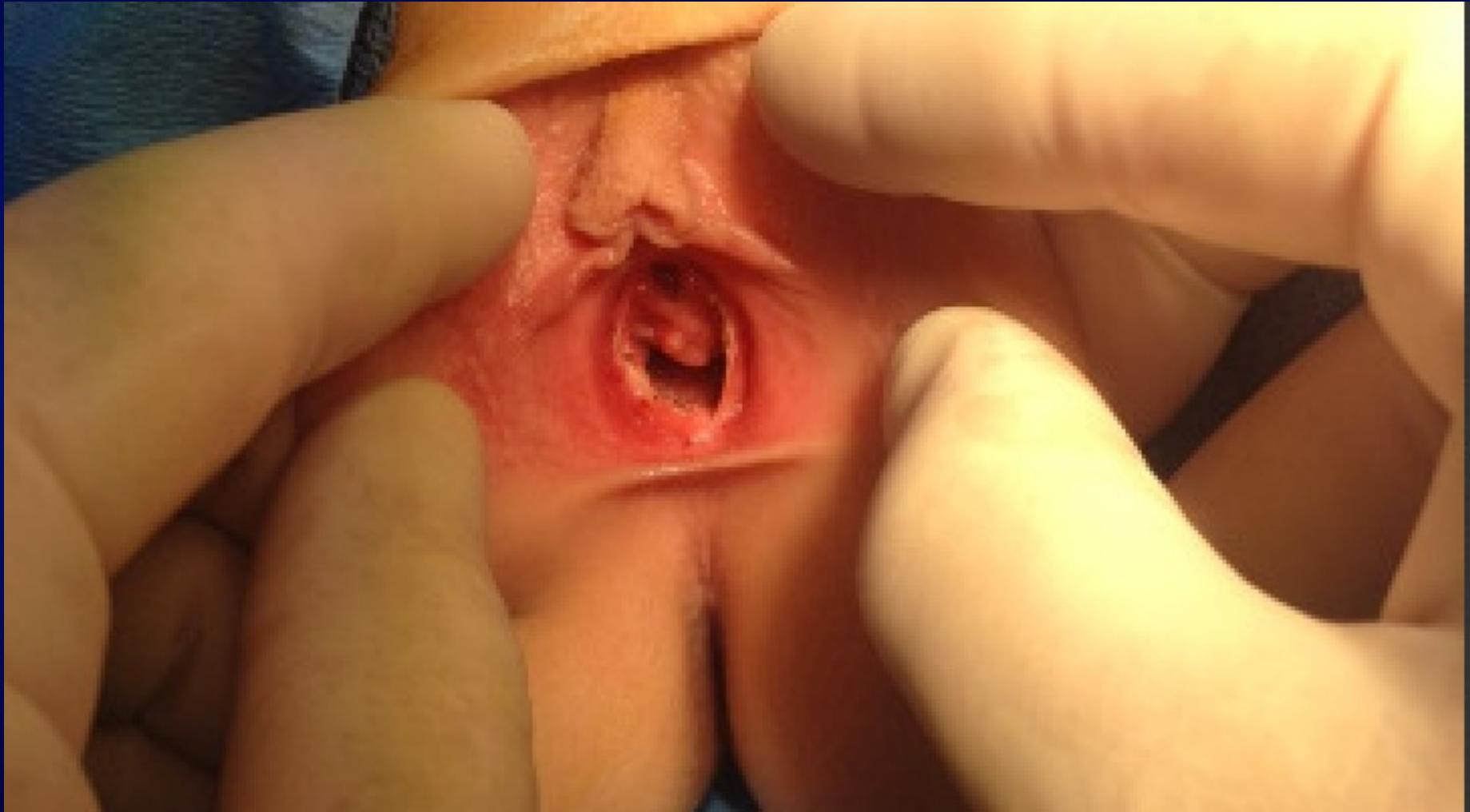

Imperforate Hymen

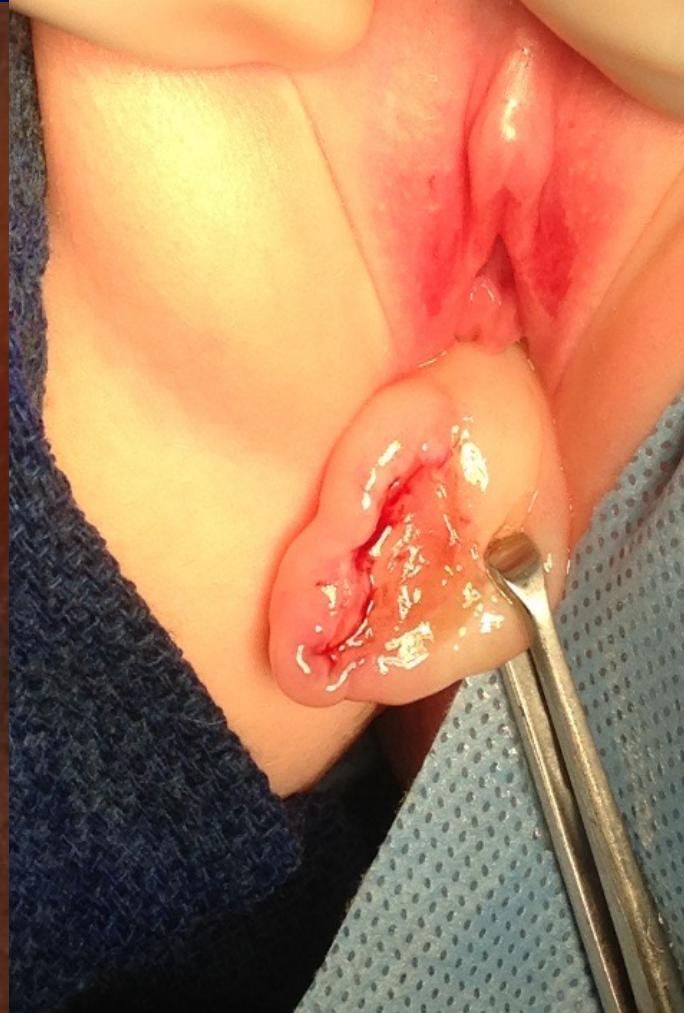
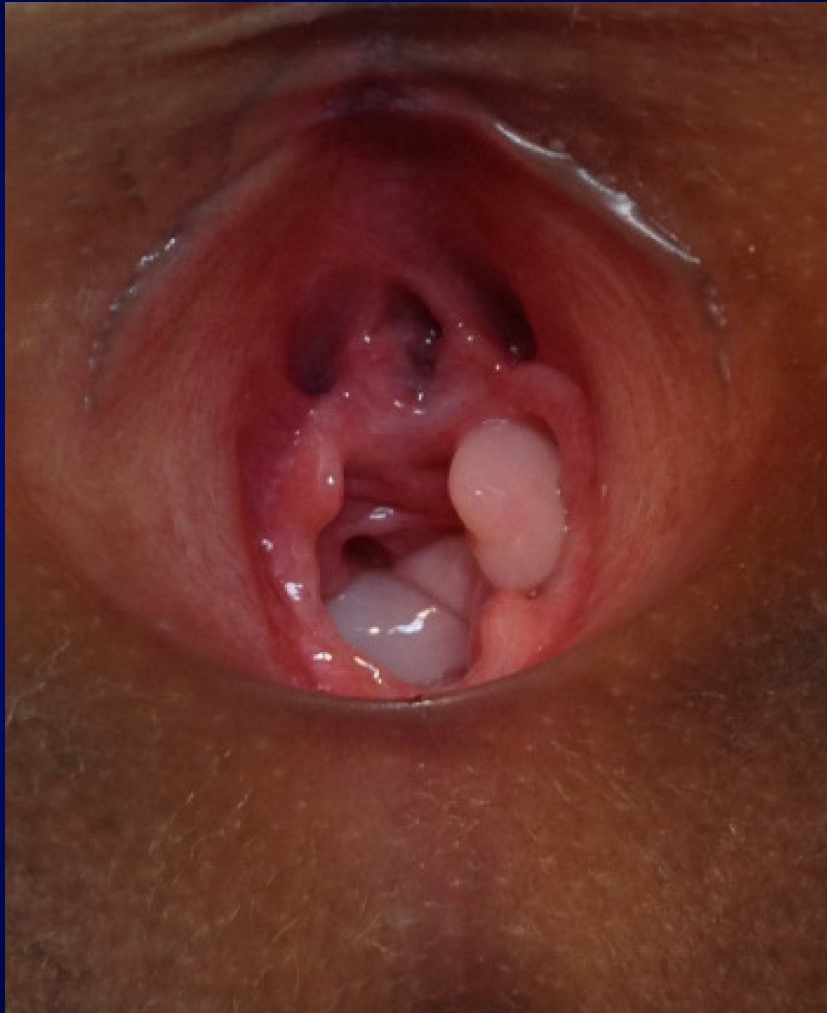


S/p Hymenectomy



Vaginal Rhabdomyosarcoma





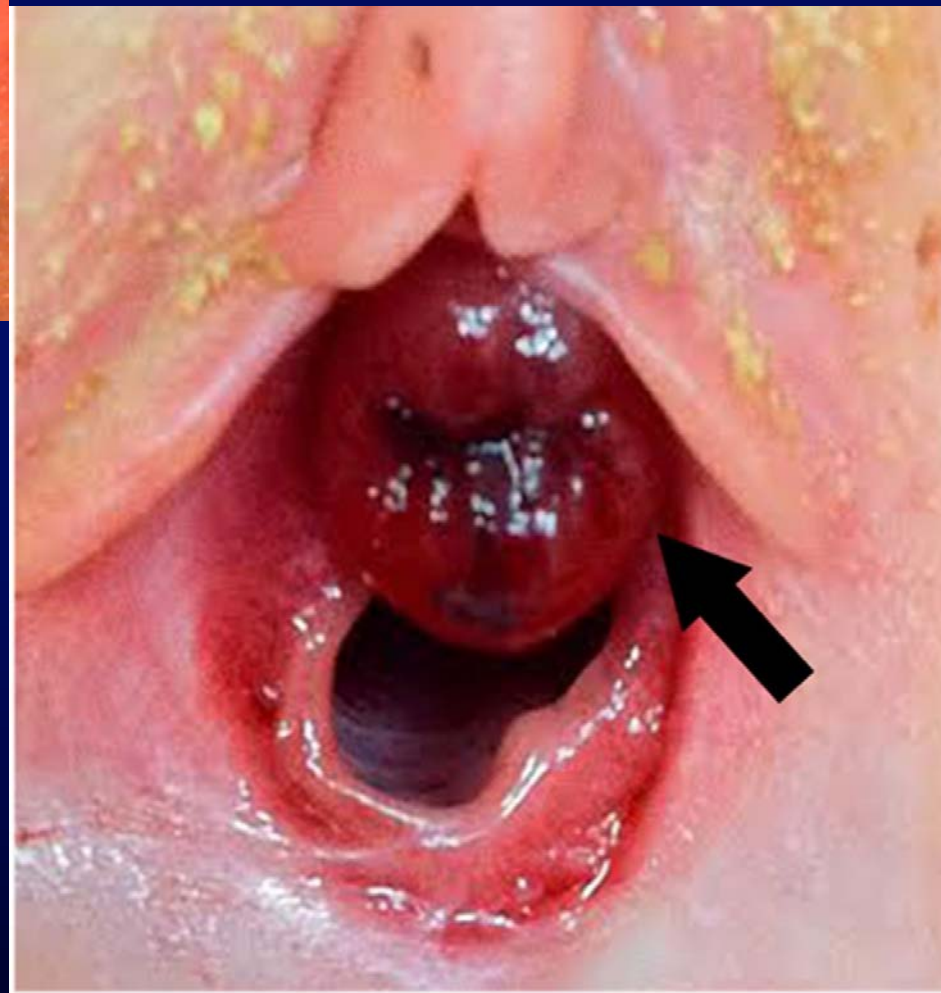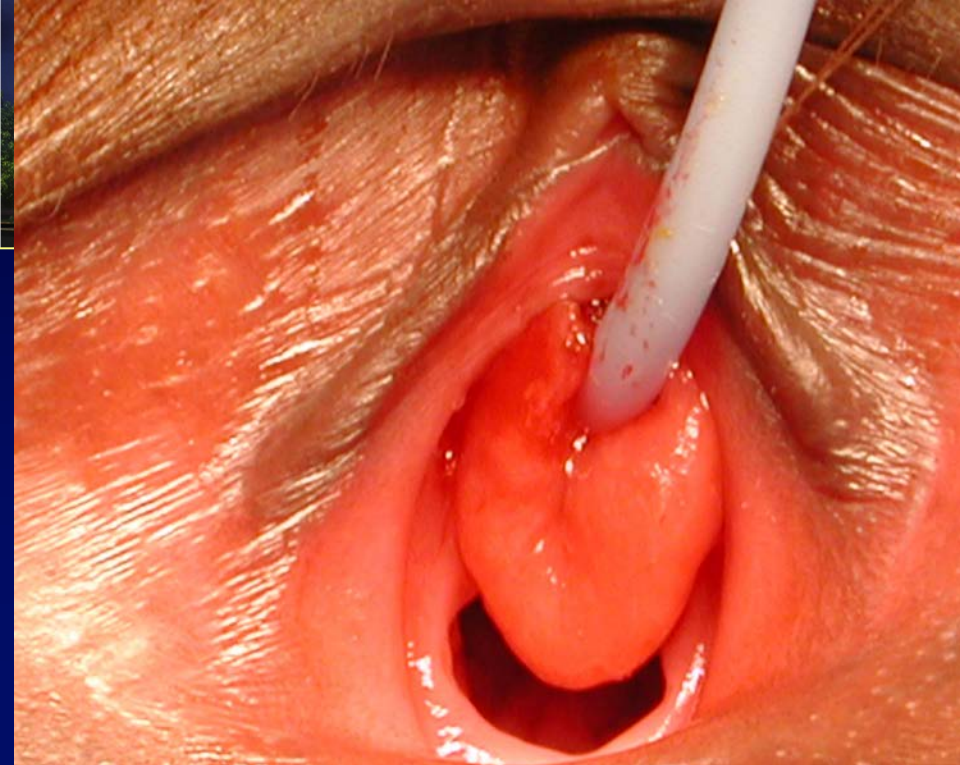
Urethral Prolapse

- Urethral mucosa protrudes



Urethral Prolapse

- History and Physical Exam:
 - Parents may report spotting of blood
 - Blood on underwear or tissue after voiding
 - “donut” appearance to urethra





Urethral Prolapse

- Treatment options:
 - Estrogen cream
 - Surgical excision by a pediatric urologist if unresponsive to estrogen cream
 - Treat underlying constipation

To Circumcise or to not
circumcise...that is the question





To circumcise or not to circumcise...the ongoing debate

- AAP consensus statement on circumcision in 2012, which was a revision of 1999 policy
- “Evaluation of current evidence indicates that the health benefits of newborn male circumcision outweigh the risks and that the procedure’s benefits justify access to this procedure for families who choose it. Specific benefits identified included prevention of urinary tract infections, penile cancer, and transmission of some sexually transmitted infections, including HIV.”

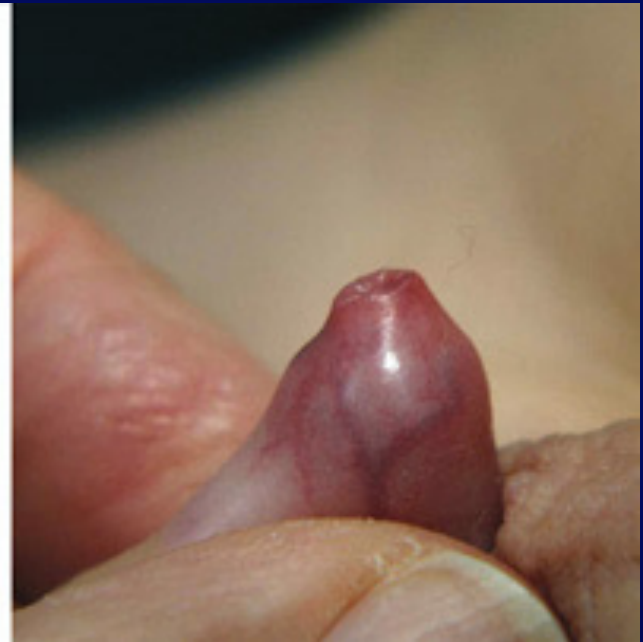
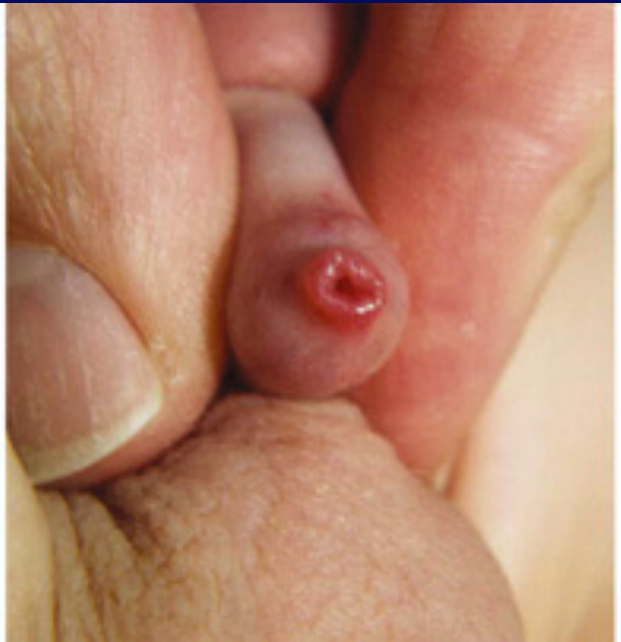
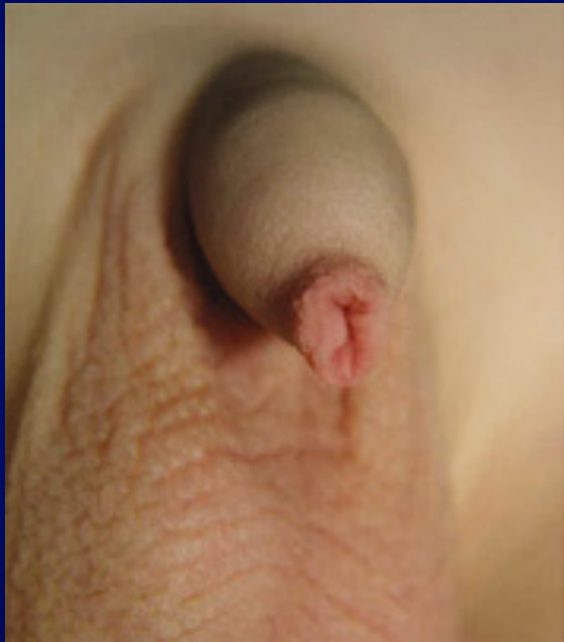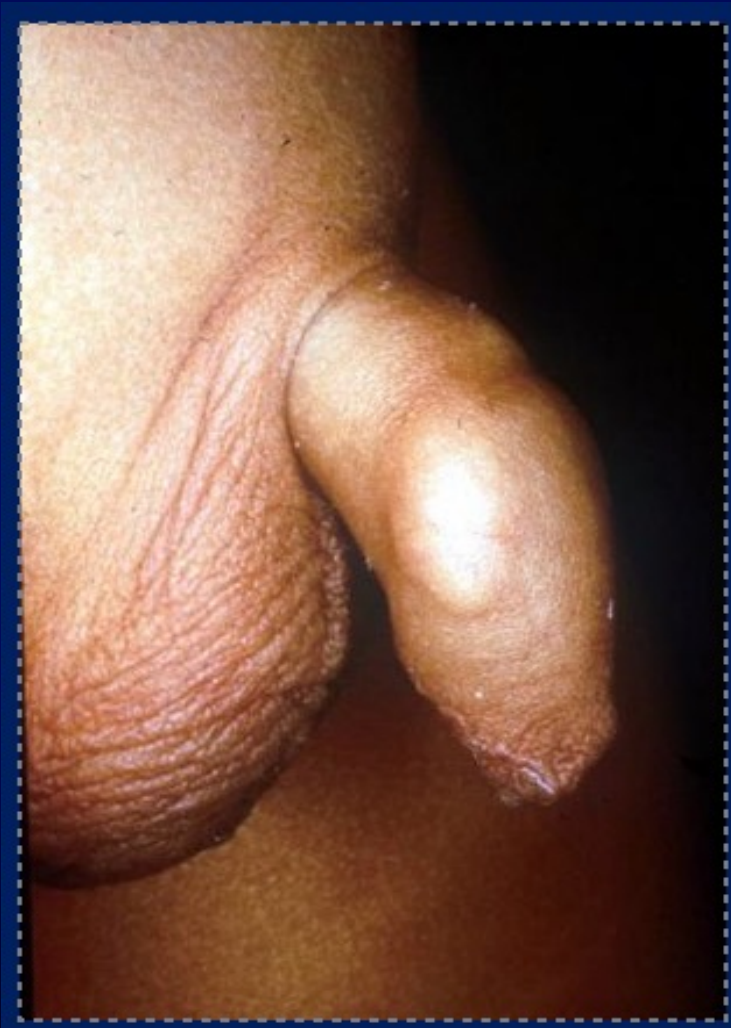The Uncircumcised Penis

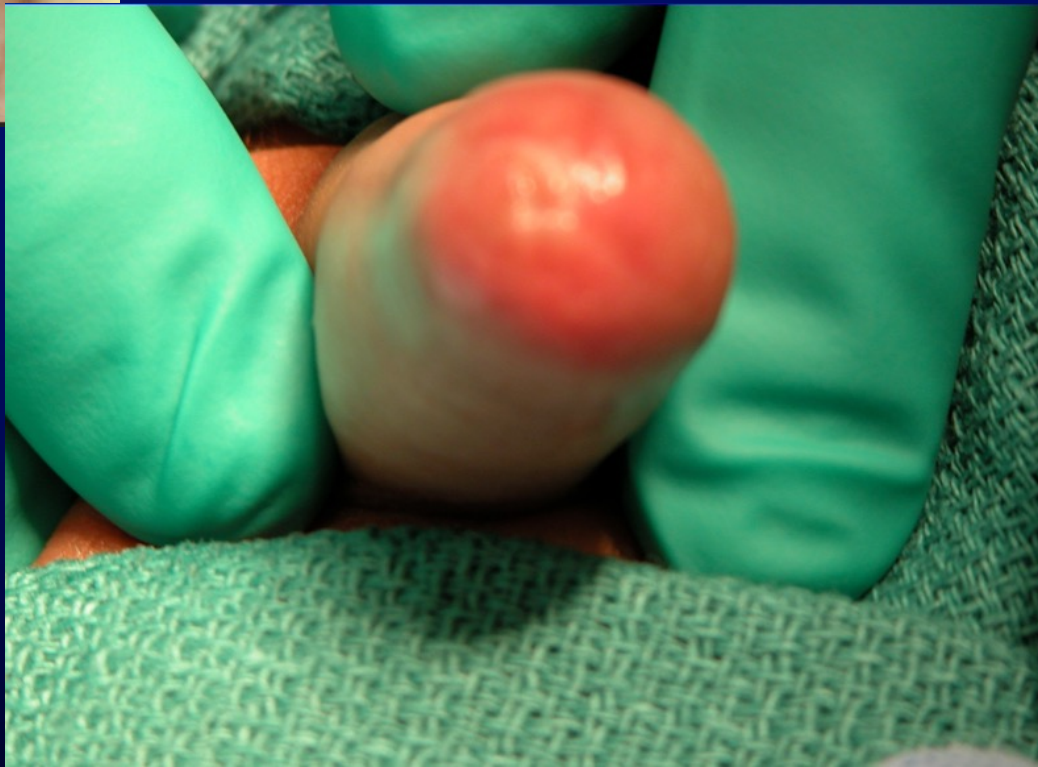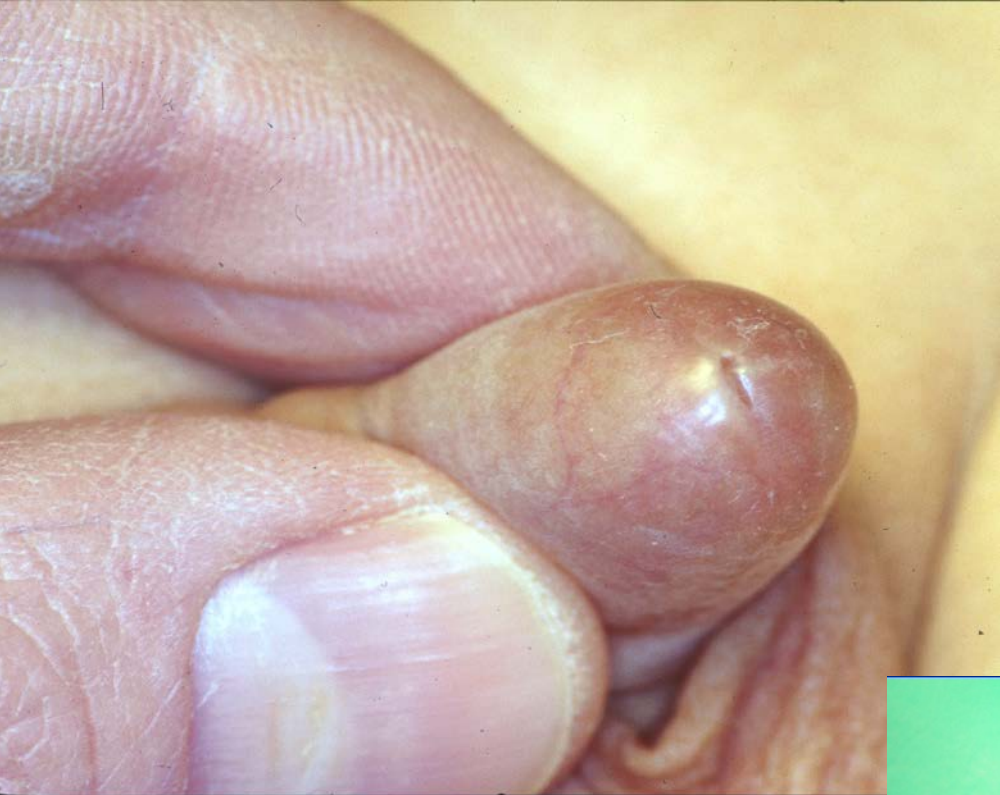- Foreskin naturally attached to head of penis by adhesions at birth
- Adhesions naturally breakdown over time and foreskin is usually retractable by 10-12 years of age
- As adhesions breakdown, smegma can accumulate



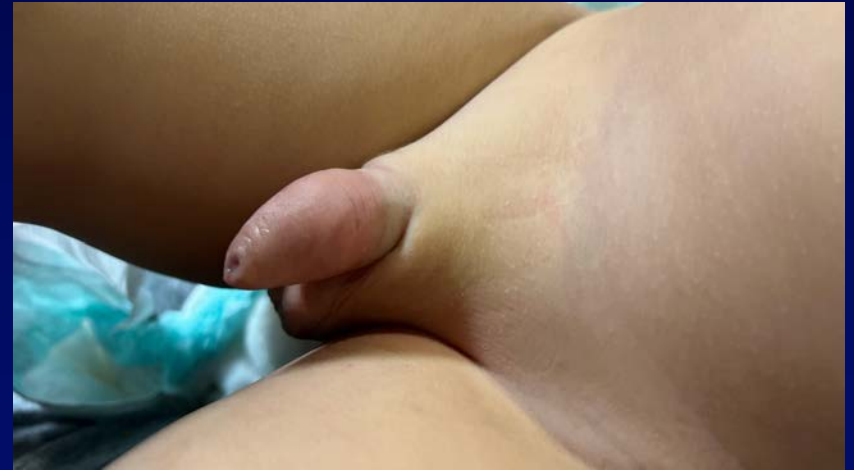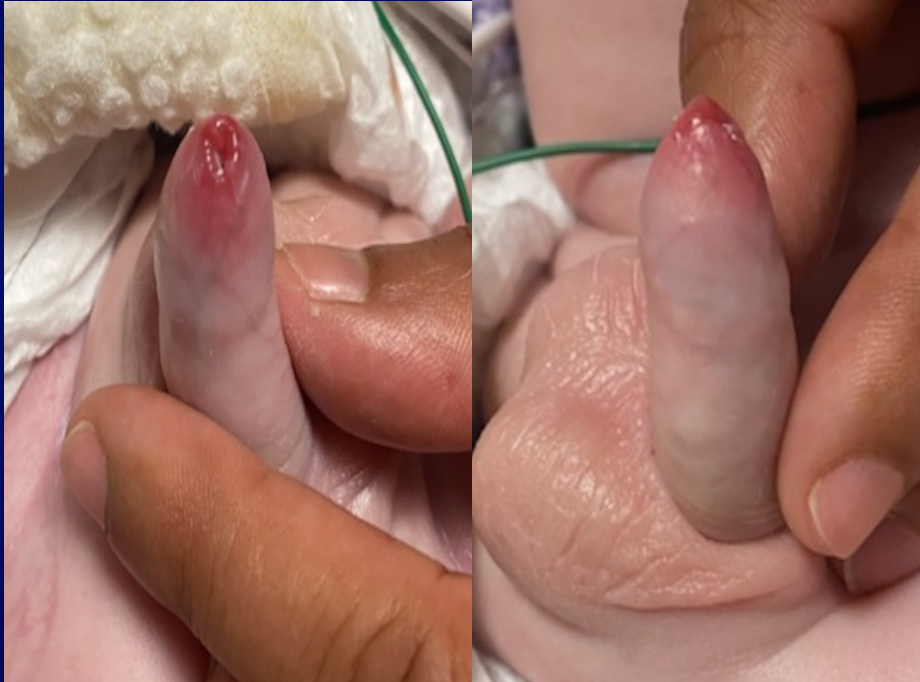Physiologic Phimosis

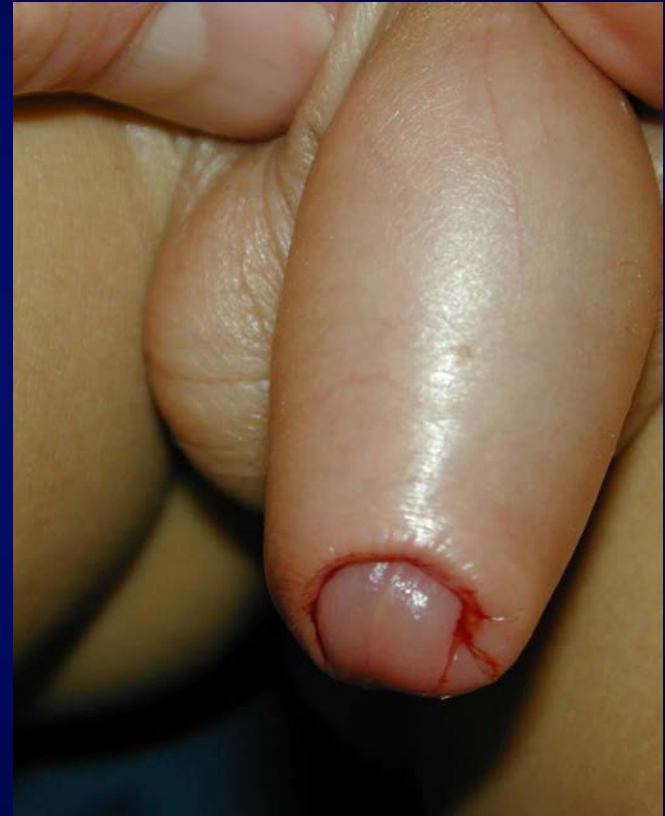
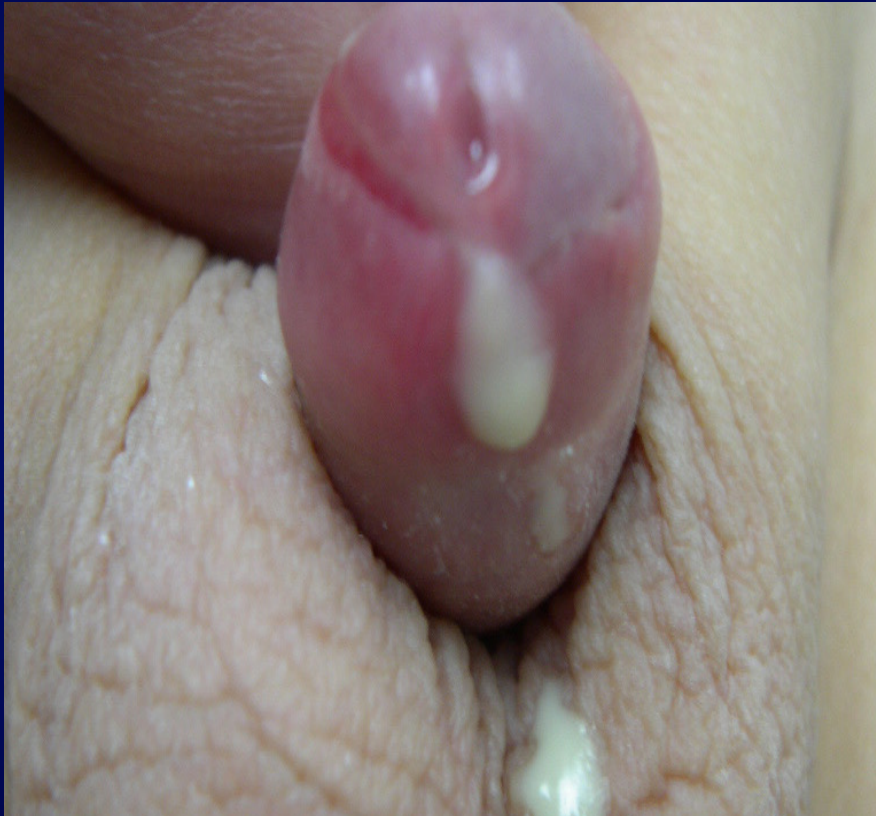




Balanitis and Balanoposthitis





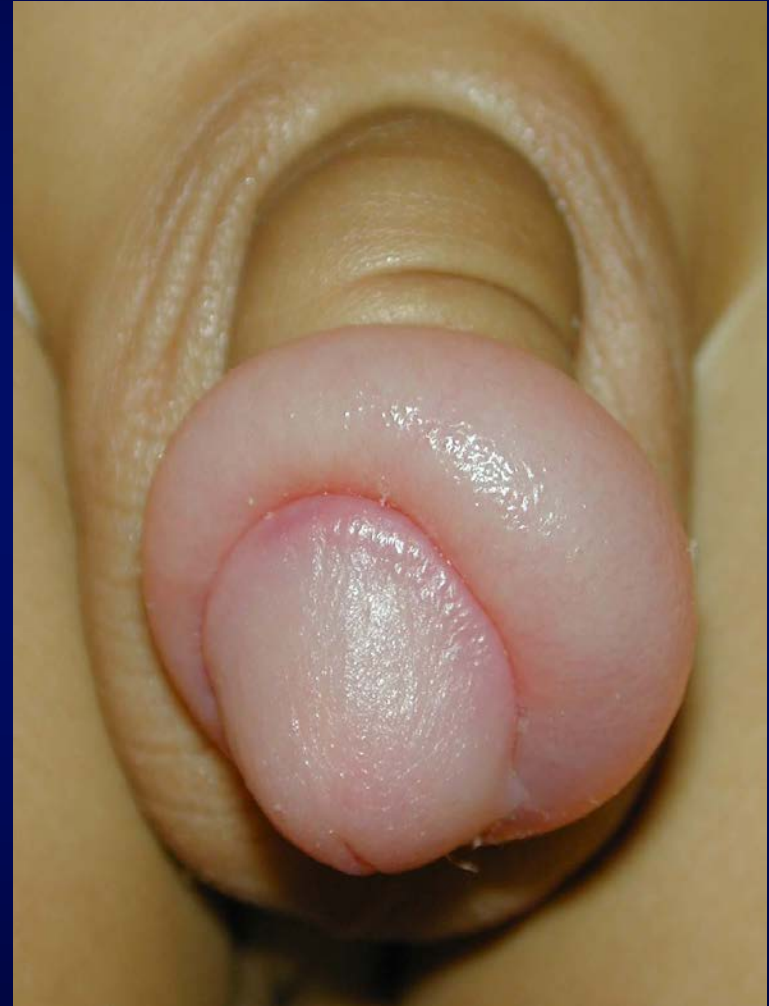
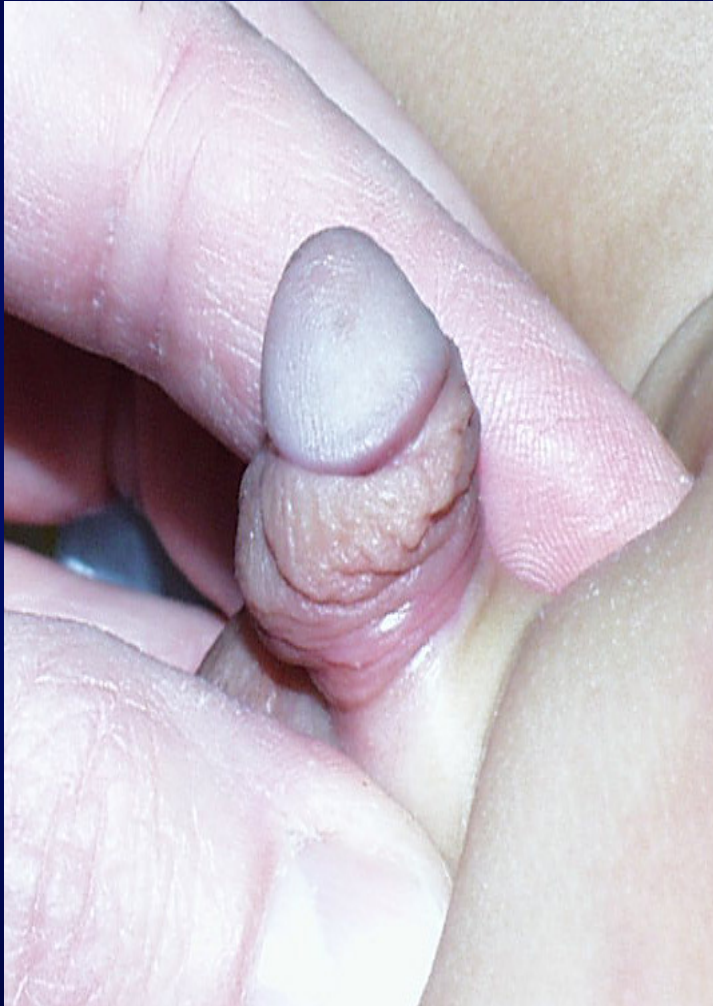
Paraphimosis

- Painful constriction of the glans when the foreskin is retracted and becomes trapped behind the corona



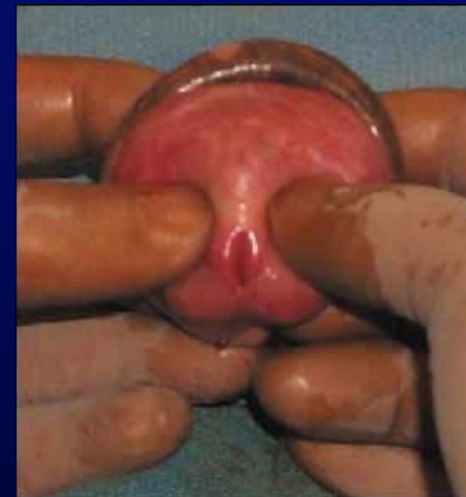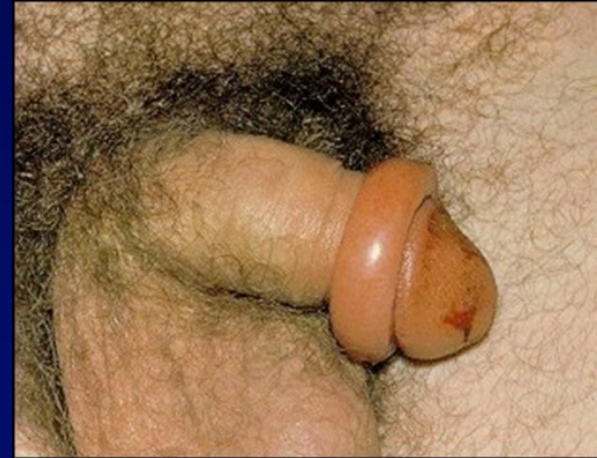Paraphimosis





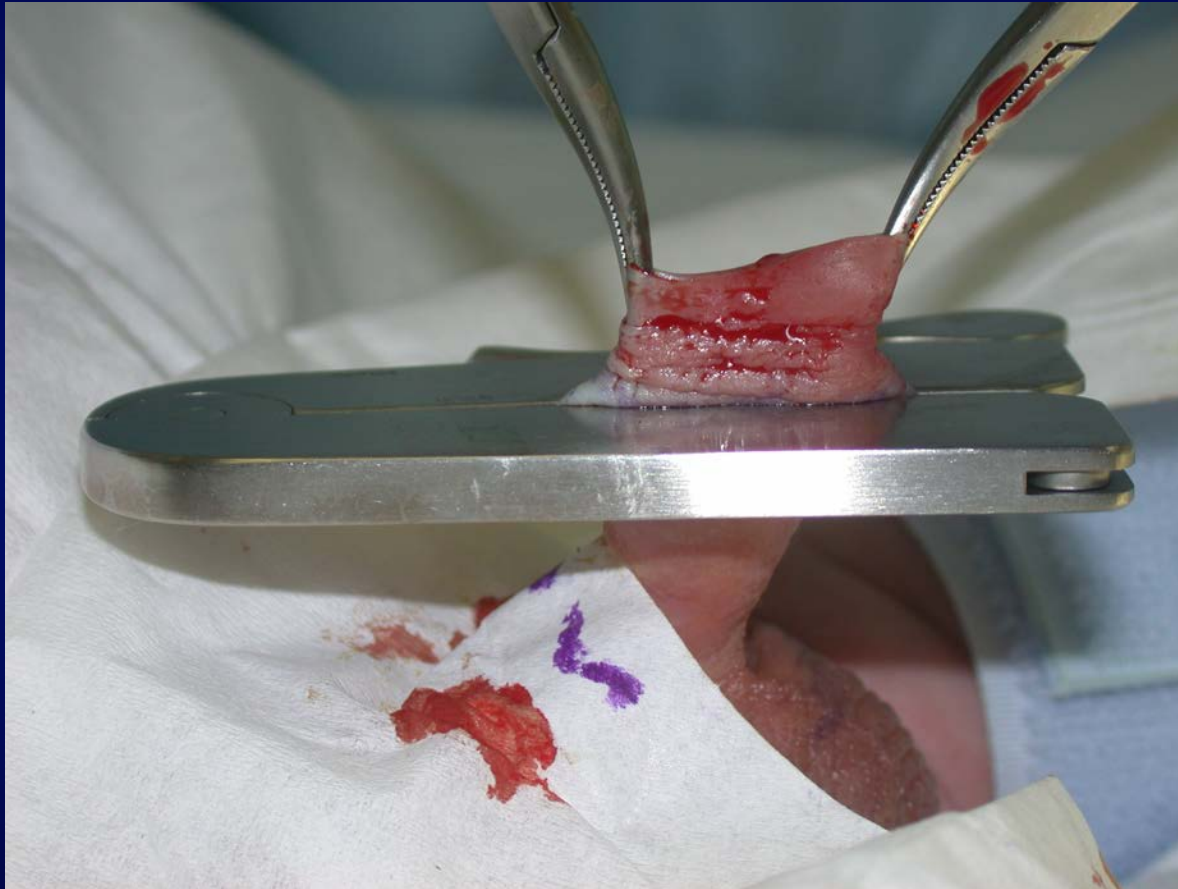Paraphimosis

- Only in uncircumcised patients
- Phimotic foreskin becomes trapped behind corona—**ischemic injury to glans may result, it is an EMERGENCY**
- Manual pressure applied to reduce foreskin over glans
- Penile block and or sedation may be needed for patient to tolerate reduction



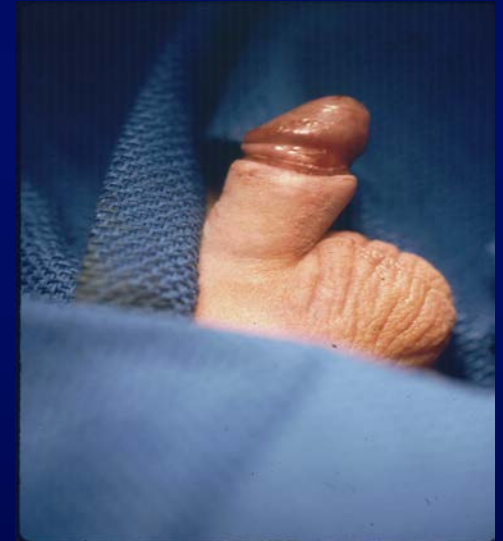
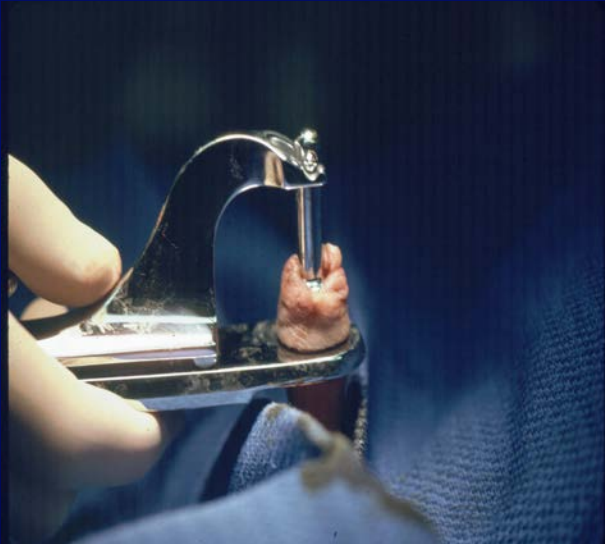
Mogen Clamp





Gomco Clamp



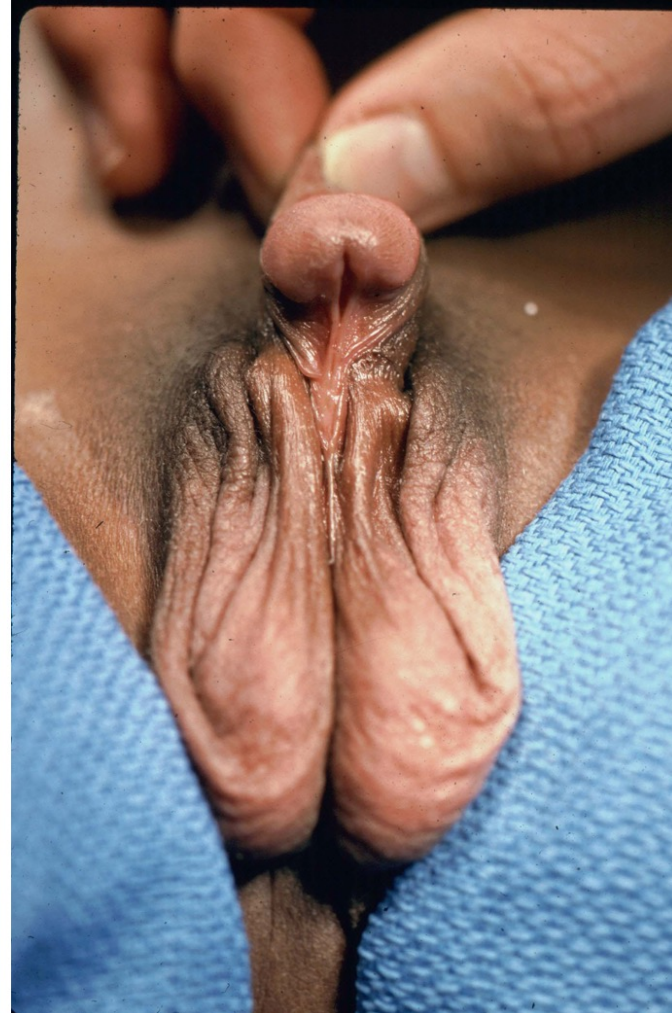
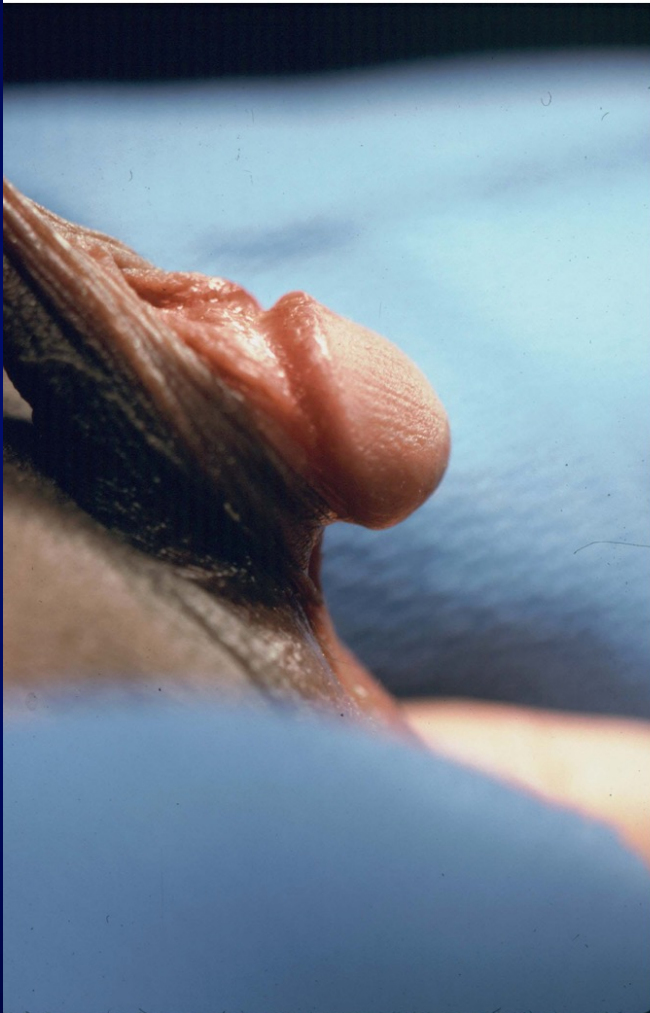
Contraindications to Circumcision

- Penile abnormalities
 - Penile torsion
 - Chordee
 - Hypospadias
 - Epispadias
 - Webbed penis
 - Concealed penis

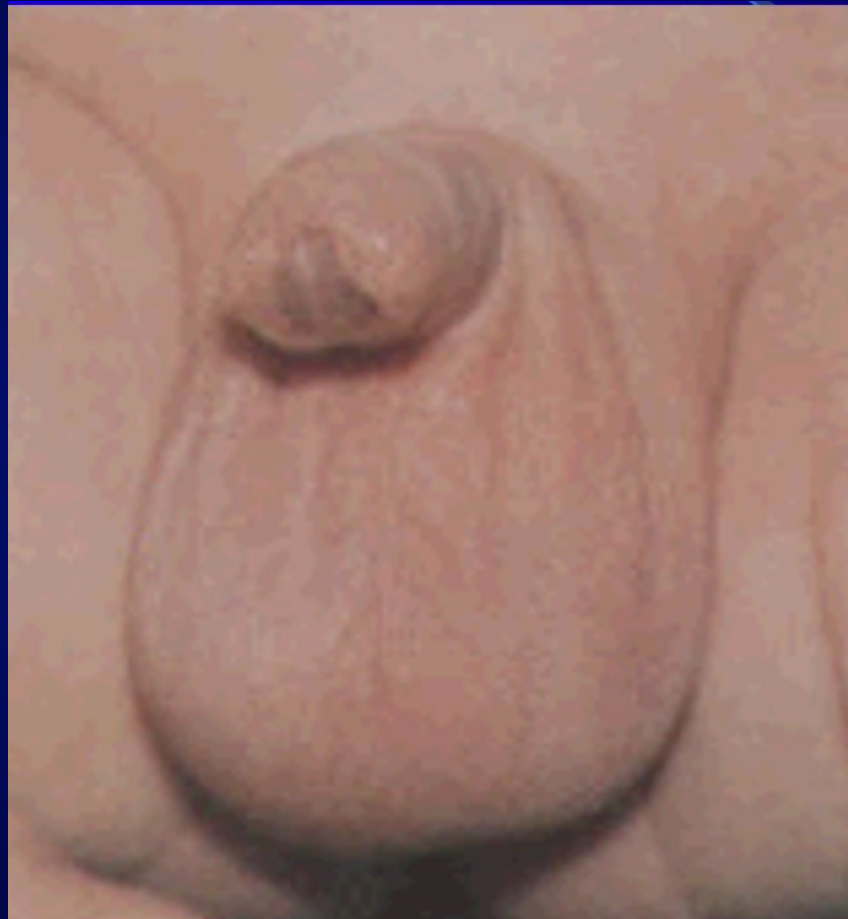

Chordee



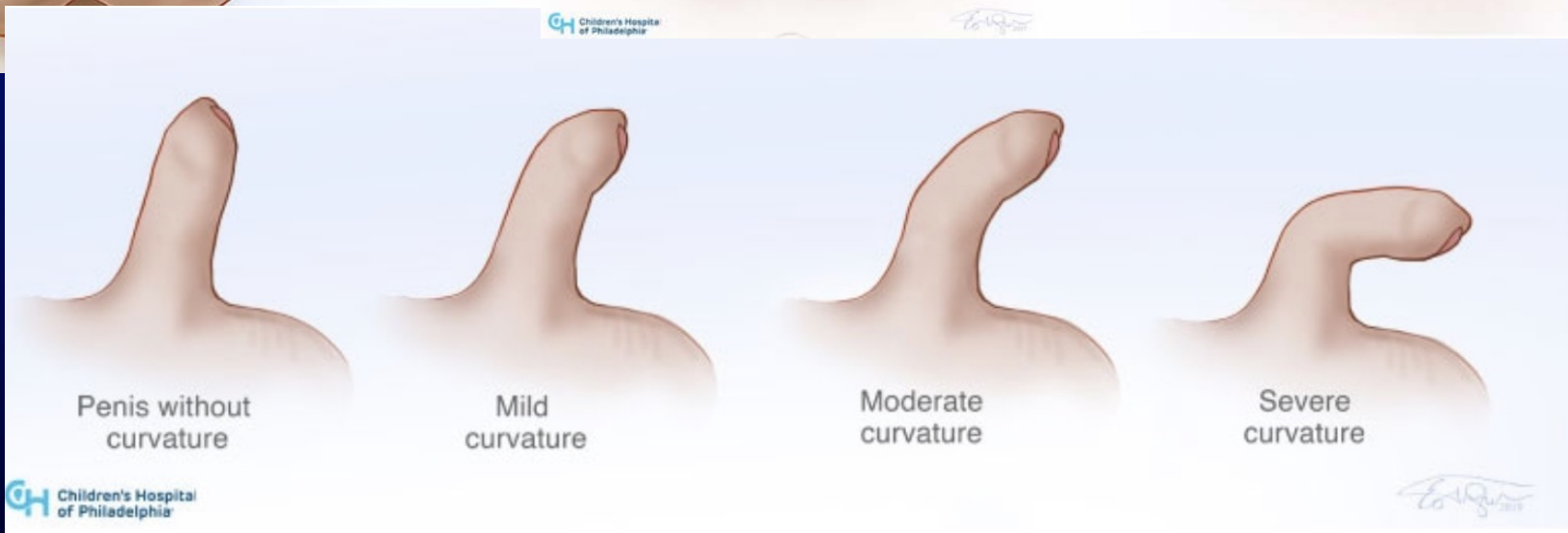
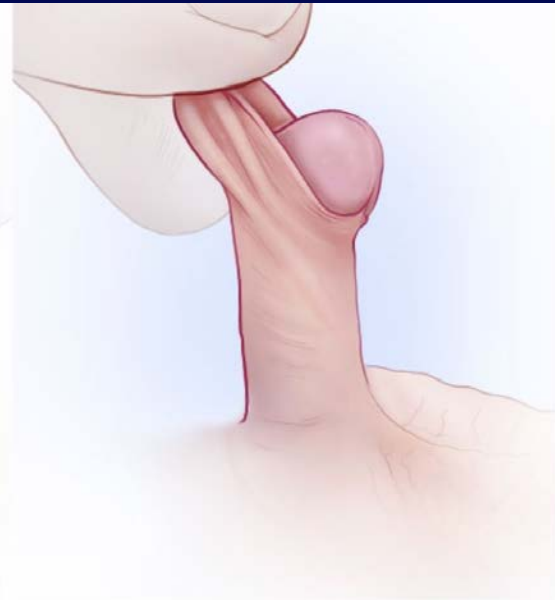
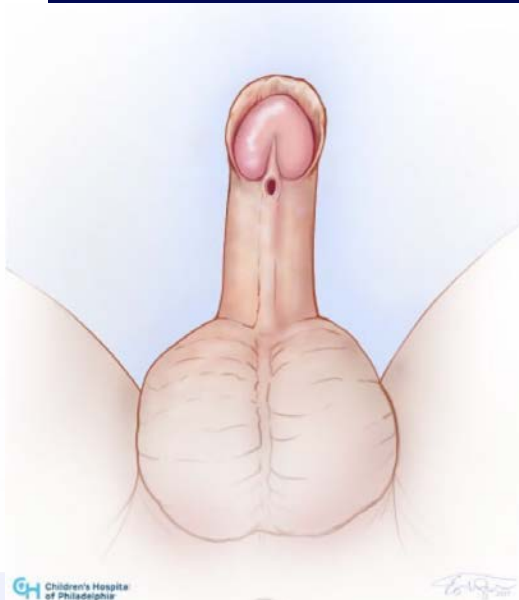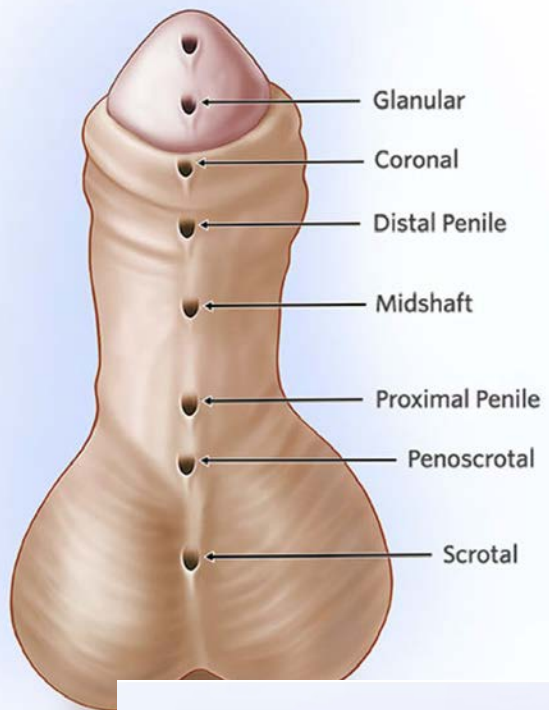


Incomplete Foreskin



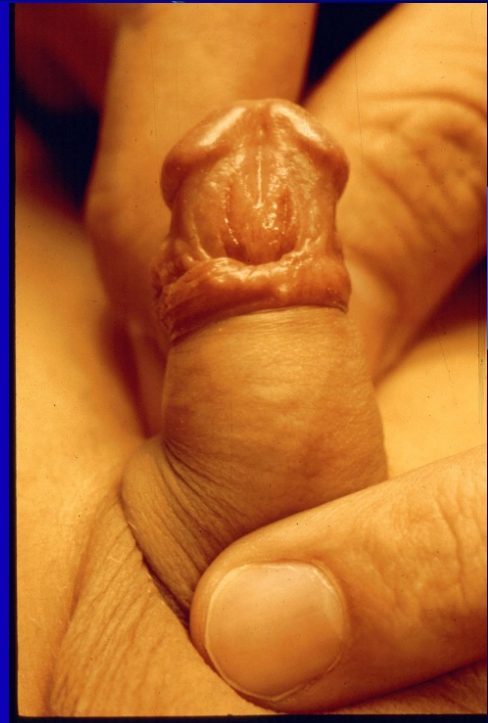
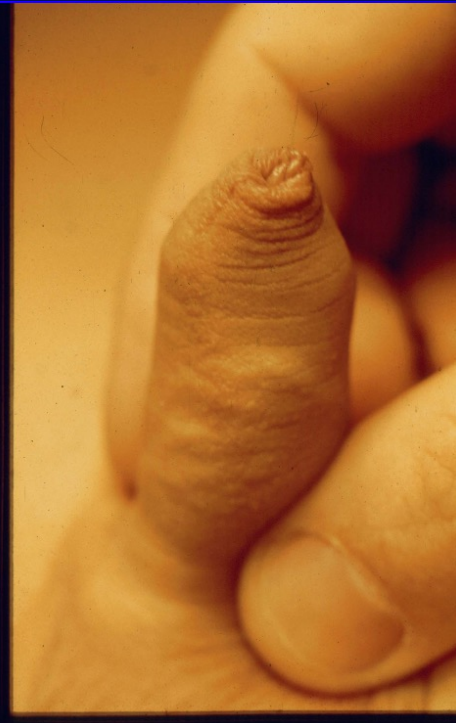
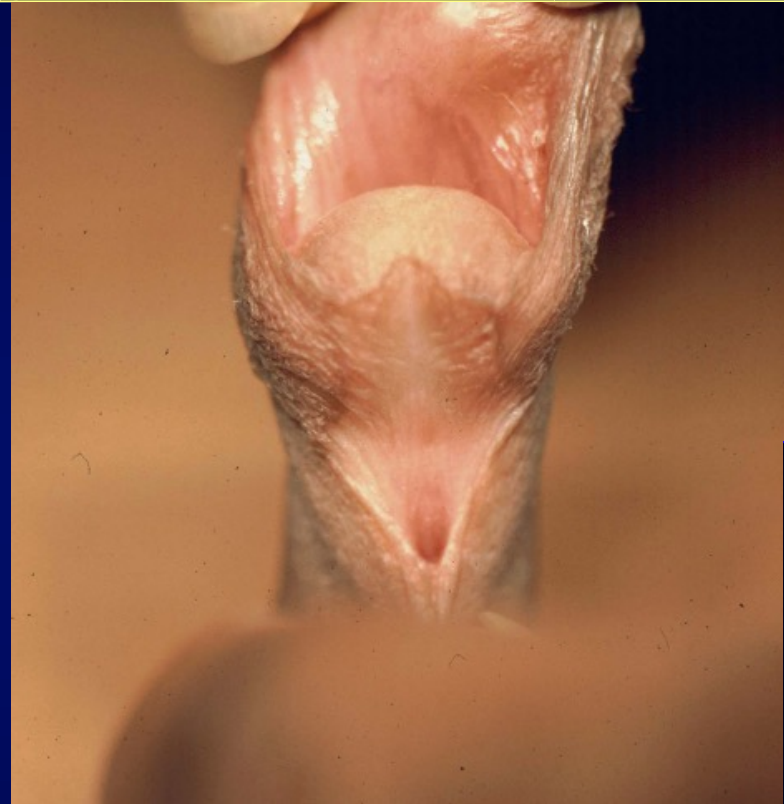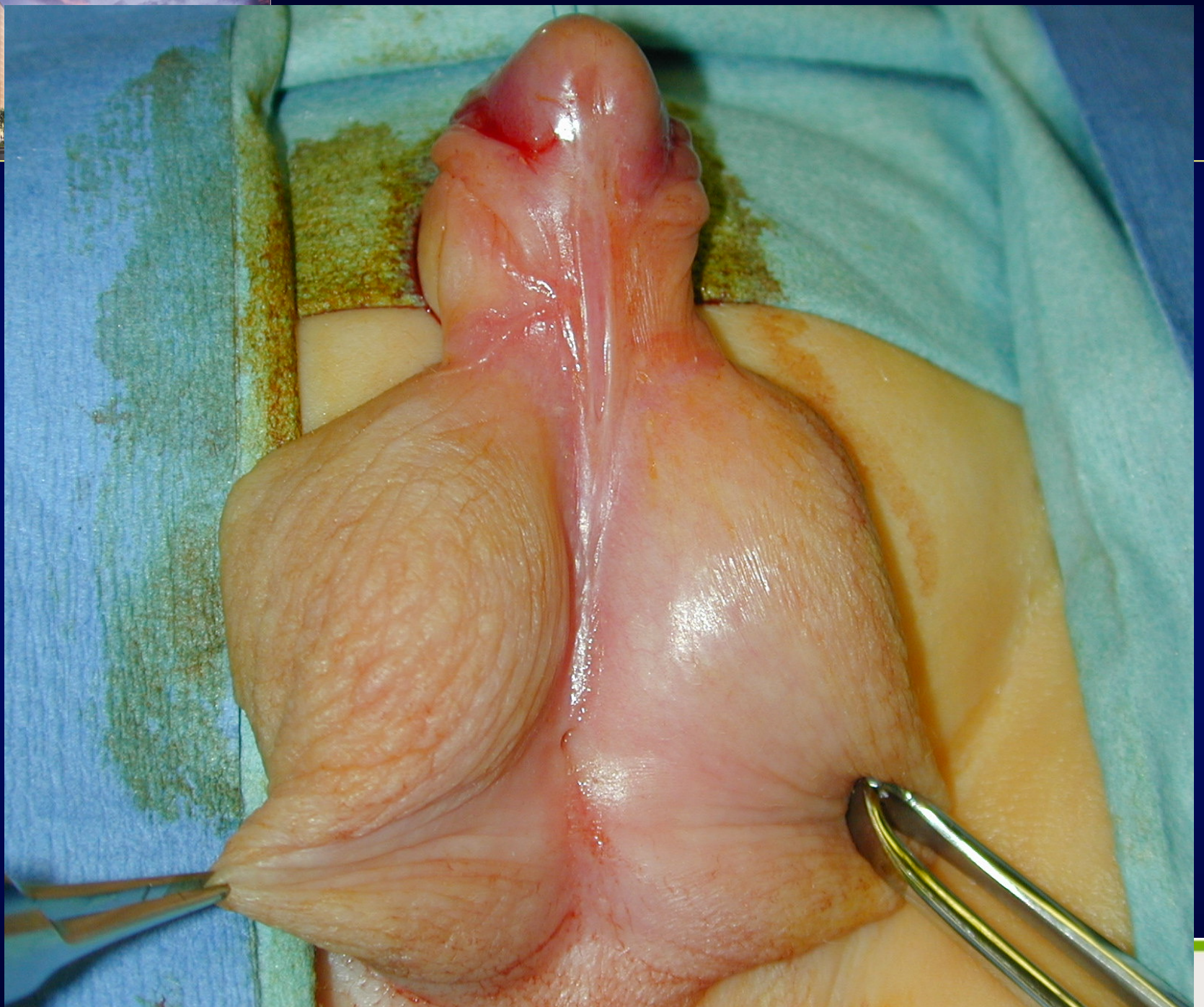Hypospadias

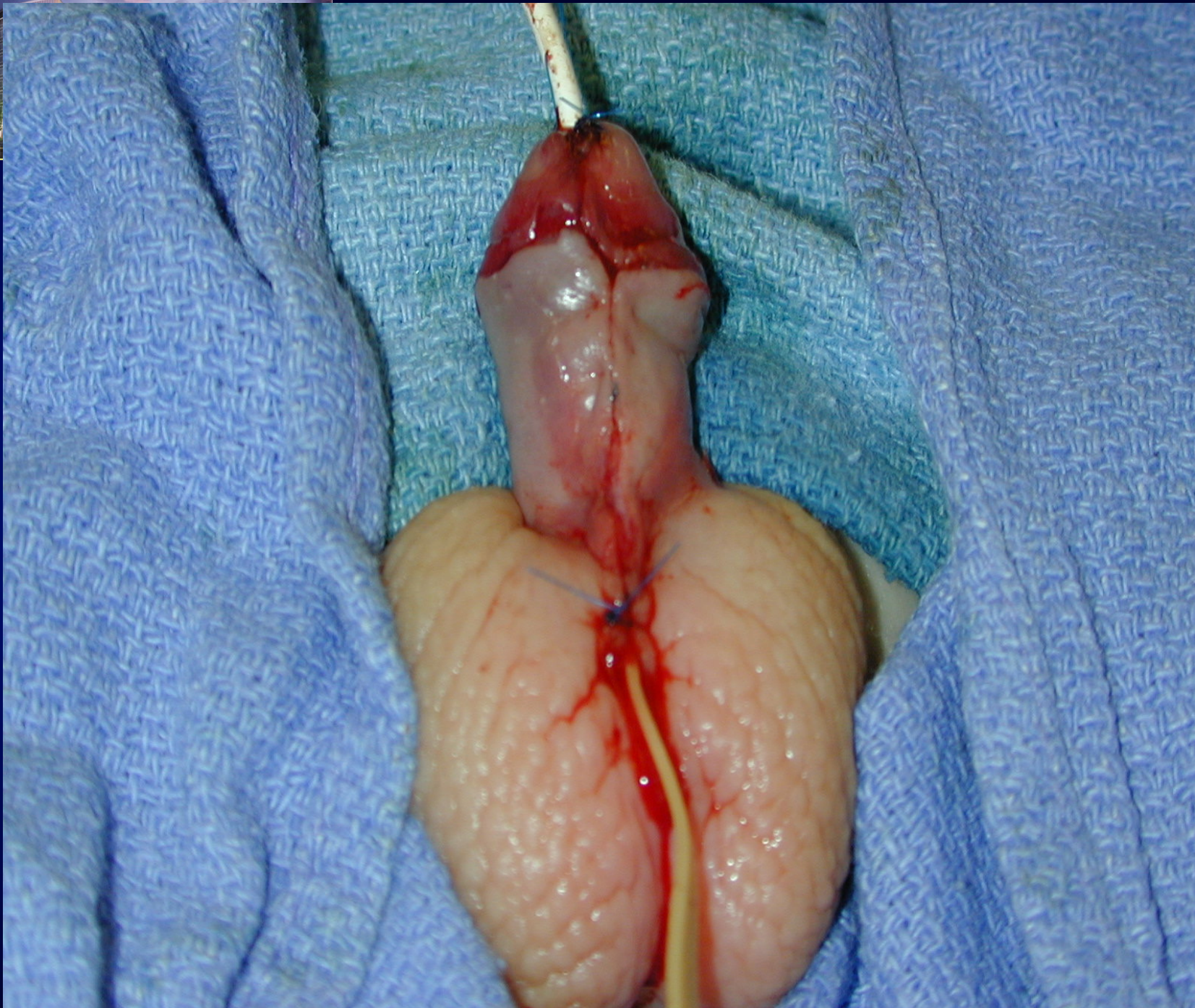




Hypospadias

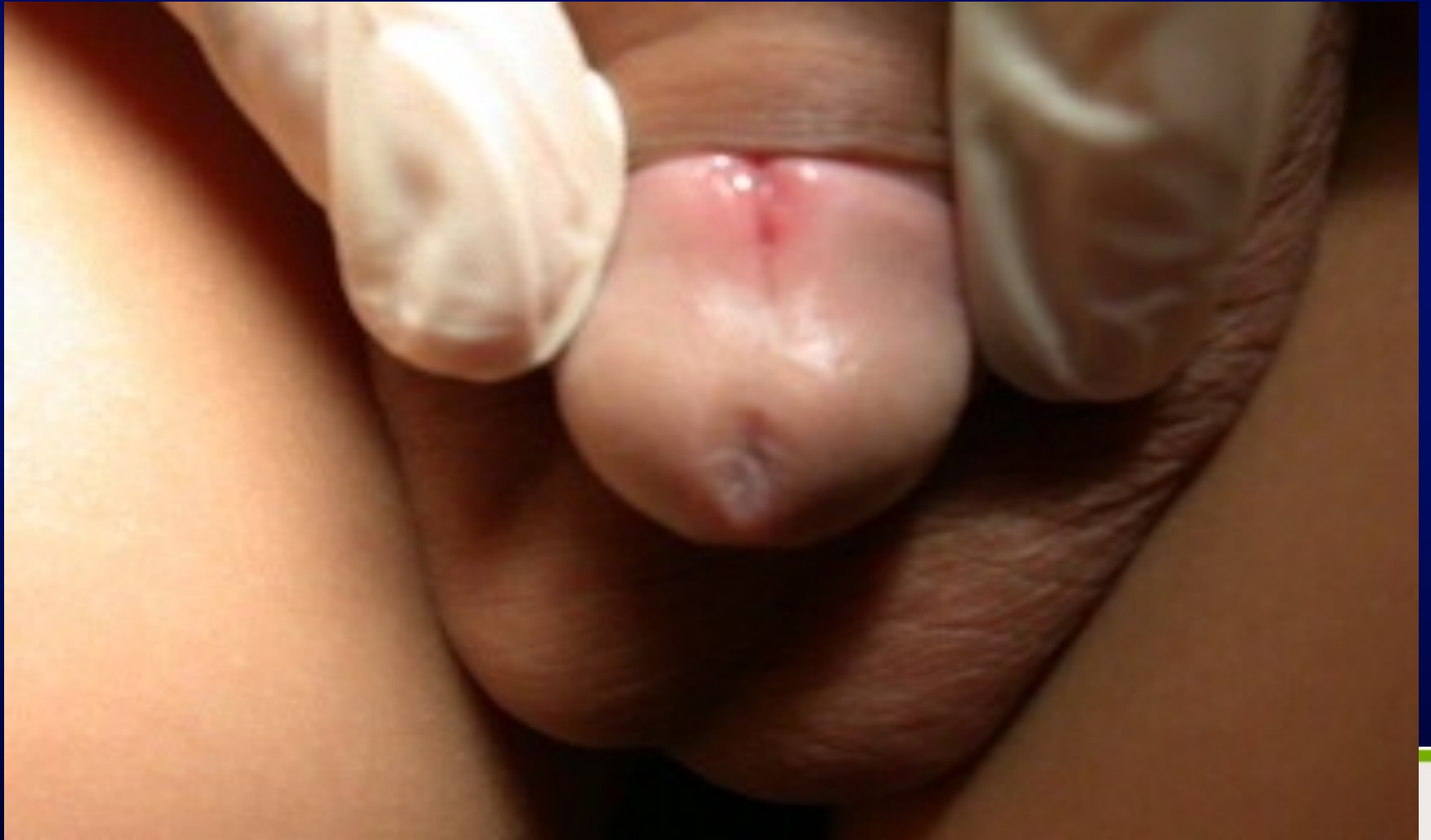






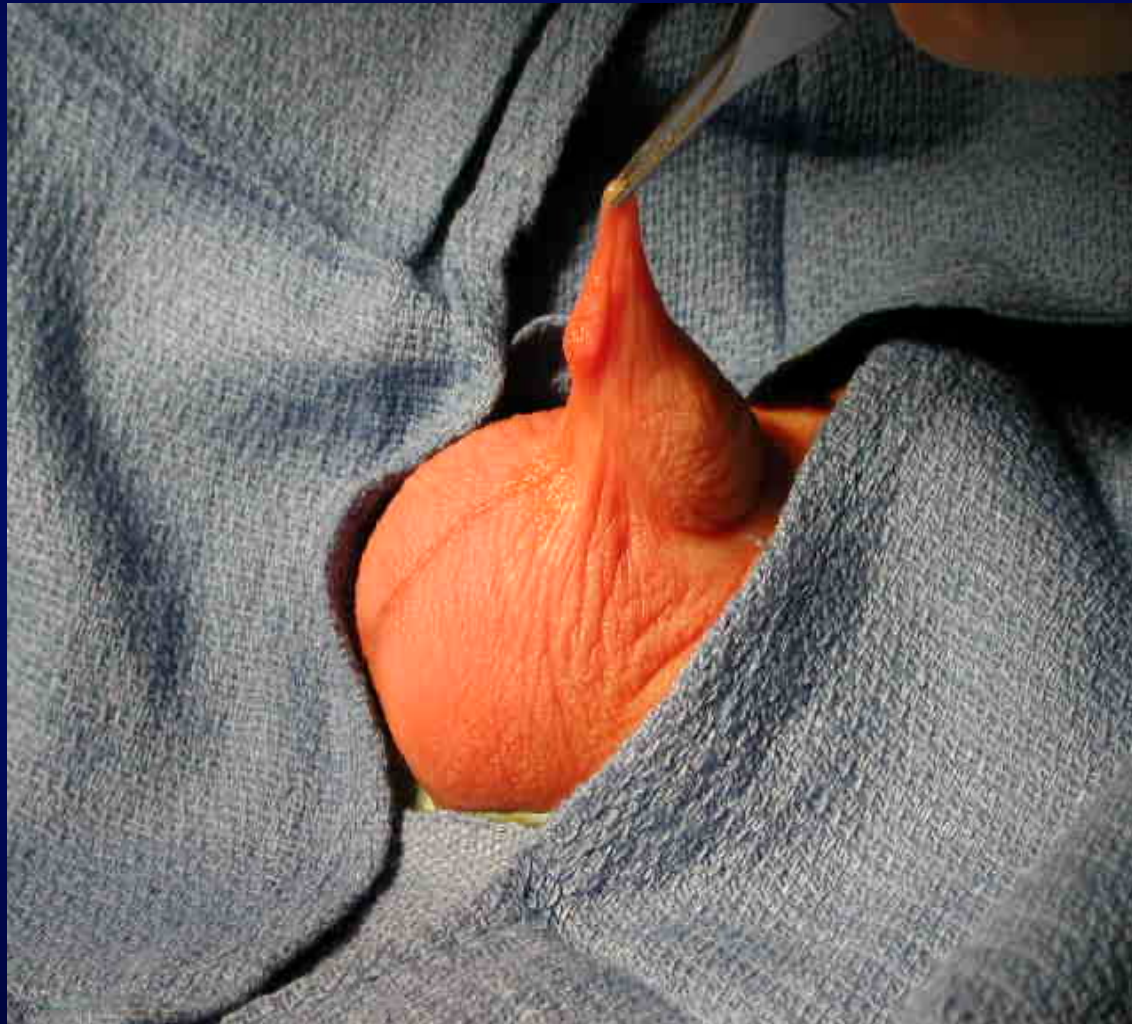
Epispadias



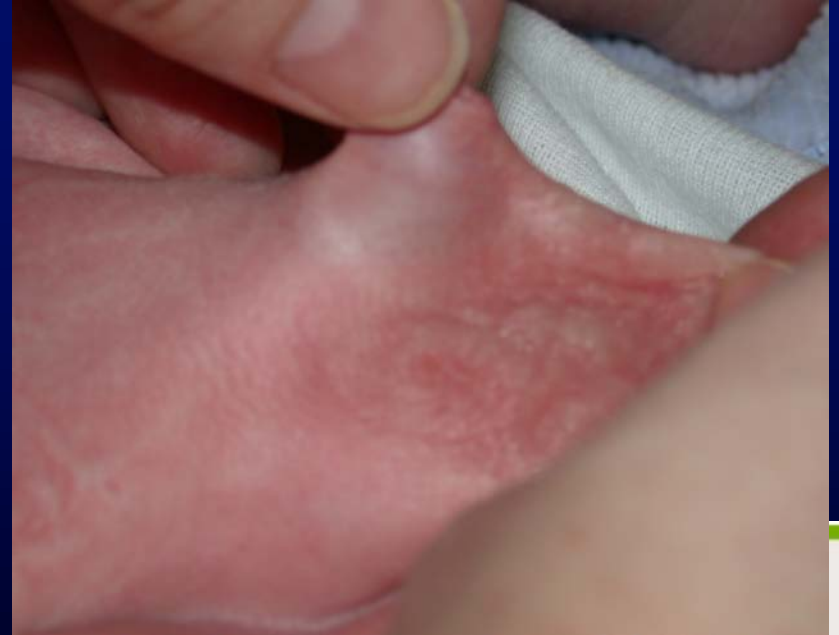
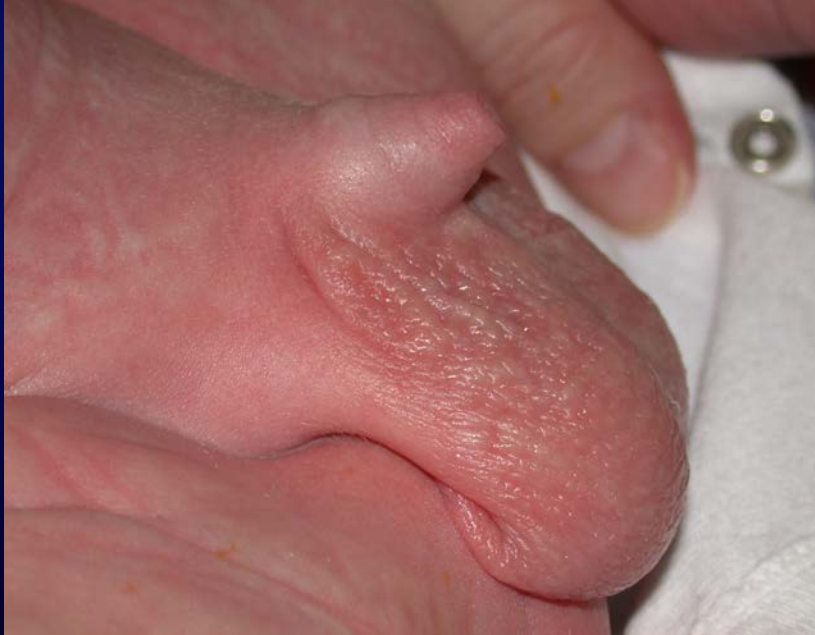
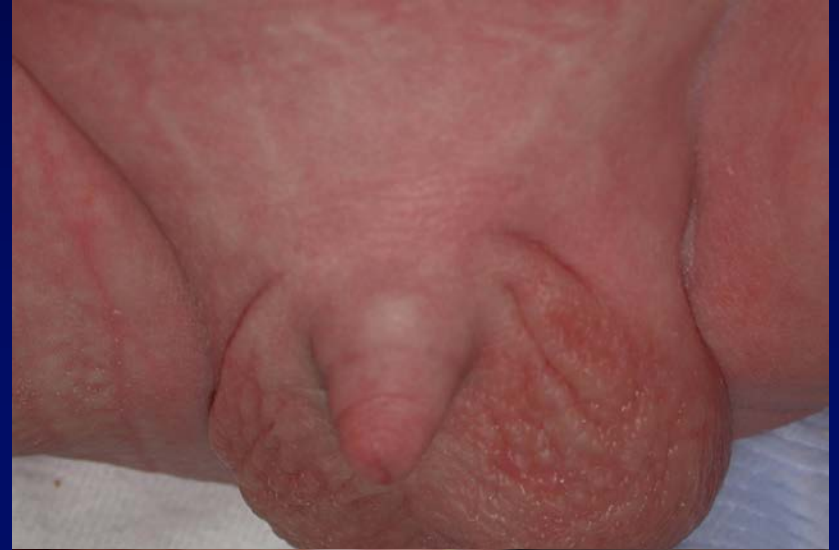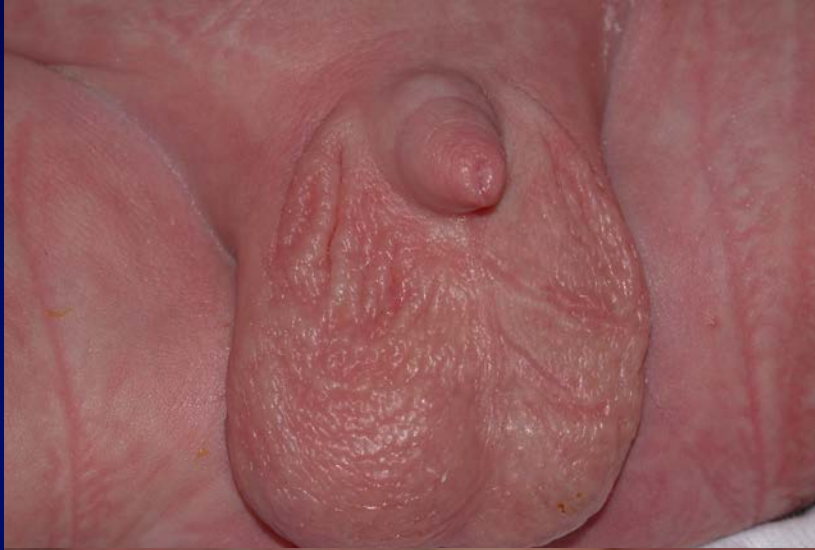Penoscrotal Webbing





Concealed Penis with Penoscrotal Web



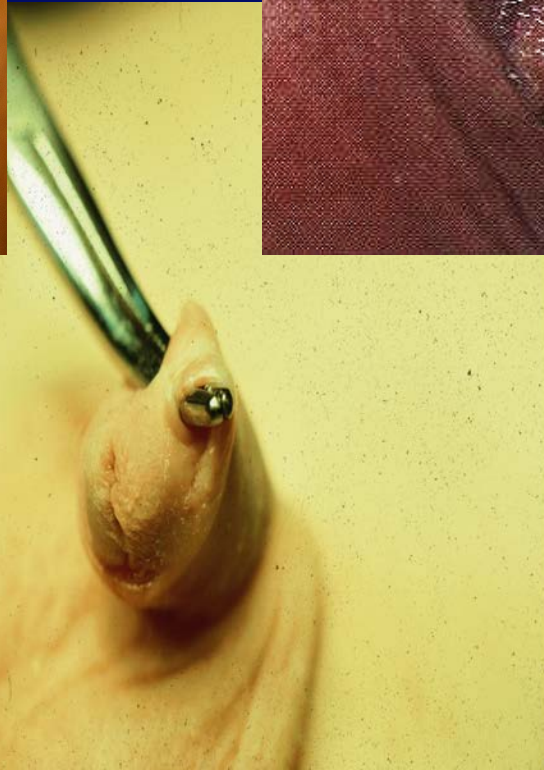
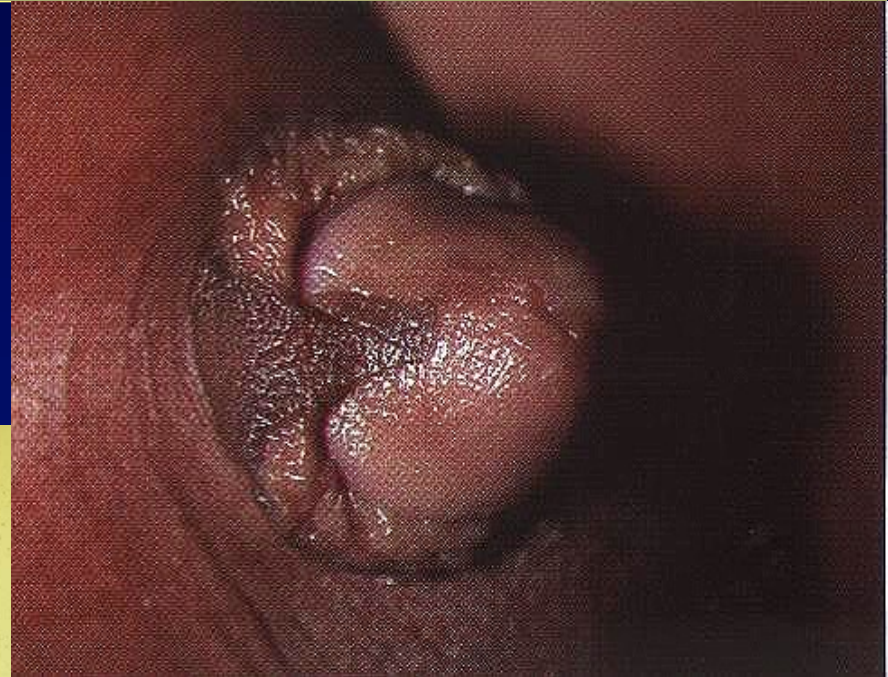
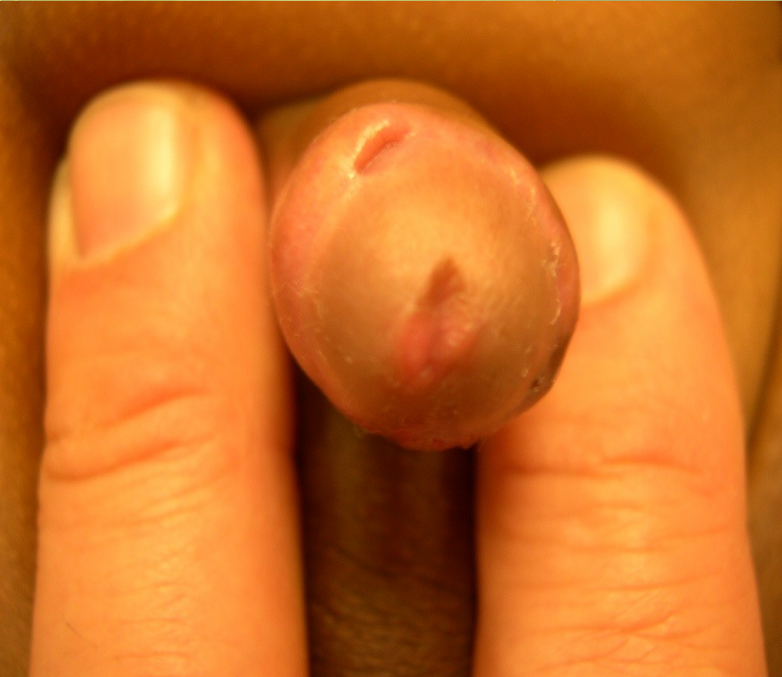
Circumcision Complications

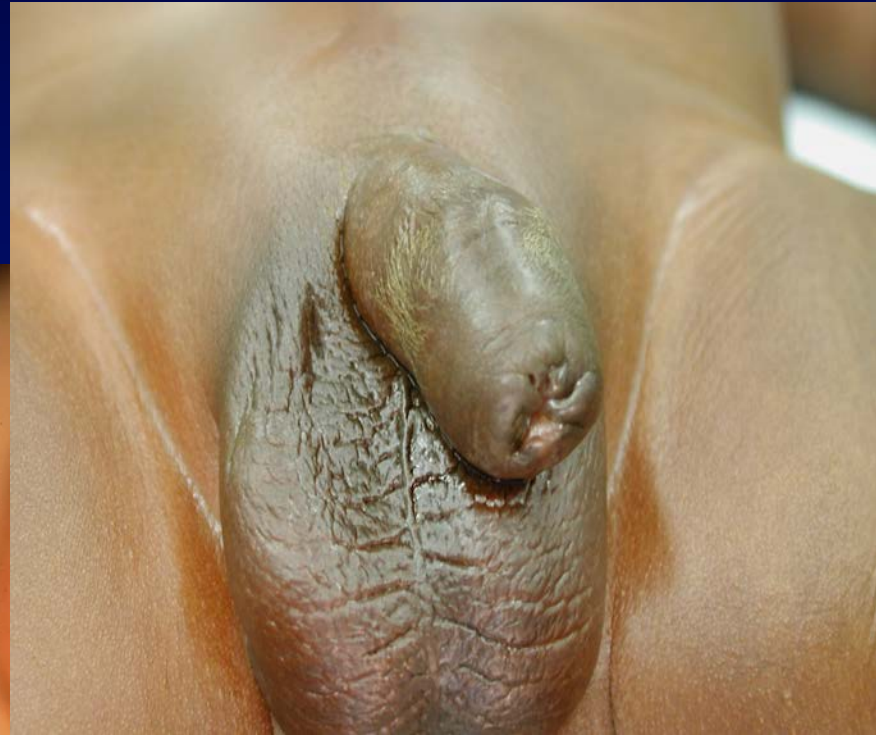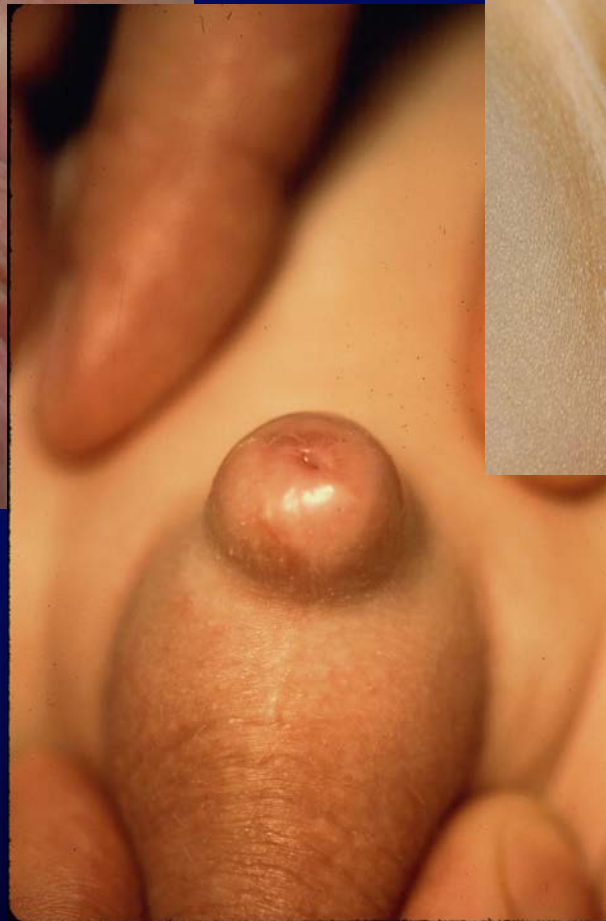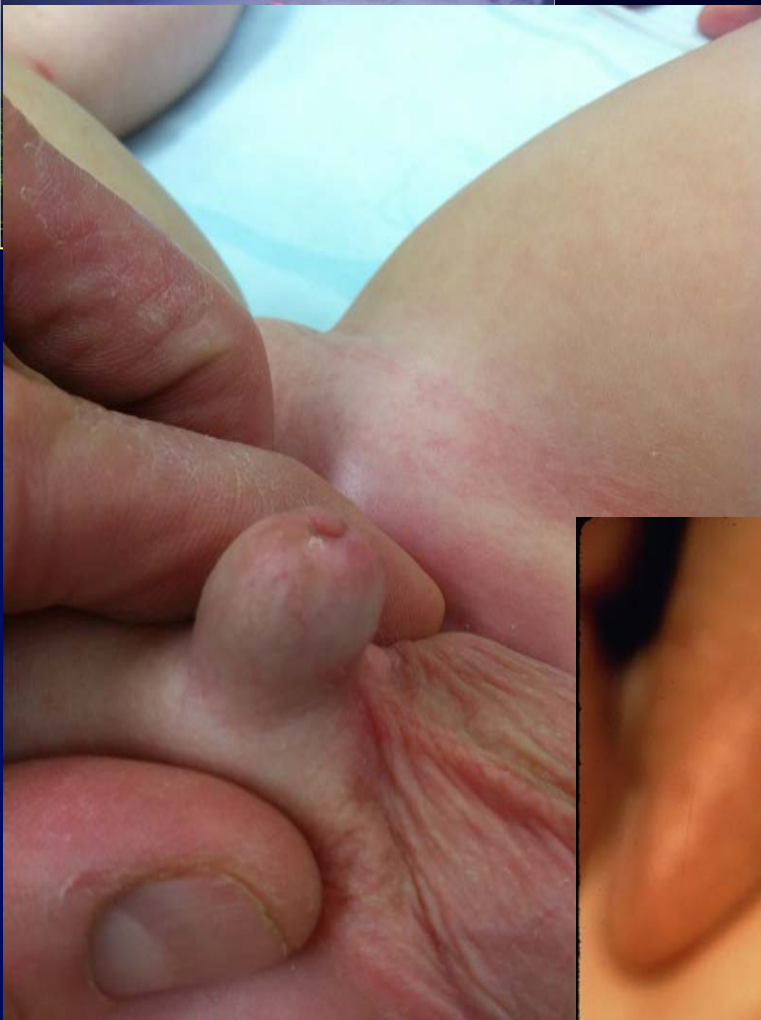- Bleeding
- Penile adhesions
- Cicatrix
- Redundant prepuce
- Meatal stenosis



Penile Adhesions

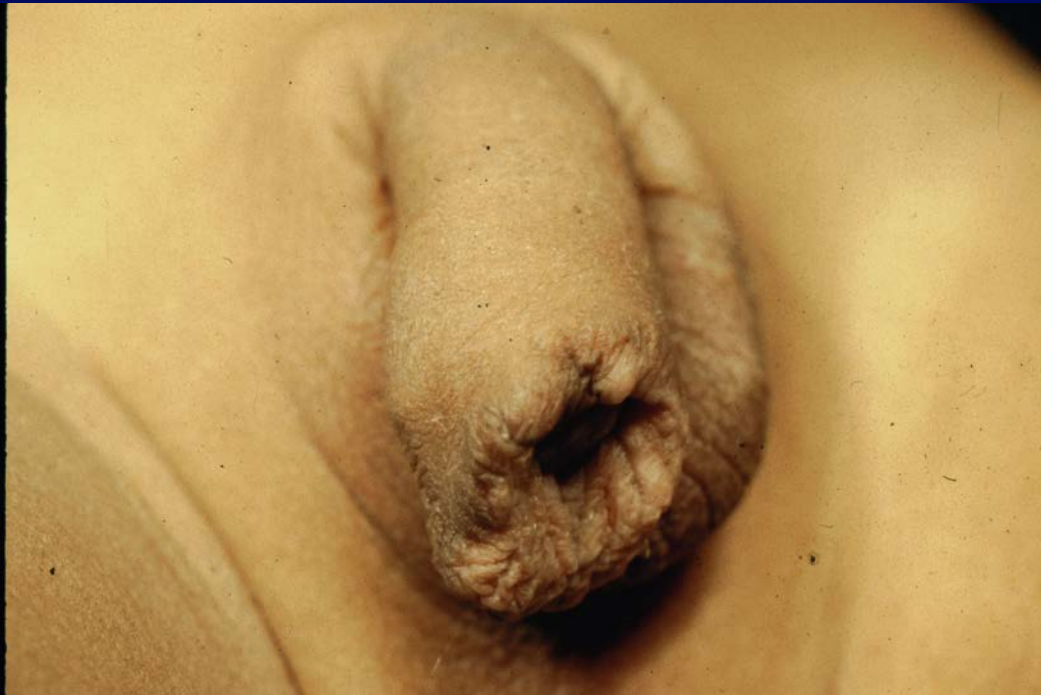

Cicatrix





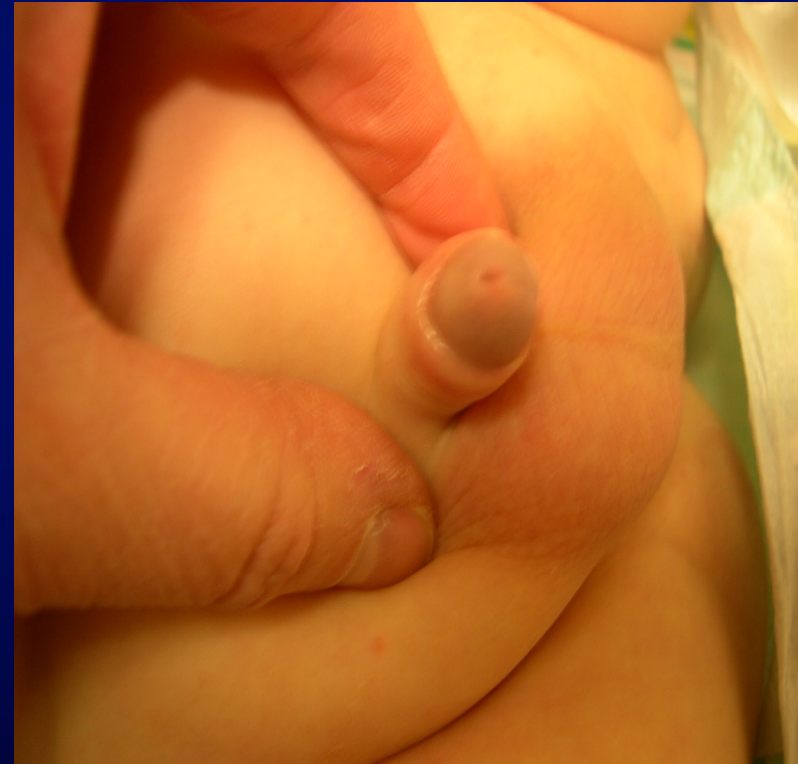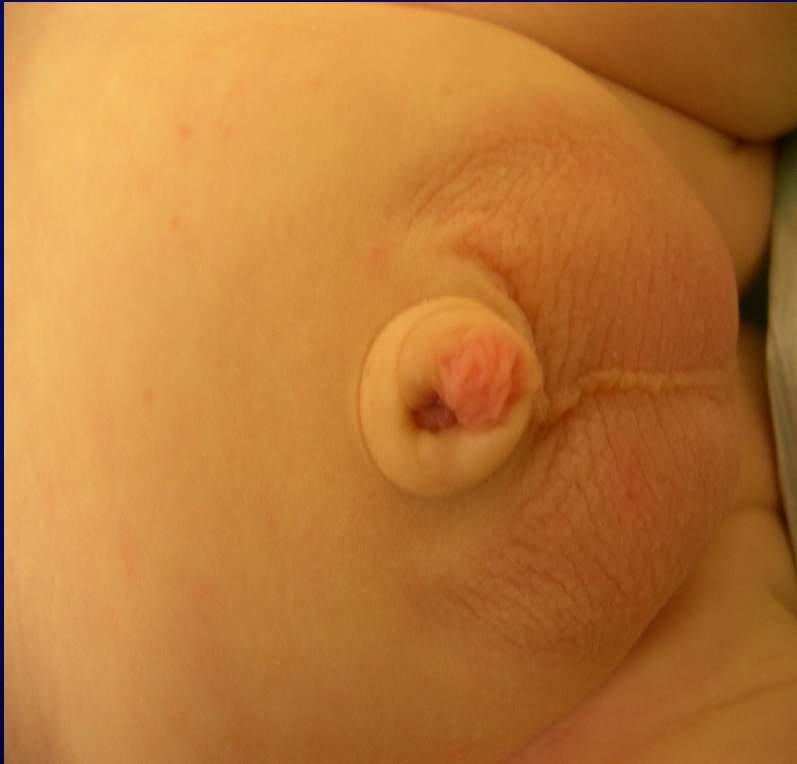Redundant Prepuce





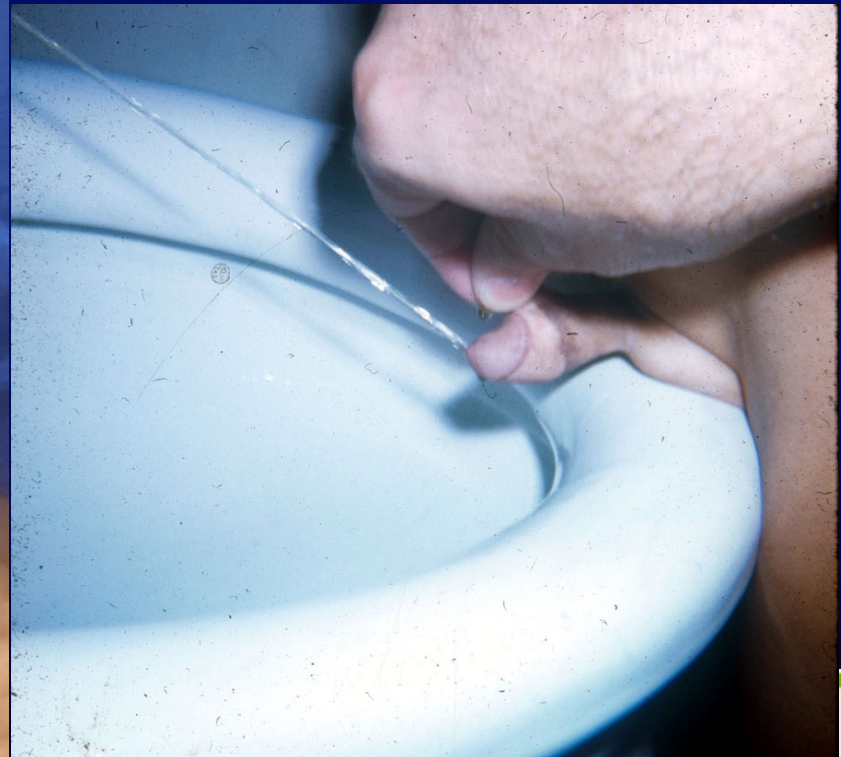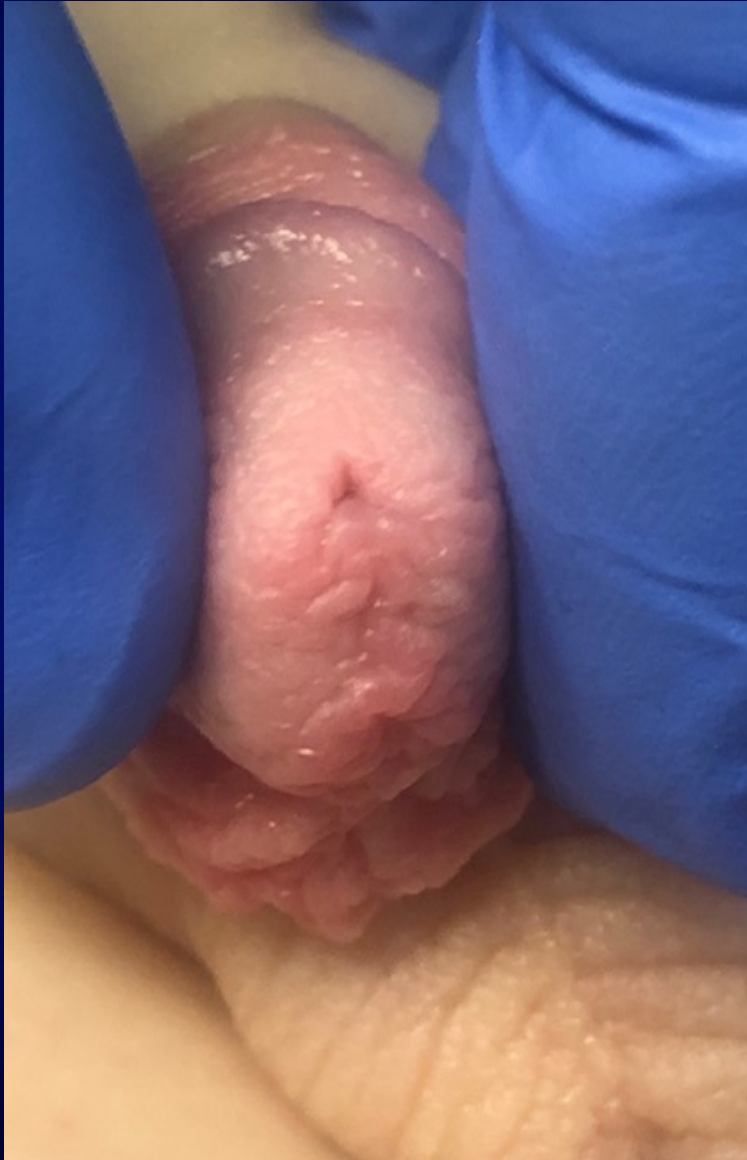Redundant Foreskin?

- Large prepubic fat pad



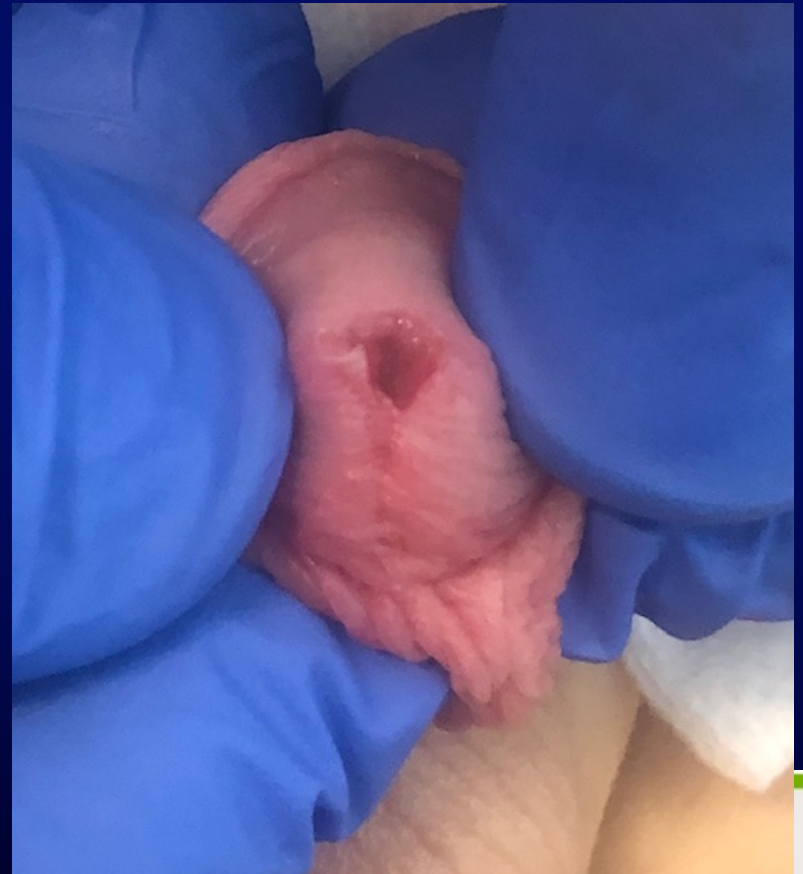
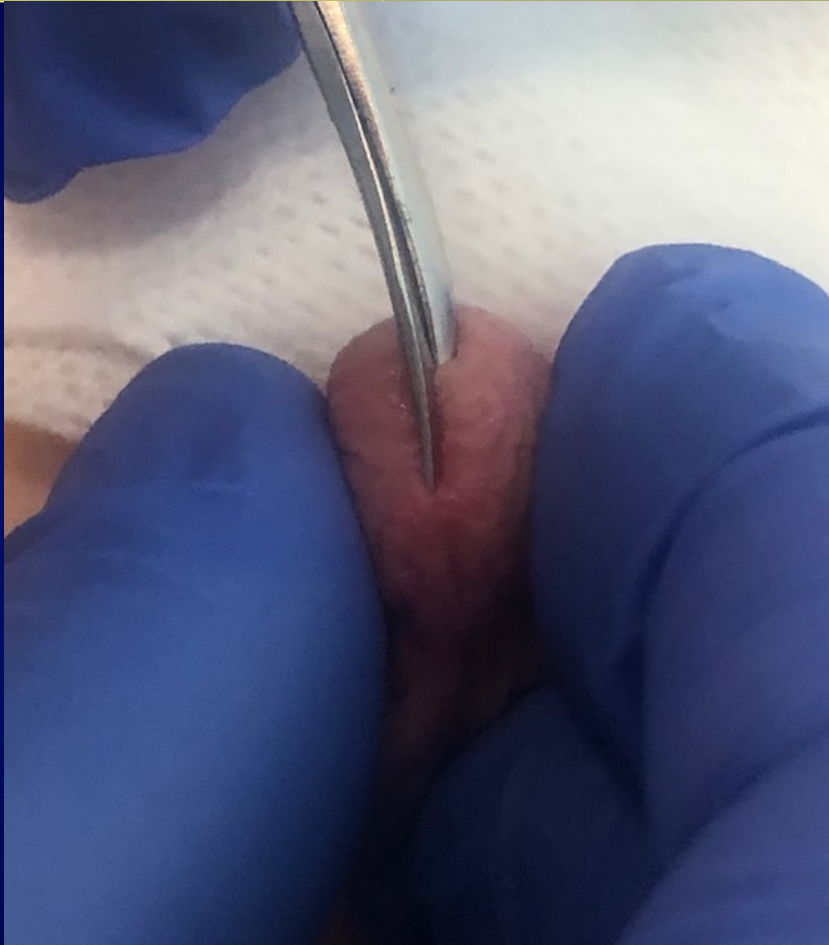
Meatal Stenosis





Meatotomy





Toilet Seat Glans Injury

