



Brace Yourself: Orthopedic Splinting Workshop

BY TRIA DENINNO, MPAS, PA-C AND
TARA MCSWIGAN, MPAS, PA-C

Disclosures

We have no relevant relationships with ineligible companies to disclose within the past 24 months. (Note: Ineligible companies are defined as those whose primary business is producing, marketing, selling, re-selling, or distributing healthcare products used by or on patients.)

Objectives

At the conclusion of this session, participants should be able to

- Identify common extremity injuries that warrant immobilization with splinting
- Execute proper techniques and placement of upper and lower extremity splints
- Appreciate contraindications to splint use, as well as post application complications

Who's Who?

Depending on healthcare or community demographic, splinting can be utilized in several disciplines

- Orthopedic providers
- Emergency Medicine providers
- Urgent Care providers
- Primary Care providers

Why Splint?

- Immobilize/stabilize injuries
- Promote and expedite healing
- Prevent exacerbation of injuries
- Improve pain

Splinting Features

- Non-circumferential – allows for swelling to occur without risk for complications
- Temporary (3-5 days)
- Easily Removable – monitoring of skin conditions
- Quick application

Which Injuries Can Be Splinted?

- Fractures
- Sprains
- Tendon injury/rupture
- Inflammation/tenosynovitis
- Soft tissue infections/cellulitis

Consider the Mechanics

When approaching an injury...

Use clinical history to narrow differential

+ Understand mechanics of the injury

Anticipate specific injury and confirm with exam findings and imaging

Radiographic Imaging

- Intended to confirm suspected mechanical injury with visualized details
 - Obvious fractures (angulation, alignment)
 - Presumed fractures based on other radiographic findings (fat pads, patterns of swelling)
 - Dislocations/subluxations
- Focus on your exam findings, which may or may not be demonstrated on imaging

Application of Splint - Supplies

- Supplies needed
 - Cool water
 - Towel
 - Measuring tape
 - Scissors
 - Elastic bandages
 - Splinting material (fiberglass vs. plaster)
 - Plaster – limited by drying time, user experience
 - Fiberglass – lighter, more porous, more expensive
 - Assistant
- Have ALL supplies ready before splint is applied

Splint Sizing

- Splinting material comes in a range of width sizes (1 inch-6 inch)
- Upper extremity
 - Adult: 2-4 inch width
 - Pediatric: 1-3 inch width
- Lower Extremity
 - Adult: 4-6 inch width
 - Pediatric: 2-3 inch width

Application of Splint

- Pre-splinting Procedures
 - Address all skin abnormalities (lacerations, wounds, open fractures)
 - Assess for skin tenting/prominences
 - Remove all jewelry (watches, bracelets, rings)
 - Address pain needs
 - Check neurovascular status – must document!
 - Circulation (pulses, capillary refill)
 - Motor function
 - Sensation

Application of Splint

- Ensure splint edges are covered
- Use elastic bandage to wrap extremity starting distally and moving proximally (avoid wrapping too tightly)
- Smooth splinting material with palm of hand to prevent wrinkles/ridges in splinting material
- When able, splint the joint above and the joint below fracture

Application of Splint

- Positioning of splint
 - Proper alignment of splint is key to promote optimal healing and prevent complications
- Position of function
 - Wrist – slight dorsiflexion with fingers flexed
 - Elbow – 90 degree flexion
 - Ankle – 90 degree flexion (one exception)

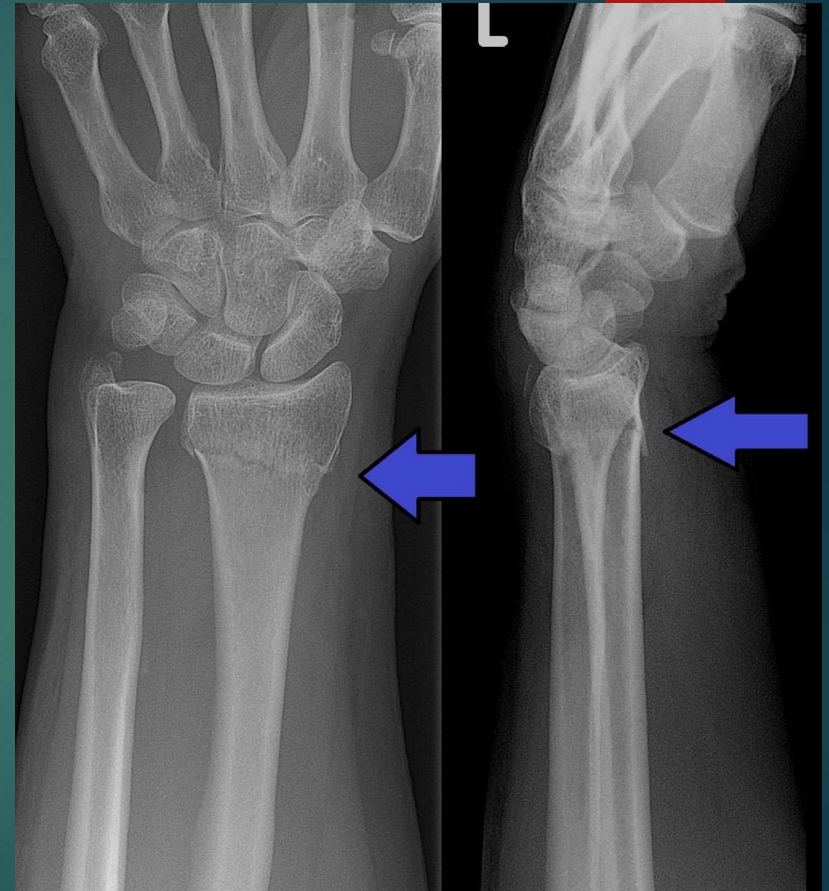Application of Splint - Aftercare

- Post-Splinting Procedure
 - Check and document neurovascular status
 - Circulation (capillary refill, pulses)
 - Motor
 - Sensation
 - Splint care/patient instructions
 - Ice and elevation
 - Keep clean and dry
 - Instruct patient to continue to monitor neurovascular status
 - Do not remove splint unless needed (wound care, compromised neurovascular status)
 - Instructions for follow-up specialty care (2-3 days)

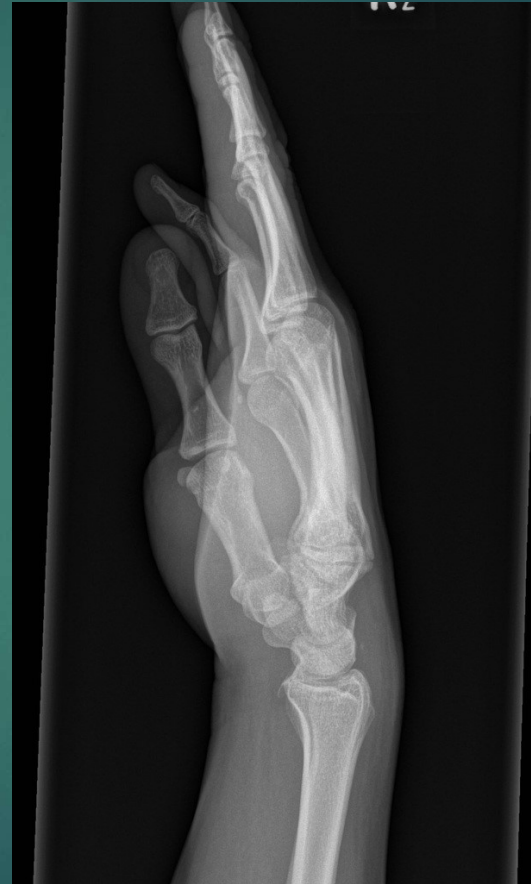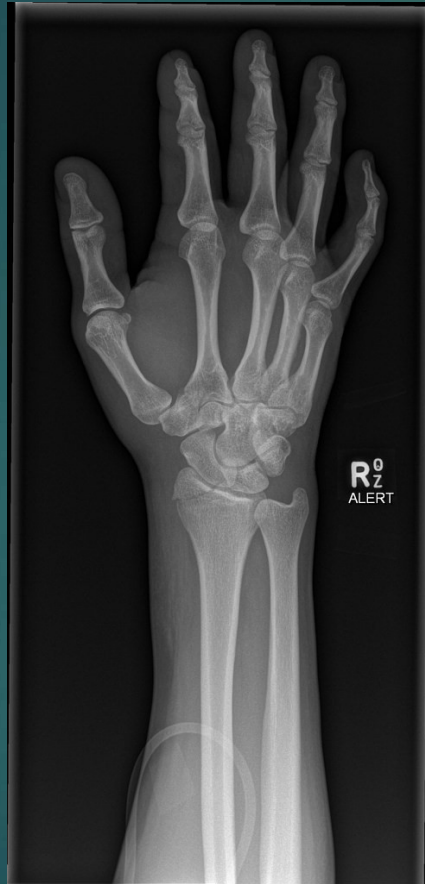Upper Extremity Splints: Volar

- Stabilization against flexion/extension of wrist and MCP joints
- Indications
 - Stable distal radius and/or ulnar fractures
 - Buckle fractures
 - 2nd-3rd metacarpal fractures
 - Wrist sprains
 - Synovial infections (extensor tenosynovitis due to animal bites, puncture wounds)

<https://commons.wikimedia.org/wiki/File:Collesfracture.jpg>

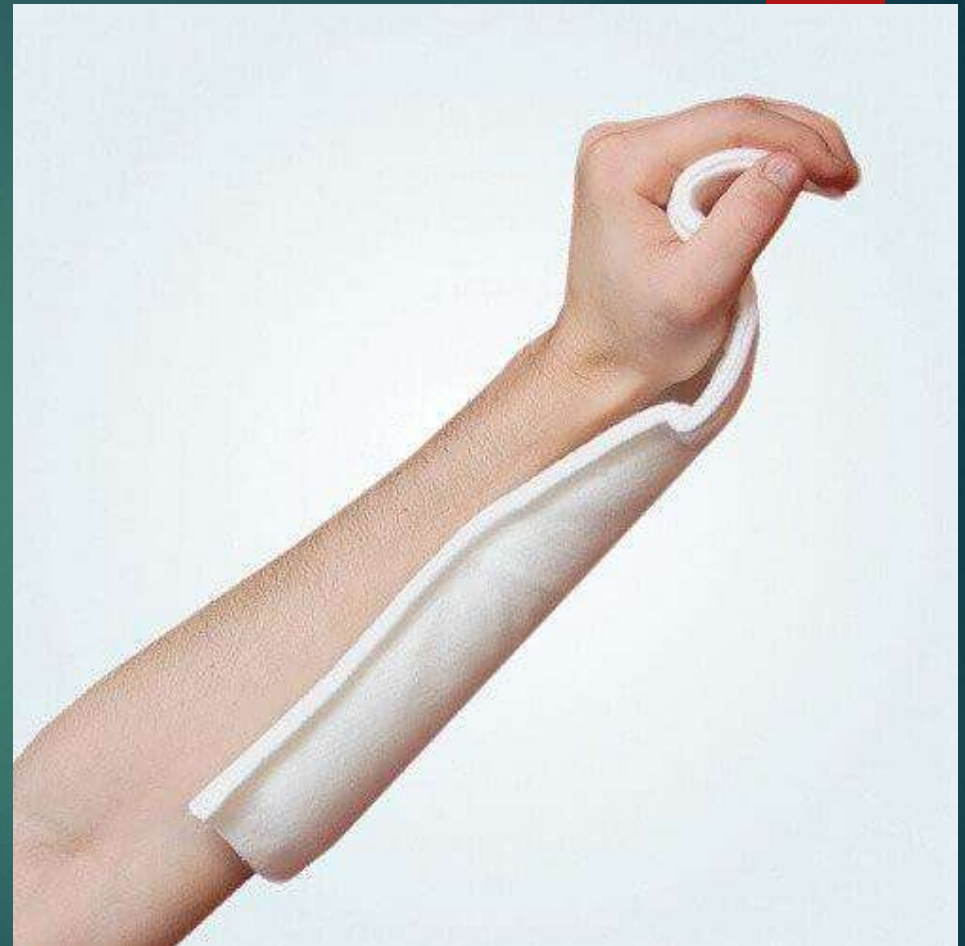


Upper Extremity Splints: Volar

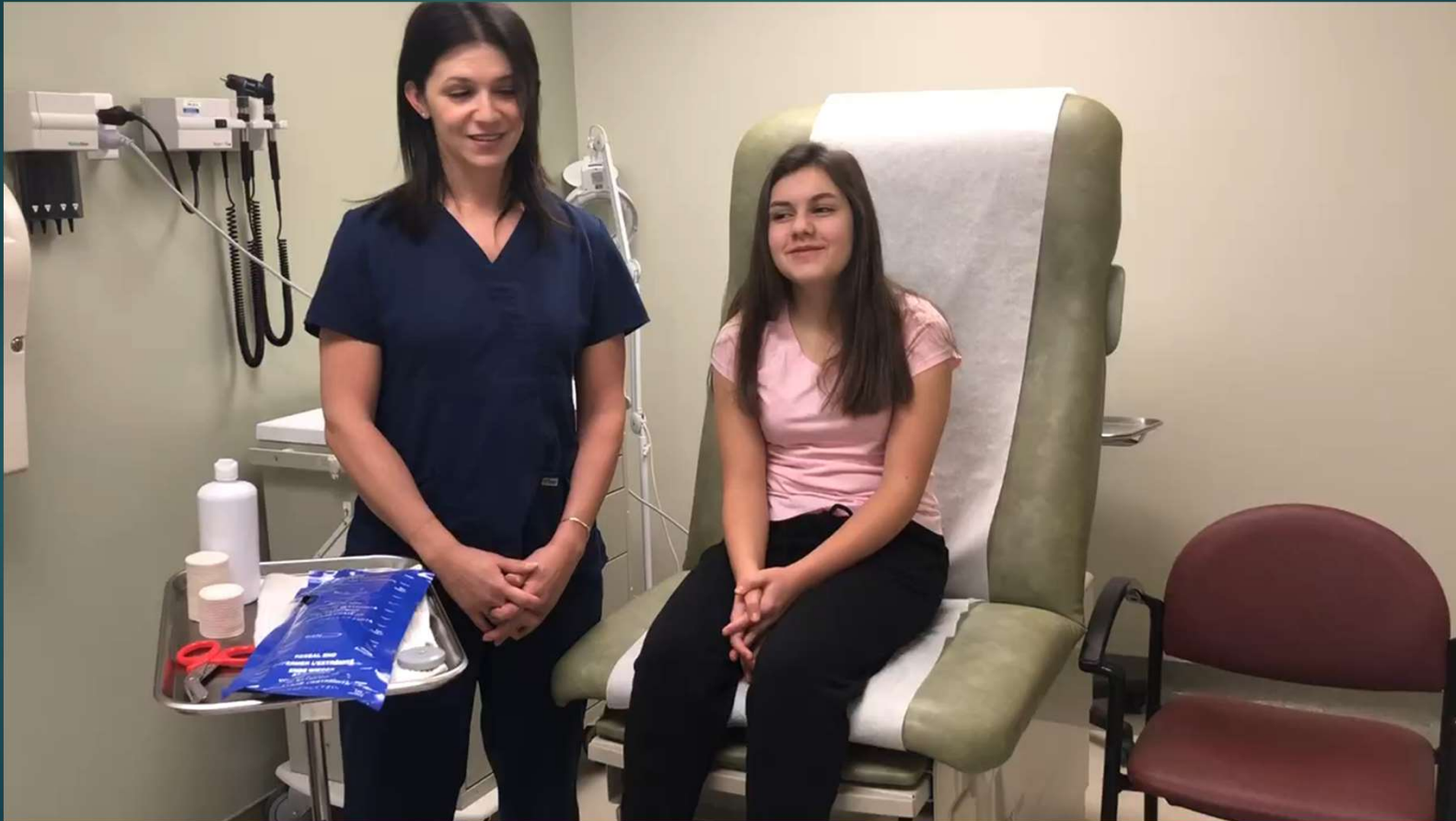

Upper Extremity Splints: Volar

- Splint width:
 - Adult 3-4 inch
 - Child 2-3 inch
- Distribution
 - Palmar crease to 2 inches distal to elbow
 - Slight dorsiflexion of wrist and flexion of fingers



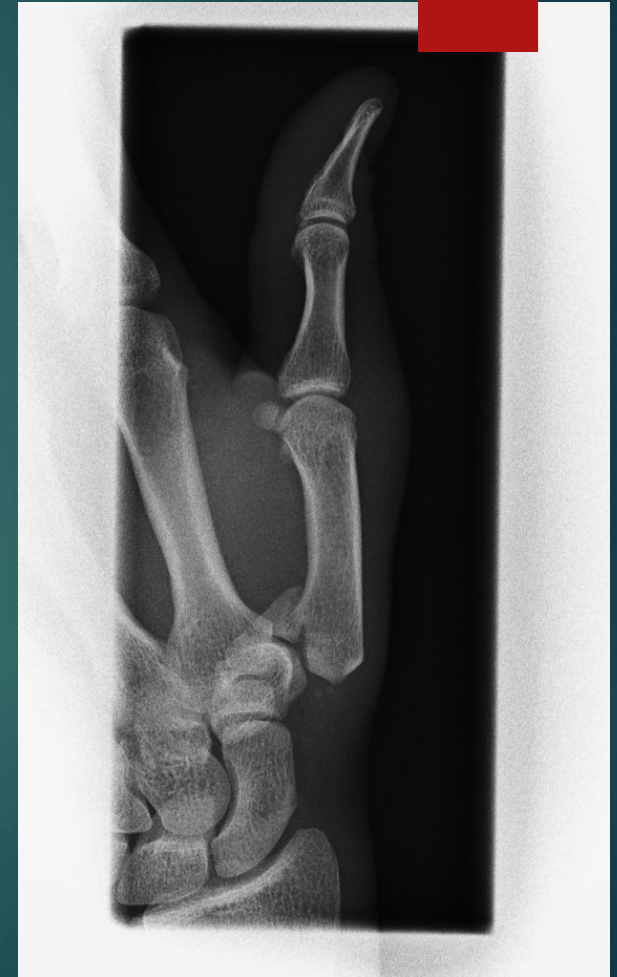Volar Splint Application



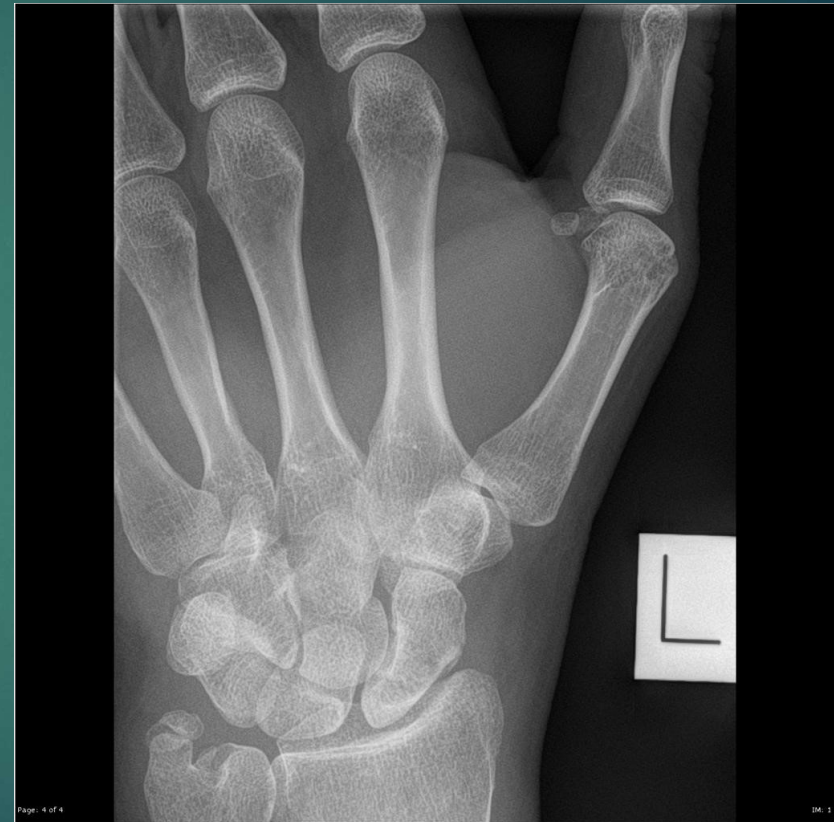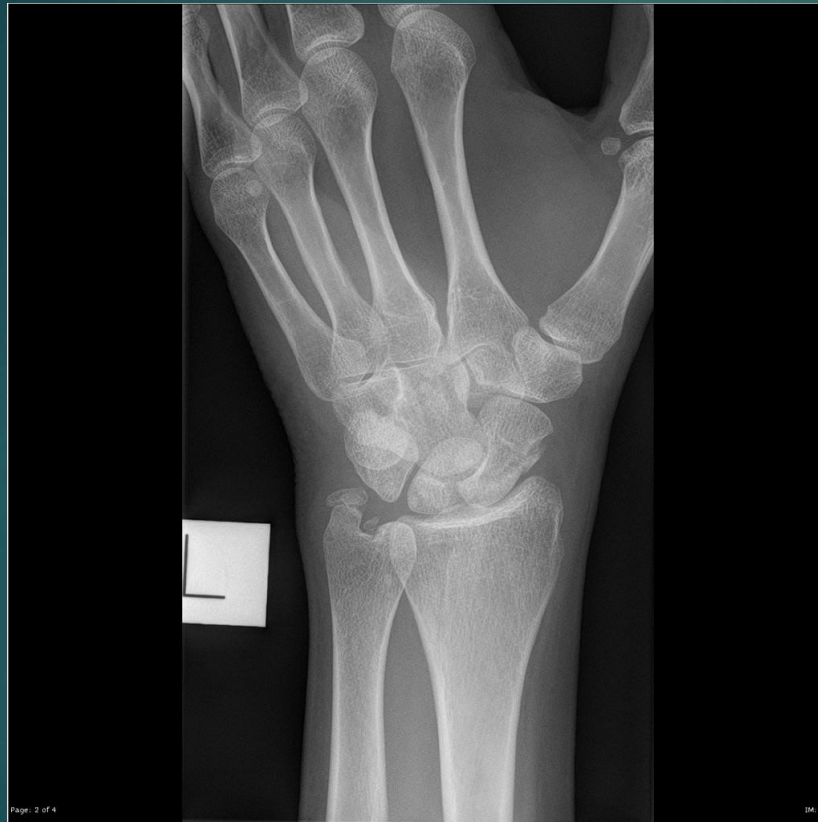Upper Extremity Splints: Thumb Spica

- Indications
 - Thumb fractures
 - Thumb Dislocation (post reduction)
 - 1st metacarpal fractures
 - Navicular/scaphoid fractures
 - DeQuervain's tenosynovitis

<https://www.google.com/url?sa=i&url=https%3A%2F%2Fwww.flickr.com%2Fphotos%2F6x7%2F437545989&psig=AOvVaw3Y8mF1GKDd7ntv8TOEDwNL&ust=1645459133057000&source=images&cd=vfe&ved=0CAsQjRxqFwoTCKC70JnTjvYCFQAAAAAdAAAAABAK>

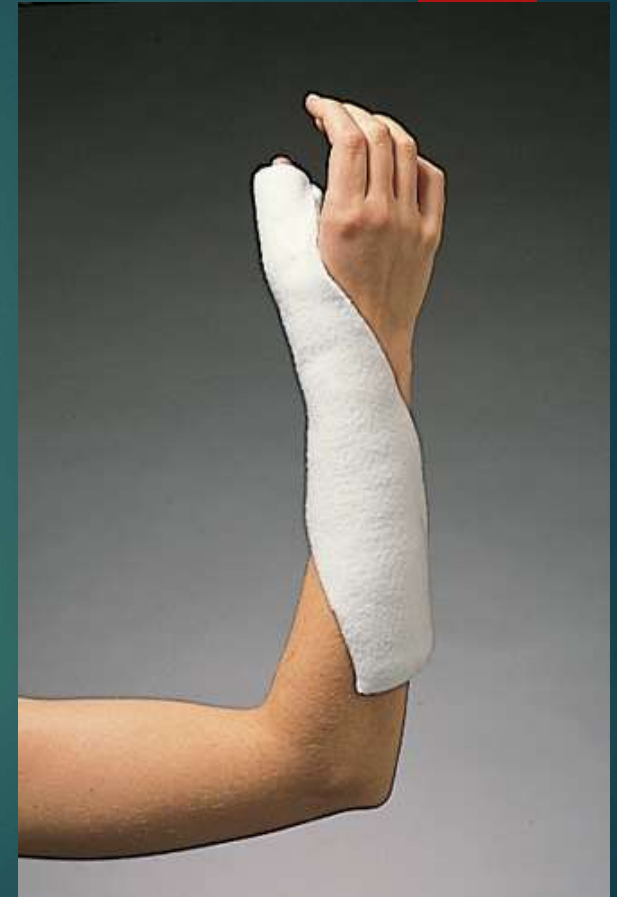

Upper Extremity Splints: Thumb Spica

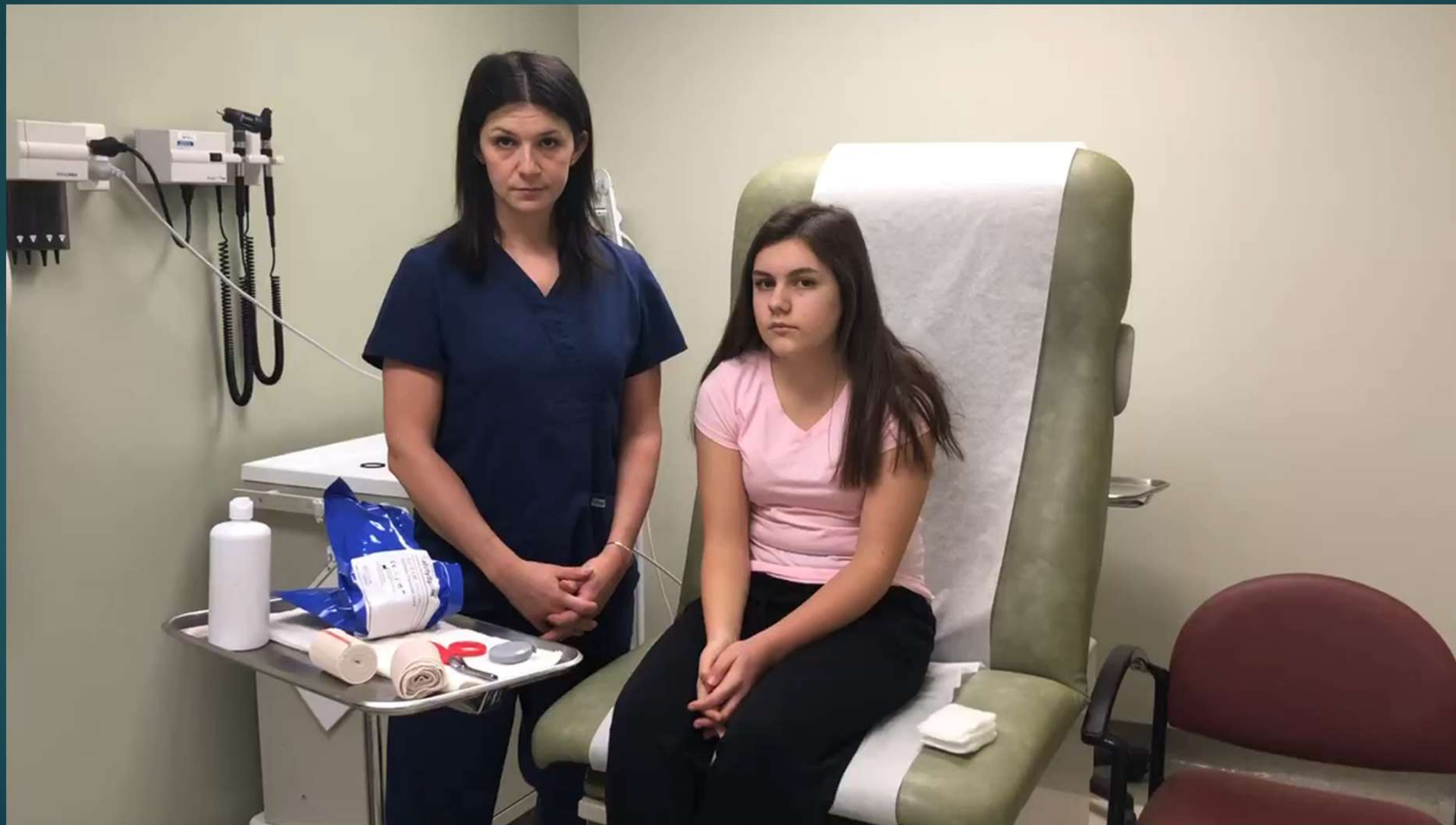

Upper Extremity Splints: Thumb Spica

- Splint width:
 - Adult 2-3 inch
 - Child 1-2 inch
- Distribution
 - Tip of thumb around dorsal forearm to 2 inches distal to elbow on ULNAR side
 - Slight dorsiflexion of wrist



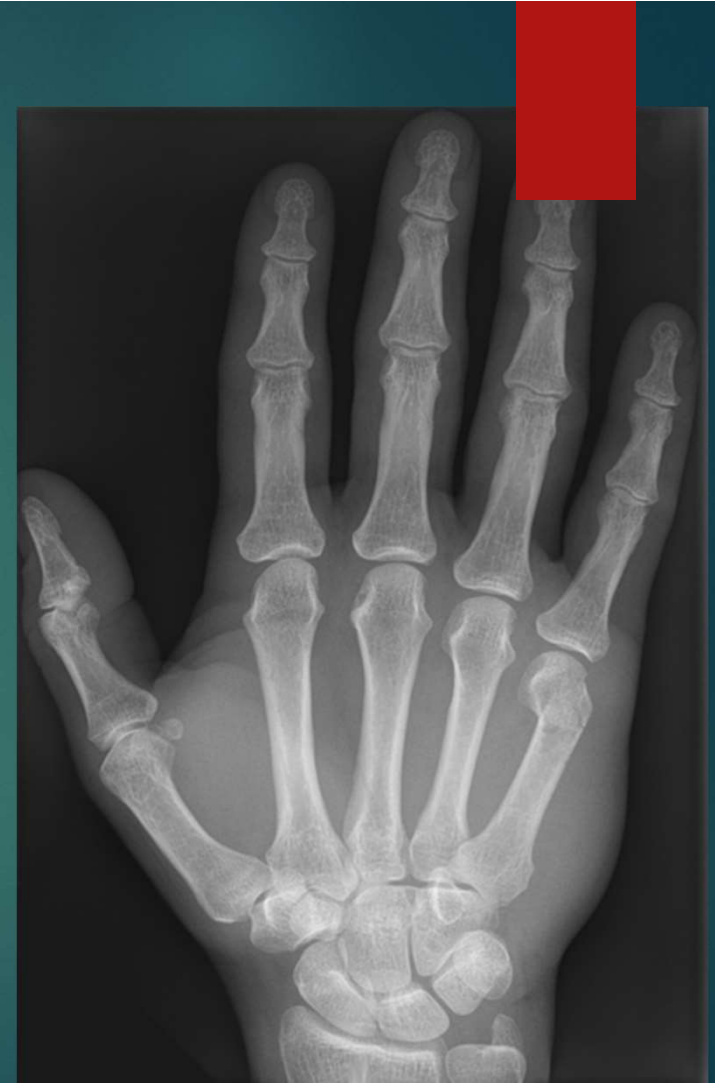Thumb Spica Application



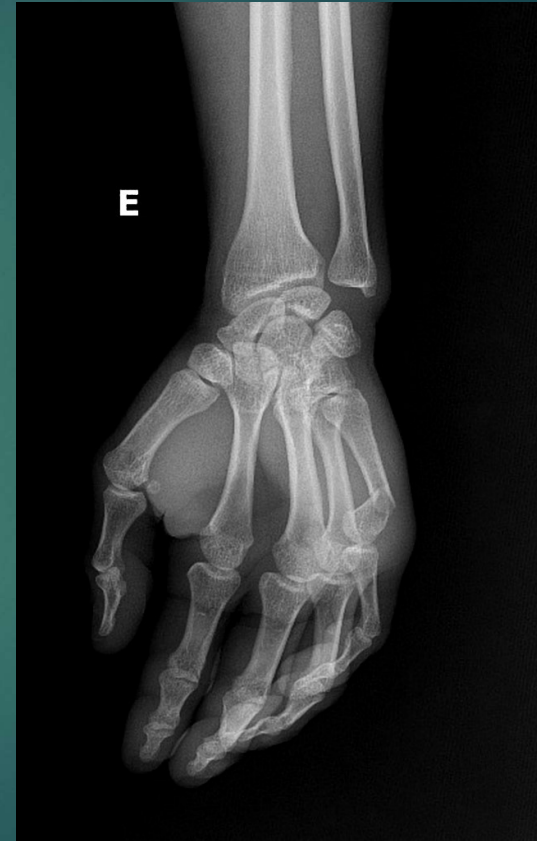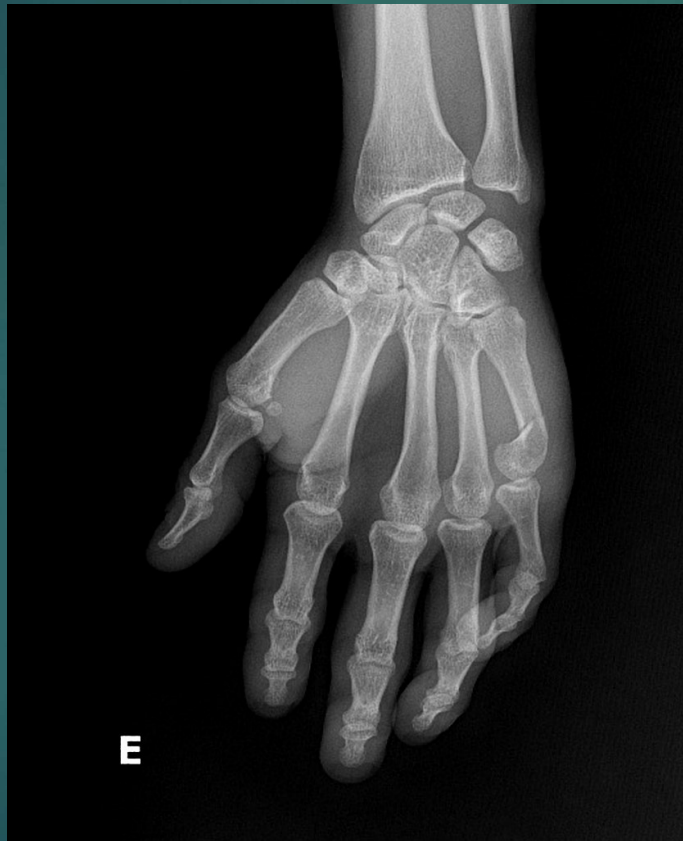Upper Extremity Splints: Boxer/Ulnar Gutter

- Indications
 - Fracture of 4th or 5th metacarpal bones (Boxer's fracture)
 - Isolated ulnar styloid fracture

<https://commons.wikimedia.org/wiki/File:Boxerfraktur.png>

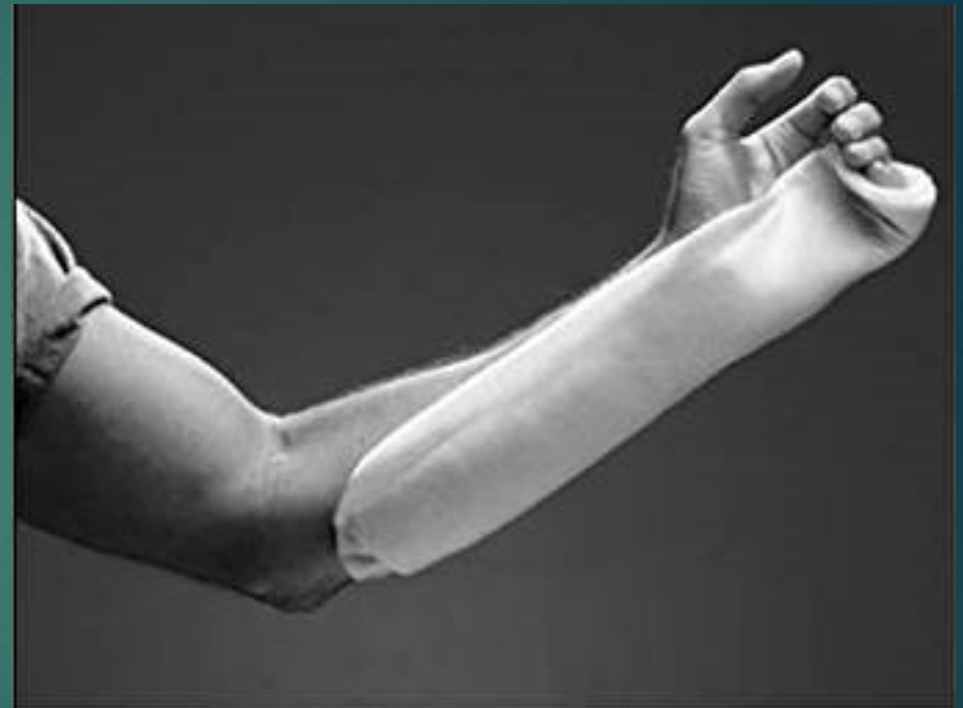

Upper Extremity Splints: Boxer/Ulnar Gutter



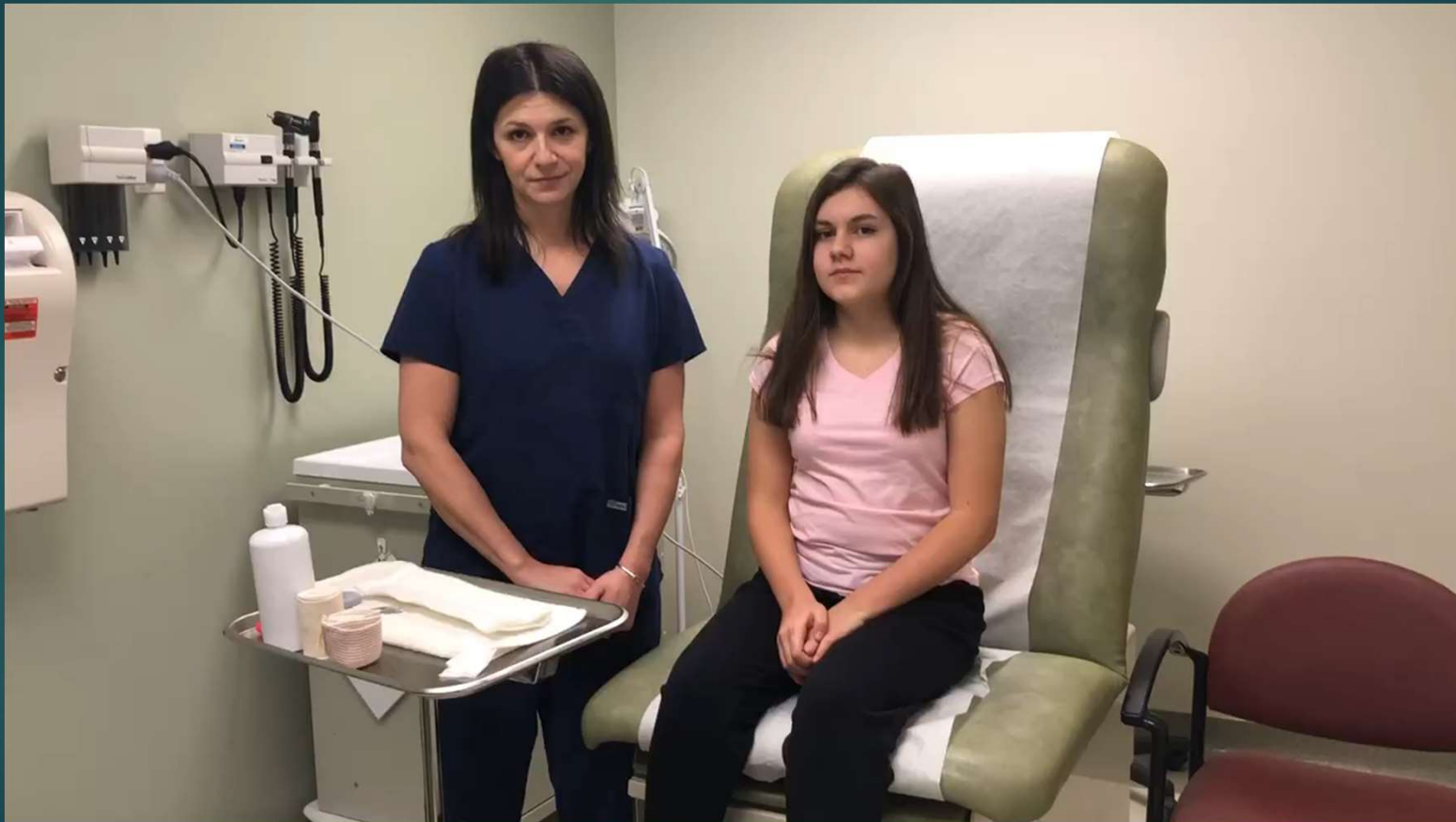Upper Extremity Splints: Boxer/Ulnar Gutter

- Splint width:
 - Adult 3-4 inch
 - Child 2-3 inch
- Distribution
 - Tip of 5th finger (including 4th finger) forming gutter around forearm on ulnar side to 2 inches distal to elbow
 - Slight dorsiflexion of wrist



<https://www.amazon.com/3M-Scotchcast-Conformable-Splint-72335/dp/B01DME2XX2>

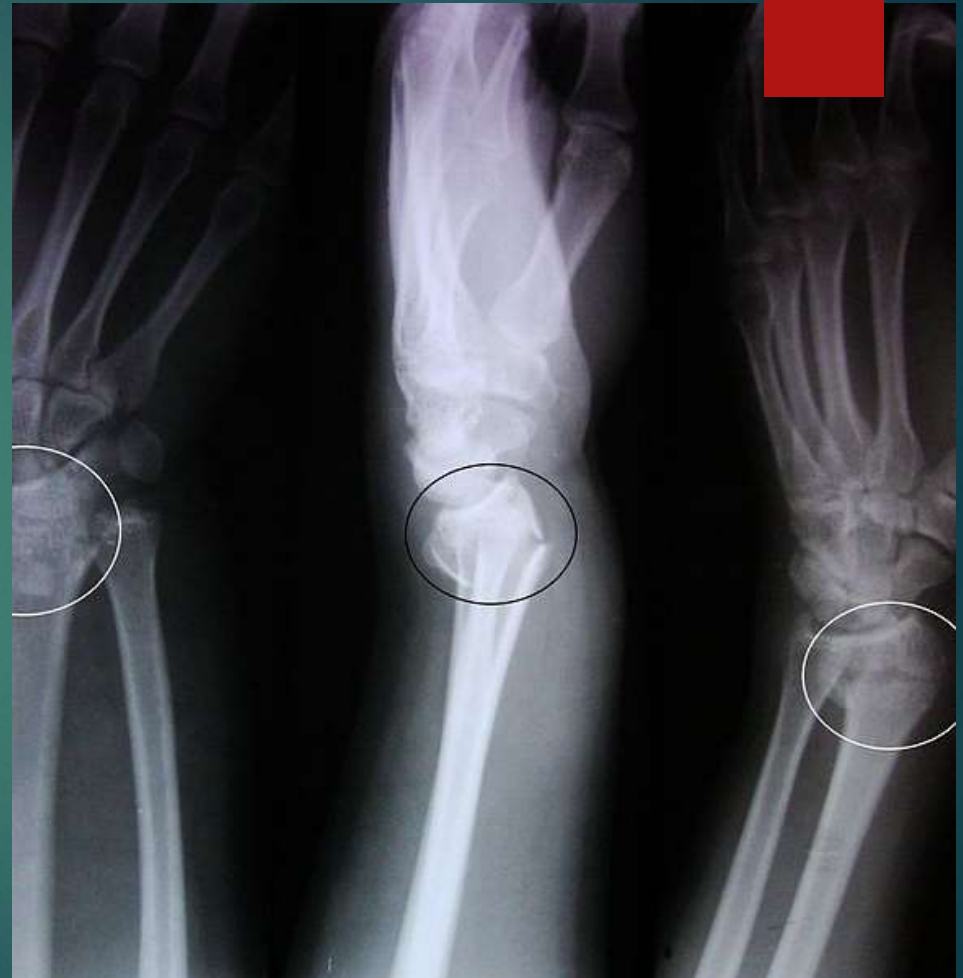Boxer Splint Video



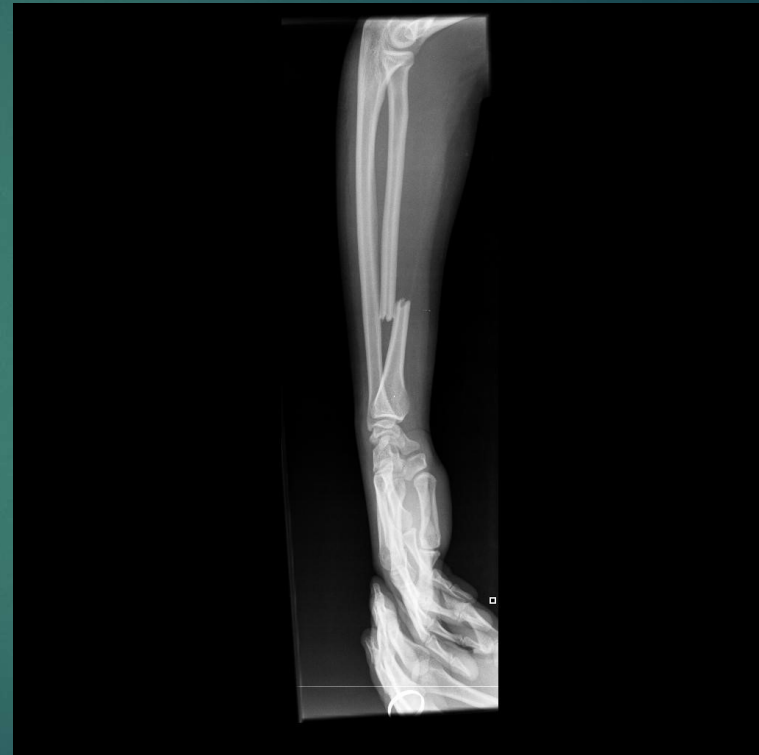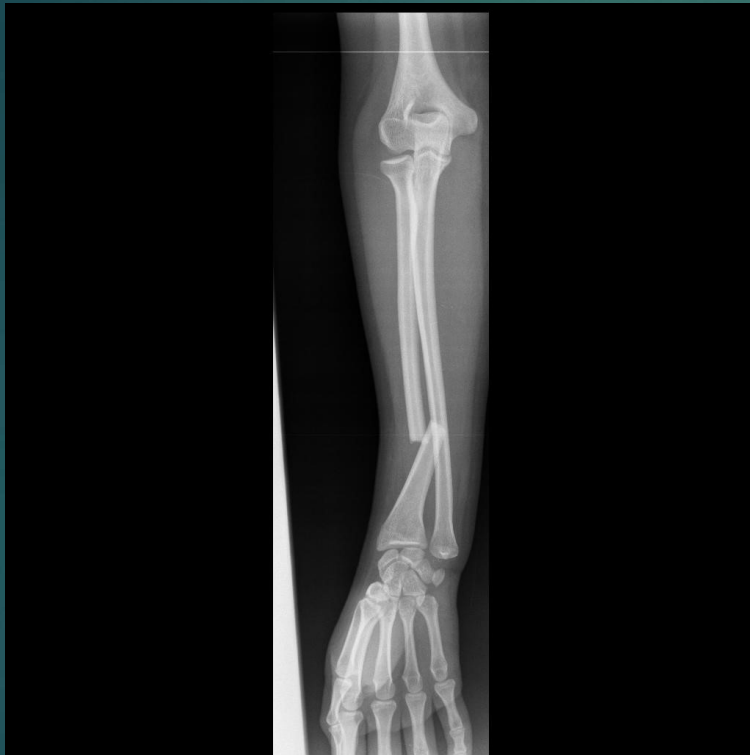Upper Extremity Splints: Sugar Tong

- Stabilizes against flexion/extension AND supination of wrist
- Indications
 - Colle's fractures (distal radius and ulnar fracture with dorsal displacement)
 - Unstable wrist fractures

<https://health.uconn.edu/msi/clinical-services/orthopaedic-surgery/hand-and-wrist/distal-radius-fracture-colles-fracture/>



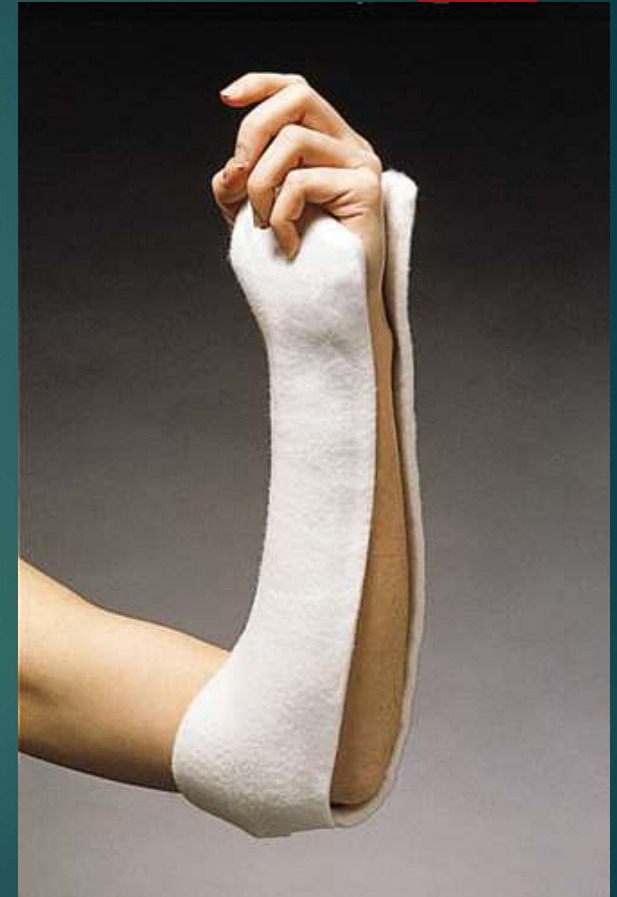Upper Extremity Splints: Sugar Tong



<https://radiopaedia.org/cases/distal-third-radius-fracture?lang=us>

Upper Extremity Splints: Sugar Tong

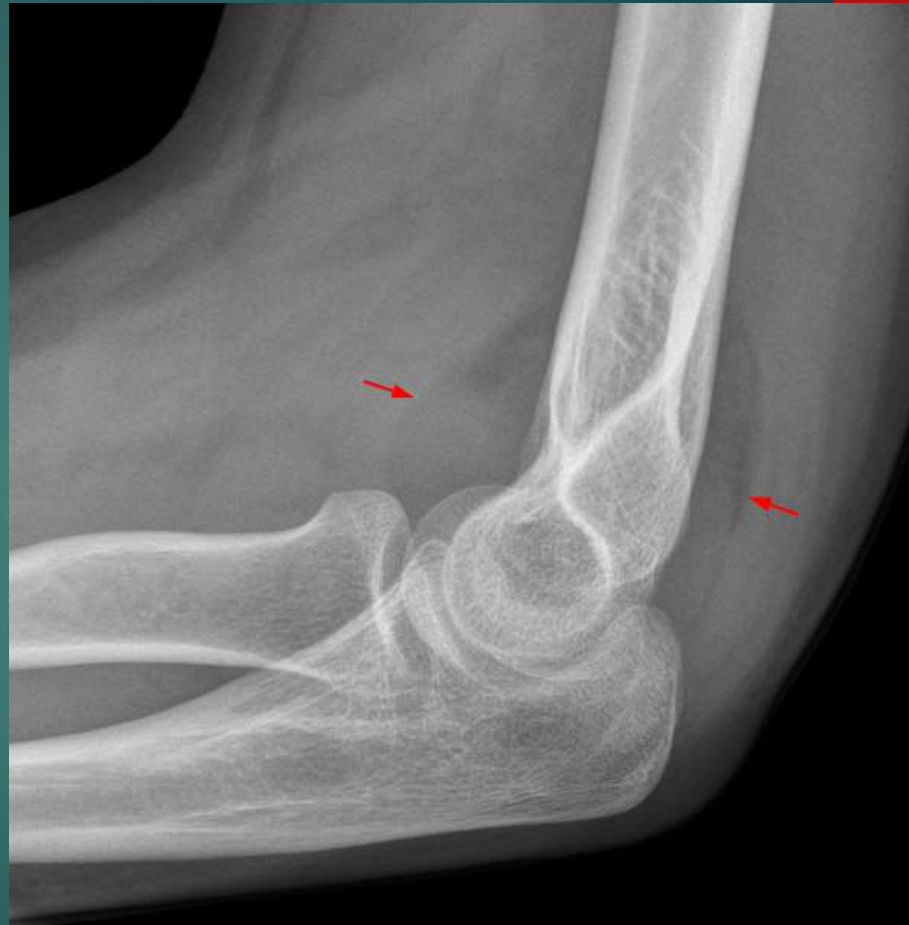- Splint width:
 - Adult 3-4 inch
 - Child 2-3 inch
- Distribution
 - Elbow flexed to 90 degrees
 - Splint from MCPs on palmar side, wrapping around elbow, to MCPs on dorsal side
 - Place extremity in sling after application of splint to prevent slippage with movement of extremity



Upper Extremity Splints: Long Arm

- Indications
 - Proximal forearm fractures/radial head fractures
 - Distal humerus fractures
 - Elbow sprain

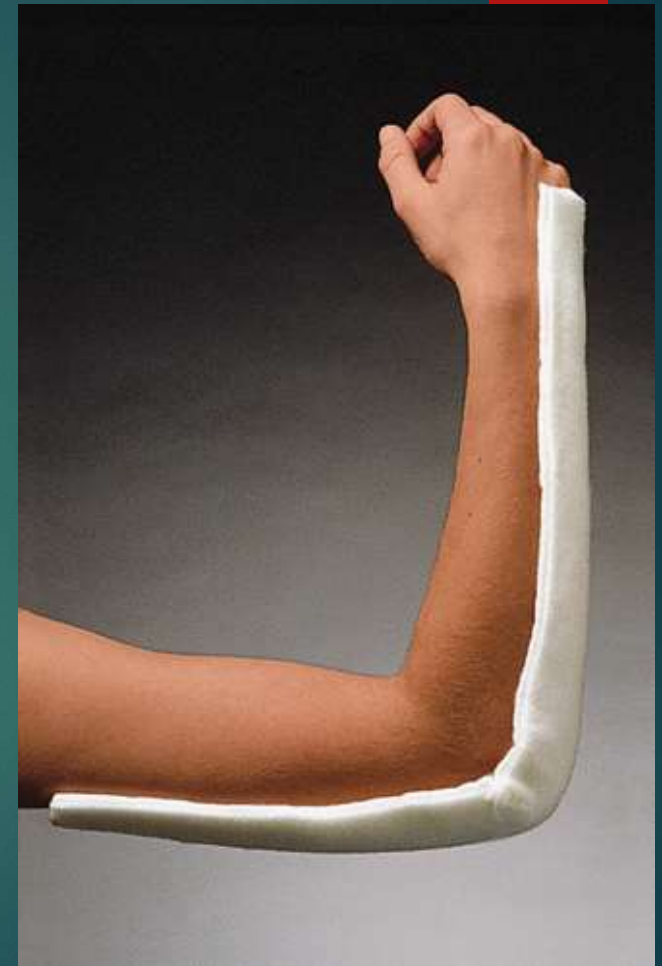https://commons.wikimedia.org/wiki/File:Fettpolsterzeichen_paathologisch_Ellenbogen.png



Upper Extremity Splints: Long Arm

- Splint width:
 - Adult 3-4 inch
 - Child 2-3 inch
- Distribution
 - Elbow flexed at 90 degrees
 - Splint from 5th MCP joint over ulnar aspect of forearm to 2 inches distal to axilla
 - Slight dorsiflexion of wrist
 - Place splinted extremity in sling

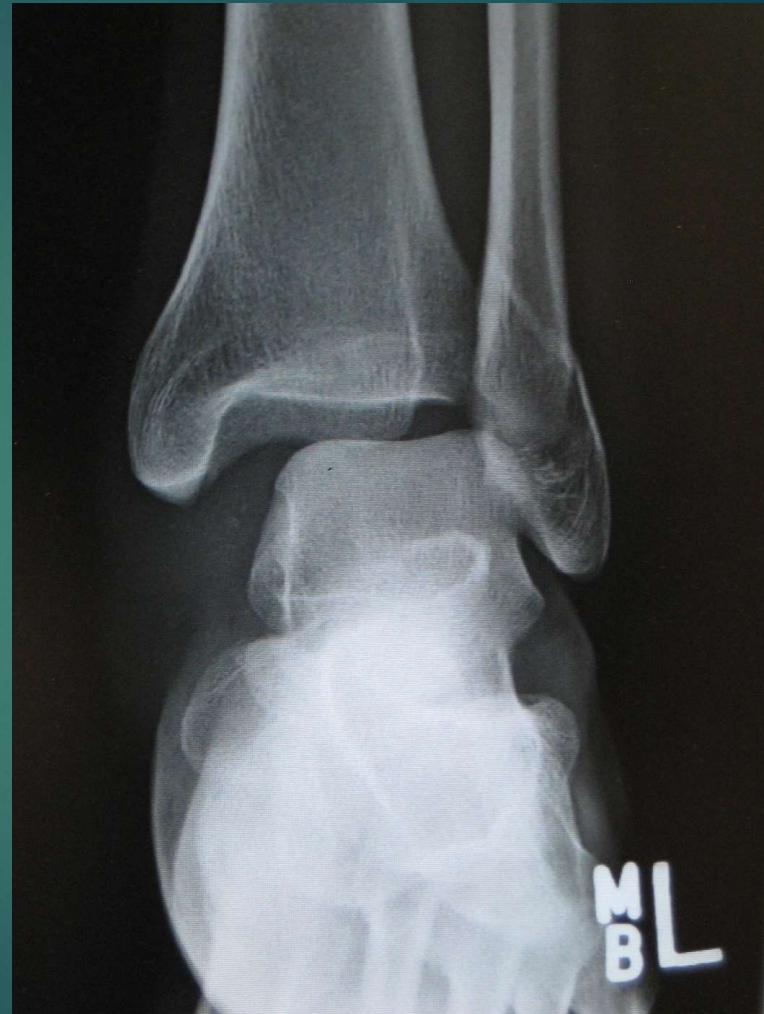<http://www.quickmedical.com/bsn-medical-ortho-glass-splinting-system.html>



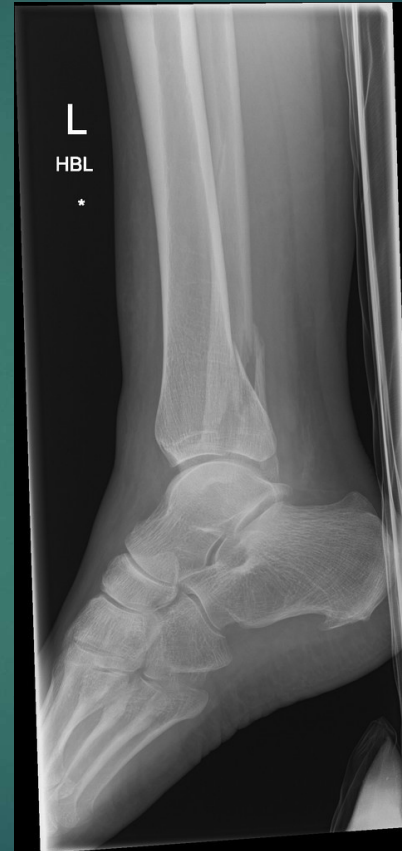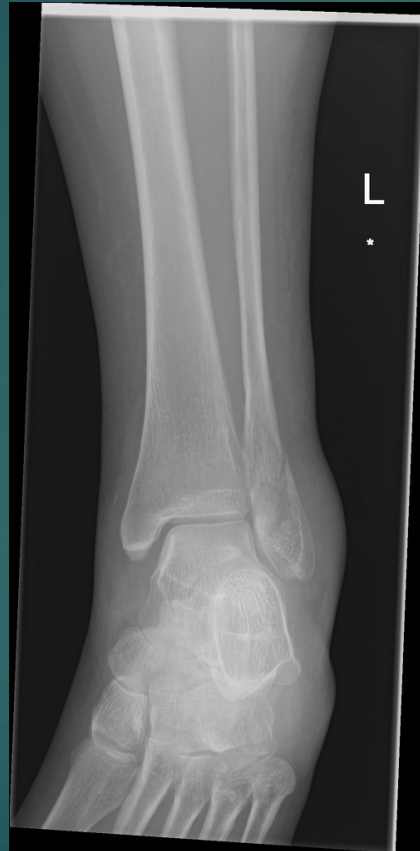Lower Extremity Splints: Posterior Ankle

- Indications
 - Metatarsal fractures
 - Distal fibula fractures
 - Achilles tendon rupture (slight plantar flexion)

<https://commons.wikimedia.org/wiki/File:AnkleFractureDislocation2008.jpg>



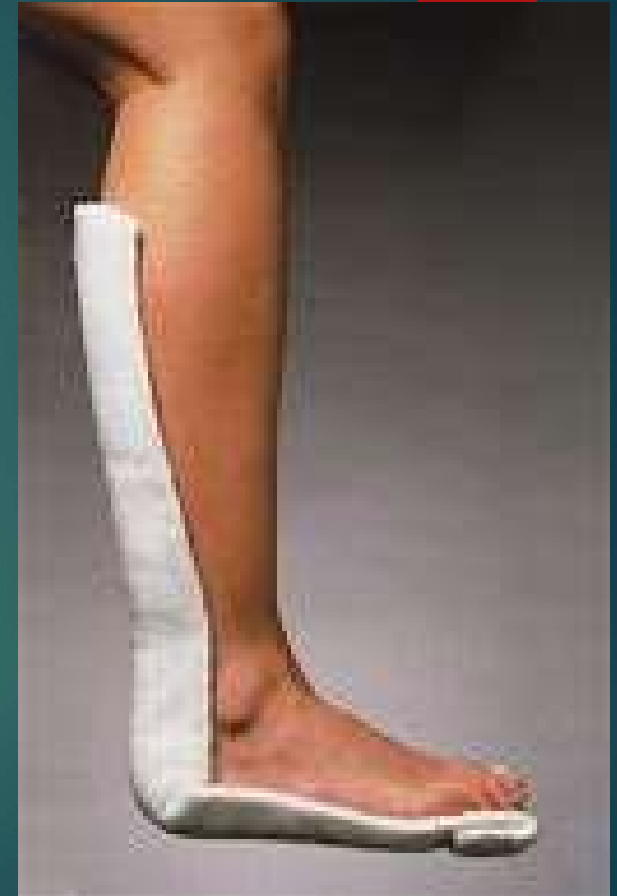Lower Extremity Splints: Posterior Ankle



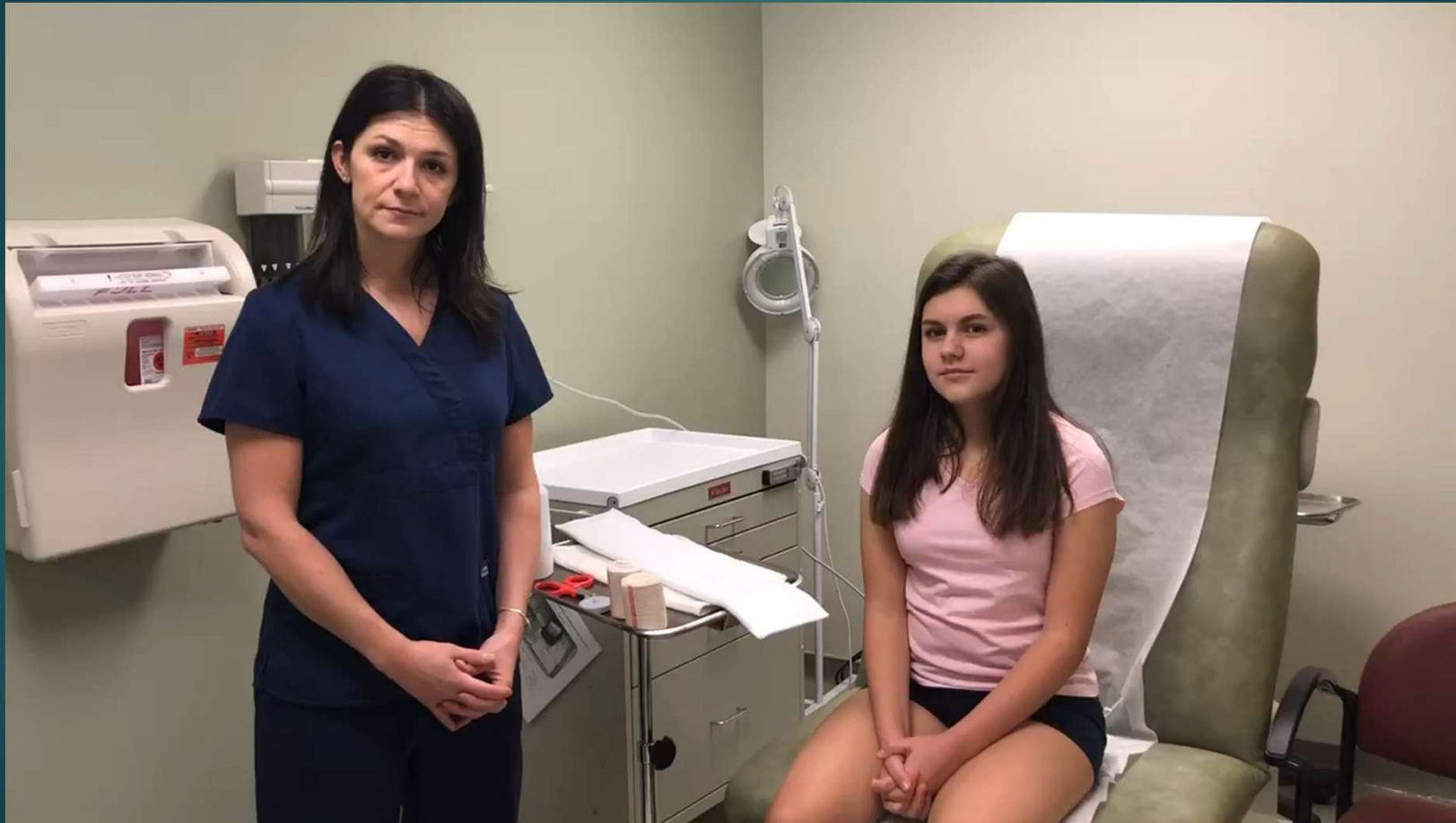<https://radiopaedia.org/cases/distal-fibula-fracture-1?lang=us>

Lower Extremity Splints: Posterior Ankle

- Splint width:
 - Adult 4-5 inch
 - Child 3-4 inch
- Distribution
 - MTP joints (2 in. toe pad) on plantar surface of foot to 2 inches distal to popliteal space
 - 90-degree flexion of ankle (Achilles tendon rupture – slight plantar flexion)
 - Discharge patient with crutches and advise non-weightbearing status



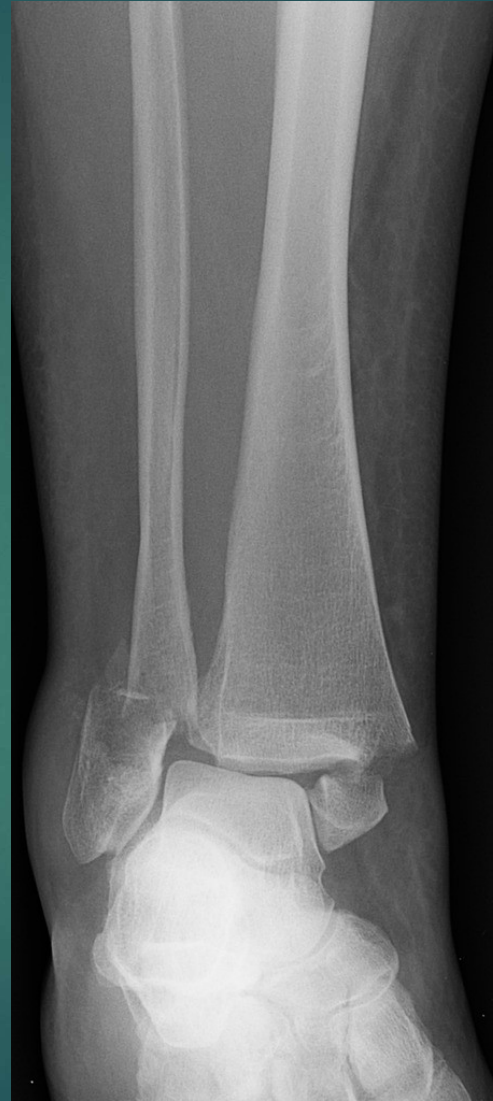Posterior Ankle Application



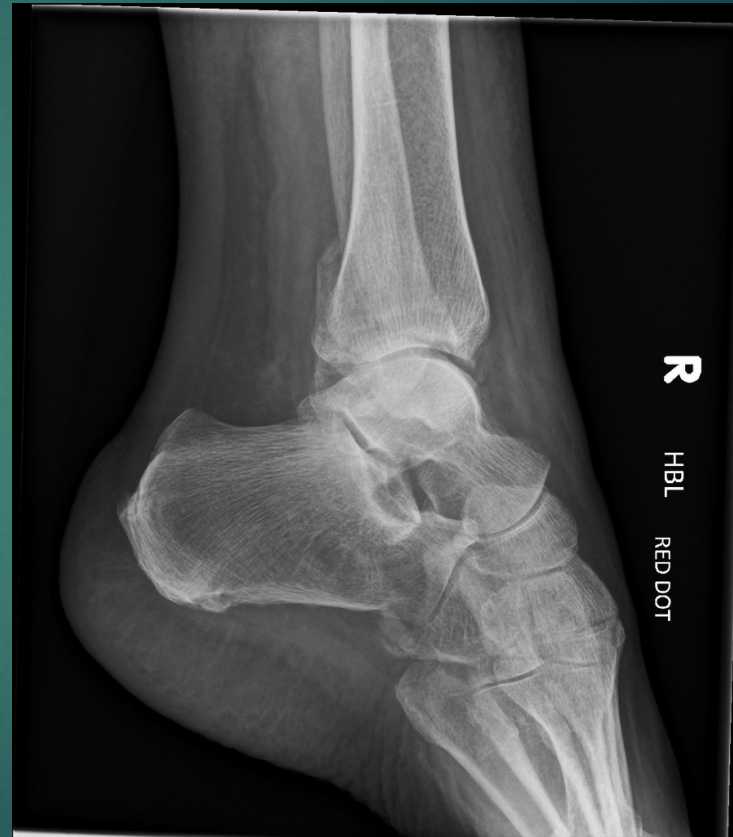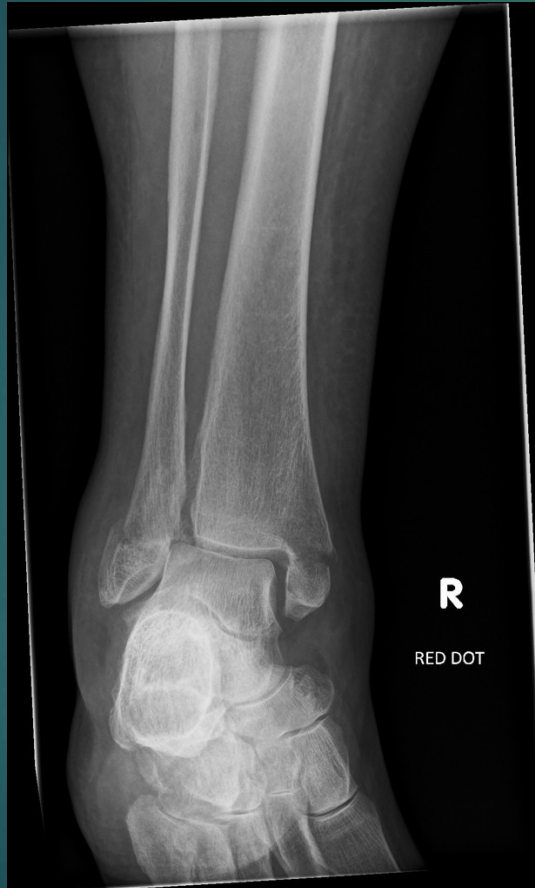Lower Extremity Splint: Stir up

- Indications
 - Bi/trimalleolar fractures
 - Unstable ankle fractures
 - Severe ankle sprain

<https://radiopaedia.org/cases/trimalleolar-fracture-6?lang=us>

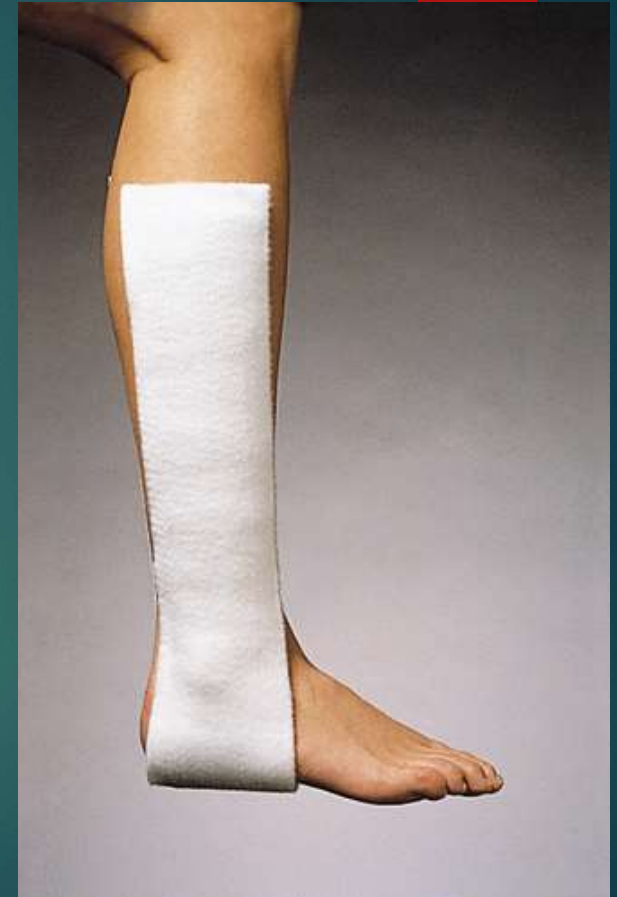

Lower Extremity Splint: Stir up



Lower Extremity Splint: Stir Up

- Splint width:
 - Adult 4-5 inch
 - Child 3-4 inch
- Distribution
 - 2 inches below knee on medial side around calcaneus to 2 inches below knee on lateral side
 - 90-degree flexion of ankle
 - Discharge patient with crutches and advise non-weightbearing status



Splinting Complications

- Compartment syndrome
- Flexion contractures
- Burns
- Pressure sores (caution especially in patients with neuropathy)
- Compliance issues

Take Home Points

- When presented with an injury, choose the appropriate splint for optimal healing
- Use proper application techniques to avoid complications
- Ensure appropriate follow up care
- When in doubt, SPLINT!

QUESTION 2

All of the following supplies are needed for proper splint application EXCEPT

- a) Hot water
- b) Assistant
- c) Elastic bandage
- d) Splinting material

QUESTION 3

Splints should NOT be used for which of the following injuries?

- a) Sprains/strains
- b) Cellulitis
- c) Injuries with neurovascular compromise
- d) Unstable fractures



QUESTIONS?

triadeninno@yahoo.com

mcswigan1977@gmail.com