



MAYO CLINIC

HEALTH SYSTEM

Venous thrombosis

Kyle Burkhamer, PA-C

Objectives

- Evaluate for acute DVT of the proximal lower extremities – limited compression ultrasonography (LCU)

Transducer selection



LCU vs. “Duplex” examination

LCU

- Compression only
- Proximal LE veins only
- EP interpretation

Traditional duplex US

- Compression AND Doppler
- Whole leg (proximal AND calf veins)
- Radiologist interpretation

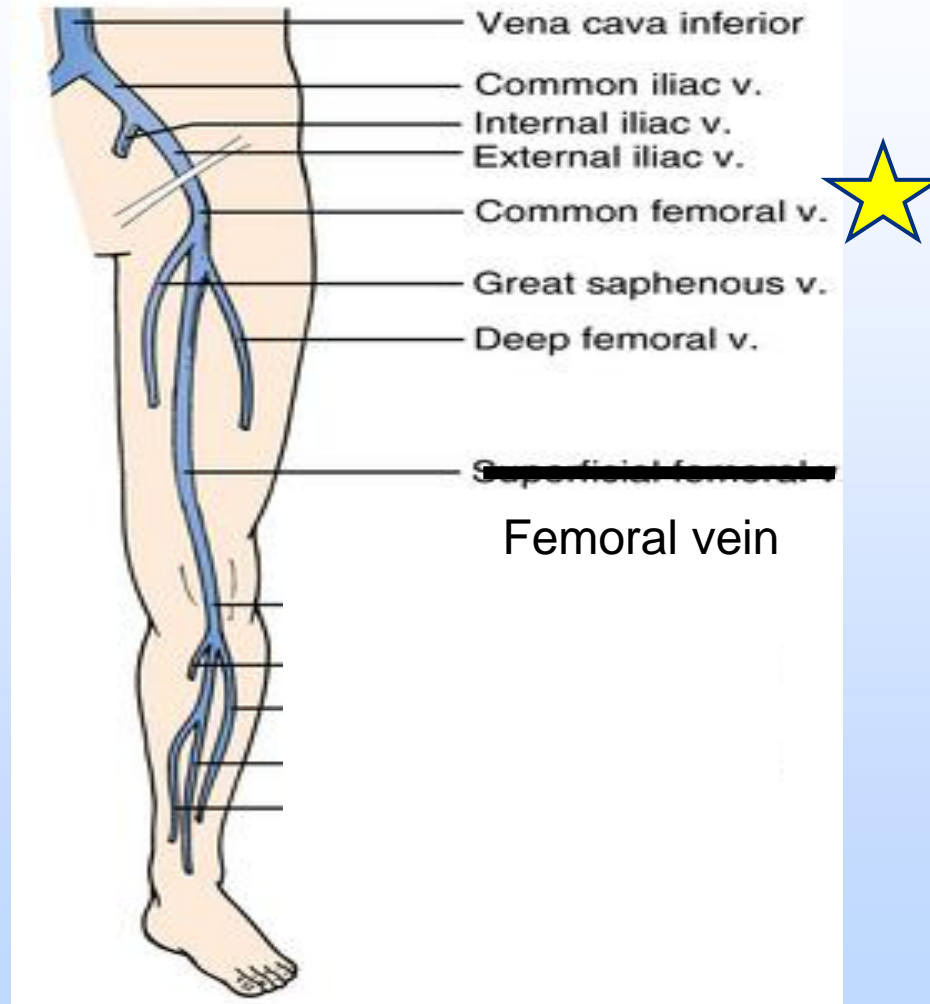
Limitations/pitfalls

- Mistaking artery for vein
- Believing that the absence of visualized thrombus = no DVT
- Prior history of DVT
- Failing to arrange for repeat, formal exam when indicated

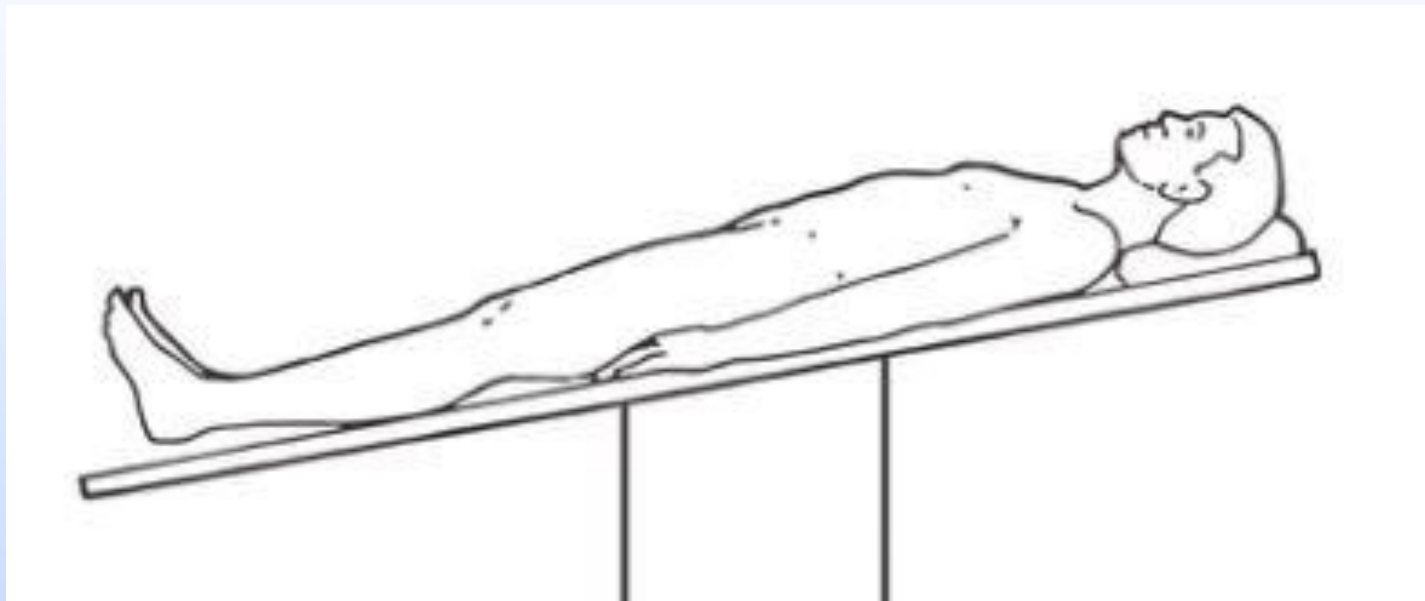LCU exam

- Two regions
 - Femoral system
 - Popliteal system

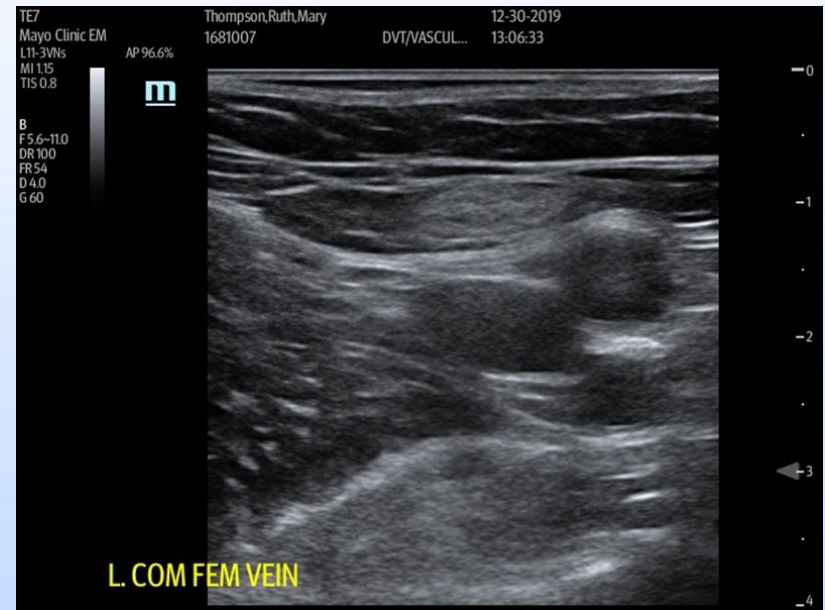
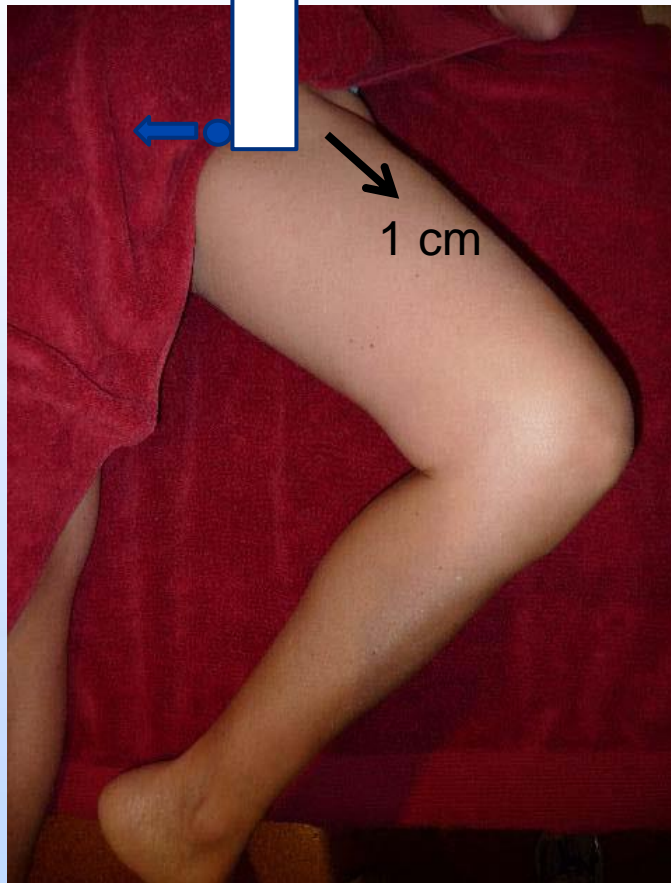
Femoral system



Patient positioning I



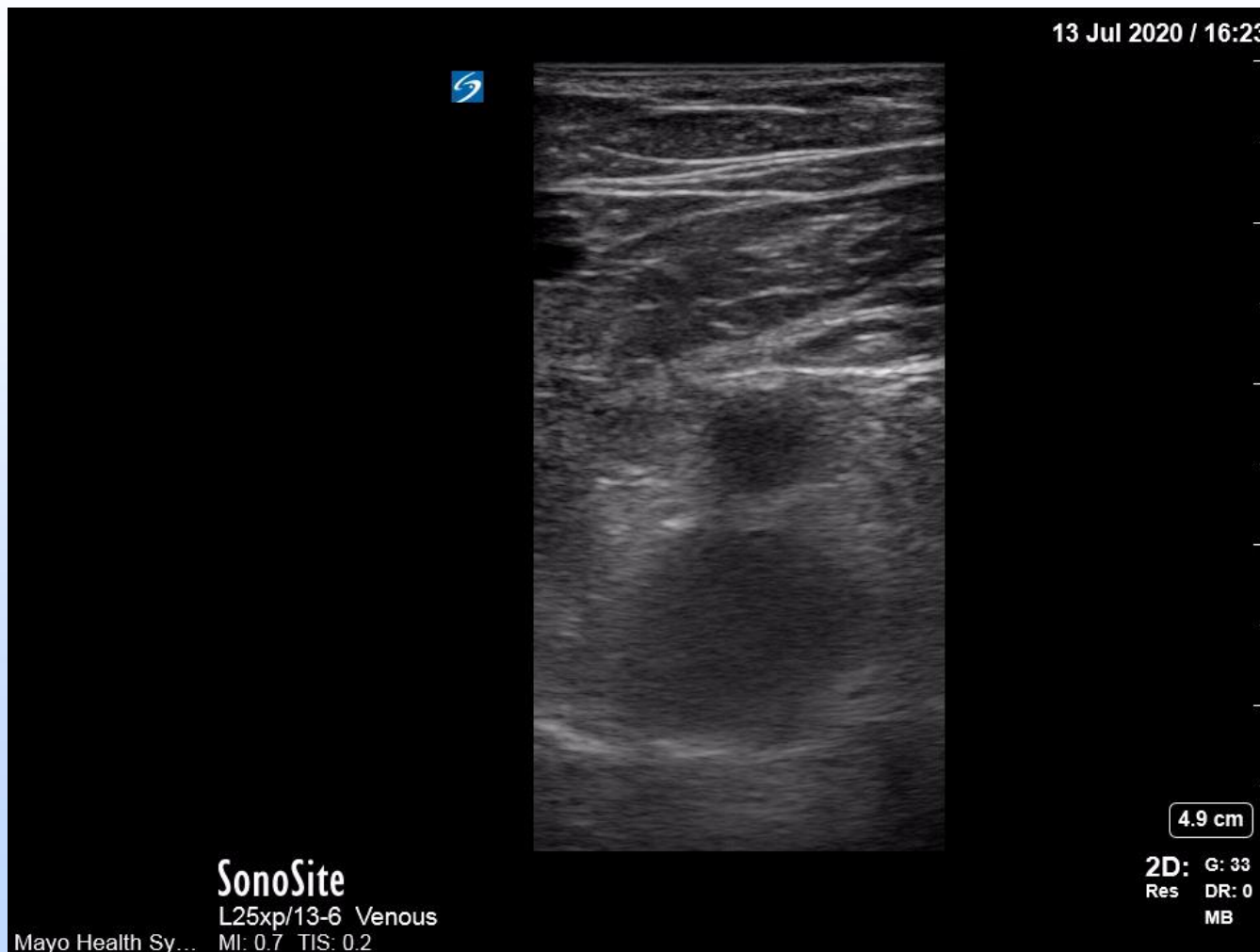
Technique I



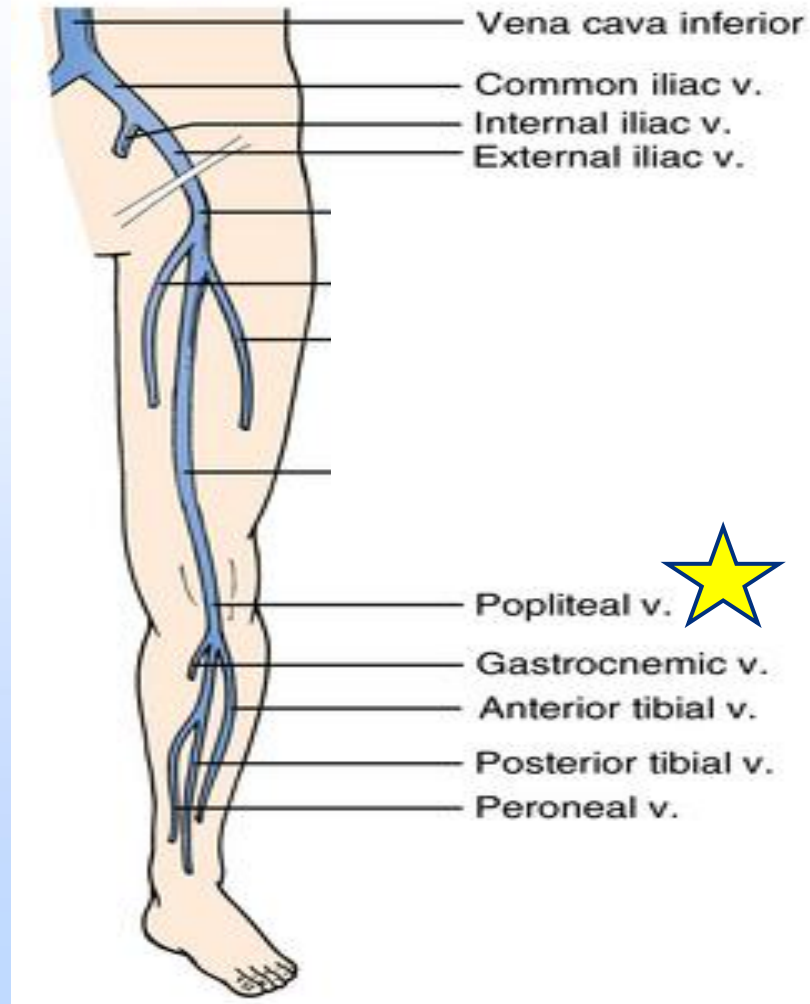
How much pressure?



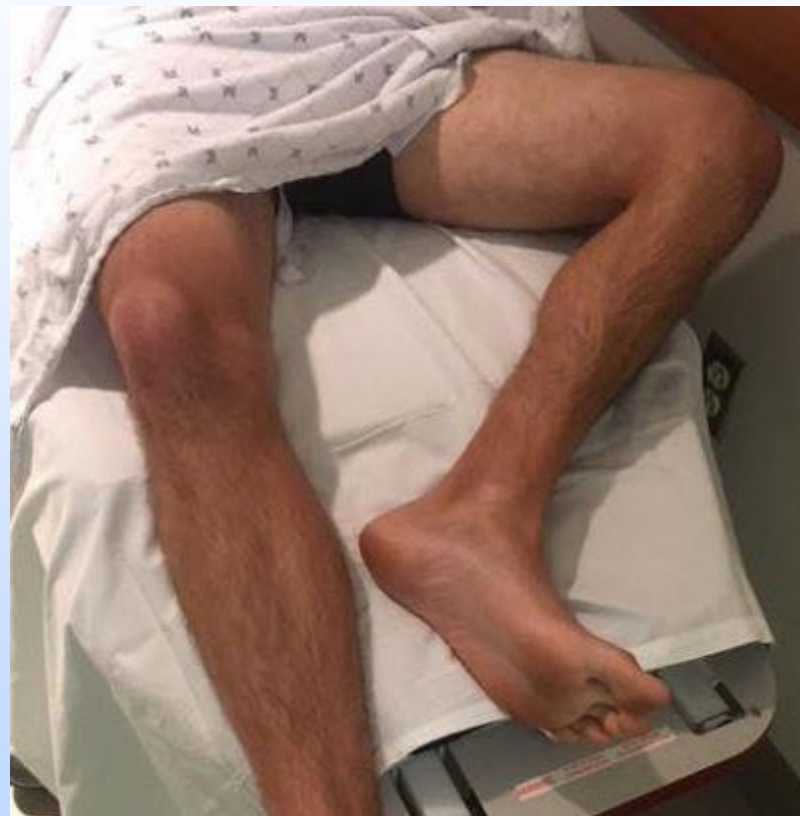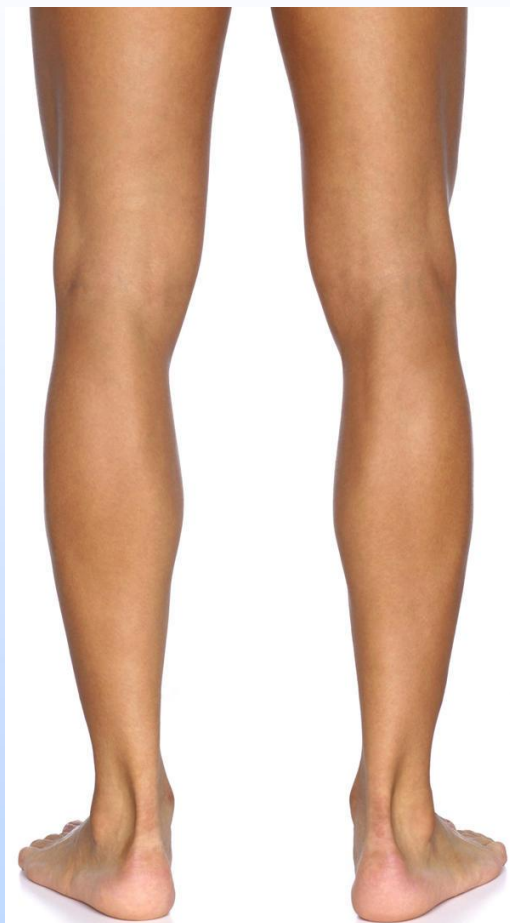Positive DVT



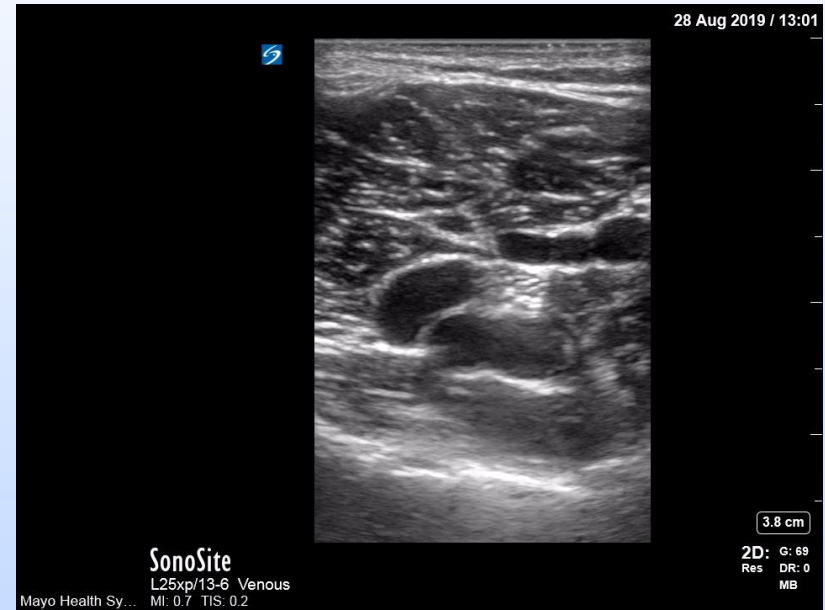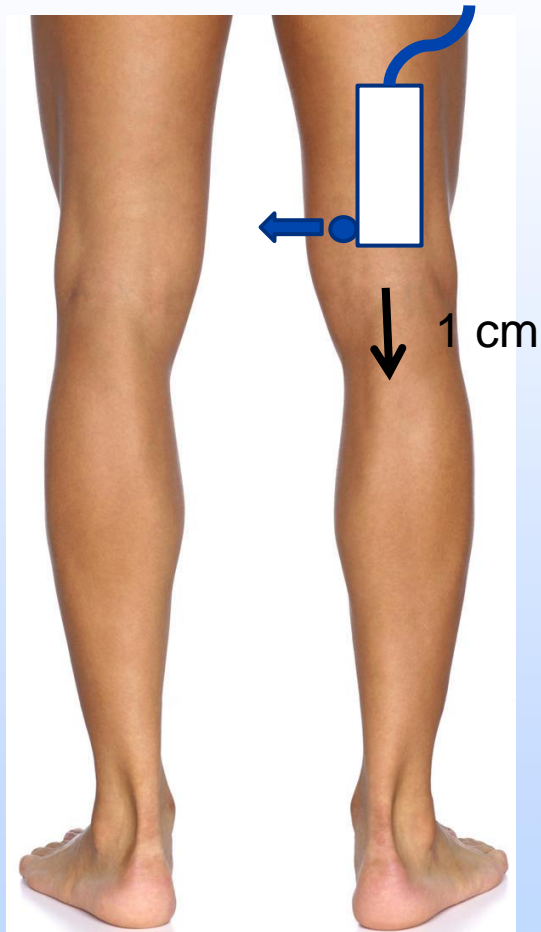
Popliteal system



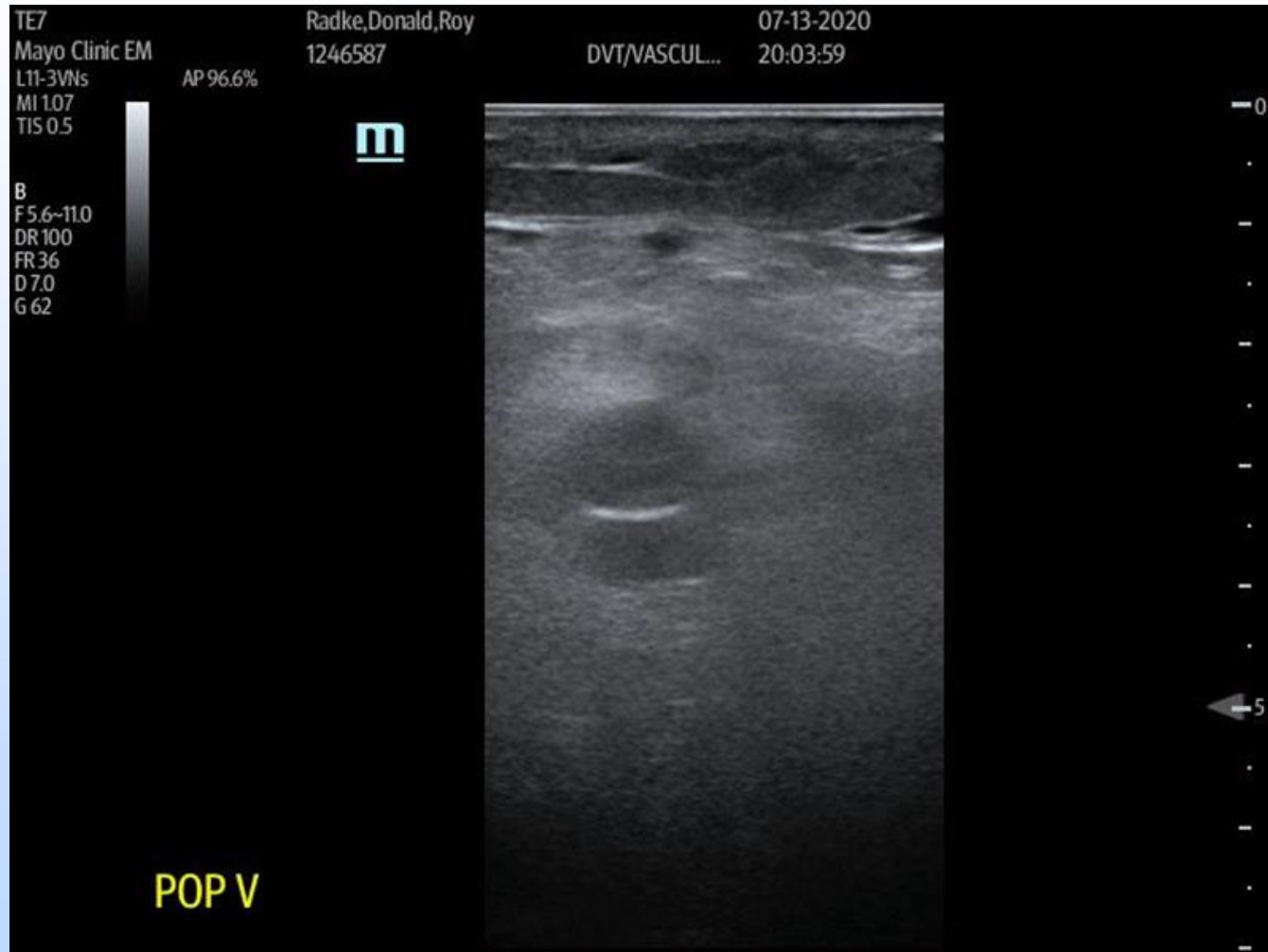
Patient positioning II



Technique II



Positive DVT



Recap

- Two regions
 - Femoral region
 - Popliteal region
- Compression
- Arrange follow-up when indicated

Questions

