



LUNG ULTRASOUND

MIKE BREUNIG, PA-C



AAPA 2023
Nashville, TN

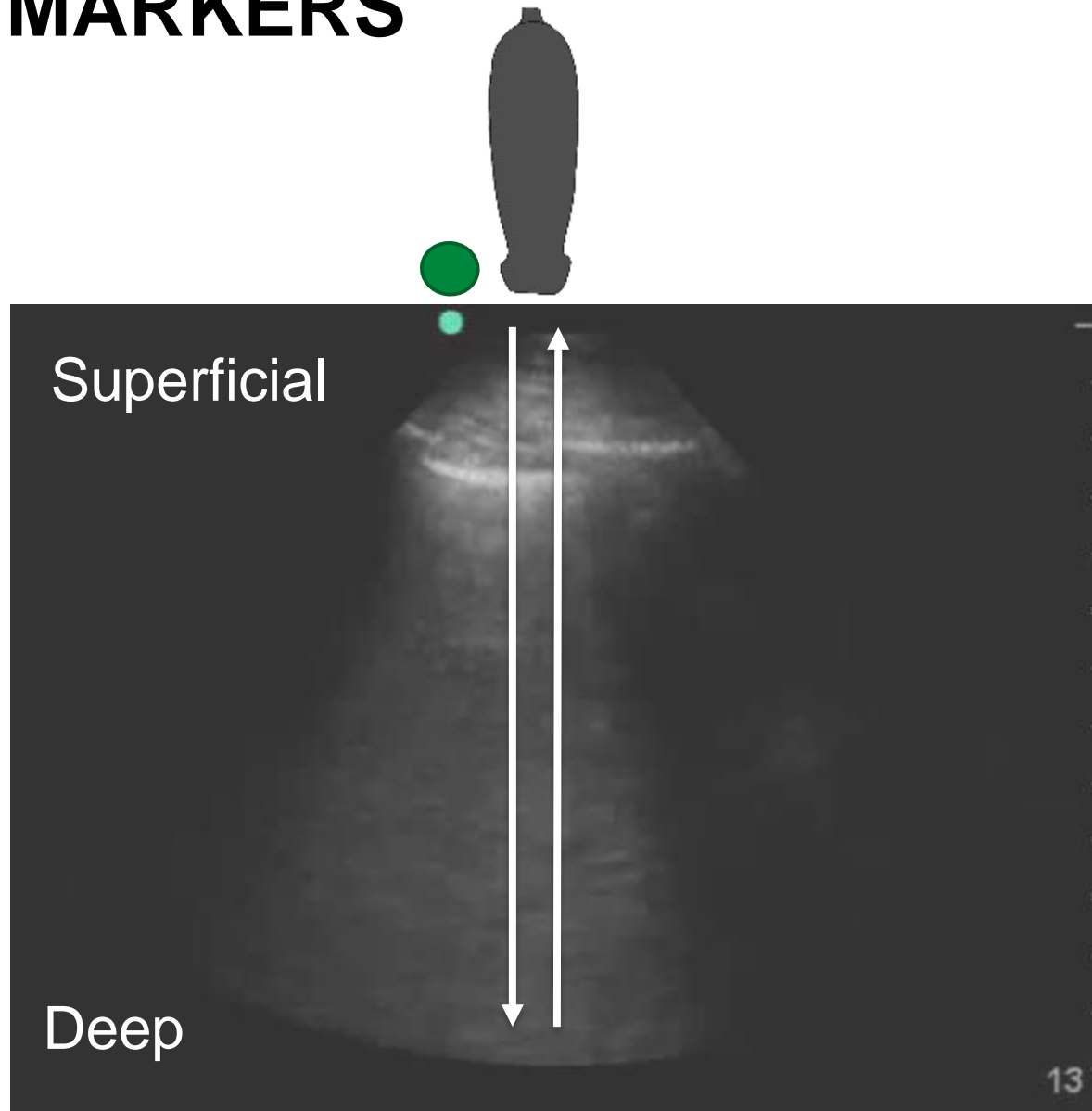
DISCLOSURES

None

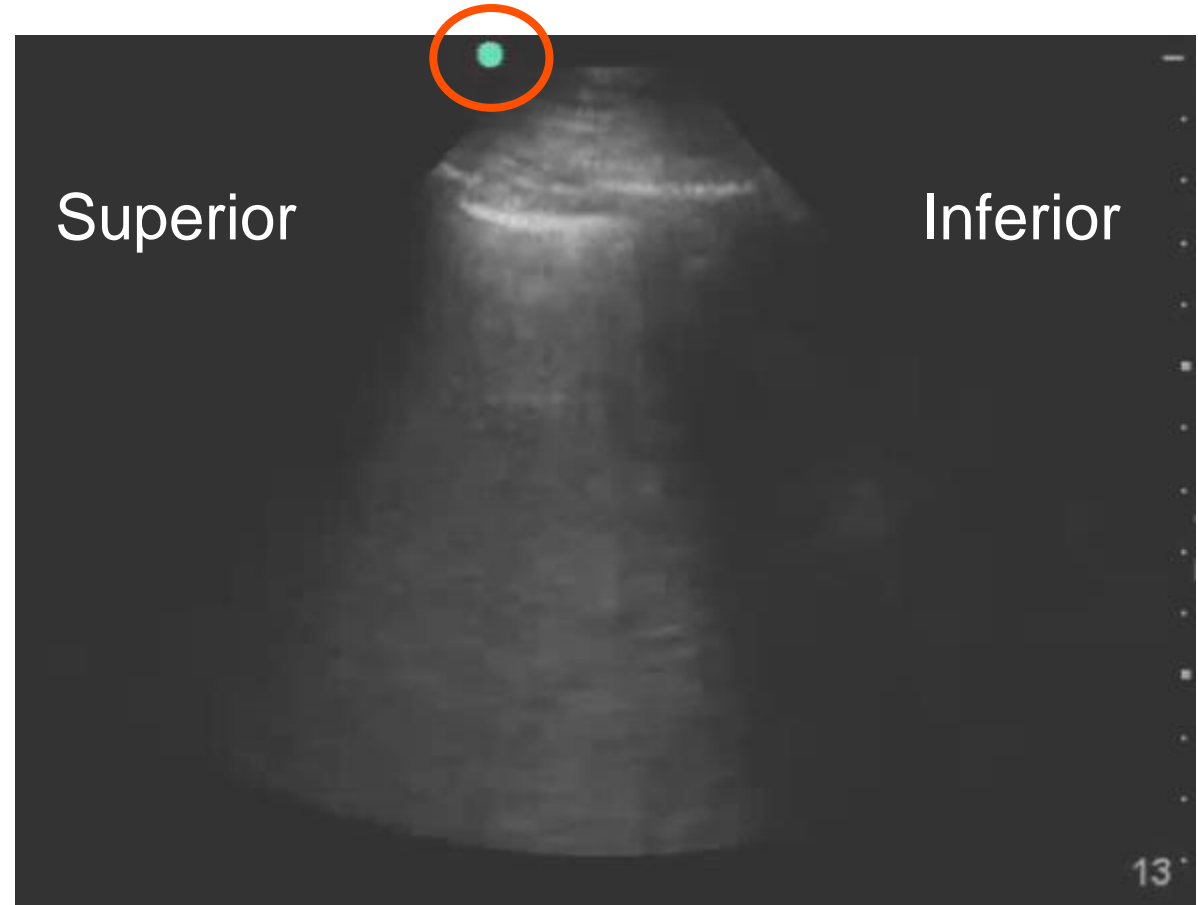
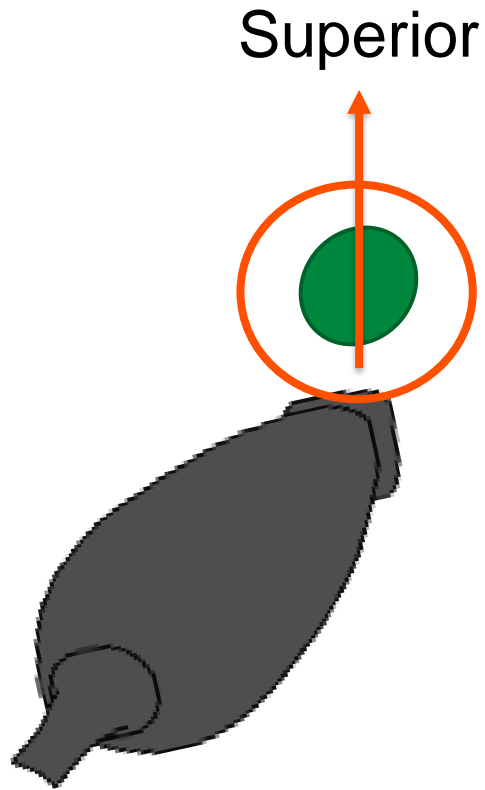
LEARNING OBJECTIVE

- Identify the scope and indications of lung ultrasound
- Contrast normal and abnormal findings on lung ultrasound
- Obtain lung ultrasound images

INDICATOR MARKERS



INDICATOR MARKERS

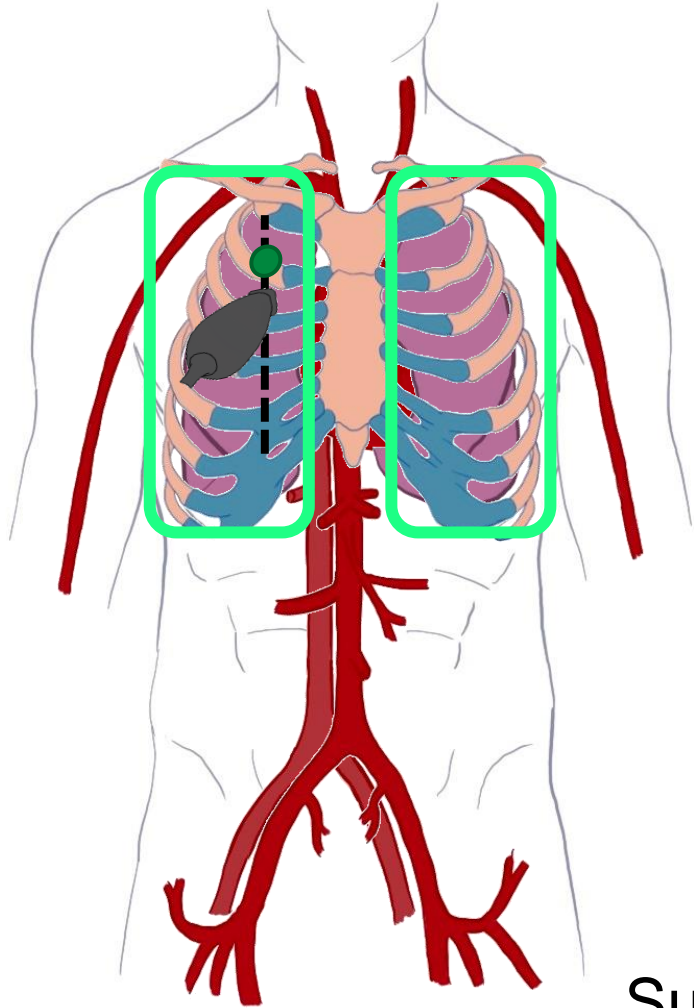


LUNG ULTRASOUND

- Scope:
 - Pulmonary Edema
 - Pneumonia (viral and bacterial)
 - Pleural effusions (simple vs complex)
 - Pneumothorax
- Indications:
 - Dyspnea
 - Hypoxia
 - Respiratory Failure
 - Intravascular volume assessment

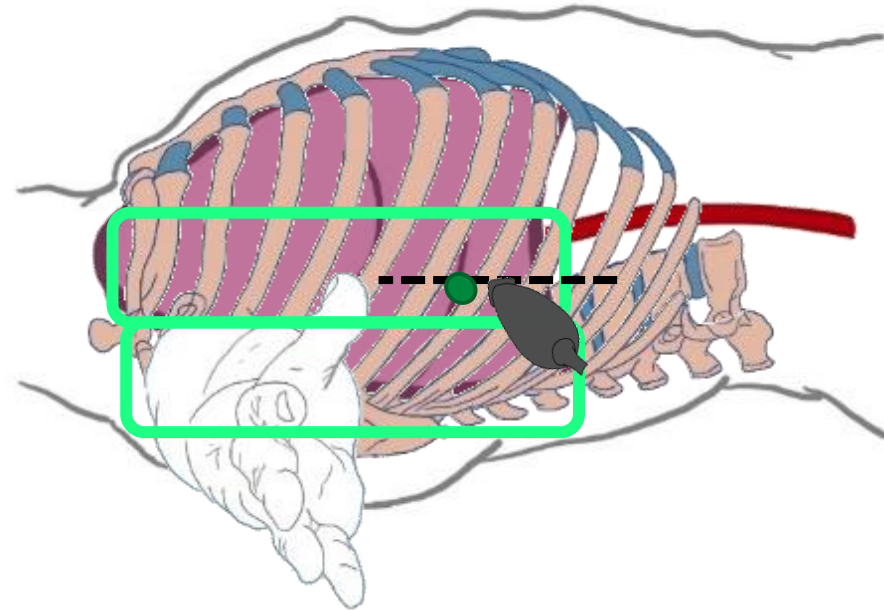
LUNG ULTRASOUND

Zone 1

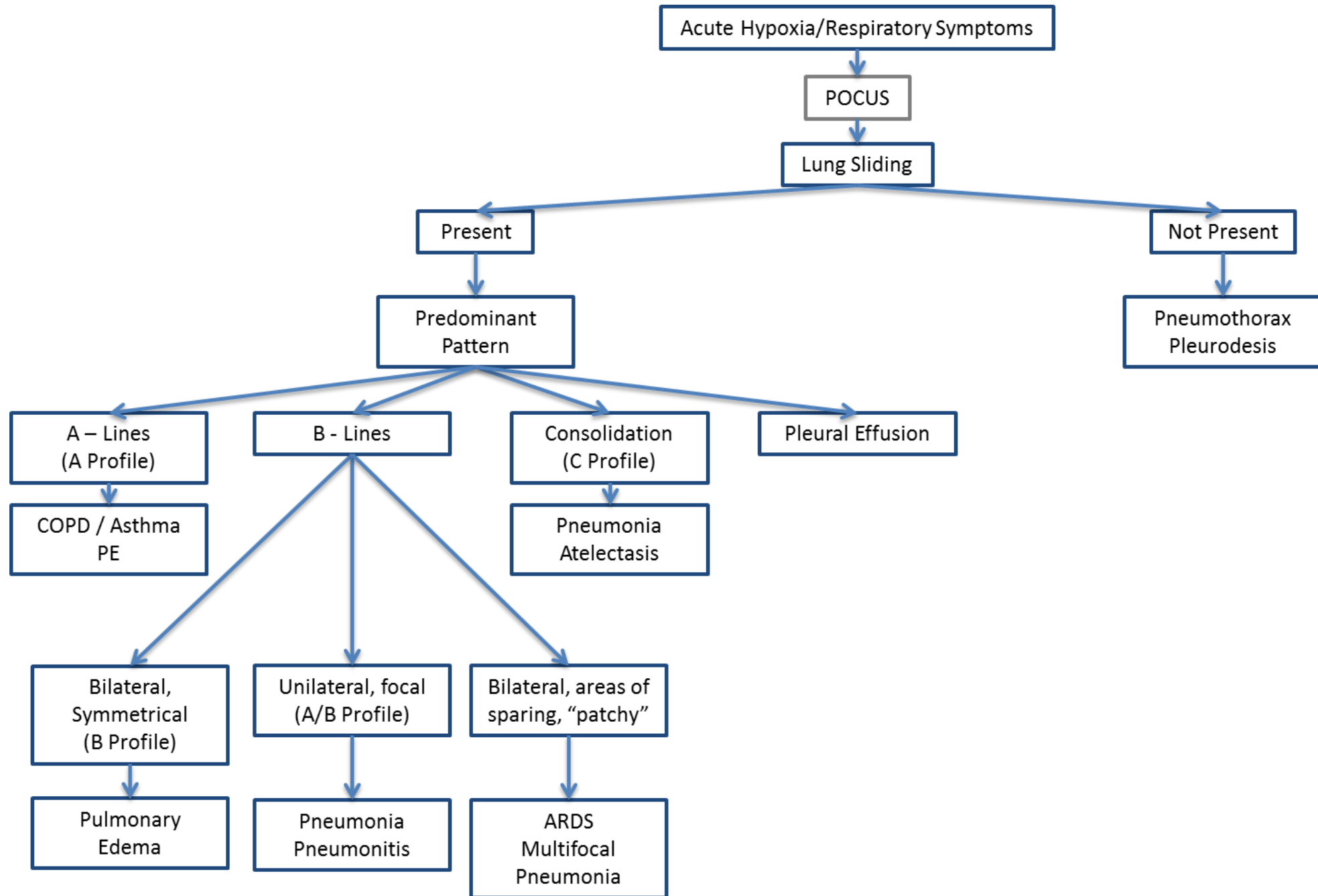


Zone 2

Zone 3

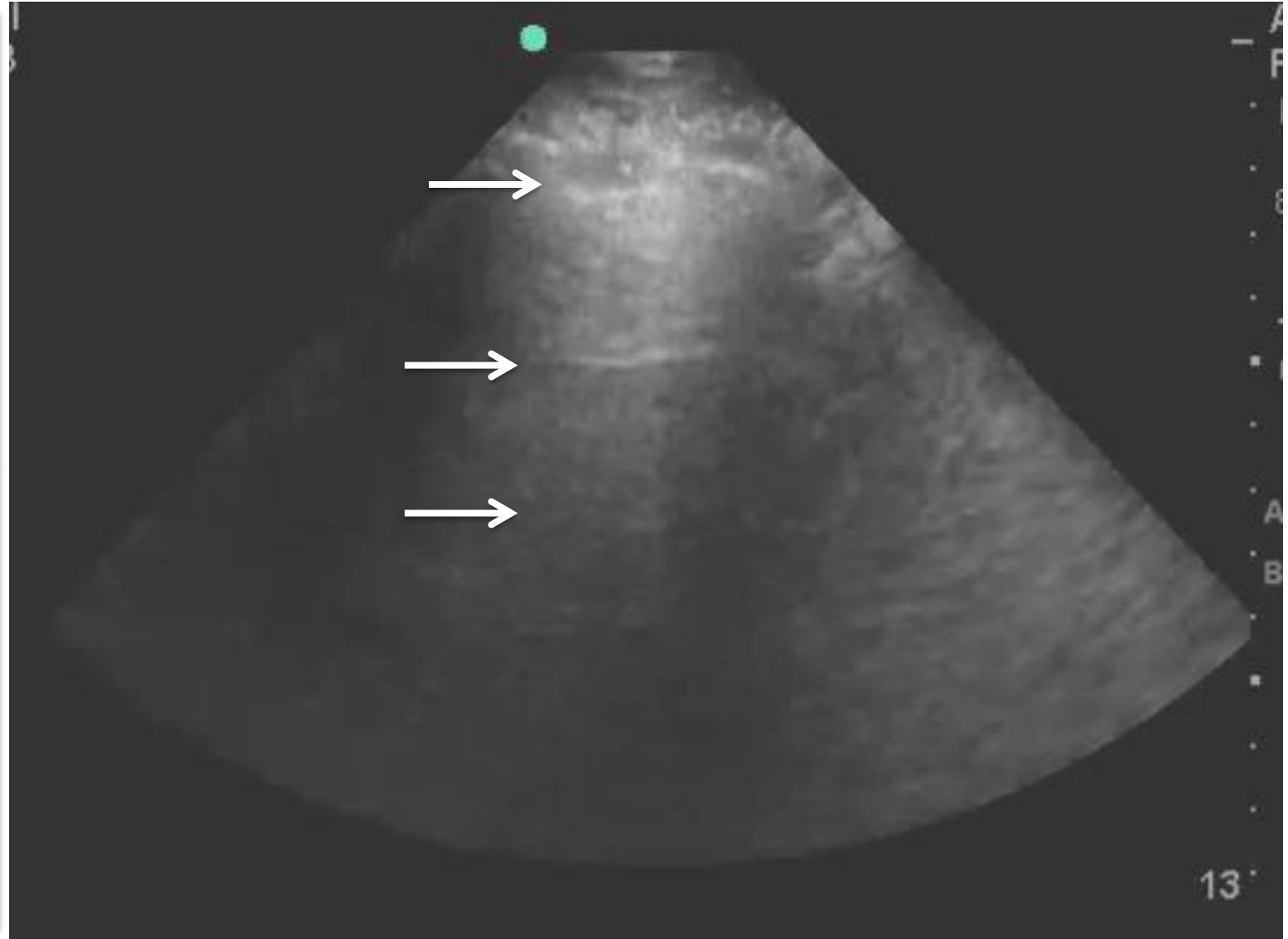
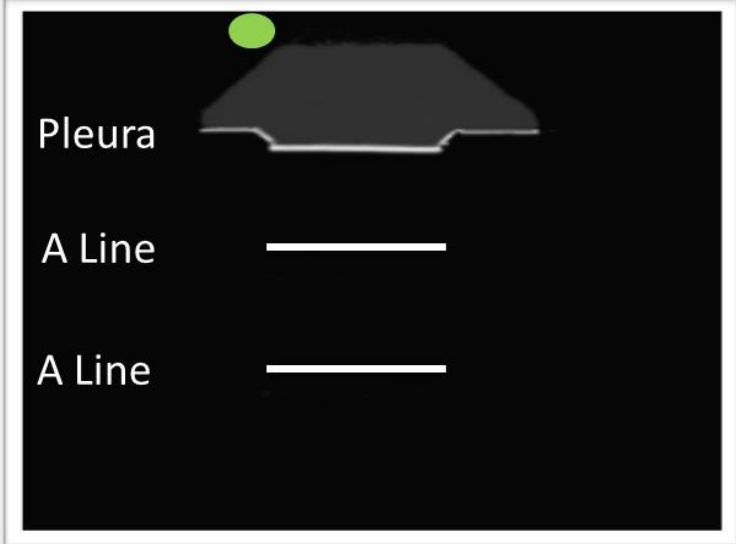
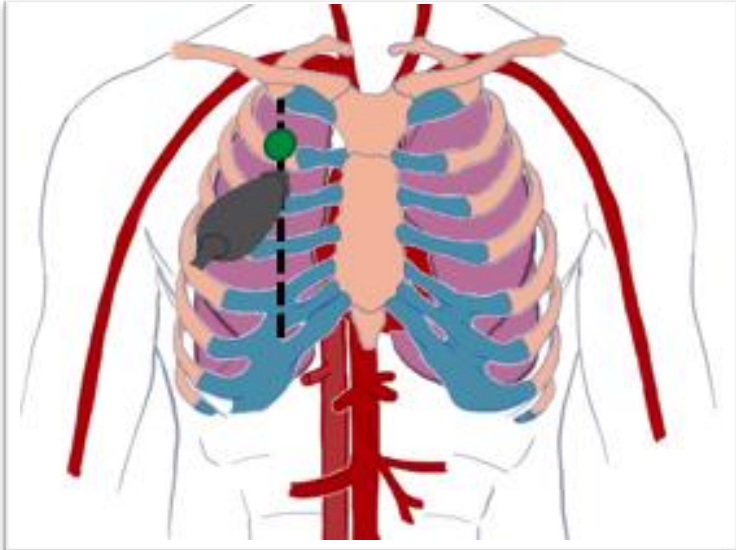


Superior + Inferior Points



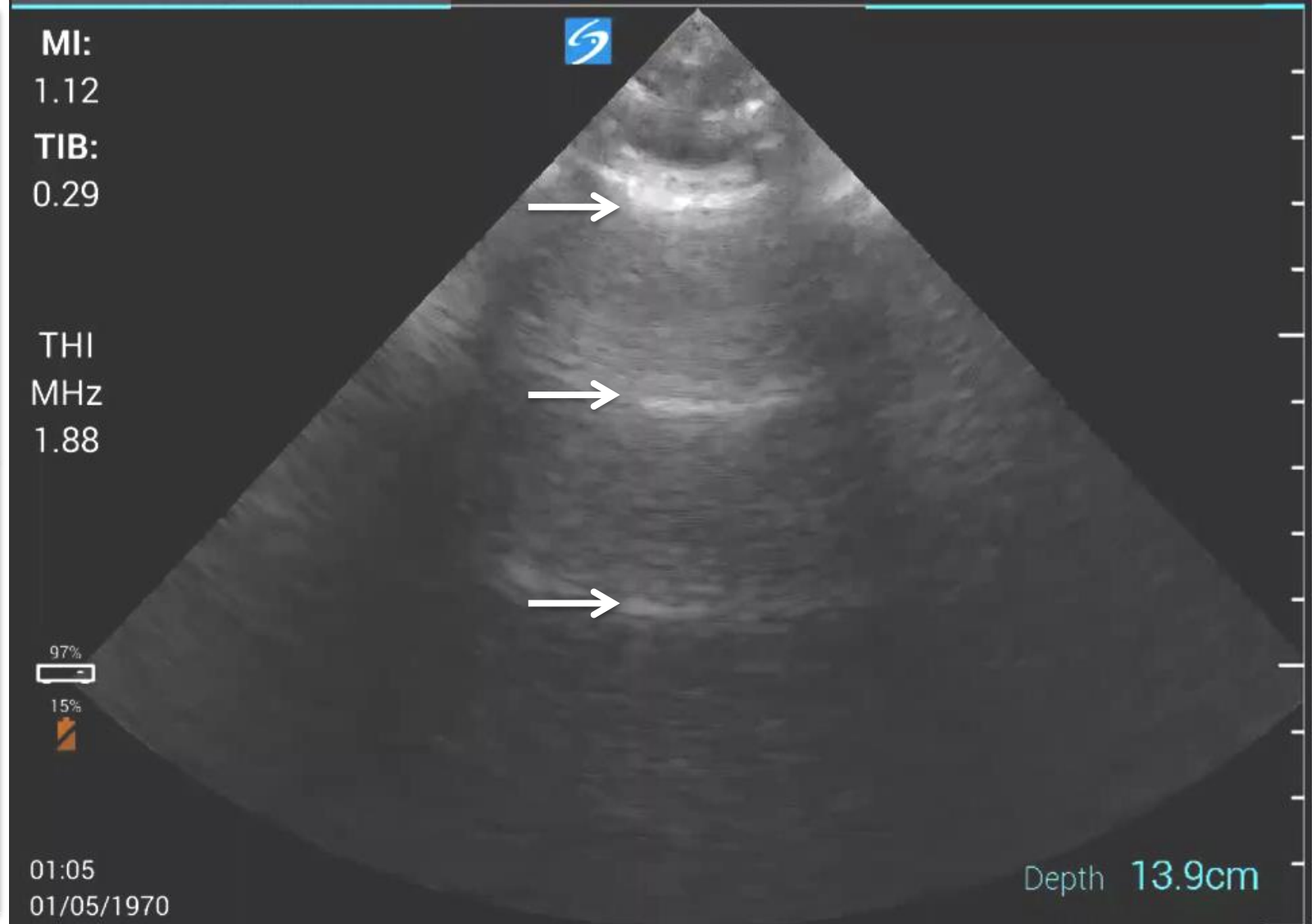
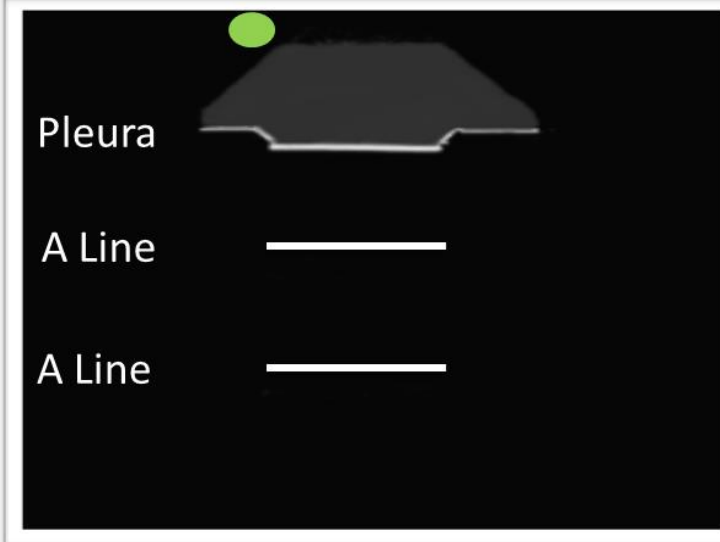
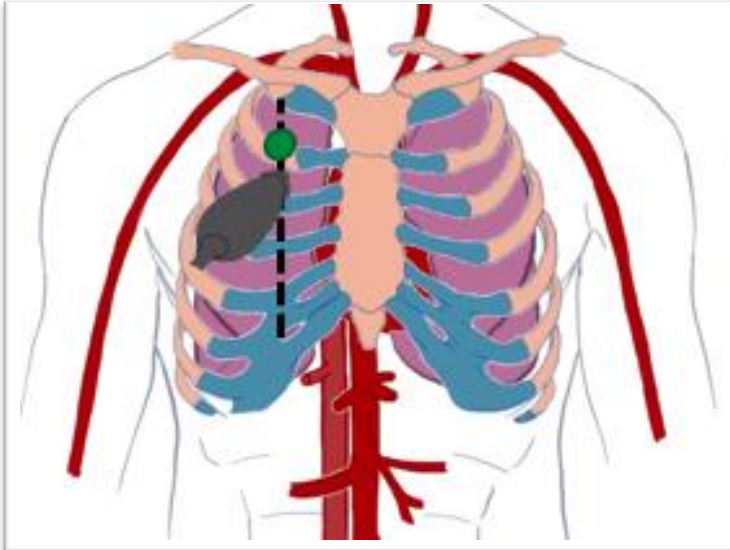
LUNG ULTRASOUND

A LINES + LUNG SLIDING



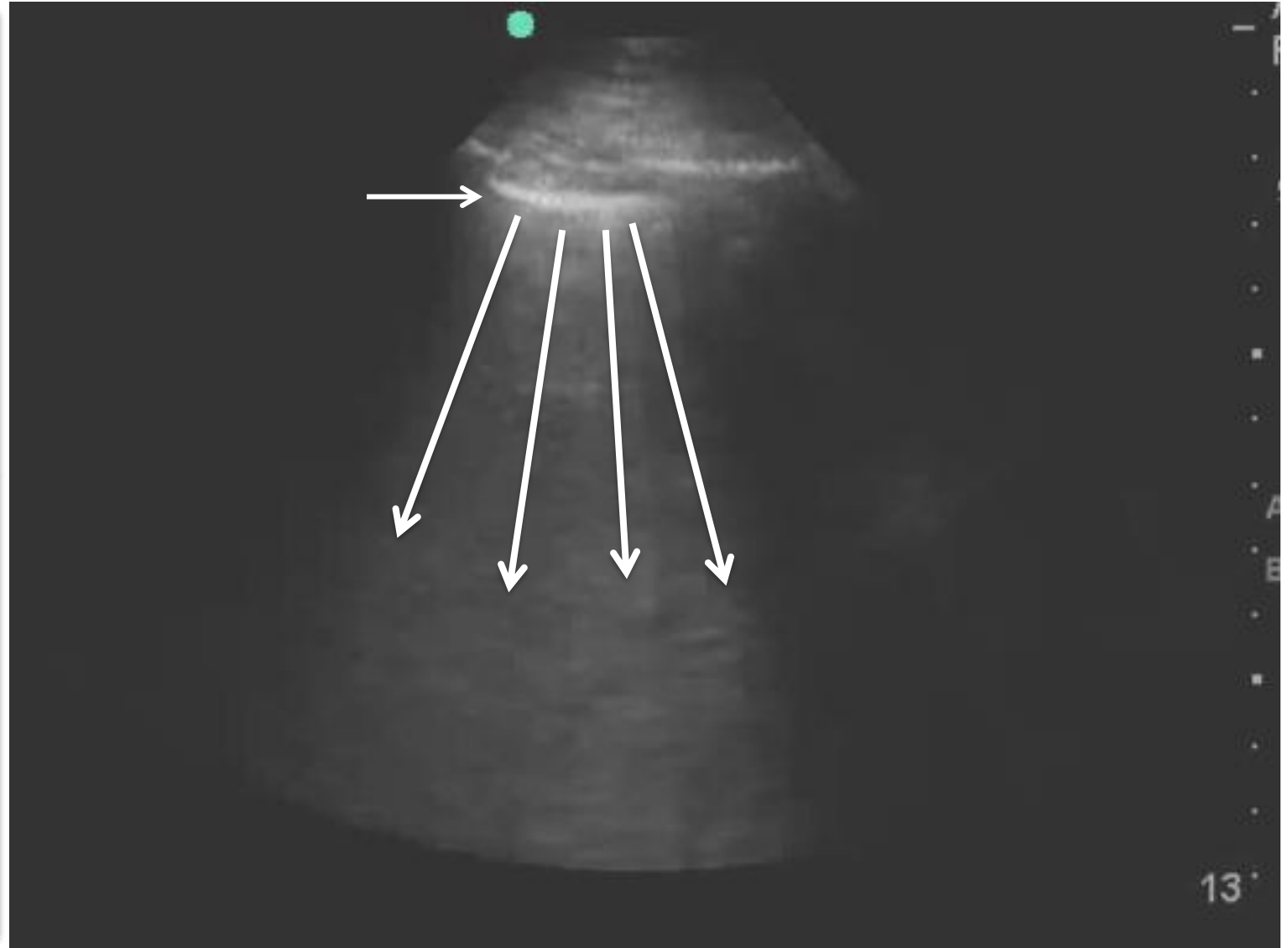
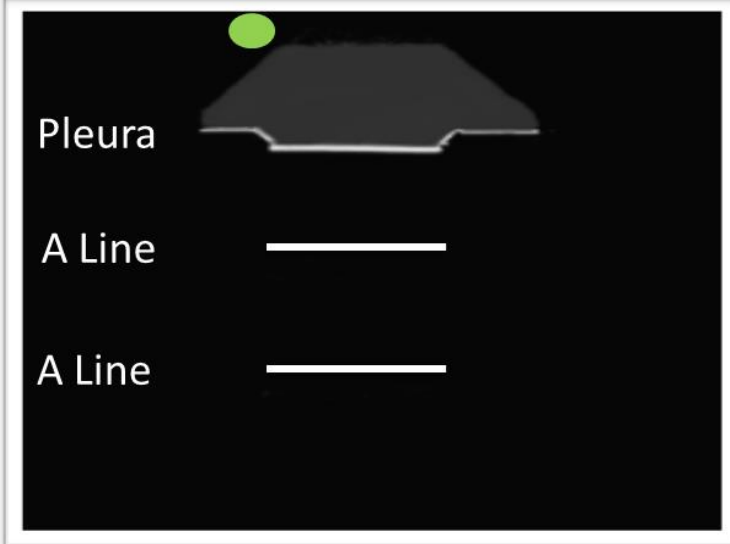
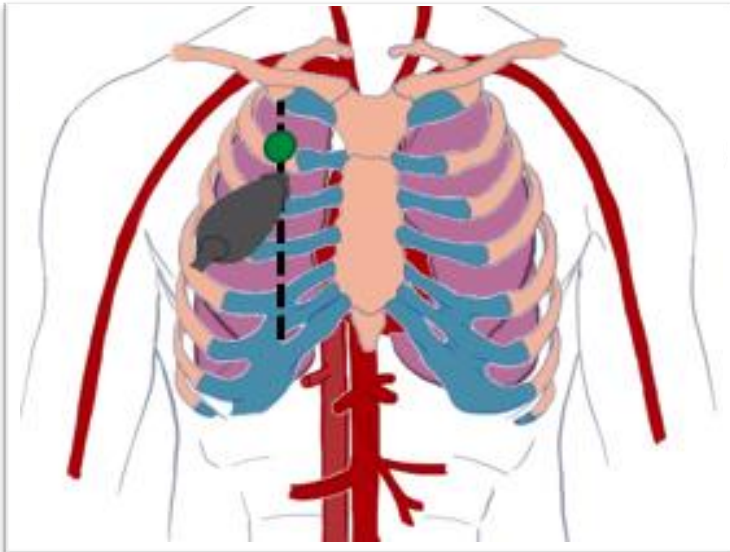
LUNG ULTRASOUND

ABSENT LUNG SLIDING

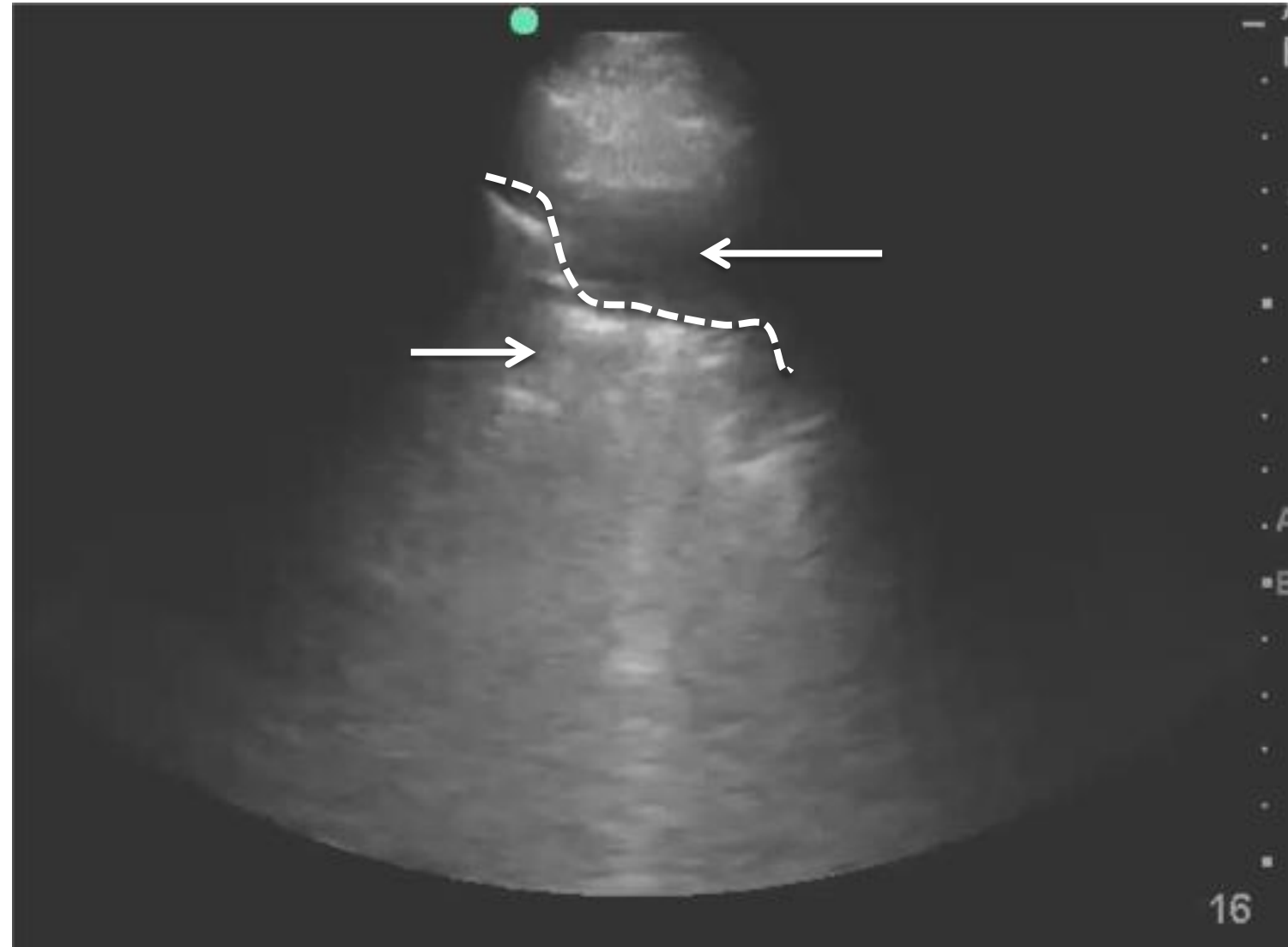
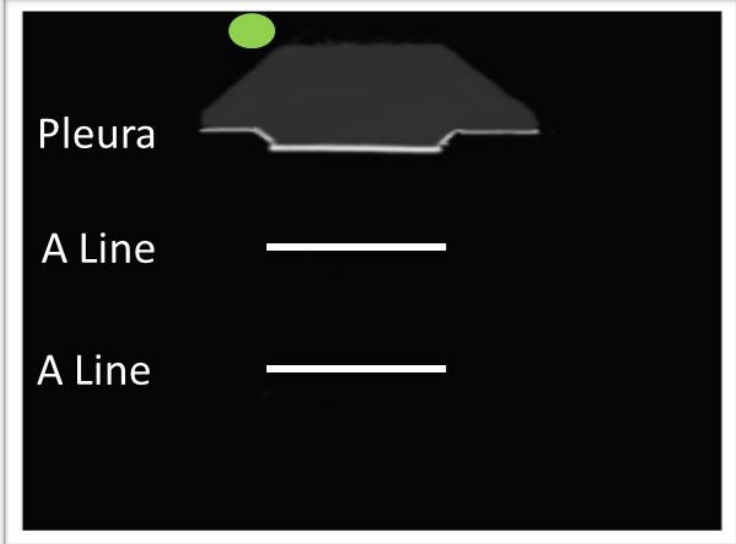
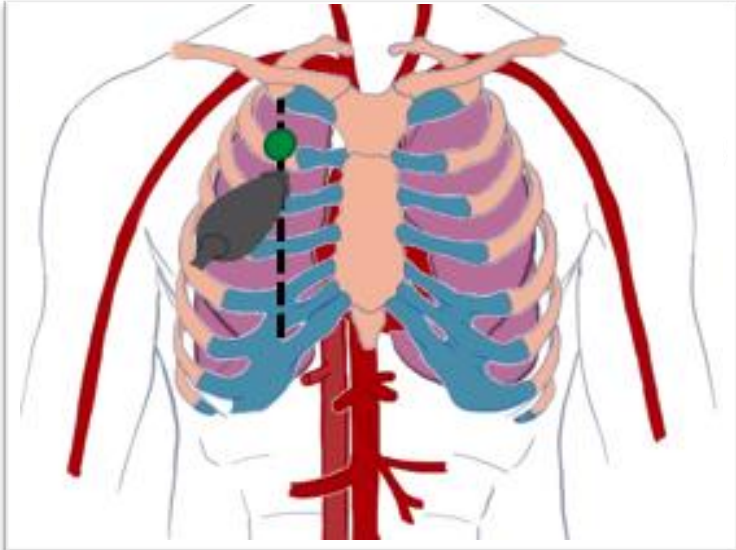


LUNG ULTRASOUND

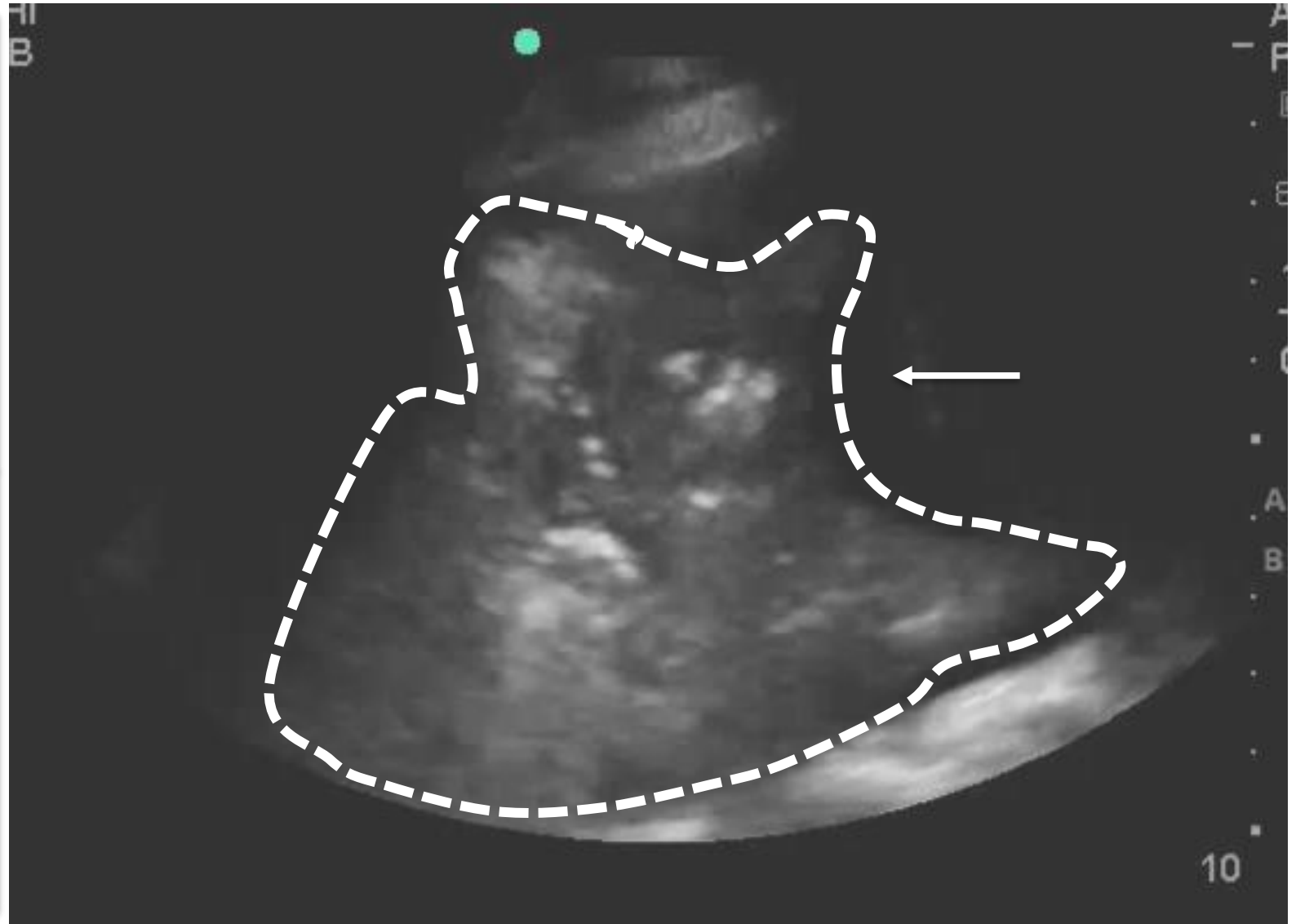
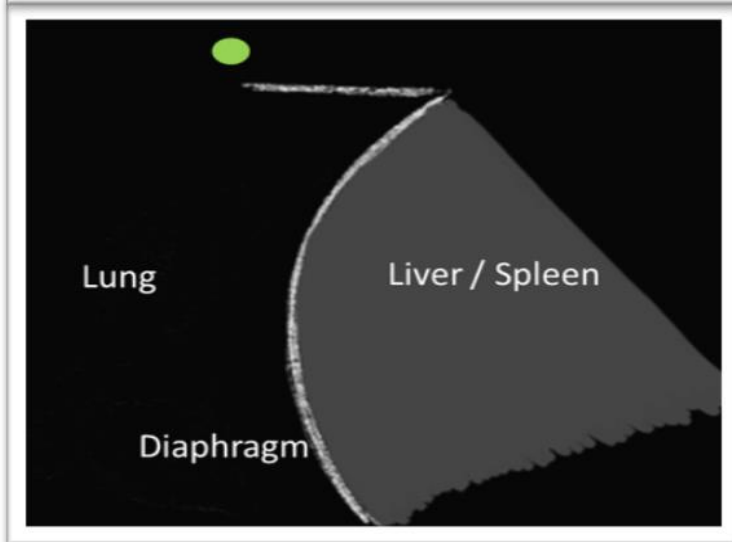
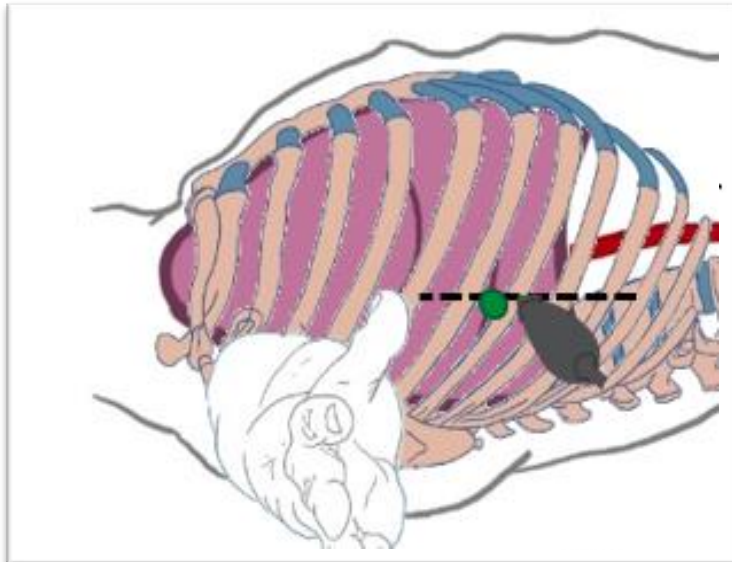
B LINES



LUNG ULTRASOUND CONSOLIDATION

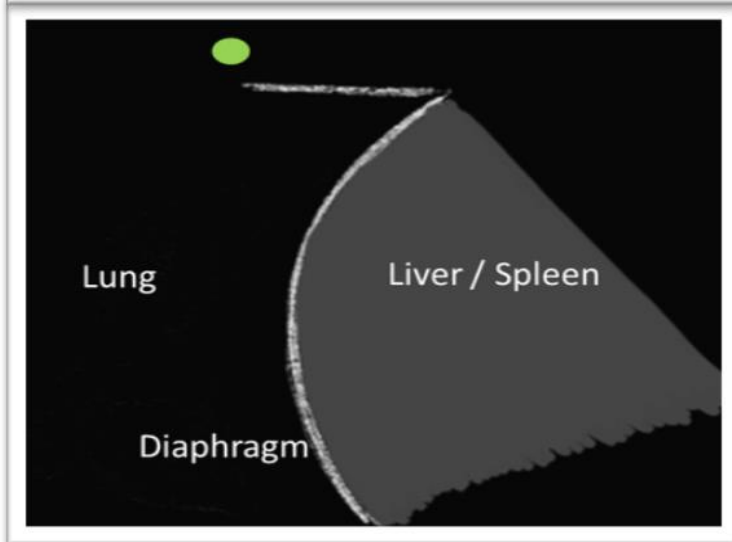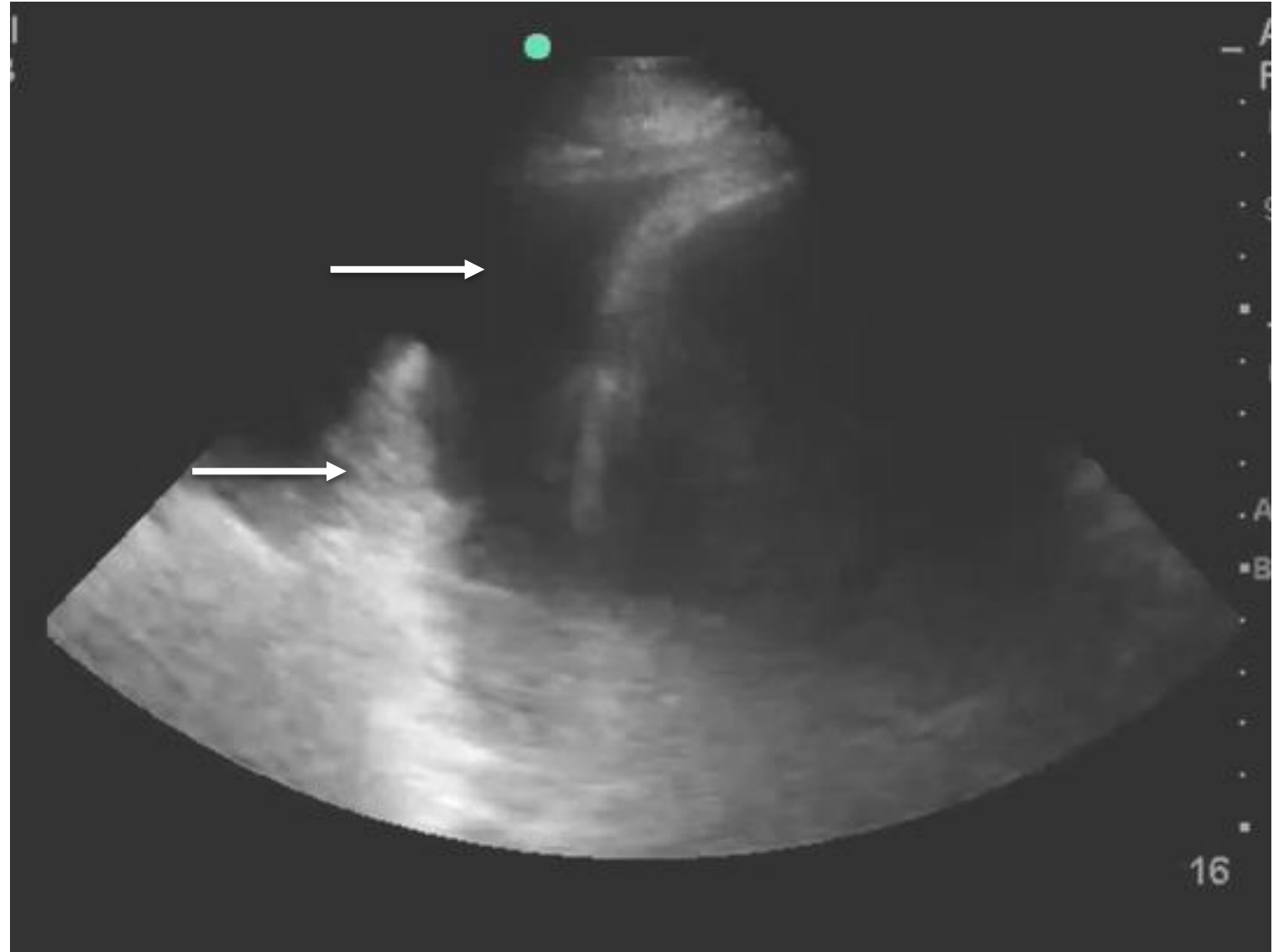
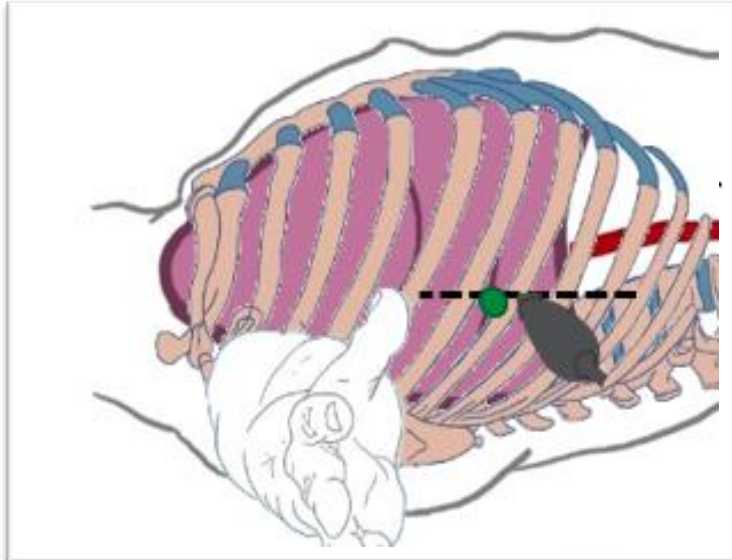


LUNG ULTRASOUND CONSOLIDATION



LUNG ULTRASOUND

PLEURAL EFFUSION



QUESTIONS AND DISCUSSION

Breunig.Michael@mayo.edu

