

Common Orthopedic Conditions of the Knee (Part 1) Intra articular injuries

Musculoskeletal Galaxy Conference 2023

Ljiljana Bogunovic, MD

Orthopedic Surgeon Sports Medicine

Orthopedic Associates of Wisconsin



Disclosures

- I have no relevant commercial relationships to disclose

Learning Objectives

- At the conclusion of the session, participants should be able to understand the presentation, diagnosis and treatment of common intra-articular injuries of the knee including ACL tears, meniscal tears and cartilage injuries.

Case 1

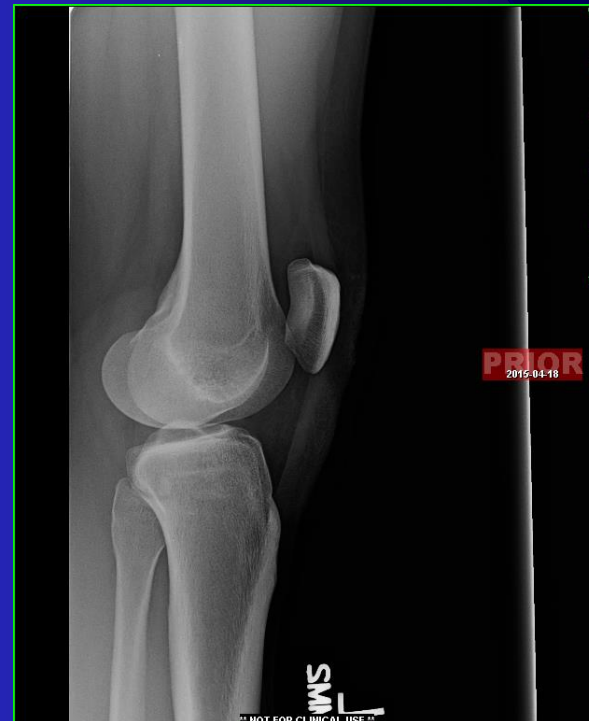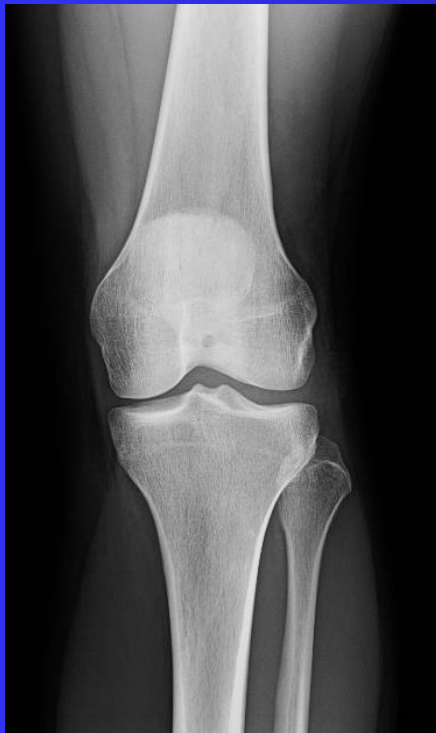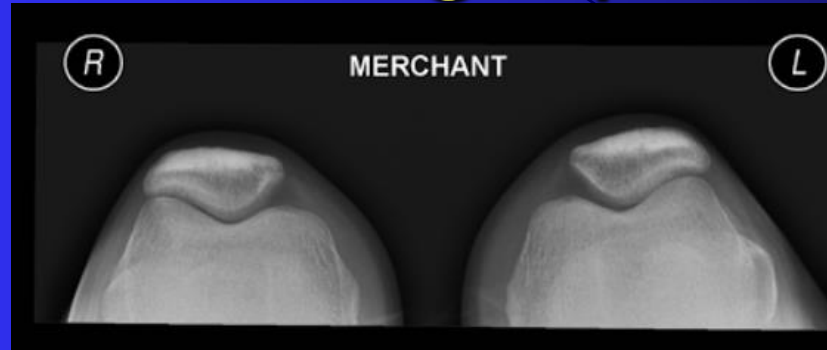
- 17 yo female rugby play with left knee pain
- Felt a "pop" in her knee while making a cut
- Immediate pain and swelling
- Unable to return to play
- Difficulty bearing weight
- No previous history of knee injury or pain



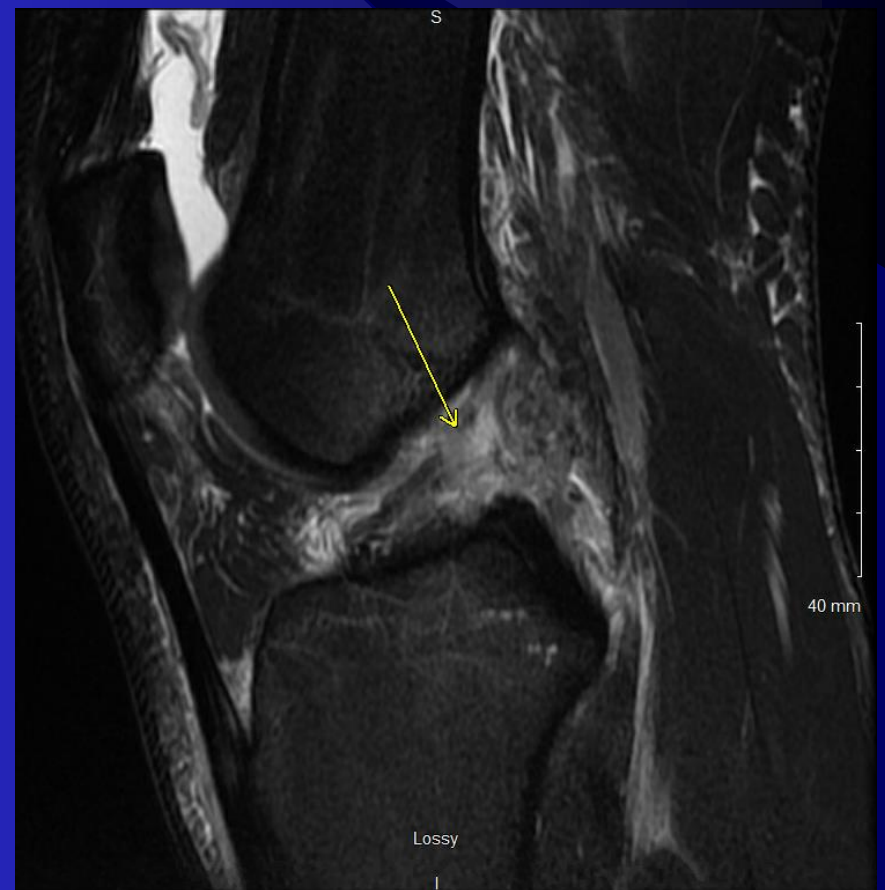
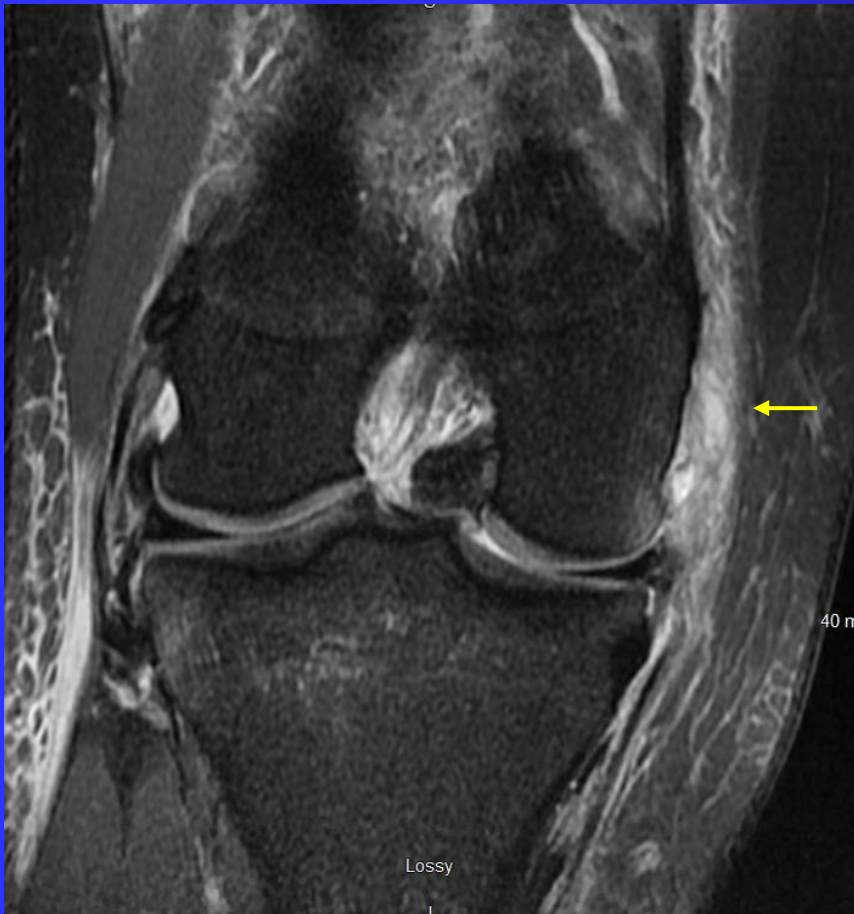Physical Examination

- Moderate Effusion
- Motion 0-120 degrees
- Stable to varus stress at 0-30 degrees, grade 2 instability to valgus stress at 0 and 30
- 2B Lachman, + Ant drawer, guarding pivot
- Neg Post drawer
- Neg Dial at 30 and 90 degrees
- NVI

Radiographs



MRI

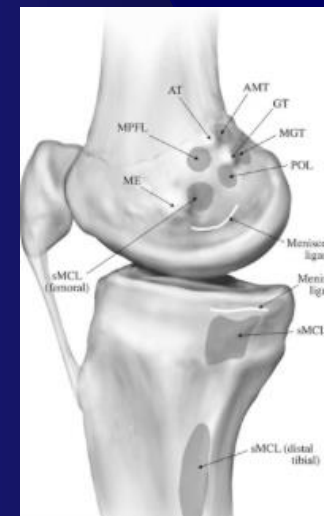
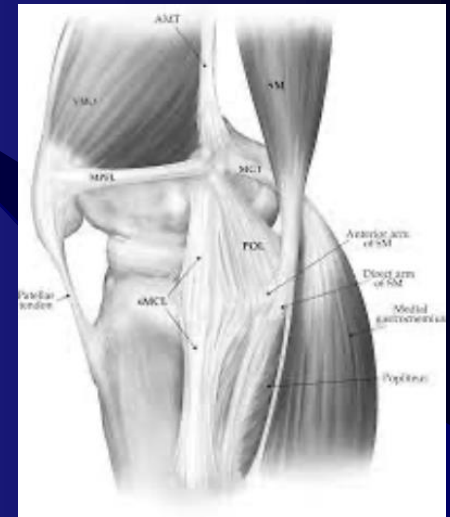


Diagnosis

- ACL tear
- MCL Tear

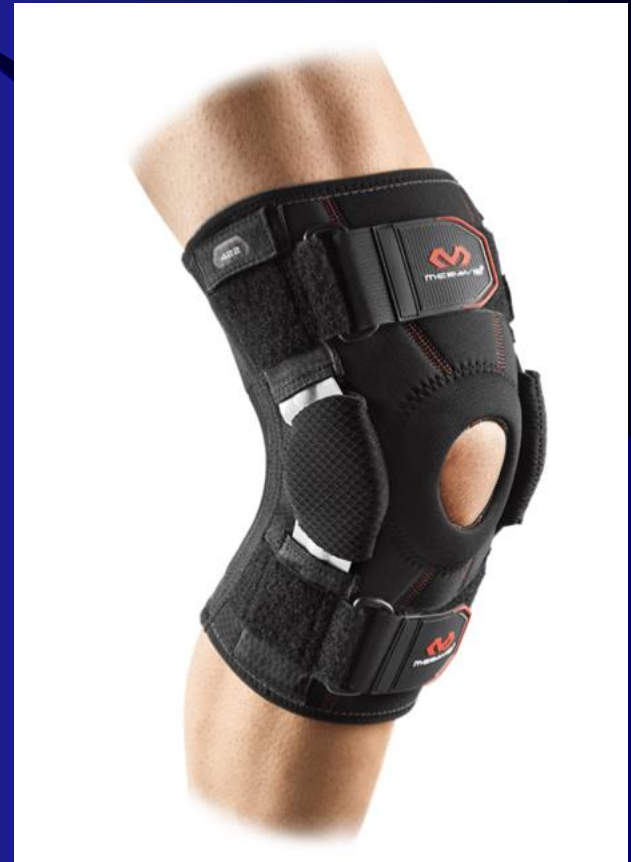MCL Tears

- Most frequently injured ligament of the knee
- Primary restraint to valgus stress
- Isolated and combined injuries
- Femoral side vs tibial sided injuries



Treatment


- Nonoperative management
>>>>Surgical reconstruction
and/or repair
- Bracing for 4-6 weeks
- When combined with ACL tear,
delay ACL recon until after
MCL healing



ACL TEARS

Epidemiology

- Commonly injured knee ligament
- 100,000 – 200,000 each year in the US
- NCAA Surveillance System (1988)
 - Football highest numbers (53%)
 - Female gymnast highest rate (1/330)
 - Females > males
 - Soccer: 3.5, Basketball: 2.7
 - Hockey / Baseball – low incidence
- Skiing (beginners > experts)



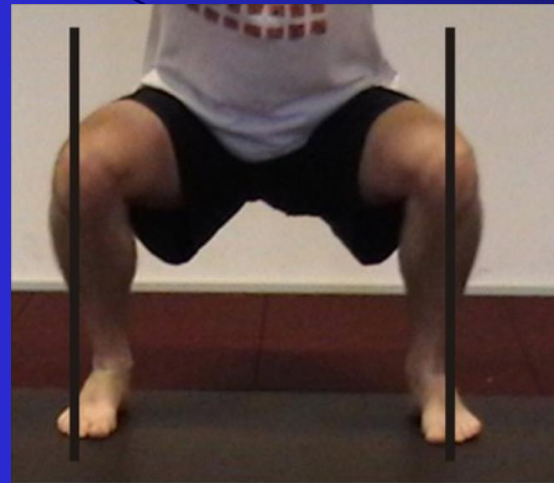Mechanism of Injury

- Often non contact (70%)
 - Sudden change in direction
 - Quick deceleration, hyperextension or rotational injury
- Contact

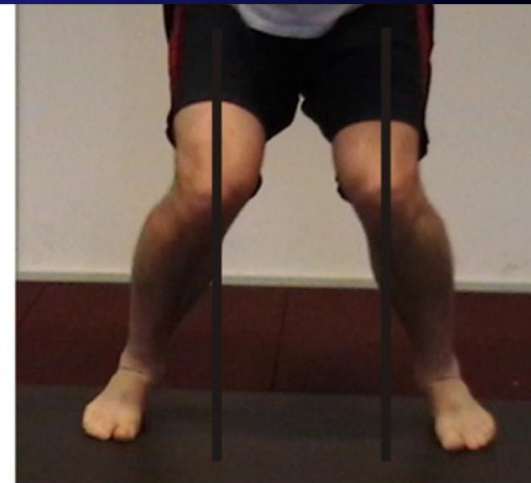

Risk Factors

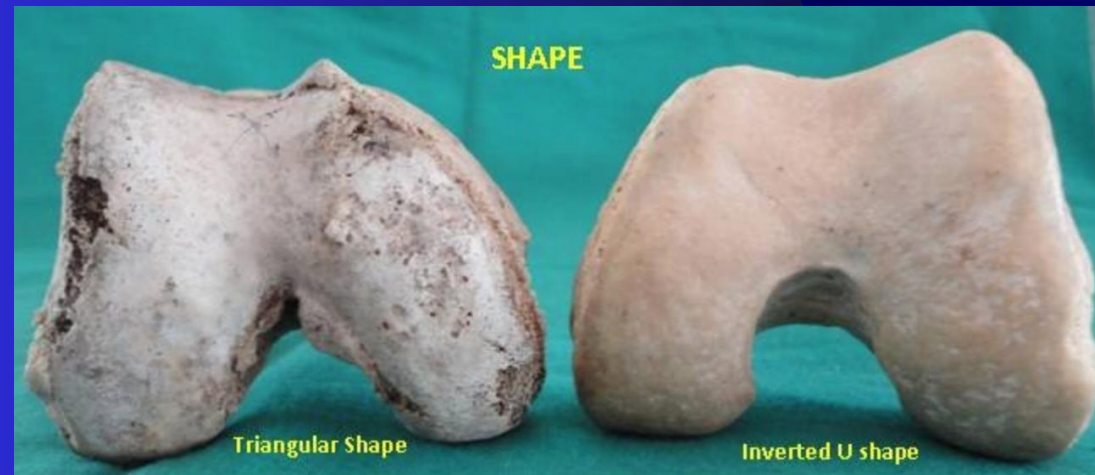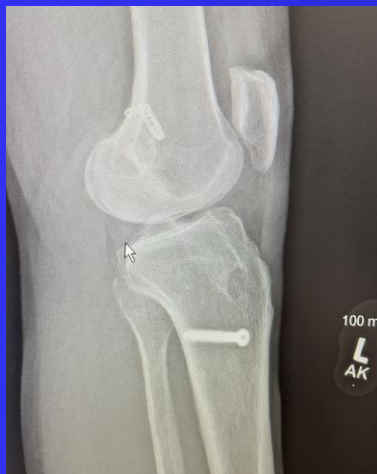- Female gender
- Knee valgus with pivot, deceleration or landing
- Quadriceps dominance
- Playing surface:
↑ with traction
- Decrease notch width /
Increased tibial slope



Good



Bad



Patient Presentation

ACUTE

- Report a “pop”
- Unable to return to play
- Effusion (24 hrs / 70%)
- Pain with weight bearing

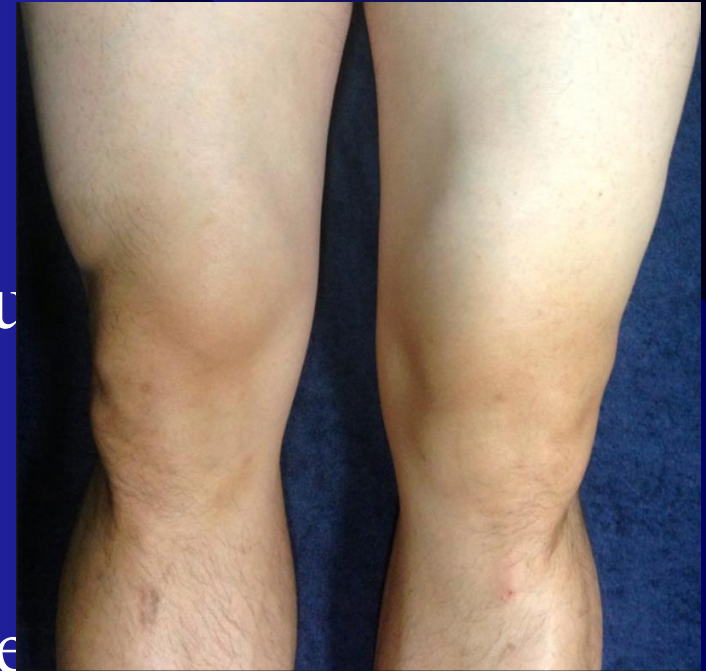CHRONIC

- Shifting events
- Restored ROM
- Minimal to no swelling



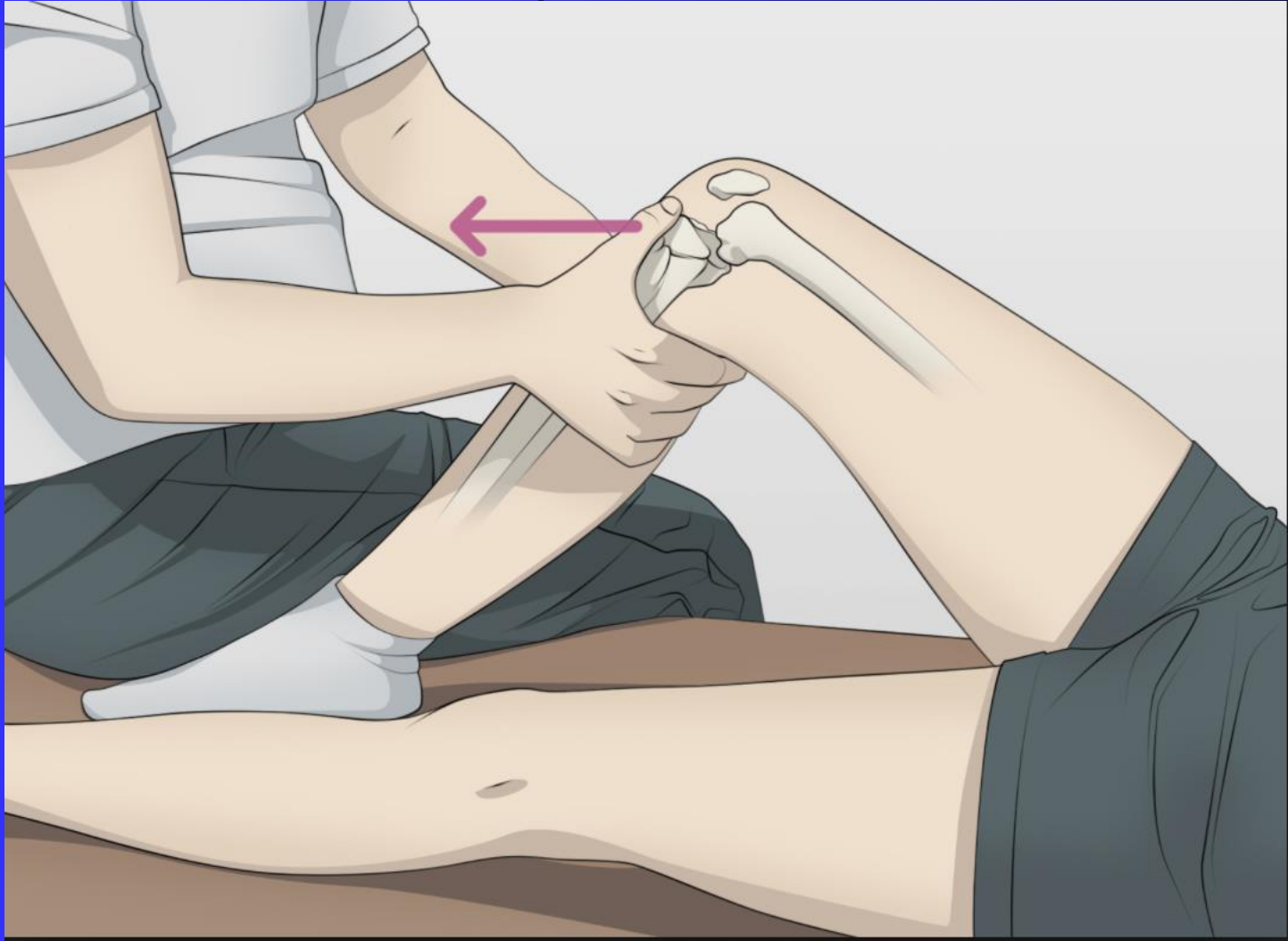
Physical Examination

- Often limited in the subacute setting
- Effusion
- Limited ROM
- Lateral joint line tenderness
- Assessment for concomitant injury
 - Varus/valgus laxity (LCL/MCL)
 - Posterior drawer (PCL)
 - Dial test (PCL/PLC)
- Generalized laxity and excessive hyperextension



COMPARE TO THE NORMAL KNEE!!!!

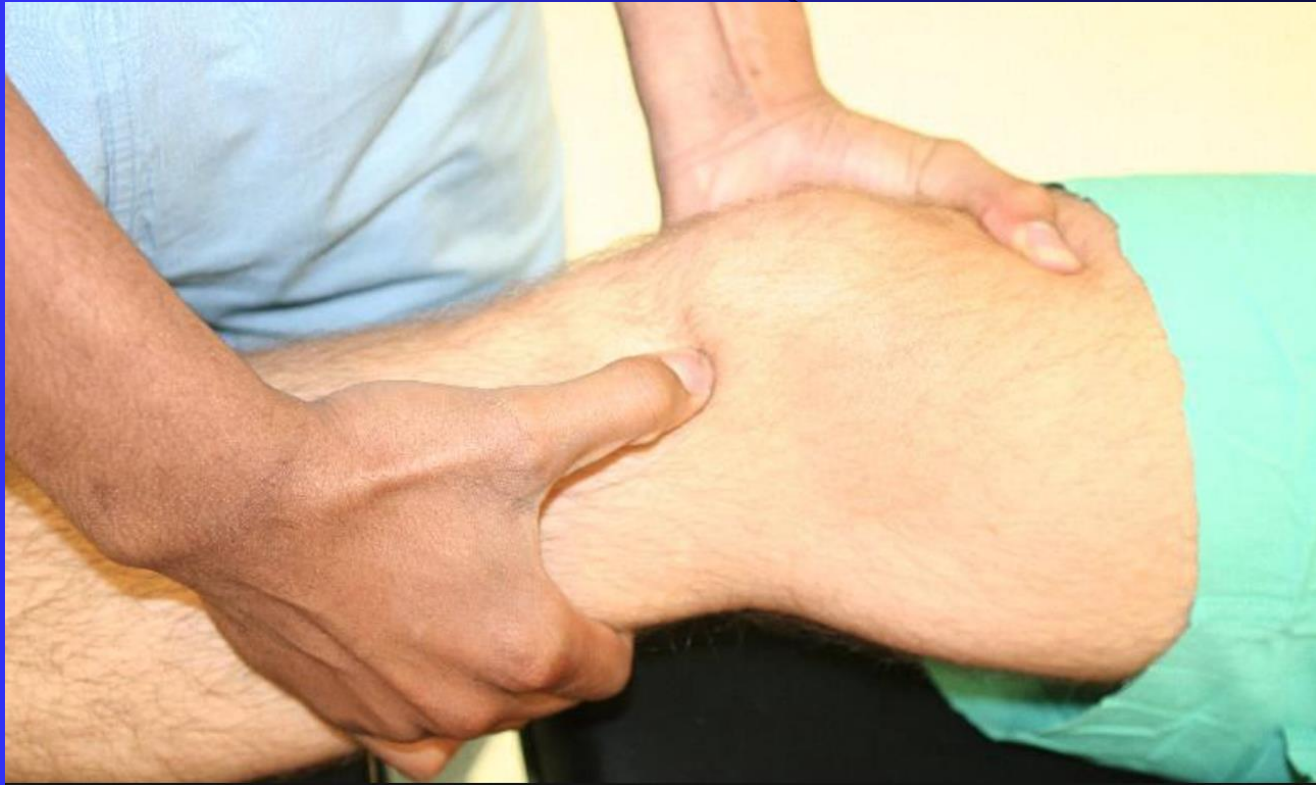Anterior Drawer



Make Sure No Posterior SAG

Lachman

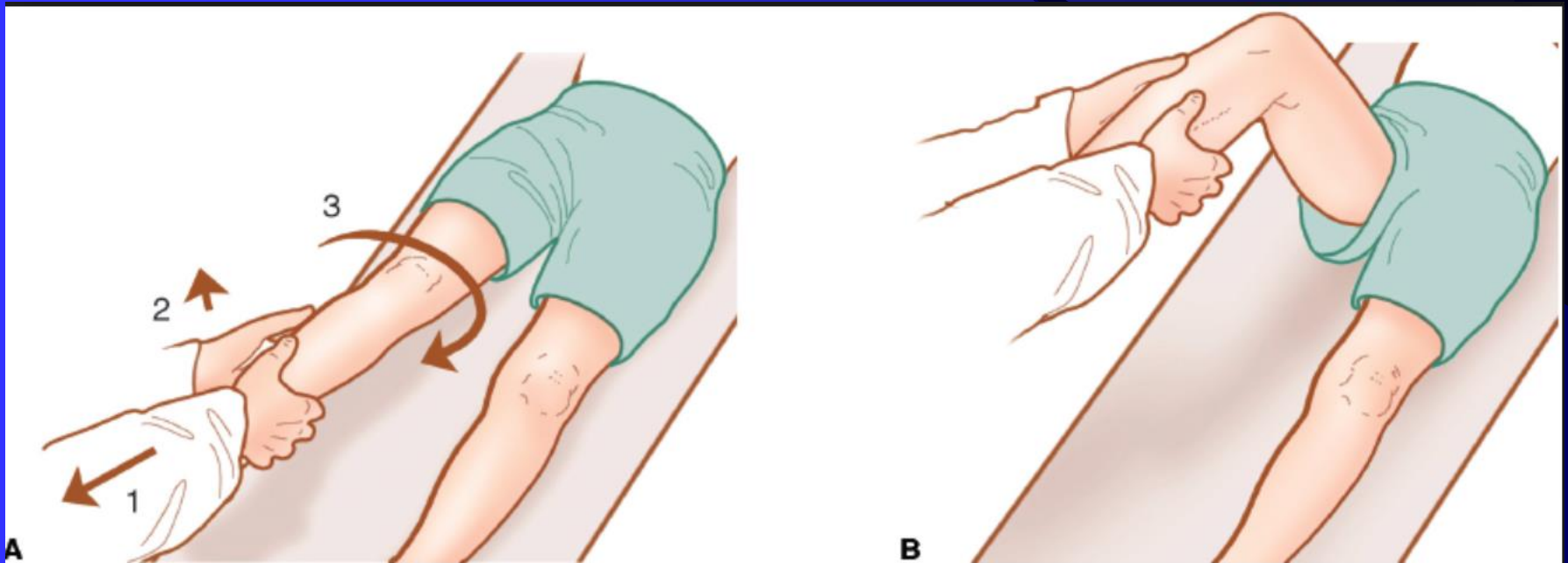
Most Sensitive 85%



Grade 1 (0 – 5mm), Grade 2 (5 – 10mm), Grade 3 (>10mm)

Endpoint: A (Firm), B (Soft)

Pivot Shift



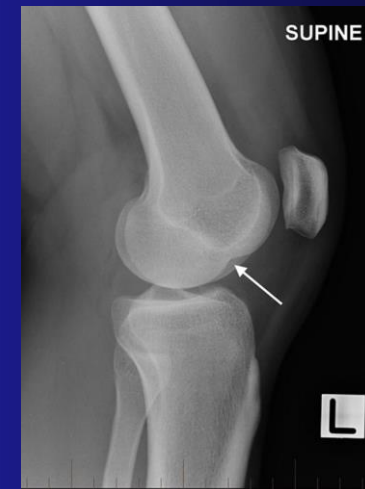
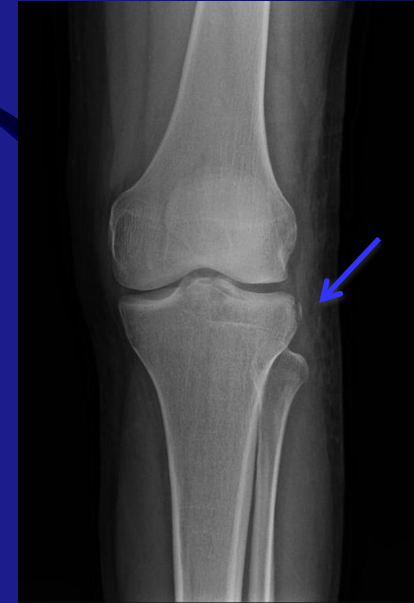Most Specific 94%

Imaging: Xrays

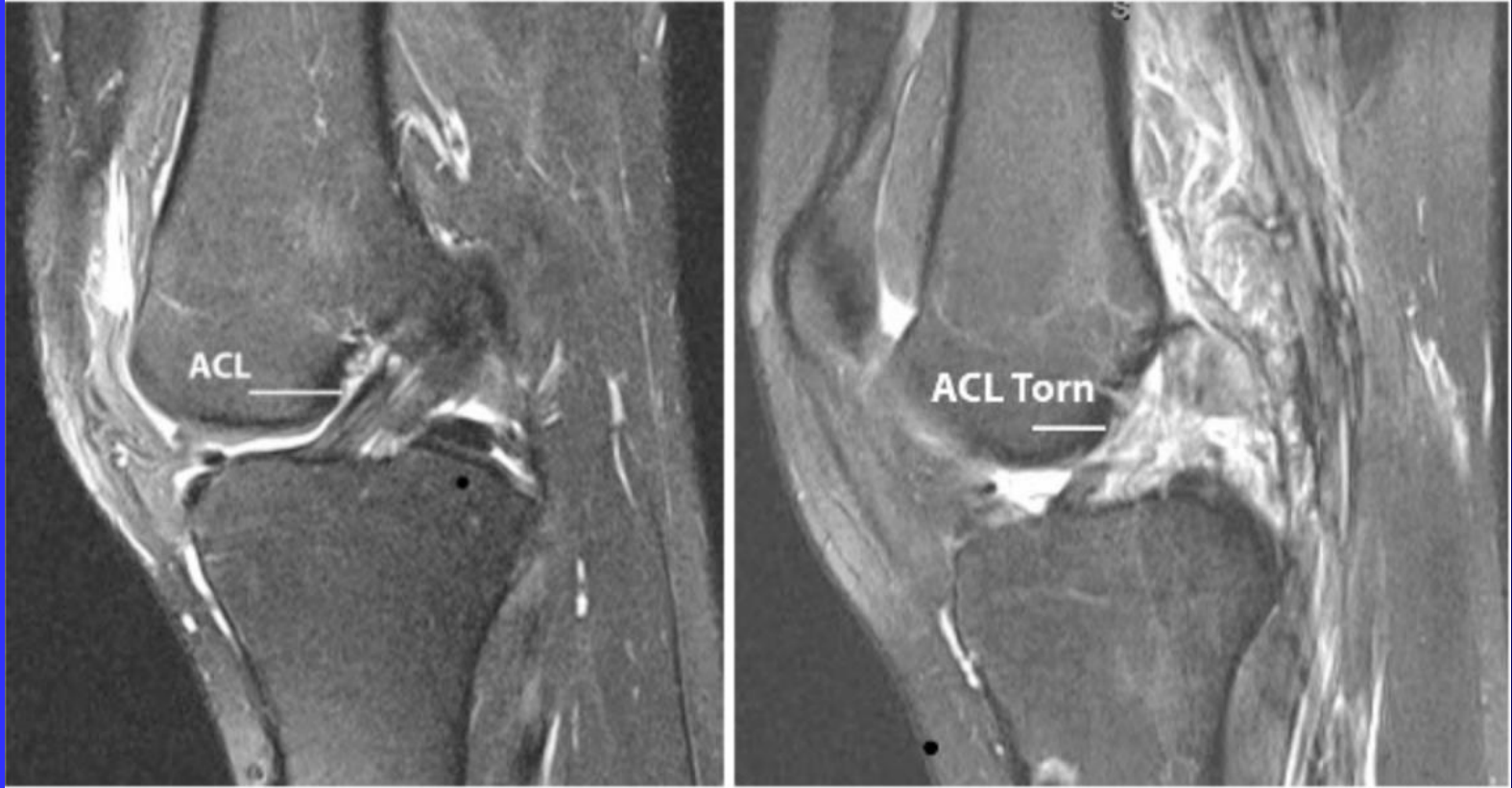
Segond Fracture

- Avulsion of the anterolateral capsule
- Pathognomonic for ACL injury

Impaction at the sulcus terminalis on the lateral femoral condyle

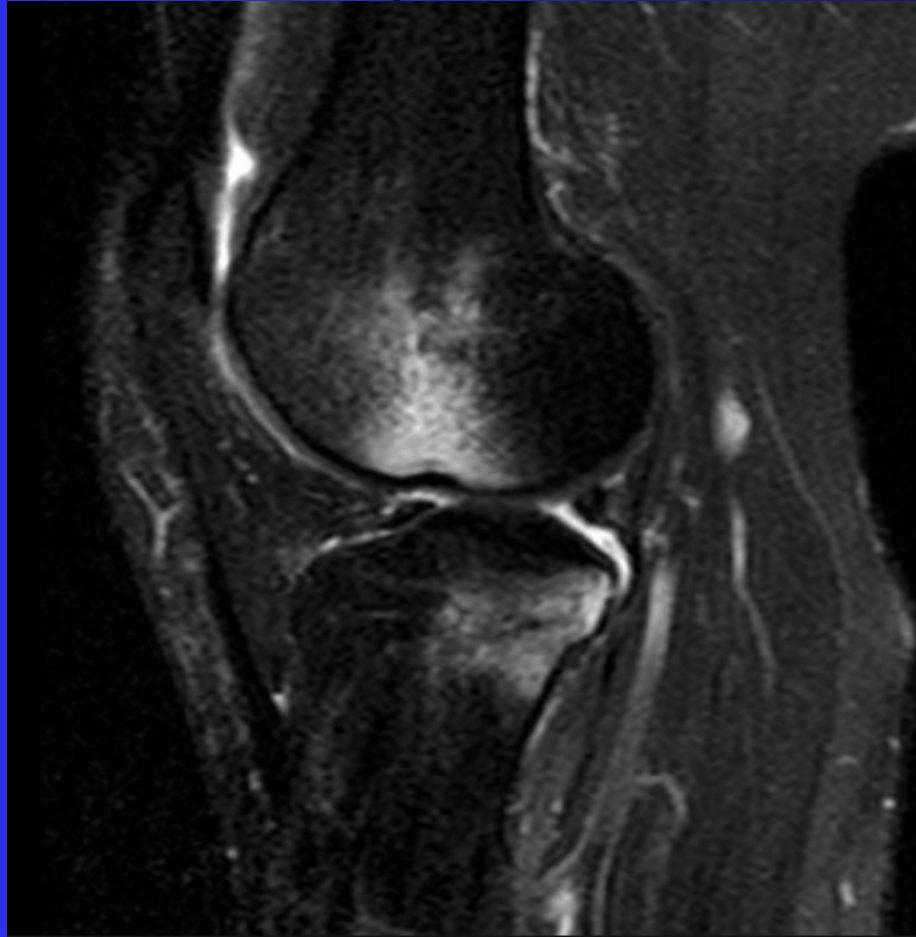


Imaging: MRI



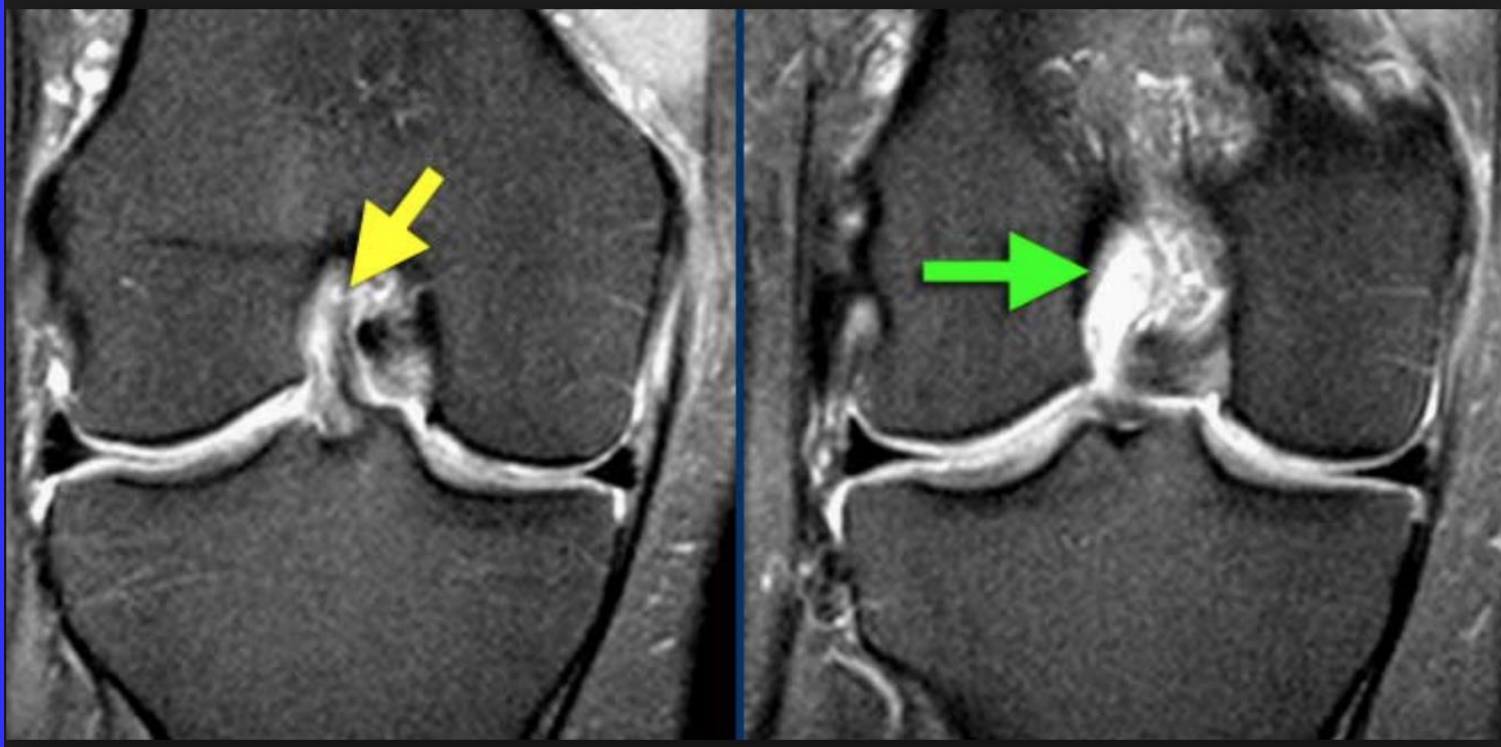
SAGITTAL

Imaging: MRI



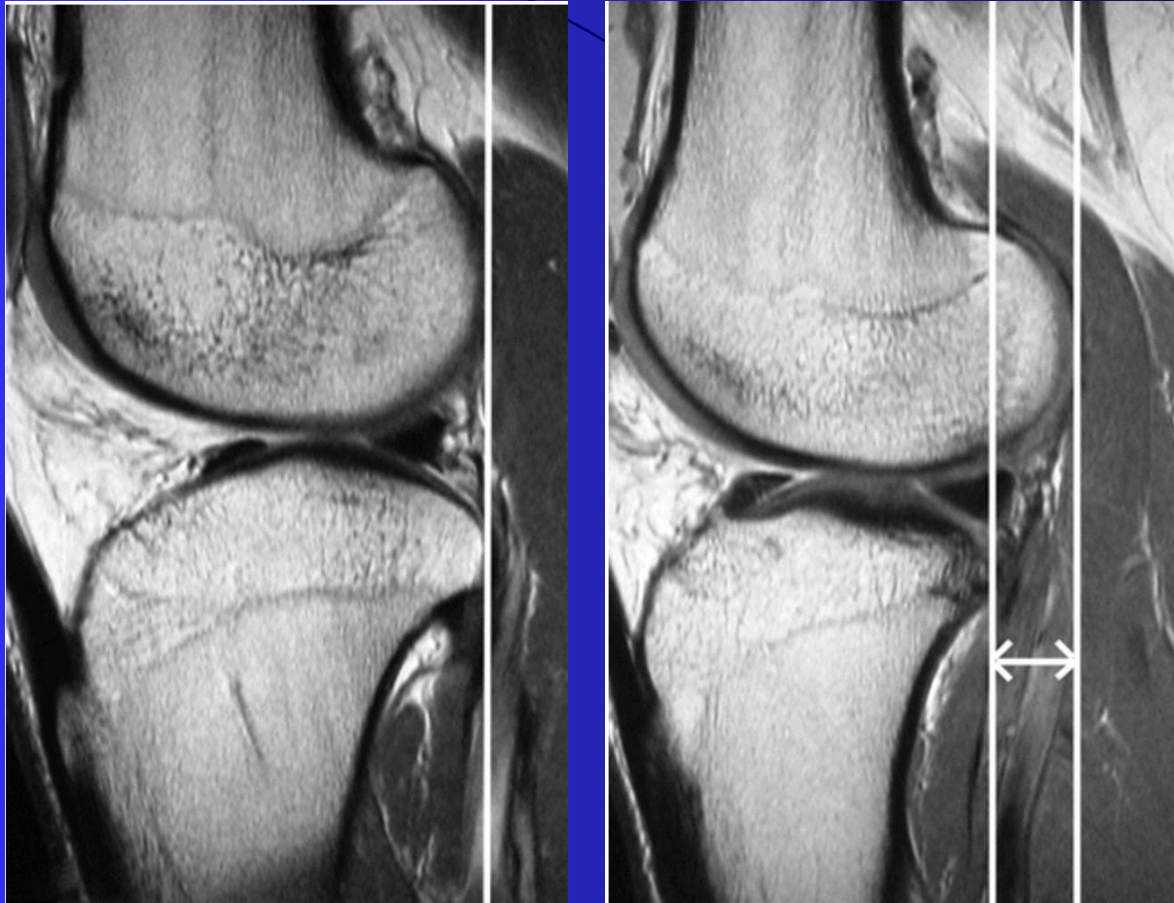SAGITTAL T2 — “Bone bruise”

MRI Imaging



CORONAL – “Empty wall”

Imaging: MRI



SAGITTAL — “Anterior tibial translation sign”

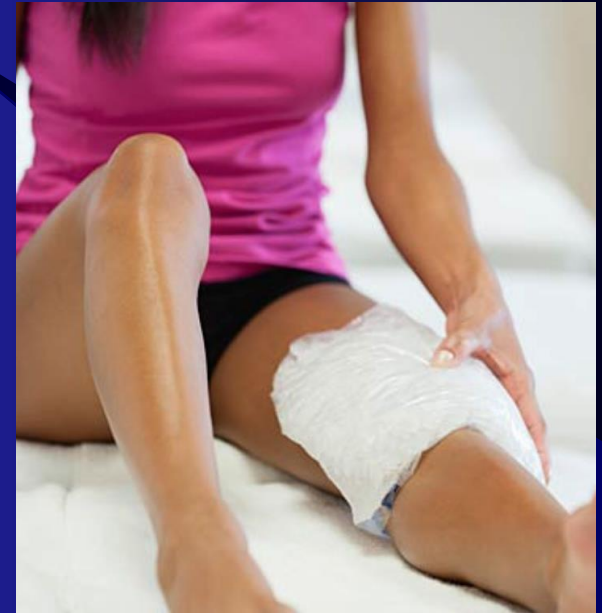Treatment

Initial

- R.I.C.E, restore ROM, wean from crutches

Long Term

- Nonoperative
- Operative



GOAL is to AVOID SHIFTING EVENTS

Activity Limitations

Bracing

Surgery

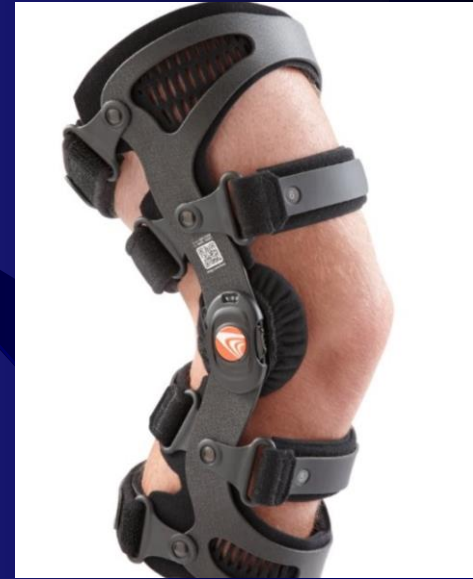Nonoperative

Indications

- Low demand
- Straight line activities (walking, cycling, etc)
- Failure nonoperative treatment / Instability with ADLS (33%) Grindmen JBJS 2014

● Treatment

- Physical therapy: optimize quad, hamstring, gluteal and core strength



Operative

Indications

- Cutting, jumping, pivoting sport
- Younger age
- Failed trial of nonop

Considerations

- Autograft vs Allograft
- Autograft choice:
BTB, hamstring, quad,
contralateral BTB



Autograft vs Allograft

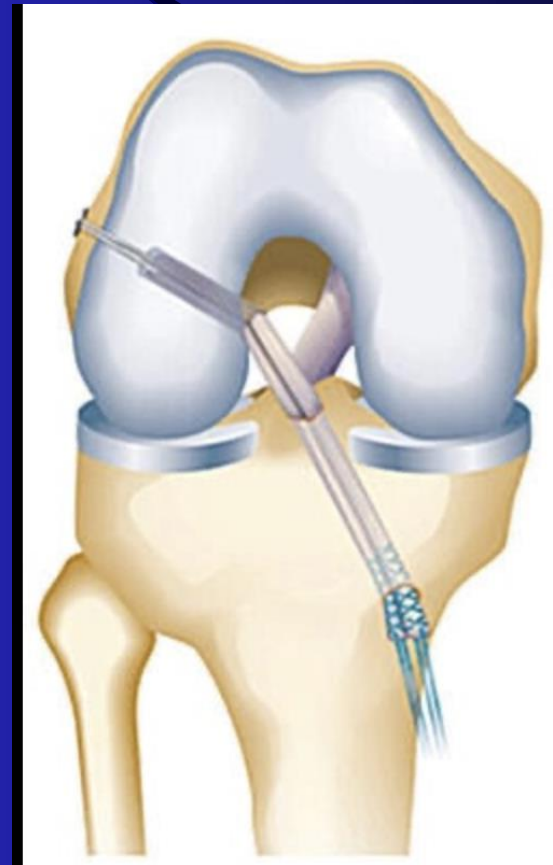
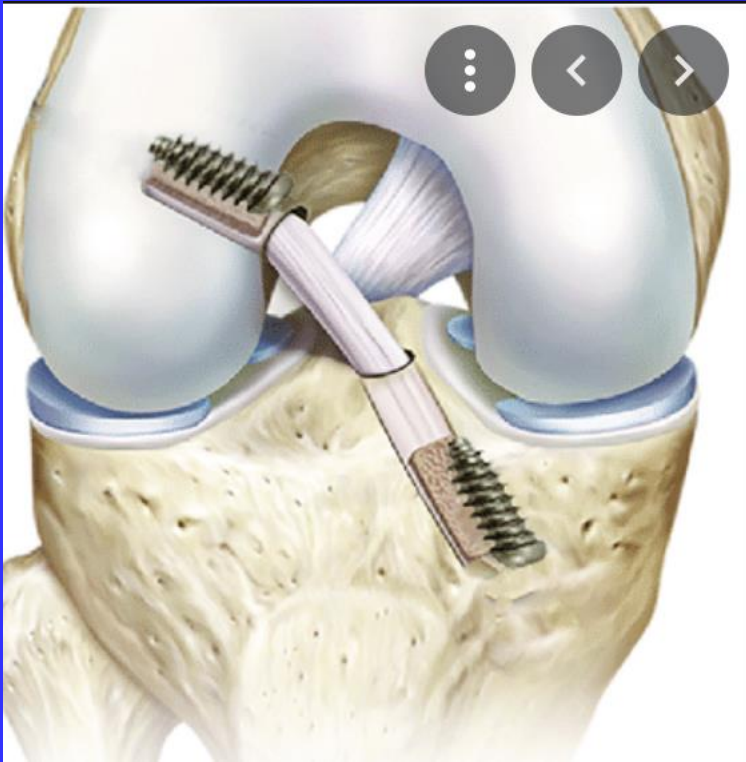
Autograft

- Lower failure rate
- Faster maturation
- Donor site pain
- Not always an option in revision and multilig

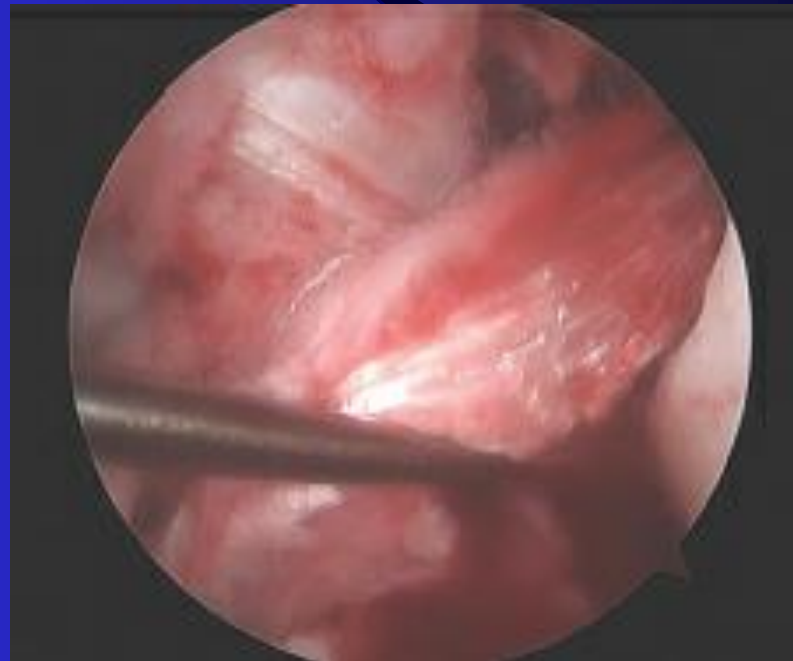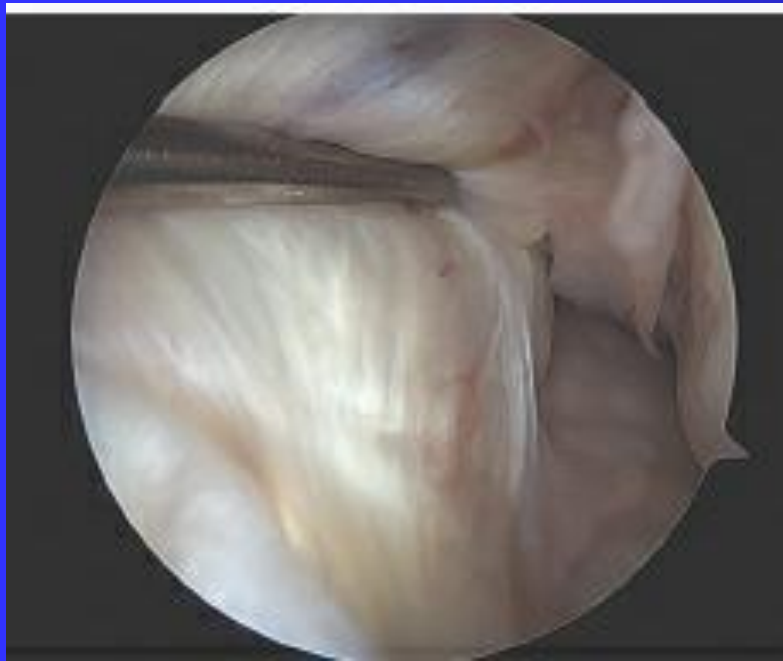Allograft

- Decreased morbidity
- Decreased OR time
- Disease transmission (< 1.1 million)
- Increased time to incorporation
- **INCREASED FAILURE RATE (> 4 X higher)**

ACL Tears



ACL Tears



Postoperative

- Weight bear as tolerated immediately after
- No routine DVT prophylaxis
- Physical therapy within 5 days
- Elliptical at 6 weeks, straight line running at 12 weeks
- Return to sports 6-8 months post op

Outcomes

- Recurrent ACL tears after reconstruction can happen
 - Younger and more active patients are more likely to re-injure their ACL 10-20%
- Allograft has a 4x higher failure rate than autograft
 - Over 30, this difference is not clinically important
- Post-operative recovery 6-12 months back to sports

Case 2

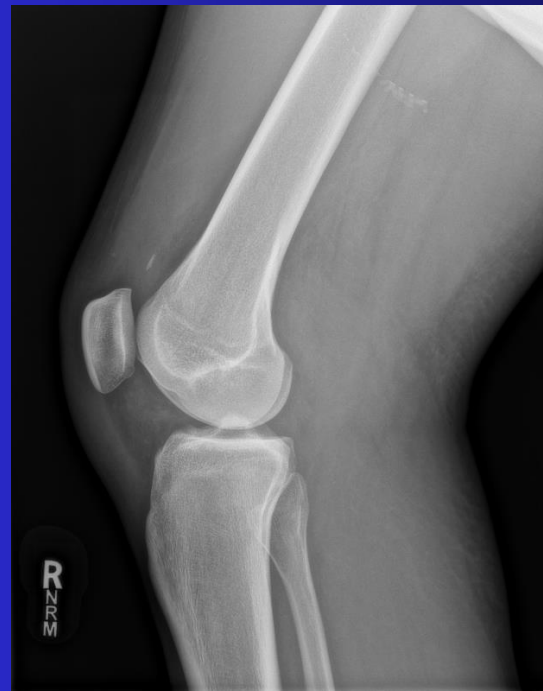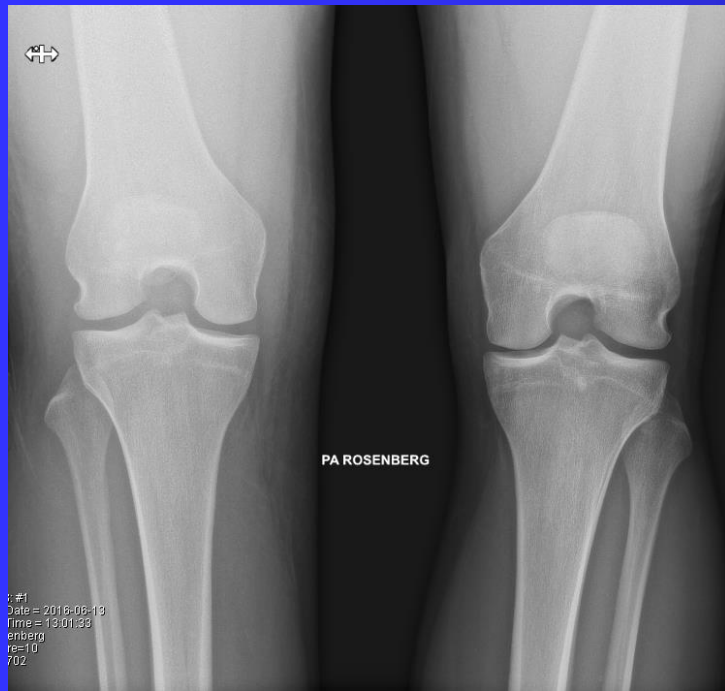
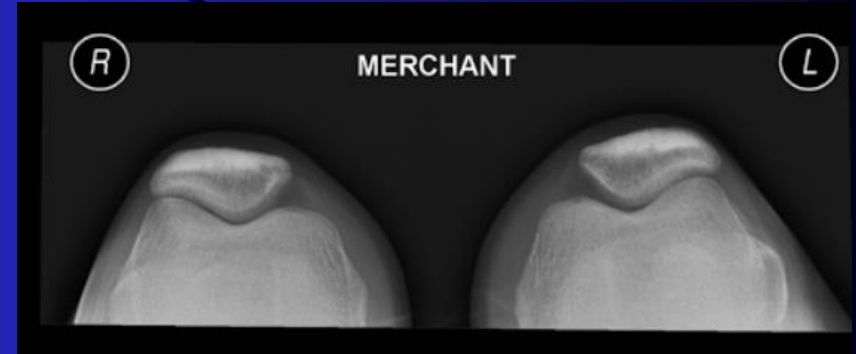
- 55 yo male with left knee pain and swelling
- No specific injury
- Worse with squatting and twisting
- Occasionally catching and popping
- Pain rolling over in bed
- Minimal improvement with ice and NSAIDs

Physical Examination

- Moderate swelling
- Stable to varus and valgus stress
- Negative Lachman, Ant/Post Drawer
- Medial joint line tenderness
- Positive McMurray (medial)
- NVI

Radiographs

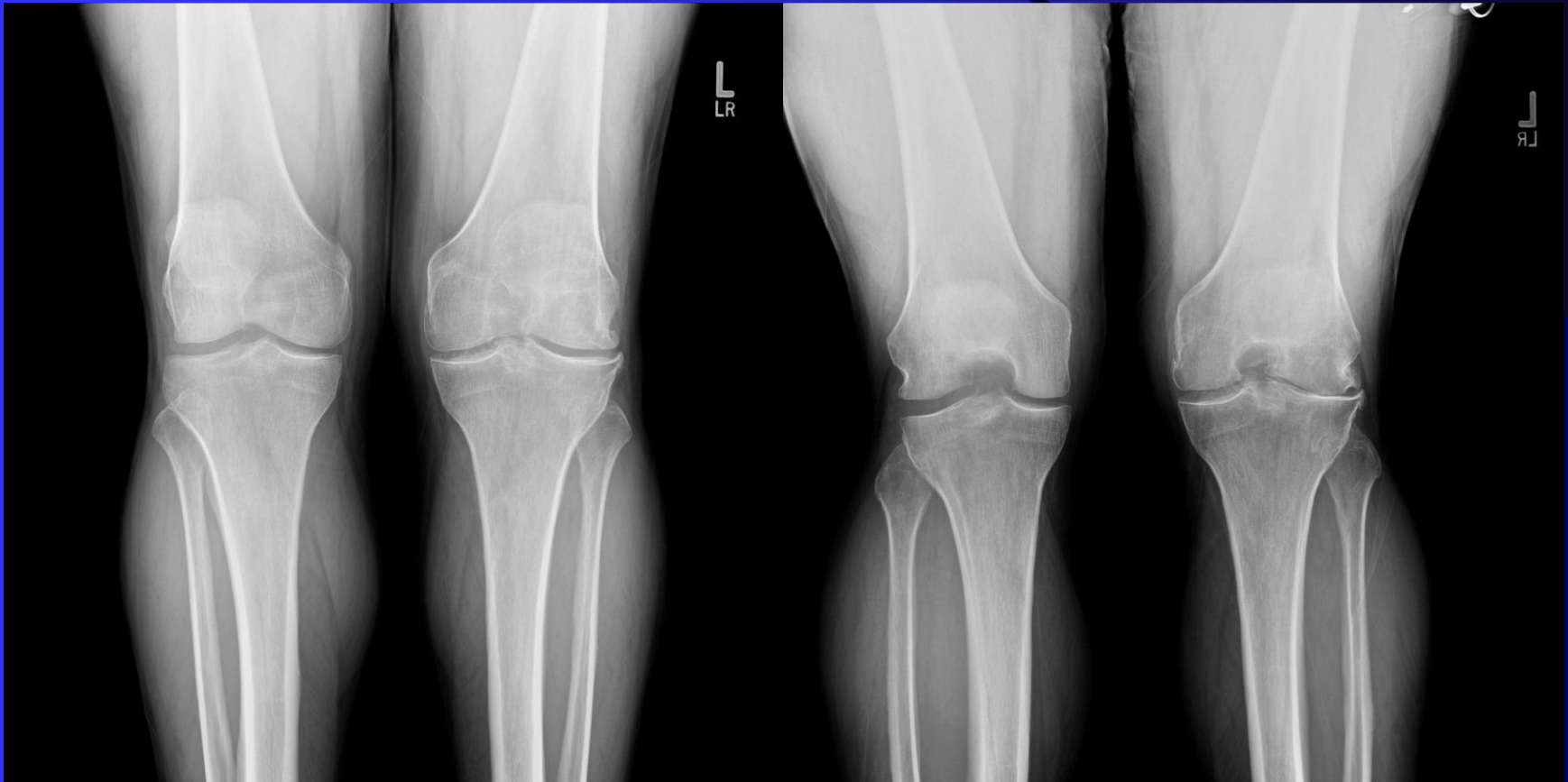- Weight bearing!!!!
 - Need to rule out arthritis



Rosenberg View

AP

30 degree flexion PA

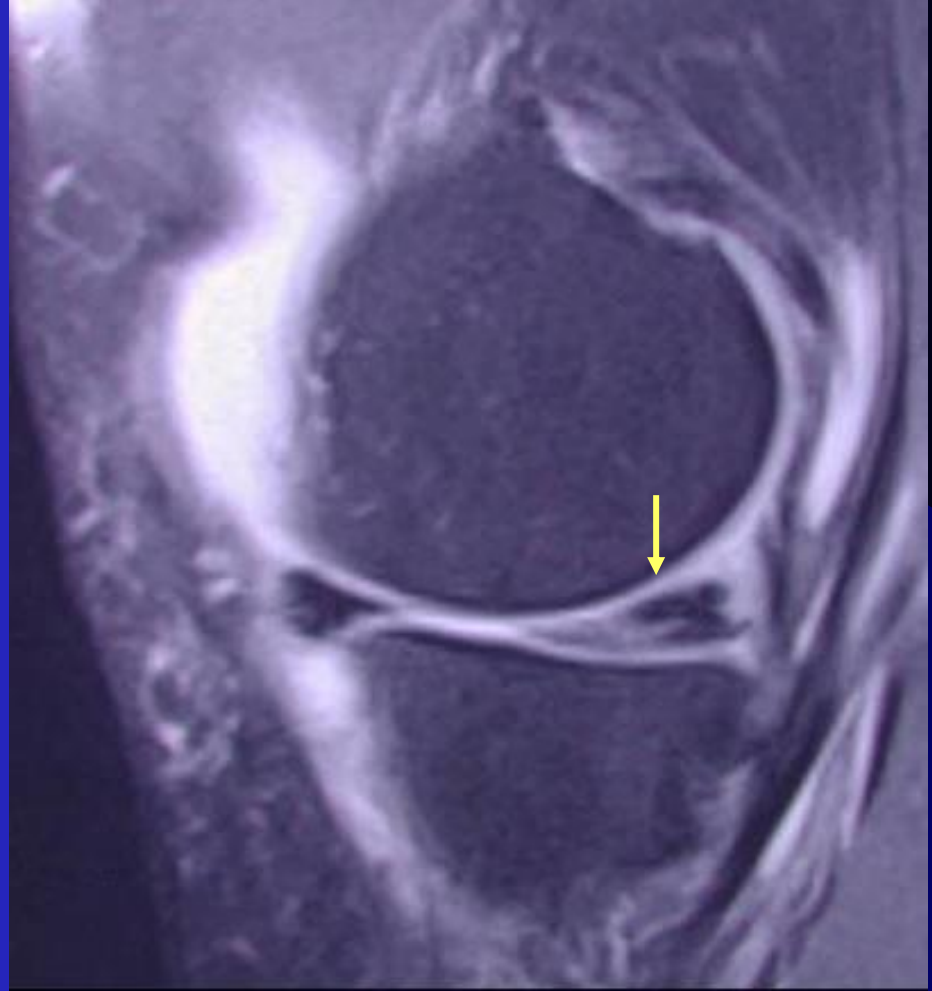
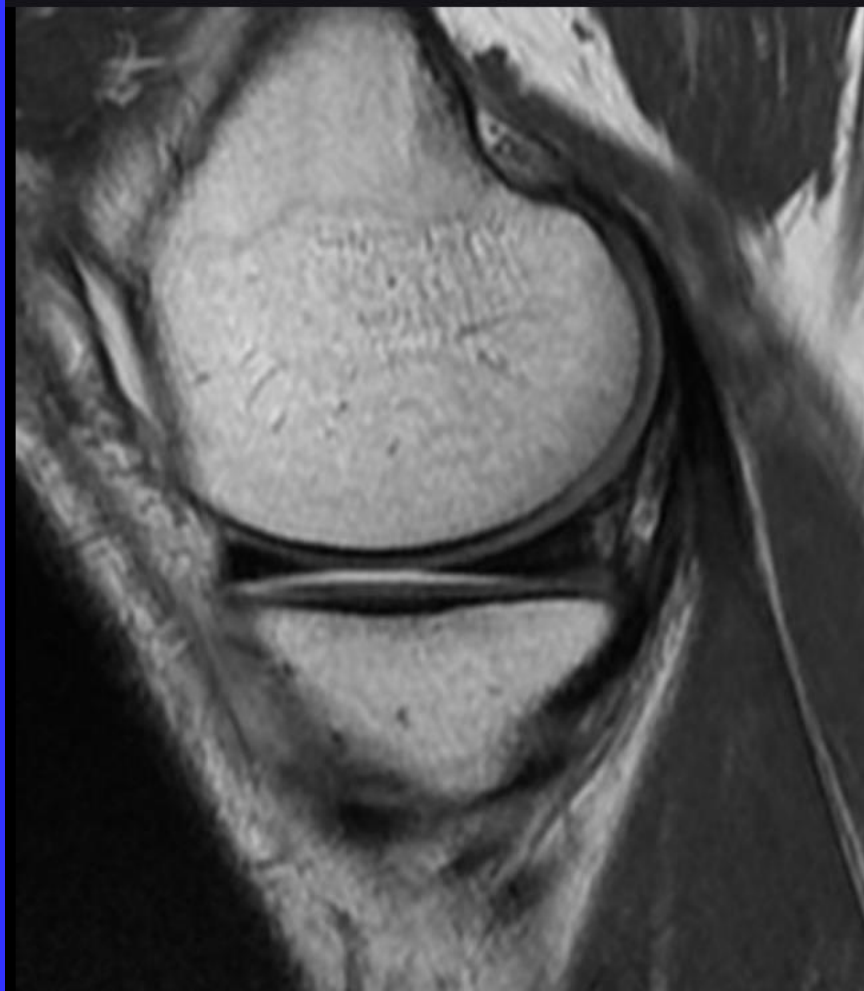


Profiles the posterior condyle. More sensitive in early OA

Next Step

- Trial of Nonoperative management
 - Cortisone Injection (decrease inflammation)
 - Physical Therapy (increase lower extremity strength and mobility)
- Advanced imaging with MR
 - Reasonable in patients with meniscal symptoms but minimal to no evidence of OA on plain films
 - Consider in patients with normal plain films and mechanical symptoms

MRI

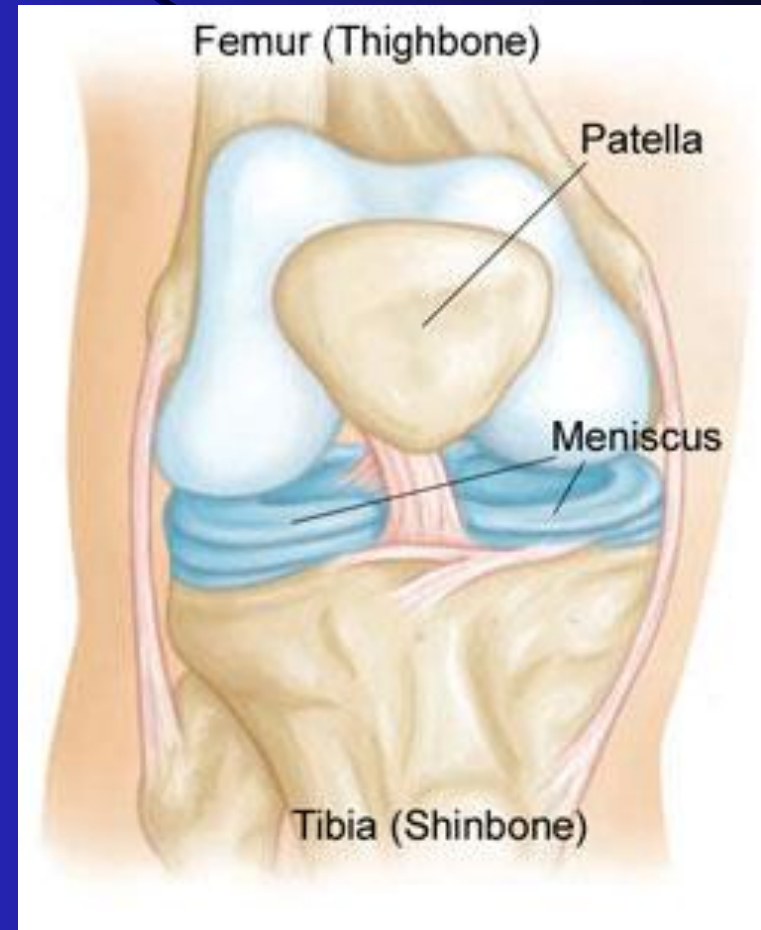


Diagnosis

- Meniscal Tear

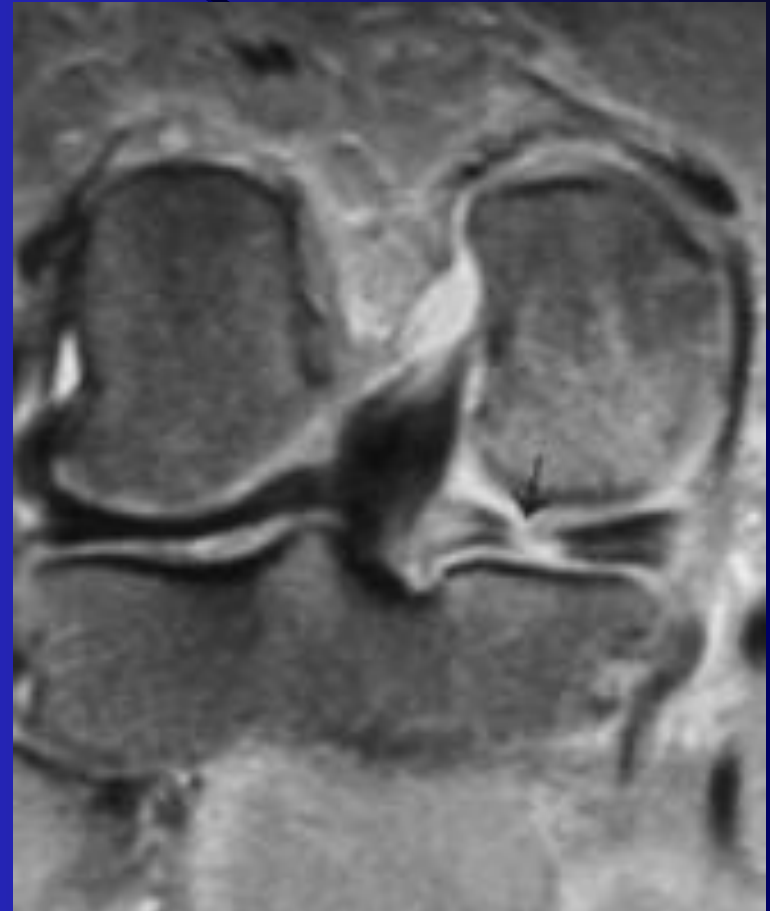Mensicus

- Wedge-shaped cartilage between the femur and the tibia
- Act as "shock absorbers" for the knee joint
 - Protects the joint cartilage



Meniscus Tear

- 12-14% of knee related injuries
- Occur as a result of
 - Sports injuries
 - Squatting
 - Twisting
 - Associated ligament injury
 - Degeneration due to age
 - Tear with awkward twist
 - Getting out of a chair
 - Deep knee bends
 - Seen with arthritis as well

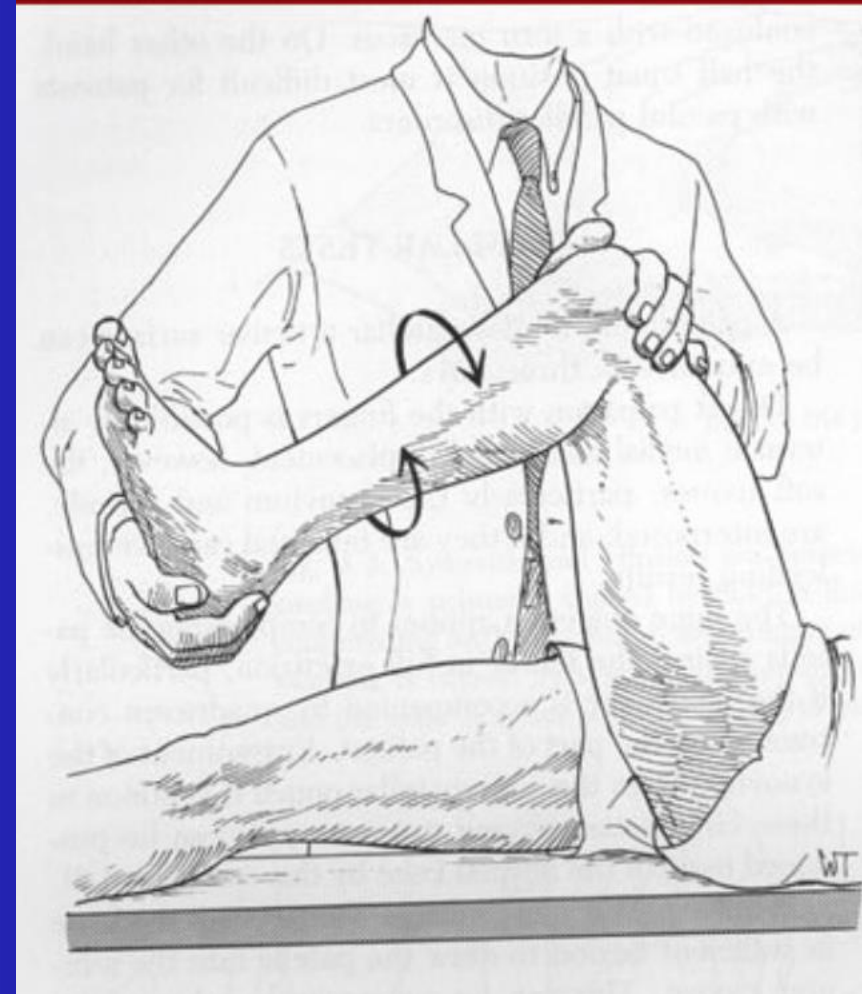

Symptoms

- Pain or popping with squatting or twisting
 - Usually isolated to one side of the knee or in the back of the knee
- Swelling or tightness
 - within a couple of days after injury
- Catching or locking (mechanical symptoms)
- Sensation of the knee "giving way"
- Pain rolling over in bed

Physical Exam

- Swelling
- Pain at end ROM
- Joint line tenderness
- + McMurray

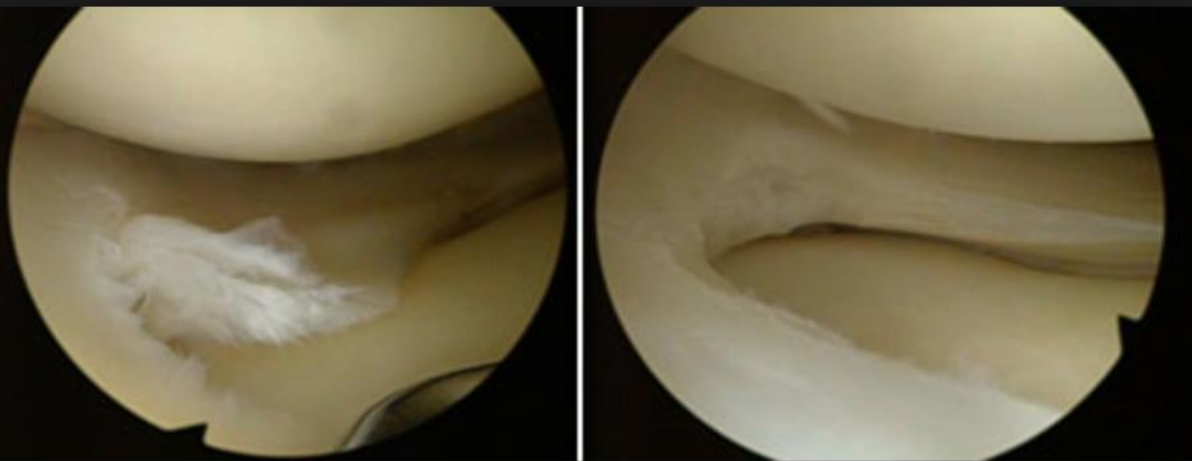


Treatment: Nonoperative

- Physical Therapy
 - Quad, Glute, Core strengthening
- Anti-inflammatory medication
 - NSAIDs (oral and topical)
 - Cortisone Injection

Treatment: Operative

- Arthroscopic Surgery
 - Symptoms without arthritis = good indication
 - Mild to moderate associated arthritis + meniscus tear = surgery may help depending pattern of symptoms
 - Advance arthritis = surgery rarely indicated



Post Operative

- WBAT immediately post operative
- No DVT prophylaxis
- 6 weeks of physical therapy starting week 2
- Avoid impact activities for 6 weeks
- Return to full activity at 6 weeks

Case 3

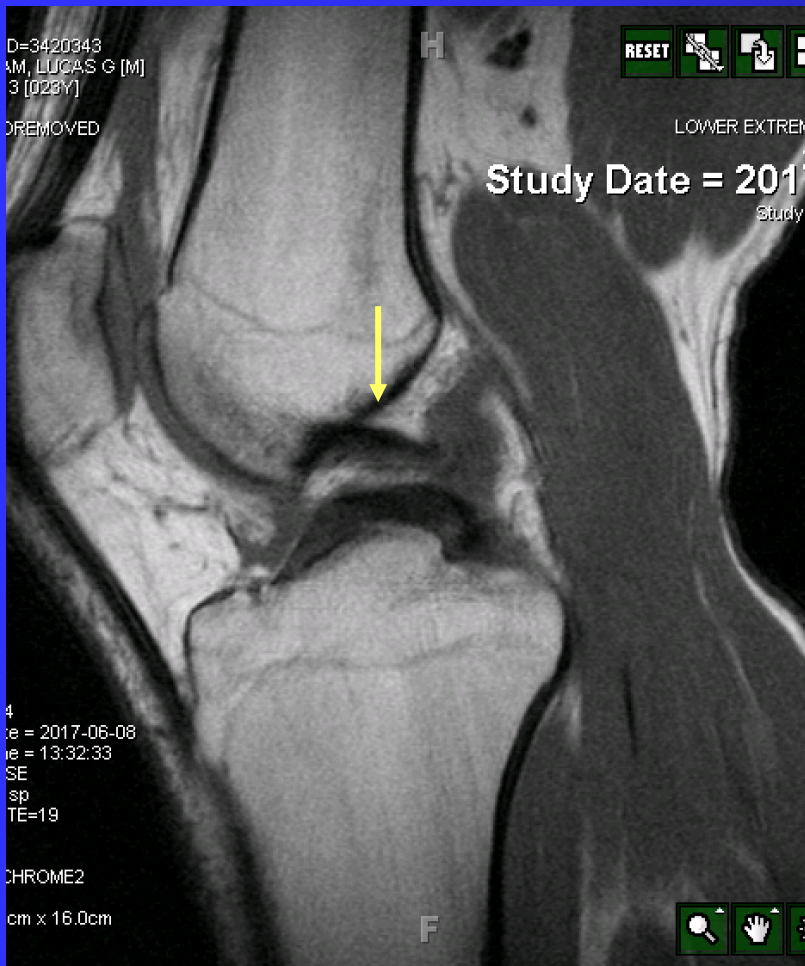
- 16 yo female soccer player with left knee pain
- Felt a "pop" during the game
- Immediate swelling
- Inability to extend the knee
- No previous history of knee injury

Physical Examination

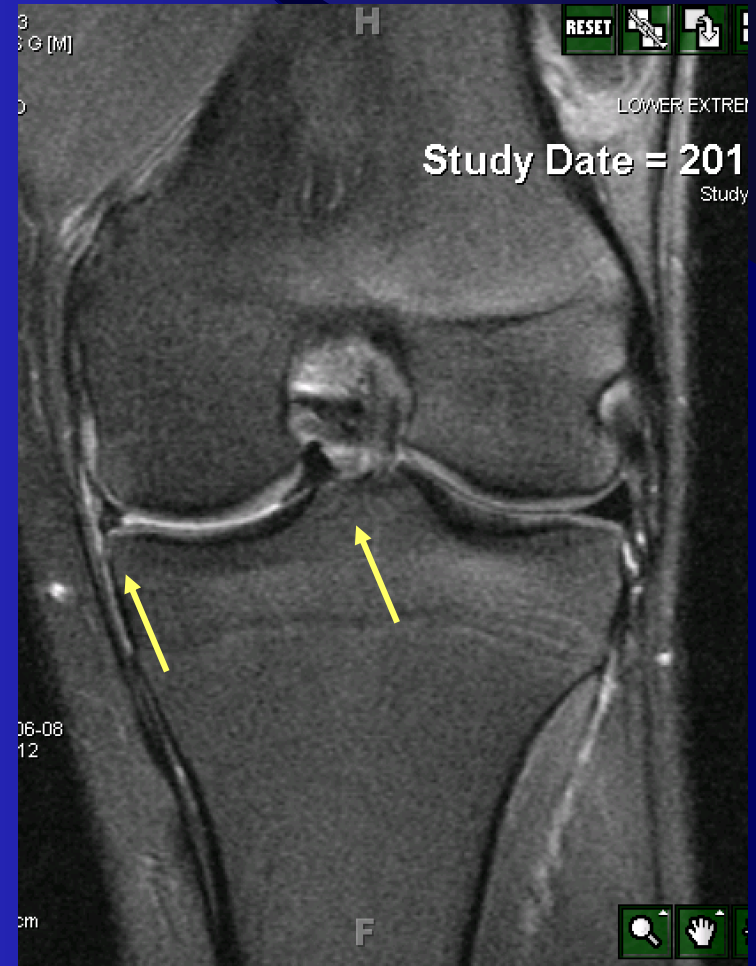
- Moderate swelling
- Motion from 20-60 degrees
- Stable to varus and valgus stress
- Negative Lachman
- Tenderness of the medial joint line
- NVI
- Radiographs normal

MRI

Double PCL



Flipped in Notch



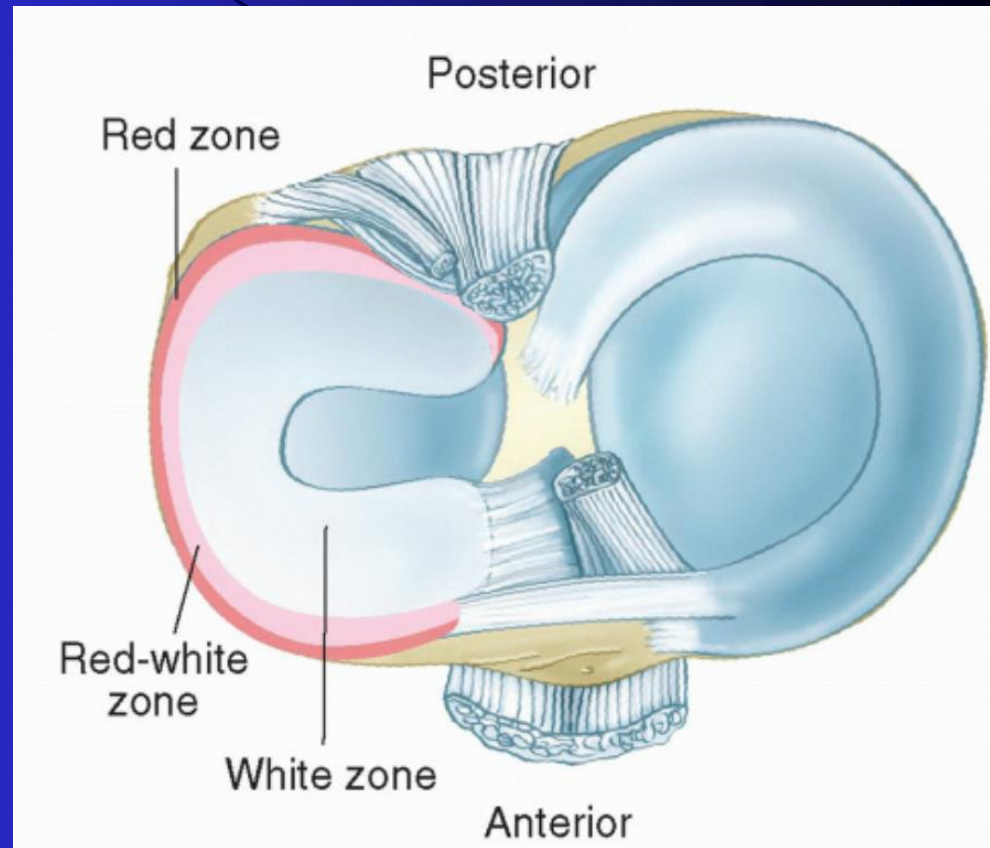
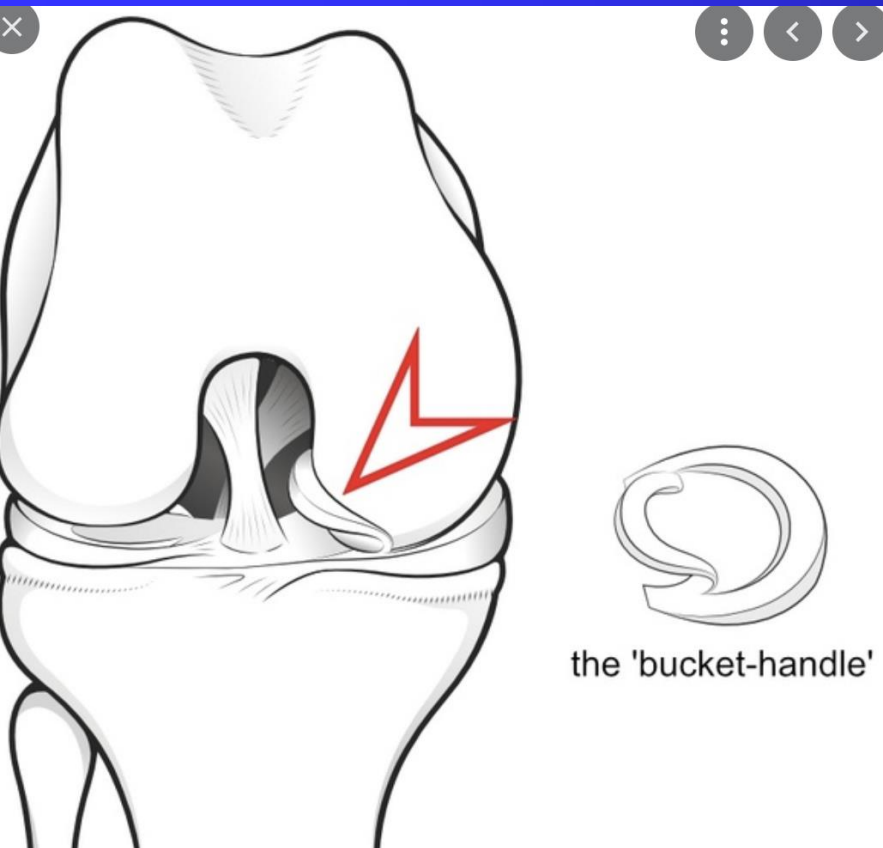
Diagnosis

- Bucket Handle Meniscal Tear

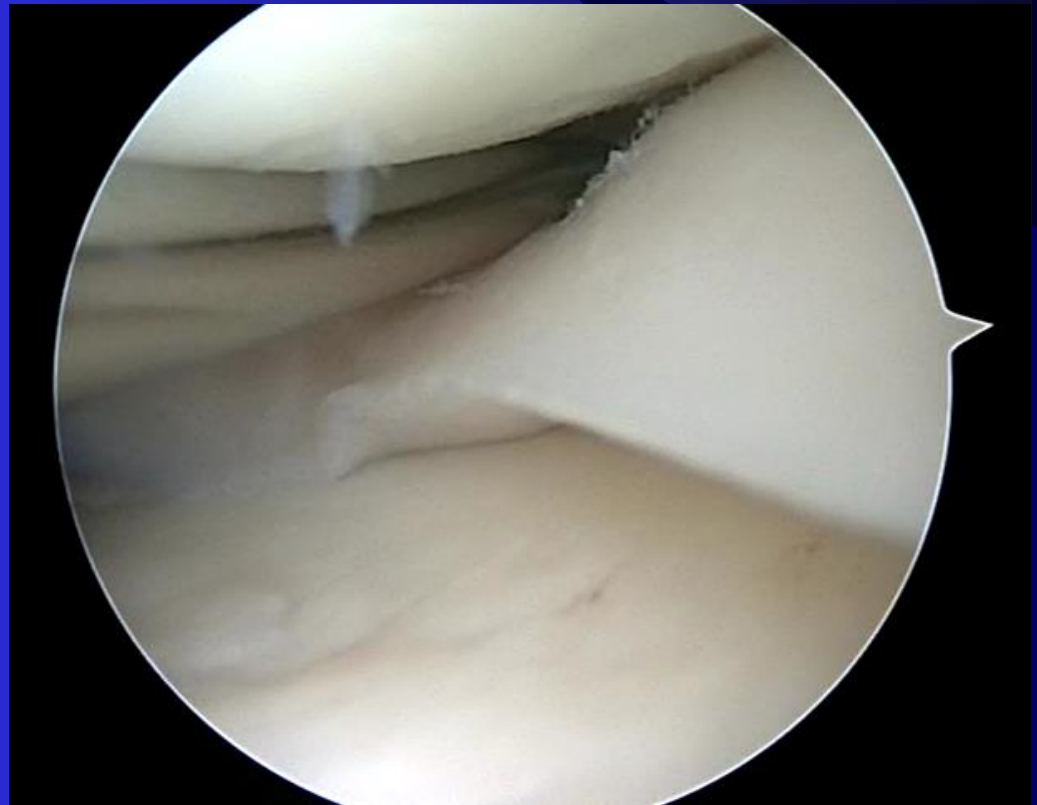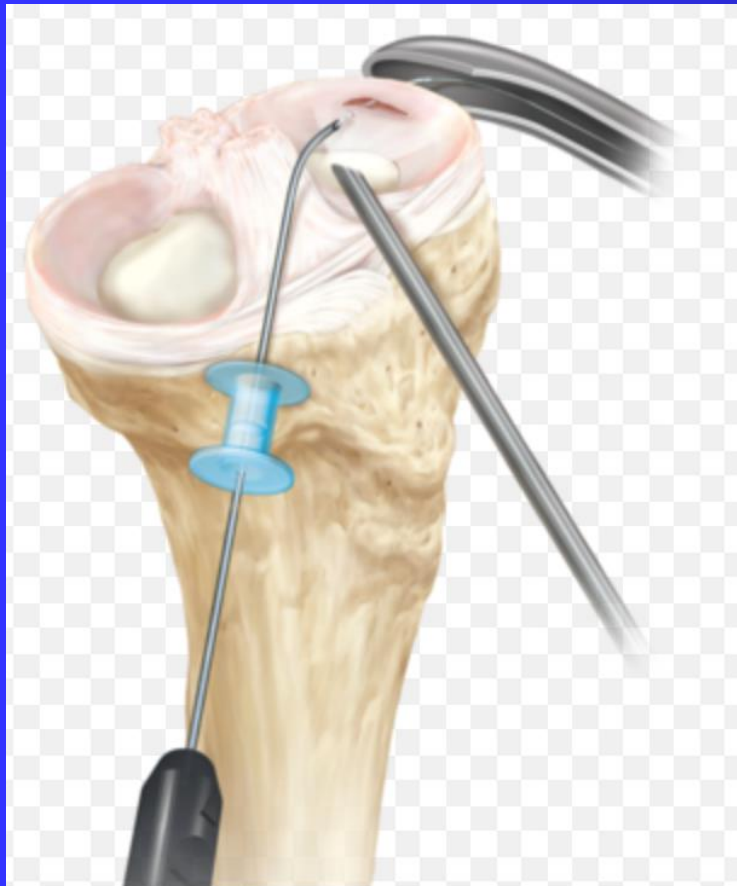Treatment

- Nonoperative????
 - NO role for nonoperative treatment in a locked bucket handle meniscus tear
- Operative
 - Relative sports surgical emergency!
 - Keep patients nonweight bearing until surgery
 - Goal is repair if possible in especially in younger patients.

Treatment

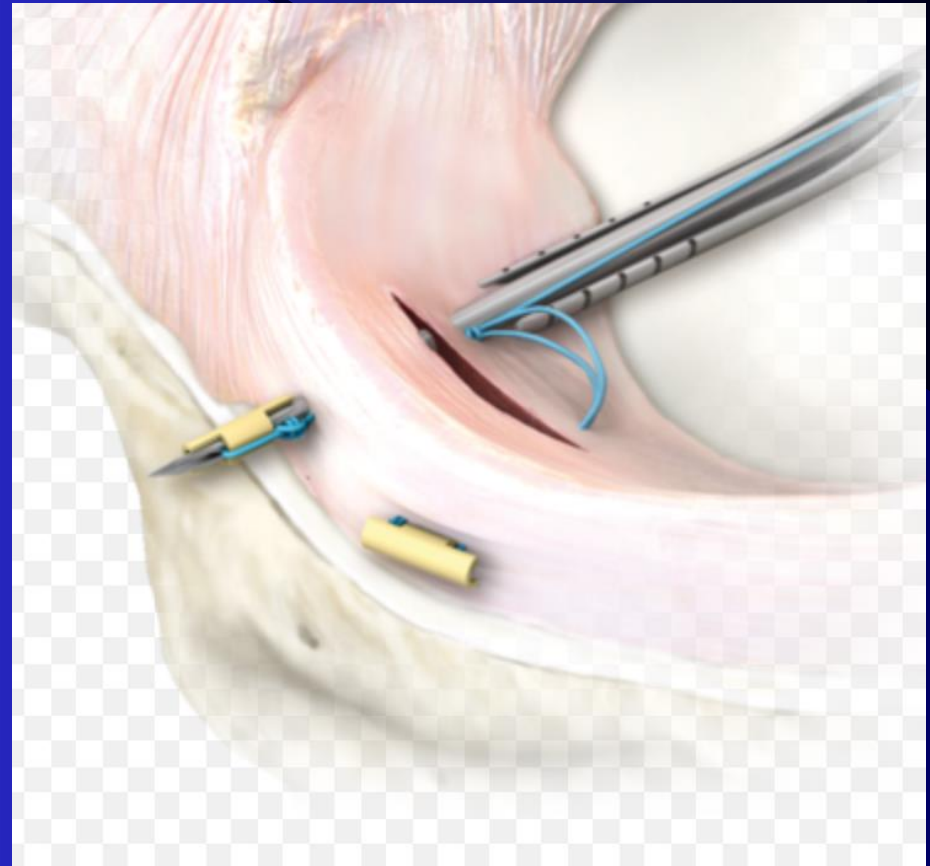


Repair Techniques: Inside-Out



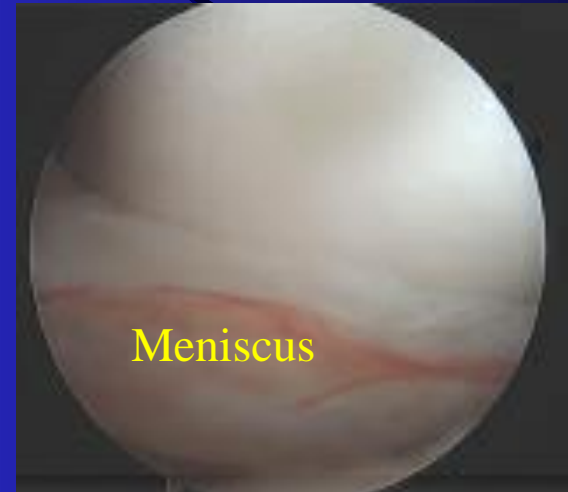
Repair Technique: All Inside

- Single use implant
- Less invasive
- Data shows no difference in terms of healing rates
- Can be difficult to reduce to capsule with true bucket
- \$\$\$\$\$\$

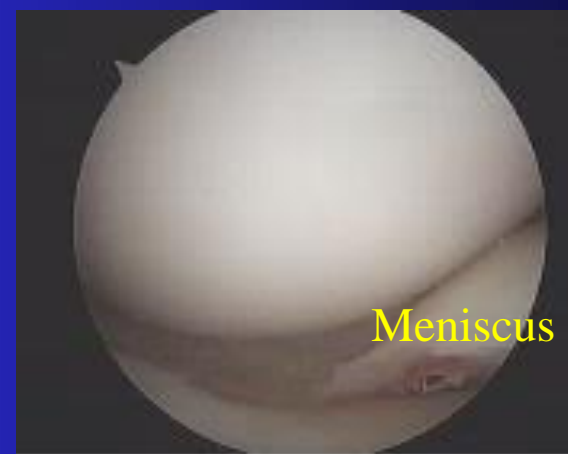

Meniscal Repair

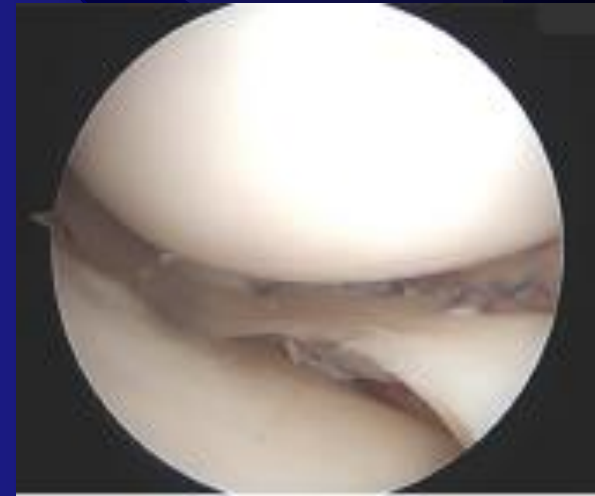
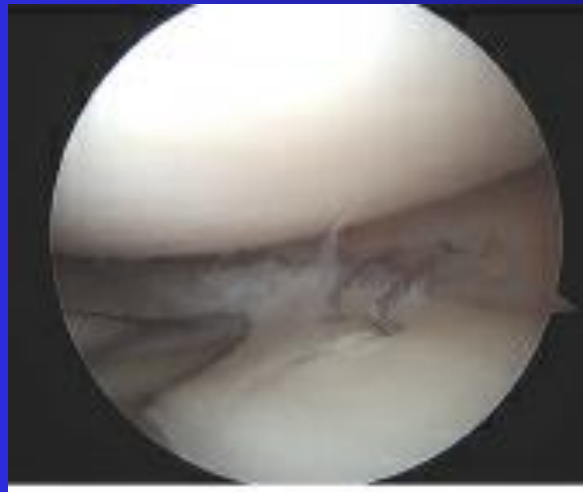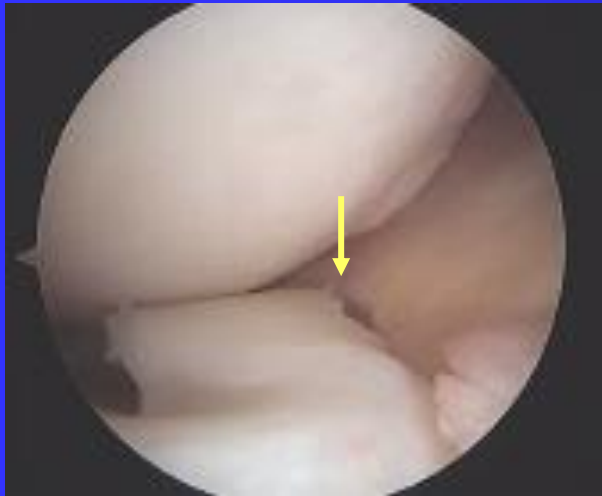Displaced medial meniscus
sitting anterior to the
medial femoral condyle



Post reduction

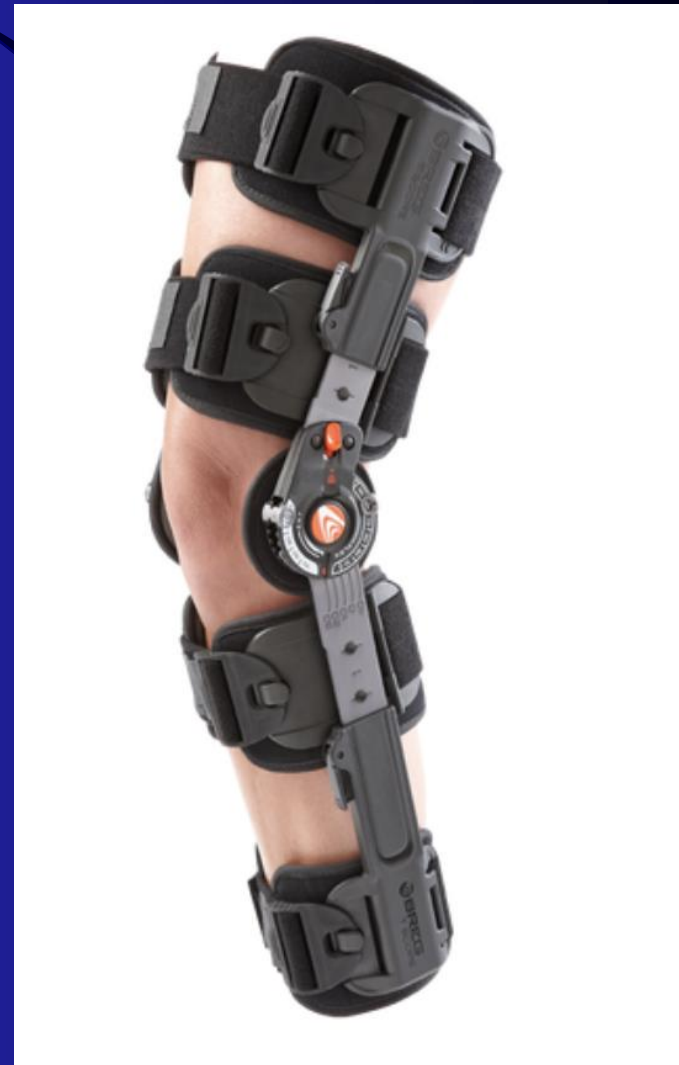

Inside Out Medial Meniscal Repair



Post Operative

- Hinged knee brace
- PWB x 2 weeks
- WBAT brace locked in extension 4-6 weeks
- No routine DVT prophylaxis
- Return to running 12 weeks
- Return to sports 6 months



Outcome

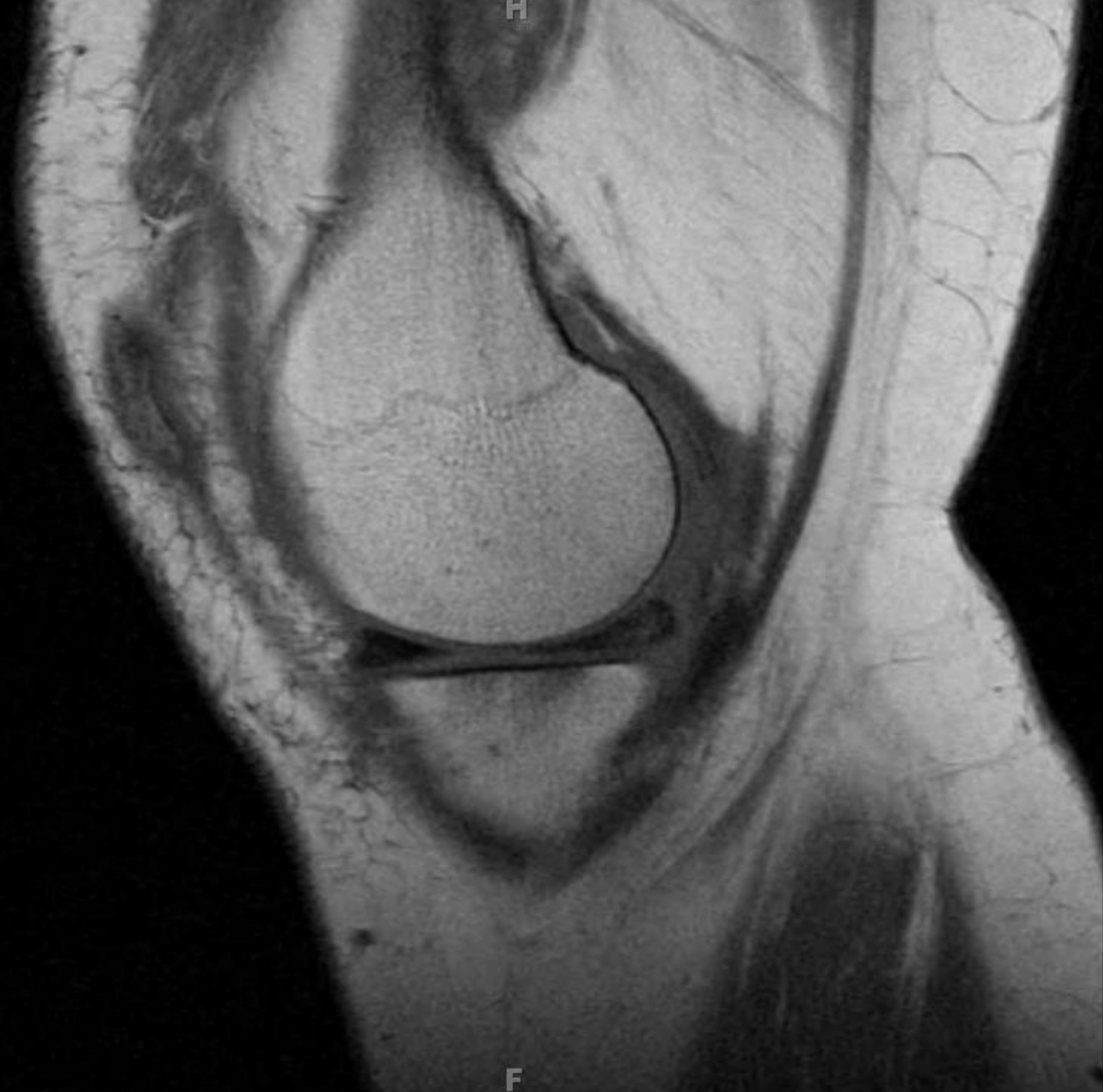- 84% success at a minimum of 5 yr follow up for 2nd generation all inside devices
 - Bogunovic et al. JBJS. 2014
- Slight improvement in failure rate for inside out (10%) vs all inside (16%) in a meta analysis of combined ACL/meniscal repair
 - Westerman et al. AJSM. 2017

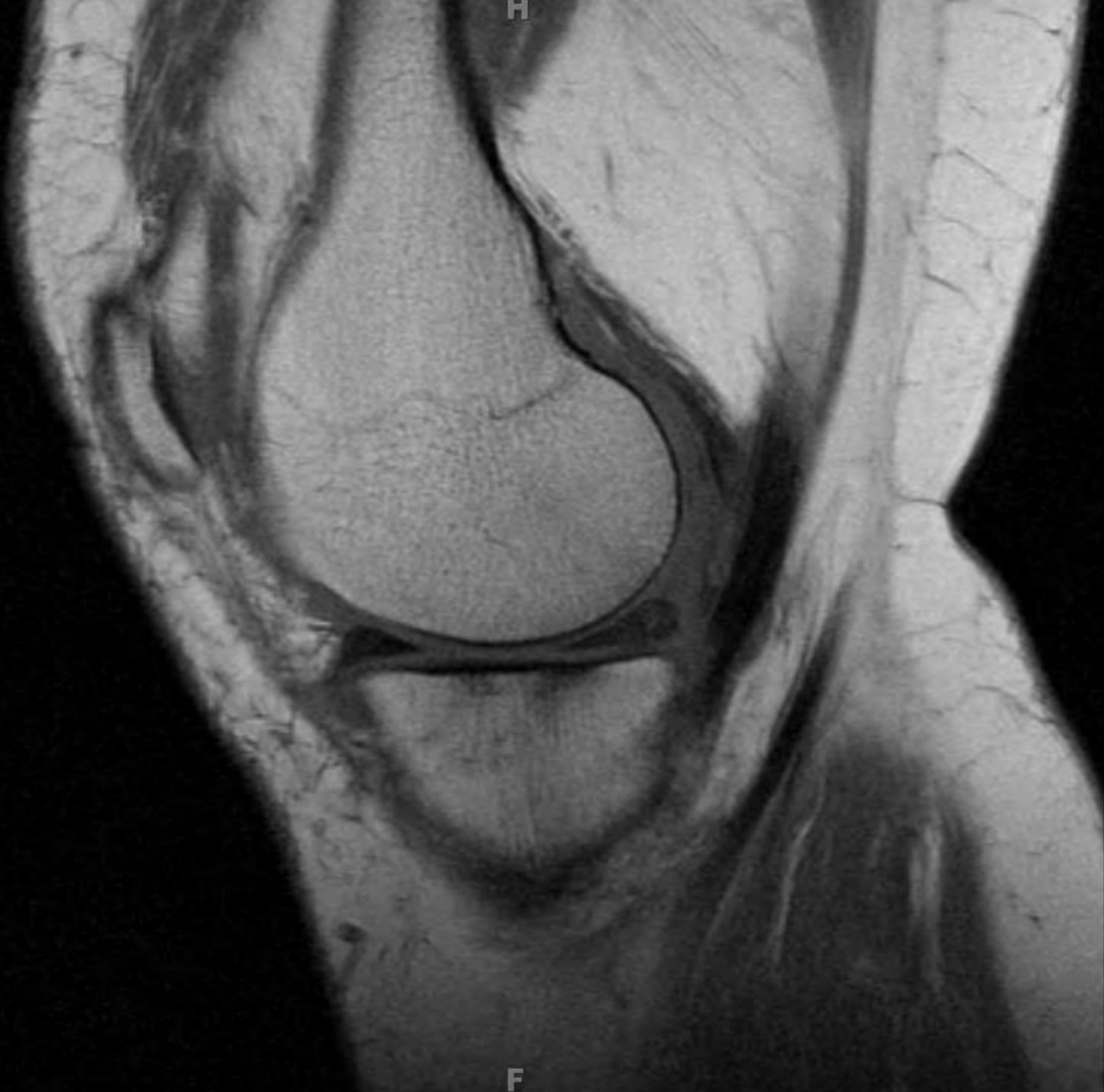Case 4

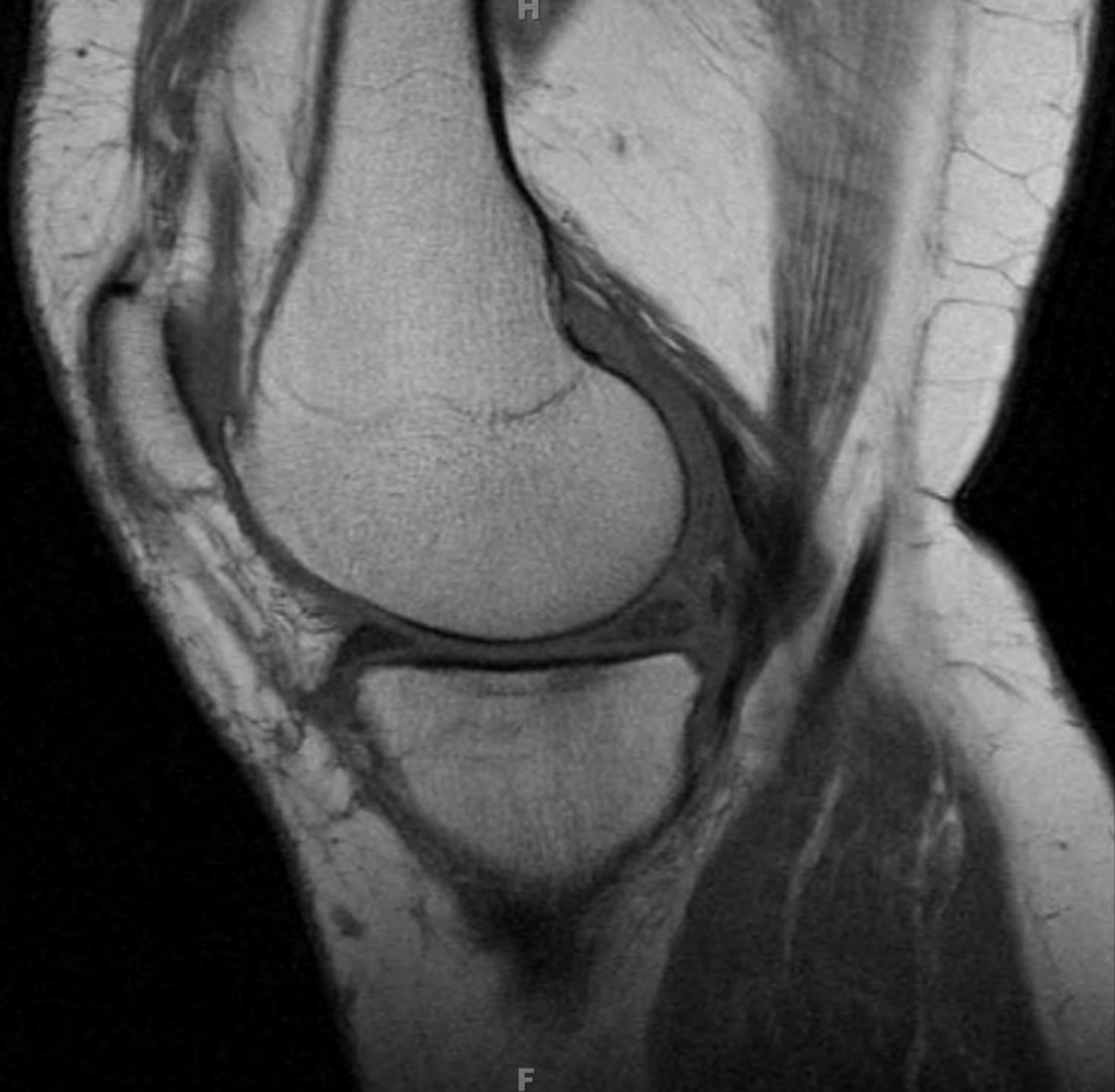- 45 yo female with left knee pain
- Felt a “pop” while running
- Pain and swelling
- Occasional catching and popping
- No previous history of knee injury

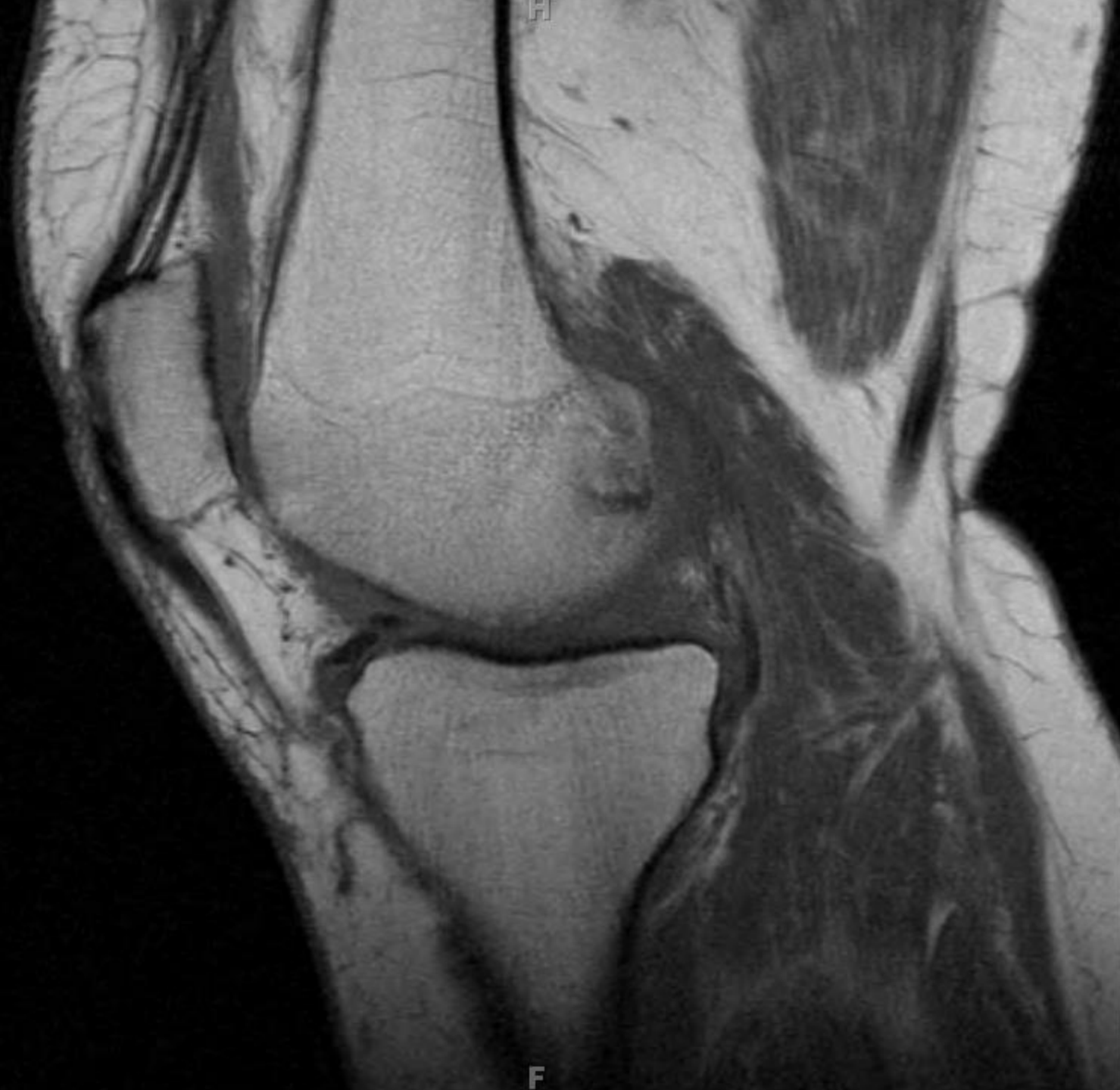Physical Examination

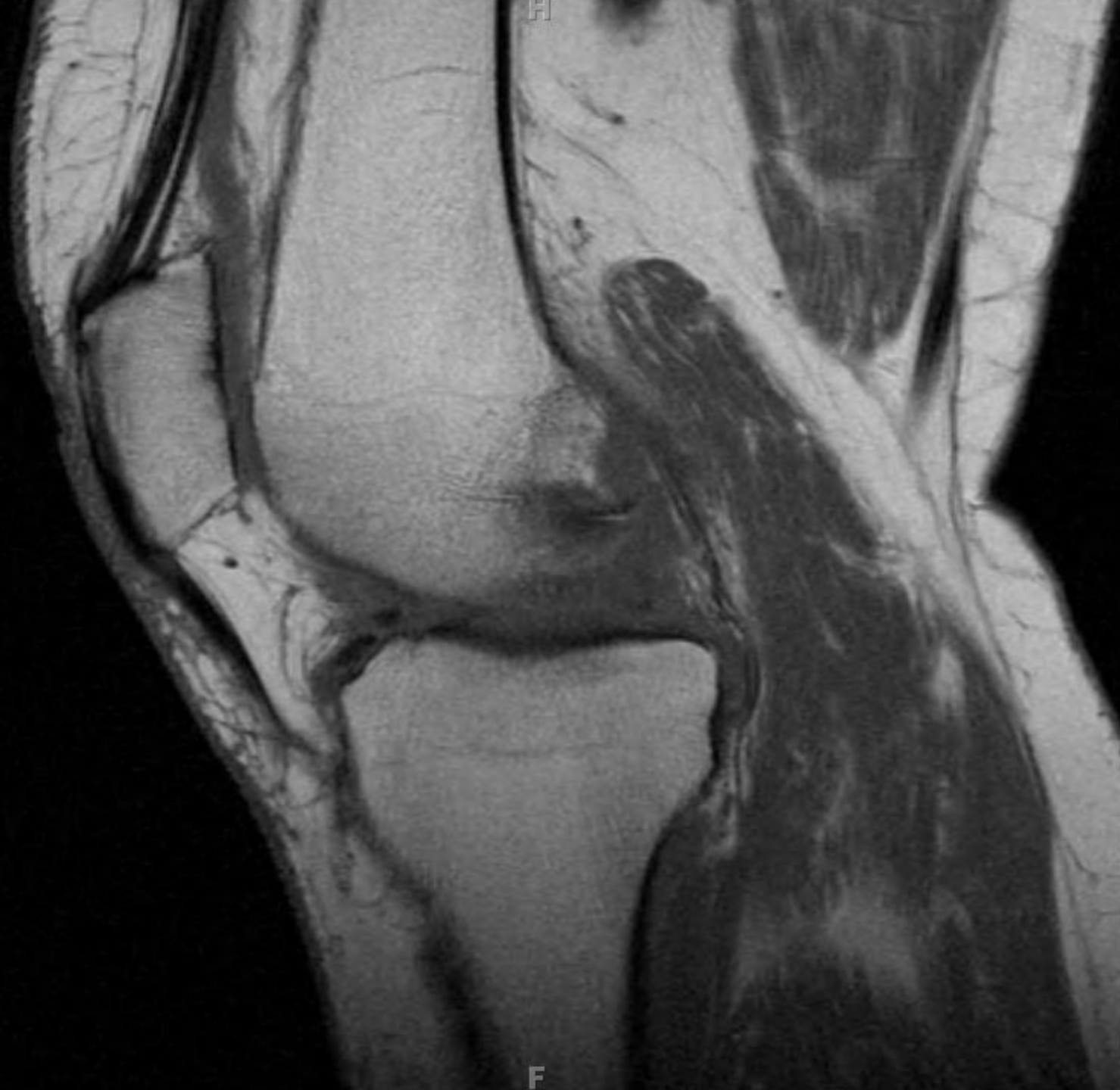- Moderate effusion
- Motion 0-120 degrees
- Stable to varus/valgus
- Negative Lachman, ant/post drawer
- Tenderness over the medial joint line
- Pain with McMurray maneuver
- Normal weight bearing radiographs

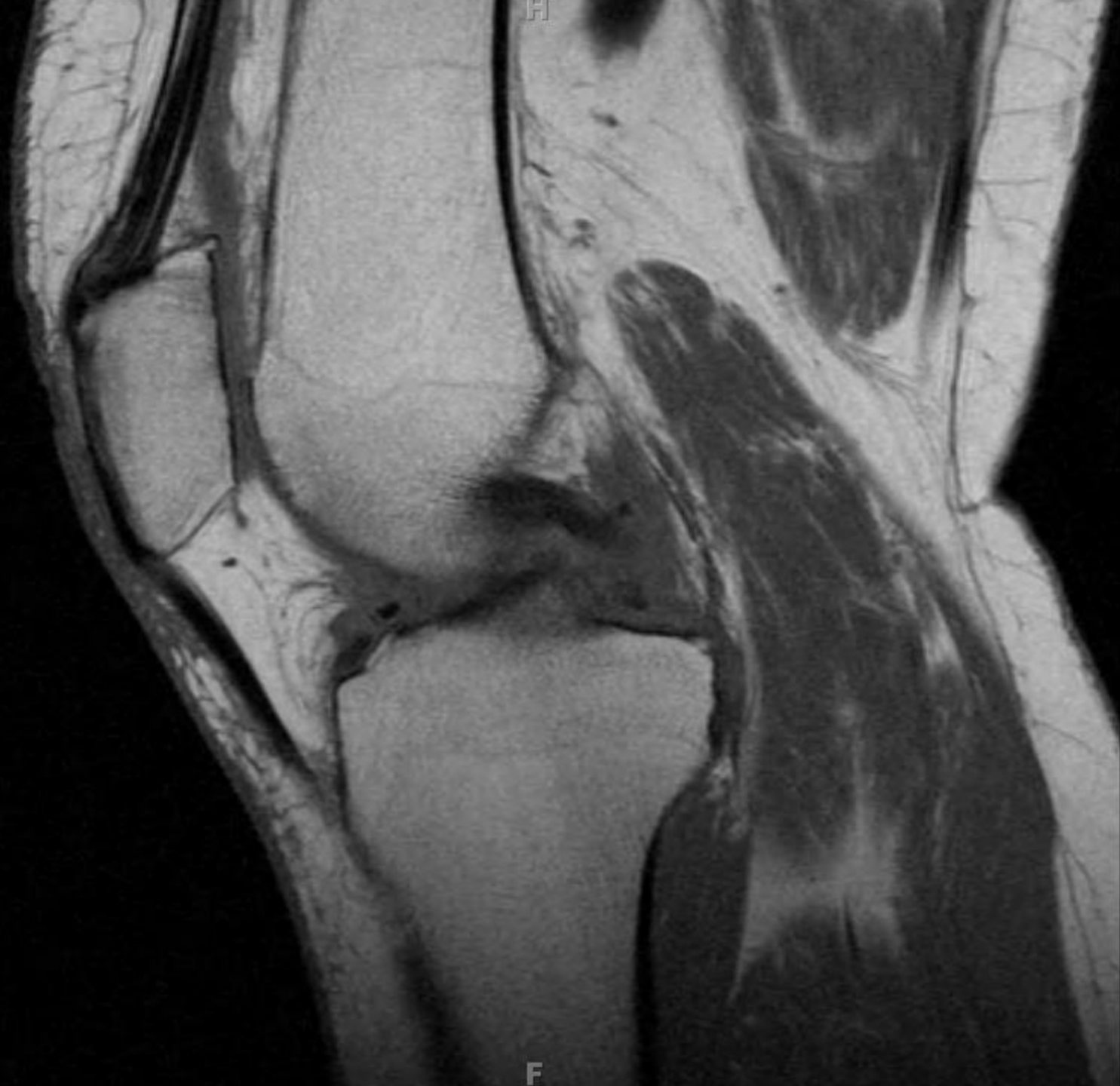


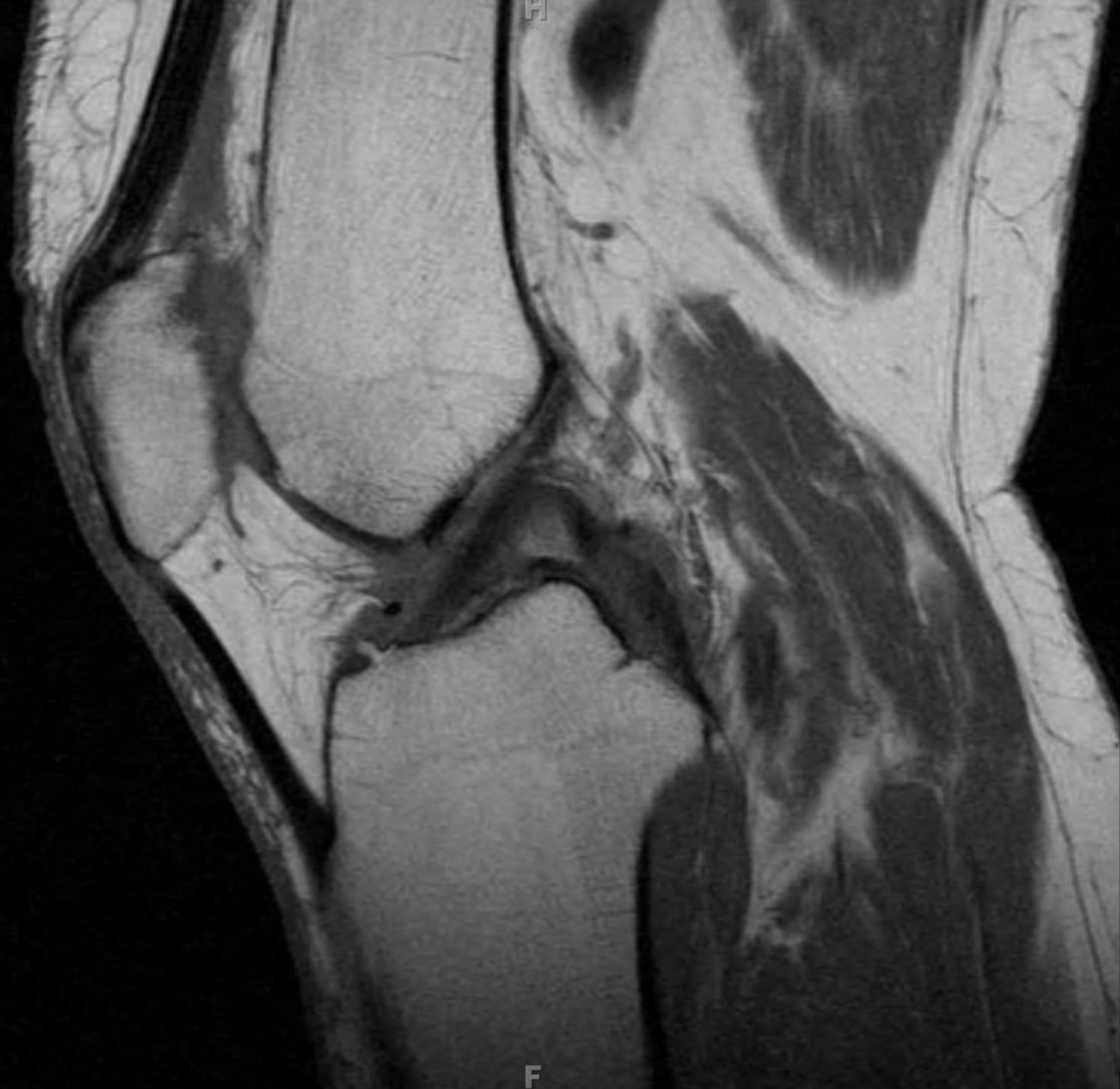




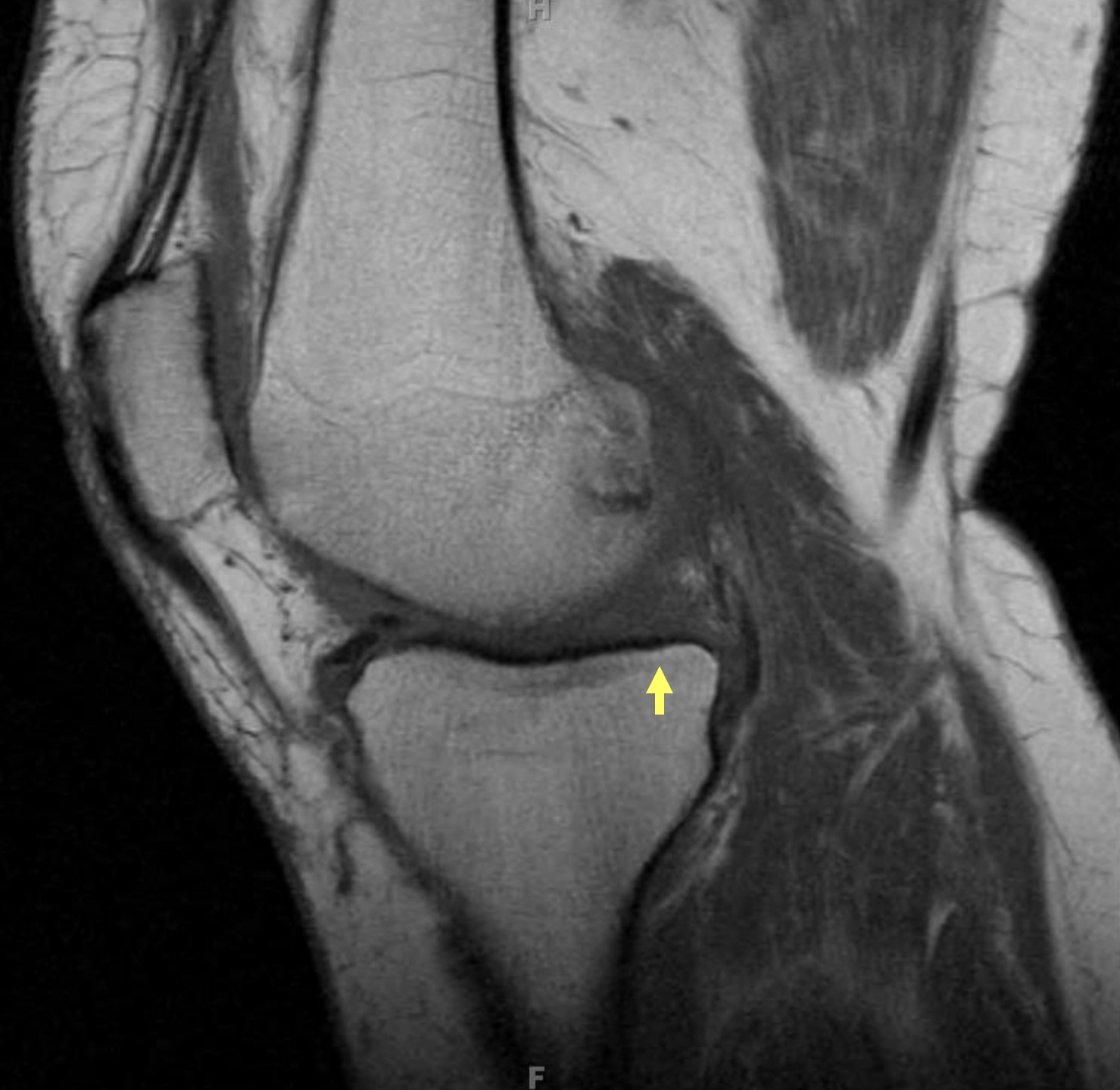





F

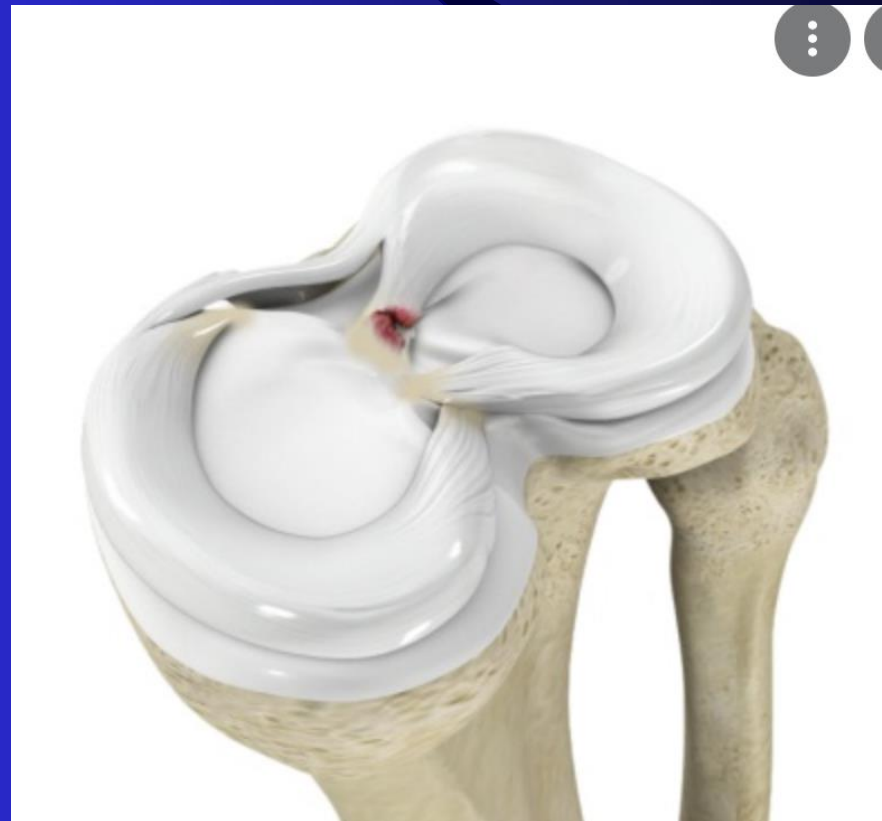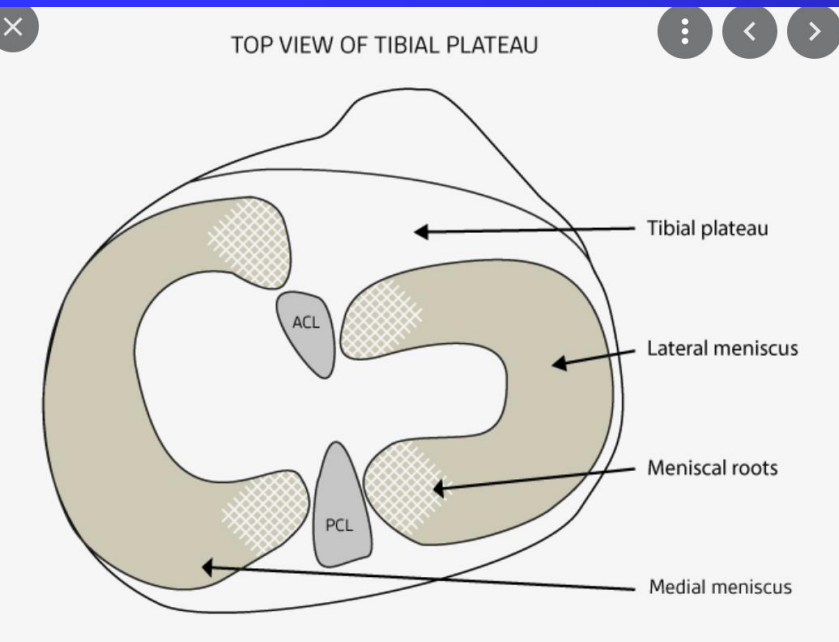


H

F

Diagnosis

Meniscal Root Tear



Meniscal root tears

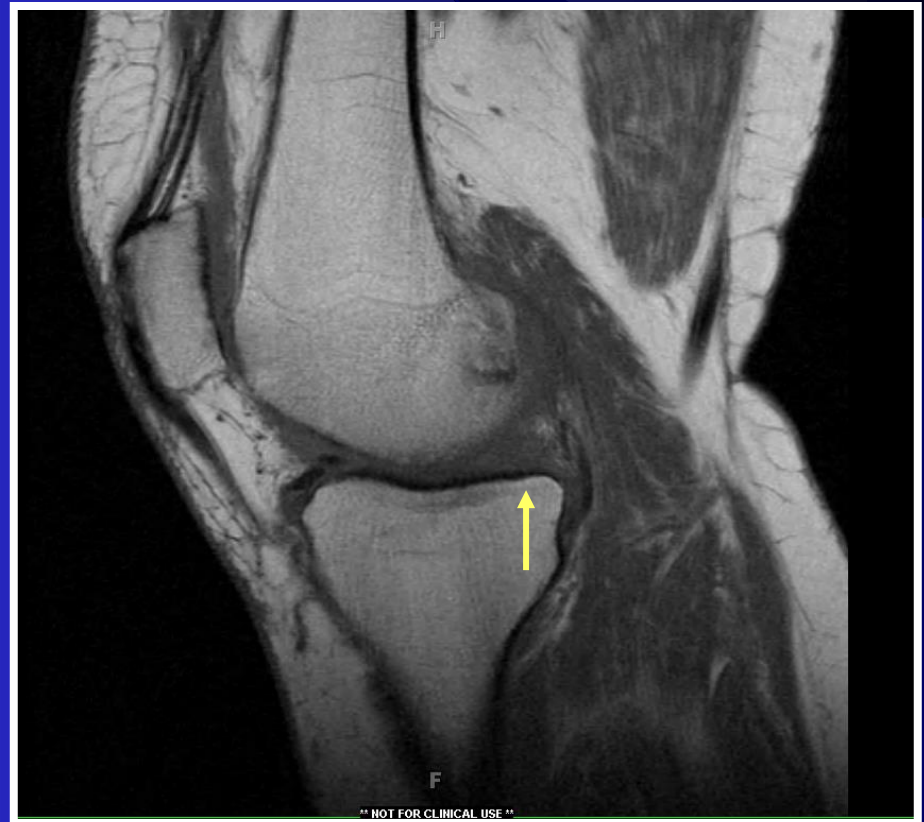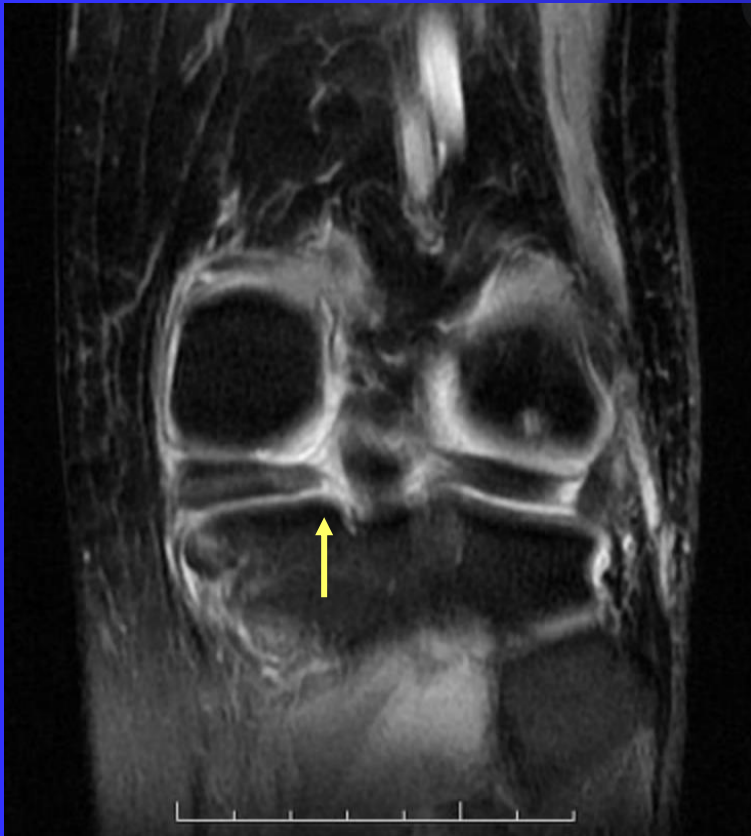
- 7-9% of all meniscal tears
- 2/3rd medial and 1/3rd lateral
- Biomechanically equivalent to a complete meniscectomy (50-70% increase in stress)
- Poor natural history with up to 30% of patients requiring TKA in 3 years.

Presentation

- Posterior pain
- Pain with end range of motion
- Joint line pain
- Positive McMurray
- Less likely to have catching and locking compared to standard meniscal tear

Diagnosis: MRI

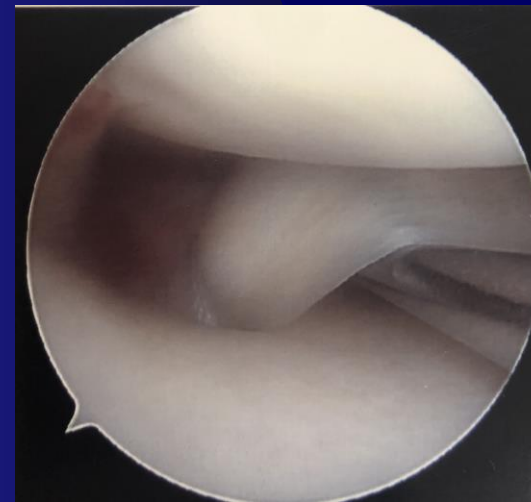
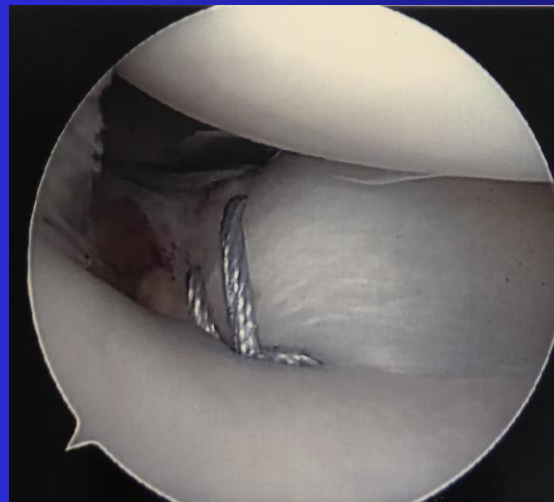
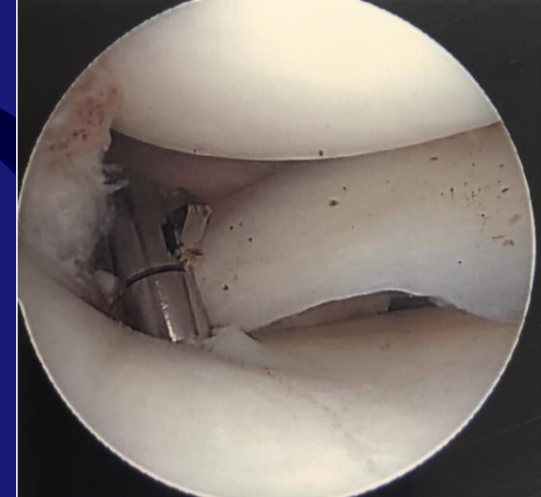
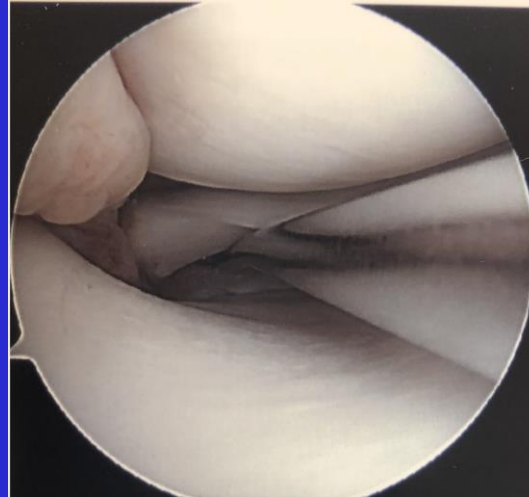
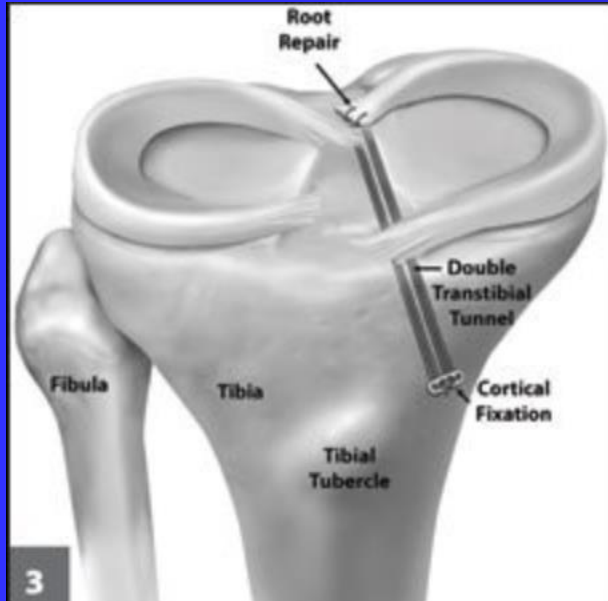
- Sensitivity 82% (medial) and 60% (Lateral)



Treatment

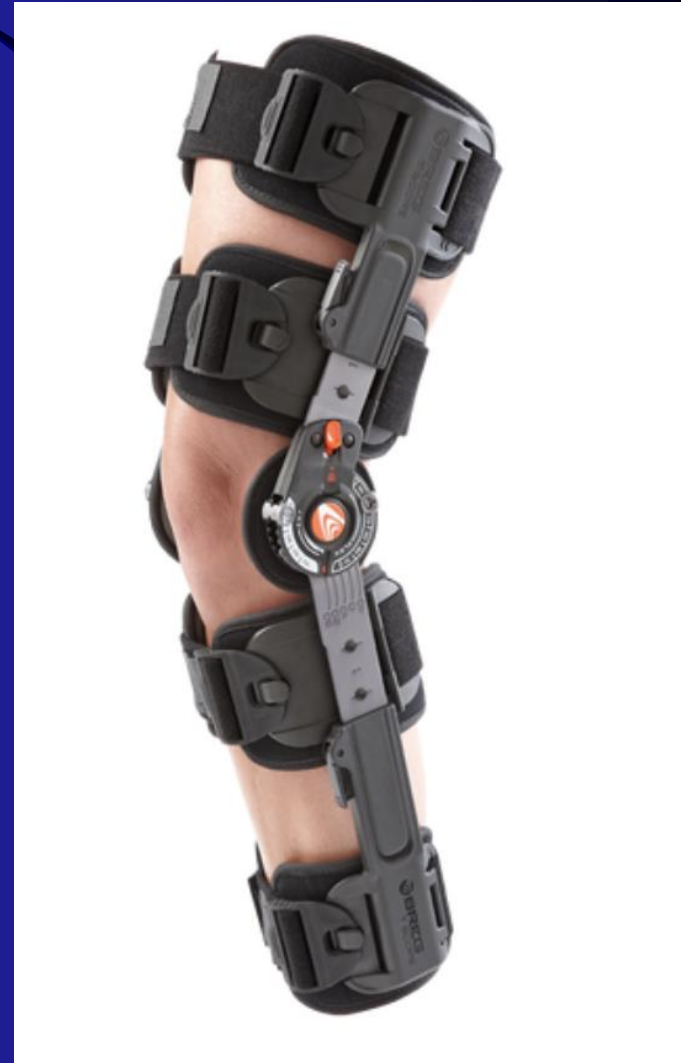- In the setting of normal cartilage and BMI < 35 operative repair is recommended to preserve underlying cartilage
- Nonoperative management and/or debridement can lead to rapid chondral degeneration (3-5 years progress to TKA)

Meniscal Root Repair



Postoperative

- NWB x 6 weeks
- ASA for DVT prophylaxis
- Motion 0-90 X6 weeks
- PWB and full motion 6-10 weeks
- Full return to activity 6 months



Outcome

- Improved function and decreased conversion to total knee (35% vs 0%) in patients treated with repair compared to meniscectomy
- At 6 years on 14% of repairs had progressive OA
- Only 1% converted to TKA at 7 years
- Poorer results in patients with BMI > 35

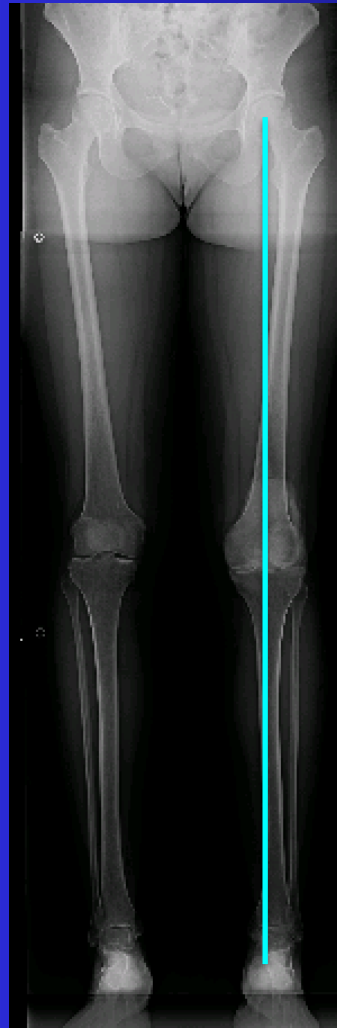Case 5

- 15 yo female with left knee pain
- Injury while playing basketball in 2008, treated with microfx of the medial tibial plateau
- Continued pain and underwent revision microfracture in 2011
- Did well until car accident in 2013
- Persistent pain and underwent diagnostic knee scope in 2014
- Pain despite PT, injections (cortisone and HA), improvement with unloader brace

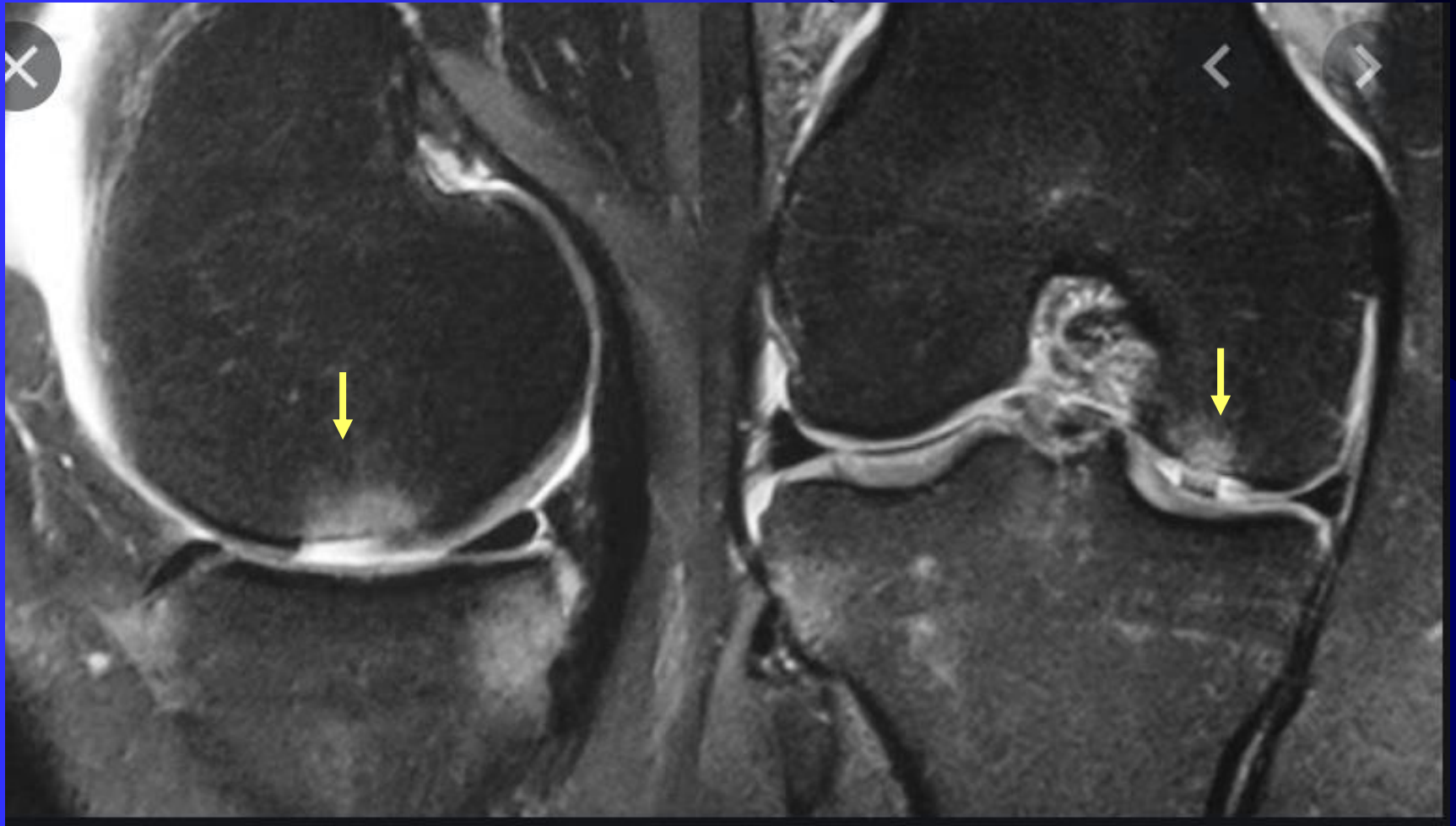
Physical Exam

- Mild swelling
- Motion from 0-140 degrees
- Stable on ligamentous exam
- Tenderness over the medial joint line
- No tenderness laterally
- Normal standing and alignment radiographs

Standing Alignment Films

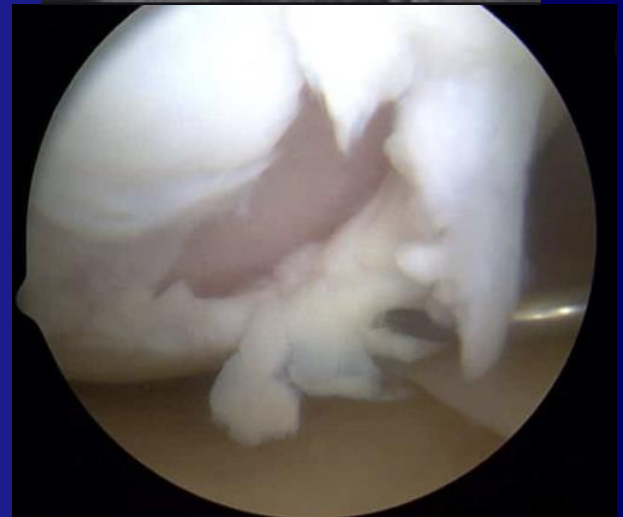
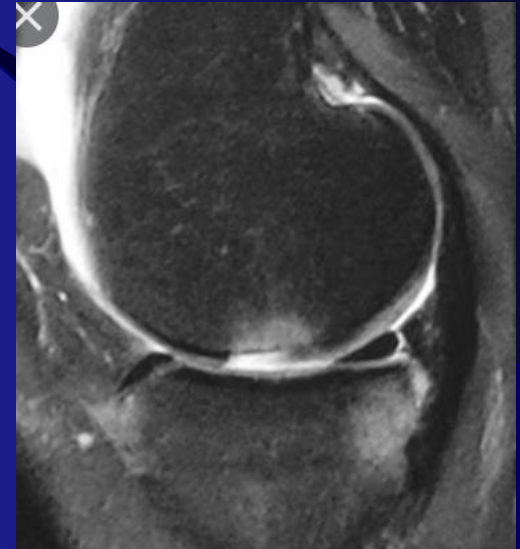

MRI



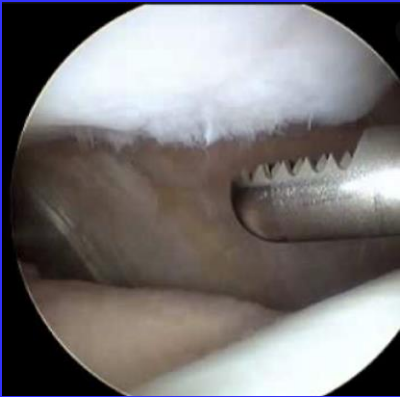Cartilage Defects

- Traumatic vs Insidious
- Partial vs Full Thickness
- With and without subchondral edema

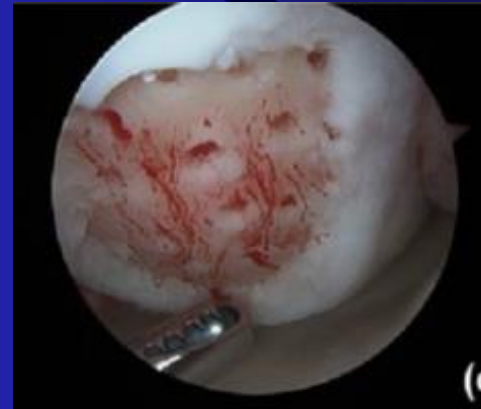

Treatment Options

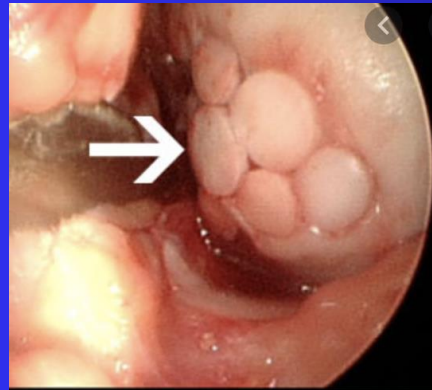
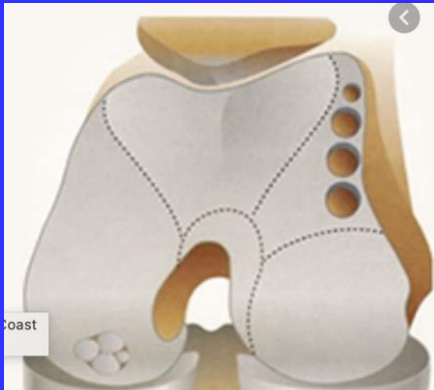Chondroplasty



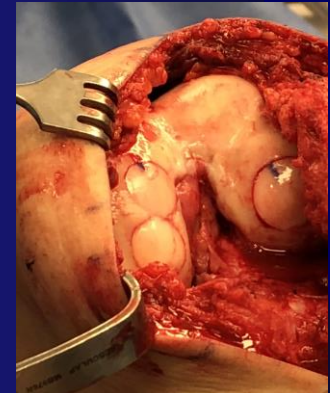Microfracture



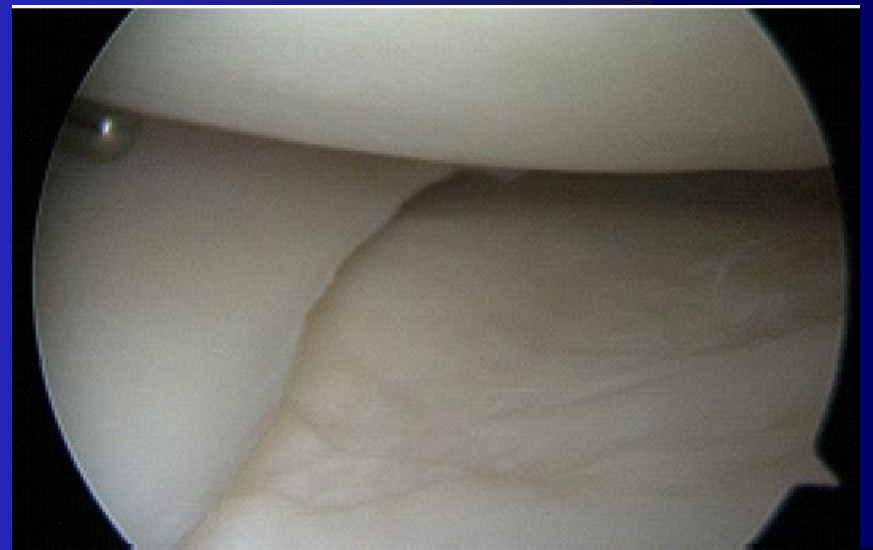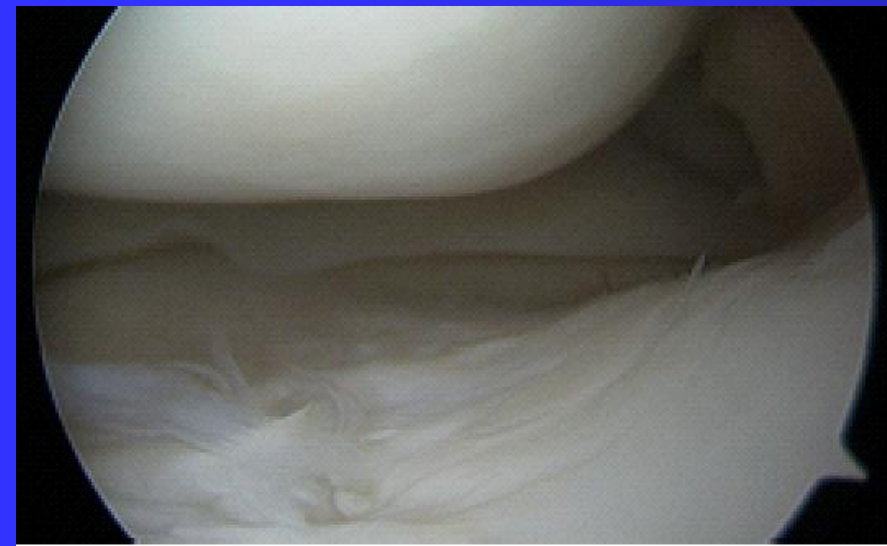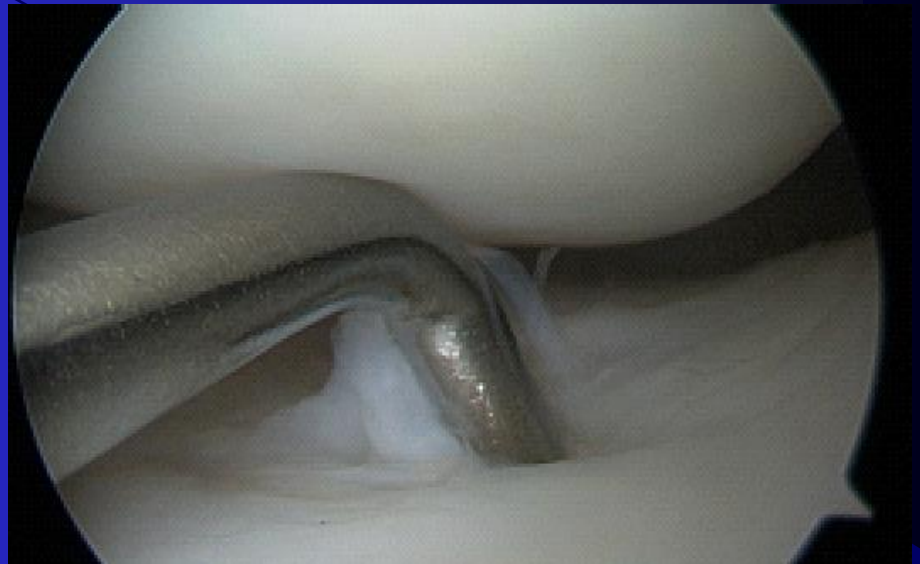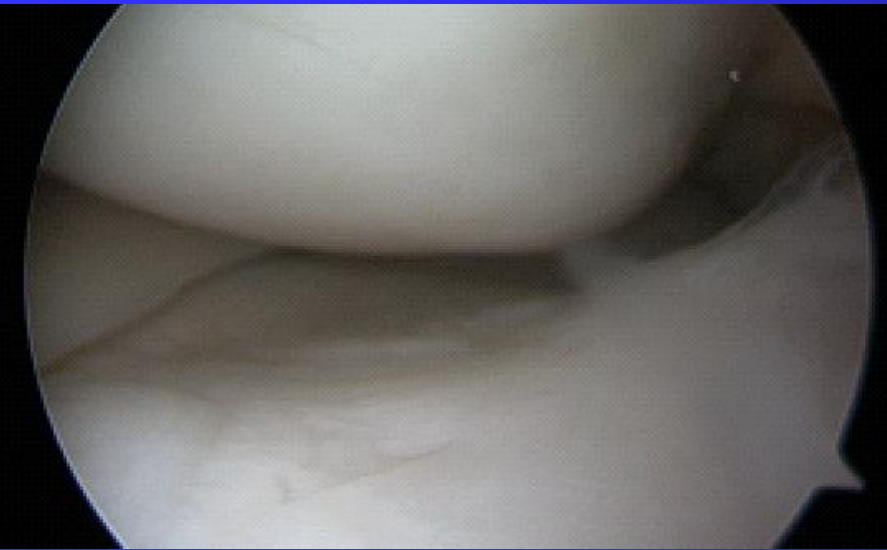Osteochondral Autograft



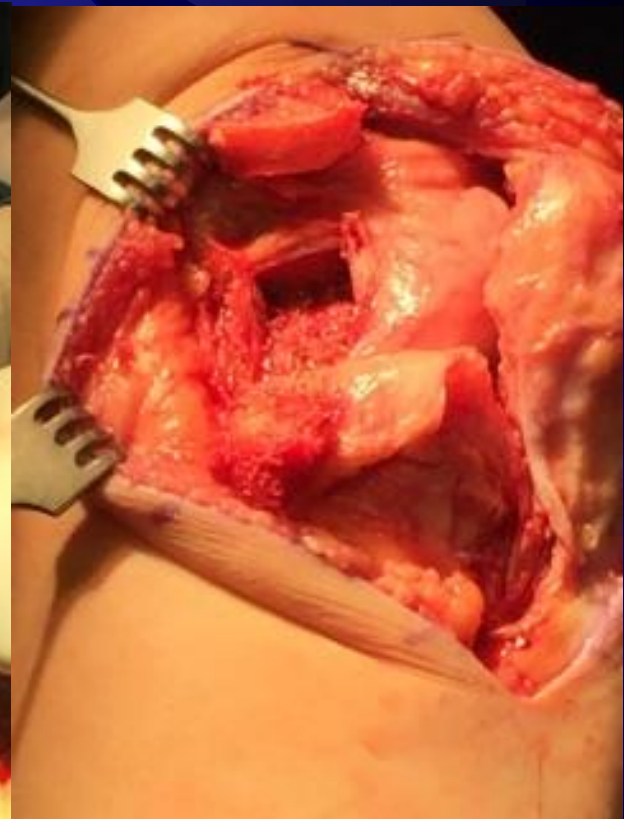
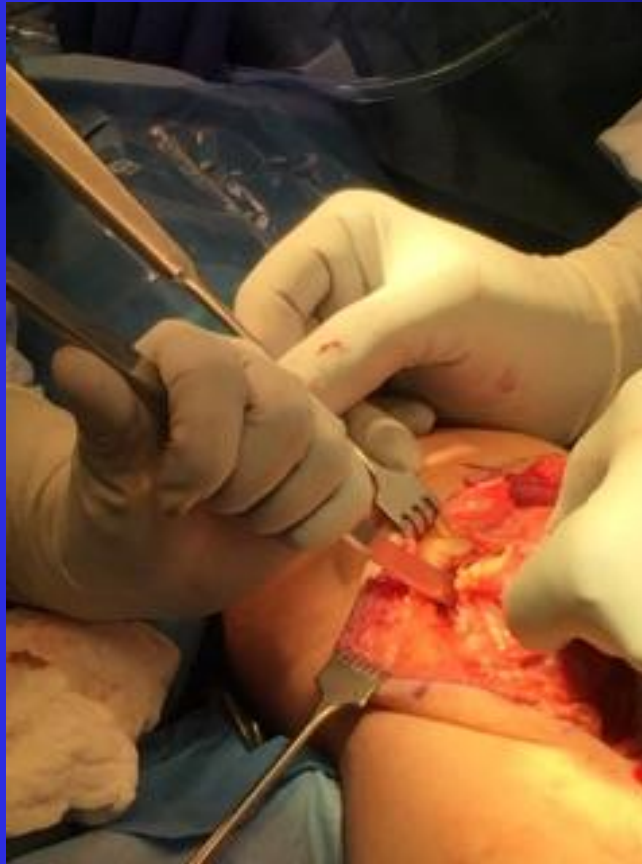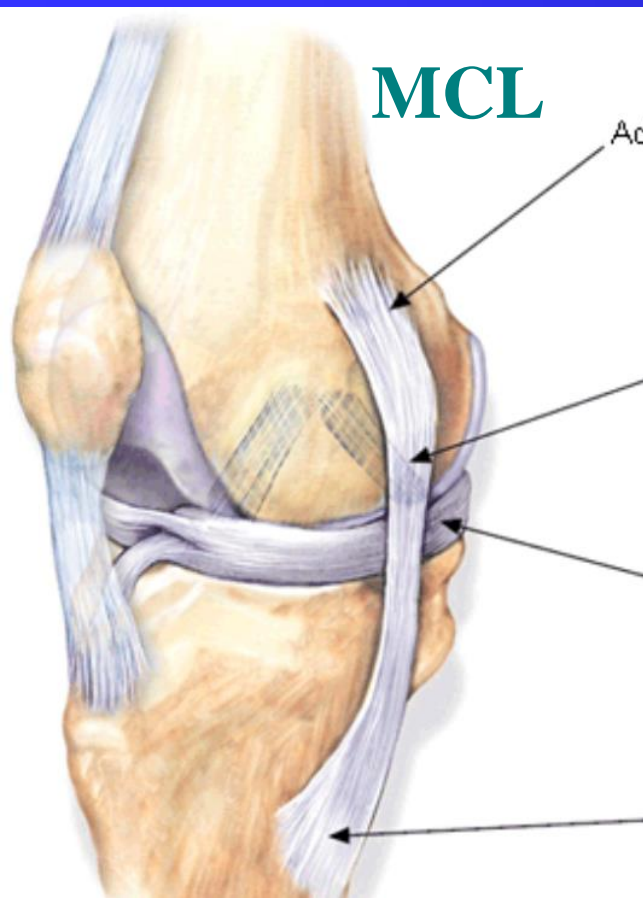
Osteochondral Allograft



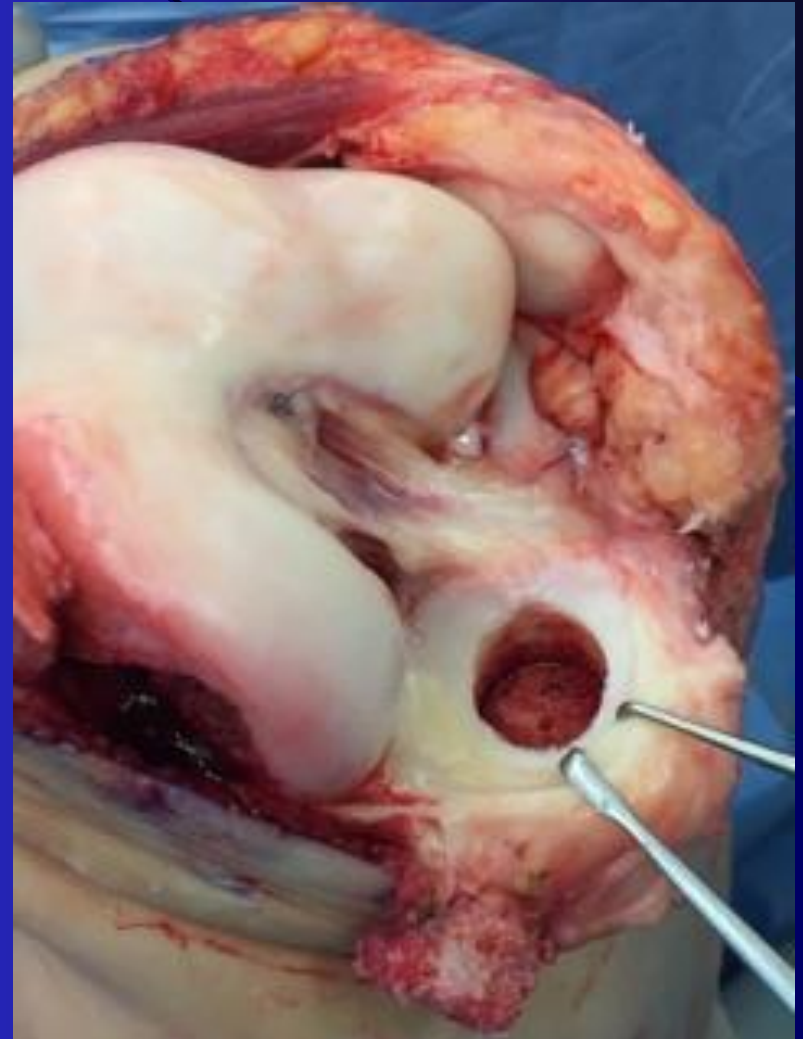
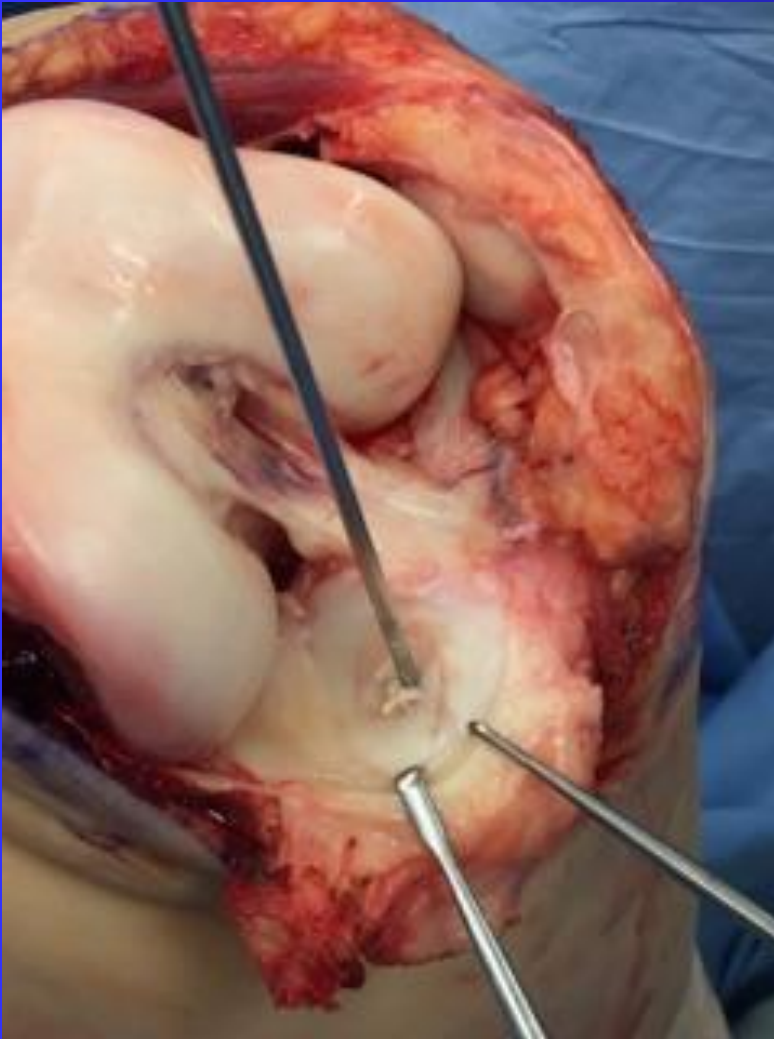
Back to our Patient: Arthroscopy



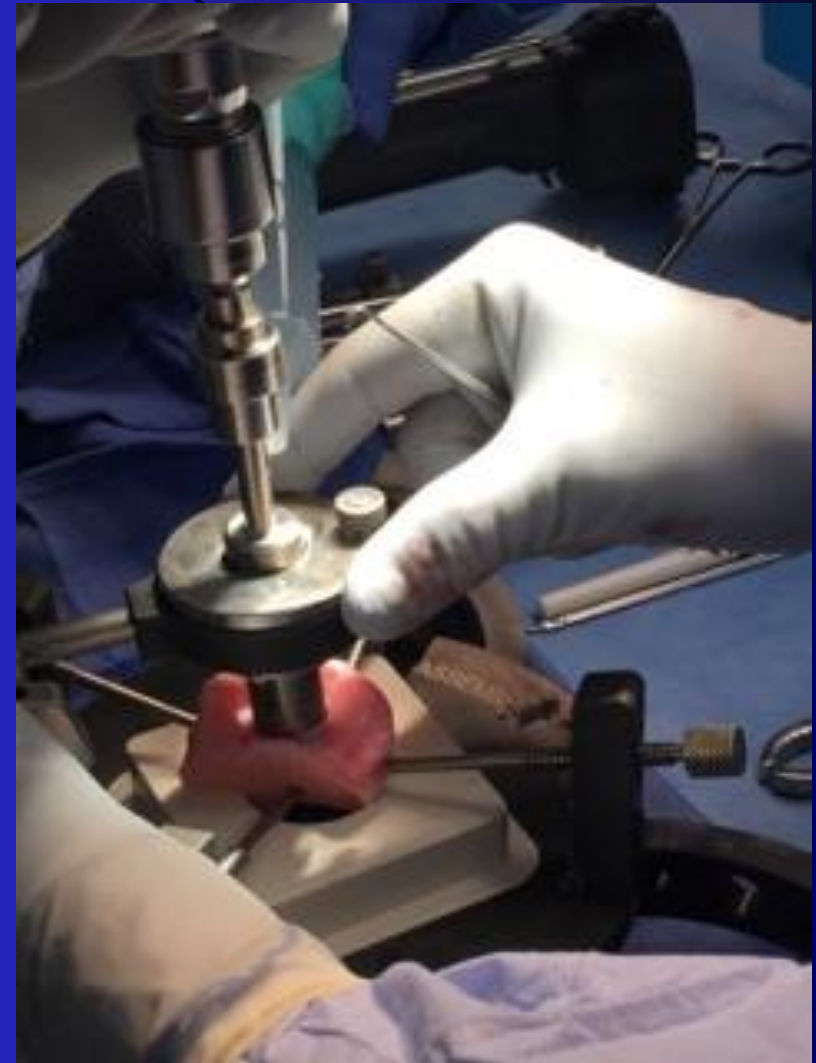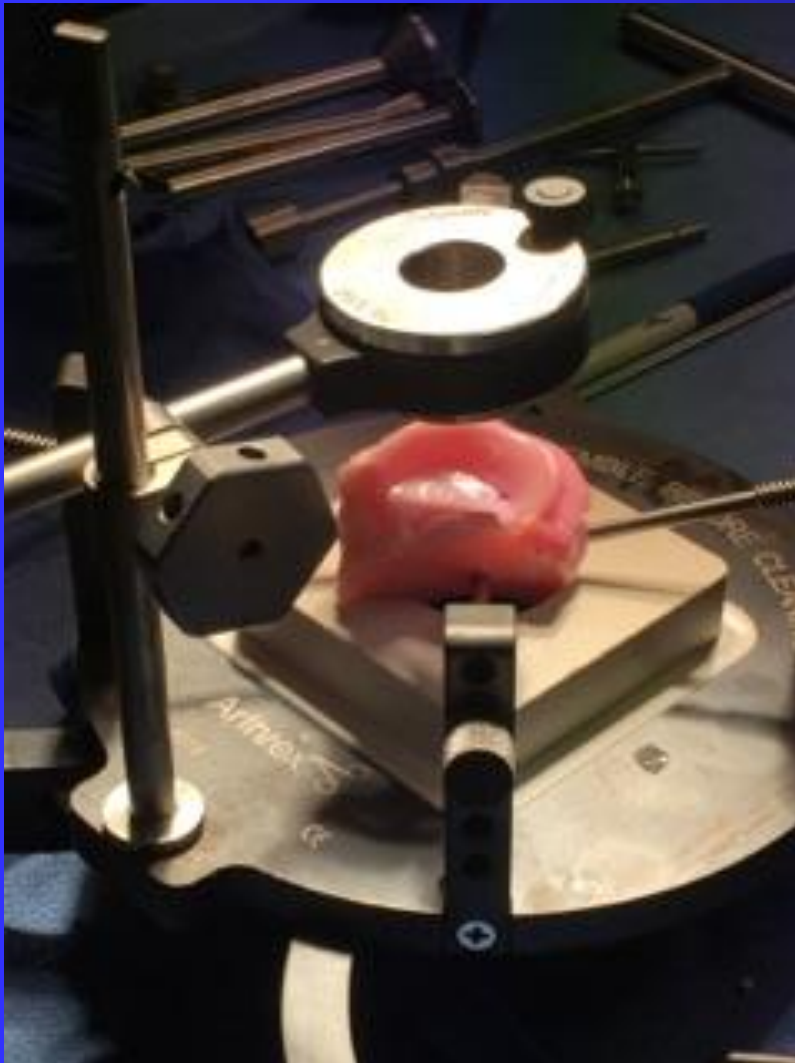
Exposure



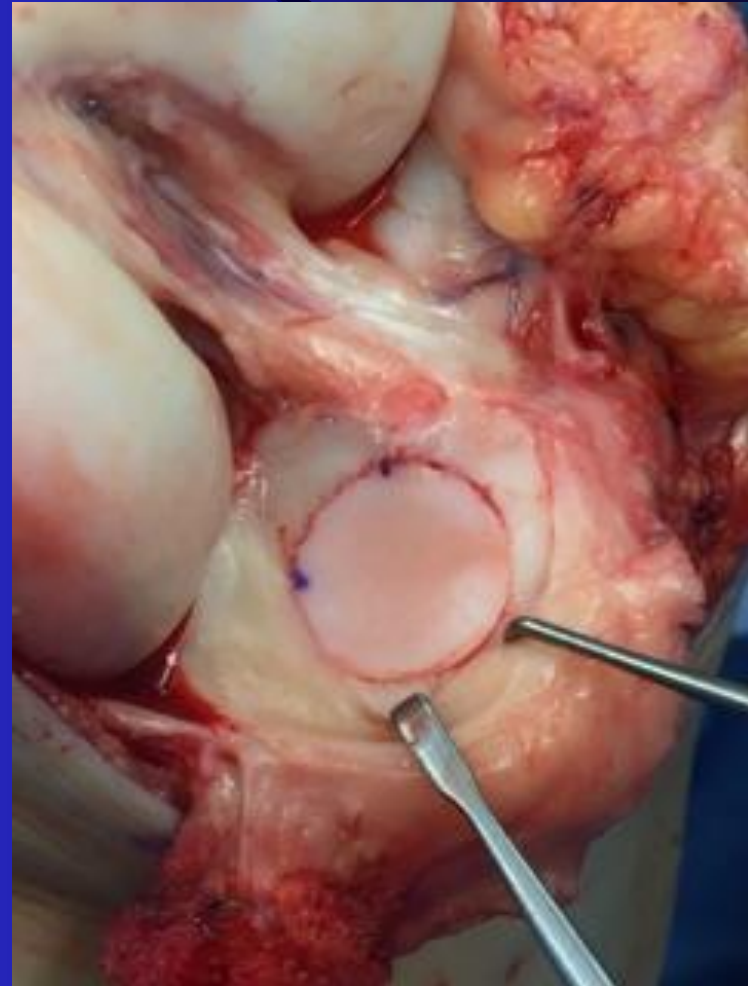
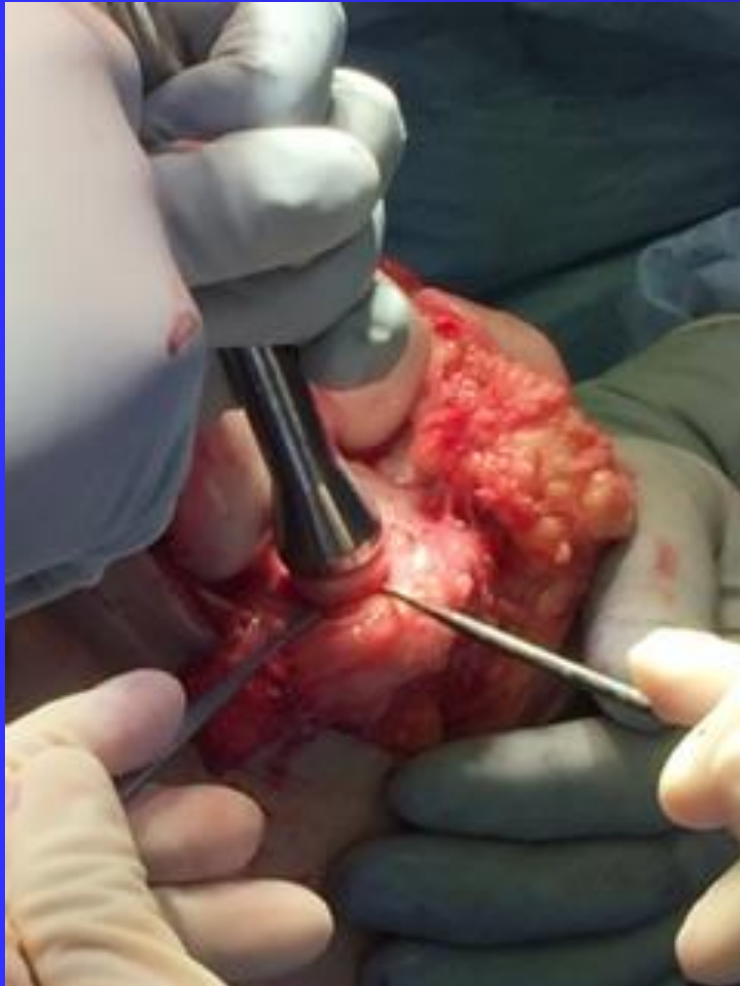Defect Prep



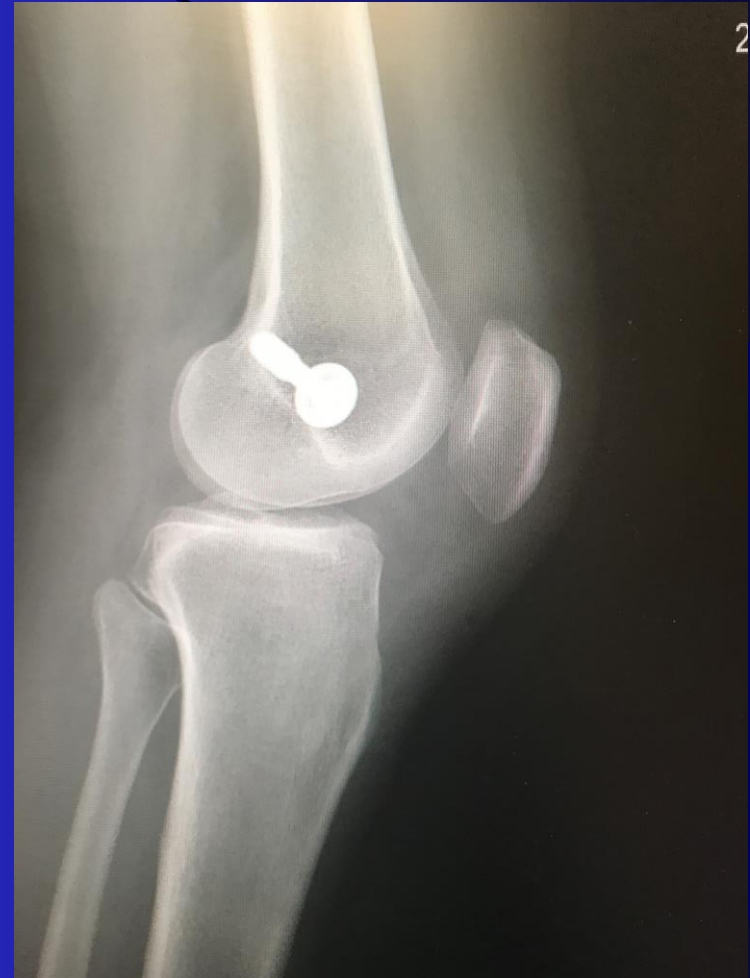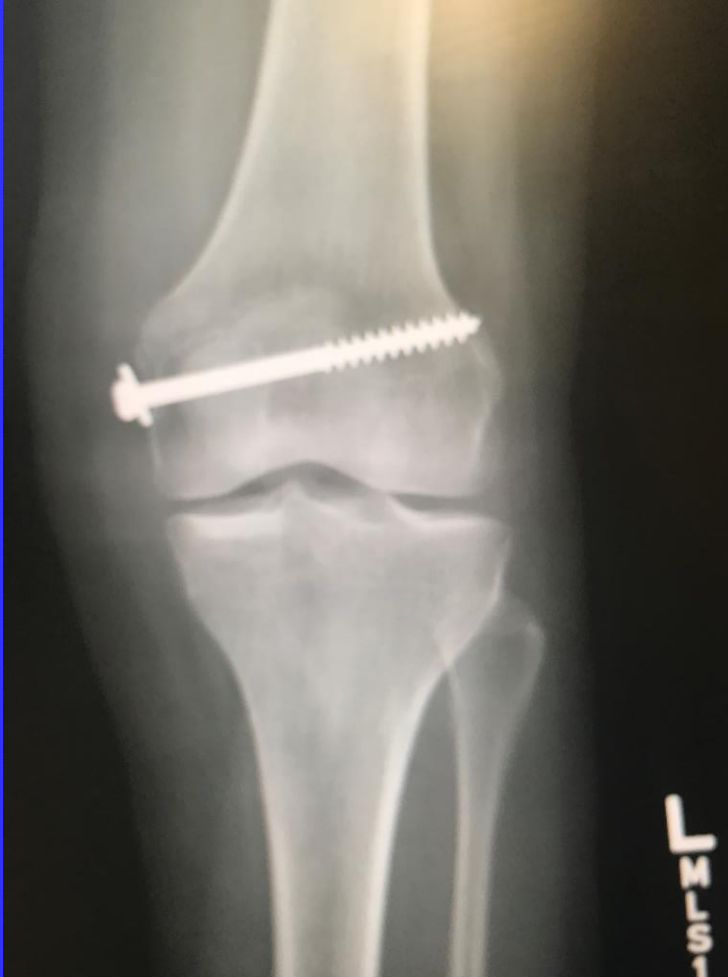Donor Prep



Graft Placement




Post Radiographs



Post Operative Plan

- NWB x 6 weeks
- CPM 6-8 hrs a day x 6 weeks
- ASA 325 BID
- Return to impact 9-10 months
- Continue to experience improvement for up to 1 year



Case 6

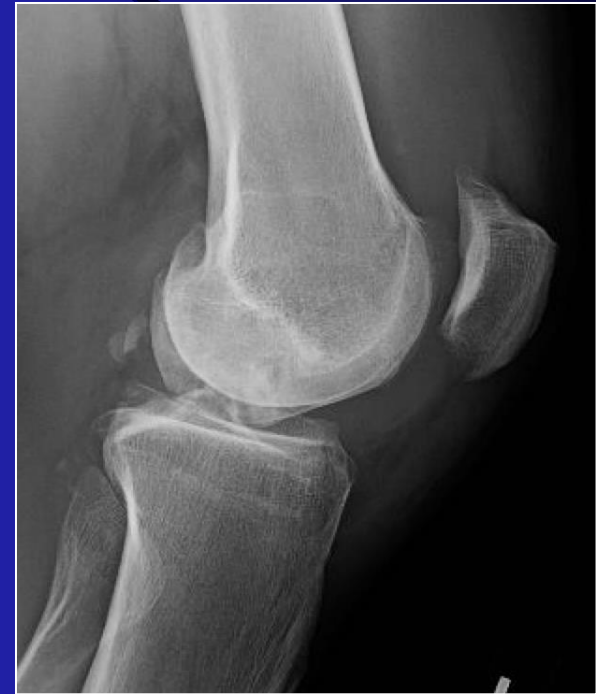
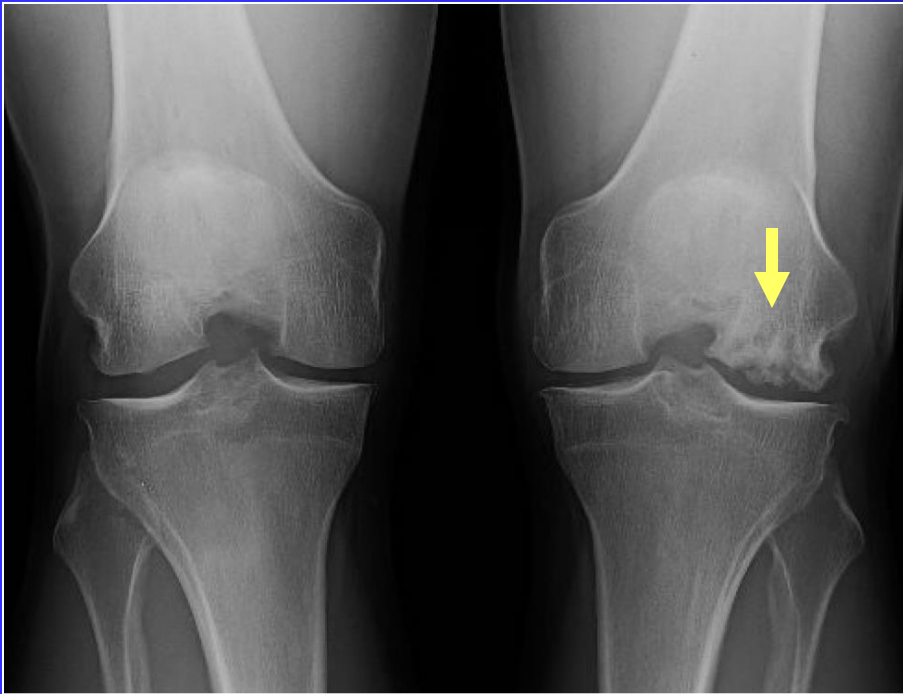
- 25 yo male football player with left knee pain
- History of previous
 - Arthroscopic debridement
 - Microfracture
- Now with persistent pain & swelling
- Locking



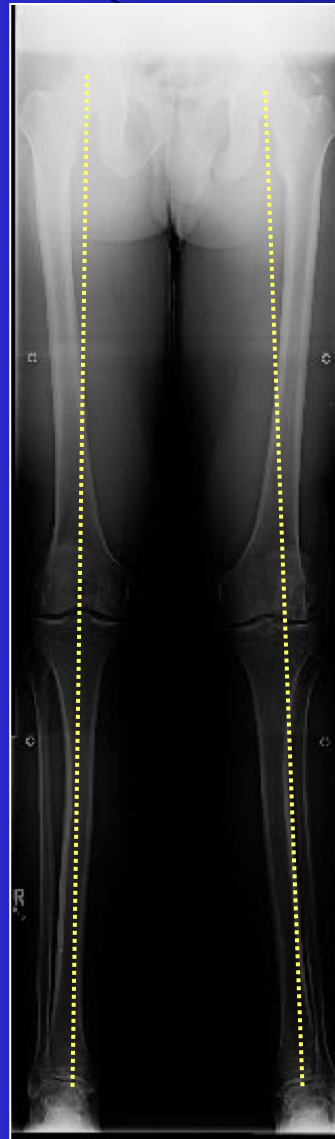
Physical Examination

- Knee effusion
- Motion 0-130 degrees
- Genu valgum on standing exam
- Tenderness over the lateral femoral condyle and lateral joint line
- Stable on ligamentous exam

Xrays

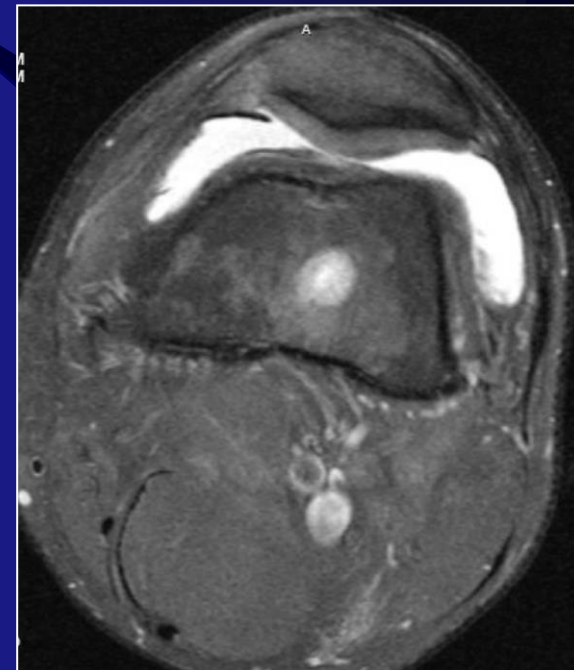
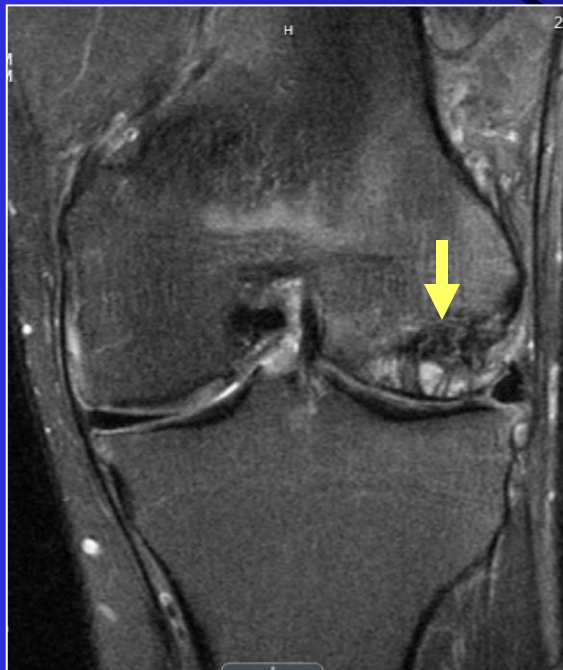
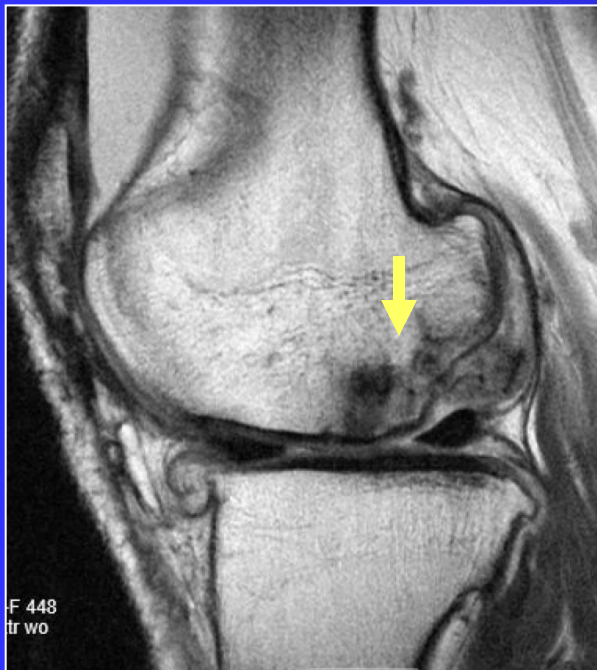


J.M. – Radiographic Alignment

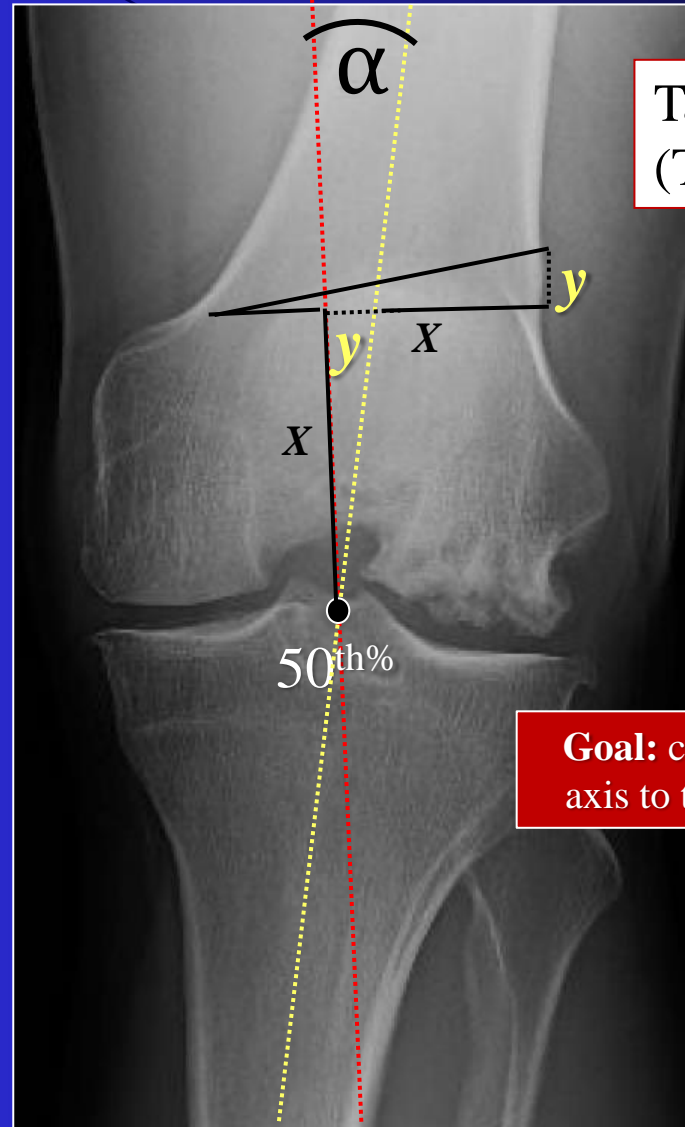
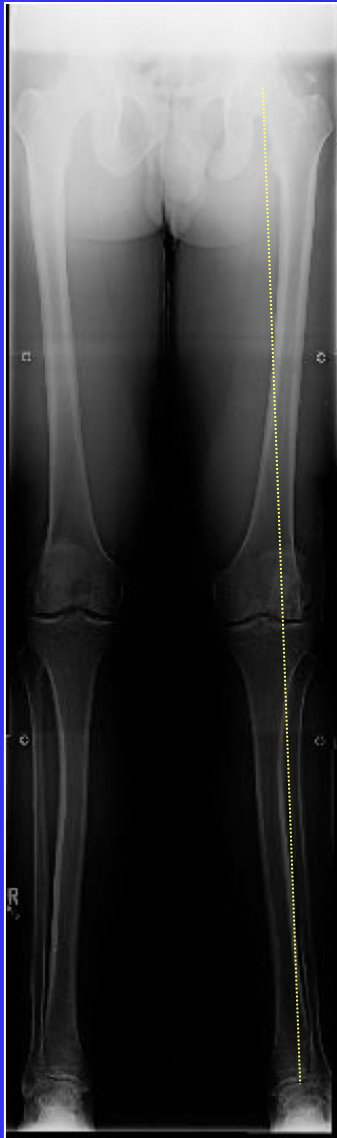

Mechanical axis

J.M. – MRI



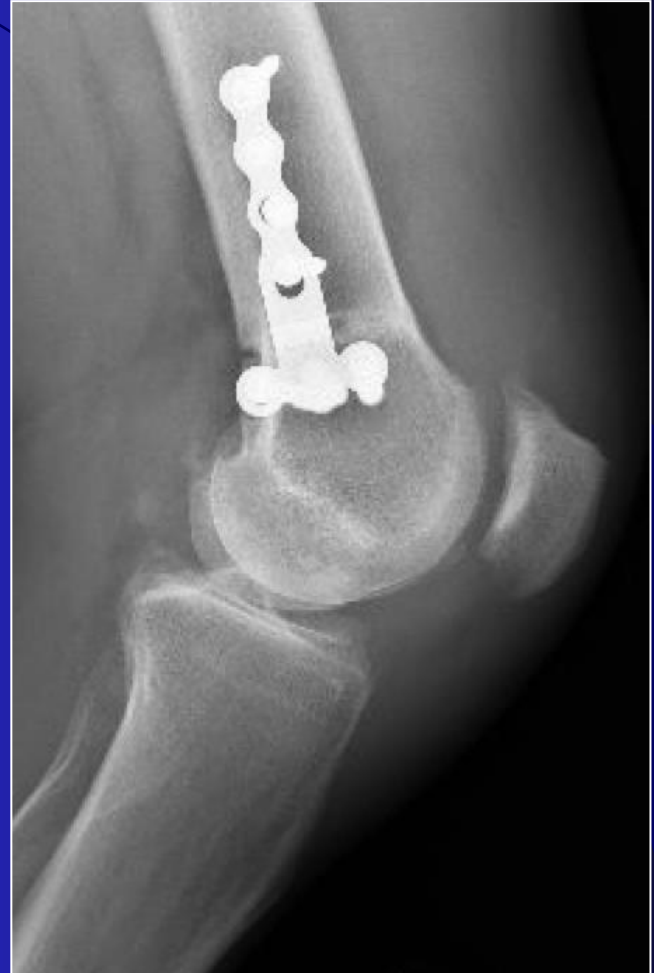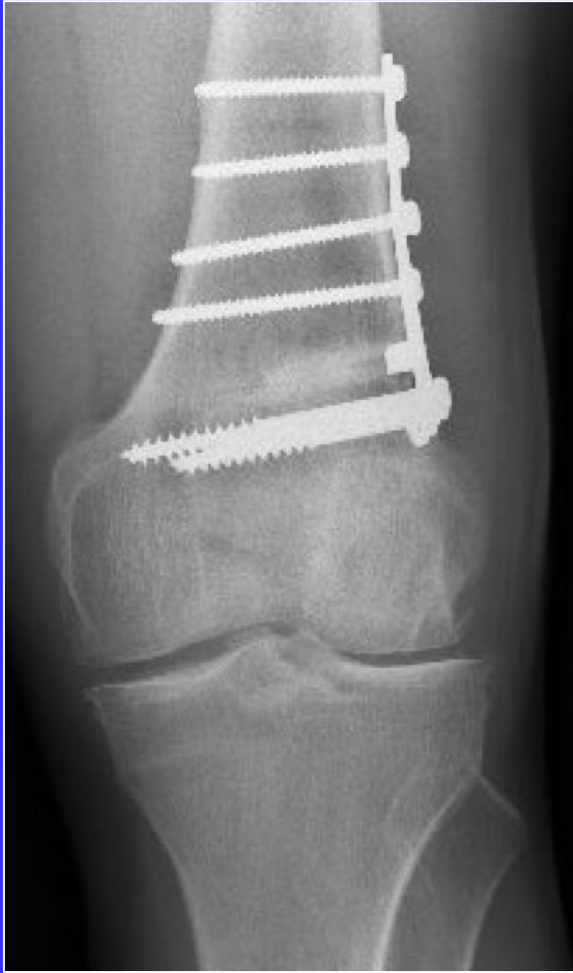J.M. – Goal of Correction



$$\tan \alpha = y/x$$
$$(\tan \alpha) x = y$$

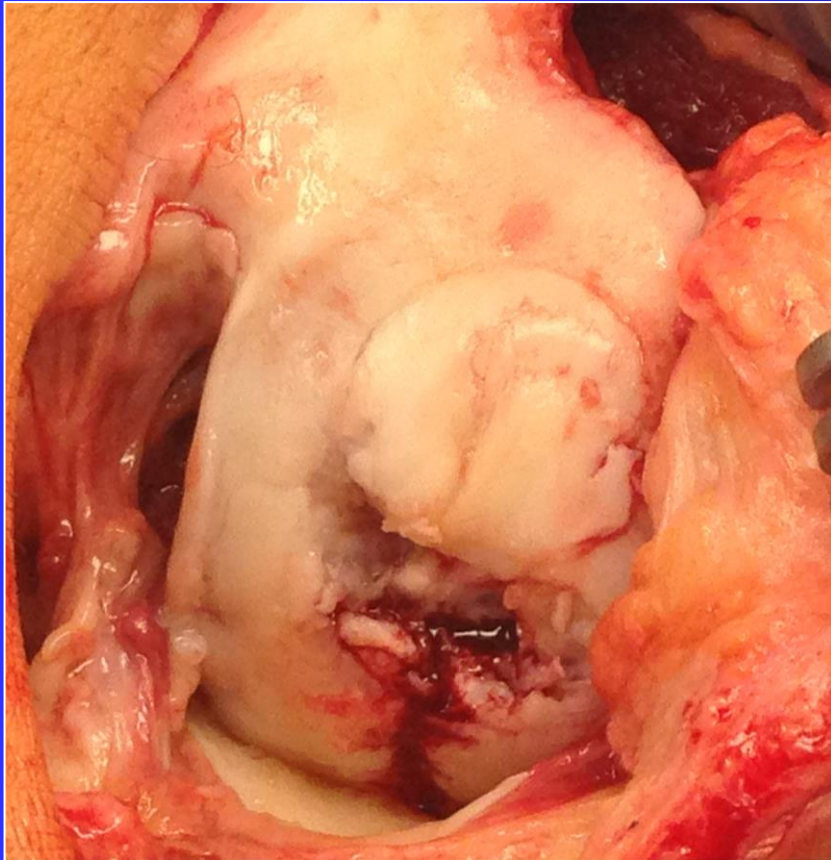
Goal: correct mechanical axis to the 50th percentile

J.M. – Distal Femoral Osteotomy

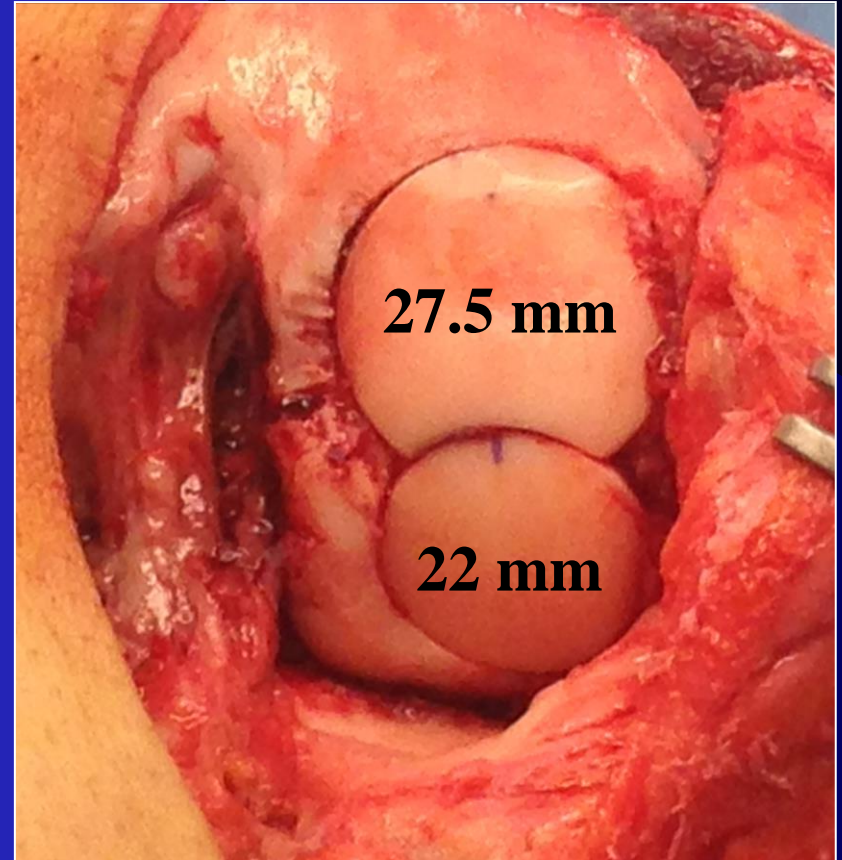


9 months postoperative

J.M. – Surgery: Open osteochondral allograft x 2
Distal femoral osteotomy (5 mm)



PREoperative



POSToperative

Outcome

- For lesions greater than 3 cm² OAT shows benefit over microfx in terms of patient post op activity and graft failure rate
- OA graft survival rate at 10 years 79%
- In a military pop. 64% able to return to previous activity level after OA graft

Take Home Points

- ACL reconstruction indicated in patient wanted to return to jumping, twisting and pivoting activity
- Allograft ACL reconstruction associated with a higher failure rate compared to autograft tissue and not recommended in young athletes
- Treatment of meniscal tears is dependent on the type of tear, age of the patient and degree of underlying osteoarthritis
- Bucket handle meniscal tear is a relatively surgical emergency and repair recommend
- Repair of meniscal root tears recommended in patient with minimal OA and appropriate BMI to decrease the progression of arthritis and need or TKA
- Treatment of chondral defects dependent on size of the lesion

References

- Gee S. et al. Anterior Cruciate Ligament Repair: Historical Perspective, Indications, Techniques and Outcomes. JAAOS. 2020. 23(23):936-971
- Krych A. et al., Meniscal Root Injuries. 2020. 28(12):491-499
- Krych A. et al. Cartilage Injury in the Knee: Assessment and Treatment Options. JAAOS. 2020. 28(22):941-922

Thank You



Email with further questions:
Lily.Bogunovic@gmail.com

