

MSK Focus POCUS

Kevin Shinsako, MS, PA-C

Physician Assistant

Instructor, Department of Orthopaedic Surgery

University of Colorado School of Medicine



MSK Focus POCUS

Kevin Shinsako, MS, PA-C

Physician Assistant

Instructor, Department of Orthopaedic Surgery

University of Colorado School of Medicine



MSK Focus **Point Of Care** US

Kevin Shinsako, MS, PA-C
Jason Rand, PA-C, and Keri Riechers, PA-C



MSK Galaxy Ultrasound

- Kevin Shinsako, PA-C: No Disclosures.
- Jason Rand, PA-C: No Disclosures
- Keri Riechers, PA-C: No Disclosures



MSK Galaxy Ultrasound

- Introduction to Ultrasound
- Why
- How
- Basics of MSK Injections



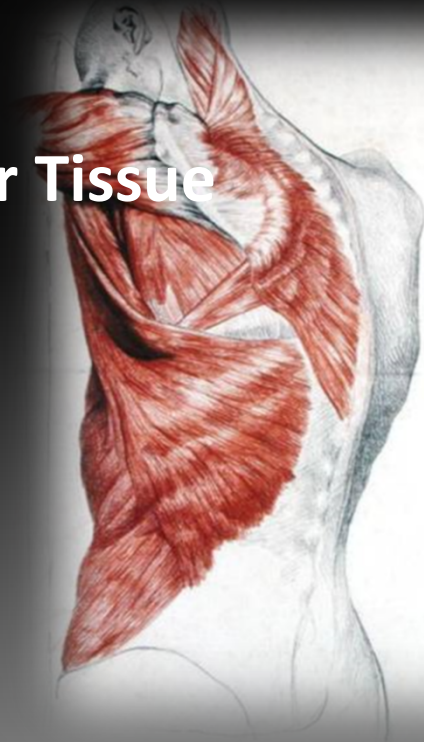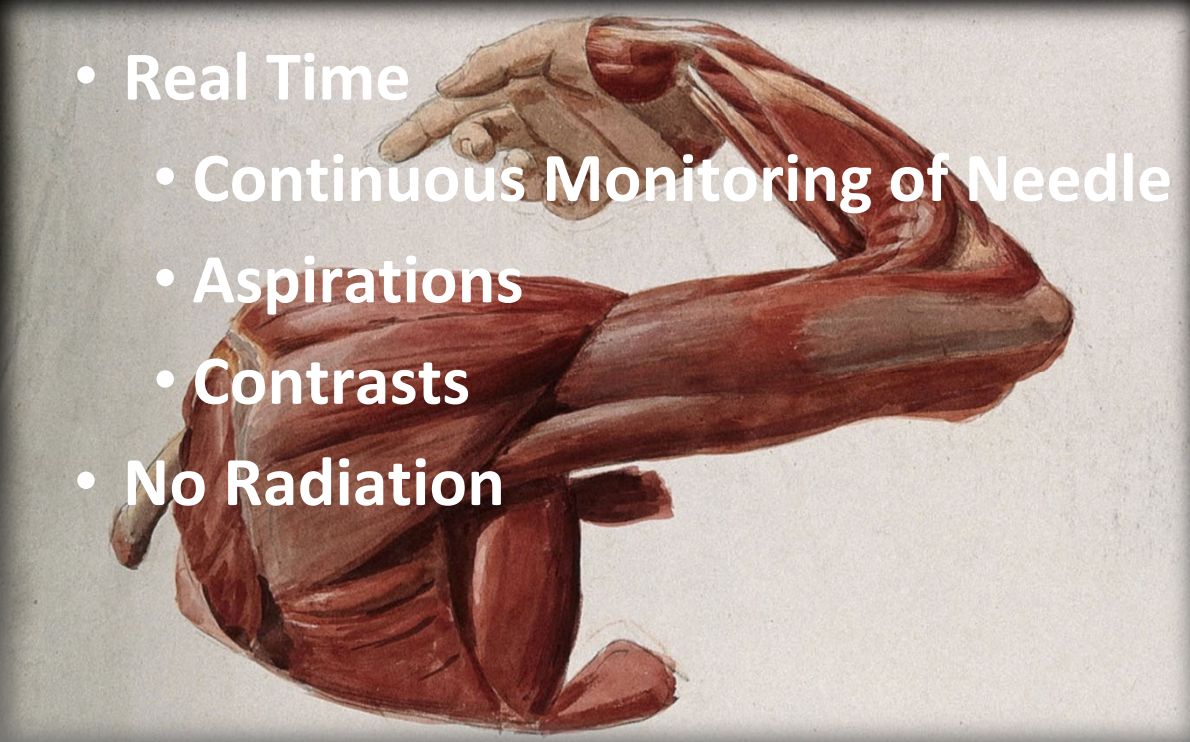
Objectives:

- Explain why and how to use ultrasound for MSK conditions and procedures
- Describe tips for identifying critical structures and landmarks for basic MSK injections
- Identify modern techniques for utilization of ultrasound and its role in performing injections of large joints



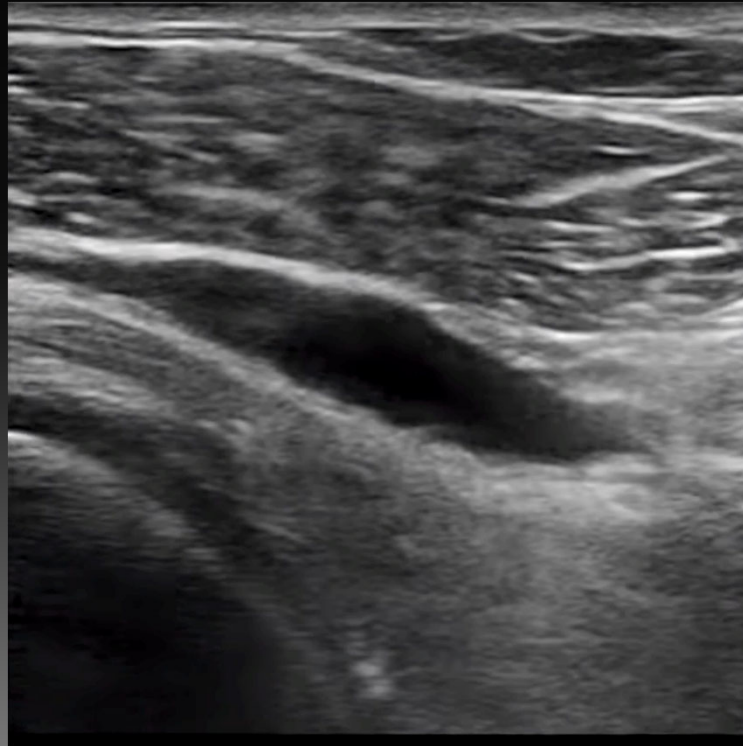
Advantages of Ultrasound

- Depiction of Soft Tissues
 - Tendon, Muscle, Bursae, Joint, Cysts/Masses
- Real Time
 - Continuous Monitoring of Needle or Tissue
 - Aspirations
 - Contrasts
- No Radiation



Advantages of Ultrasound

- Real Time
 - Continuous Monitoring of Needle or Tissue
 - Aspirations
 - Contrasts
- No Radiation



Advantages of Ultrasound

- **Accuracy of US guidance vs Palpation**
 - Subacromial Injection 100% vs 60-75%
 - Glenohumeral Injection 92-95% vs 40-79%
 - AC Joint Injection 100% vs 40-67%
 - Biceps Tendon Sheath Injection 100% vs 67%
- **Comfort of Patient – No probing or repeated poking**
- **Aid in Diagnosis**
- **Reimbursement**



Advantages of Ultrasound

- **Accuracy of US guidance vs Palpation**
 - Subacromial Injection 100% vs 60-75%
 - Glenohumeral Injection 92-95% vs 40-79%
 - AC Joint Injection 100% vs 40-67%
 - Biceps Tendon Sheath Injection 100% vs 67%
- **Comfort of Patient – No probing or repeated poking**
- **Aid in Diagnosis**
- **Reimbursement**



Expansion of Practice

- Advance from simple and common injections to more complex interventions
- Keeping more “in-house”
- Increased confidence of the clinician
- Increased clinician retention and recruitment



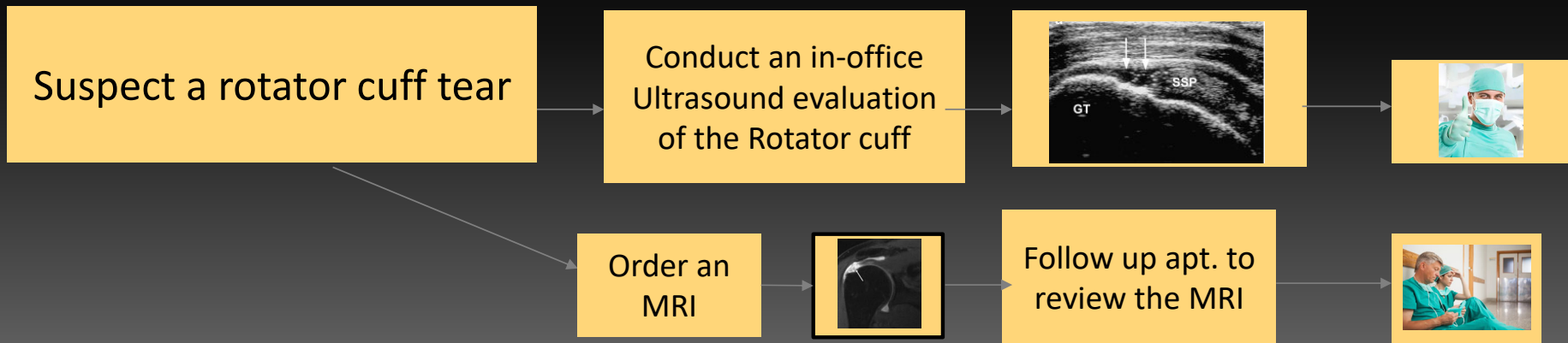
Patient Satisfaction

- Increased patient confidence when visualization is used.
- The patient becomes an active participant in the procedure
- Improved Efficiency
 - No “hunting” for the proper spot to inject
- More willing to take part in more expensive procedures
- You and they gain invaluable knowledge concerning patient diagnosis



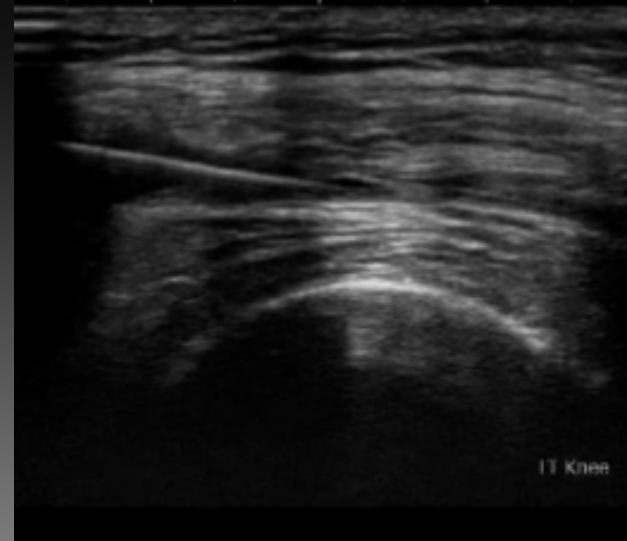
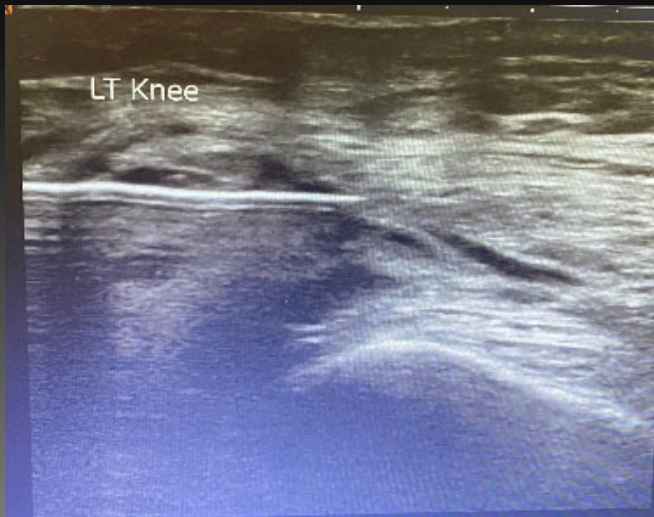Advantages of US vs CT/MRI

- Provide onsite and immediate information
- No radiation exposure
- Capture the diagnostic fee
- Improved patient experience



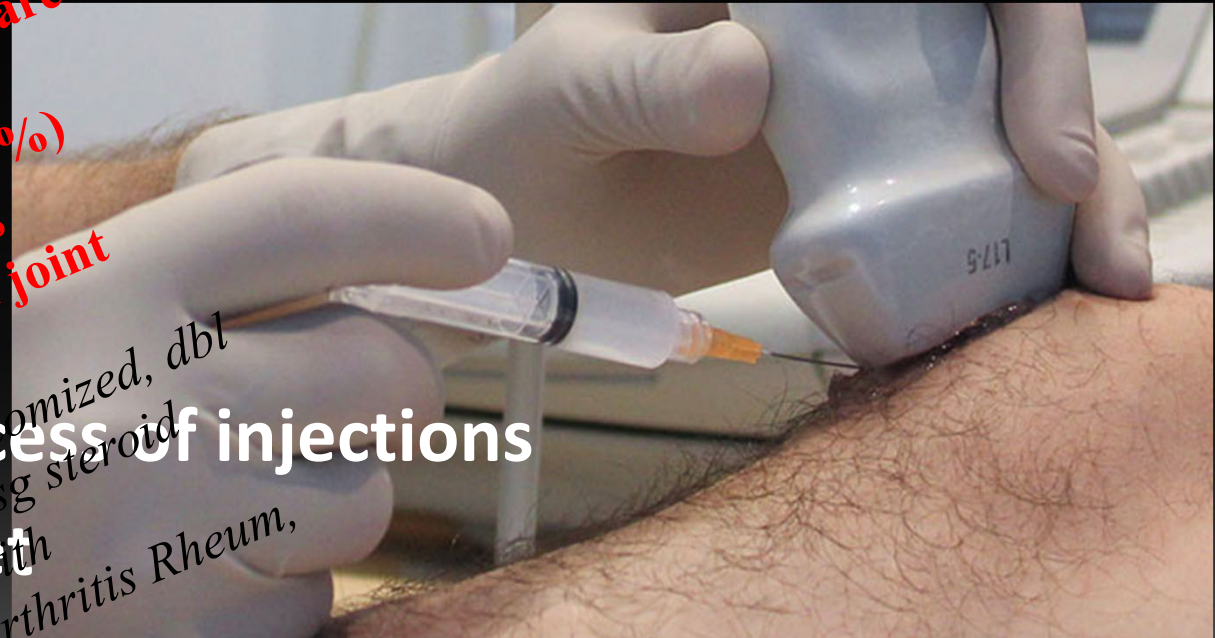Medical-legal Benefits of Interventional US

- Patient Safety
- Acceptable Practice compared to the standard level of care
- Documentation of injection placement and anatomy
 - Image placed into patient's chart



Disadvantages of Ultrasound

- Time Commitment
- May need assistant
- ROI
- Discrepancies in success of injections
- Dependent on skill set



Even inexperienced practitioners are more accurate performing joint injections with US guidance (83%) than experienced practitioners performing palpation-guided joint injections (66%)

- Cunningham, J et al. A randomized, double-blind, controlled study of usg steroid injections into the joint of patients with inflammatory arthritis. Arthritis Rheum, 2010. 62(7): p 1862-1869



Ultrasound Terms

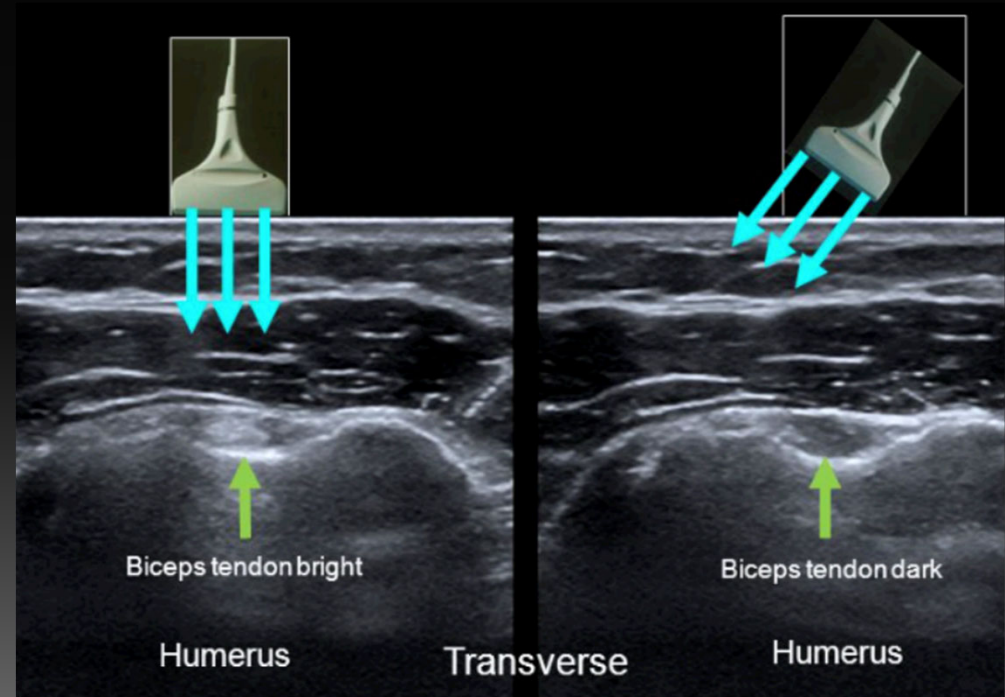
Anisotropy - The property of being directionally dependent

Hyperechoic – Brighter

Hypoechoic – Darker(grey)

Isoechoic – Same density

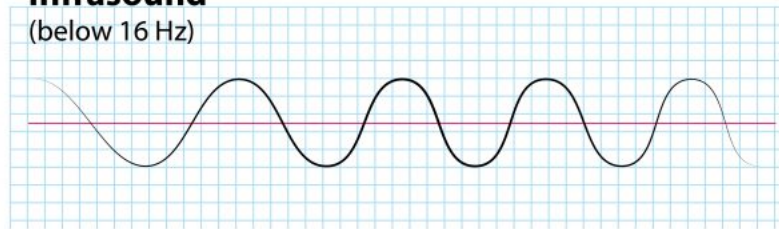
Anechoic – No signal(black)



Ultrasound

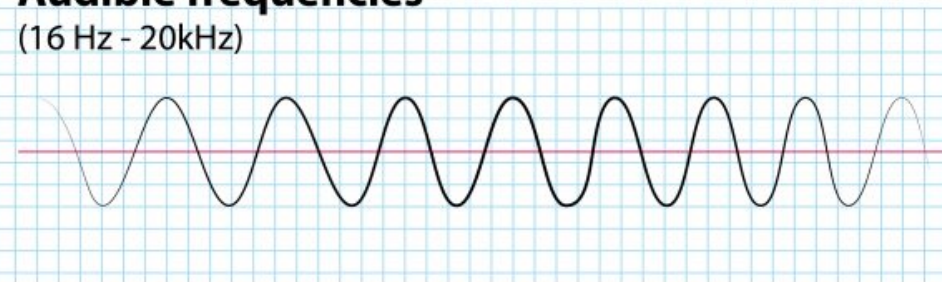
Infrasound

(below 16 Hz)



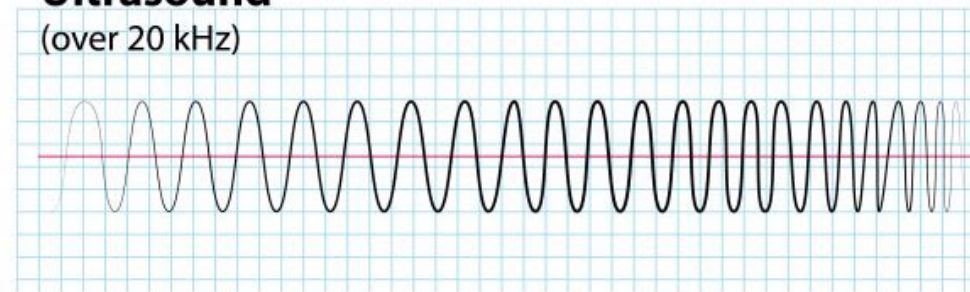
Audible frequencies

(16 Hz - 20kHz)



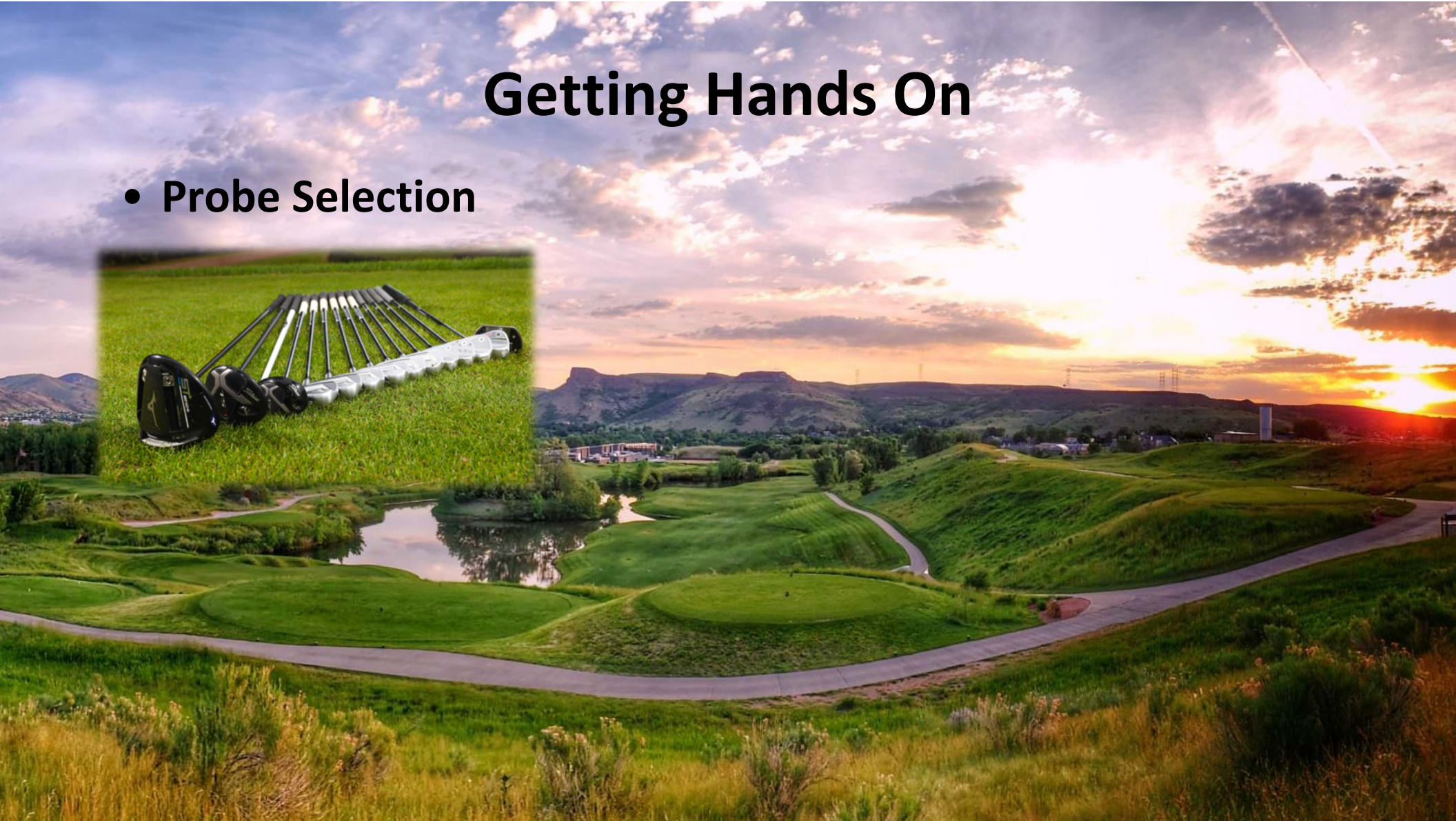Ultrasound

(over 20 kHz)



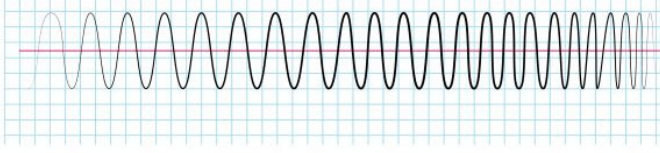
Getting Hands On

- Probe Selection




Ultrasound

(over 20 kHz)

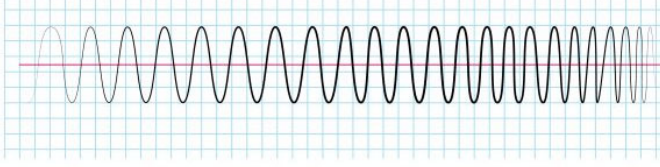


Probe Selection



Ultrasound

(over 20 kHz)

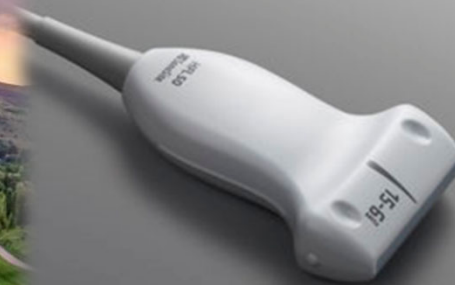

Probe Selection



Curvilinear Probe:

- Low Frequency(2.5-5MHz)
- Higher Penetration
- Lower Image Quality



Linear Probe:

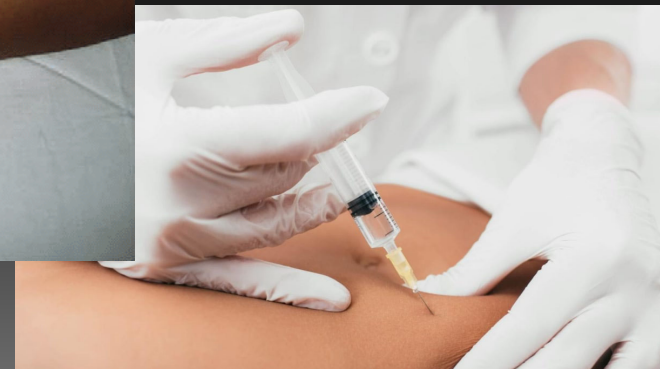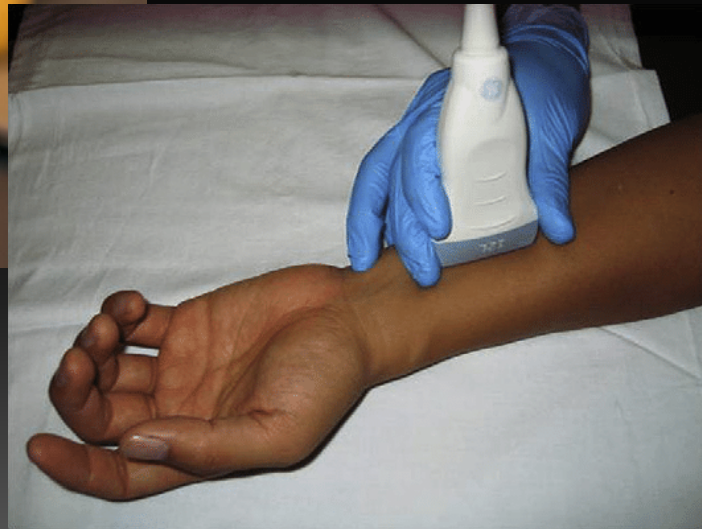- High Frequency(5-10MHz)
- Lower Penetration
- Greater Image Quality

Probe Selection



Getting Hands On

Holding the Transducer

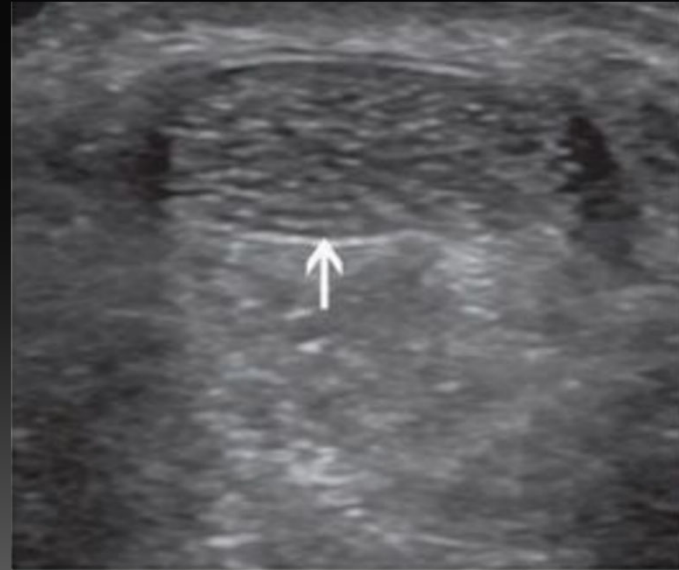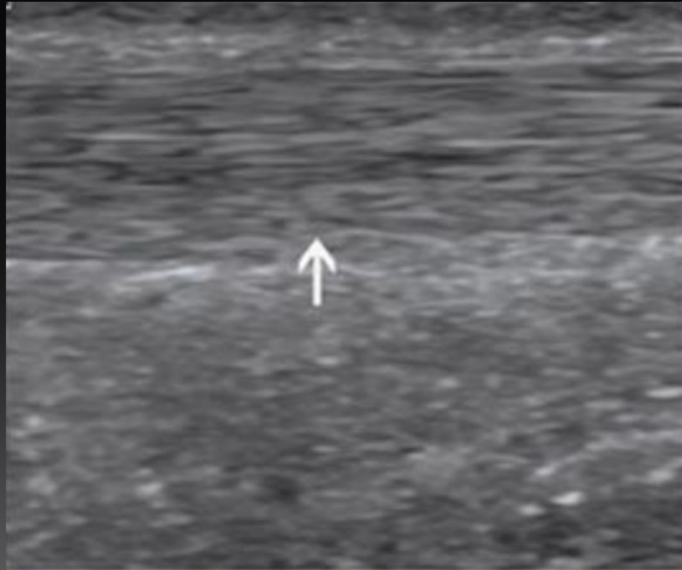


Making an Appearance



Making an Appearance

Tendon: Echogenic and Fibrillar

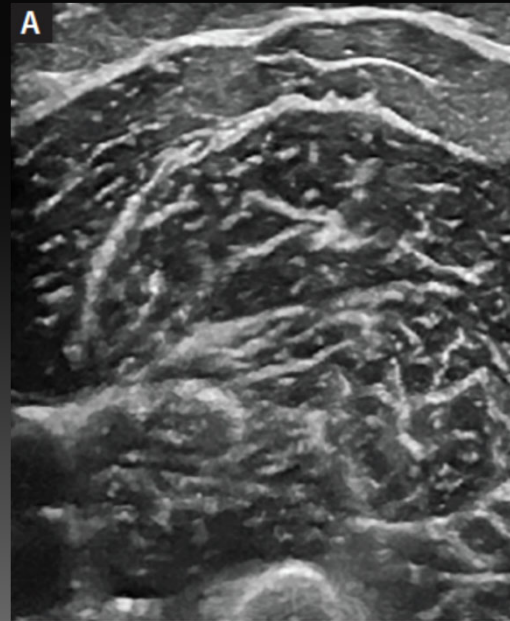
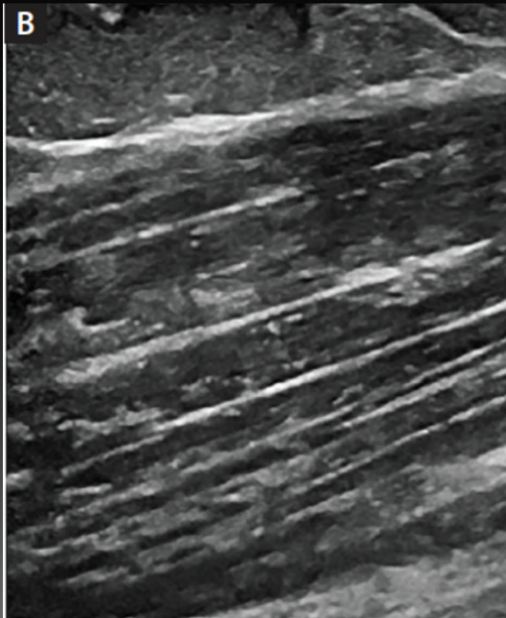


Echogenic: The ability to reflect US waves



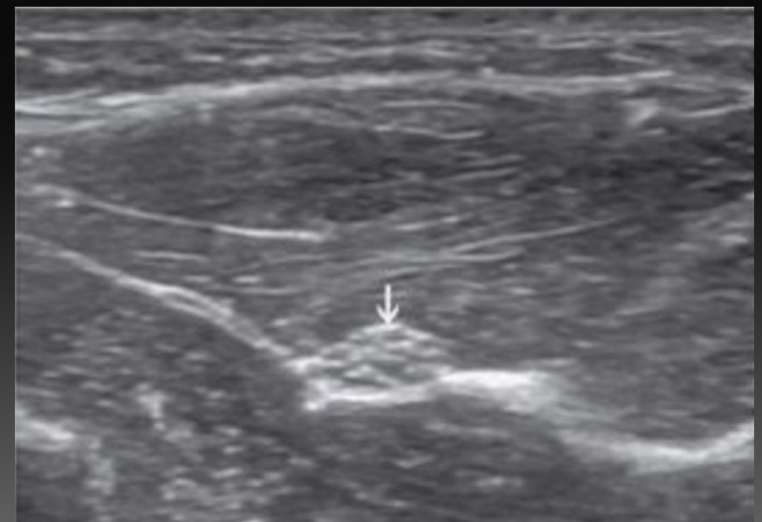
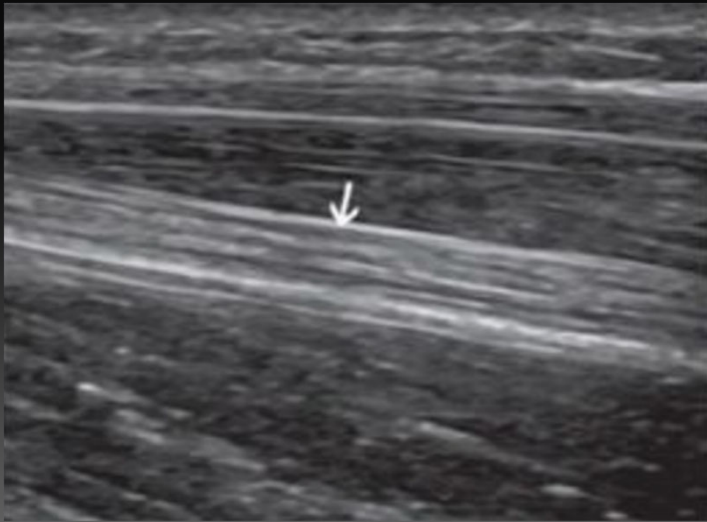
Making an Appearance

Muscle: Hypoechoic with interspersed echogenic signal
(Fibro-adipose connective tissue)



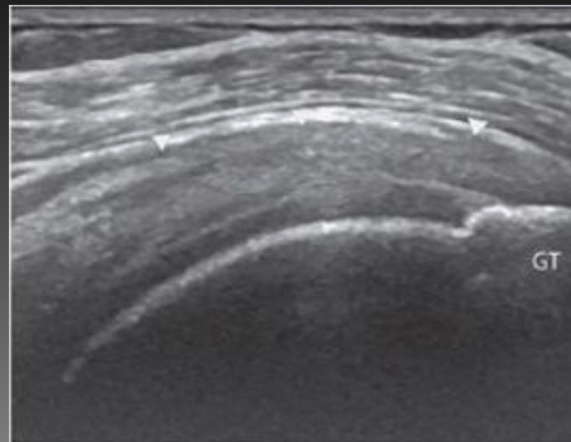
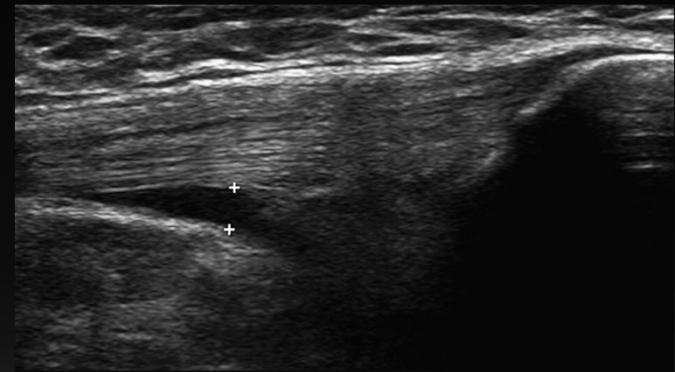
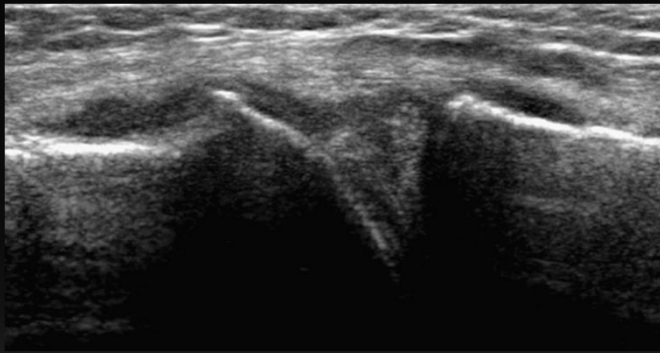
Making an Appearance

Nerves: Hypoechoic signals (like that of grapes) separated by hyperechoic signal (perineurium)



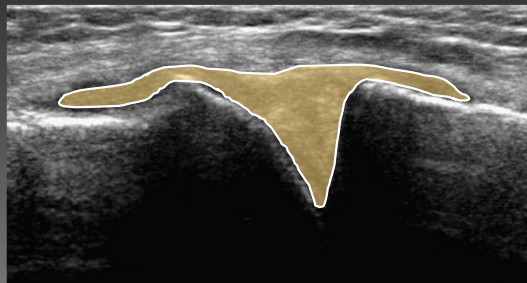
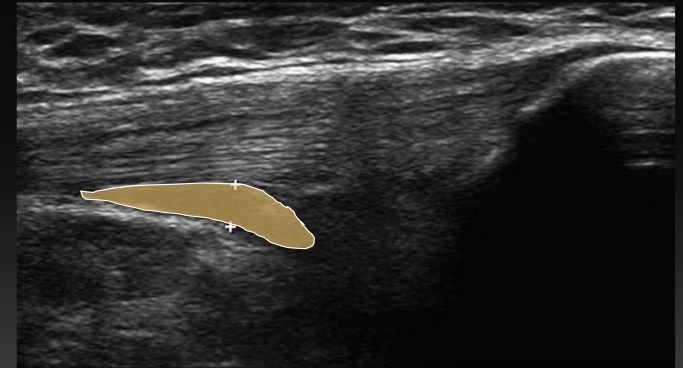
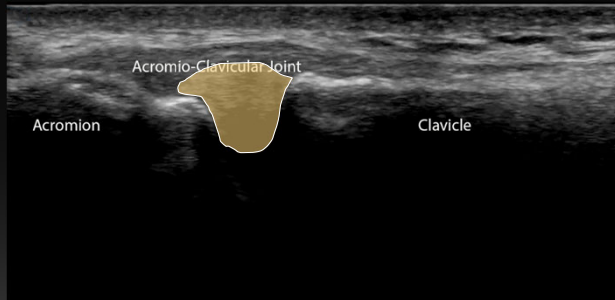
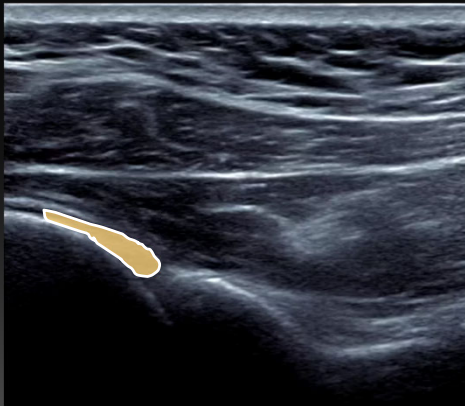
Making an Appearance

Bone: Hyperechoic signal, usually linear with shadowing



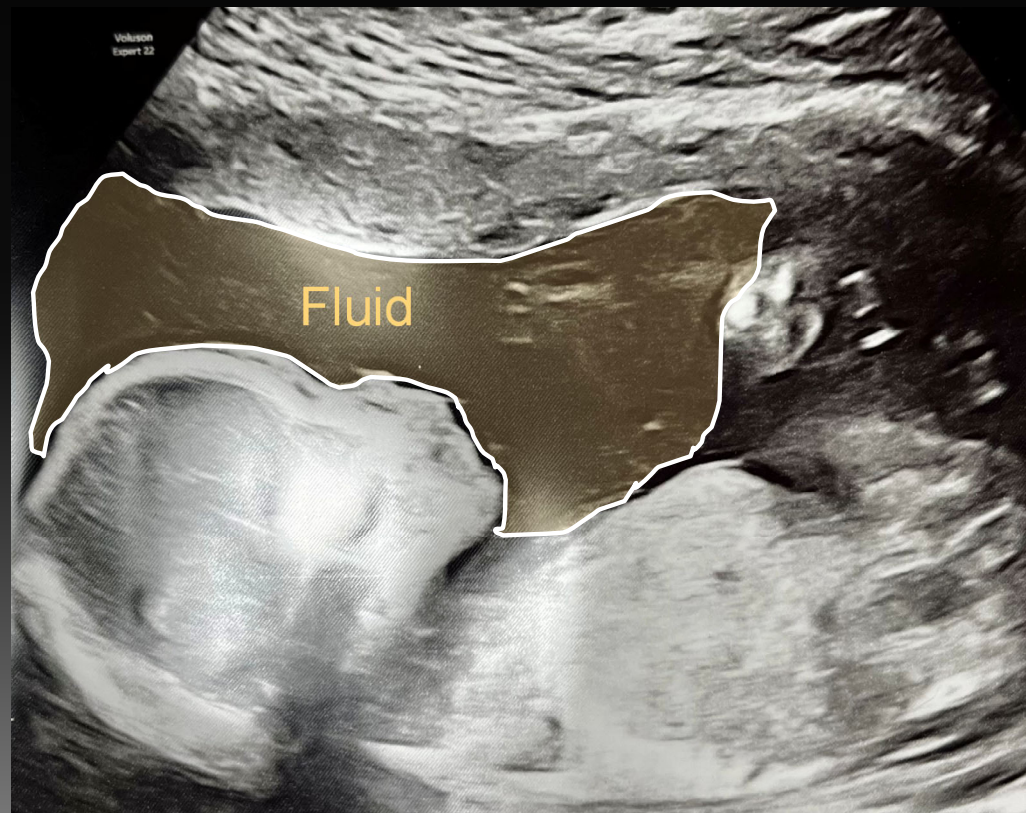
Making an Appearance

Joint: Hyperechoic signal consistent with cortical surface overlying a hypoechoic layer consistent with articular cartilage
Echogenic tissue between cortical surfaces can be capsule or soft tissue



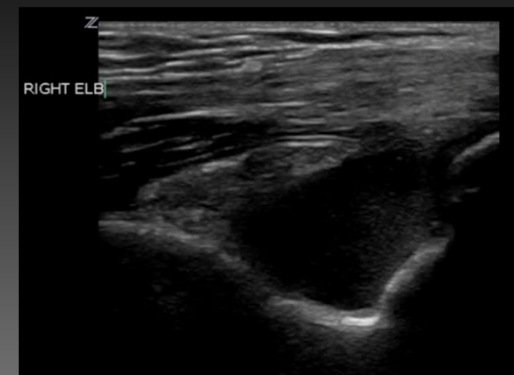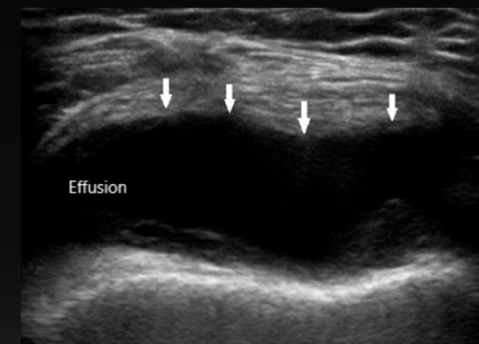
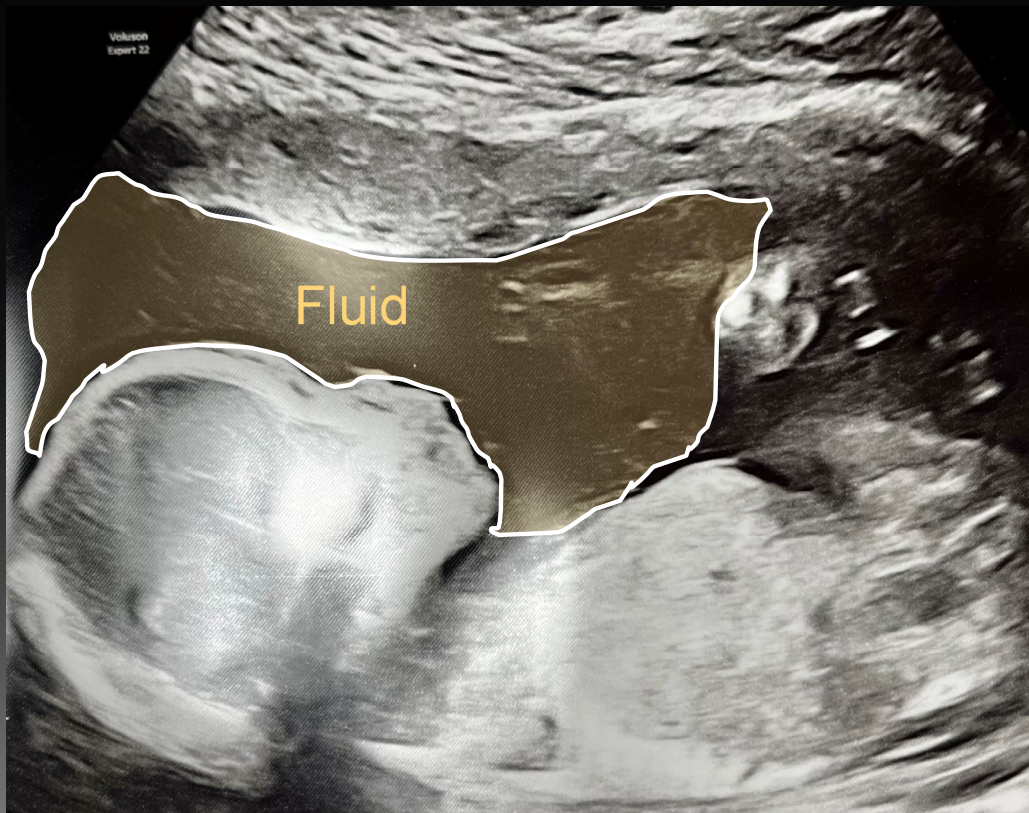
Making an Appearance

Fluid: Hypoechoic

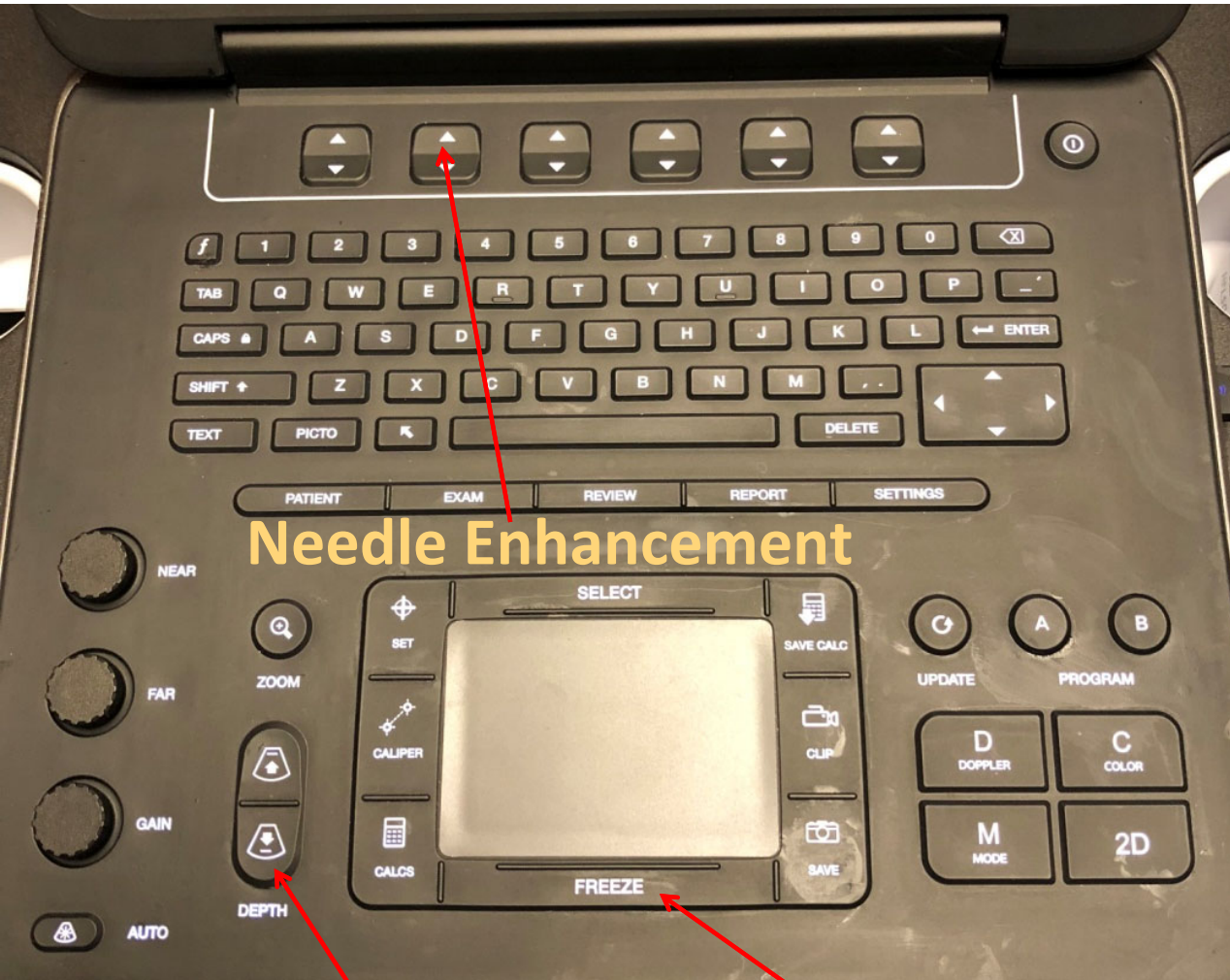


Making an Appearance

Fluid: Hypoechoic



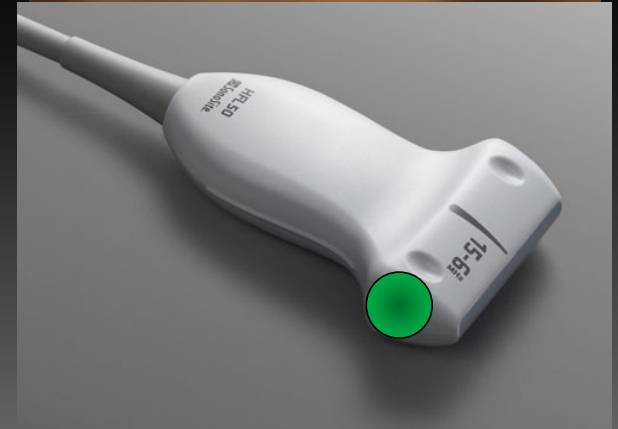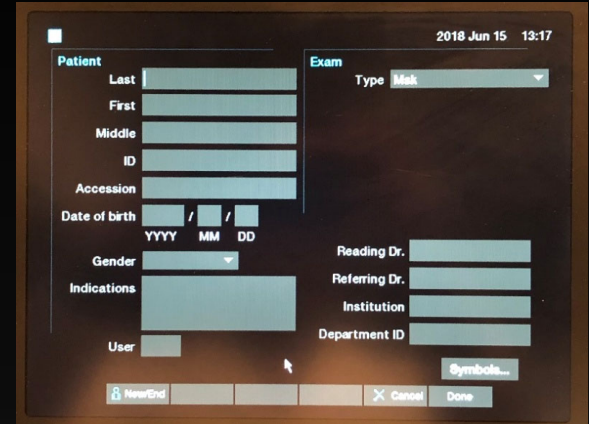
Knob-ology



Needle Enhancement

Depth

Freeze/Unfreeze

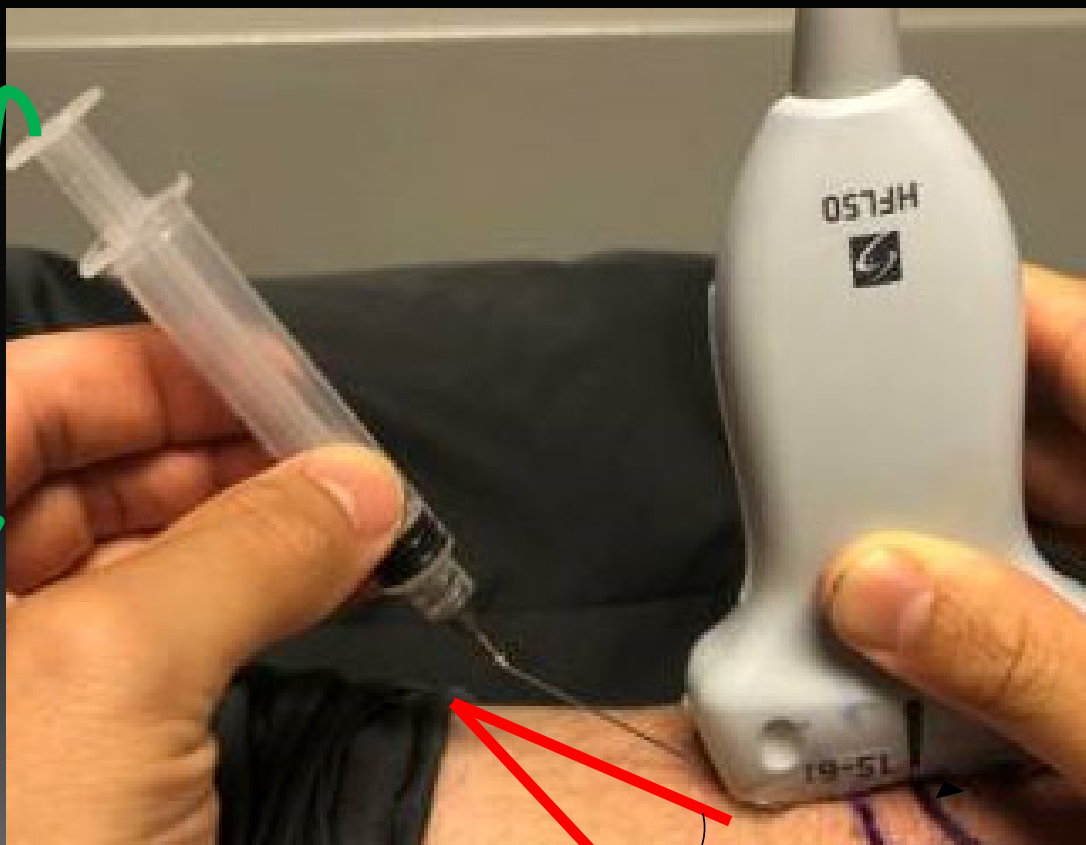

Choose Your Angle

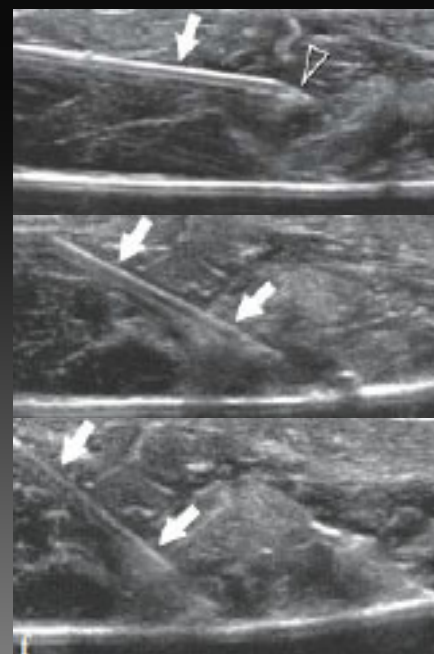
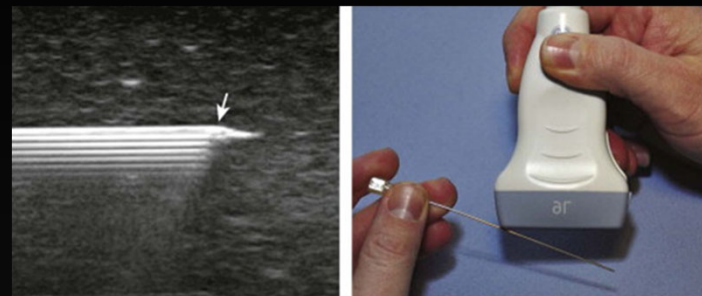
- Find an entry point to maximize capability to visualize needle
- Maximize visualization of target Zone
- Trajectory to target zone, coordinating position of US probe



Needle Trajectory



30-45 degrees



Words

Long Axis

Parallel to tendon or joint

Needle trajectory is along tendon

Needle trajectory along length of probe

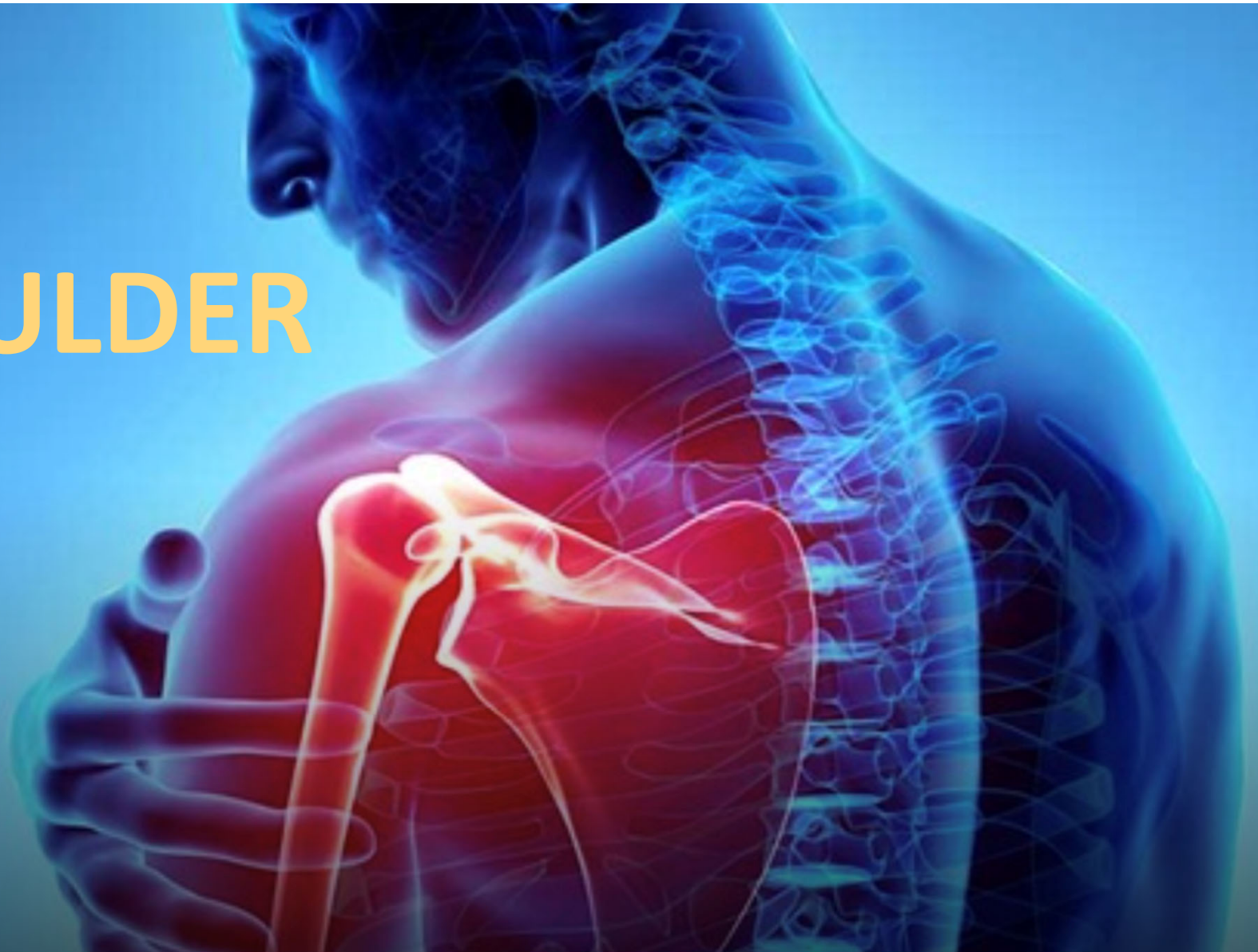Short Axis

Perpendicular to tendon or Joint

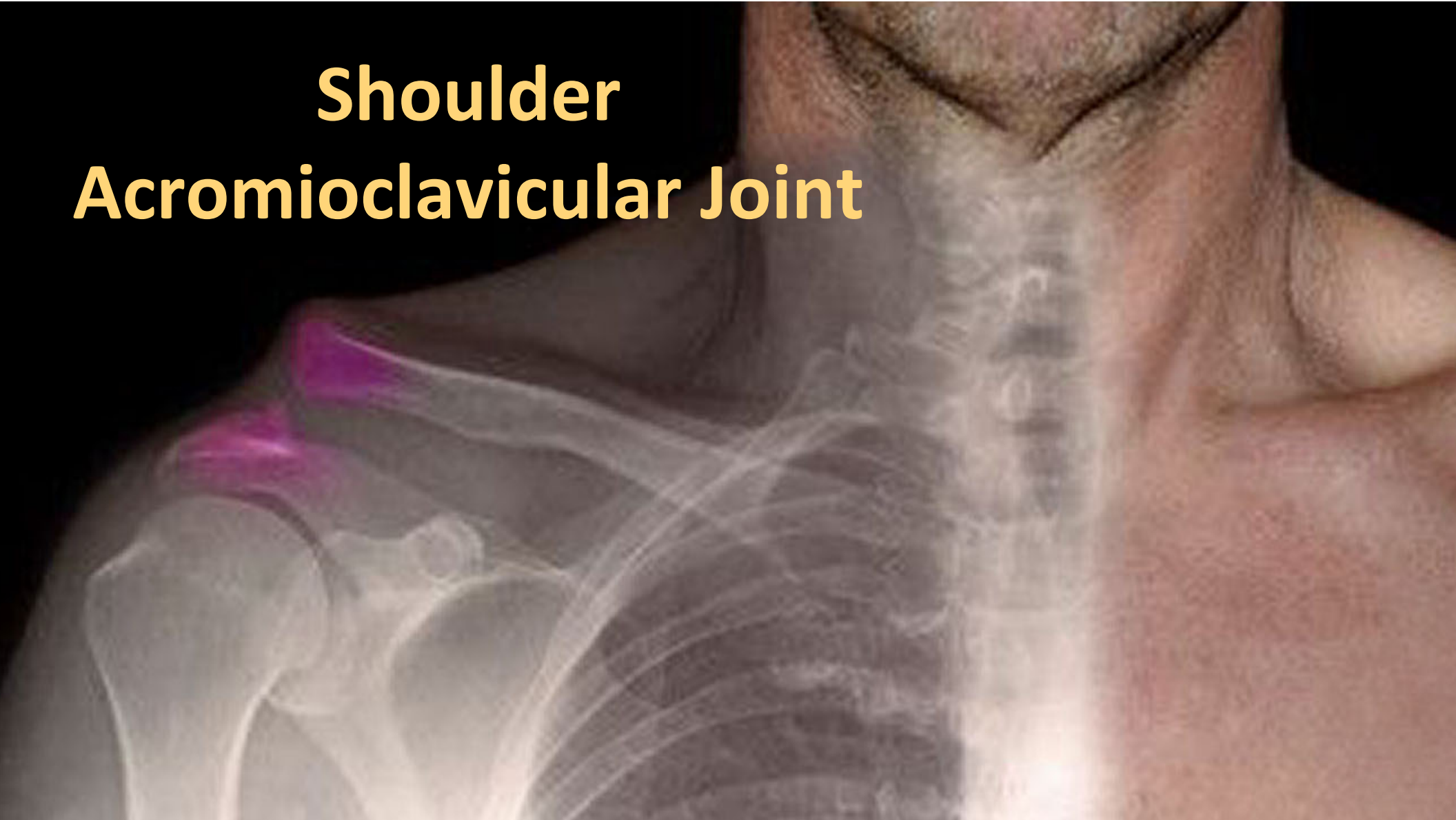
Needle is perpendicular to length of probe



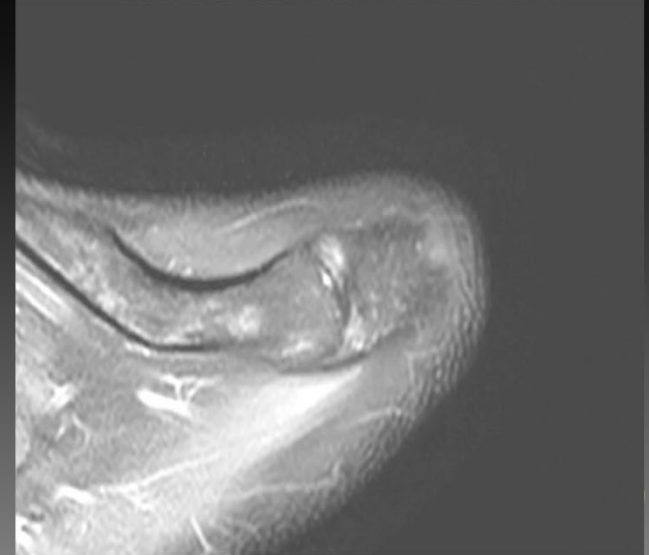
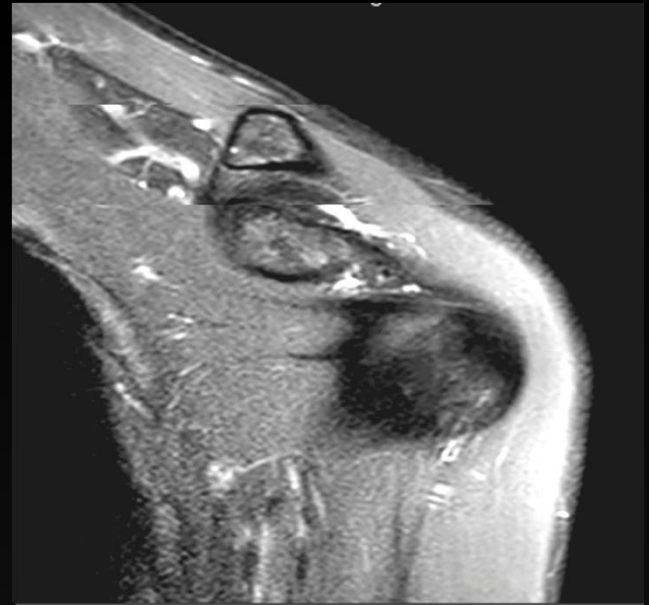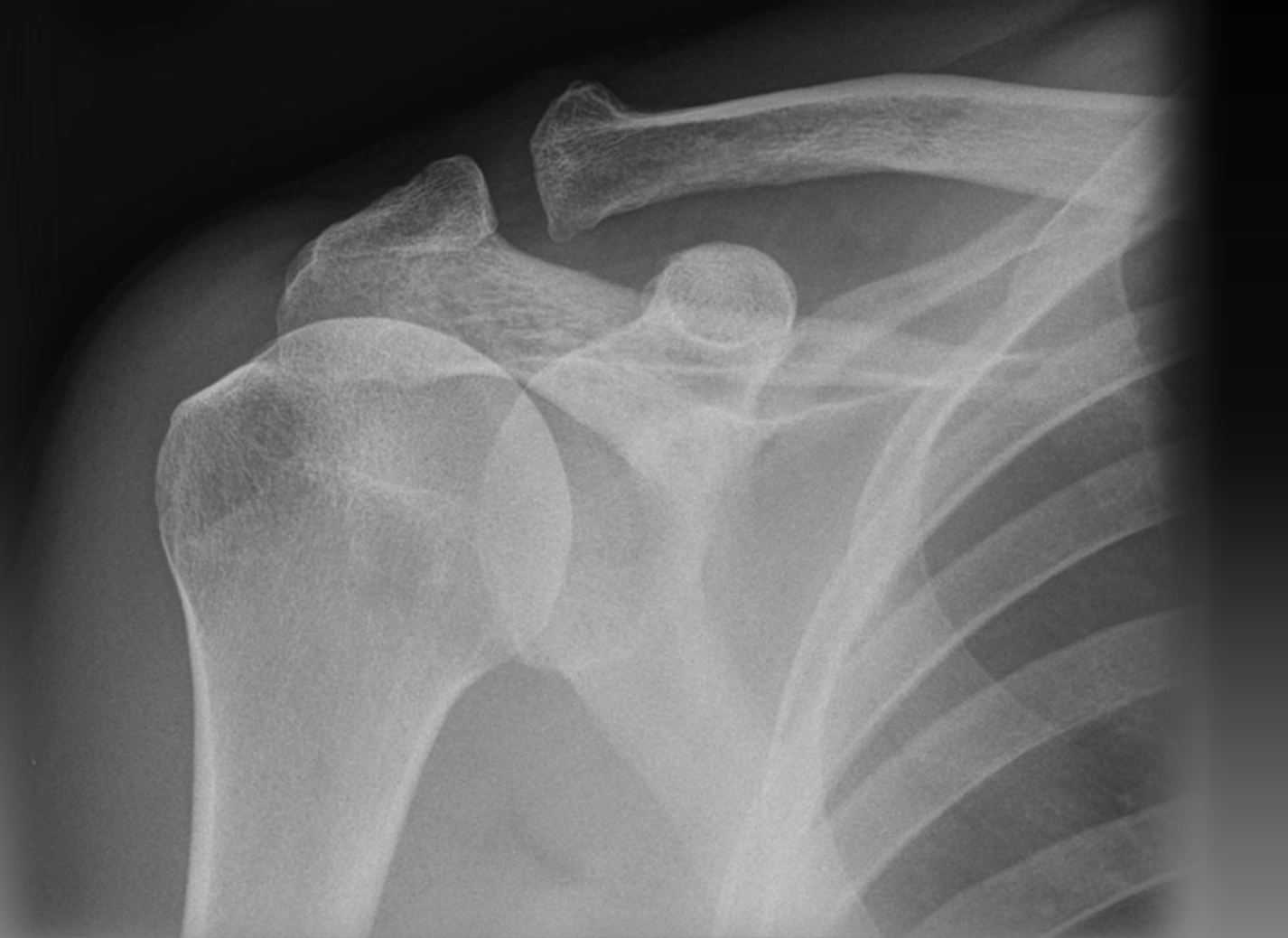
SHOULDER



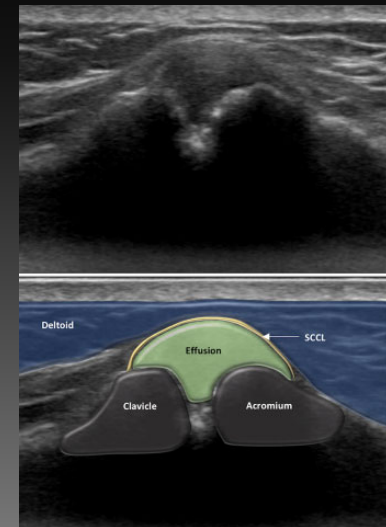
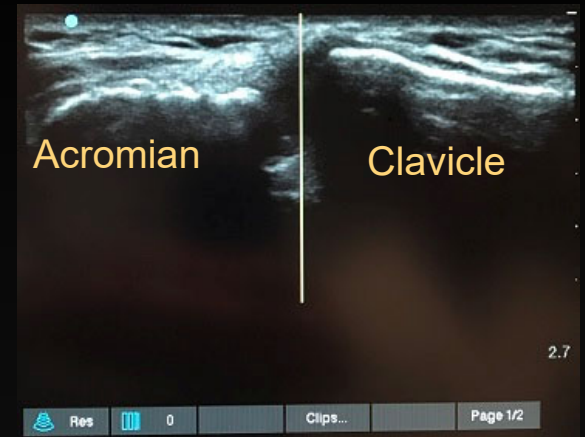
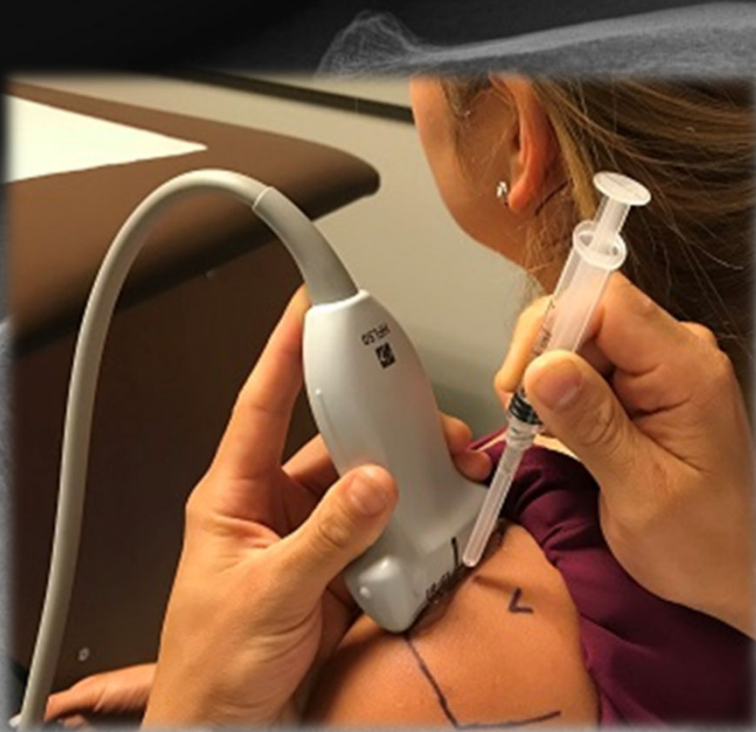Shoulder Acromioclavicular Joint



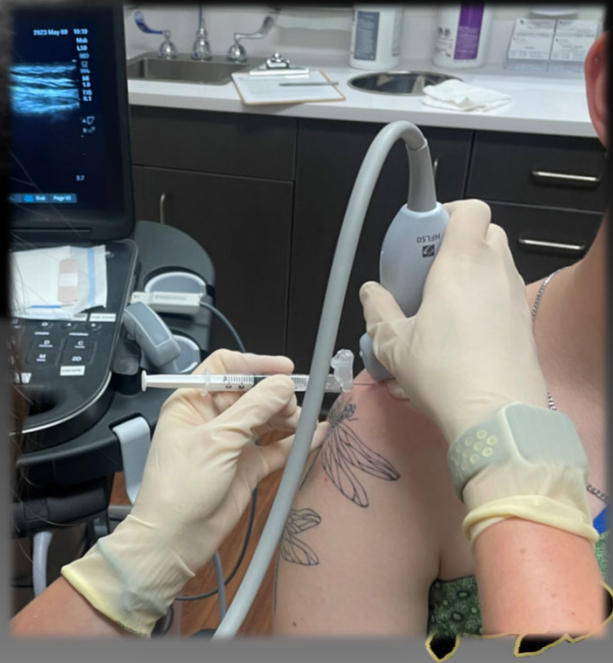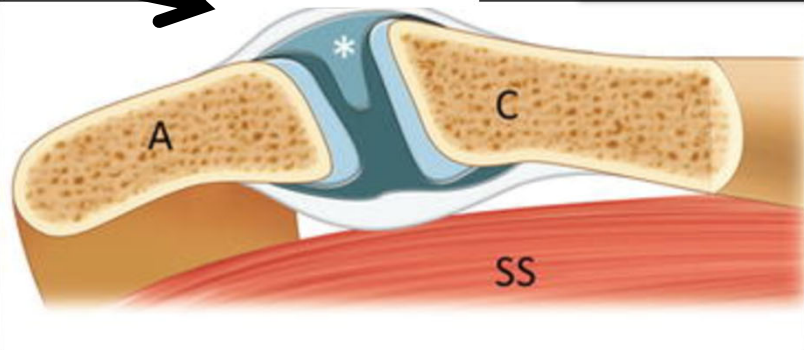
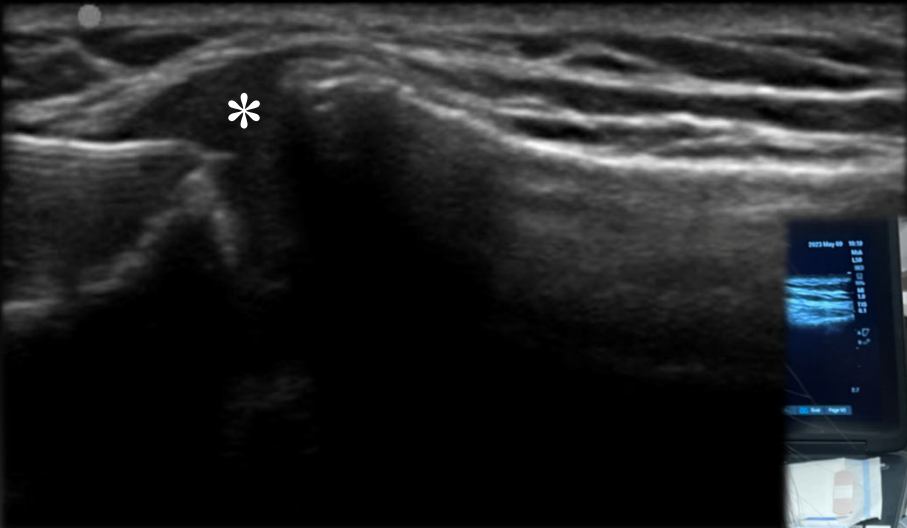
Acromioclavicular Joint



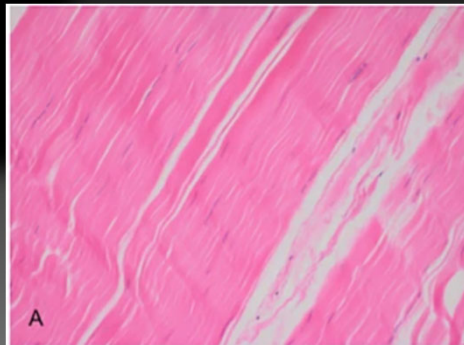
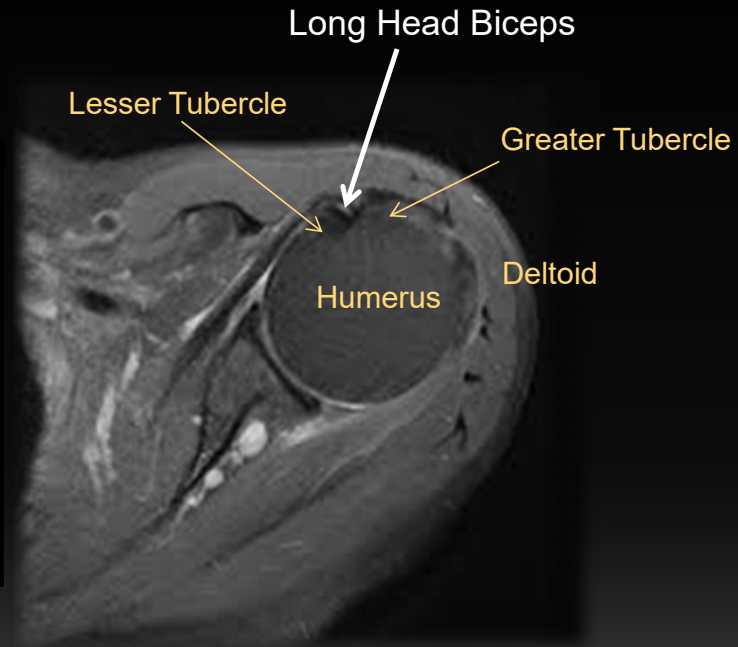
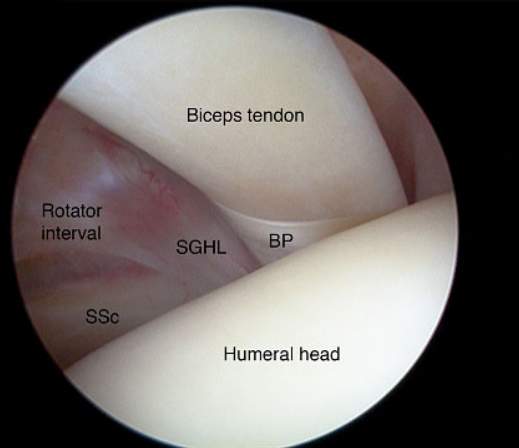
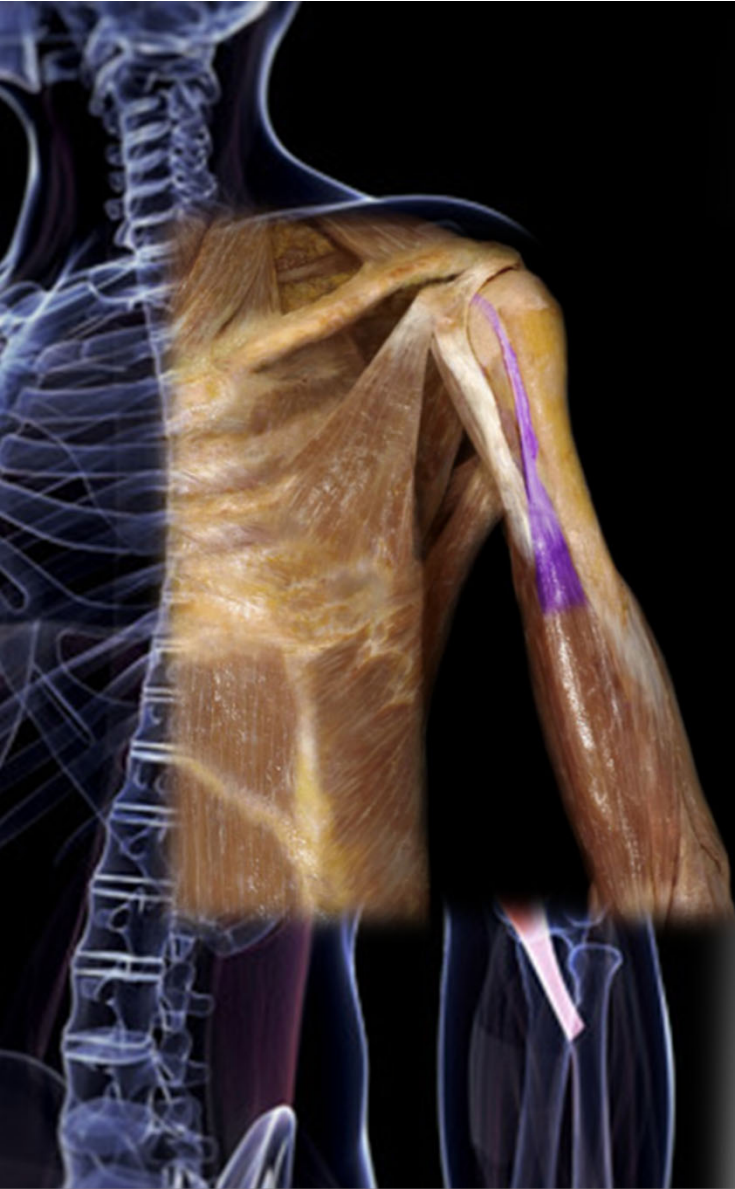
Acromioclavicular Joint



Acromioclavicular Joint



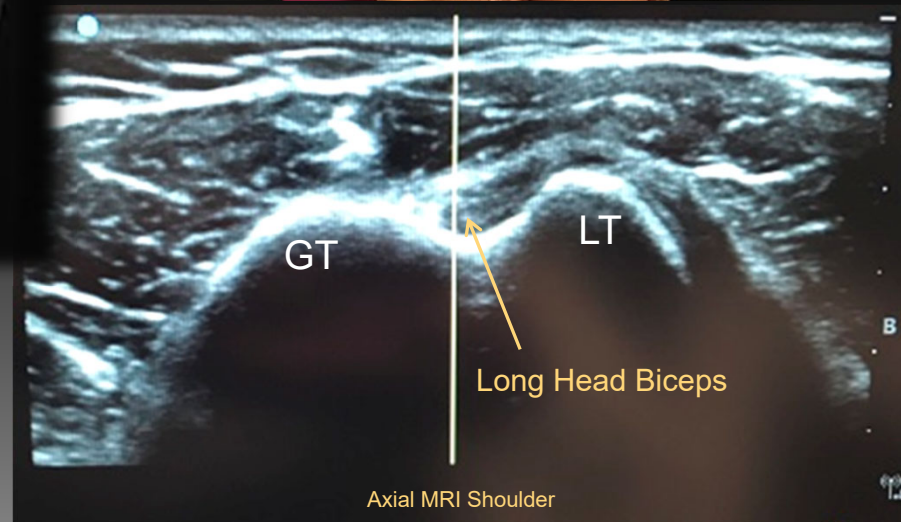
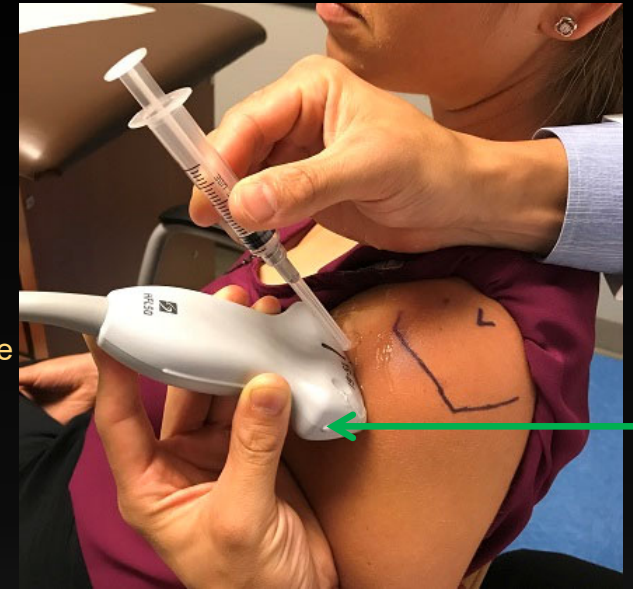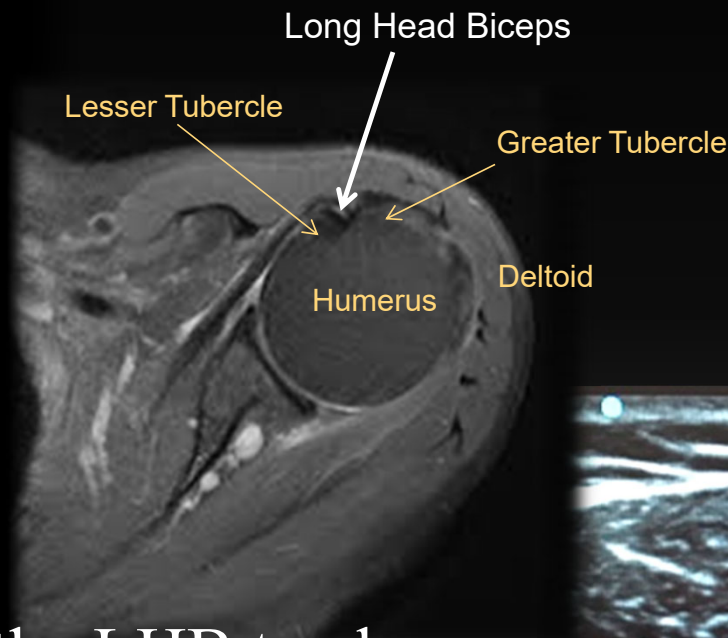
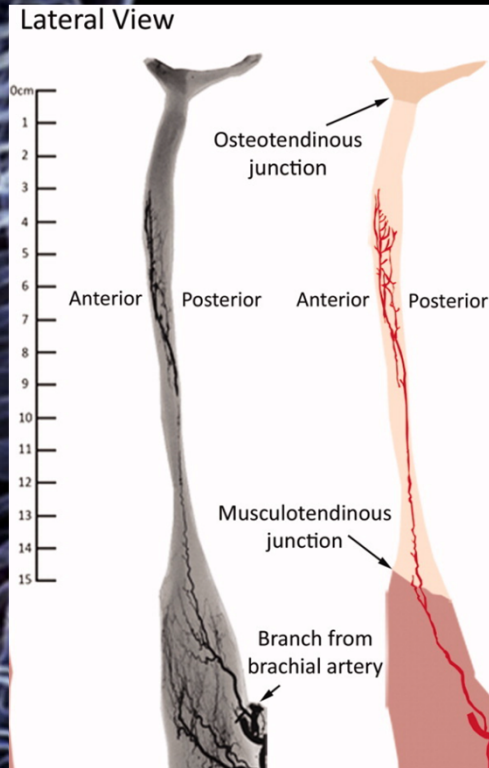
Biceps Brachii



Histopathology of long head of biceps tendon removed during tenodesis demonstrates degenerative histopathology and not inflammatory changes. Maciei J. K. Simon et al. *BMC Musculoskeletal Disorders* volume 23, Article number: 185 (2022)

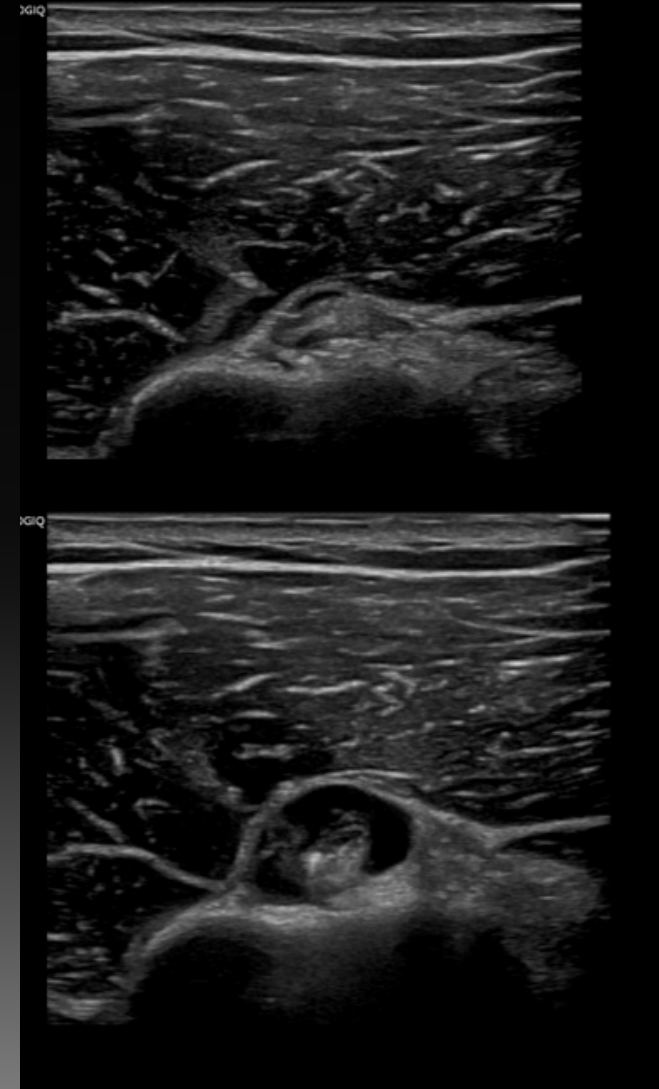
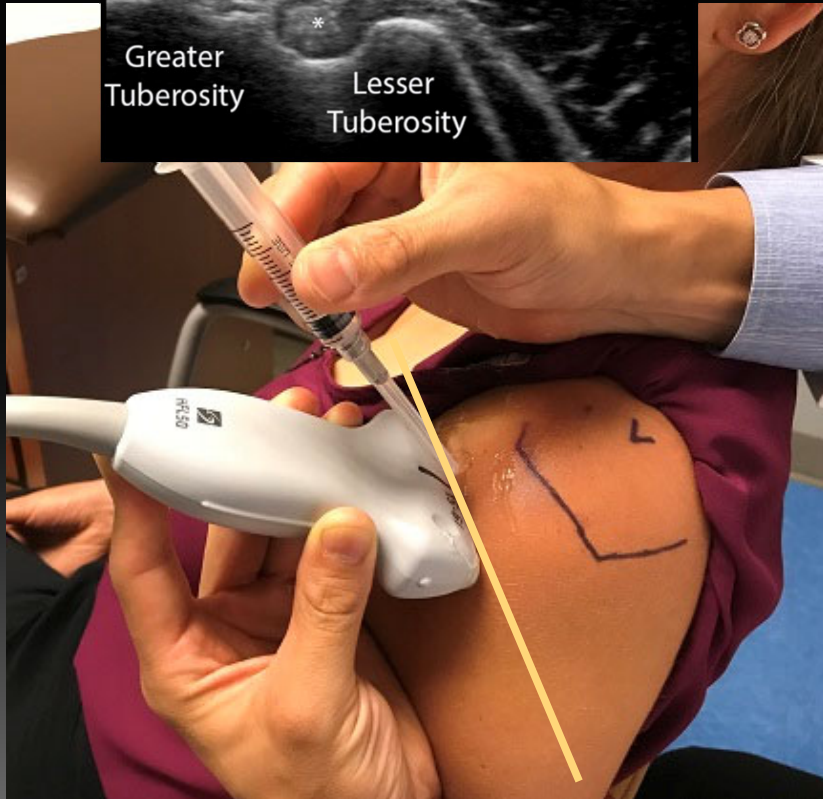
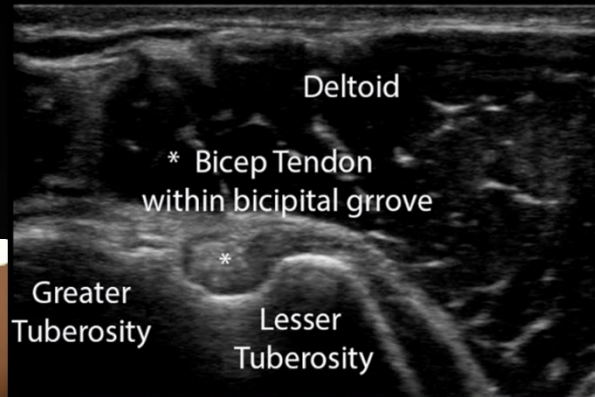


Biceps Brachii

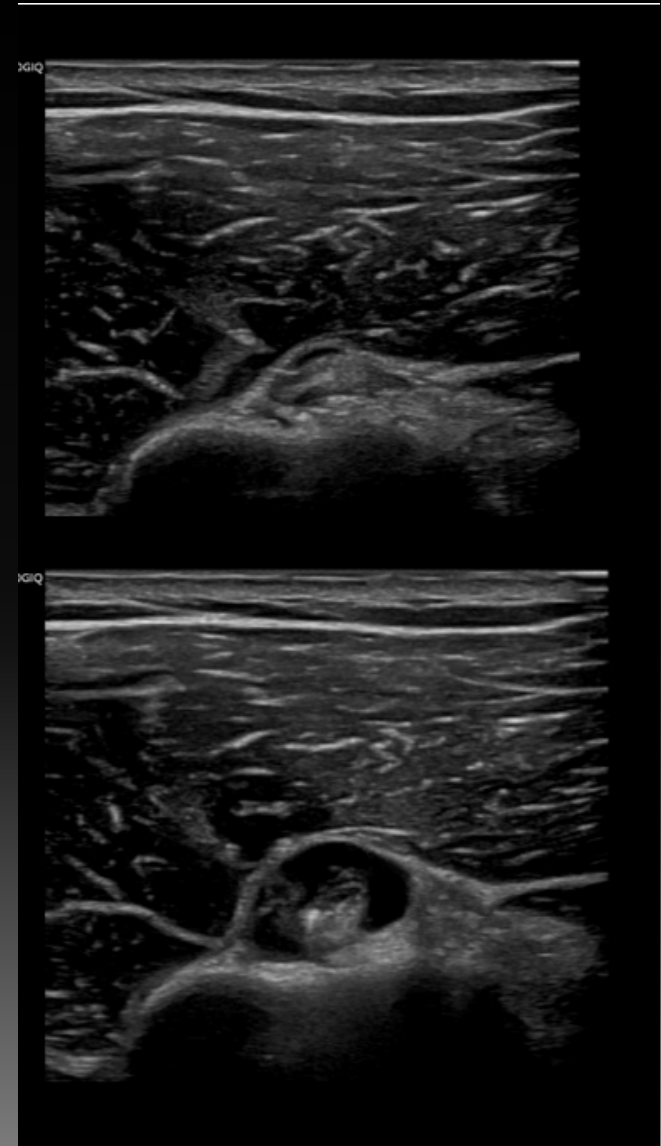
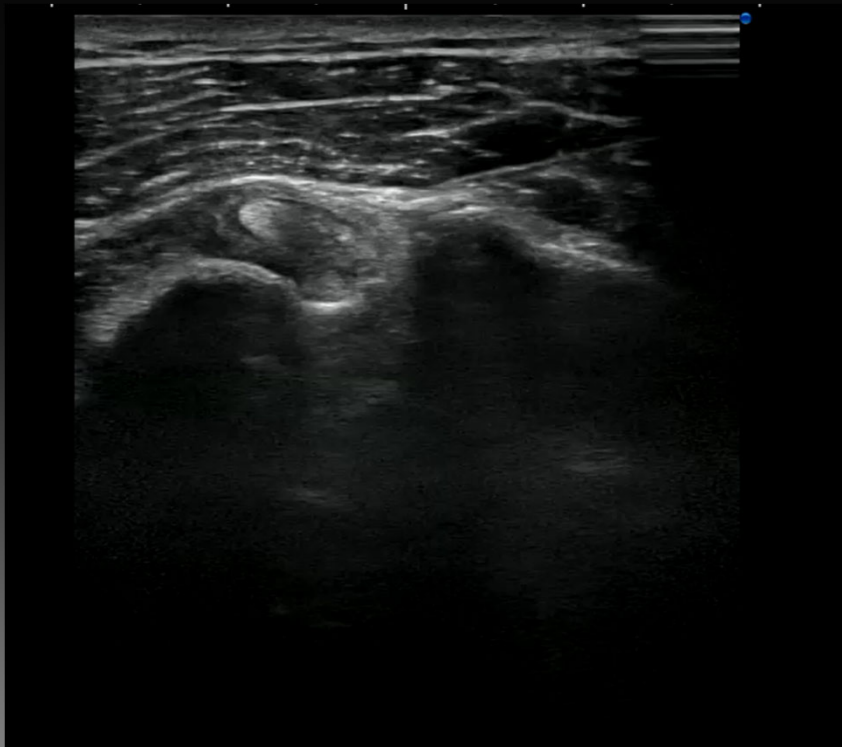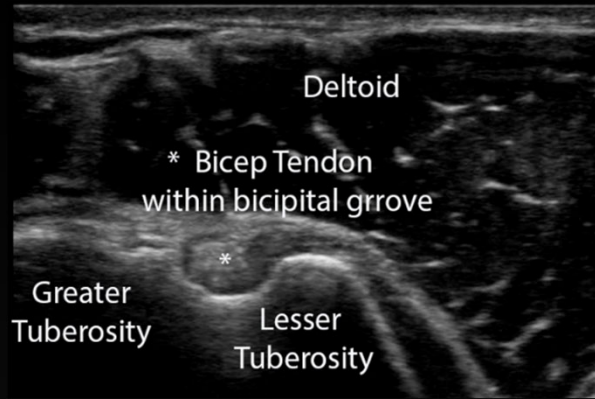


The blood supply to the LHB tendon occurs via the anterior humeral circumflex artery.

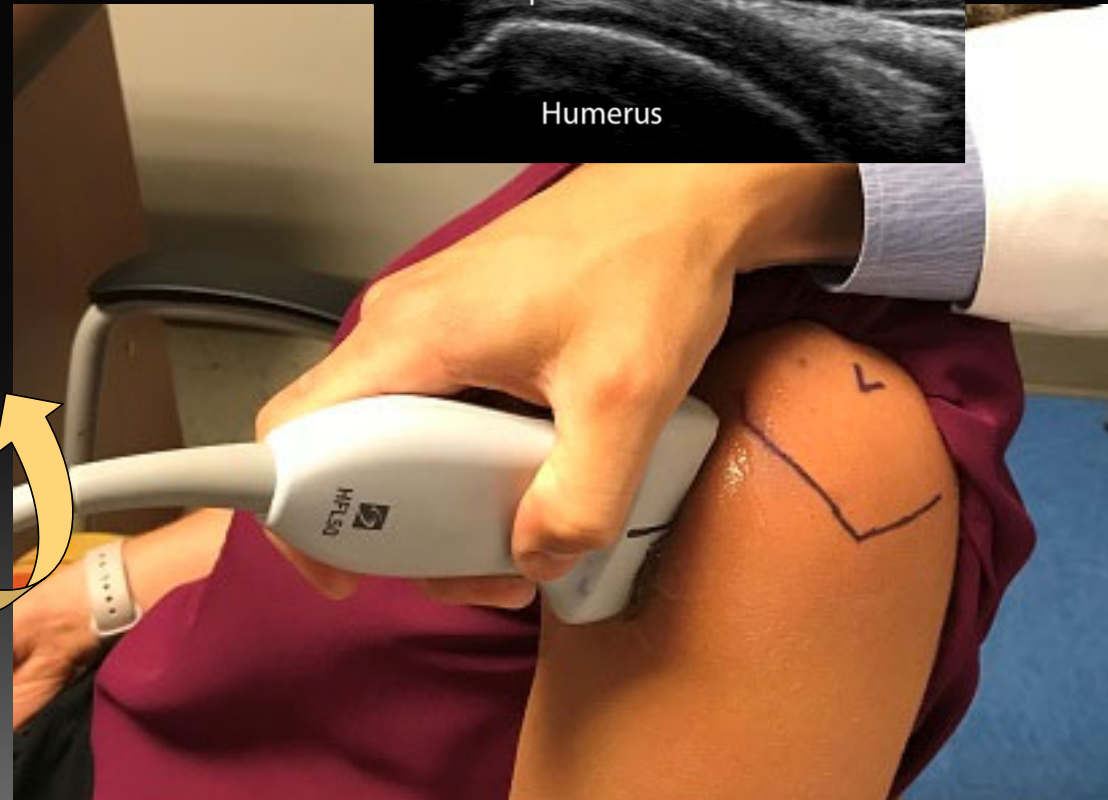
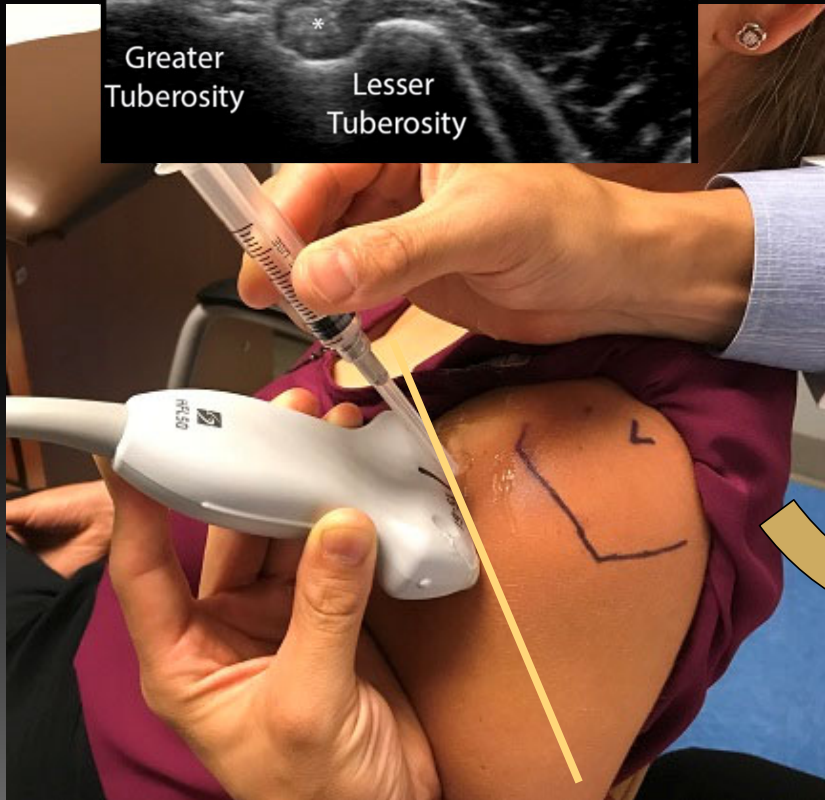
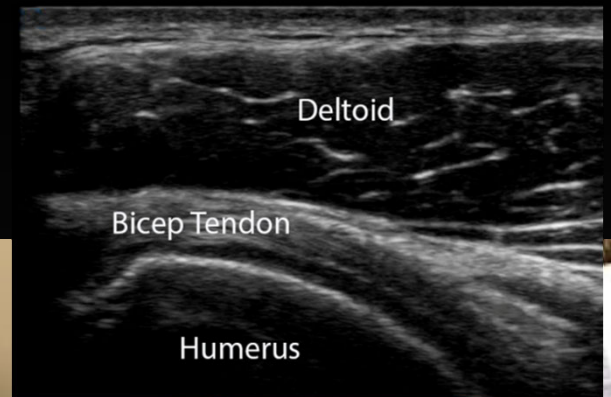
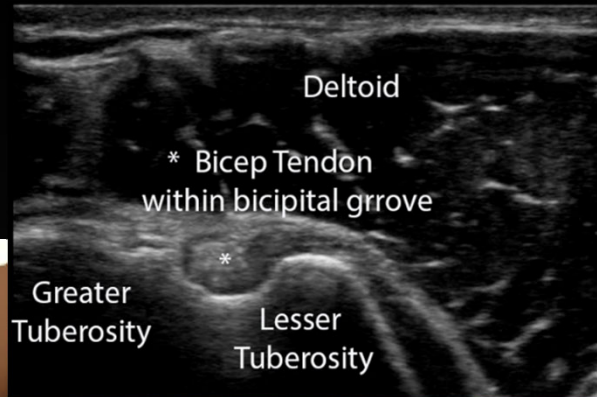
Biceps Brachii



Biceps Brachii



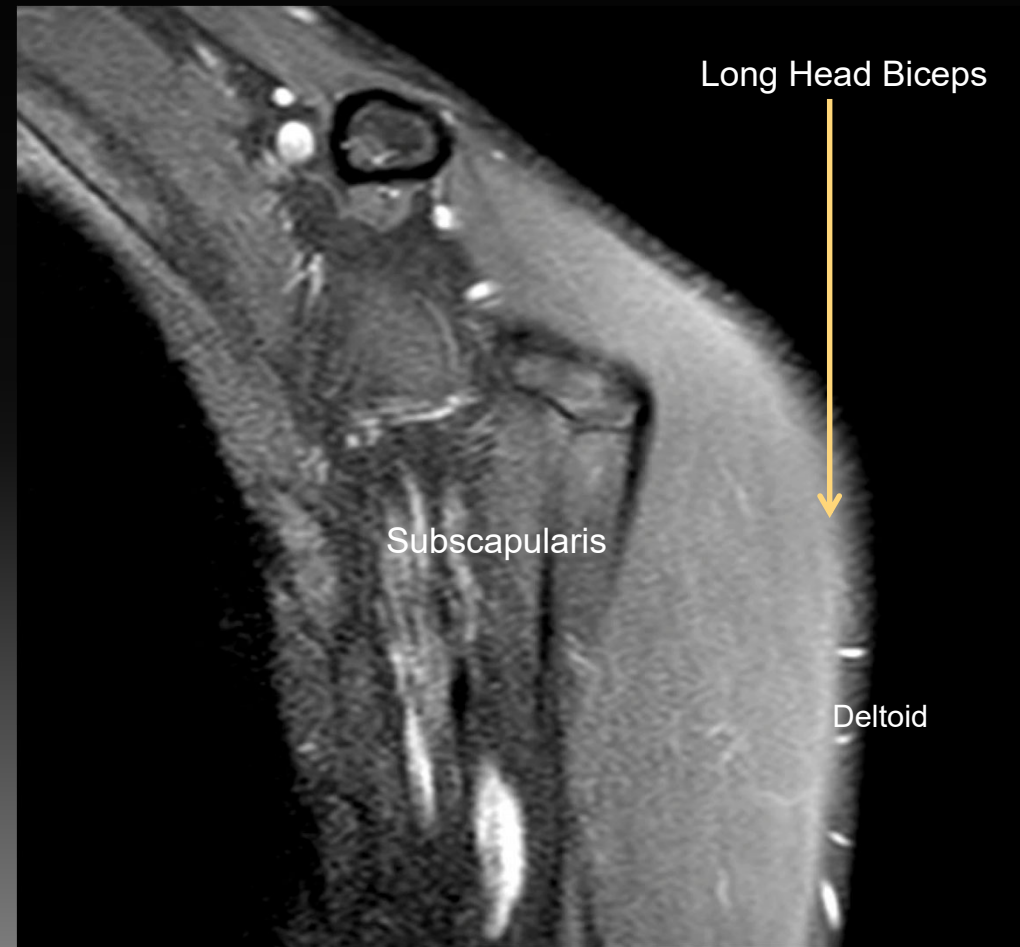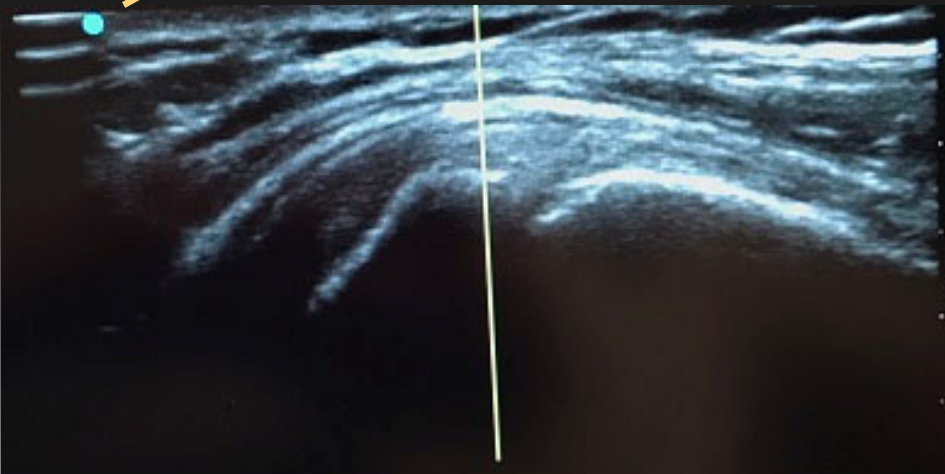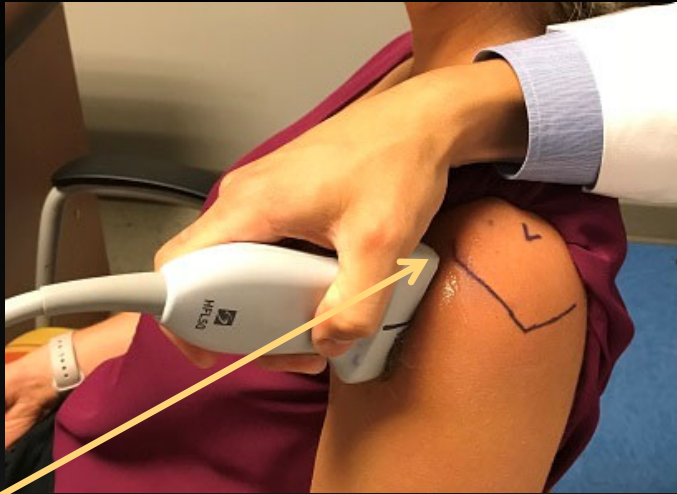
Biceps Brachii



Rotate 90 Degrees

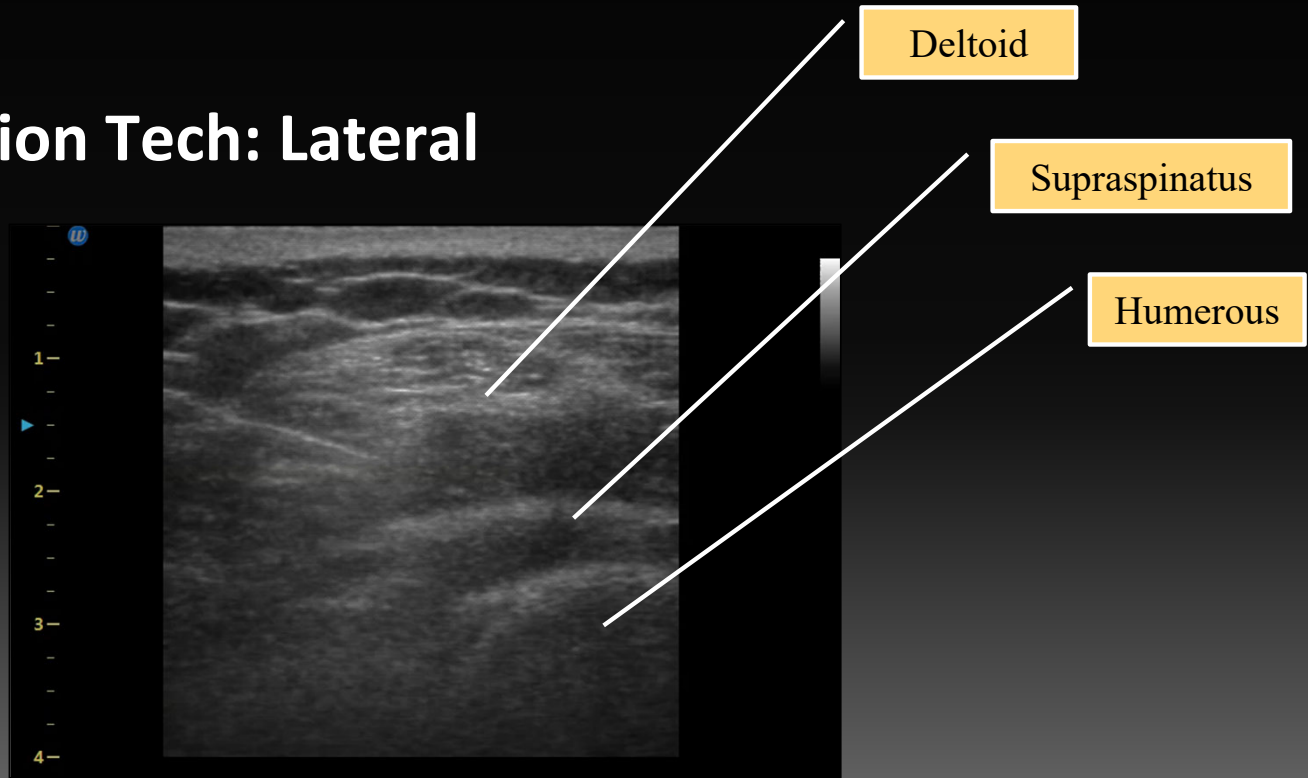
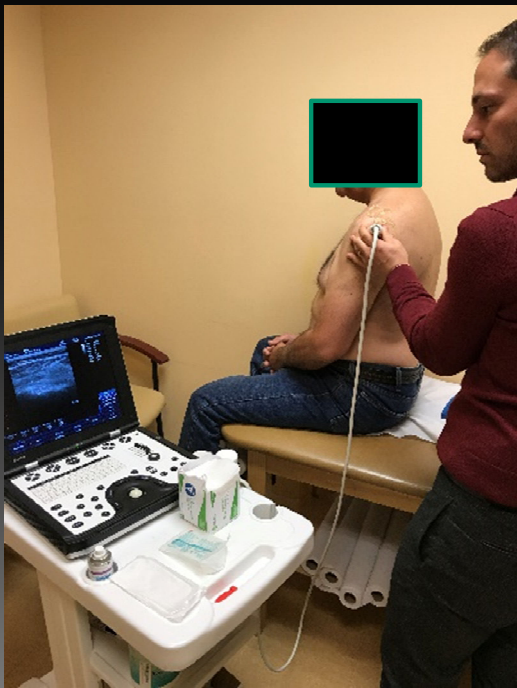

Biceps Brachii

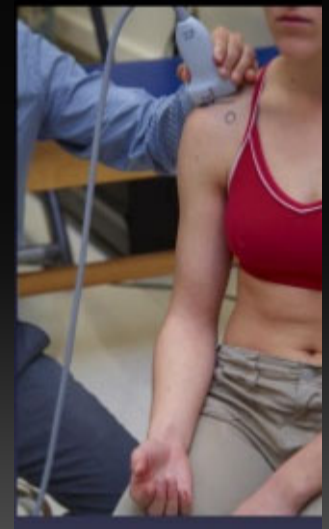
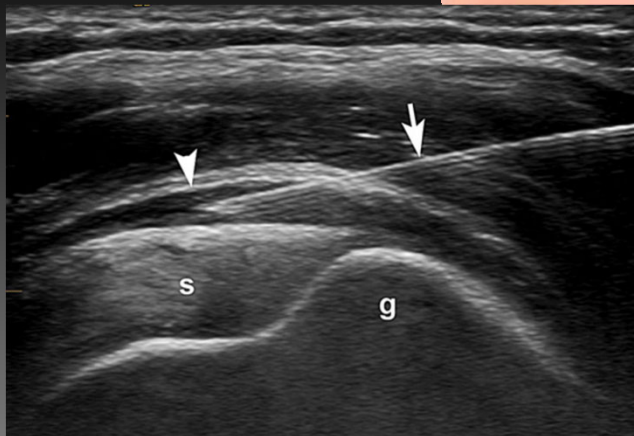
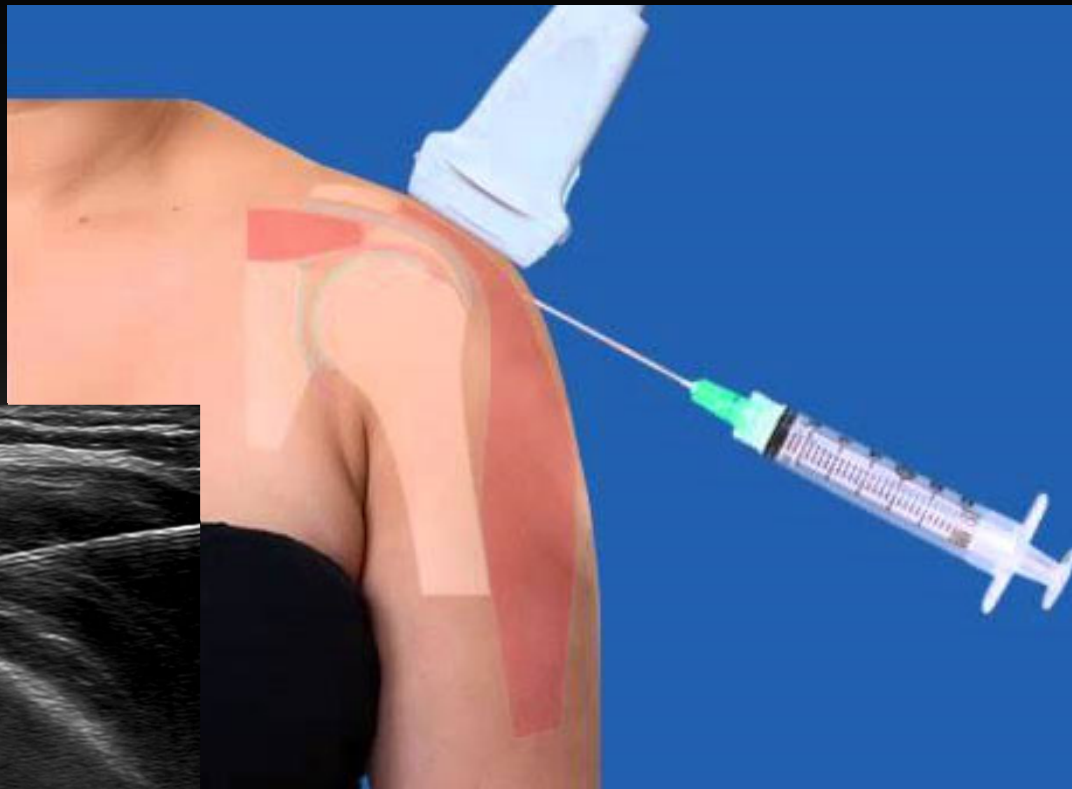
Subacromial Space Injection

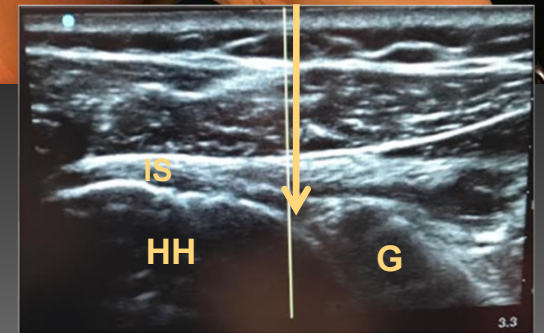
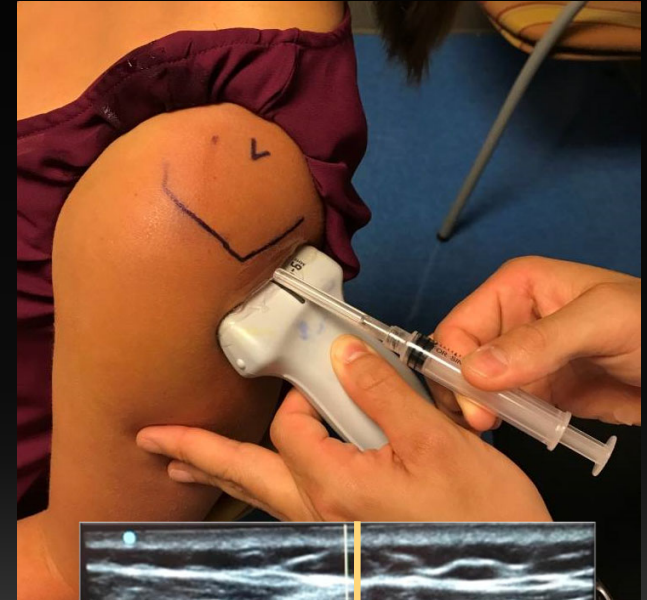
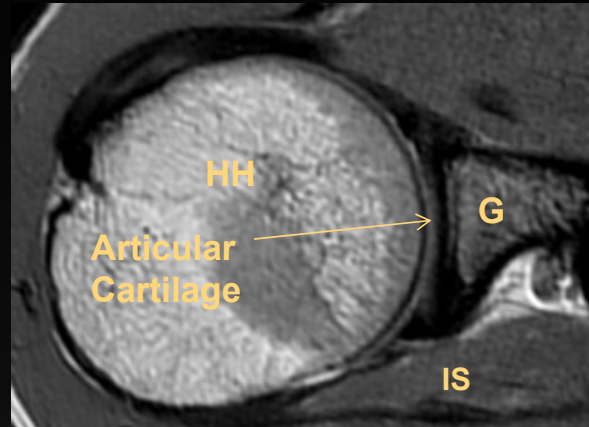
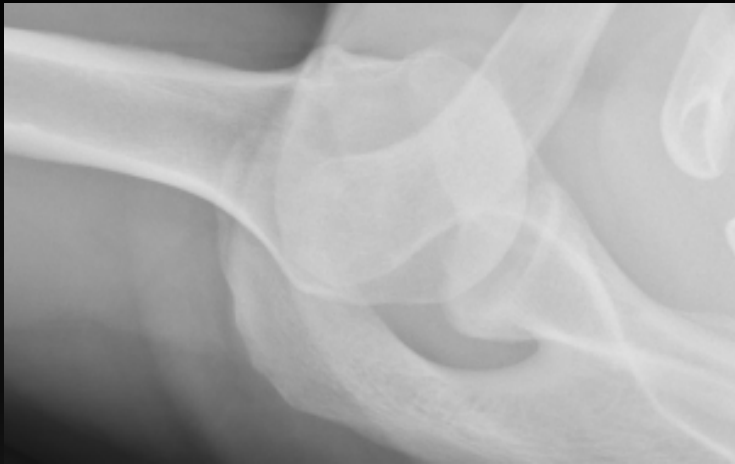- Alternative Injection Tech: Lateral



Injection Technique: Lateral entry point

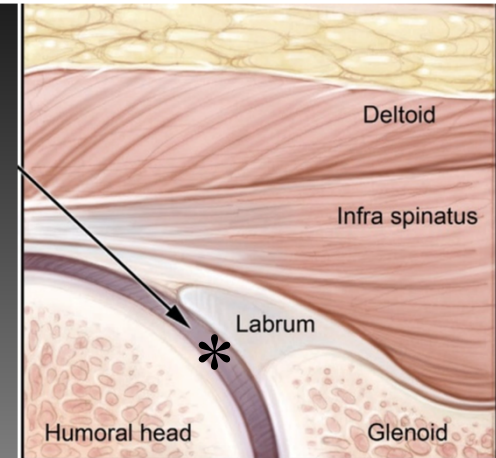
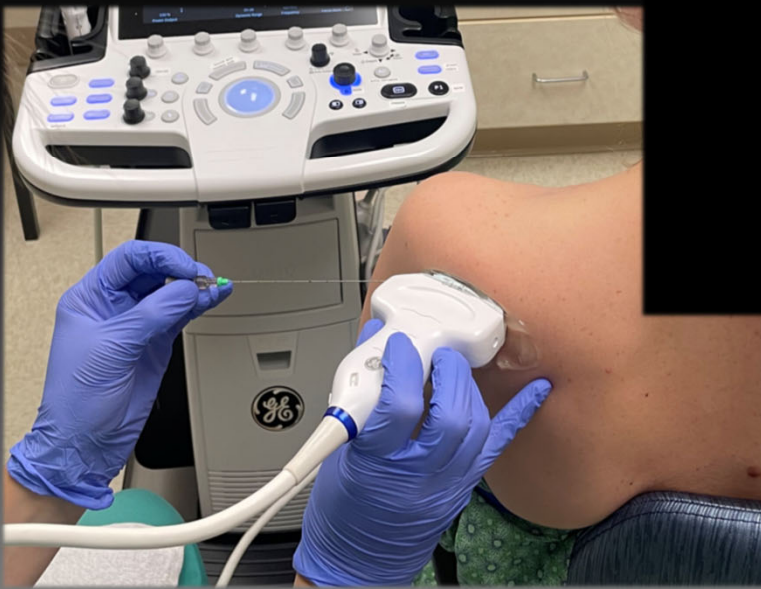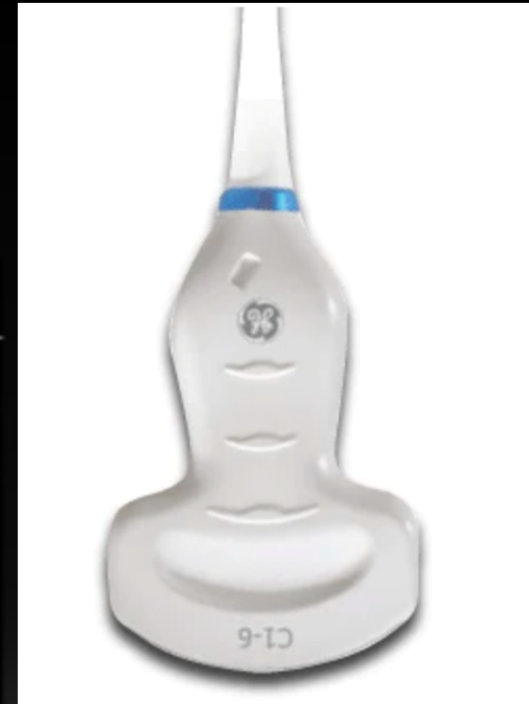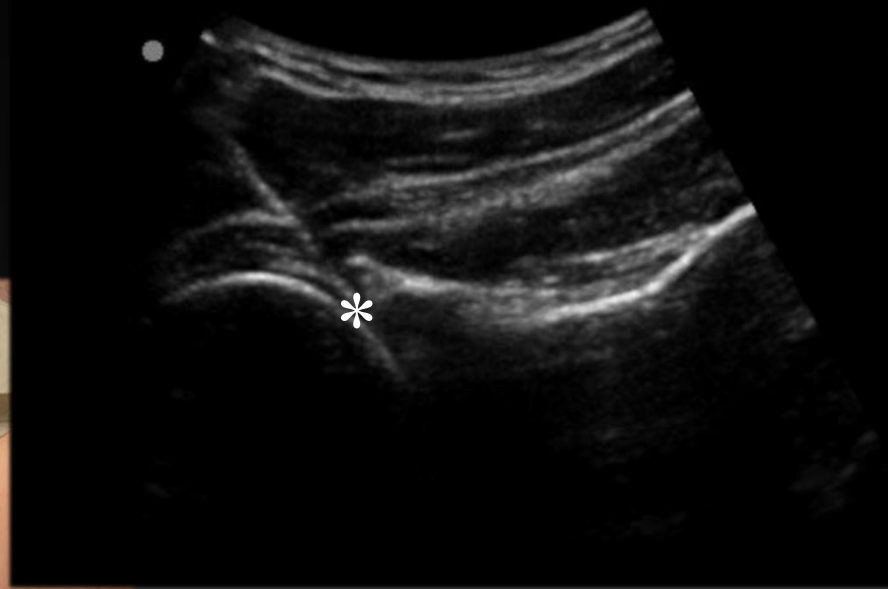


Glenohumeral Joint



GHJ Inj: A comparative study of US and fluoro-guided techniques “More successful on first attempt, less time consuming, less painful, no radiation and no iodine contrast when compared to fluoro-guided injections” - Rutten, M Et Al.

Glenohumeral Joint



Shoulder 13 Point Exam

Point 1: Transverse Long Head Biceps Tendon

Point 2: Longitudinal Long Head Biceps

Point 3: Transverse Subscap Tendon

Point 4: Longitudinal Subscap Tendon

Point 5: Coracoid, Longitudinal Subscap

Point 6: Longitudinal Anterior Supraspinatus

Point 7: Longitudinal Posterior Supraspinatus

Point 8: Transverse Anterior Supraspinatus

Point 9: Transverse Posterior Supraspinatus

Point 10: Longitudinal Infraspinatus Tendon

Point 11: Transverse Infraspinatus Tendon

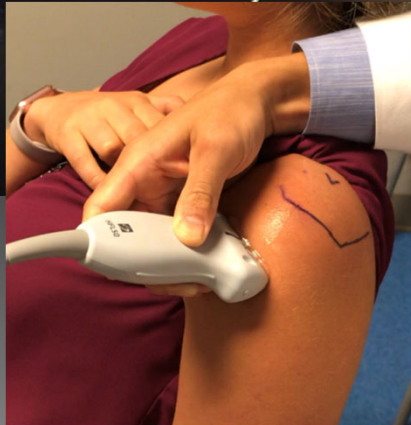
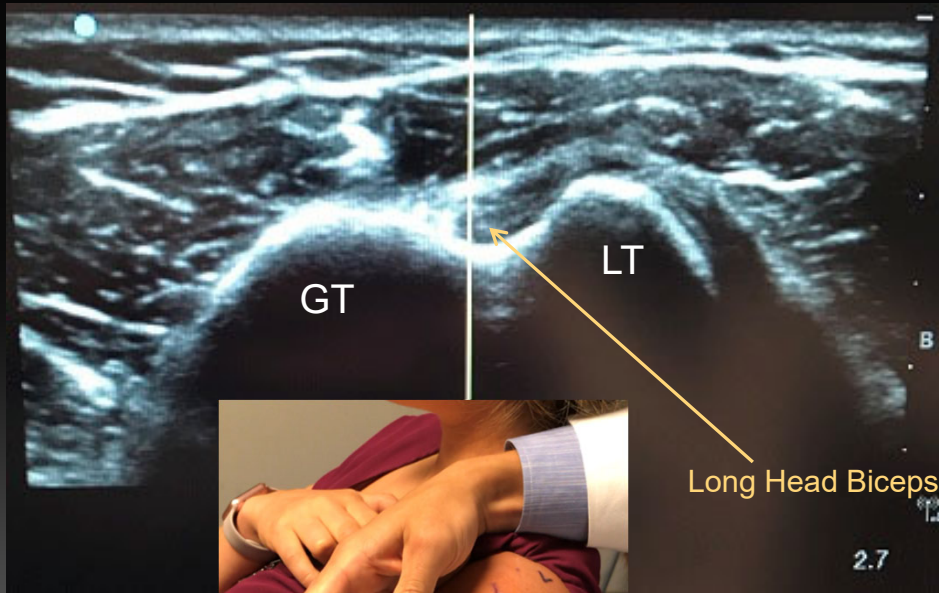
**Point 12: Posterior GH joint/ Long Intra
Tendon**

Point 13: Acromioclavicular Joint

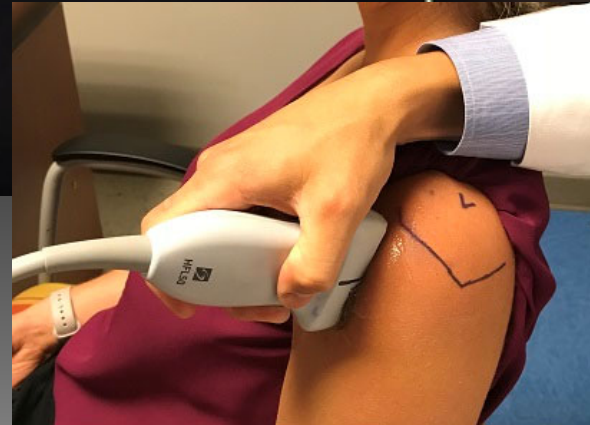
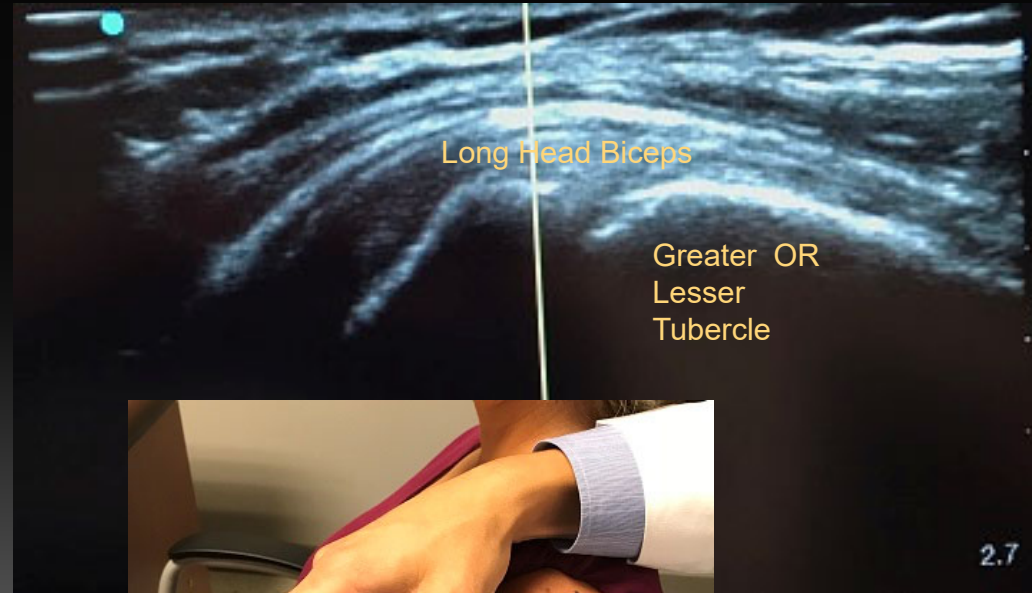


Shoulder 13 Point Exam

Point 1: Tranverse Long Head Biceps Tendon

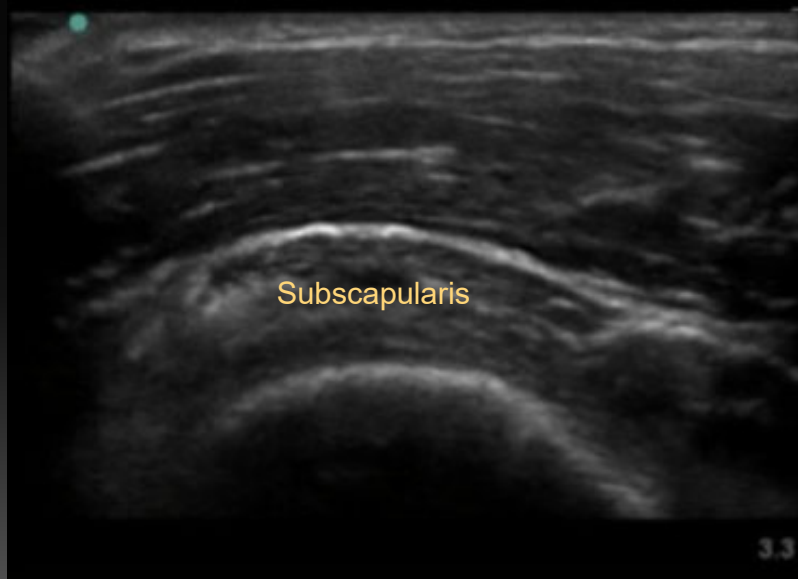


Point 2: Longitudinal Long Head Biceps



Shoulder 13 Point Exam


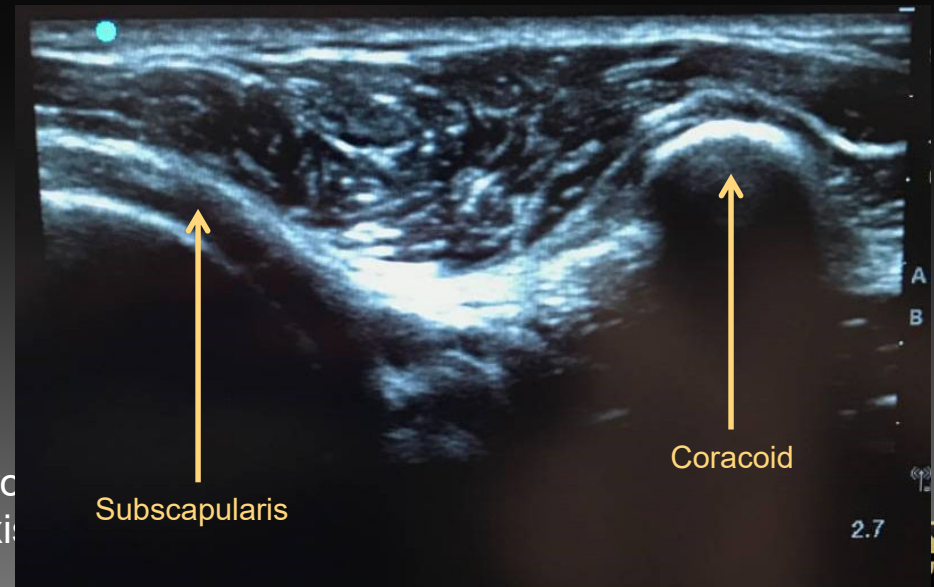
Point 3: Transverse Subscap Tendon



From short axis of biceps tendon evaluation, externally rotate shoulder and move probe medially, while probe maintained in short axis.

Point 4: Longitudinal Subscap Tendon

Point 5: Coracoid, Longitudinal Subscap

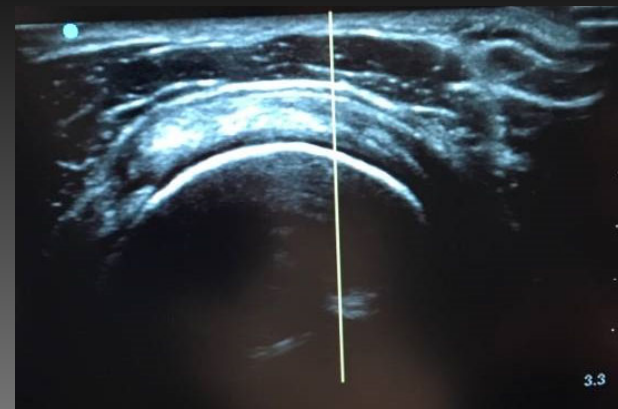
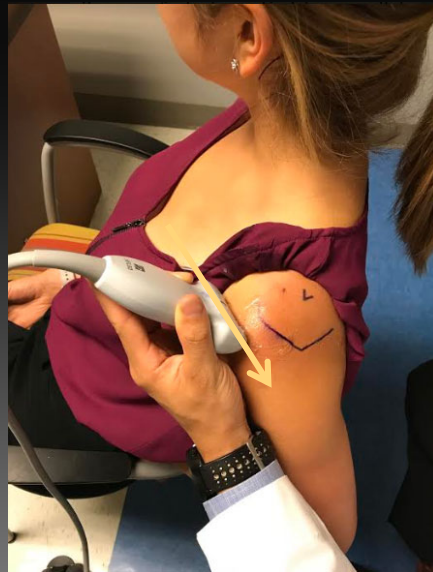
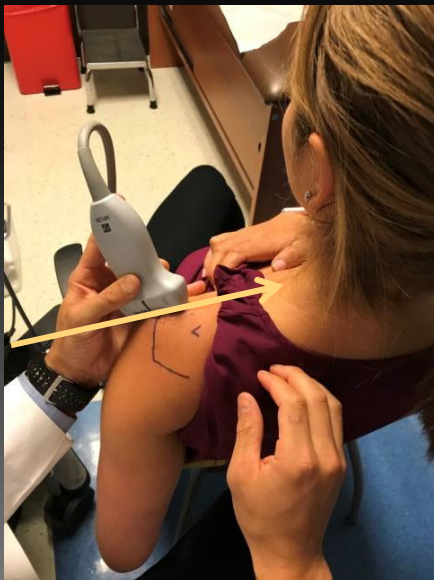
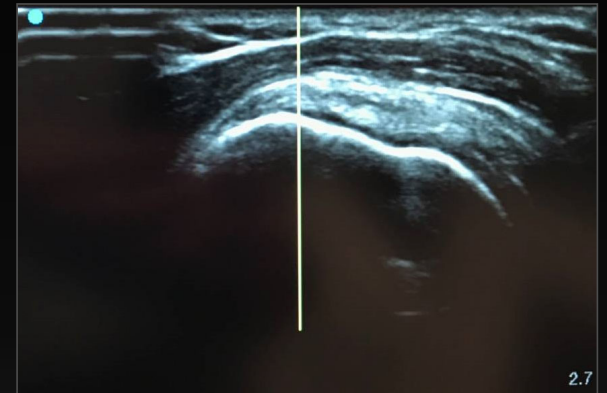Shoulder 13 Point Exam

Point 6/7: Longitudinal Ant/Post Supra

Point 8/9: Transverse Ant/Post Supra

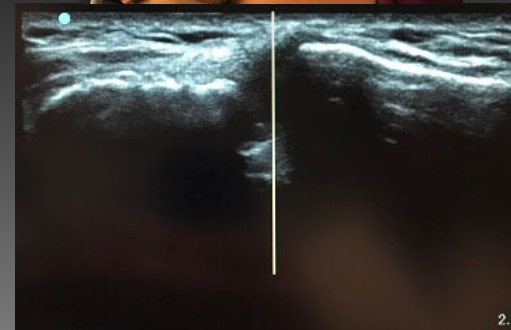
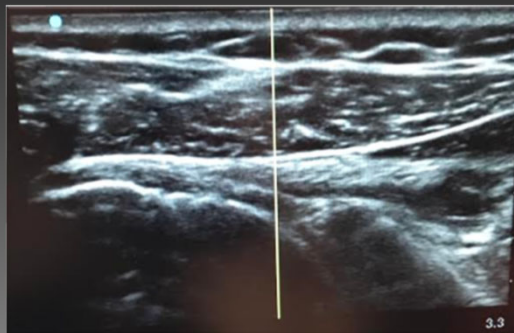
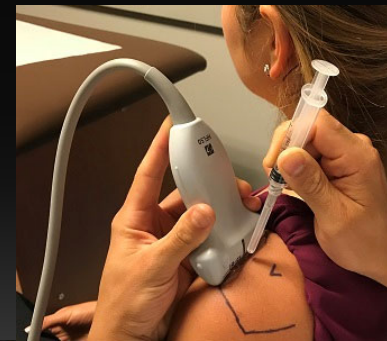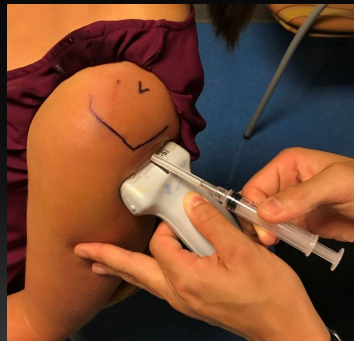
Point 10/11: Long/Transverse Infra Tendon

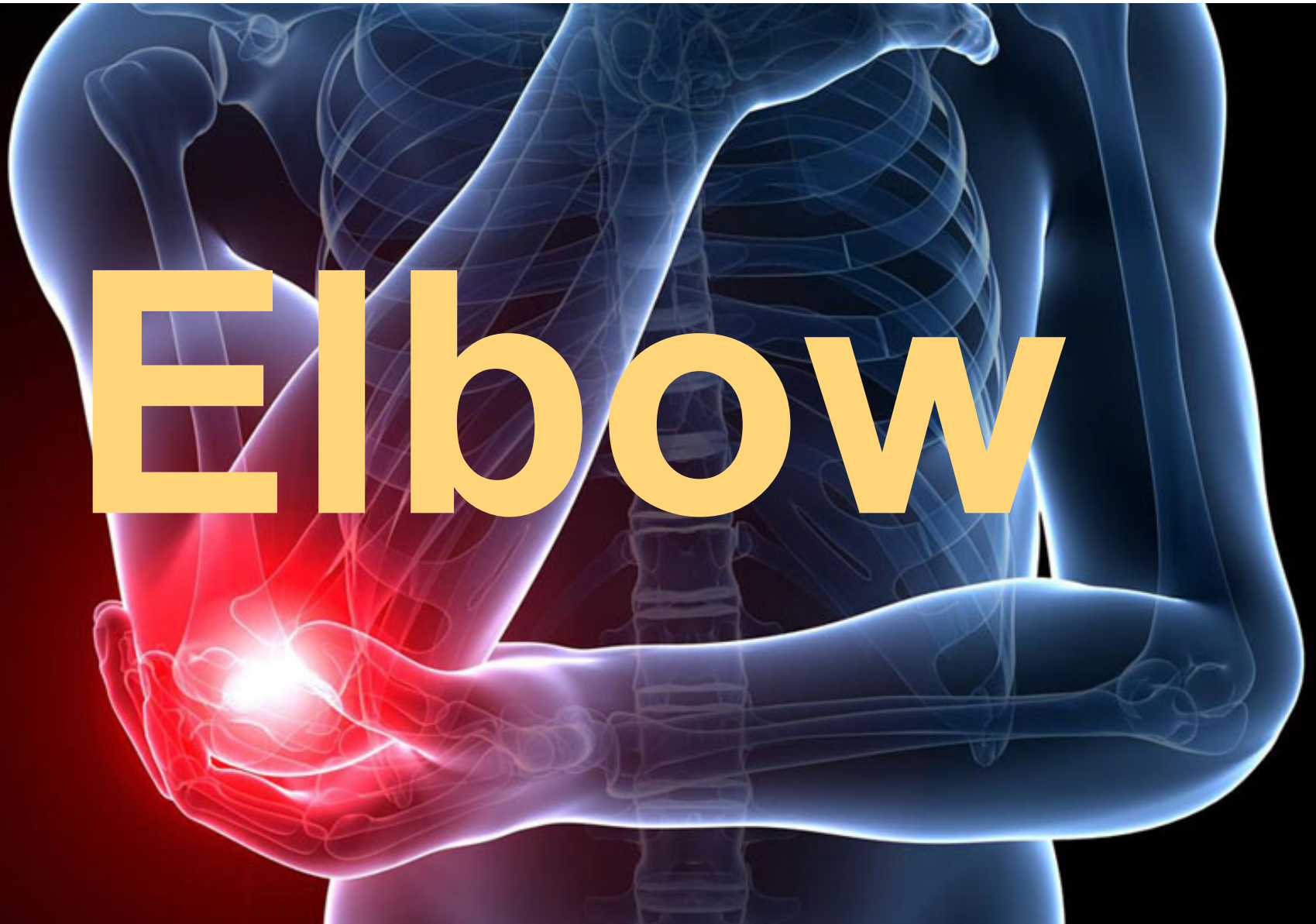

Shoulder 13 Point Exam

Point 12: Posterior GH joint/ Long Intra Tendon

Point 13: Acromioclavicular Joint



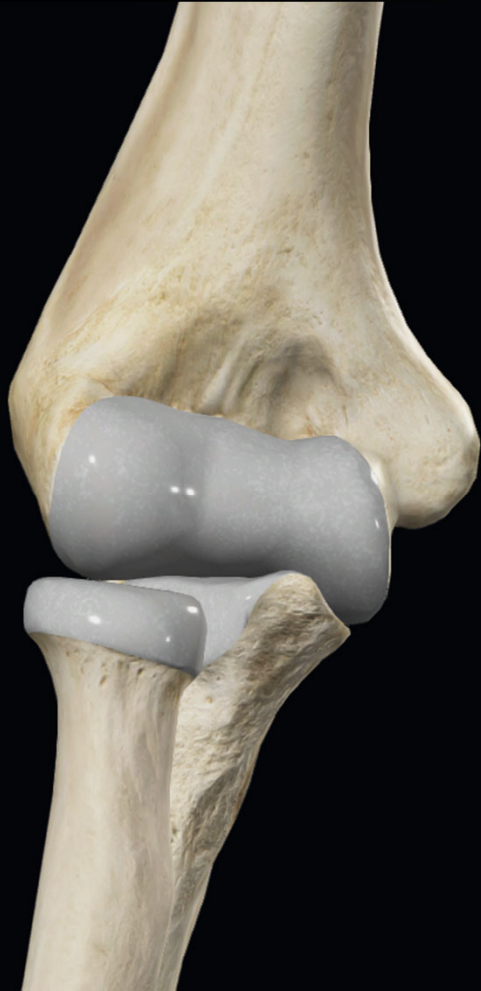

Elbow

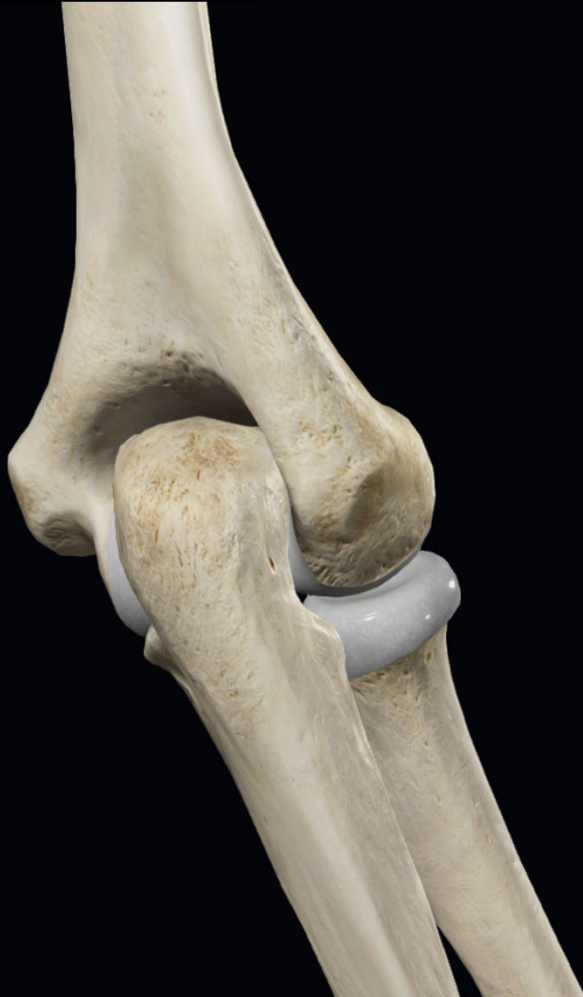Lateral Epicondyle Elbow Injections



Lateral Epicondyle Elbow Injections



Lateral Epicondyle Elbow Injections



Lateral Epicondyle Elbow Injections



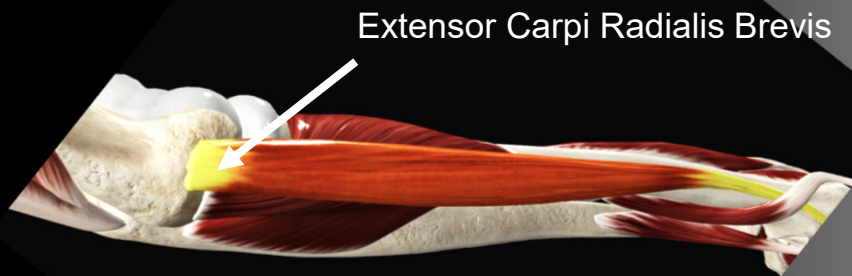
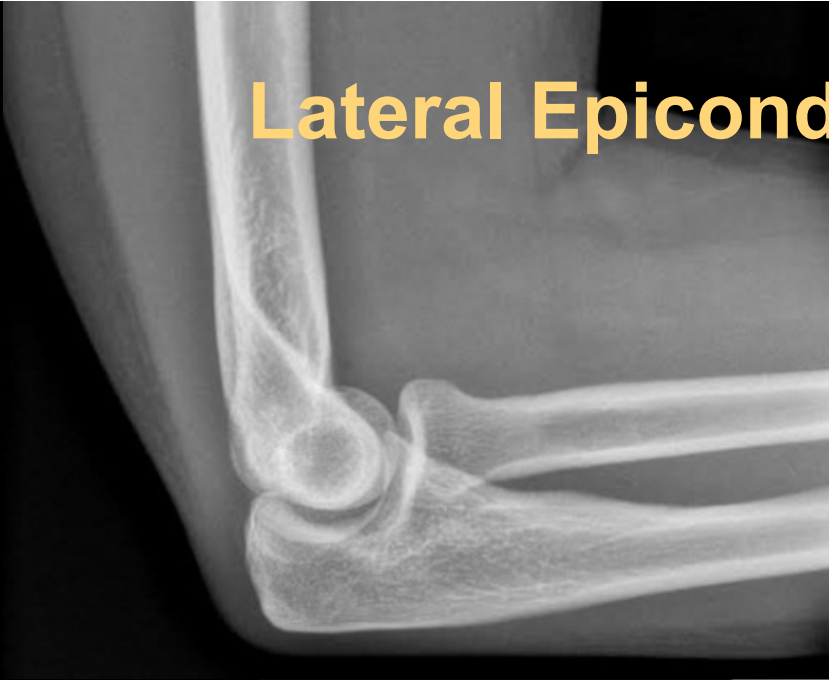Extensor Carpi Radialis Brevis

Lateral Epicondyle Elbow Injections

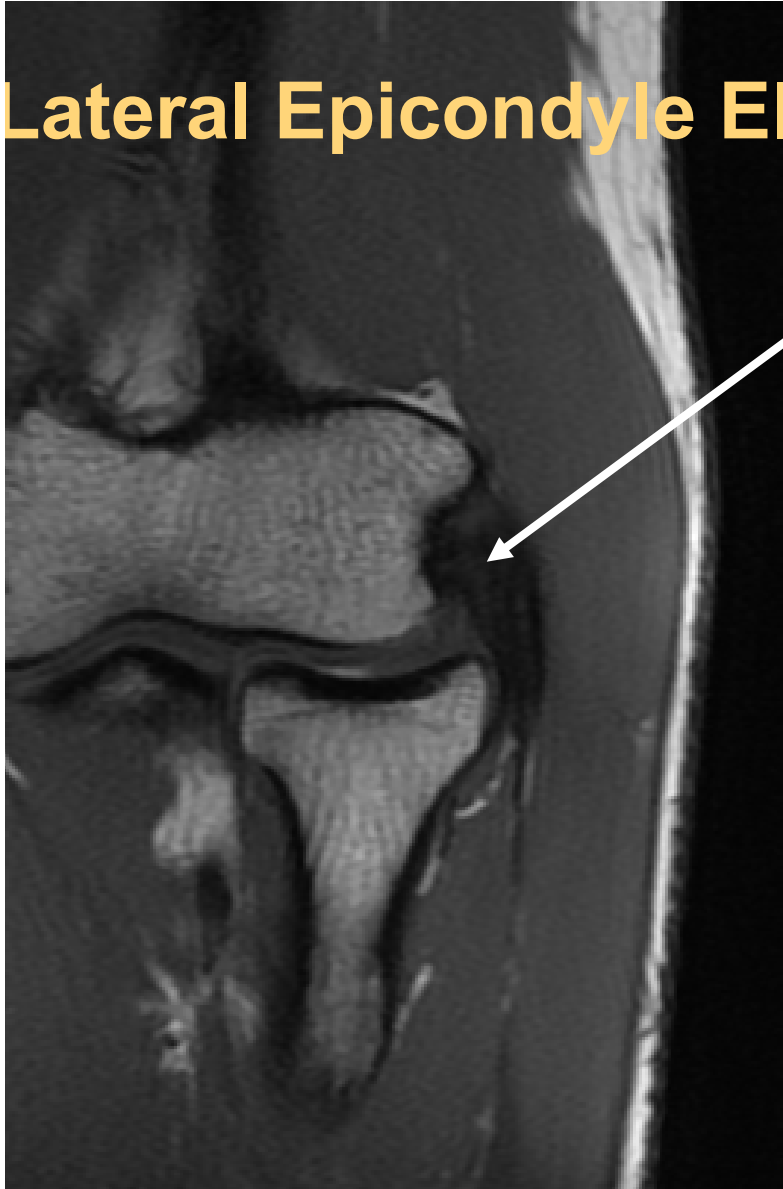Extensor Carpi Radialis Brevis



Lateral Epicondyle Elbow Injections

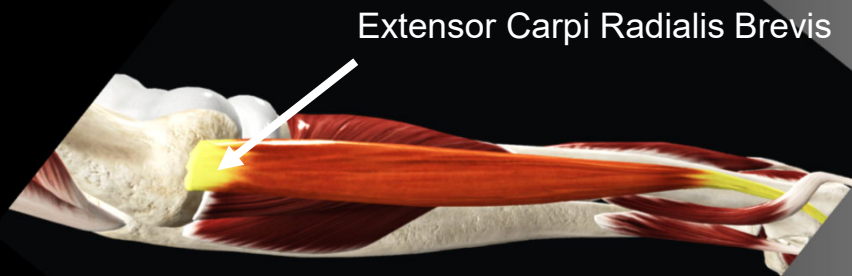


Lateral Epicondyle Elbow Injections

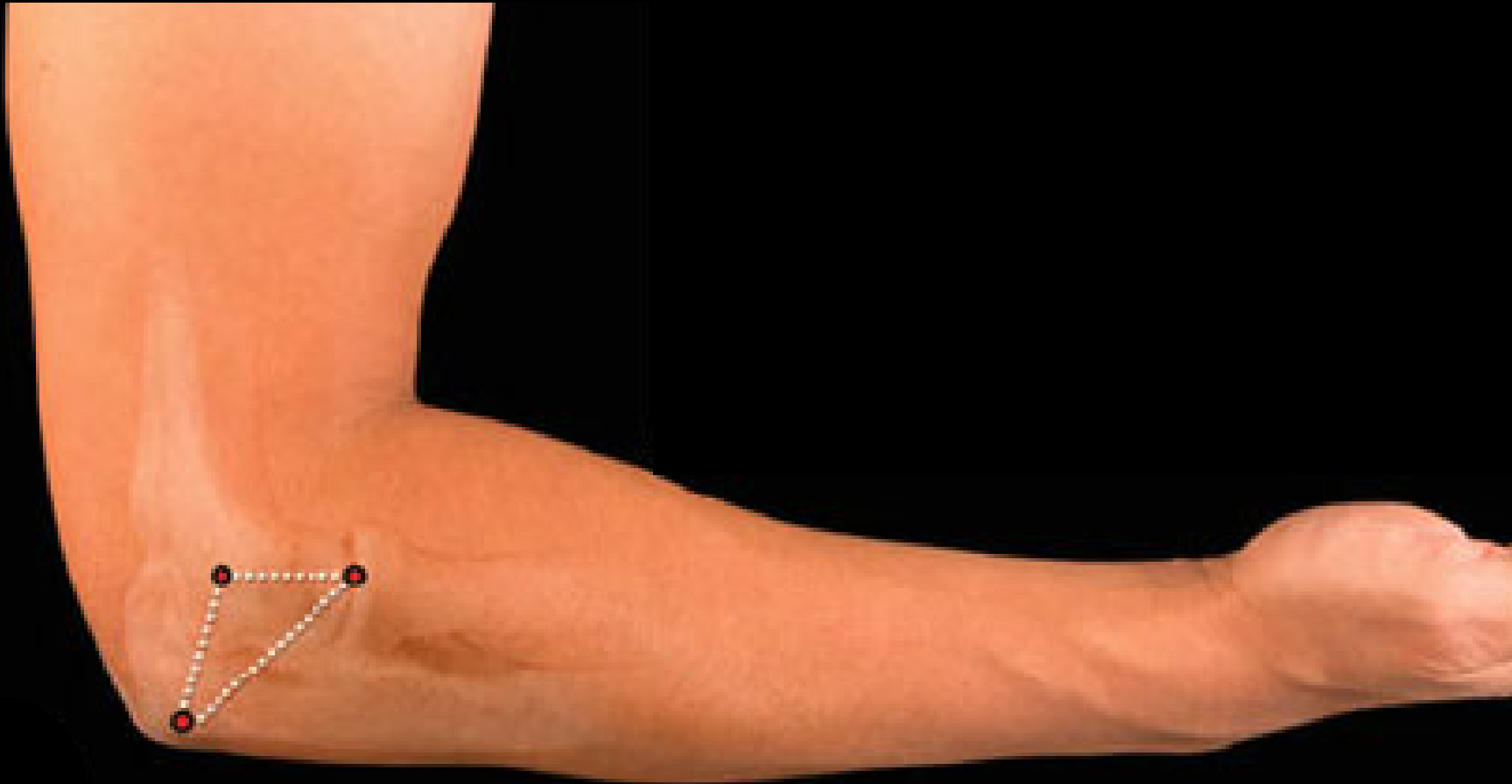

Extensor Carpi Radialis Brevis

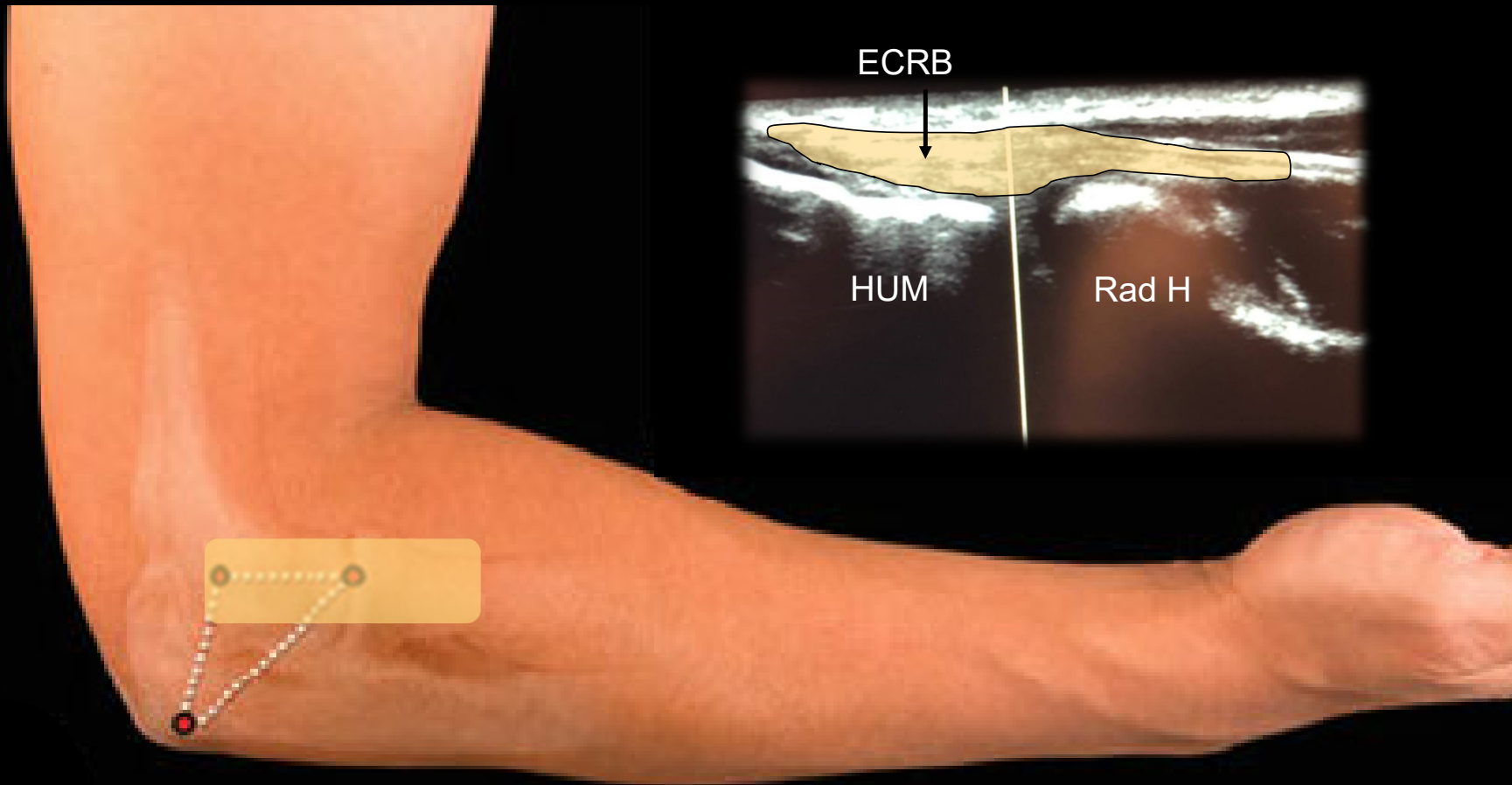
Lateral Epicondyle Elbow Injections



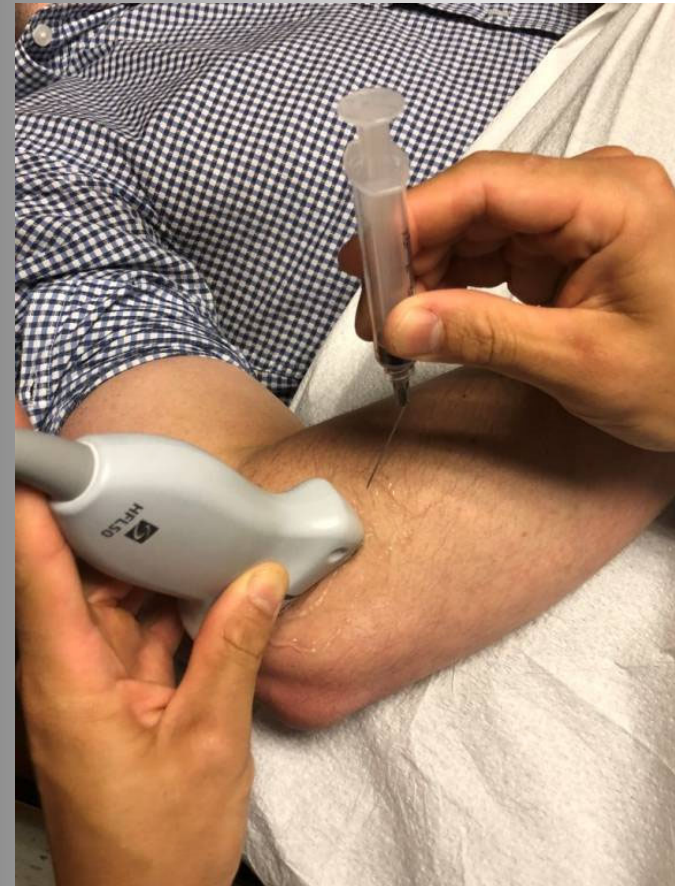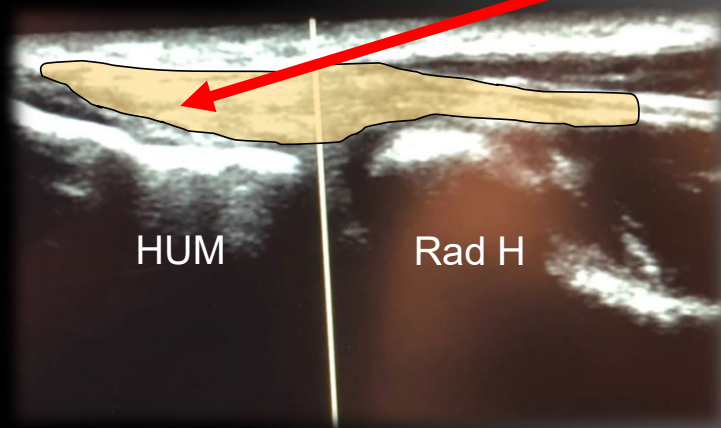
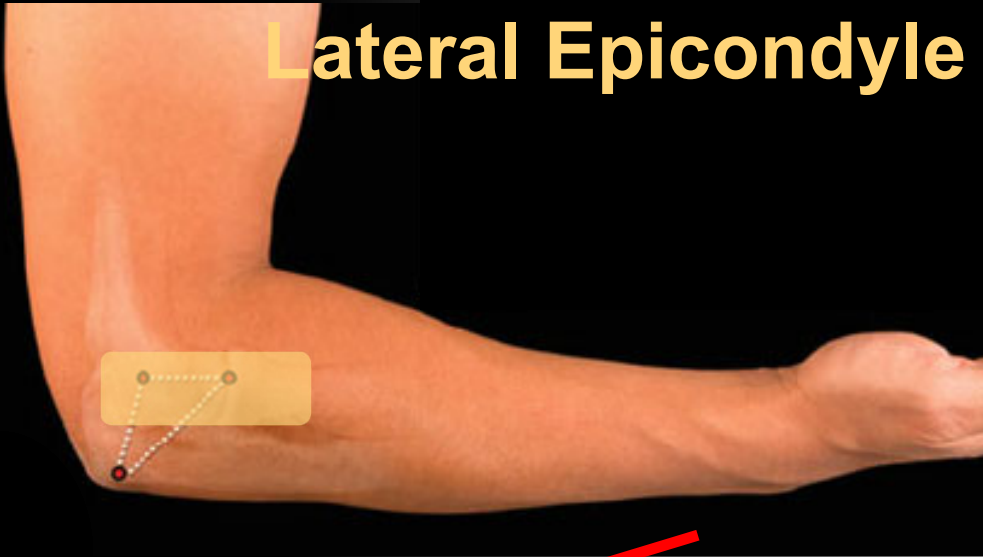Lateral Epicondyle Elbow Injections



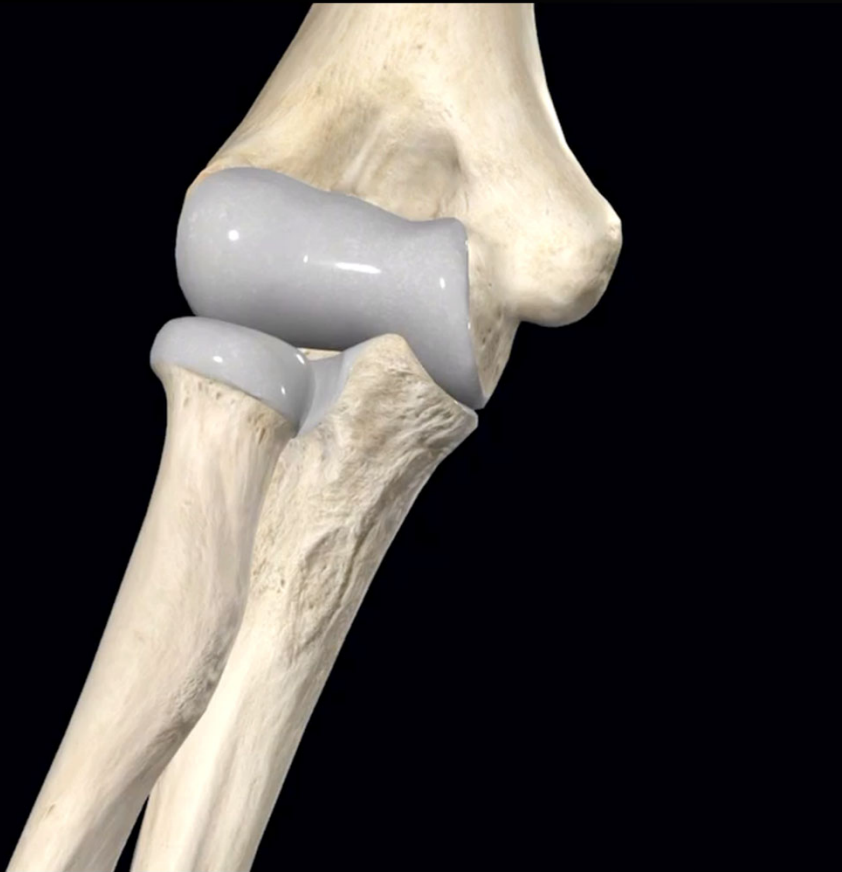Lateral Epicondyle Elbow Injections



Lateral Epicondyle Elbow Injections

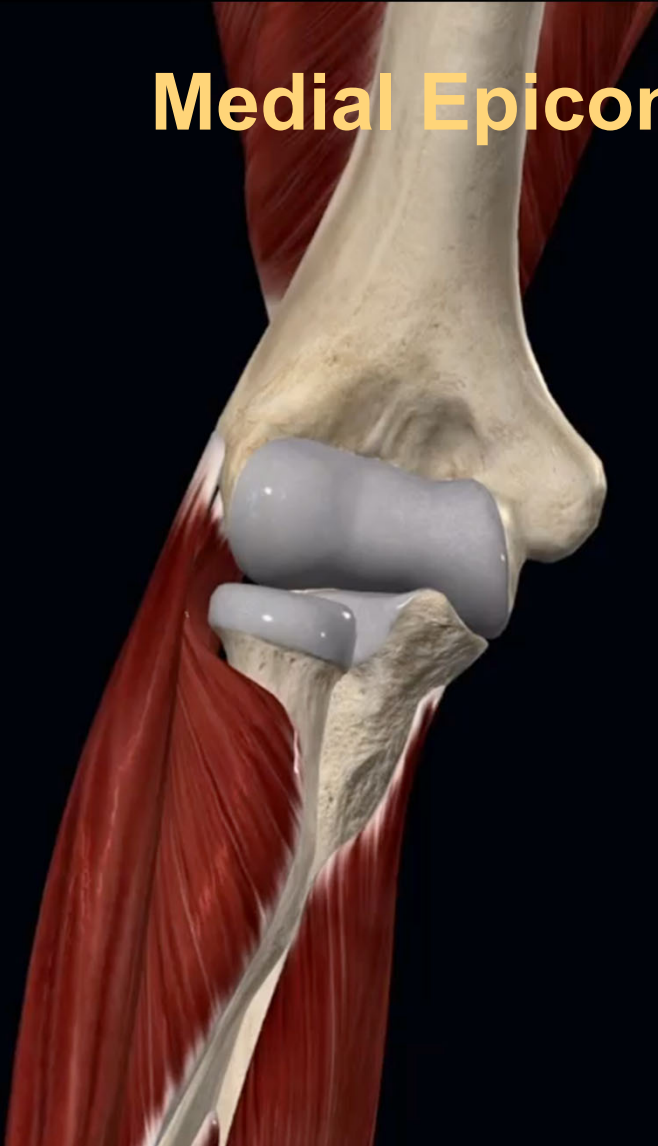


Medial Epicondyle Elbow Injections

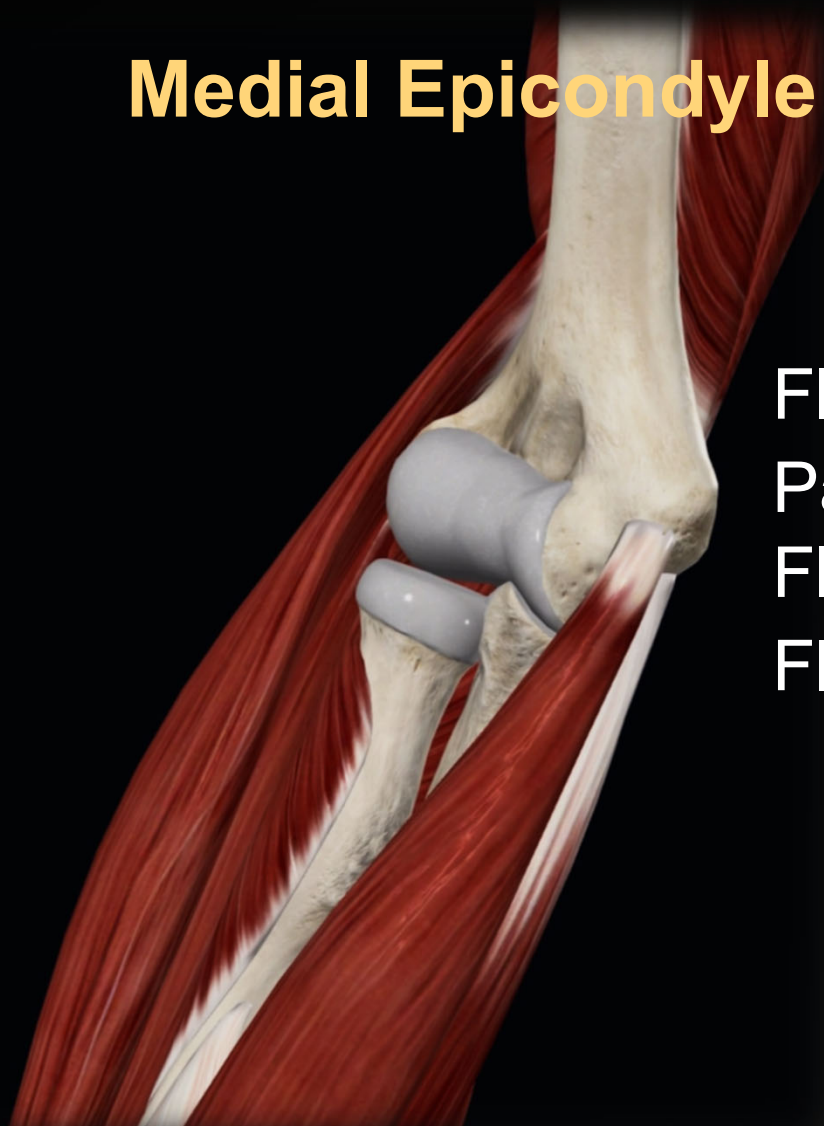


Medial Epicondyle Elbow Injections

Flexor Carpi Radialis
Palmaris Longus
Flexor Carpi Ulnaris
Flexor Digitorum Superficialis



Medial Epicondyle Elbow Injections



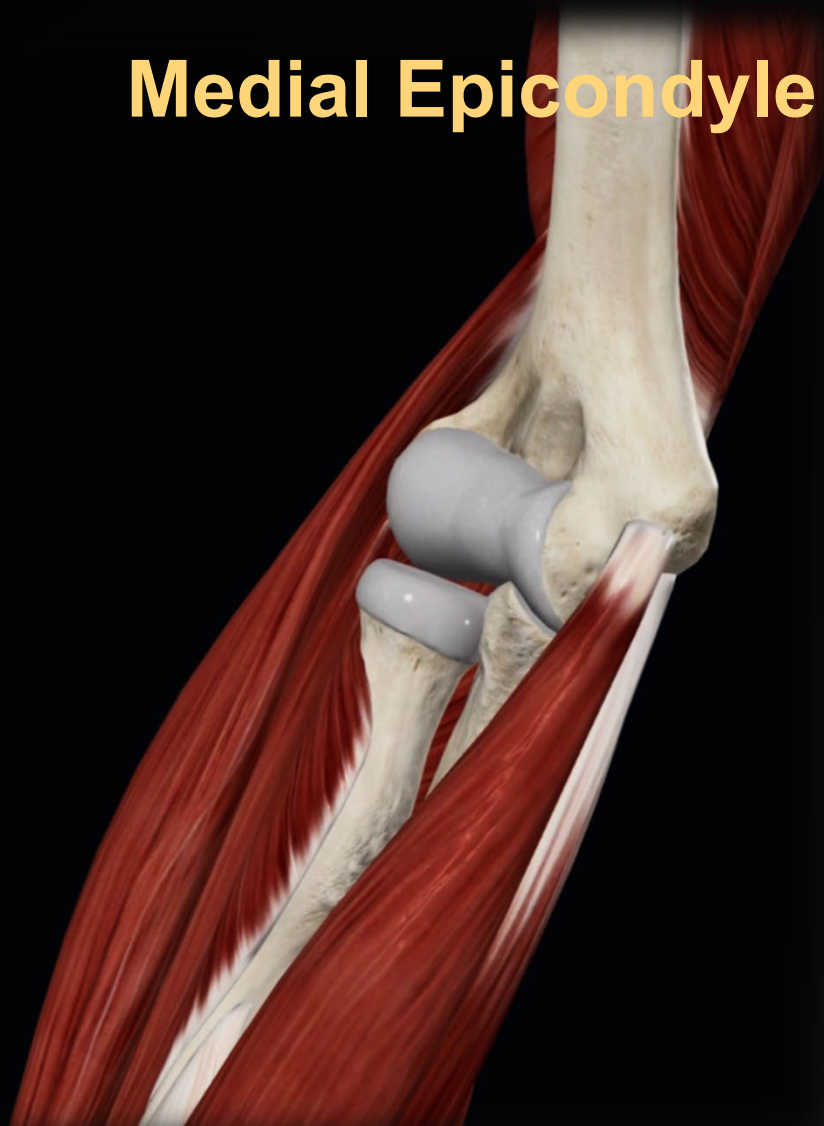Flexor Carpi Radialis

Palmaris Longus

Flexor Carpi Ulnaris

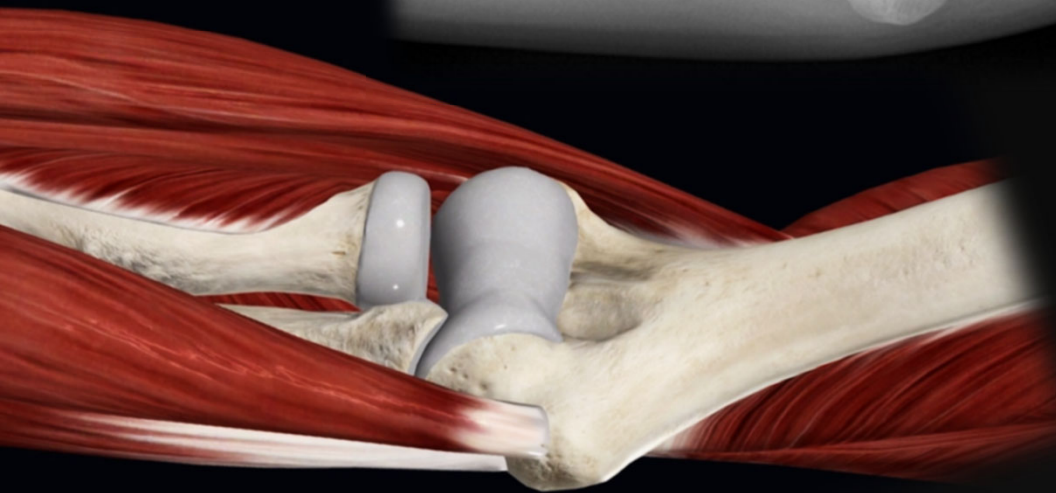
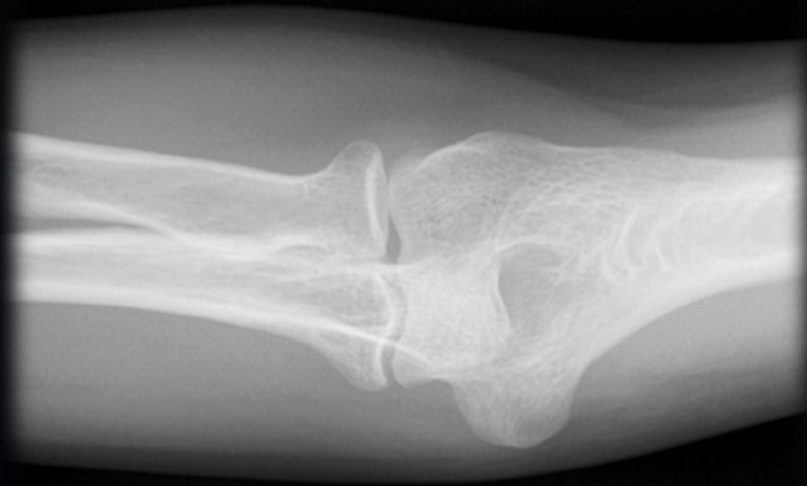Flexor Digitorum Superficialis

Medial Epicondyle Elbow Injections

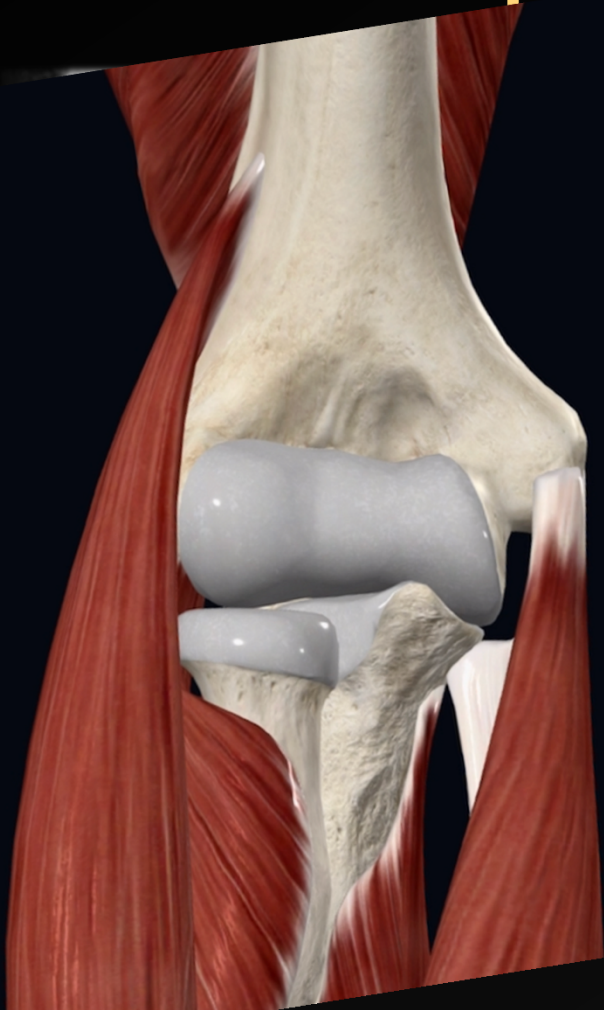

Common Flexor Tendon

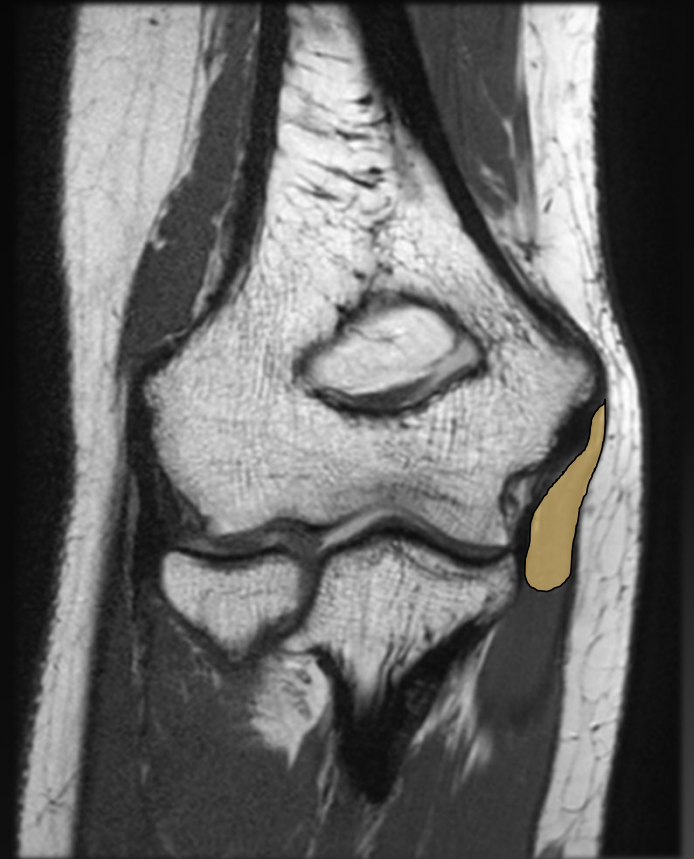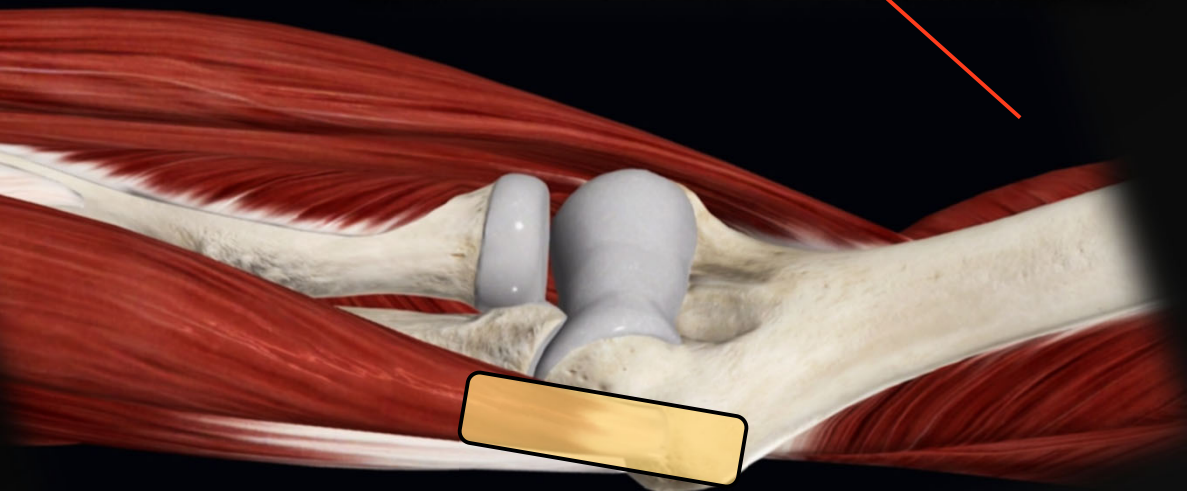
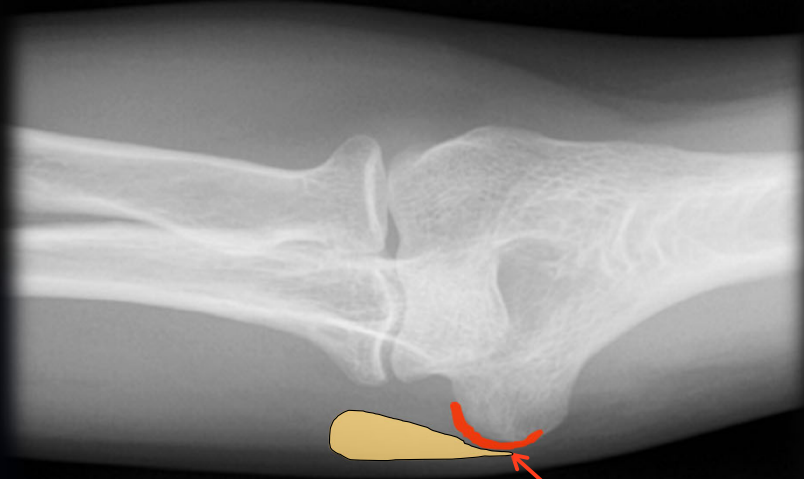
Medial Epicondyle Elbow Injections



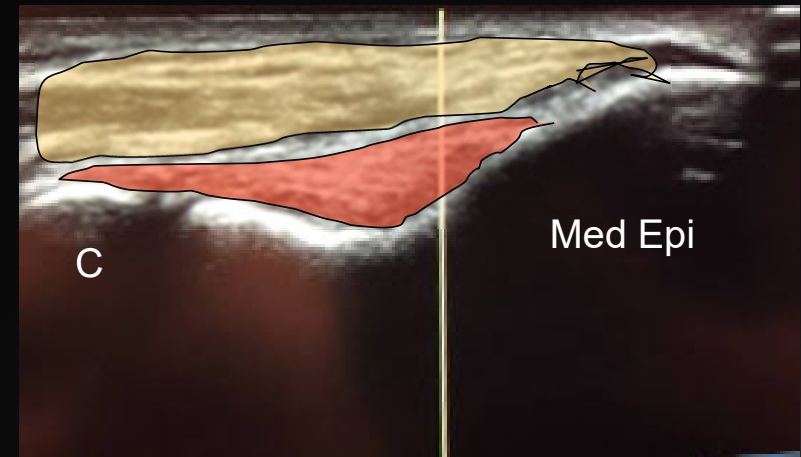
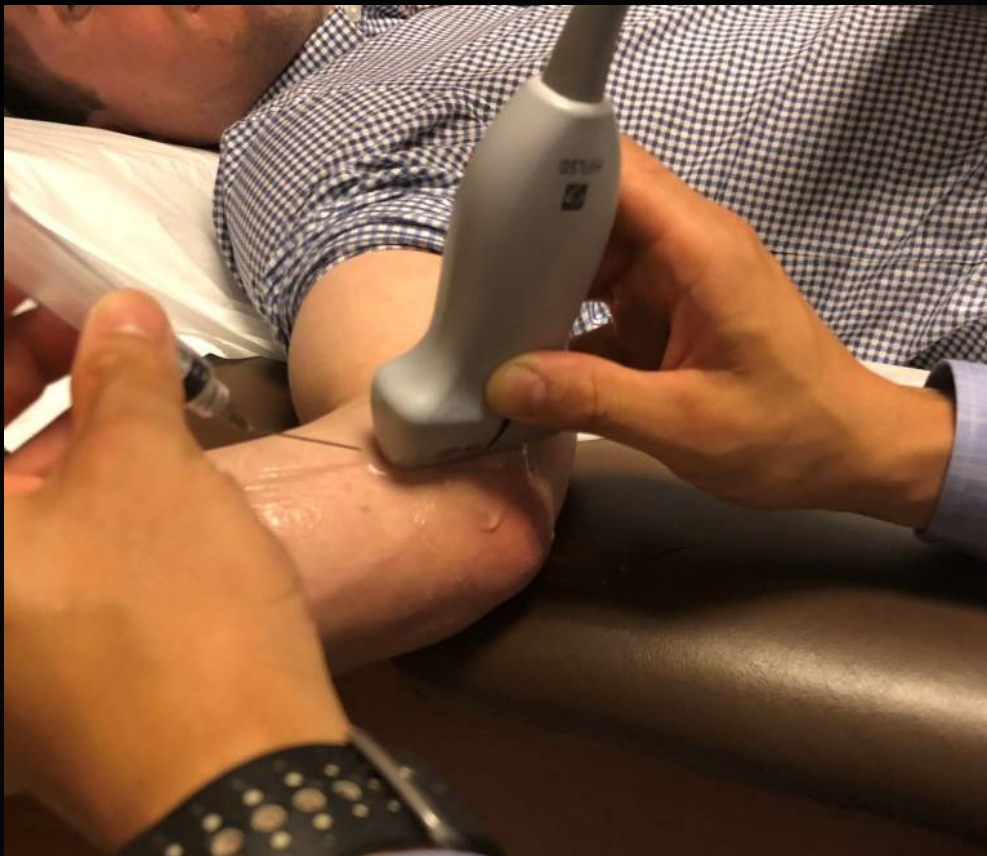Medial Epicondyle Elbow Injections



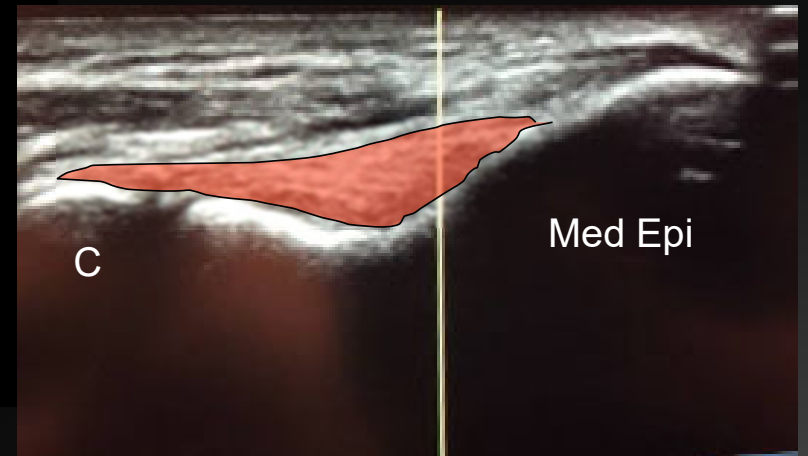
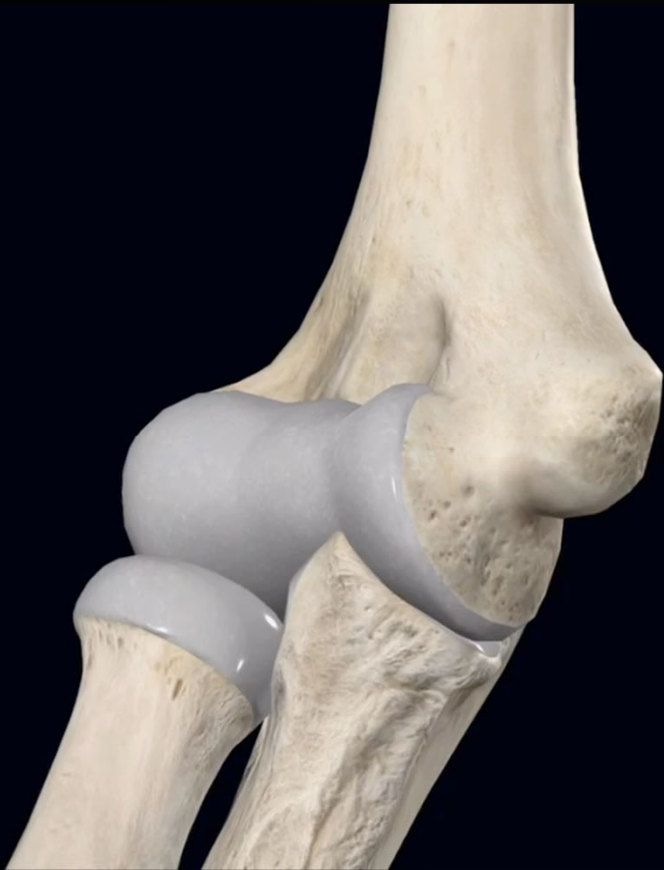Medial Epicondyle Elbow Injections



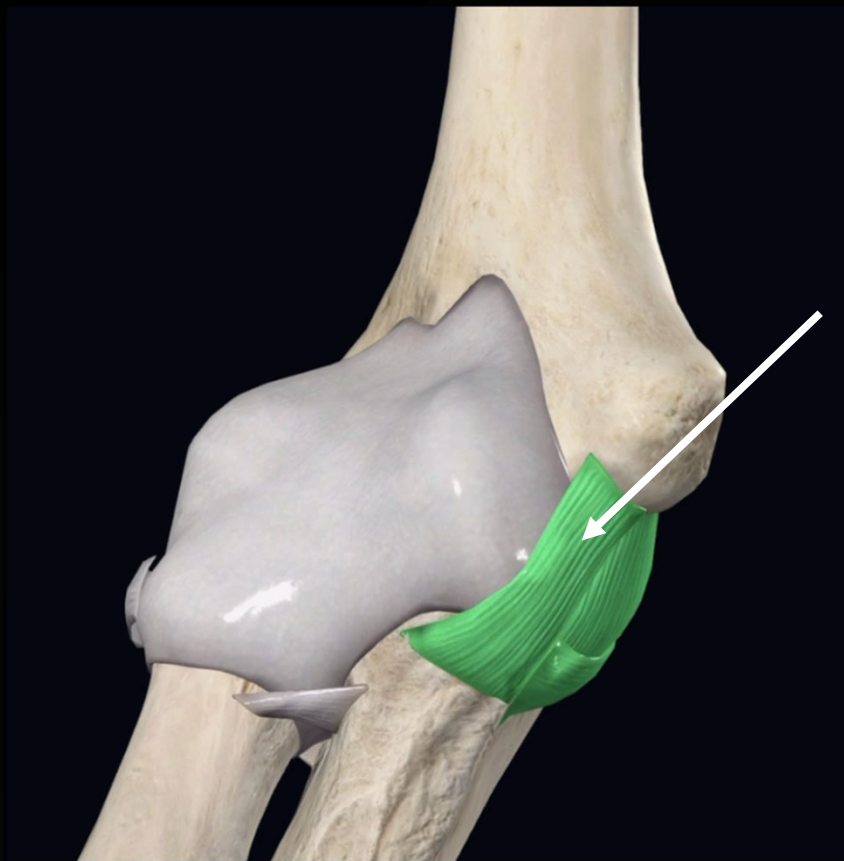
Medial Epicondyle Elbow Injections



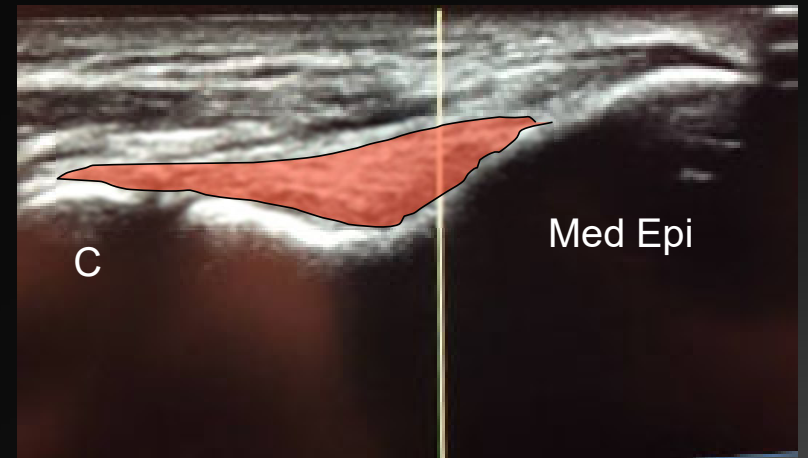
Ulnar Collateral Ligament Elbow Injections



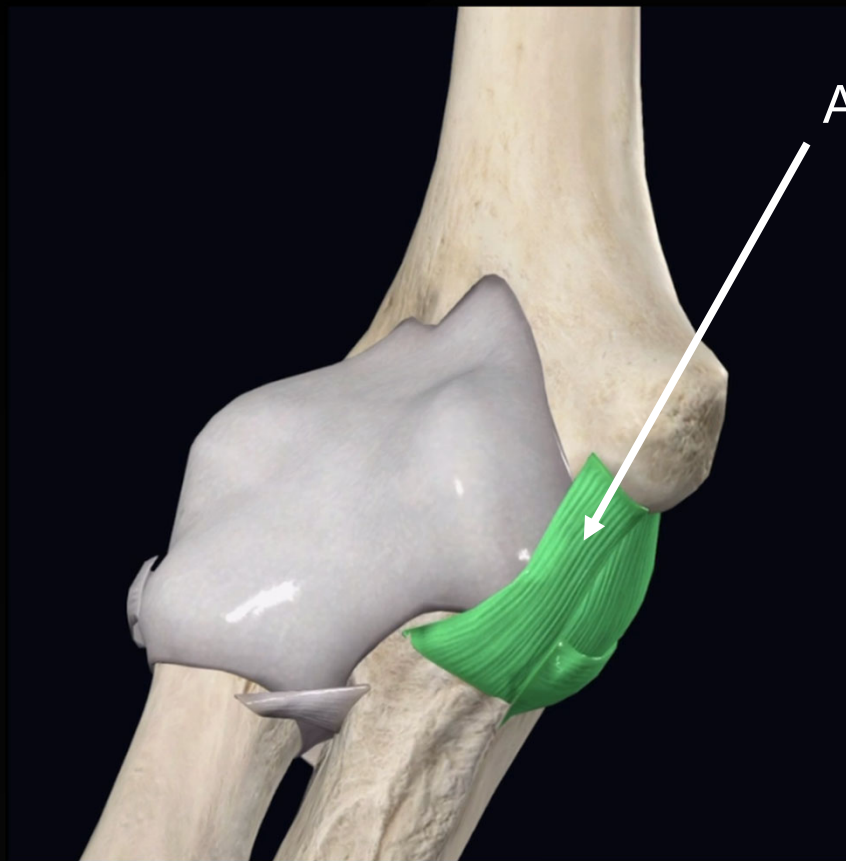
Ulnar Collateral Ligament Elbow Injections



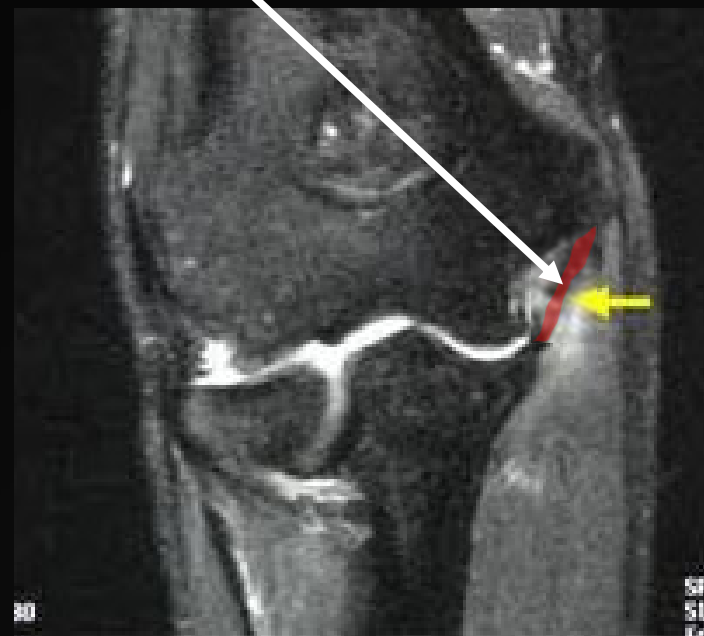Anterior Band of UCL



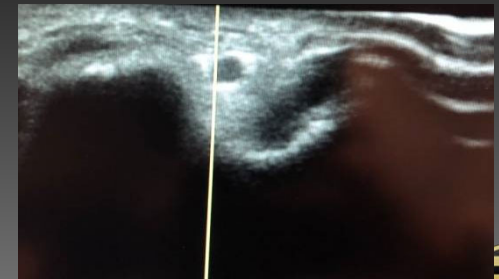
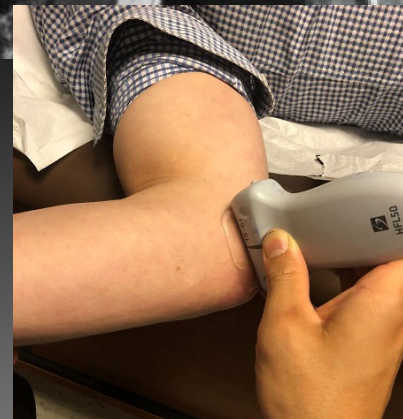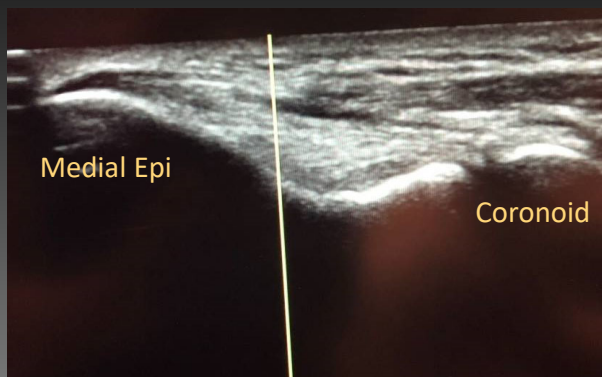
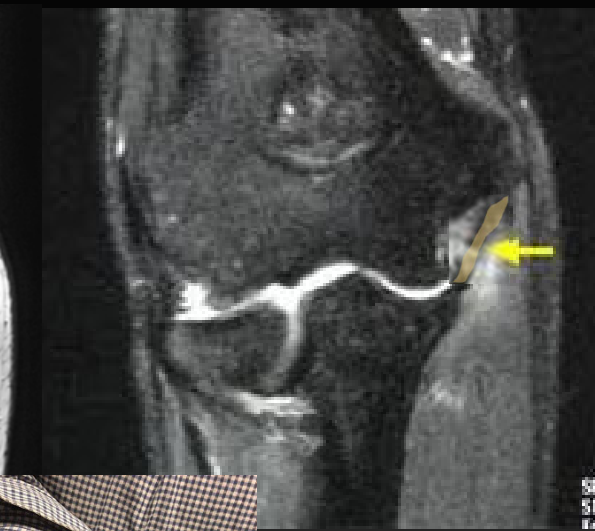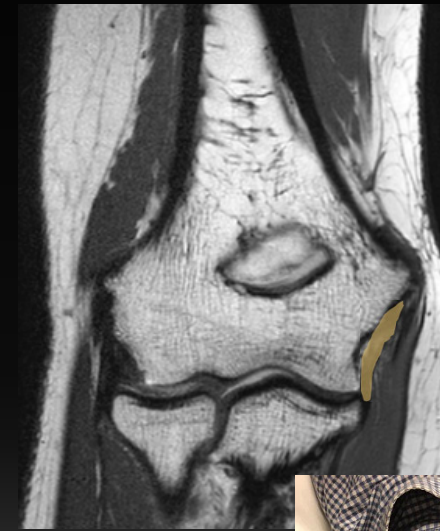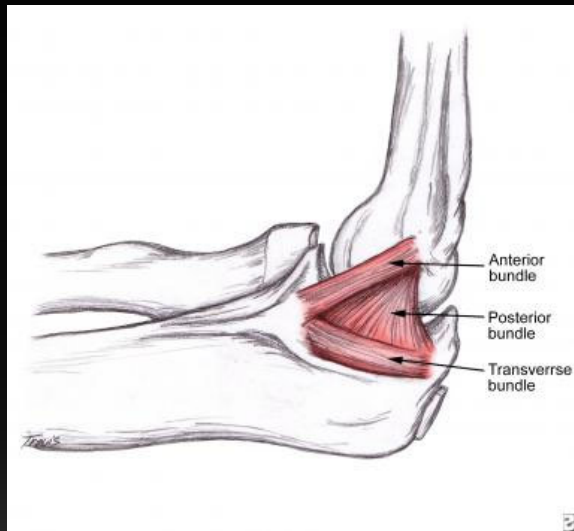
Ulnar Collateral Ligament Elbow Injections



Anterior Band of UCL



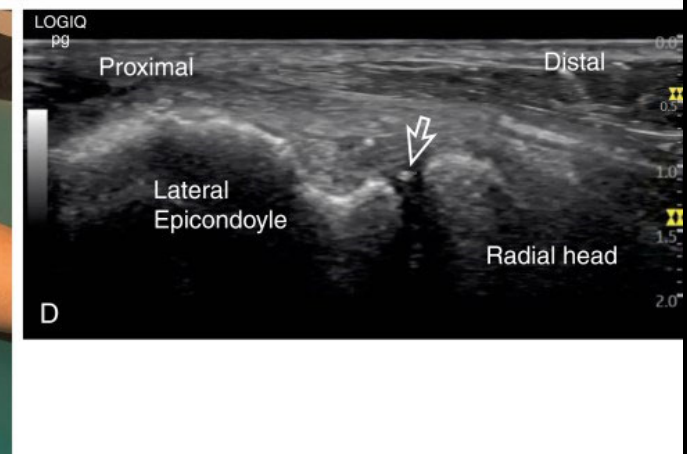
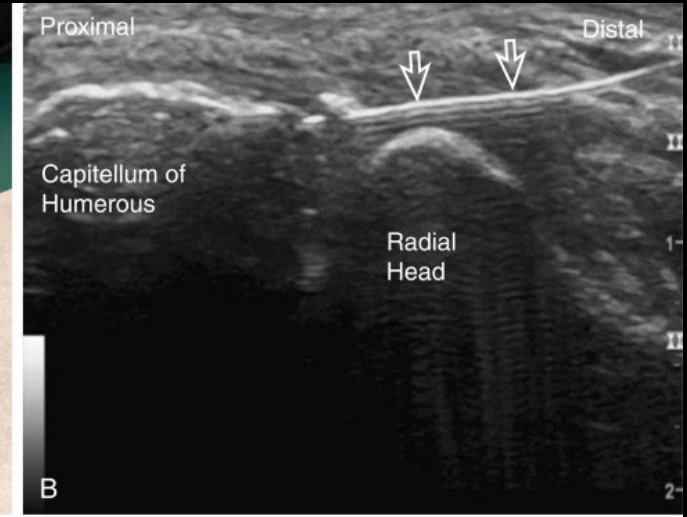
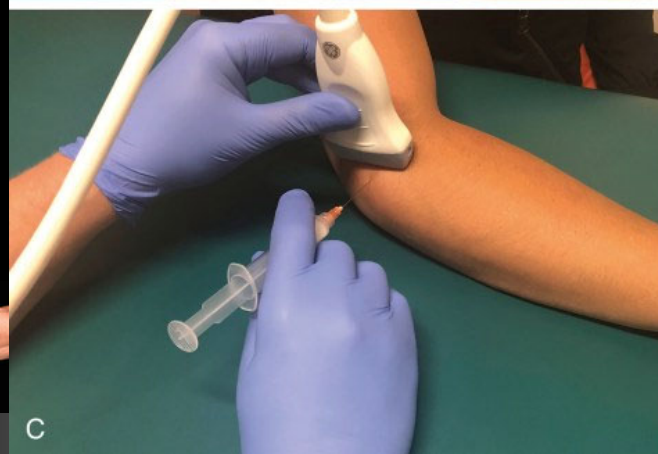
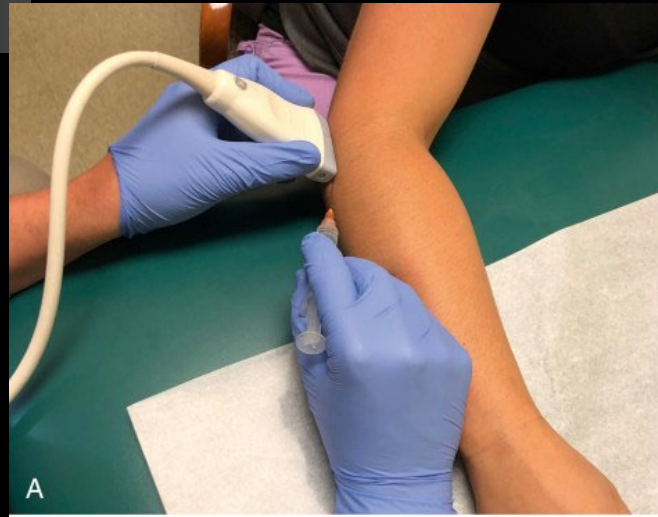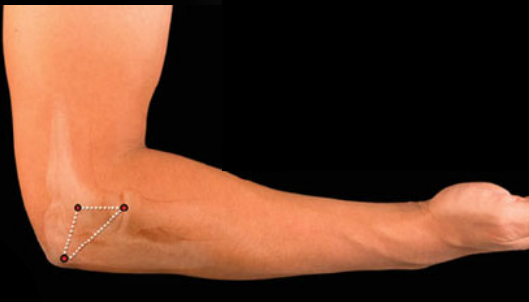Ulnar Collateral Ligament Elbow Injections



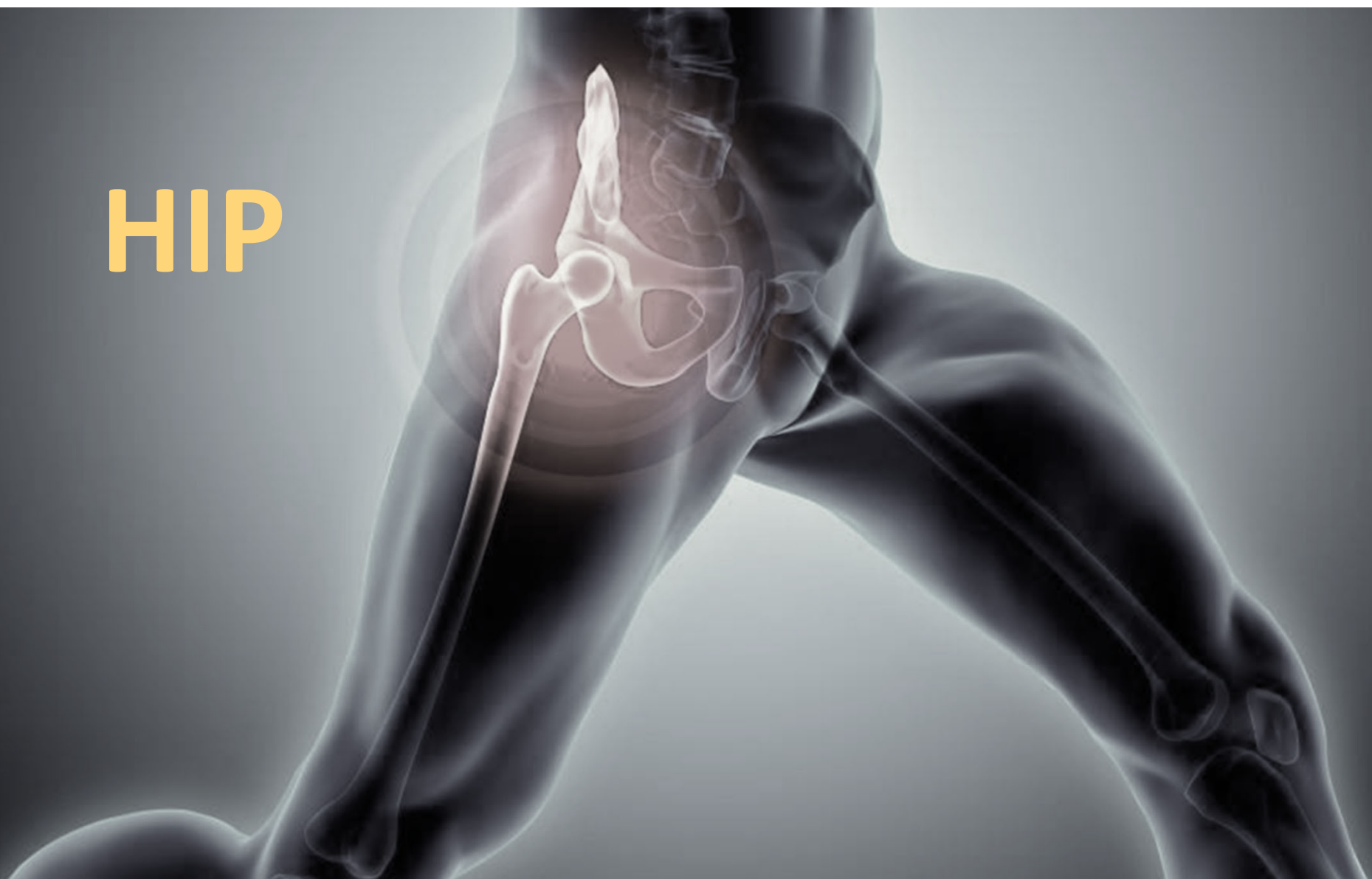IntraArticular Injection



Intra-Articular Injection



HIP



Anatomy of the Capsule

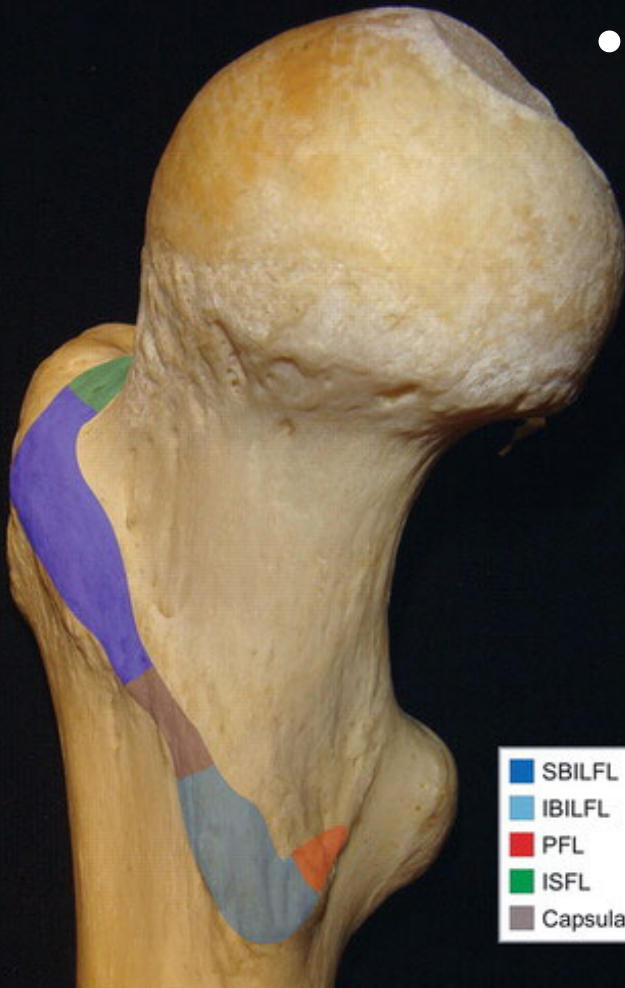
- **Capsular Anatomy:**

- Attached at the outer margin of the labrum

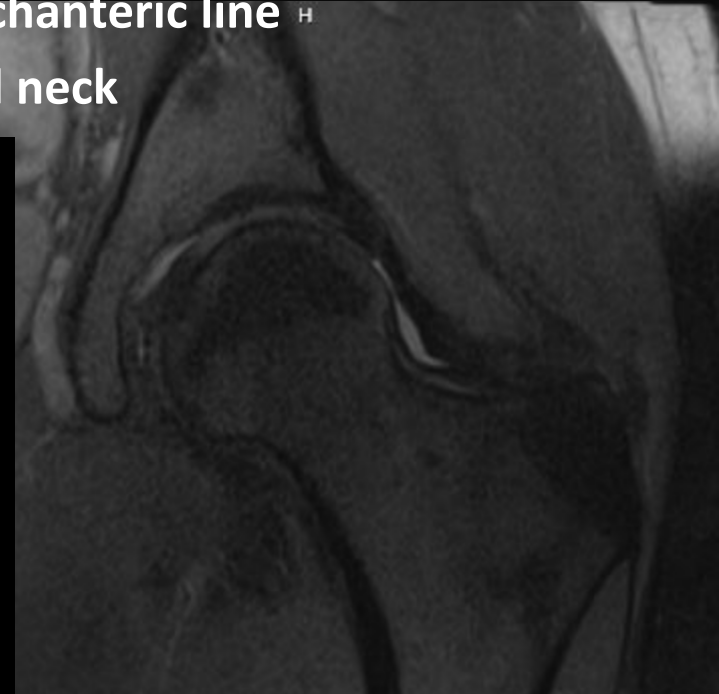
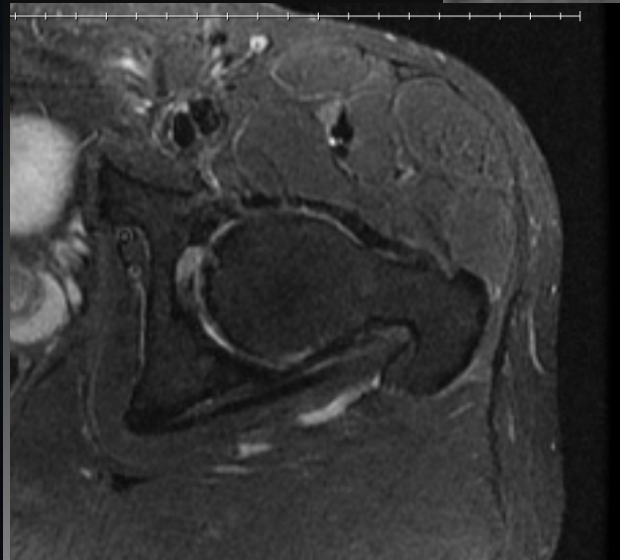
- Femoral attachments

- Anteriorly at the intertrochanteric line ^H

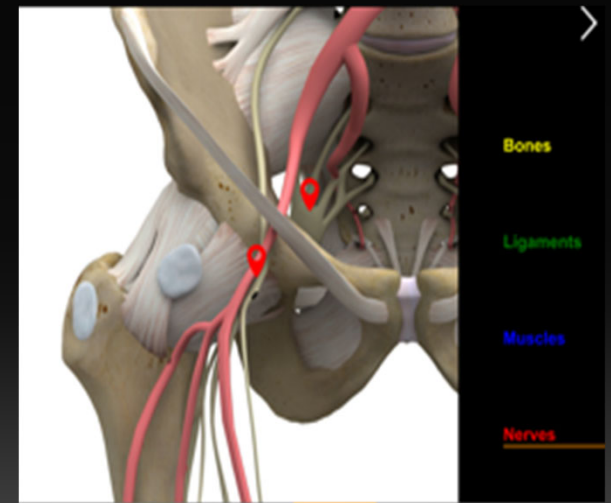
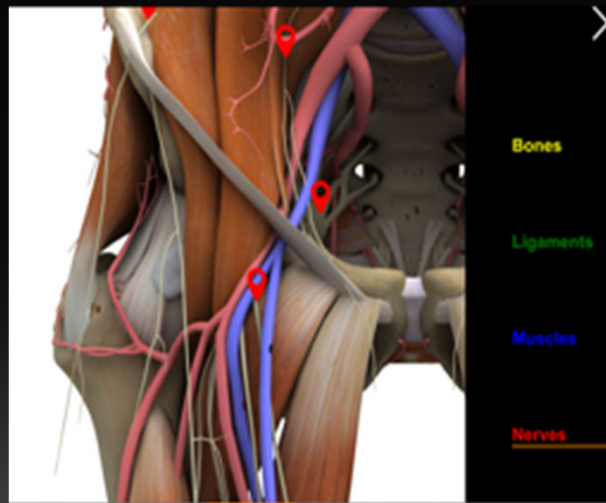
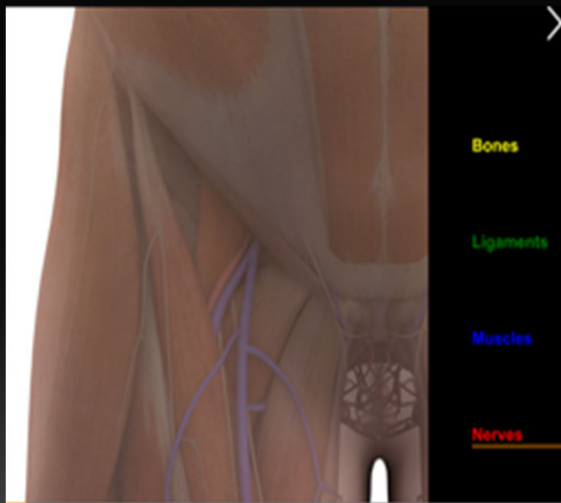
- Posteriorly at the femoral neck



■ SBILFL
■ IBILFL
■ PFL
■ ISFL
■ Capsular Fibers

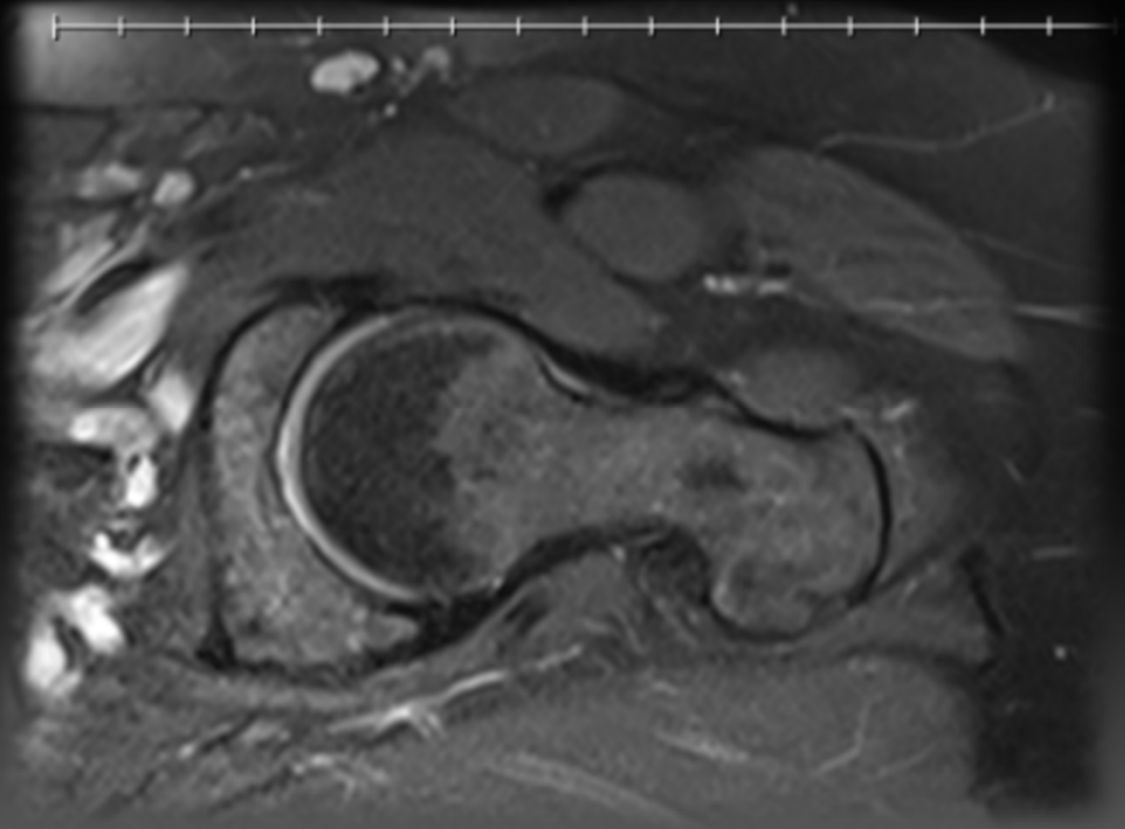


Anatomy review



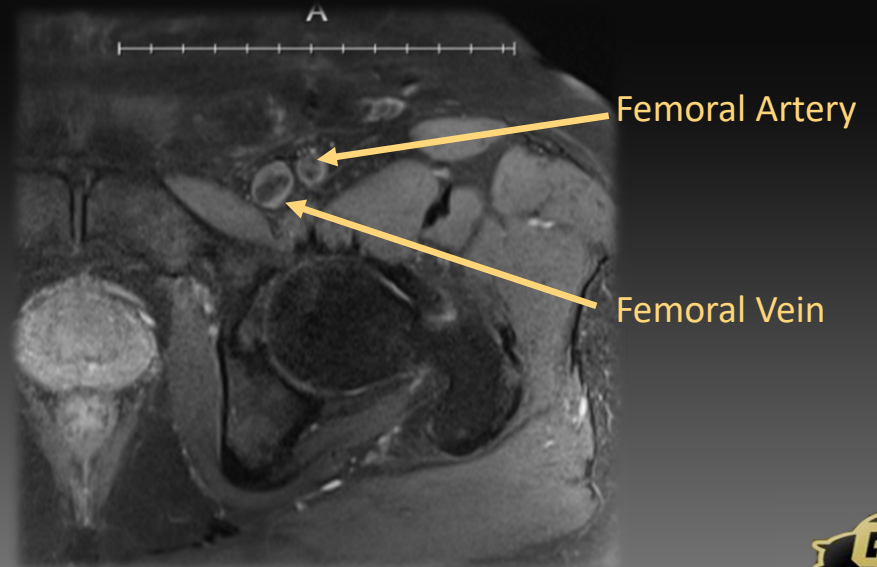
Anatomy

- TFL
- Rectus Femoris
- Sartorius
- Iliacus



Neurovascular Anatomy

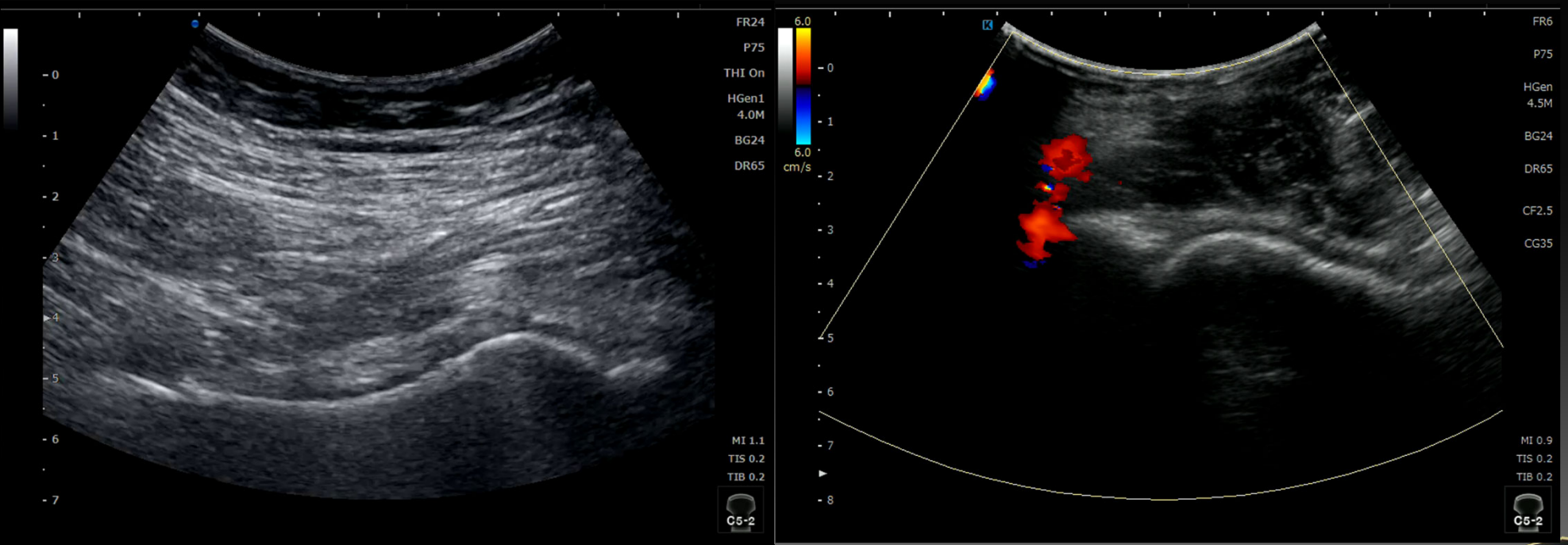
- Avoid the Femoral NAV
- Avoid regional vascular structures
 - Lateral Circumflex Artery
 - From the deep femoral artery, deep to sartorius and rectus, curves around the inferior neck



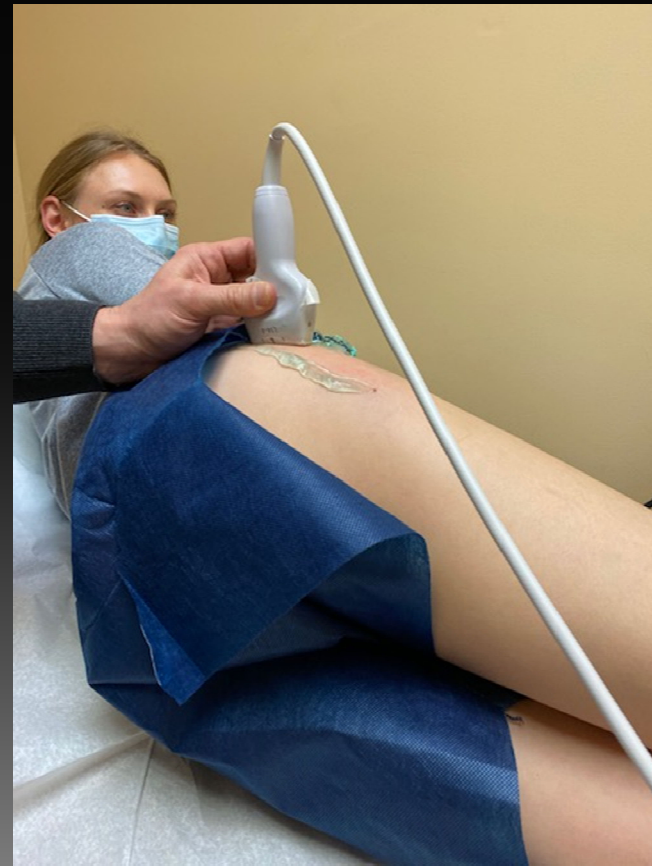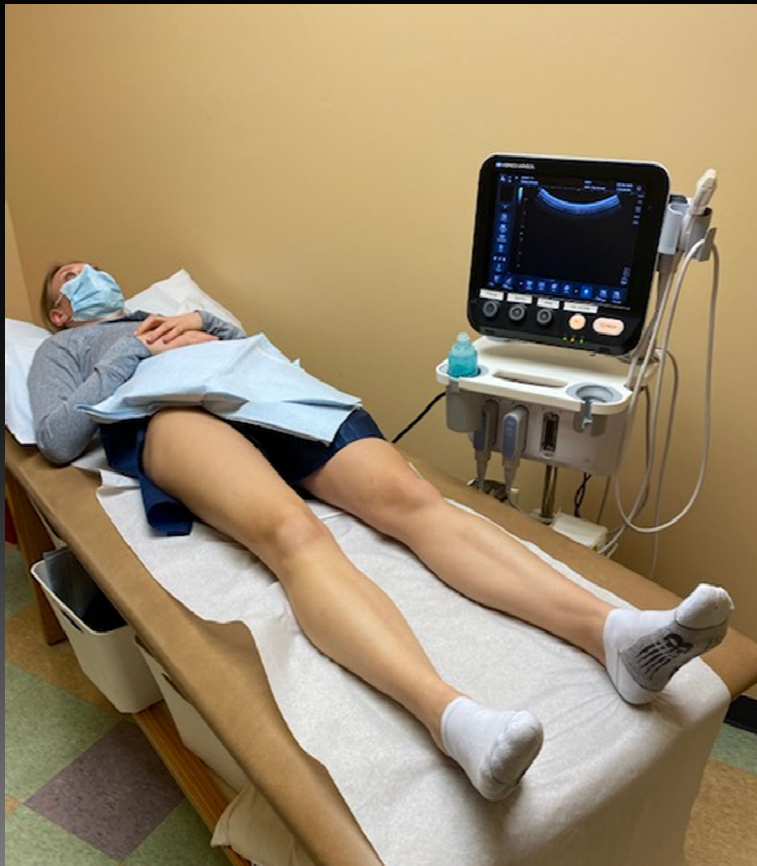b1

bssc, 2/11/2021

Vascularity on Ultrasound

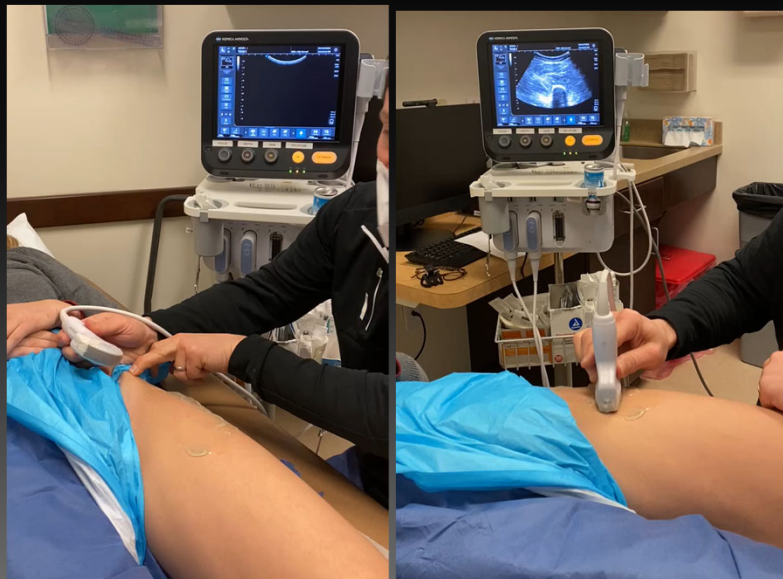
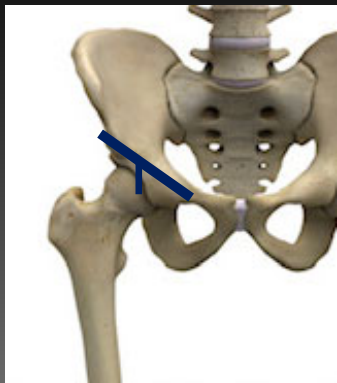

Procedure – Patient Positioning



Procedure – Surface Anatomy, Joint Localization

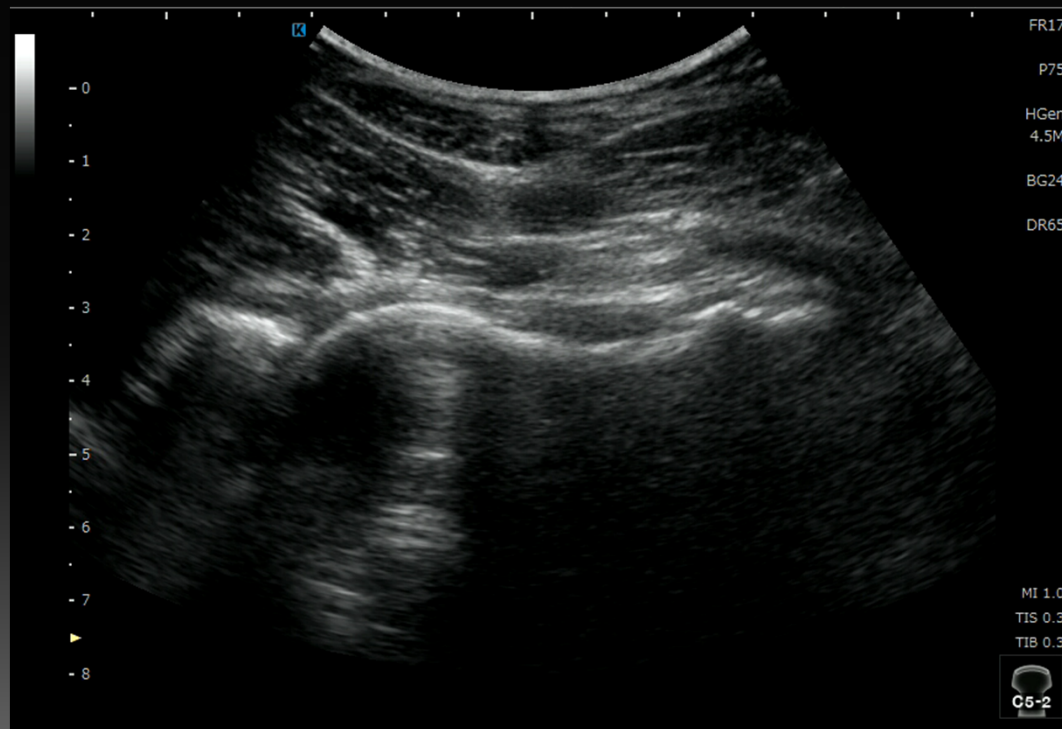
- From above: 3cm distal to the midpoint between the ASIS and the pubic symphysis

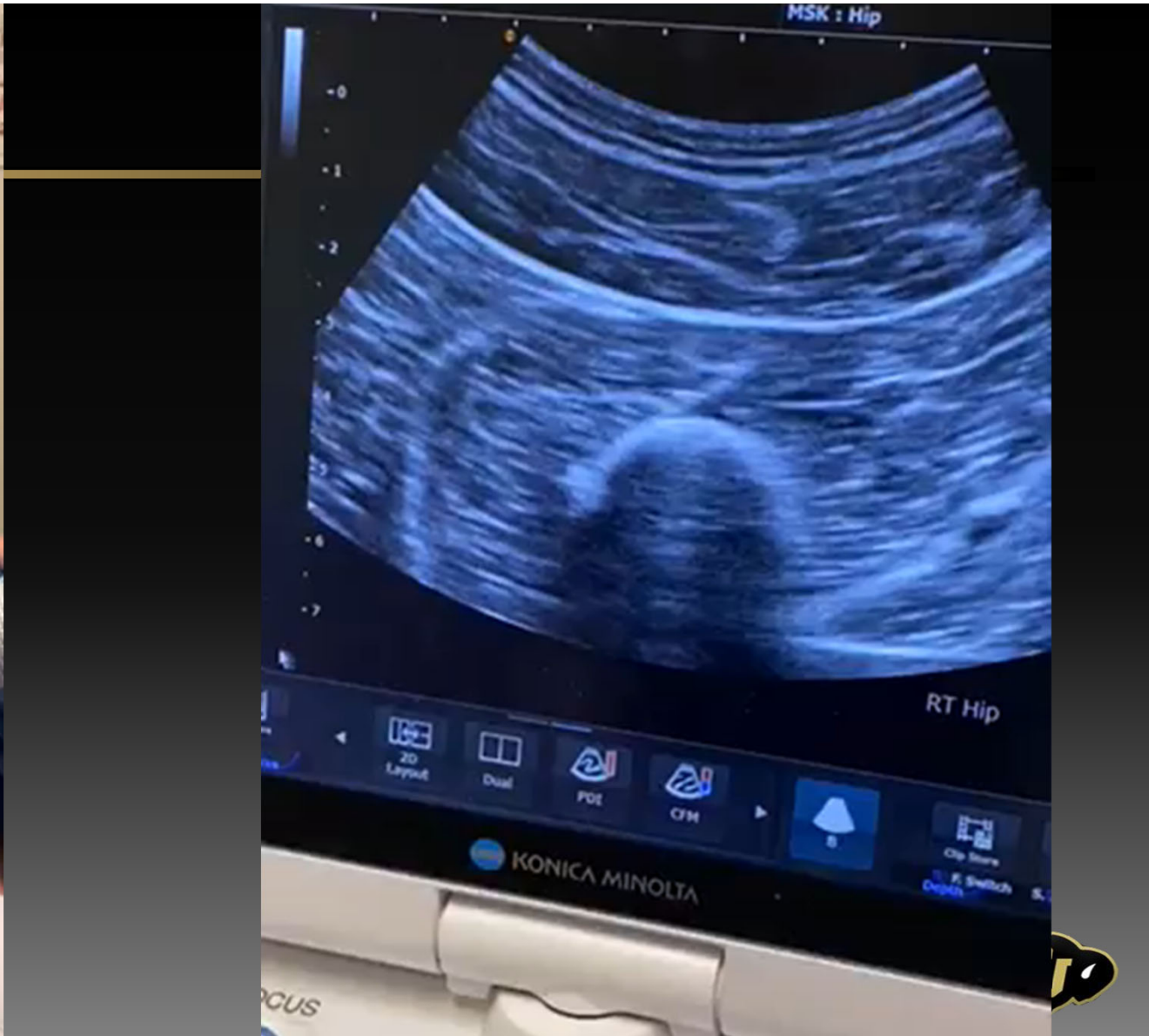
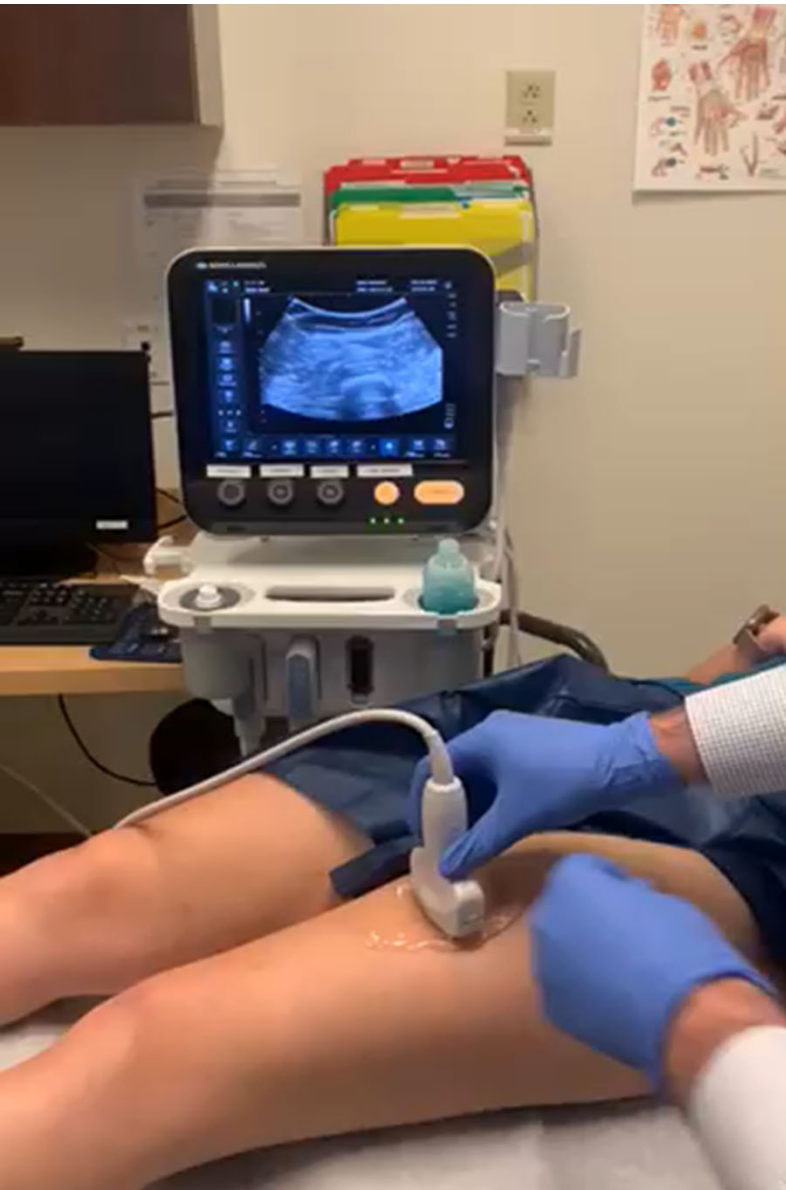
- From below: obtain a short axis view of the femur, slide proximally until contour changes, rotate probe 45-60 towards the opposite shoulder

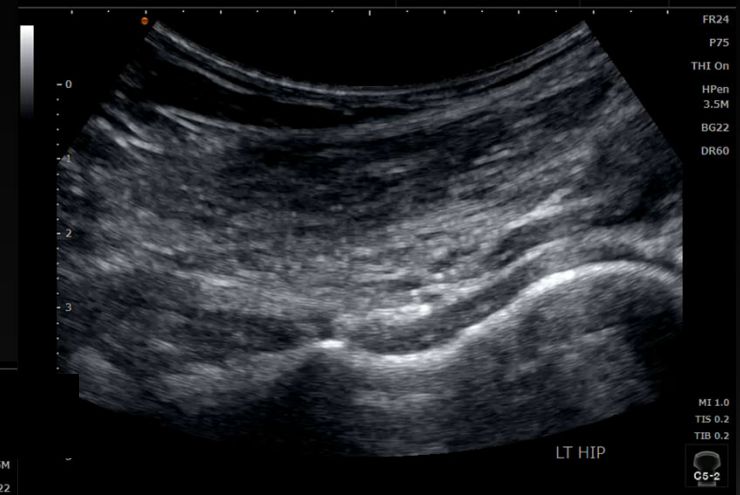
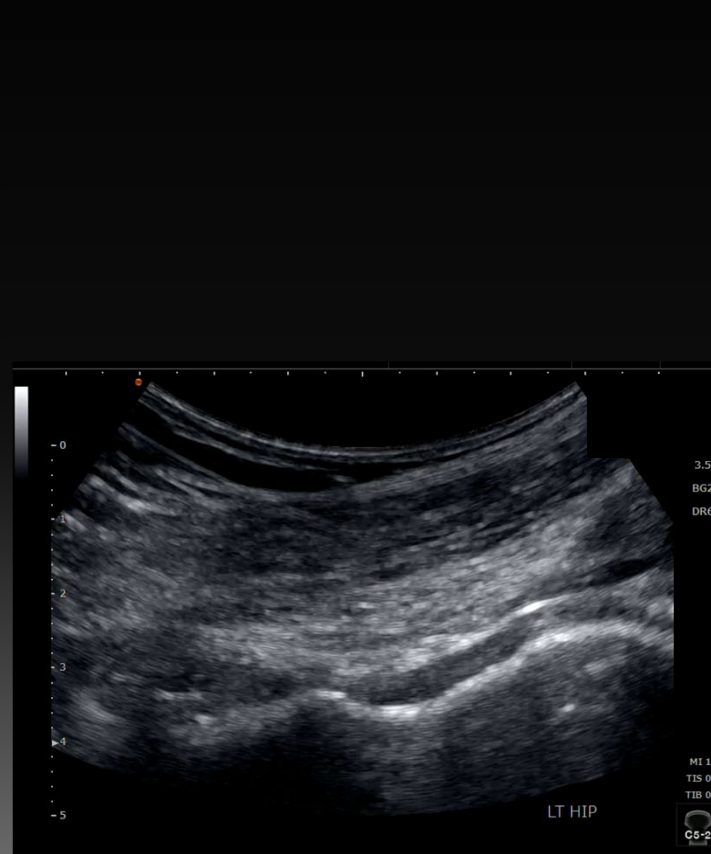
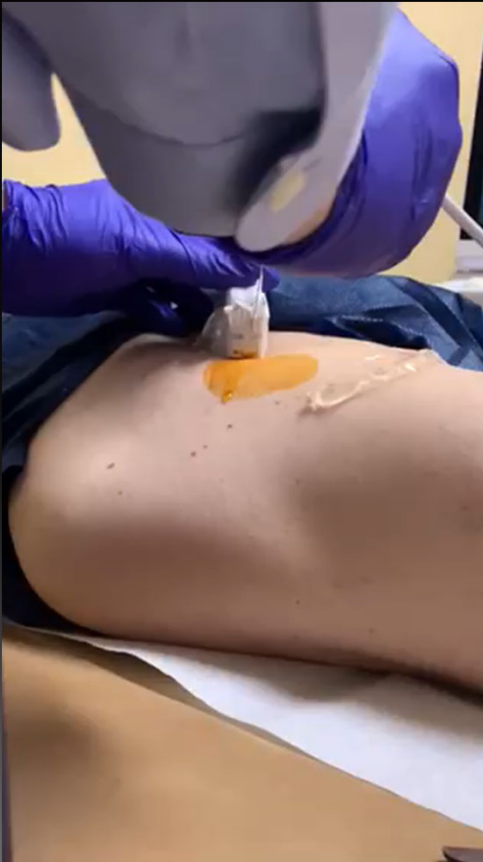
Evaluation of Anatomy

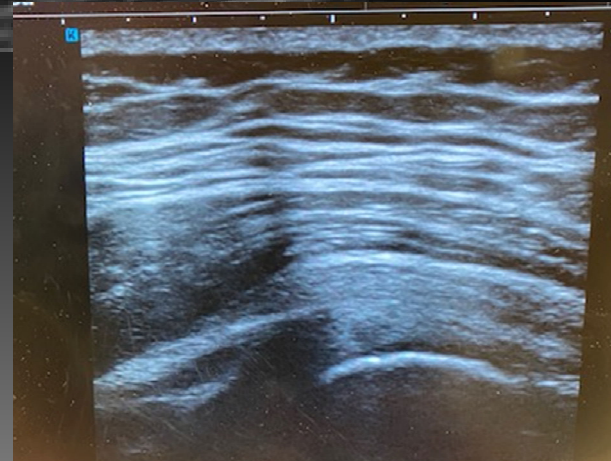
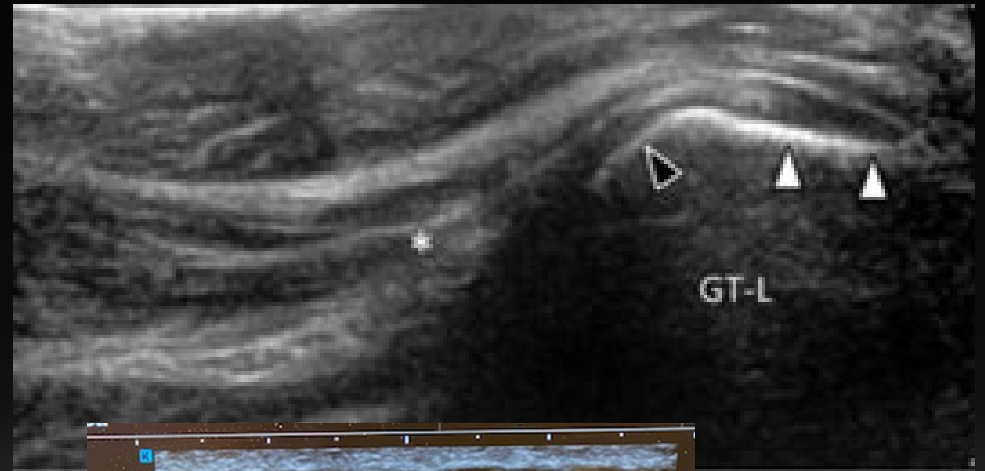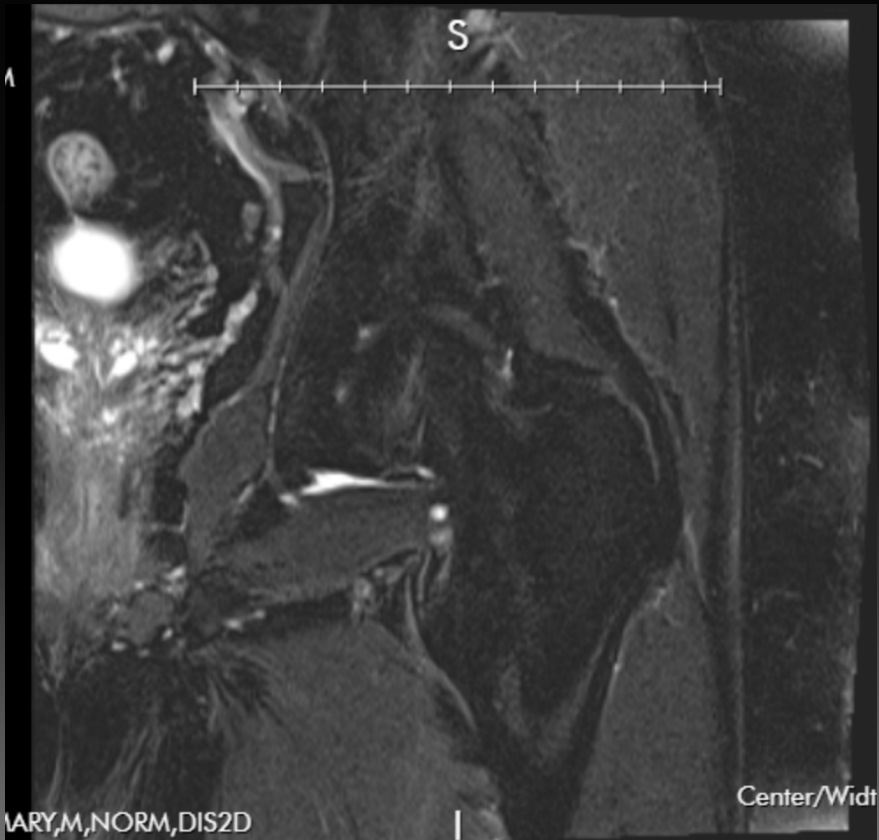




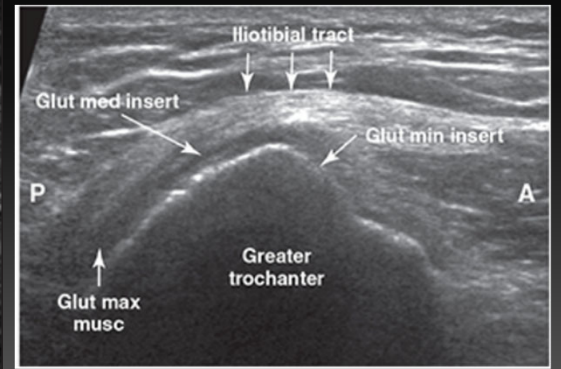
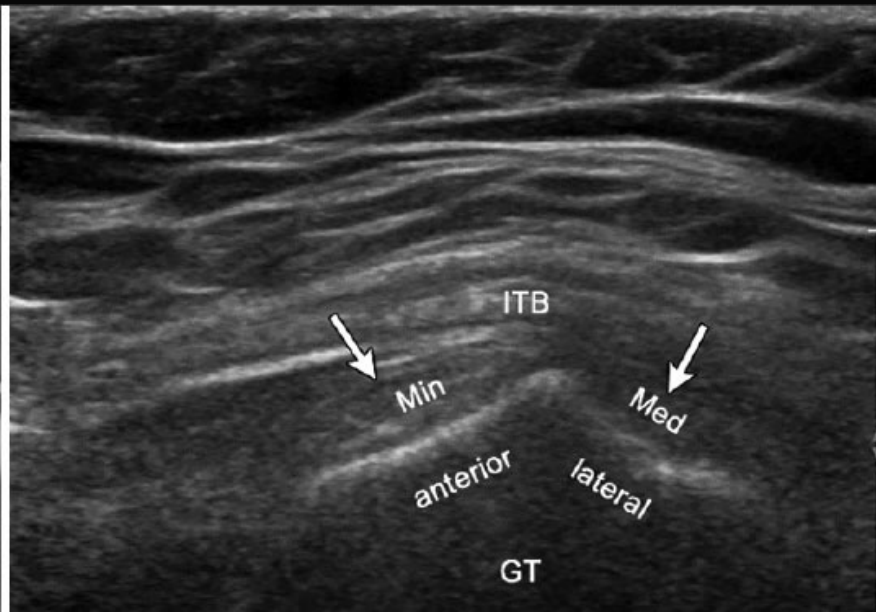Intra-Articular Injection



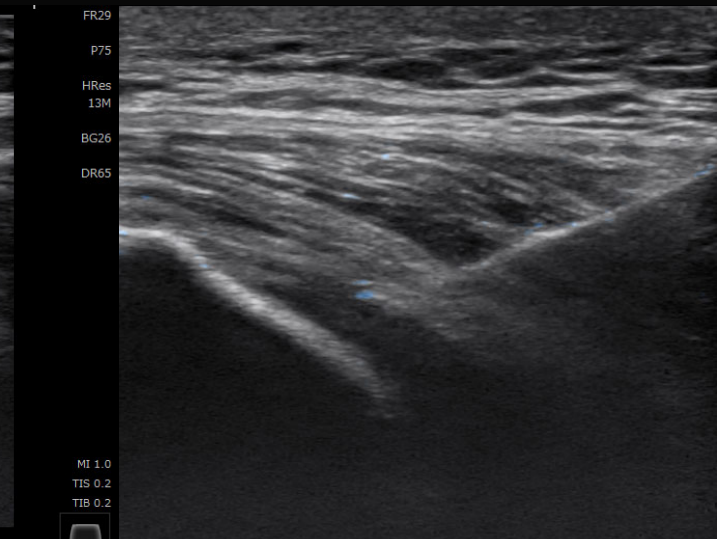
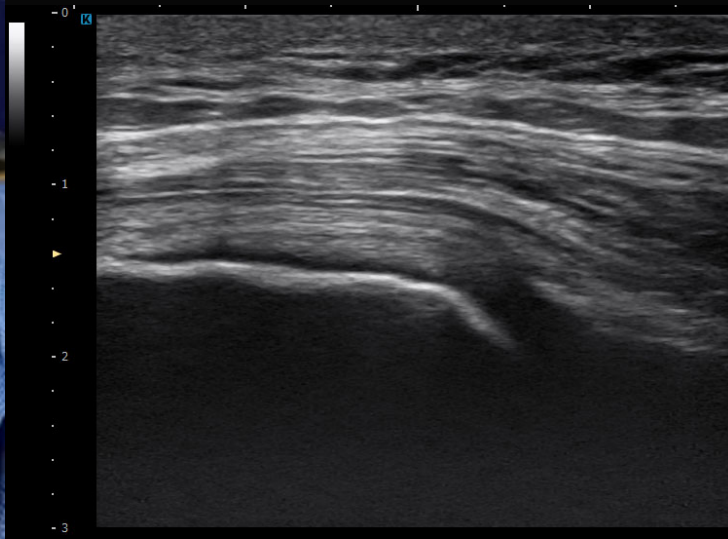
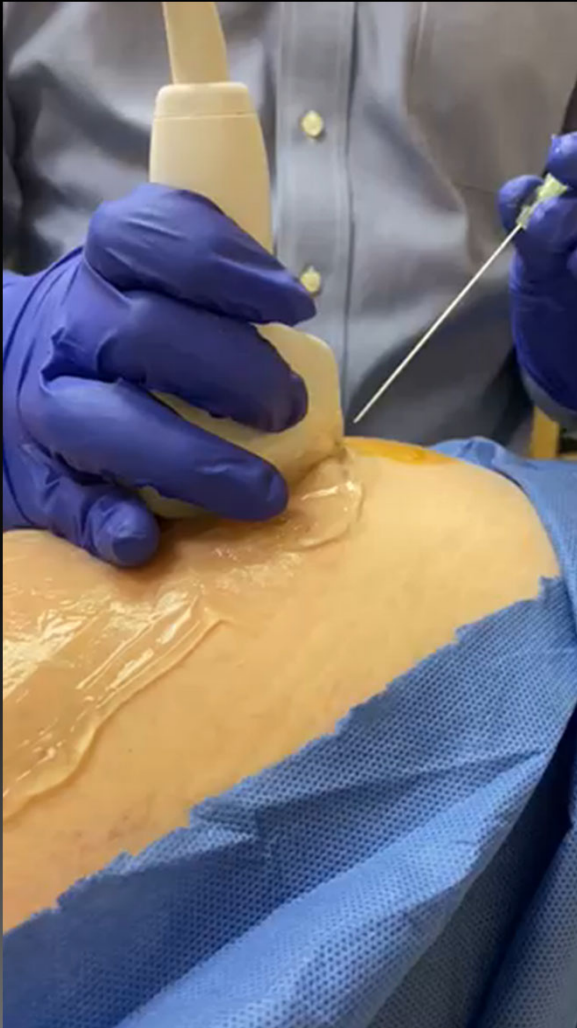
Anatomy of the lateral hip



Finding the anatomy



Peritrochanteric Injection



Common pathology

- **Femoroacetabular Intraarticular injection**
 - OA
 - Labral tearing
 - FAI
 - Rule out infection/
crystalline dz.
- **Extraarticular injection**
 - Trochanteric Bursitis
 - Tendinopathy

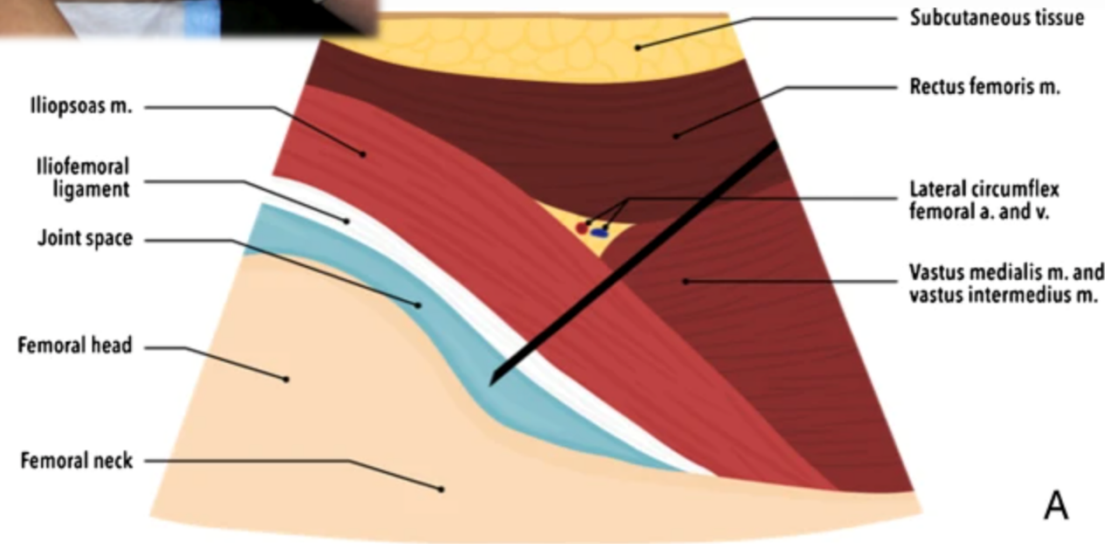
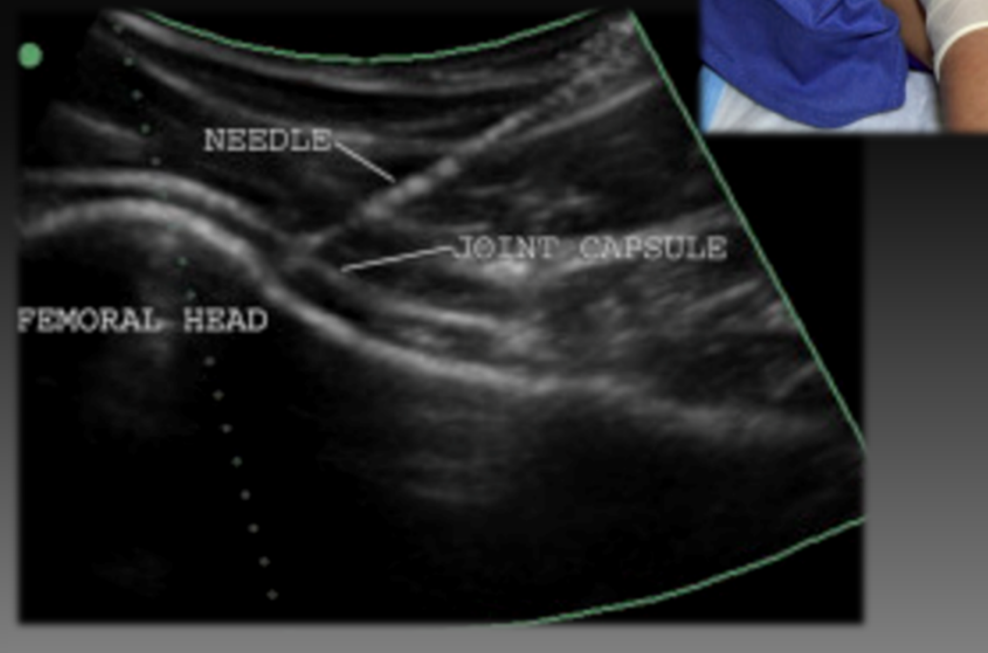
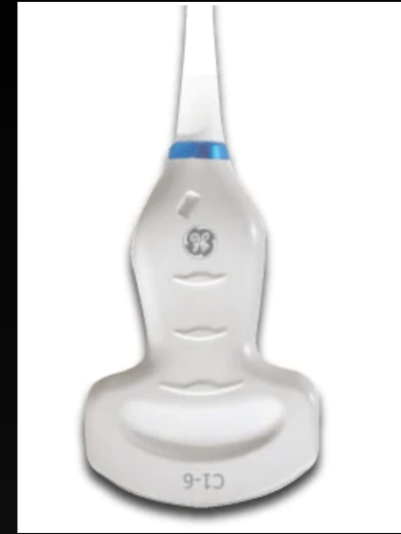
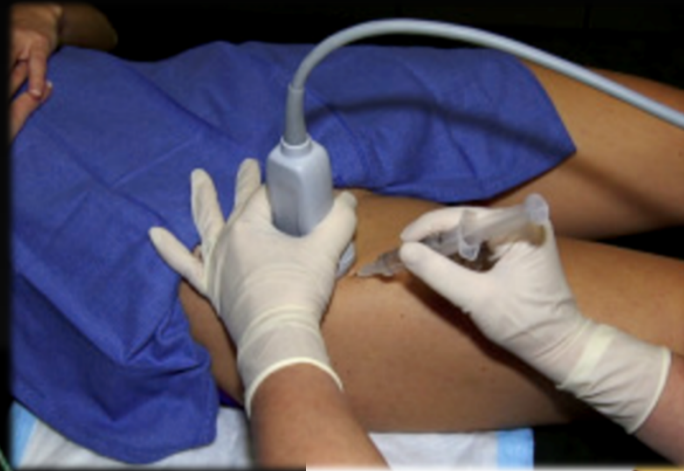
Hip Injection Pearls

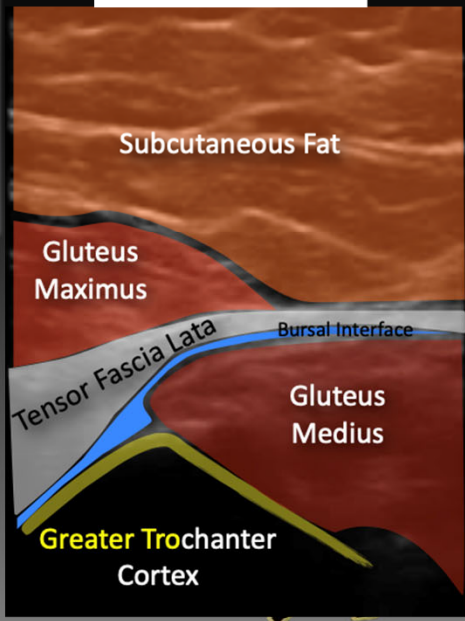
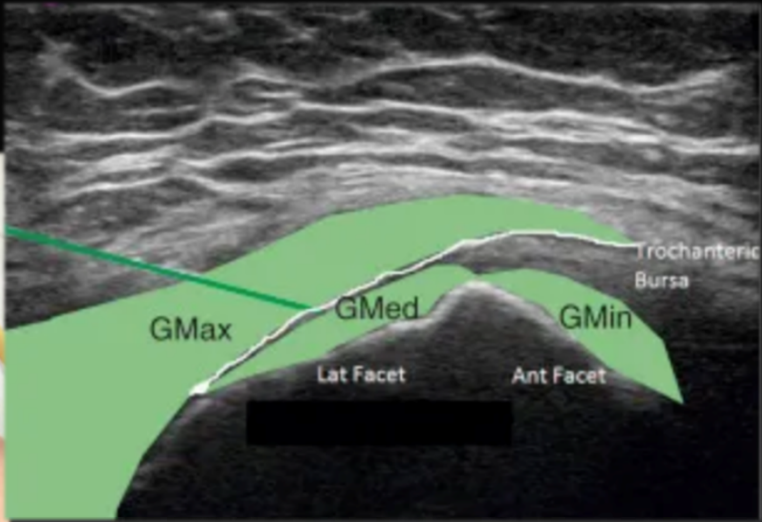
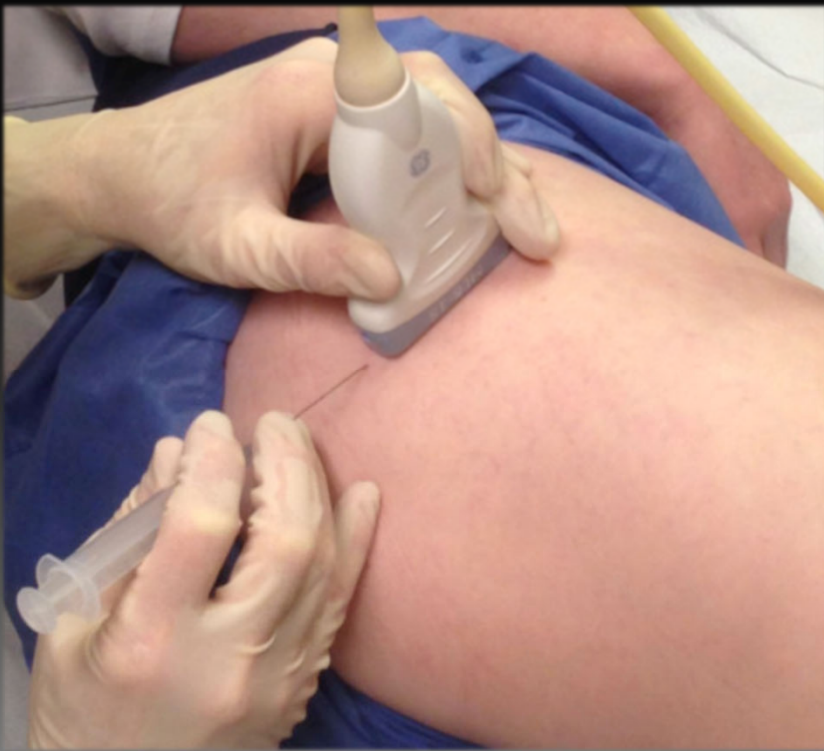- **Don't compress the soft tissue. Excessive pressure can cause compression of the soft tissue specifically the vascular structures**
- **Know your limits/ patient limits**
- **Maximize visualization prior to injection accounting for location, depth and gain**



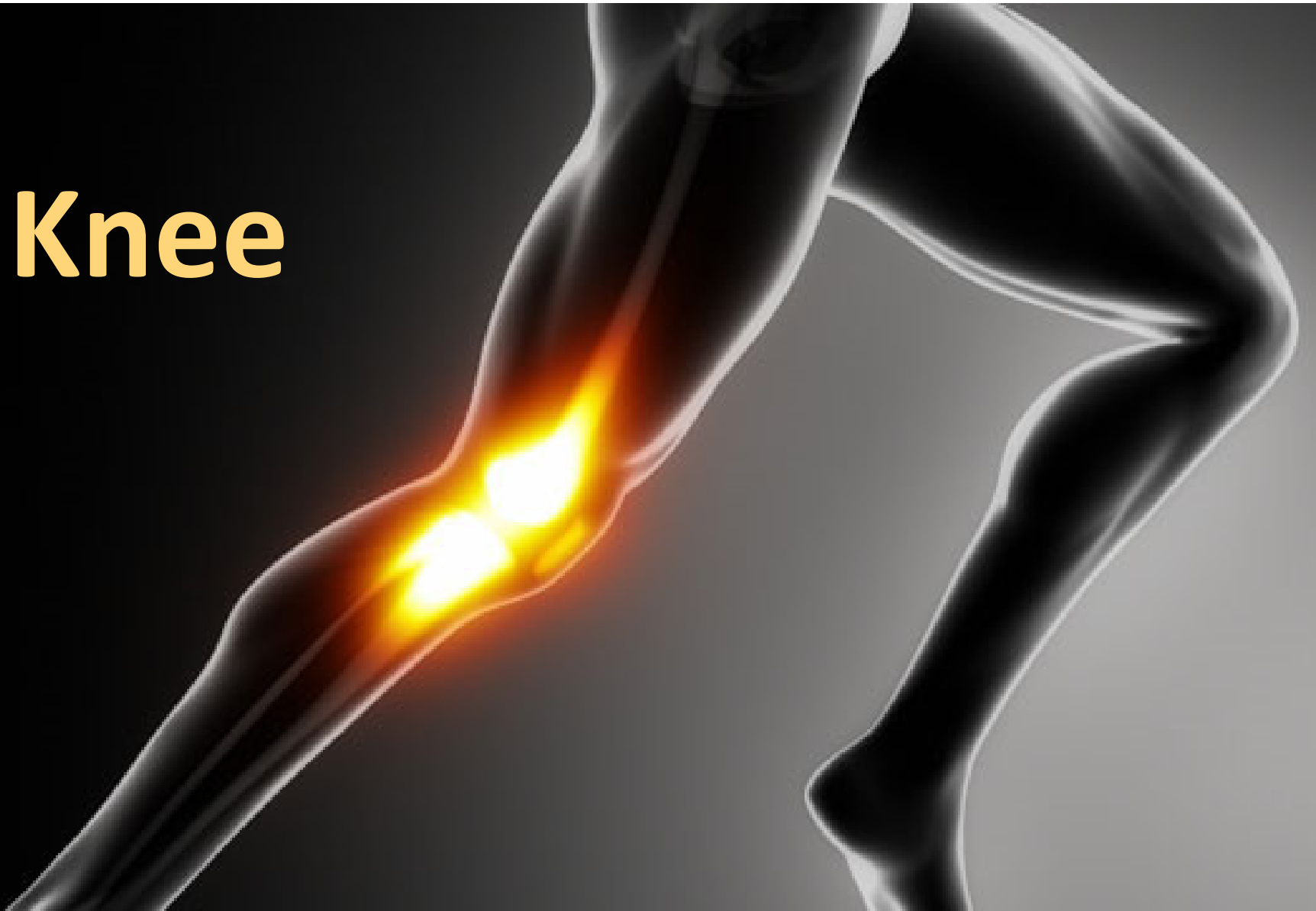Hip Joint



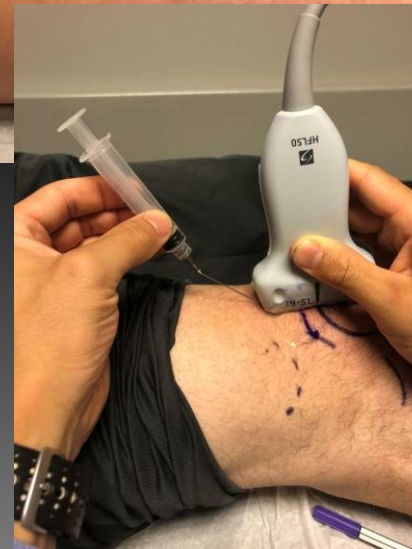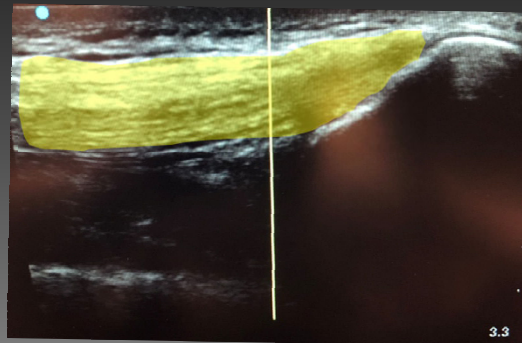
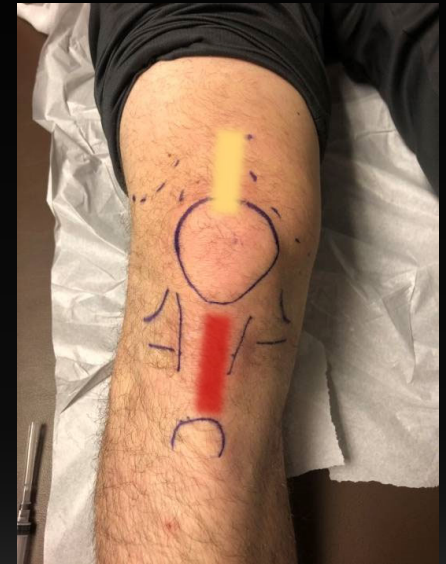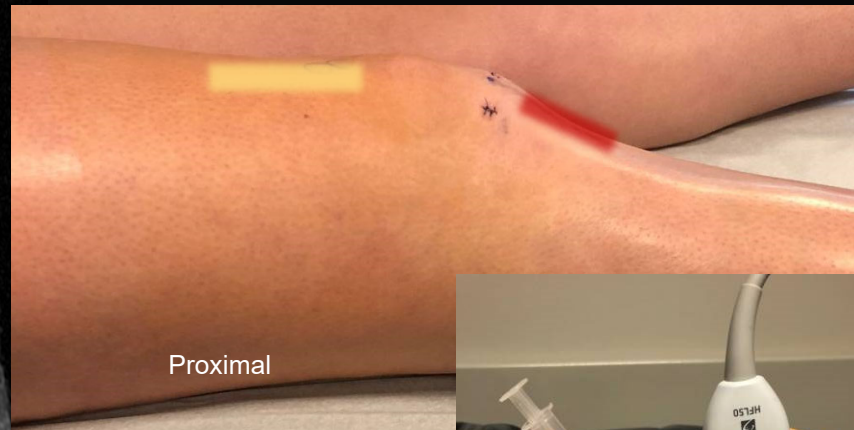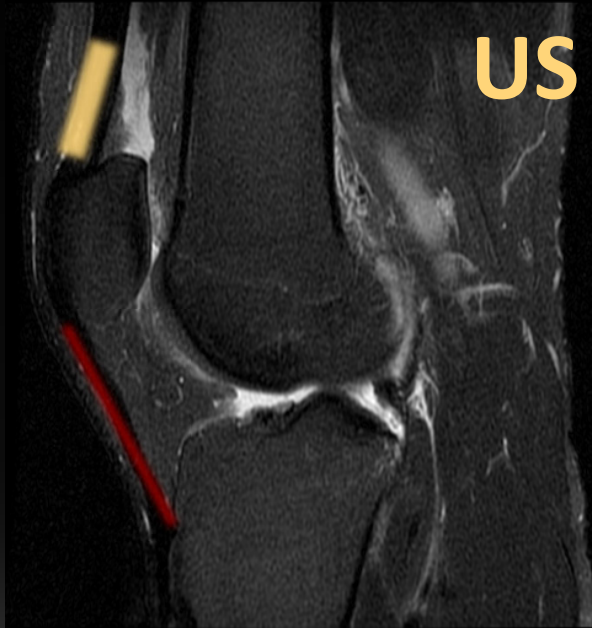
Greater Trochanter Bursa




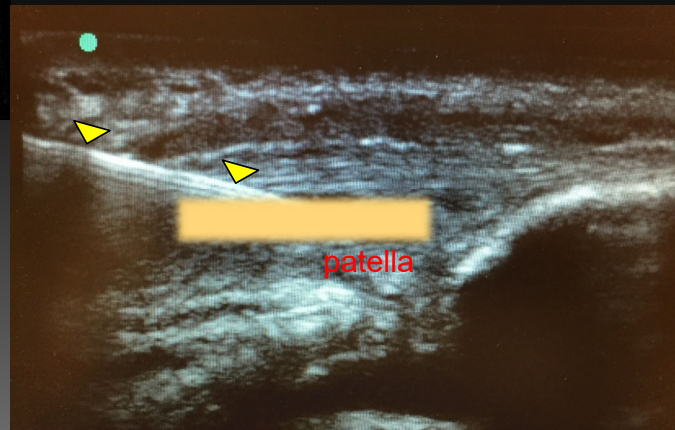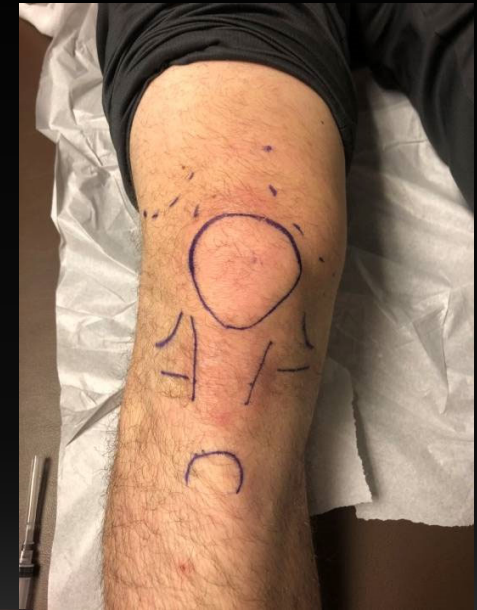
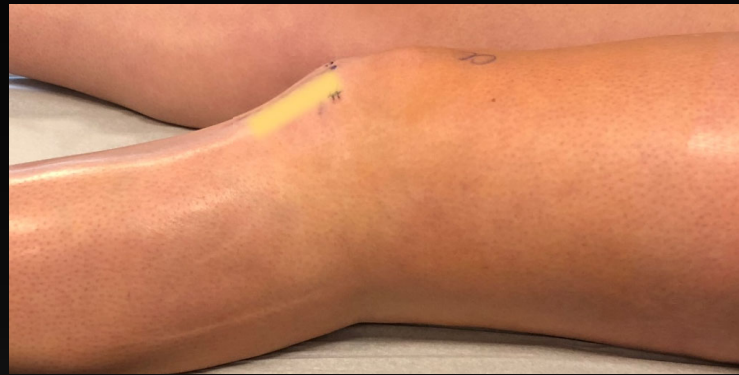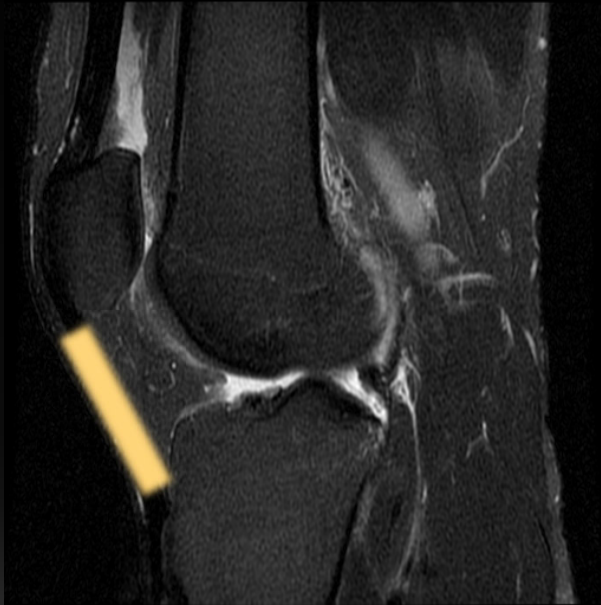Knee



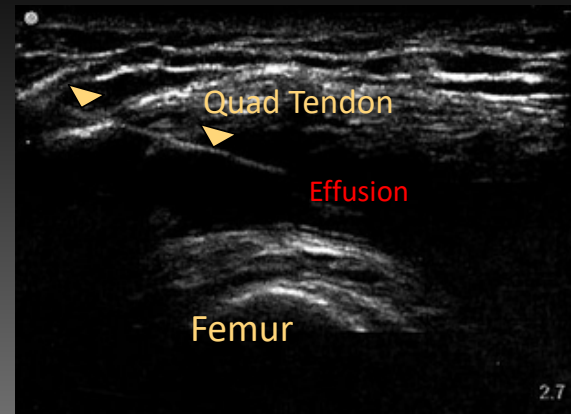
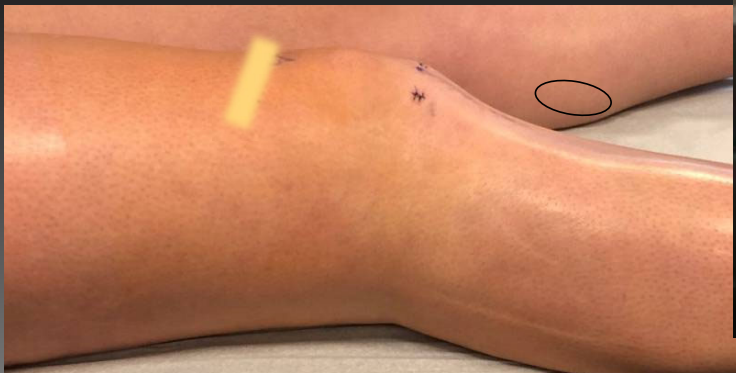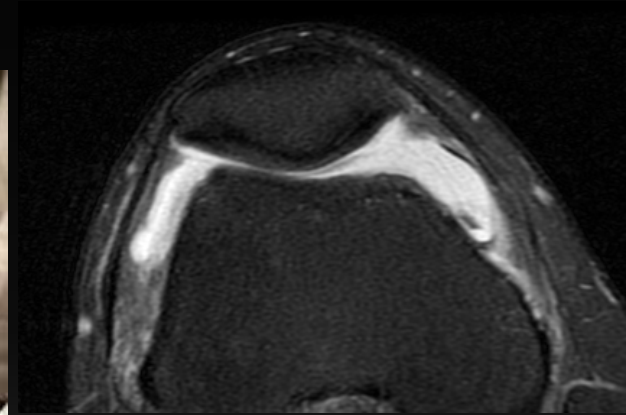
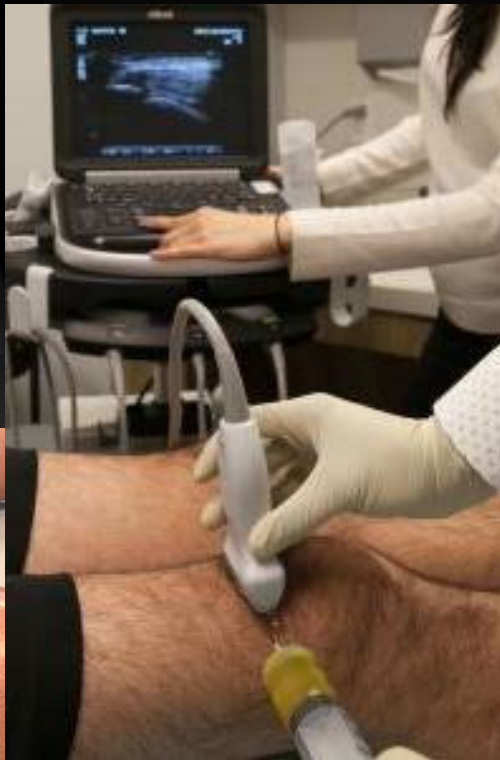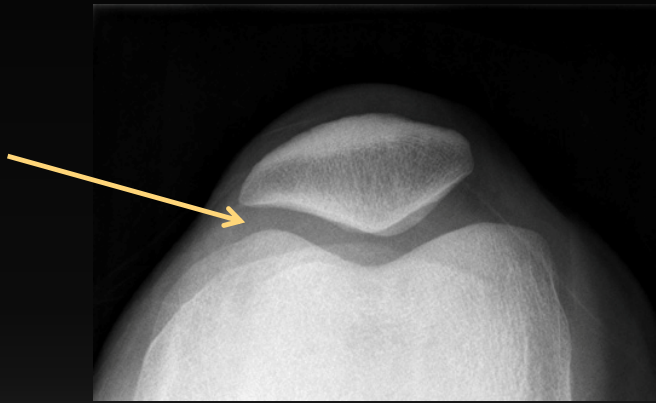US Guided Quad Tendon



Patellar Tendon

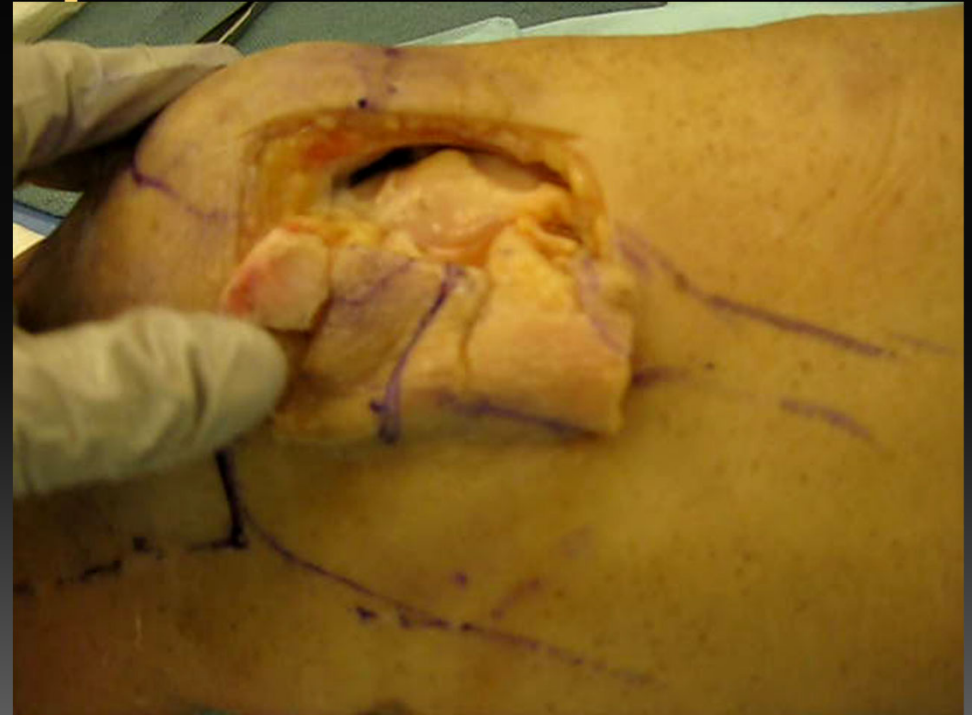
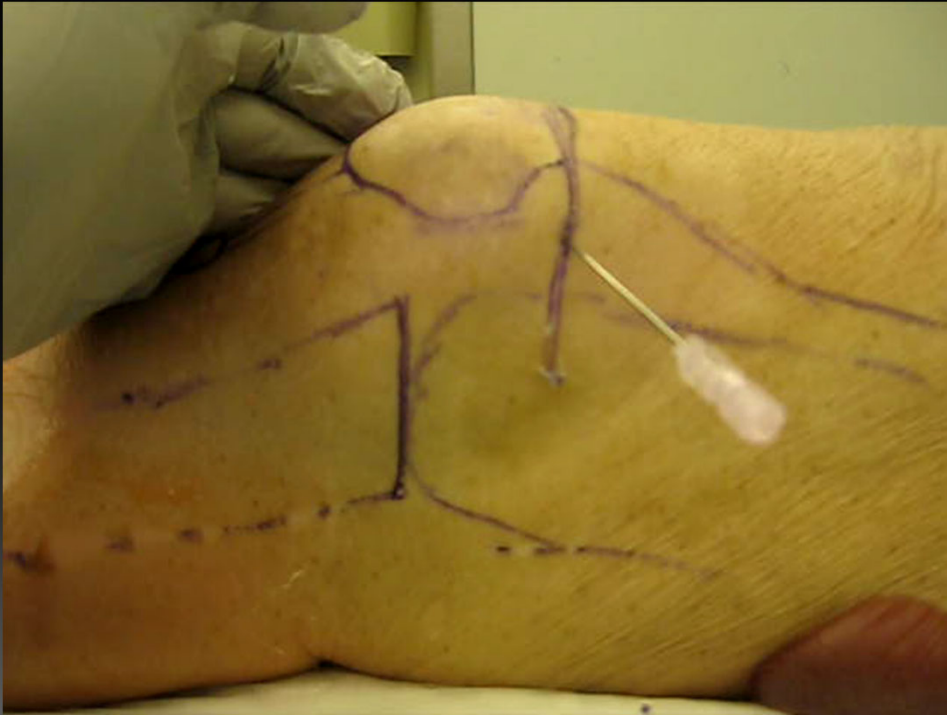
Intra-Articular Injection/Aspiration



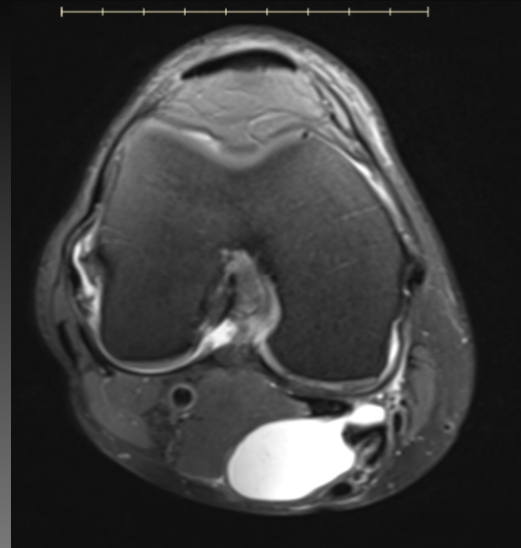
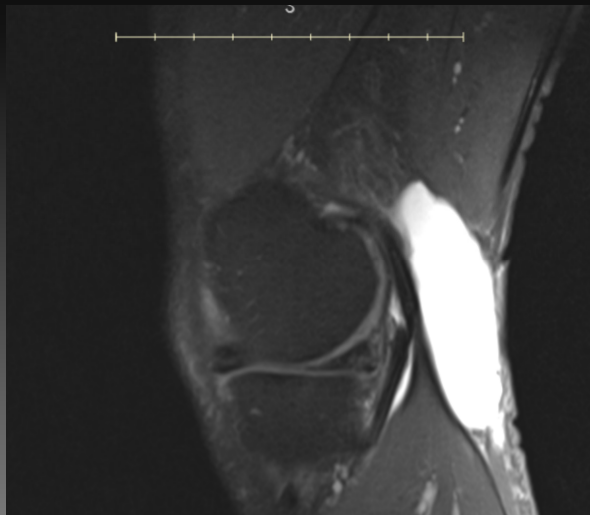
Anatomy of the knee capsule

Entrance point



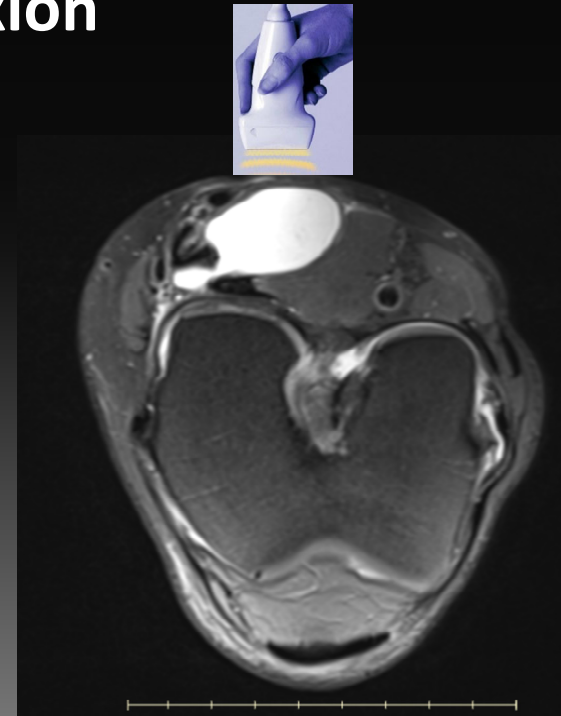
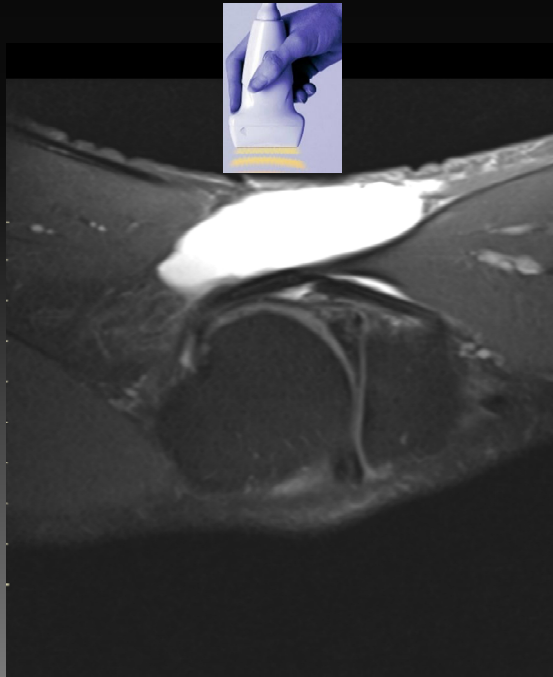
Bakers or Popliteal Cyst - Aspiration

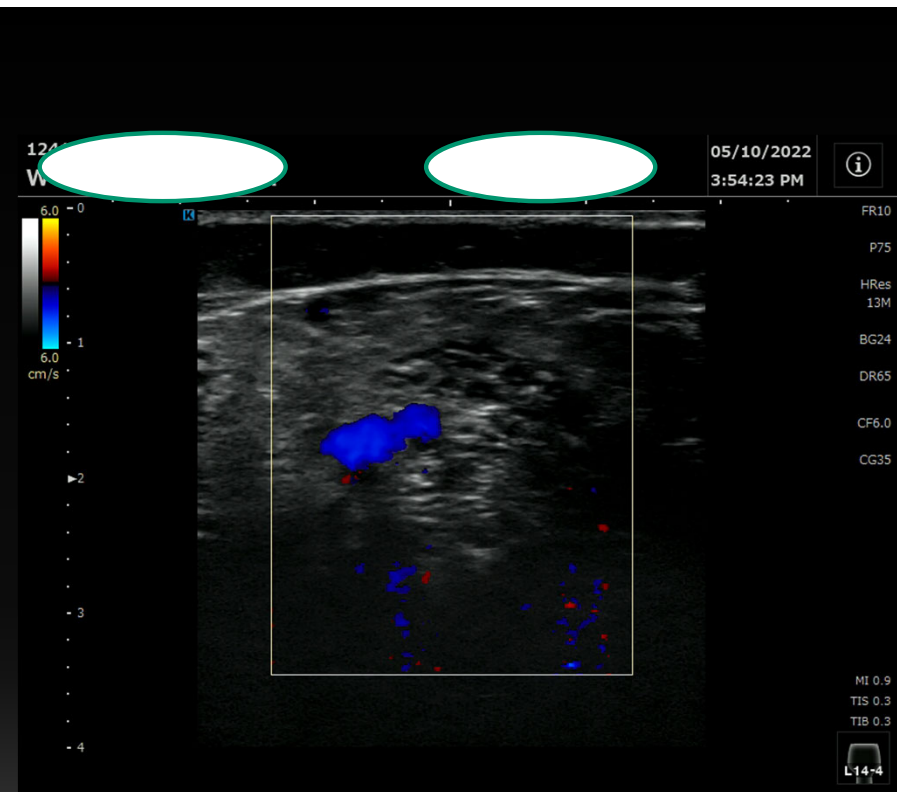
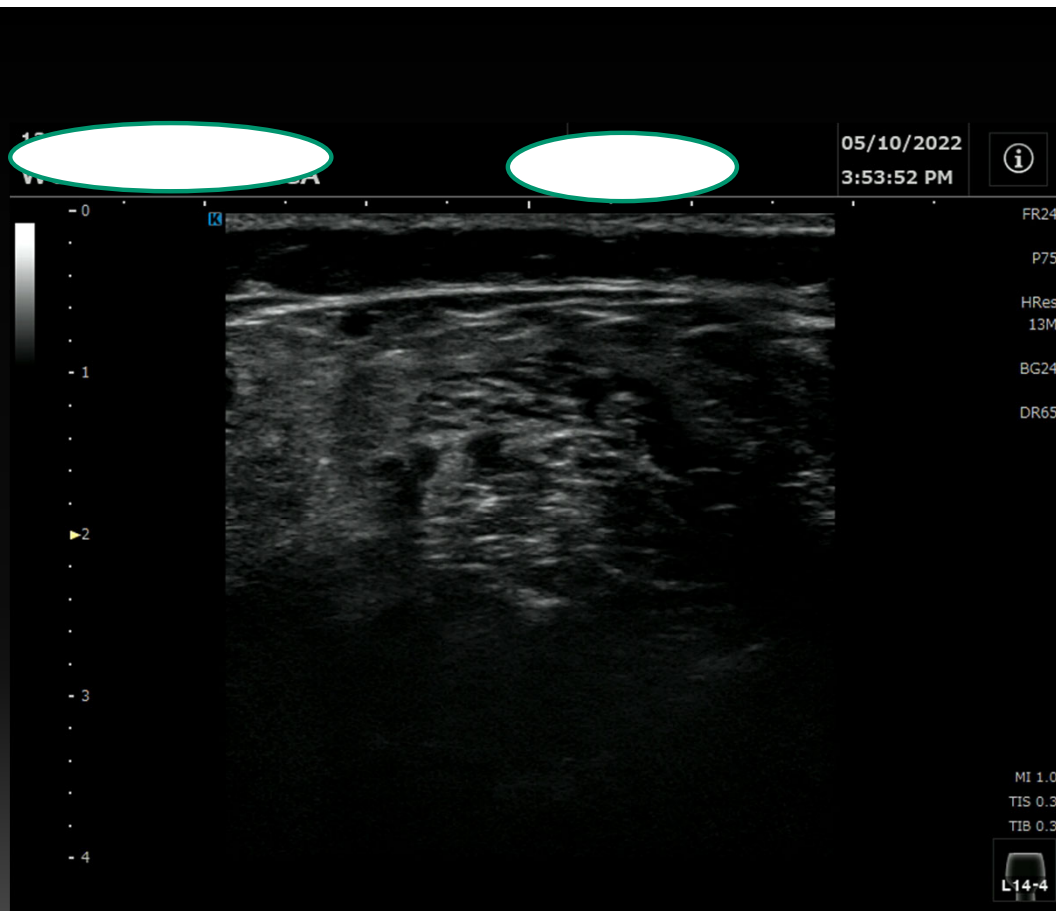
- Fluid communicates through a normal bursa between the semimembranous and medial head of the gastrocnemius
- Located at the posterior portion of the knee with the Popliteal artery/ vein/ nerve



Baker's cyst (Popliteal cyst)

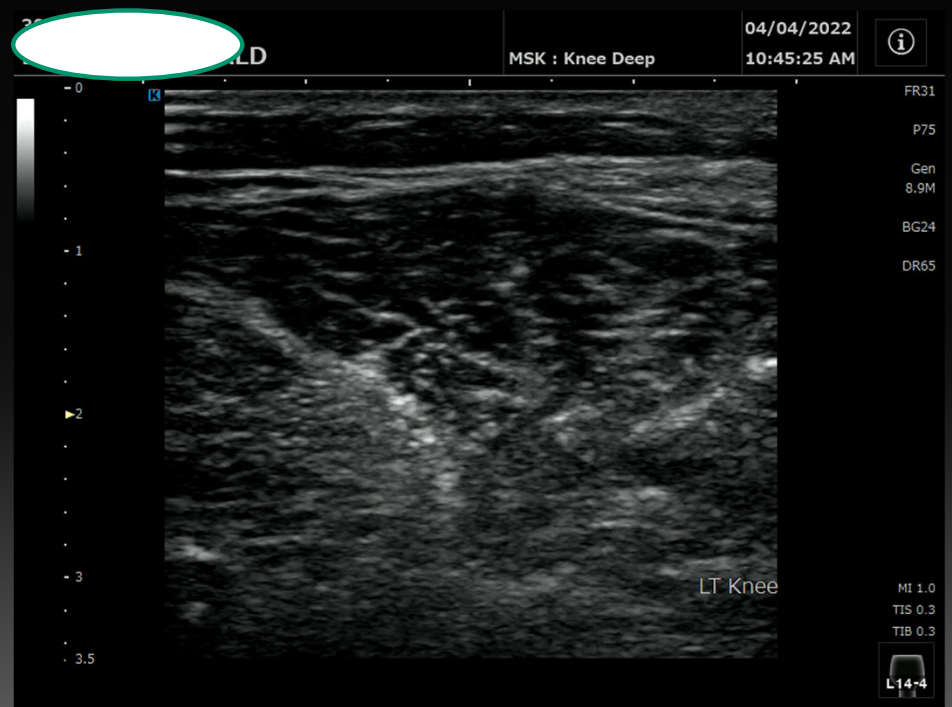
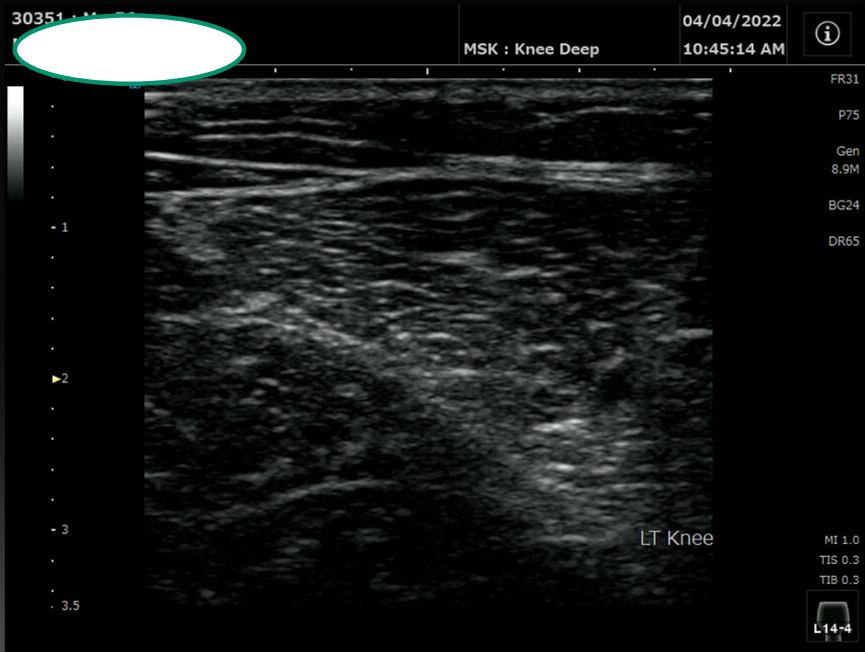
- Patient Prone
- Knee in extension or minimal flexion





Assessment of Vascularity





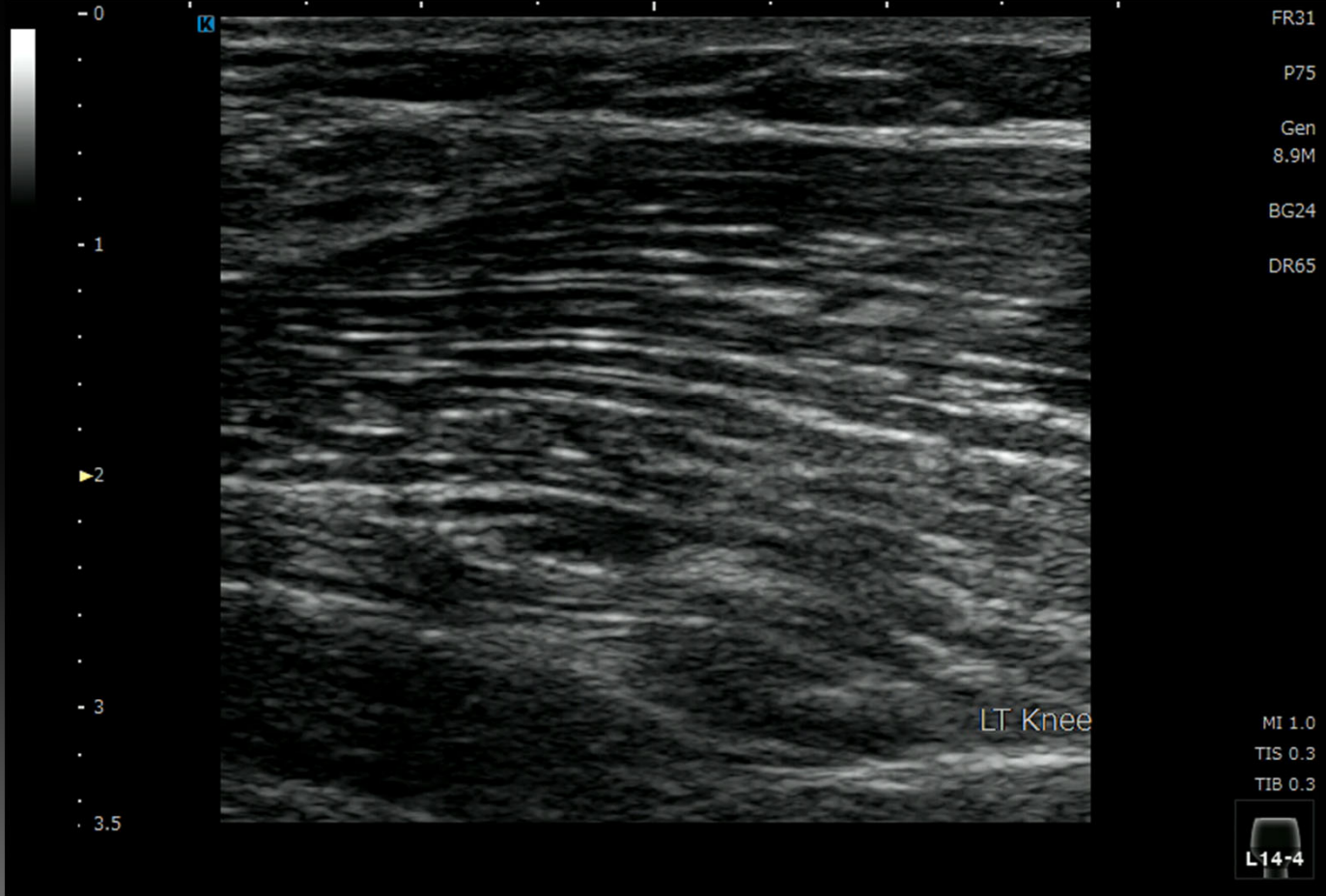
30351 : M : 56



MSK : Knee Deep

04/04/2022

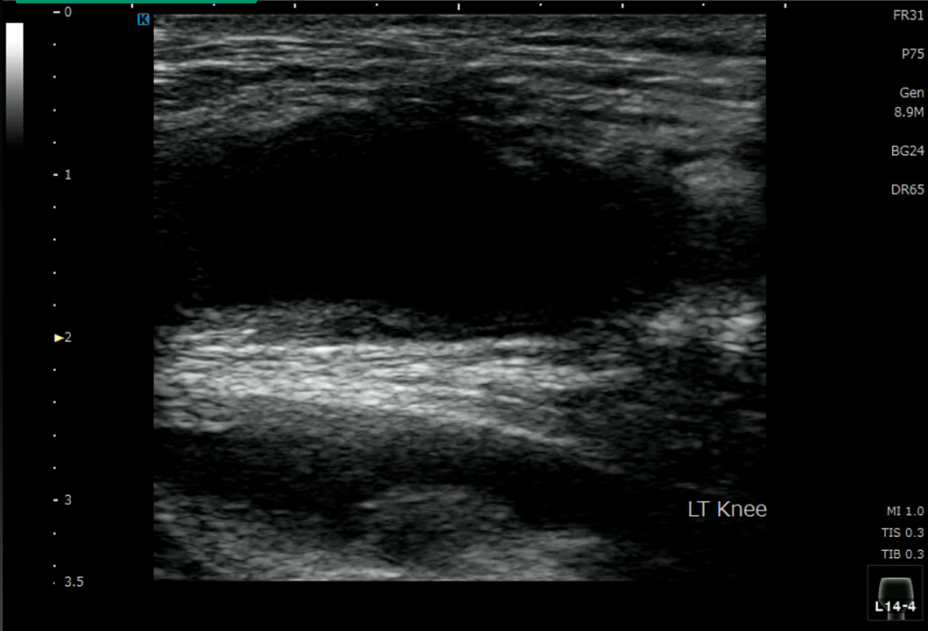
10:45:49 AM



30351 : M : 56

MSK : Knee Deep

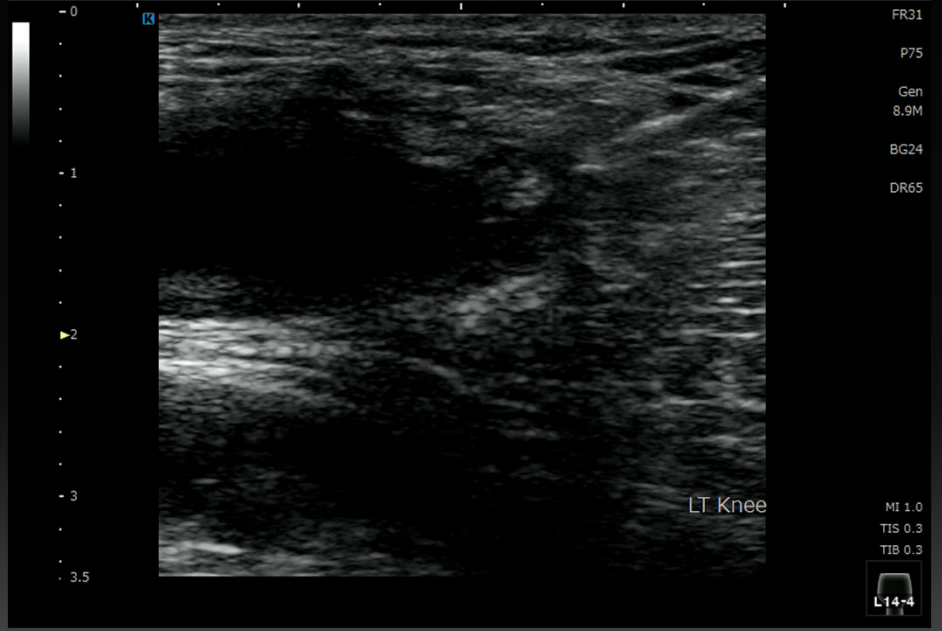
04/04/2022
10:46:50 AM



30351 : M : 56

MSK : Knee Deep

04/04/2022
10:47:26 AM



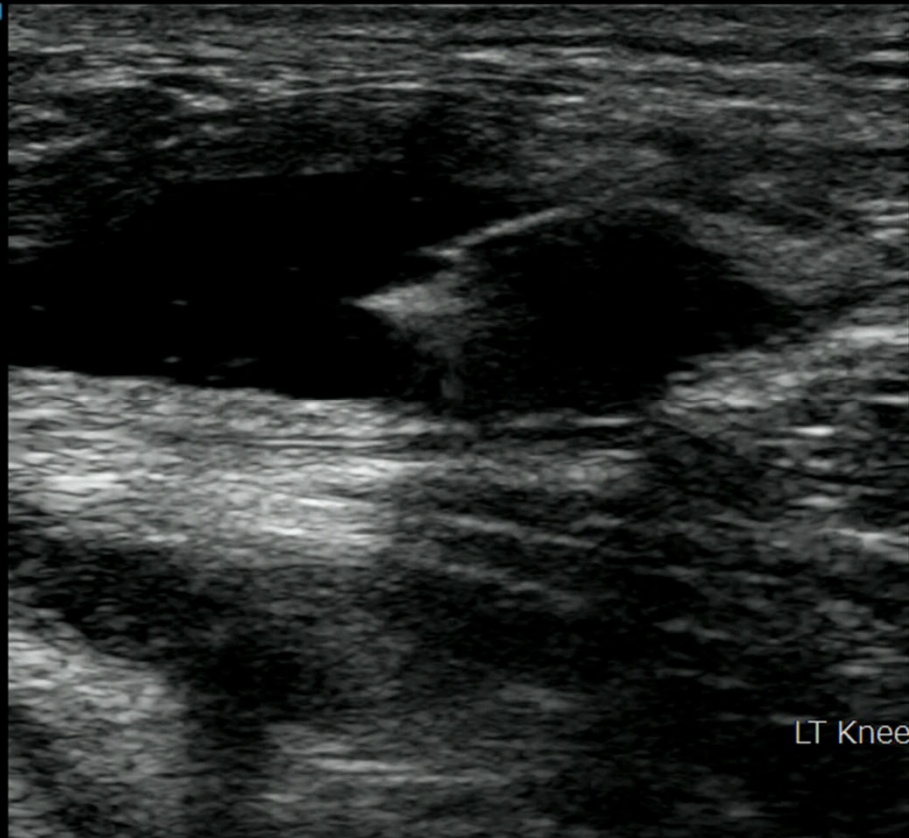
30351 : M : 56



MSK : Knee Deep

04/04/2022

10:48:27 AM



FR31
P75
Gen
8.9M
BG24
DR65

LT Knee

MI 1.0
TIS 0.3
TIB 0.3



Reimbursement Information

Jason Rand, PA-C

Physician Assistant



Reimbursement for Diagnostic Ultrasound

- Must meet all Medicare/ Insurance requirements for documentation and storage of images
- Diagnostic Ultrasound in particular requires a complete report

Musculoskeletal Ultrasound and Procedural CPT Codes and Descriptions				
CPT Code	Description	Private Office	Professional Component	Technical Component
76881	Ultrasound, extremity, nonvascular, real time with image documentation; Complete		\$33.44	\$35.26
76882	Limited ultrasound, nonvascular, real time image documentation	\$41.09	\$25.45	
76942	Ultrasonic guidance for needle placement (e.g., biopsy, aspiration, injection, localization device), imaging supervision and interpretation	\$34.01	\$33.40	

A separate written record of the ultrasound procedure

- Description of the structures or organs examined
- US findings
- Reason for the ultrasound procedure(s).

Images

- labeled with patient identification
- Facility identification
- Examination date
- The anatomical site imaged
- Transducer orientation

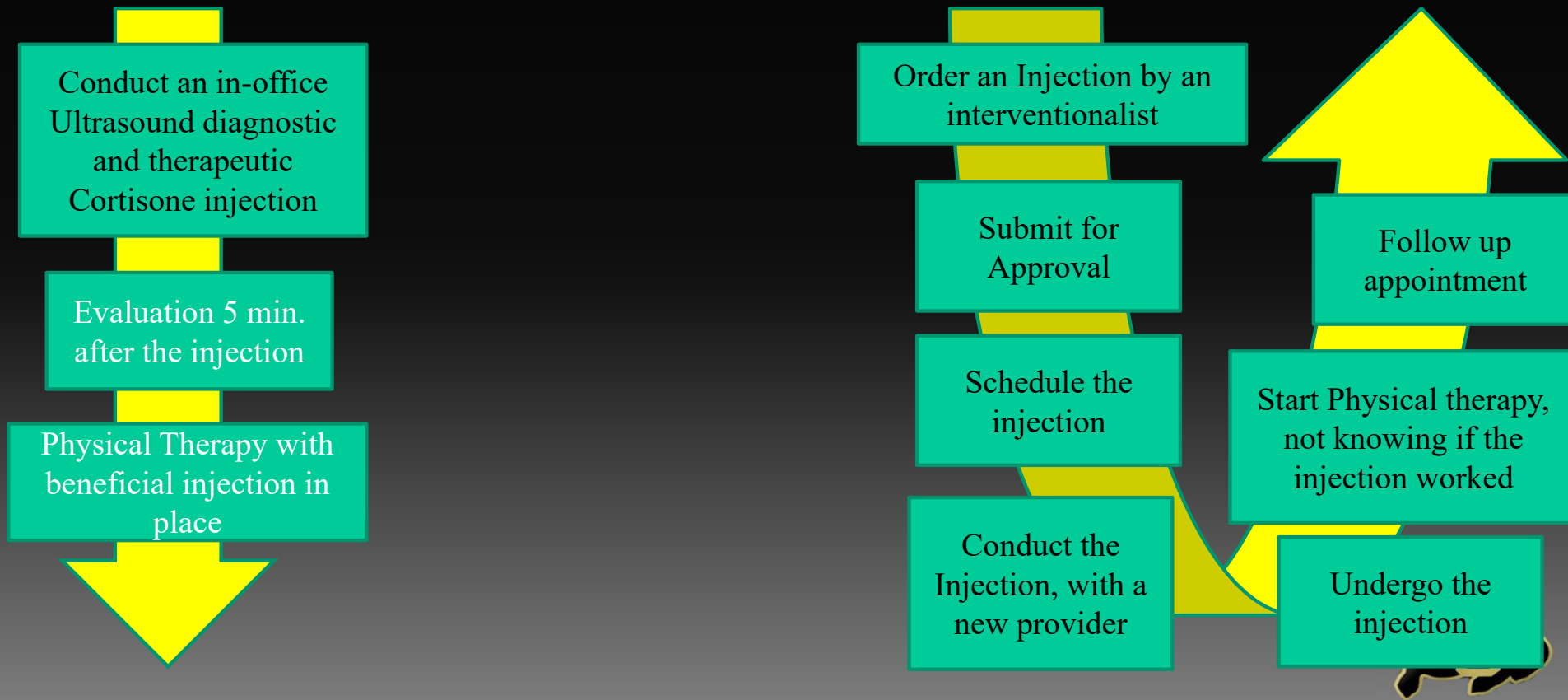


Interventional Ultrasound



Optional Tracks for the care of your patient

Suspect a labral tear of the Hip



Interventional Ultrasound Billing

Procedures that include ultrasound guidance (do not report with 76942) New codes for joint aspiration and/or injection have been created to include ultrasound guidance. The existing codes were revised to state "not using ultrasound guidance".				
CPT CODE	Description	Private Office	Professional Payment	Technical Payment
10005	Fine needle aspiration biopsy; including ultrasound guidance; first lesion	\$161.20	N/A	N/A
10006	Fine needle aspiration biopsy; including ultrasound guidance; each additional lesion (list separately in addition to code for primary procedure, e.g., CPT code 10005)	\$67.53	N/A	N/A
20604	Arthrocentesis, aspiration and/or injection, small joint or bursa (e.g., fingers, toes); with ultrasound guidance	\$95.17	N/A	N/A
20606	Arthrocentesis, aspiration and/or injection, intermediate joint or bursa (e.g., temporomandibular, acromioclavicular, wrist, elbow or ankle, olecranon bursa); with ultrasound guidance	\$103.20	N/A	N/A
20611	Arthrocentesis, aspiration and/or injection, major joint or bursa (e.g., shoulder, hip, knee, subacromial bursa); with ultrasound guidance	\$115.20	N/A	N/A

Baker's Cyst Aspiration

Procedures Once Reserved for the

Arthroscopist or Inte

Technical parameters:

- 2C TH
- Freq 5.8 MHz
- Proc. 2/60/2/4/2
- Comp. On
- Map A
- Tint 0
- Power 100
- Depth 4.5cm
- FPS 18.8
- TSI Normal

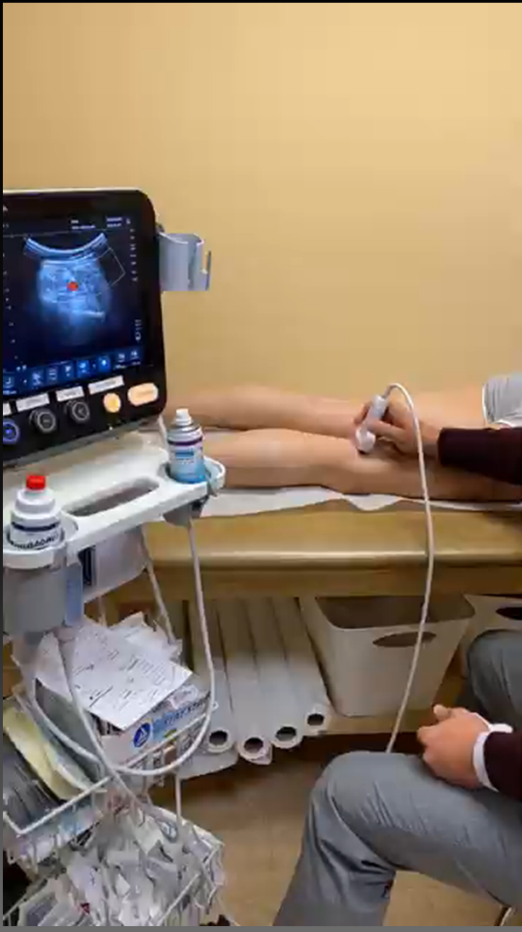Buttons:

- 2D Live
- DR 60
- Speckle Reduce 2
- Edge Enhance 2
- Persist 4
- Map A
- Tint 0
- Power 100

Bottom controls:

- Focus Pos. +
- Focus Number +
- Freq. +
- Needle Viz. +
- Up/Down
- Left/Right
- Compound
- Trapez
- Width +
- Dual Live +
- Cursor: a en

Text: R KNEE



How Ultrasound Changed My Practice

A Case Based Approach



Diagnosis

- Patient is a 57 y/o female with insidious onset of right shoulder pain. Patient has attended 2 PT sessions
- Subjective
 - Pain with overhead activity
 - Pain at the region of the lateral deltoid, not beyond the elbow
- Objective
 - Pain with empty can testing
 - No weakness with empty can testing, mild weakness with resisted external rotation

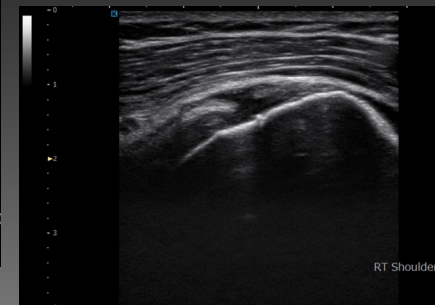
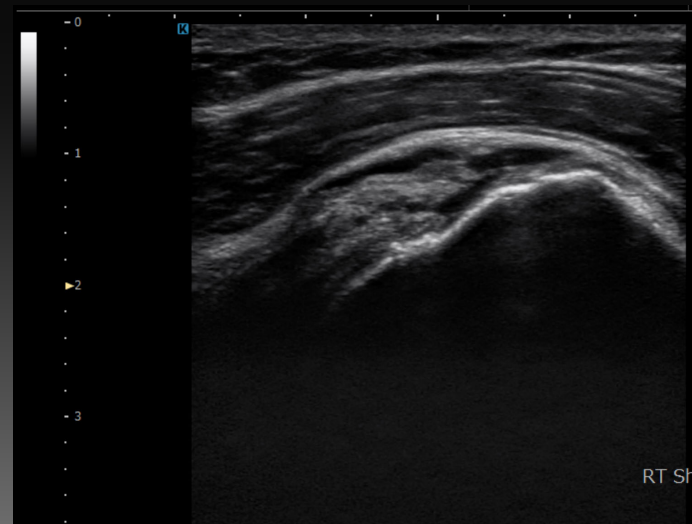
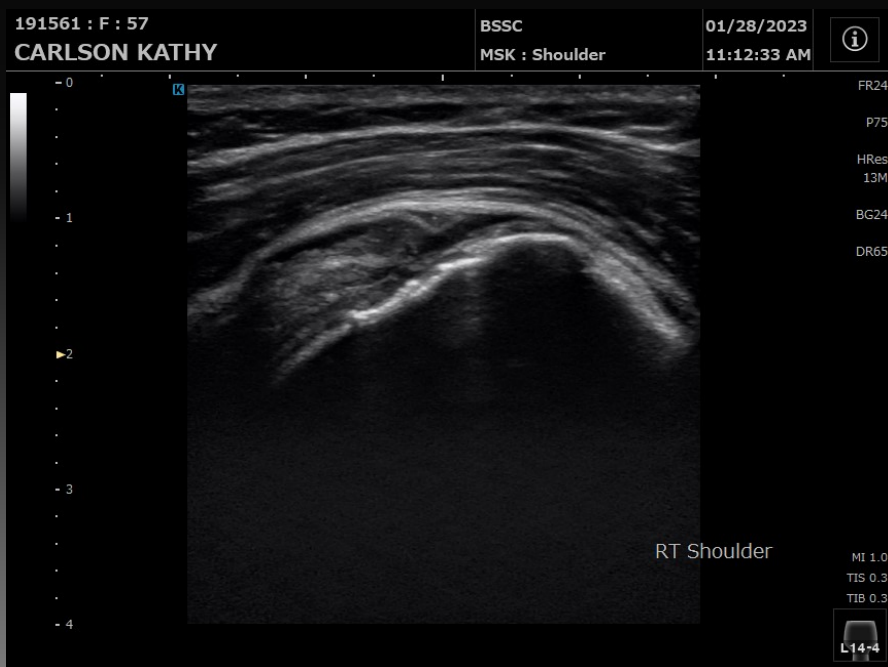Differential diagnosis

- **Differential diagnosis**
 - Rotator Cuff Impingement
 - Rotator cuff tear
 - Bicipital pathology
- **Next step in the care of the patient?**
 - MRI
 - Physical therapy
 - Injection therapy – Cortisone injection

Patient opted for a cortisone injection

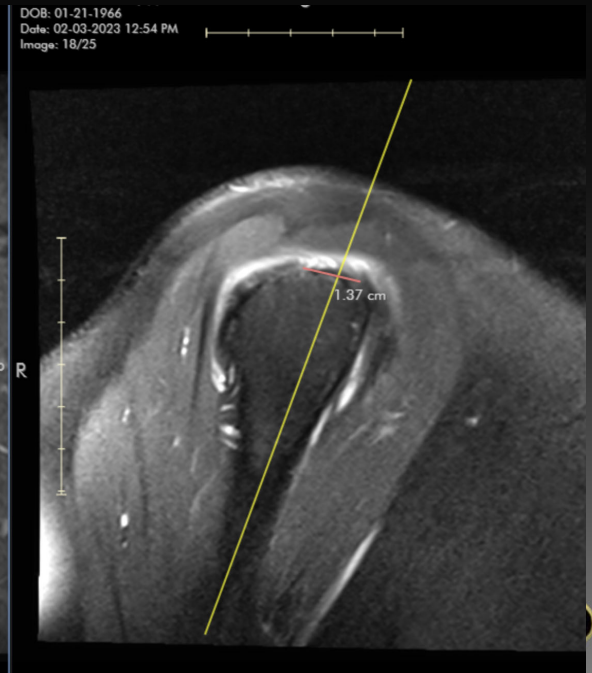
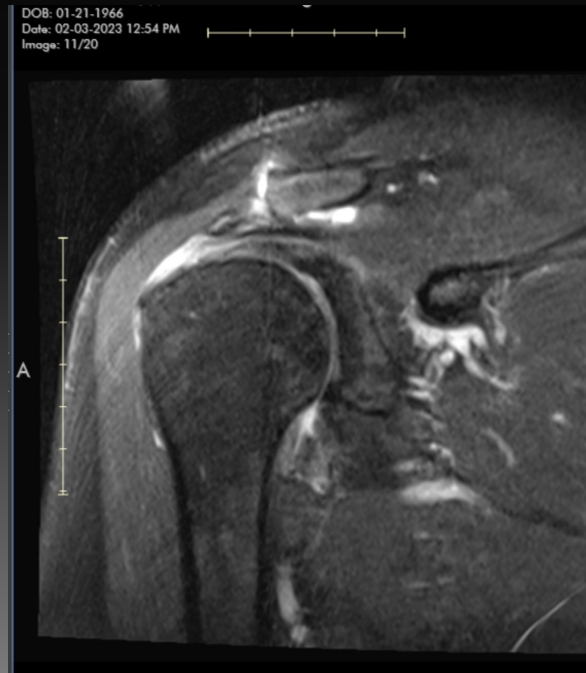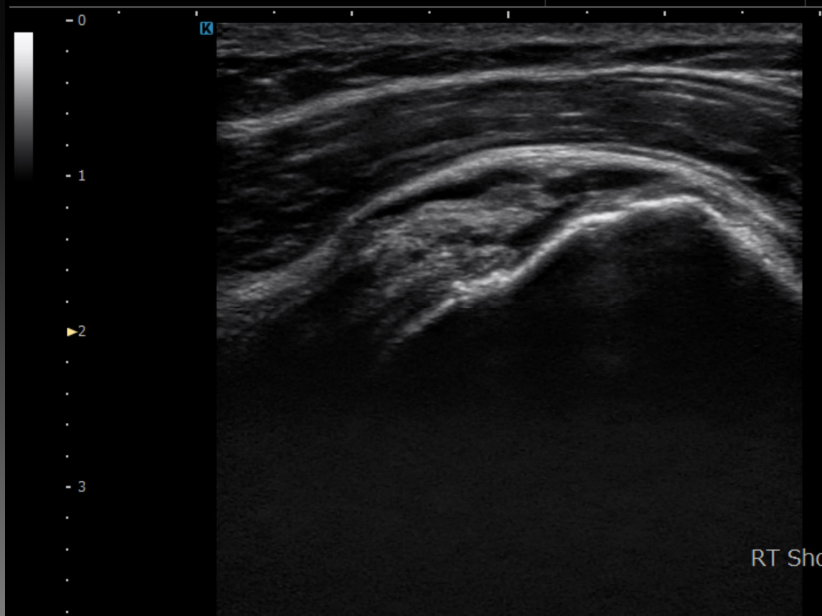
Great opportunity to evaluate rotator cuff integrity

Evaluation of rotator cuff reveals a full thickness tear of the supraspinatus



Ultrasound demonstrates a full thickness tear of the supraspinatus

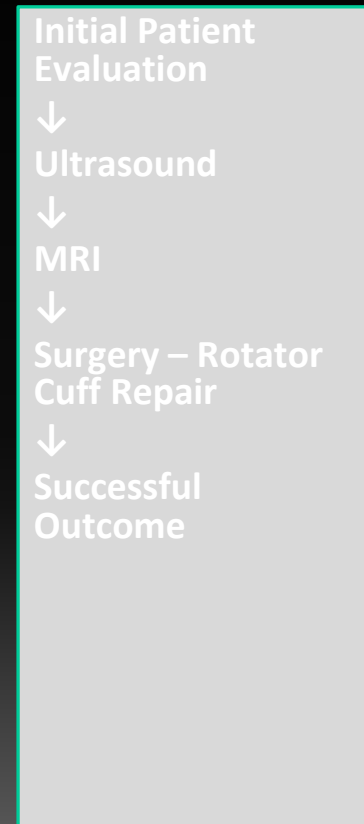
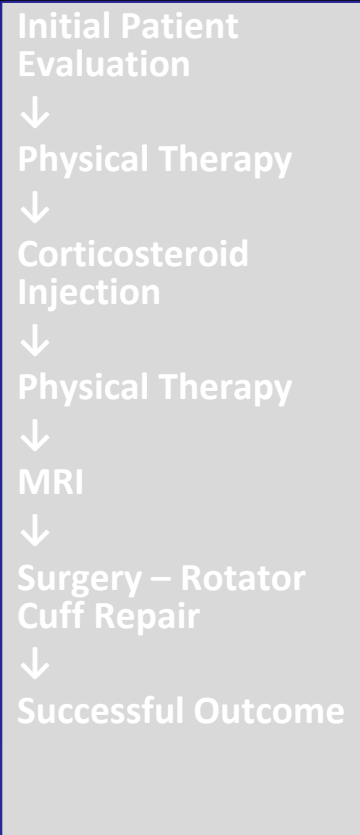
- Patients plan of care was changed from conservative to surgical



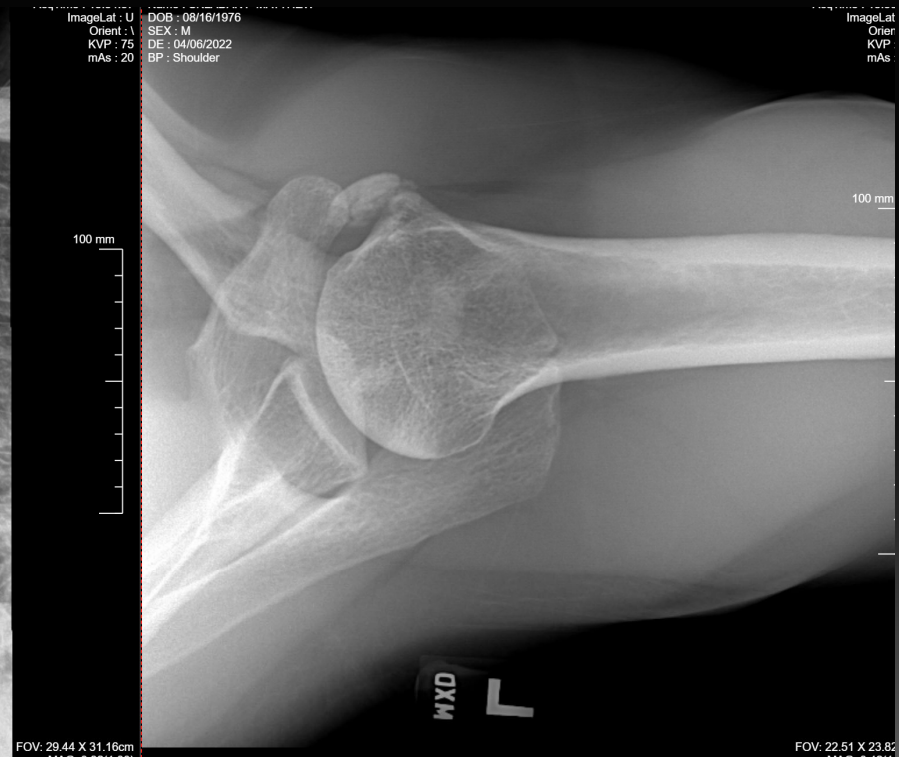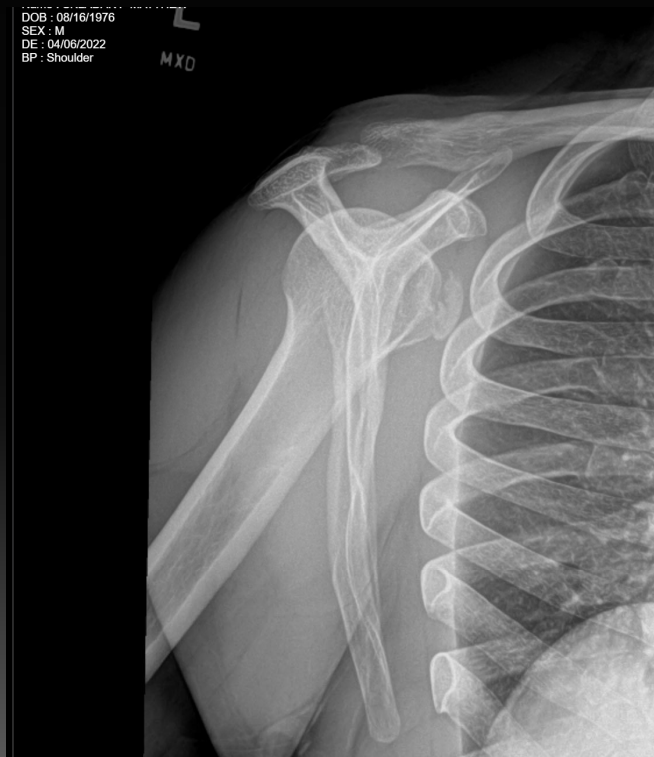Arthroscopic Rotator Cuff Repair Surgery



Two Pathways



46 y/o male with acute onset of non-traumatic lateral deltoid pain

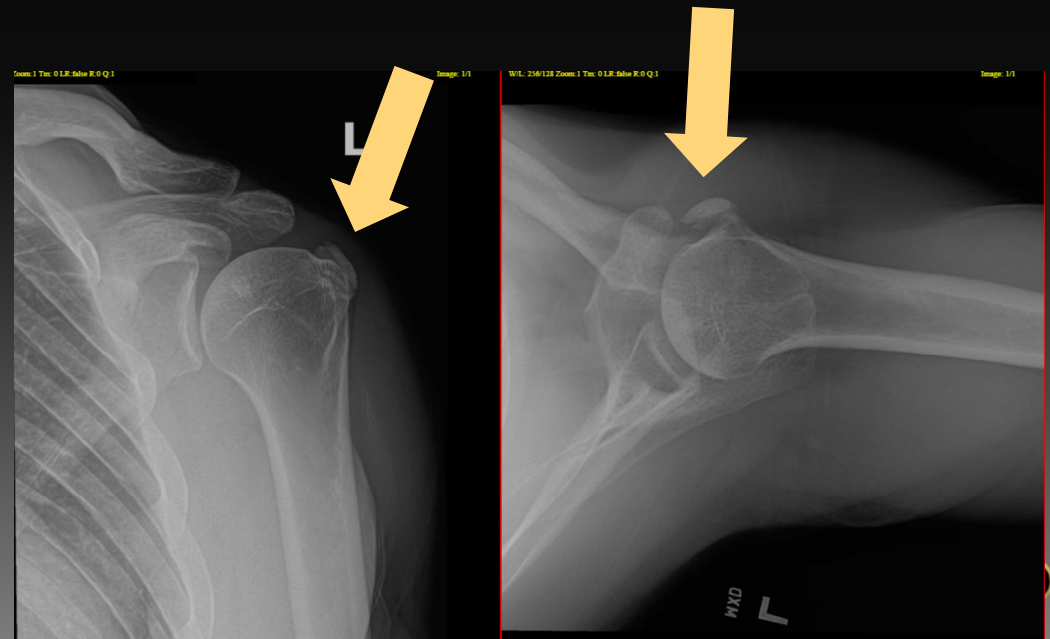


FOV: 29.44 X 31.16cm

FOV: 22.51 X 23.8cm

Calcific Tendonitis

- Collection of calcium within a tendon
- Etiology
 - Degenerative
 - Ischemic
- Presentation
 - Severe disabling pain
 - F > M
 - Spontaneous onset

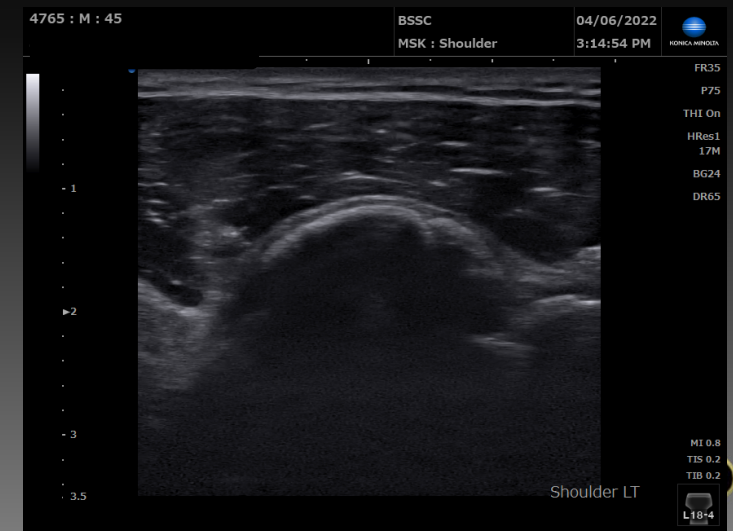
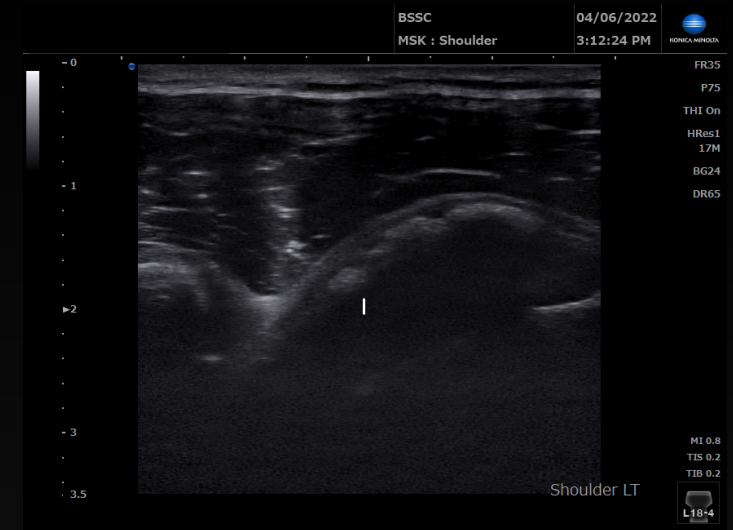
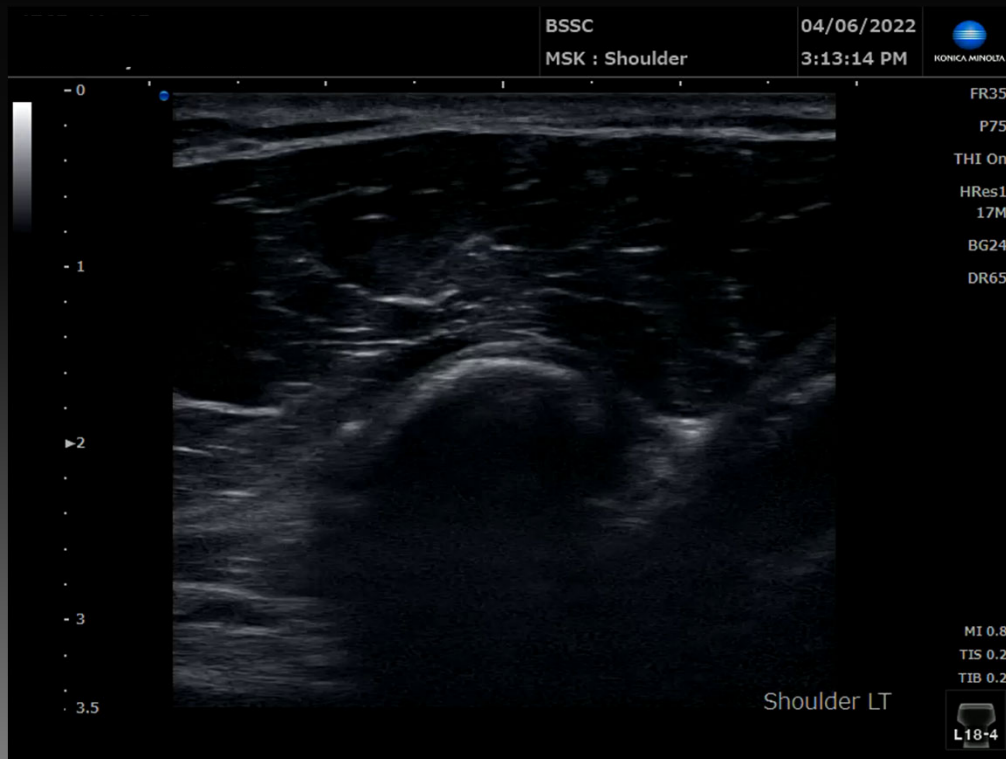


Options for treatment

- Nothing
- MRI
- Refer to Interventionalist
- Cortisone injection
- Surgery
- Ultrasound guided Barbotage or lavage or calcium

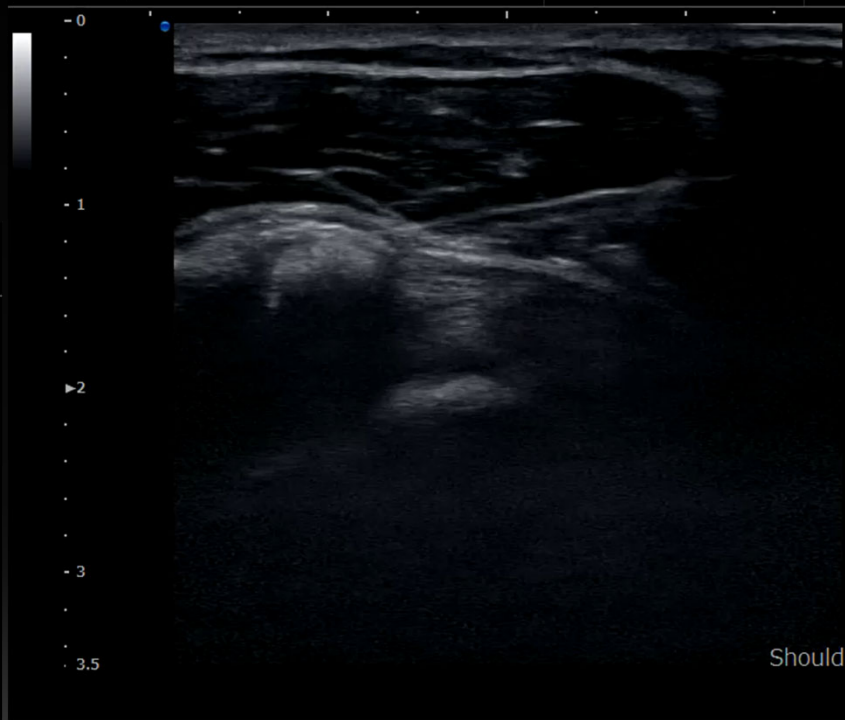
De Witte et al. described the differences observed between a group of patients treated with US-guided percutaneous needling and lavage and a group of patients treated with simple subacromial injection of corticosteroid; at one year after treatment the group of patients treated with needling showed better recovery of shoulder function (Constant score: 86/100) with respect to those treated with steroid injection; furthermore, complete resorption occurred more frequently in the patients treated with needling (13 out of 23 patients) than in those treated with corticosteroid injection (6 out of 25 patients). del Cura JL, Torre I, Zabala R, et al. Sonographically guided percutaneous needle lavage in calcific tendinitis of the shoulder: short- and long-term results. *AJR Am J Roentgenol.* 2007;189:W128-134.)

Initial Ultrasound assessment of calcium collection



BSSC
MSK : Shoulder

04/06/2022
3:18:28 PM



-0
-1
-2
-3
-3.5

FR35
P75
THI On
HRes1
17M
BG24
DR65

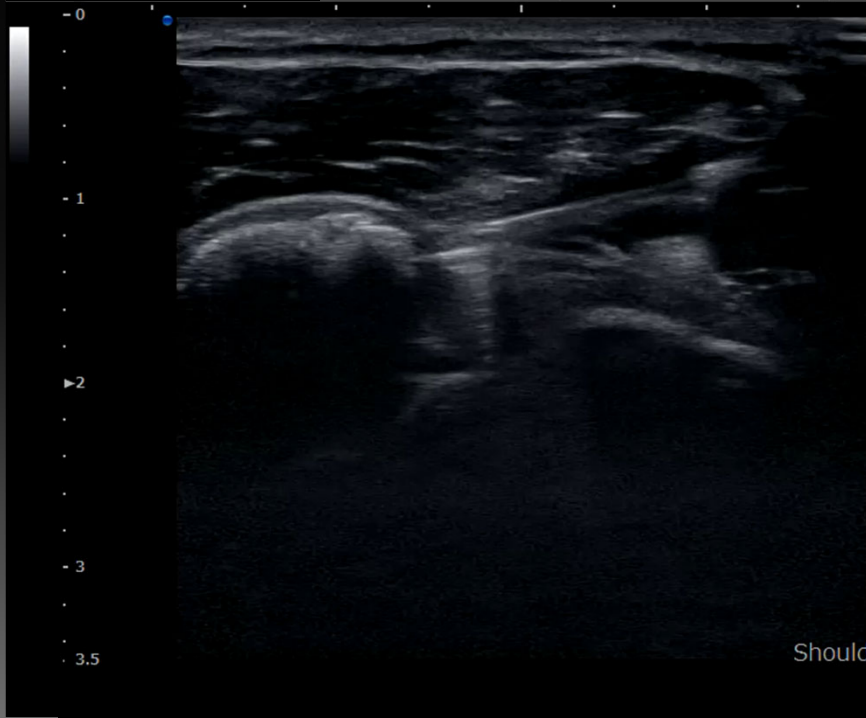
MI 0.8
TIS 0.2
TIB 0.2

Shoulder LT



BSSC
MSK : Shoulder

04/06/2022
3:16:49 PM



-0
-1
-2
-3
-3.5

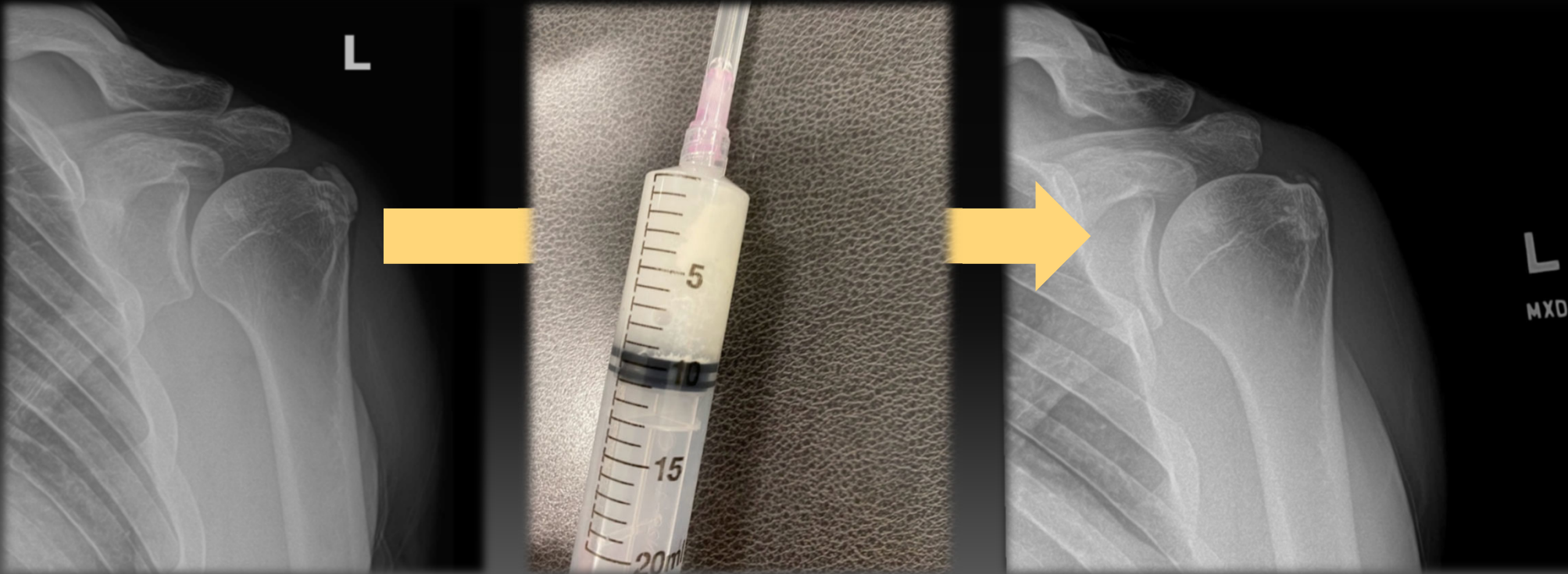FR35
P75
THI On
HRes1
17M
BG24
DR65

MI 0.8
TIS 0.2
TIB 0.2

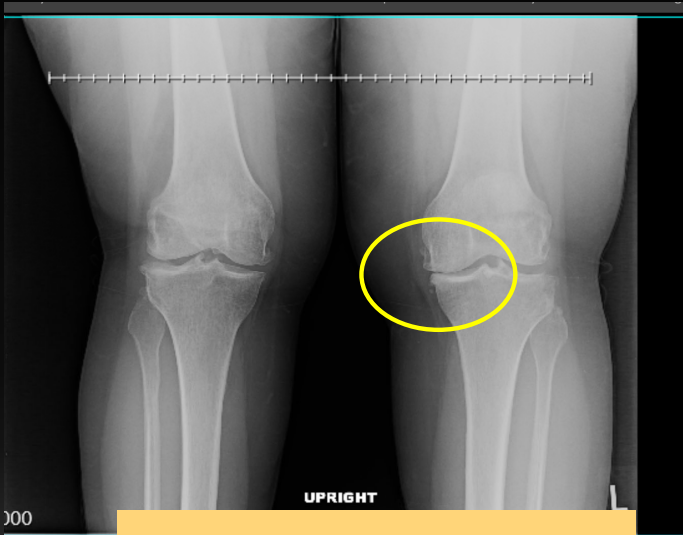
Shoulder LT



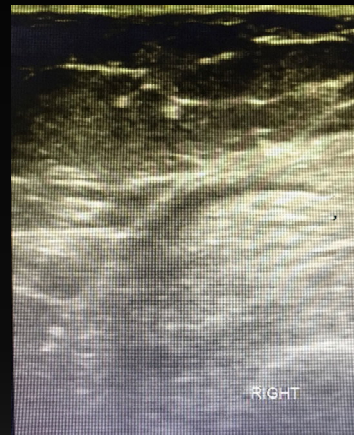Calcific Tendinitis



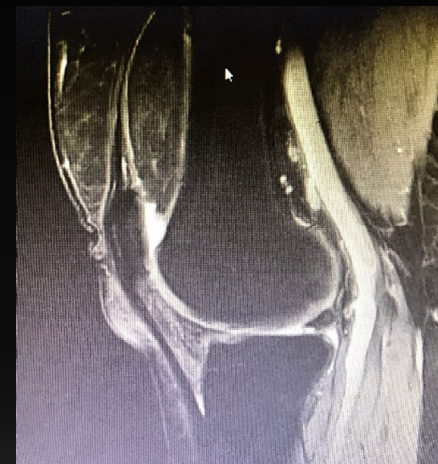Knee Osteoarthritis



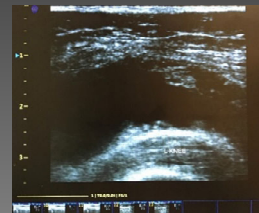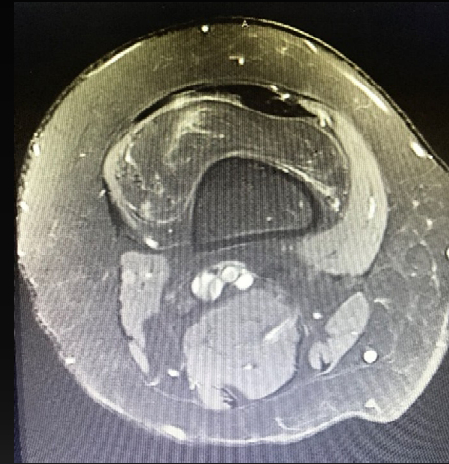
55 year old female



In-office
ultrasound



MRI



Applications of MSK US

- Evaluation of a post-operative rotator cuff repair
- Is a mass cystic or solid?
- On and On....



Thank You



Kevin Shinsako, MS, PA-C

Kevin.Shinsako@CUAnschutz.edu

Cell: 630-862-0882