

Background

Stroke is a common cause of death and disability. Common mechanisms include: a) subarachnoid hemorrhage; b) intraparenchymal hemorrhage; c) carotid or intracranial thrombosis; and d) cerebral embolism. Cerebral emboli commonly arise from left atrial thrombi associated with atrial fibrillation. Less common sources include mural thrombi in patients s/p MI, or vegetations in patients with left-sided endocarditis.

We report a case of a cerebral embolus that did not originate in any of these sites.

Case Description

A 75 y/o woman fell but did not seek medical attention for left hip pain for 24 hrs. Imaging revealed a L femoral neck fracture. PMH was positive for paroxysmal atrial fibrillation, HTN, hyperlipidemia, hypothyroidism, and s/p R THA. Medications included lisinopril, atorvastatin, L-thyroxine, and ASA. T 98.8; P 104; BP 142/94; O2sat 98%. PE was consistent with L hip fracture, but was otherwise unremarkable. She underwent successful L ORIF. Postoperatively, she became tachypneic and hypoxemic—and stated she could not move her left arm.

Stroke Assessment

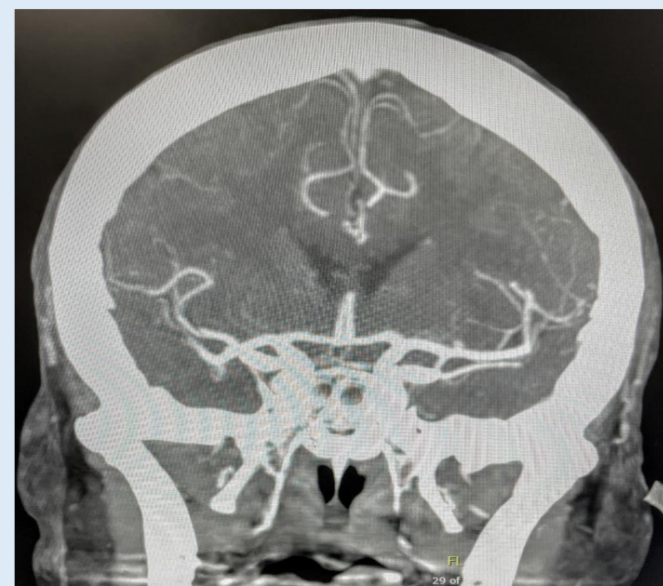
NIH-SS score of 11. Her presenting symptoms included left arm paresthesia, weakness, left facial palsy, left sided neglect and dysarthria. She was oriented to person and time but not to place.

Stroke evaluation included negative CT for bleeding, but CTA revealed occlusion at M2 of the right middle cerebral artery. ECG was negative for atrial fibrillation, and echocardiography failed to reveal a source of the presumed cerebral embolus. Emergent catheter-directed thrombectomy was successfully accomplished. After the procedure, the patient again had hypoxemia. Further work up revealed a DVT in the left iliac vein as well as pulmonary emboli.

Conclusion

Transcranial Doppler ultrasonography with bubble test was positive for a communication between the two sides of heart, consistent with a patent foramen ovale (PFO). Repeat CT of the brain revealed contrast staining versus minimal bleeding, thus, anticoagulation was not begun. Rather, the patient underwent percutaneous placement of an inferior vena cava filter. The patient had no further pulmonary or cerebral emboli and regained some strength on the left side prior to transfer to inpatient rehabilitation.

Picture showing the M2 artery occlusion

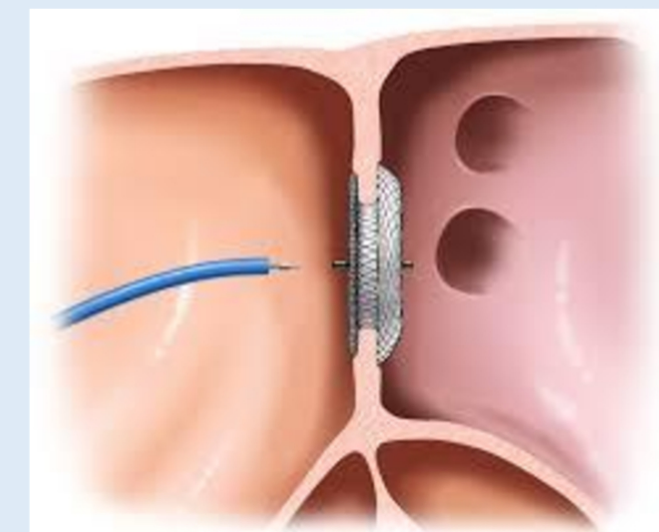


Discussion

A patent foramen ovale is an opening between the atria that fails to close on its own after childbirth. It has been shown to remain in 25% of people. While strokes derived from a PFO are still uncommon, those with a cryptogenic stroke have been shown to be four times more likely to have a PFO. Because 40% of ischemic strokes are cryptogenic, it is important to investigate this possibility in appropriate patients, such as our case, who appears to have suffered a stroke from a “so-called” paradoxical embolus—beginning in the venous circulation. This is why it is called a paradoxical embolus, because venous clots “should only” embolize to the lungs—not the brain.

Once a PFO is identified, it can be closed, decreasing the risk of stroke. The 2017 RESPECT study showed closing a PFO could greatly reduce the risk of further strokes in patients with histories of cryptogenic strokes. Ten year follow up of a series of patients who underwent percutaneous implantation of a PFO closure device showed 45% reduction in rate of strokes. In our case, added protection was afforded by the inferior vena cava filter, which would decrease the risk of emboli to the lungs or paradoxically. While rare, it is paramount for patients deemed high risk to be evaluated for this as a cause of an acute ischemic stroke.

Example of a PFO closure



References

1. Mojadidi MK, Zaman MO, Elgendy IY, et al. Cryptogenic stroke and patent foramen ovale. *Journal of the American College of Cardiology*. 2018;71(9):1035-1043. doi:10.1016/j.jacc.2017.12.059
2. Miranda B, Fonseca AC, Ferro JM. Patent foramen ovale and stroke. *J Neurol*. 2018;265(8):1943-1949. doi:10.1007/s00415-018-8865-0
3. Saver JL, Al. E., Investigators* for the RESPECT, et al. Long-term outcomes of patent foramen ovale closure or medical therapy after stroke: New England Journal of Medicine. <https://www.nejm.org/doi/full/10.1056/NEJMoa1610057>. Published September 14, 2017. Accessed September 26, 2022.
4. Rais G, Vassallo P, Schorer R, Bollen Pinto B, Putzu A. Patent foramen ovale and perioperative stroke in noncardiac surgery: A systematic review and meta-analysis. *British Journal of Anaesthesia*. 2022;129(6):898-908. doi:10.1016/j.bja.2022.06.036