

Infectious Disease and Orthopedics

August 2023

Alissa Hankee PA-C

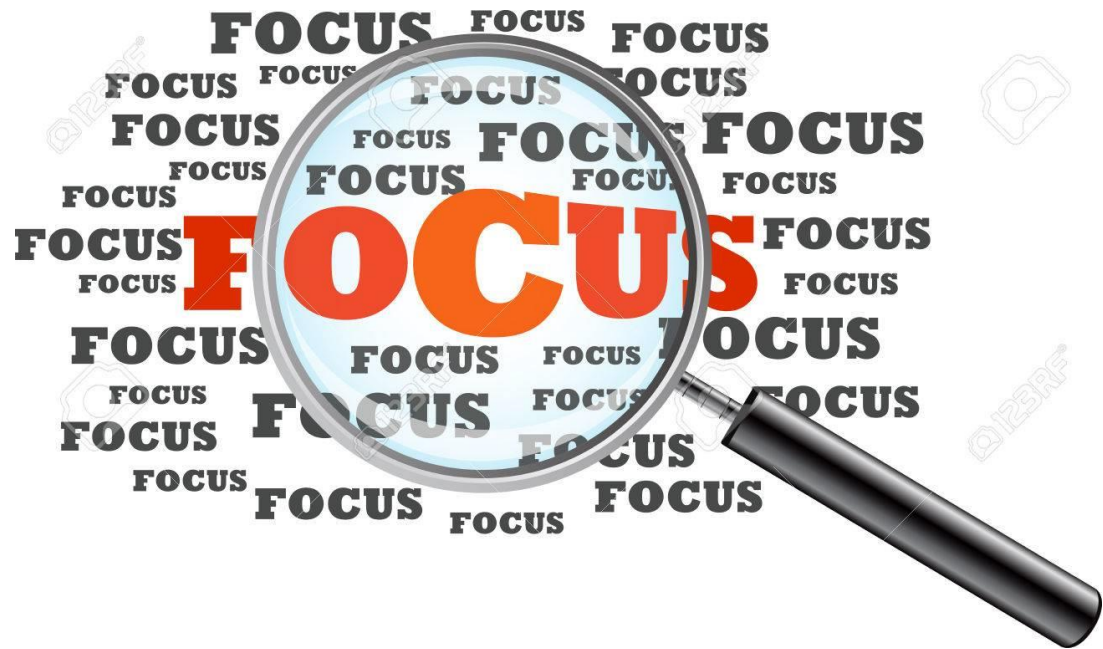

IU Health Physicians

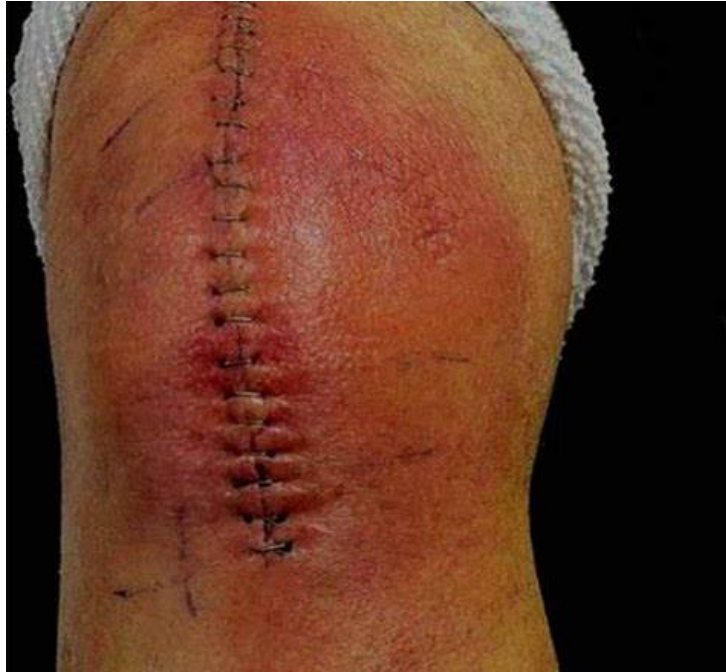BEST OF BOTH

WORLDS





What is the ID provider thinking?



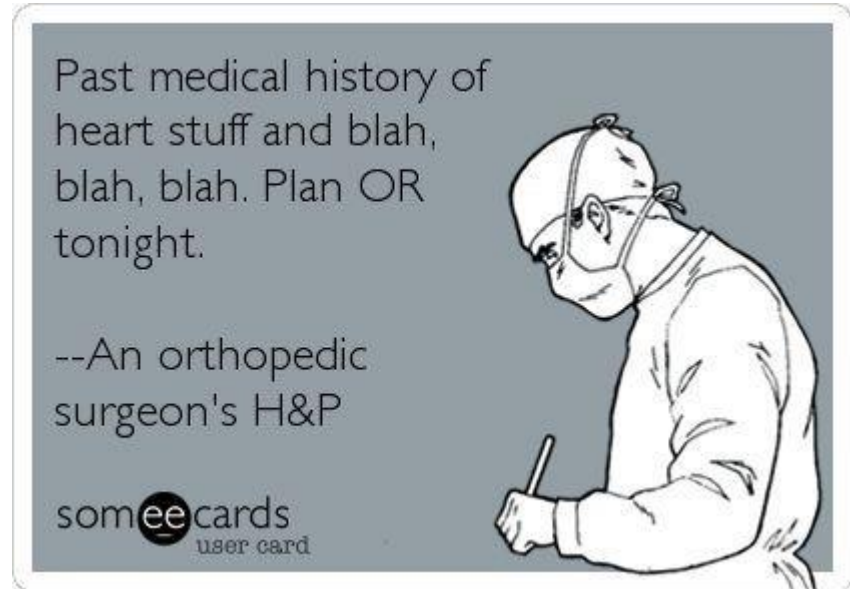
- Real pathogen v Contaminant
- How long does the patient need antibiotics
- IV v PO abx
- PO suppression for how long?
- Should hardware be removed after healing if no signs of infection



I was over in the airport bar and the bartender says, 'We don't serve germs here.'
So I told him, 'Well you're not a very good host.'

Host Optimization

- Modifiable risk factors
 - Obesity
 - DM
 - RA
 - Depression
 - Immunosuppressive medications
 - Nicotine use
 - Malnutrition
 - Alcohol abuse
 - IV Drug use
 - HIV infection



2014 IDSA Guidelines for Skin and Soft Tissue Infections

Cellulitis (most common pathogen is **strep**)

- Outpatient therapy is recommended for patients with cellulitis

Exclusions

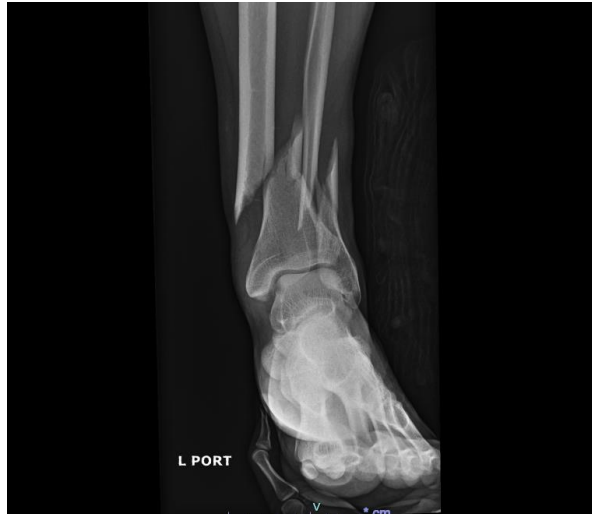- SIRS, Altered Mental Status, Hemodynamic Instability
- Concern for deeper necrotizing infection
- Patient with poor adherence
- Severely immunocompromised
- Failure of outpatient therapy

- Stevens DL et al. *Clinical Infectious Diseases*. 59(2):e10-e52



Cellulitis Case #1

- 36 yr old male
- PMH: Nicotine dependence
- HPI: work related injury 3/22/23 fell from 3 ft height off excavator (closed fx)

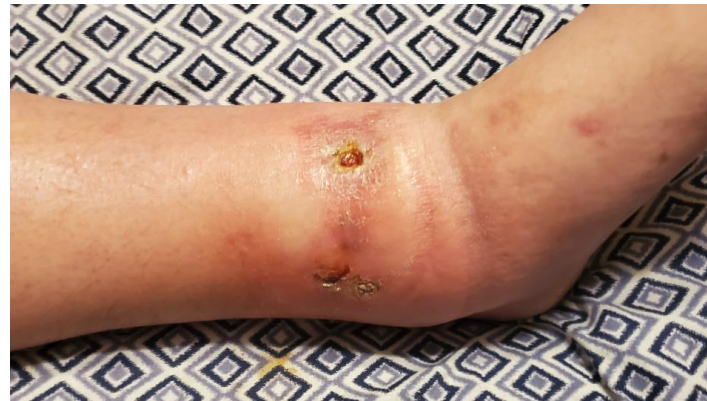
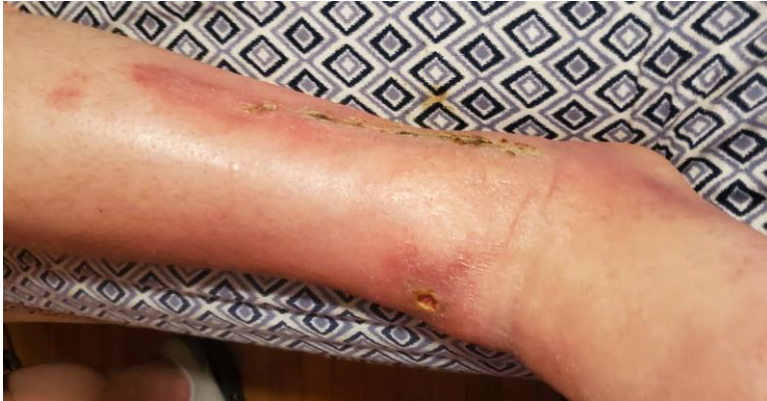
Cellulitis Case #1 cont.

- Closed reduction/splinting in ED
- The following day→ IM nailing L tibia, ORIF L fibula at OSH
- 6/14/23 repair malunion/nonunion L tib/fib
 - IM Nail removed, plate and screws fibula removed, osteotomy lateral malleolus, repair nonunion w/infuse, allograft, Infuse over anterior aspect of nonunion site
- Ongoing issues since start of July 2023 with anterior wound, redness, swelling
 - Bactrim DS 1 tab PO BID 7/3/23 x 10 days

Cellulitis Case #1 cont.

- Referred to ID outpatient, seen within a couple days of referral, not on abx at time of consult
- No recent labs or imaging
- Band aid over anterior wound



WHAT WORK UP?

- CBC w/diff
- BMP
- ESR
- CRP
- HgbA1C
- CT Scan L ankle w/contrast
- Doxycycline 100 mg po BID x 14 days
- Keflex 1000 mg po q 6 hr x 14 days
- Wound cx taken at appt: not great specimen

STAPHYLOCOCCUS AUREUS

	MDIL	MINT
Vancomycin	≤ 0.5	S
Tetracycline	≤ 1	S
Trimethoprim/Sulfa	≤ 10	S
Rifampin	≤ 0.5	S
Oxacillin*	0.5	S

*** Oxacillin* Note:

* Cephem agents, including cephalosporins, with clinical efficacy and adr

Minocycline	≤ 0.5	S
Gentamicin	≤ 0.5	S
Erythromycin		R
Clindamycin		R
Cefazolin		S

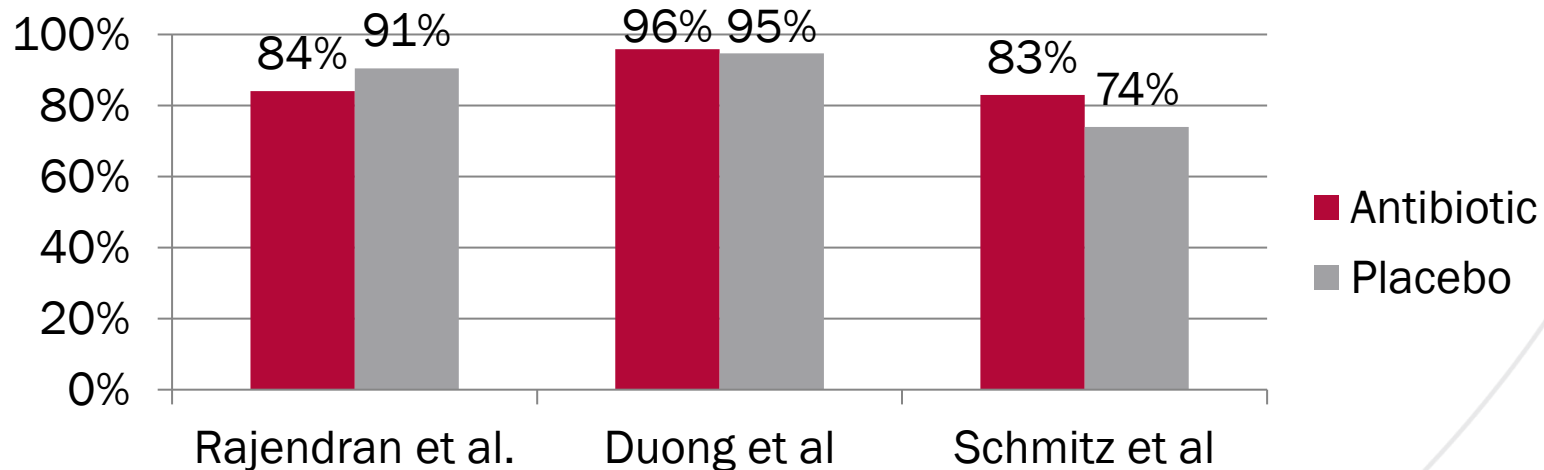
Soft Tissue Infection

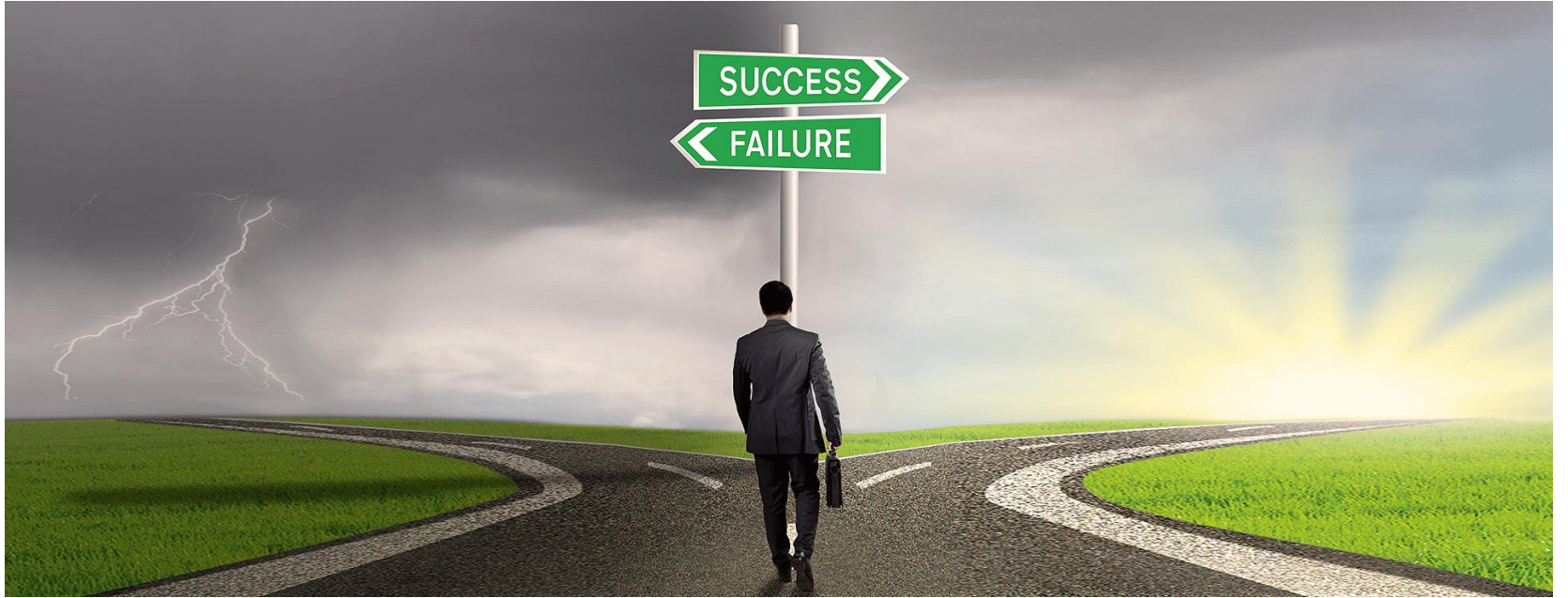2014 IDSA Guidelines for Skin and Soft Tissue Infections

■ **Abscesses** (most common pathogen is **S. aureus**)

■ Incision and drainage alone is primary treatment

– Addition of antibiotics:





Factors predisposing to bone infection

Immunosuppressive conditions

Malnutrition & general debility

Diabetes mellitus

Corticosteroid administration

Immune deficiency

Immunosuppressive drugs

Poor limbs circulations

Venous stasis in the limb

Peripheral vascular disease

Trauma

Loss of sensibility

Iatrogenic invasive measures

Osteomyelitis

- Normal bone highly resistant to infection
- Osteomyelitis develops when there is a large inoculation of organisms, presence of bone damage, and/or presence of hardware or foreign material
- Factors
 - Virulence of infecting organism (MSSA, MRSA, PsA)
 - Host immune status
 - Bone vascularity

Best Abx for Bone Penetration without Ischemia present

- Zosyn
- Cefazolin
- Cephalexin (Keflex)
- Cefadroxil
- Ceftriaxone
- Cefepime
- Cipro
- Doxycycline
- Vanc
- Daptomycin (not as good as Vanc)
- Linezolid
- Bactrim
- Dalbavancin
- Metronidazole

Diagnosis and Management of Prosthetic Joint Infection: Clinical Practice Guidelines by the Infectious Diseases Society of America^a

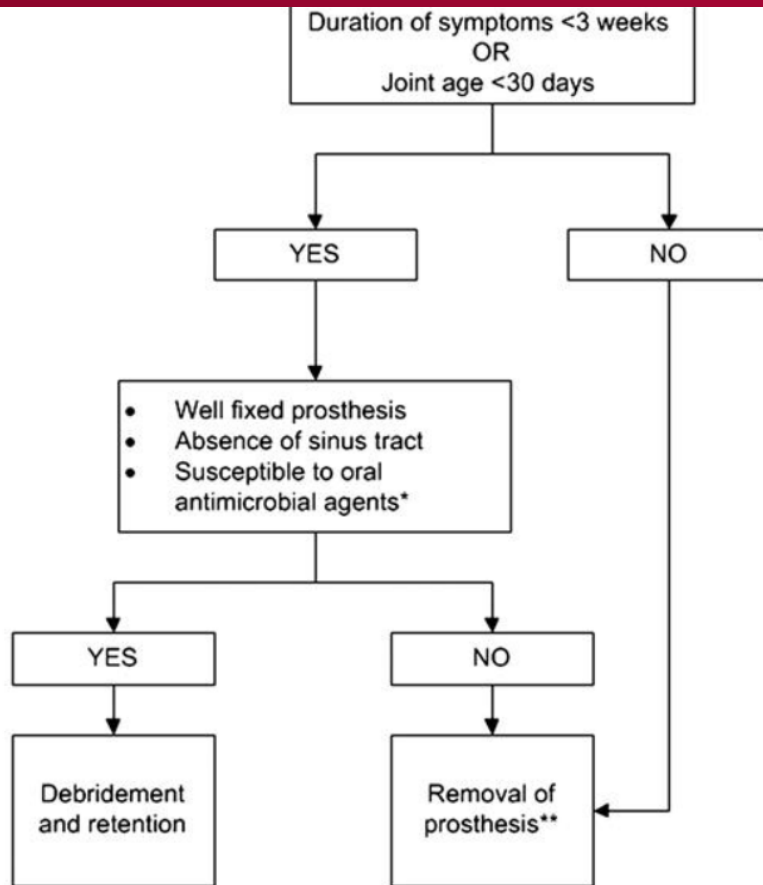
Douglas R. Osmon , Elie F. Berbari, Anthony R. Berendt, Daniel Lew, Werner Zimmerli, James M. Steckelberg, Nalini Rao, Arlen Hanssen, Walter R. Wilson [Author Notes](#)

Clinical Infectious Diseases, Volume 56, Issue 1, 1 January 2013, Pages e1–e25,
<https://doi.org/10.1093/cid/cis803>

Published: 06 October 2012 **Article history** ▼

Prosthetic Joint Infection

- Suspected in:
 - Sinus tract or persistent wound drainage over prosthesis
 - Acute onset of painful prosthesis
 - Chronic painful prosthesis at any time after implantation
 - In the absence of a pain free interval
 - First few years following implantation
 - Hx of prior wound healing problems or superficial or deep infection
 - Work up
 - ESR
 - CRP
 - Xray
 - Diagnostic arthrocentesis (unless dx is clinically evident and sx planned)
 - **Best to hold abx 2 wks prior (if medically stable)**
 - **Synovial fluid analysis**
 - Blood cx if febrile



Staph PJI → s/p debridement, poly exchange, 1 stage

Microorganism	Preferred Treatment ^a	Alternative Treatment ^a	Comments
Staphylococci, oxacillin-susceptible	Nafcillin ^b sodium 1.5–2 g IV q4-6 h or Cefazolin 1–2 g IV q8 h or Ceftriaxone ^c 1–2 g IV q24 h	Vancomycin IV 15 mg/kg q12 h or Daptomycin 6 mg/kg IV q 24 h or Linezolid 600 mg PO/IV every 12 h	See recommended use of rifampin as a companion drug for rifampin-susceptible PJI treated with debridement and retention or 1-stage exchange in text
Staphylococci, oxacillin-resistant	Vancomycin ^d IV 15 mg/kg q12 h	Daptomycin 6 mg/kg IV q24 h or Linezolid 600 mg PO/IV q12 h	See recommended use of rifampin as a companion drug for rifampin-susceptible PJI treated with debridement and retention or 1-stage exchange in text



6 wks IV abx



Po abx suppression x 6 months

Po abx suppression x 3 months

- The patient has:**
- THA
 - 6 wks IV abx or highly bioavailable po abx
 - Good bone stock
 - Susceptible to oral agents with high oral bioavailability
 - Use of antibiotics impregnated bone cement for fixation
 - No bone grafting required

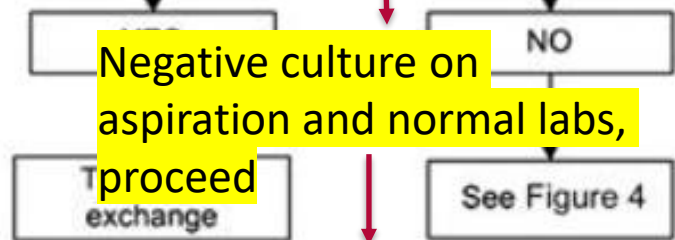
Po abx suppression x 3-6 months per previous slide

One-stage exchange*

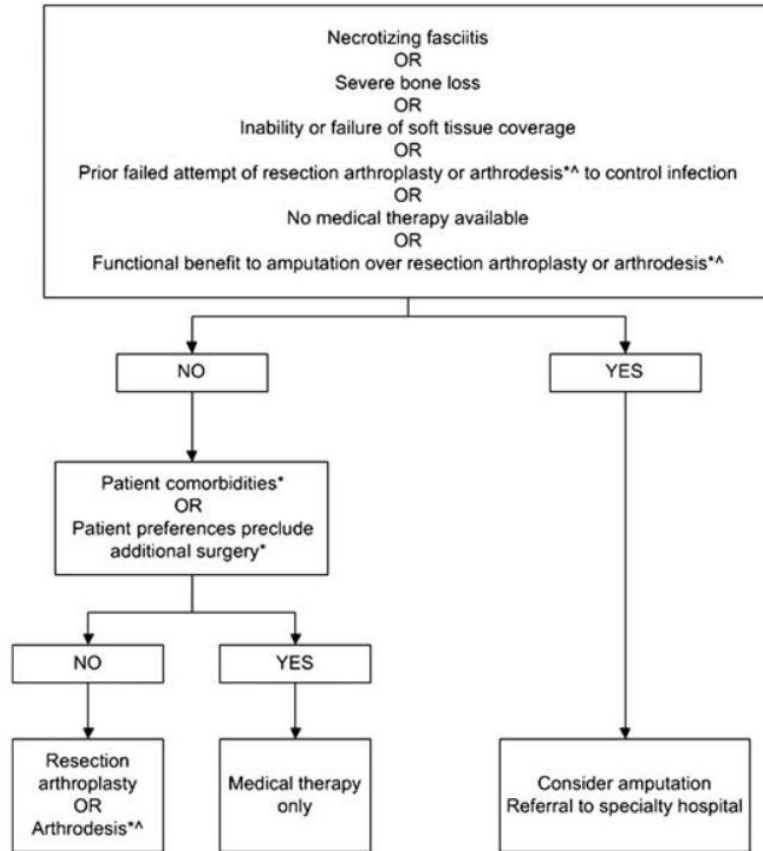
*Uncommonly performed in the U.S.

**Relative indications see text

- The patient has:
- 6 wks of IV abx or highly bioavailable po abx
 - Difficult to treat micro-organisms, AND
 - No prior two-stage exchange for infection or prior two-stage exchange and reason for failure, AND
 - Repeat inflammatory markers
 - Aspiration of joint 2-4 wks post abx completion

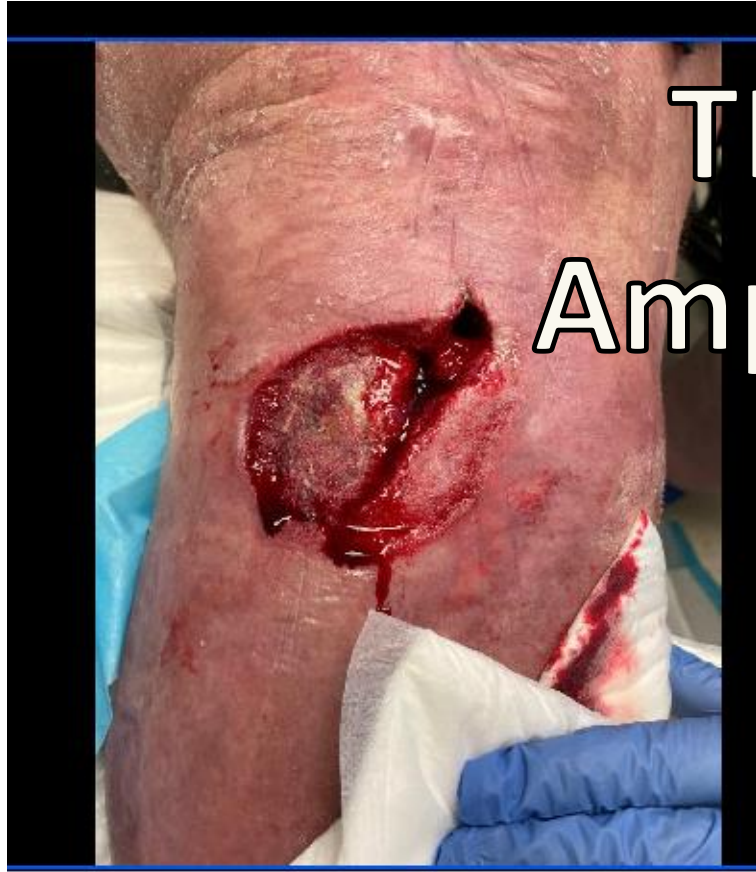

Po abx use ongoing discussion, sx preference



*For TKA or TEA only

Abx 24-48 hr
post amputation
assuming all
infected bone
and soft tissue
removed and no
bacteremia or
sepsis



TKA →

Amputation

Table 2. Intravenous or Highly Bioavailable Oral Antimicrobial Treatment of Common Microorganisms Causing Prosthetic Joint Infection (B-III Unless Otherwise Stated in Text)

Microorganism	Preferred Treatment ^a	Alternative Treatment ^a	Comments
Staphylococci, oxacillin-susceptible	Nafcillin ^b sodium 1.5–2 g IV q4-6 h or Cefazolin 1–2 g IV q8 h or Ceftriaxone ^c 1–2 g IV q24 h	Vancomycin IV 15 mg/kg q12 h or Daptomycin 6 mg/kg IV q 24 h or Linezolid 600 mg PO/IV every 12 h	See recommended use of rifampin as a companion drug for rifampin-susceptible PJI treated with debridement and retention or 1-stage exchange in text
Staphylococci, oxacillin-resistant	Vancomycin ^d IV 15 mg/kg q12 h	Daptomycin 6 mg/kg IV q24 h or Linezolid 600 mg PO/IV q12 h	See recommended use of rifampin as a companion drug for rifampin-susceptible PJI treated with debridement and retention or 1-stage exchange in text
<i>Enterococcus</i> spp, penicillin-susceptible	Penicillin G 20–24 million units IV q24 h continuously or in 6 divided doses or Ampicillin sodium 12 g IV q24 h continuously or in 6 divided doses	Vancomycin 15 mg/kg IV q12 h or Daptomycin 6 mg/kg IV q24 h or Linezolid 600 mg PO or IV q12 h	4–6 wk. Aminoglycoside optional Vancomycin should be used only in case of penicillin allergy
<i>Enterococcus</i> spp, penicillin-resistant	Vancomycin 15 mg/kg IV q12 h	Linezolid 600 mg PO or IV q12 h or Daptomycin 6 mg IV q24 h	4–6 wk. Addition of aminoglycoside optional
<i>Pseudomonas aeruginosa</i>	Cefepime 2 g IV q12 h or Meropenem ^e 1 g IV q8 h	Ciprofloxacin 750 mg PO bid or 400 mg IV q12 h or Ceftazidime 2 g IV q8 h	4–6 wk Addition of aminoglycoside optional Use of 2 active drugs could be considered based on clinical circumstance of patient. If aminoglycoside in spacer, and organism aminoglycoside susceptible than double coverage being provided with recommended IV or oral monotherapy
<i>Enterobacter</i> spp	Cefepime 2 g IV q12 h or Ertapenem 1 g IV q24 h	Ciprofloxacin 750 mg PO or 400 mg IV q12 h	4–6 wk.
Enterobacteriaceae	IV β -lactam based on in vitro susceptibilities or Ciprofloxacin 750 mg PO bid		4–6 wk
β -hemolytic streptococci	Penicillin G 20–24 million units IV q24 h continuously or in 6 divided doses or Ceftriaxone 2 g IV q24 h	Vancomycin 15 mg/kg IV q12 h	4–6 wk Vancomycin only in case of allergy

Microorganism	Preferred Treatment ^a	Alternative Treatment ^a	Comments
<i>Propionibacterium acnes</i>	Penicillin G 20 million units IV q24 h continuously or in 6 divided doses or Ceftriaxone 2 g IV q24 h	Clindamycin 600–900 mg IV q8 h or clindamycin 300–450 mg PO qid or Vancomycin 15 mg/kg IV q12 h	4–6 wk Vancomycin only in case of allergy

Table 3. Common Antimicrobials Used for Chronic Oral Antimicrobial Suppression (B-III Unless Otherwise Stated in Text)^{a,b}

Microorganism	Preferred Treatment	Alternative Treatment
Staphylococci, oxacillin-susceptible	Cephalexin 500 mg PO tid or qid or Cefadroxil 500 mg PO bid	Dicloxacillin 500 mg PO tid or qid Clindamycin 300 mg PO qid Amoxicillin-clavulanate 500 mg PO tid
Staphylococci, oxacillin-resistant	Cotrimoxazole 1 DS tab PO bid Minocycline or doxycycline 100 mg PO bid	
β-hemolytic streptococci	Penicillin V 500 mg PO bid to qid or Amoxicillin 500 mg PO tid	Cephalexin 500 mg PO tid or qid
<i>Enterococcus</i> spp, penicillin susceptible	Penicillin V 500 mg PO bid to qid or Amoxicillin 500 mg PO tid	
<i>Pseudomonas aeruginosa</i>	Ciprofloxacin 250–500 mg PO bid	
Enterobacteriaceae	Cotrimoxazole 1 DS tab PO bid	β-lactam oral therapy based on in vitro susceptibilities
<i>Propionibacterium</i> spp	Penicillin V 500 mg PO bid to qid or Amoxicillin 500 mg PO tid	Cephalexin 500 mg PO tid or qid Minocycline or doxycycline 100 mg PO bid

Abbreviations: bid, twice daily; DS, double strength; PO, per oral; qid, 4 times daily; tid, 3 times daily.

^a Antimicrobial dosage needs to be adjusted based on patients' renal and hepatic function. Antimicrobials should be chosen based on in vitro susceptibility as well as patient drug allergies, intolerances, and potential drug interactions or contraindications to a specific antimicrobial.

^b Clinical and laboratory monitoring for efficacy and safety should occur based on the clinical judgment of the clinician caring for the patient. The possibility of prolonged QTc interval and tendinopathy should be discussed and monitored when using fluoroquinolones. The possibility of *Clostridium difficile* colitis should also be discussed when using any antimicrobial.

P.Acnes (Cutibacterium) Prosthetic Joint Infection

- Part of skin normal flora, conjunctiva, oral cavity, intestinal
- ability to form a biofilm, utilizes to evade and resist the host's immune response.
- Incubation on culture may take up to 21 days—hold cultures longer than 5 days
- Tx= I&D, 6 wks abx therapy, single and 2 stage revision
- PCN, Amoxicillin, Ceftriaxone
- TSA most common

Propionibacterium acnes

Penicillin G 20 million units IV q24 h continuously or i
or
Ceftriaxone 2 g IV q24 h

Fracture Related Infection

- 5-10% of Trauma pts
- Can enter at time of injury with **contamination**, during **surgery**, **surgical incision inoculation**
- Diagnosis: multi stage process
 - Clinically: purulent drainage, wound breakdown
 - Presence of fistula, sinus tract down to bone/hardware
 - Local redness, swelling, increased pain, fever, chills
 - Serum Inflammatory Markers: ESR, CRP, CBC w/diff
 - Leukocytes/Neutrophils are 1st responders (WBC will also increase in surgery, trauma, malignancies, systemic inflammatory disease so be careful)
 - CRP: increases in infection, tissue damage, ACS (after fx typically will return to normal 2 wks later)
 - Imaging: xray, US, CT, MRI, WBC tagged scan, PET scan
 - Universally accepted suggestive signs of infection on conventional radiography and CT scan are implant loosening, bone lysis, failure of progression of bone healing (nonunion), sequestration, and periosteal bone formation.

FRI cont.

- Microbiology: confirmation of pathogen on 2 separate OR/deep tissue cx
- Antibiotic susceptibility will determine choice of antibacterial treatment
- “ Do they really need to stay until the cultures are back? “
- Avoid abx 2 wks prior to sx if possible

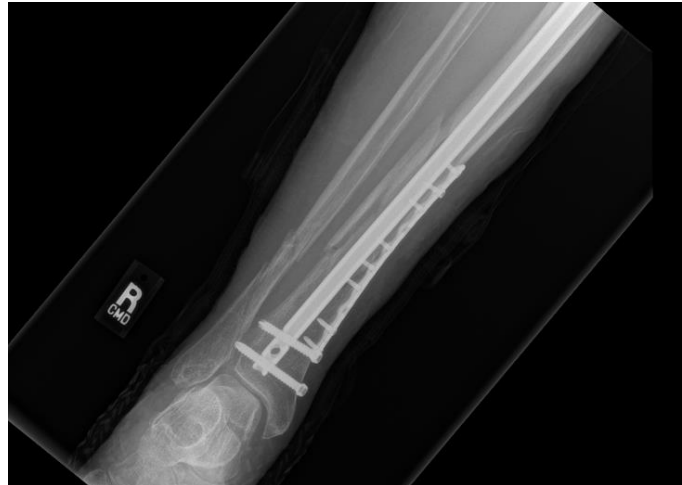- How long should a patient be on abx
 - Debridement w/removal of retained hardware
 - At least until debrided bone is covered by soft tissue—usually 6 weeks (some studies debating 4 wks is enough)
 - Debridement w/retained hardware
 - 6 wks IV + po suppression for 3-6 months or until fx united
- Consider discontinuing suppression if they are comfortable with the possibility of undergoing further surgery in case of infection relapse.
- If hardware removal is feasible in the event of infection relapse, the infection is usually well controlled
- If the prospect of surgery is unacceptable, continuing the suppression indefinitely

FRI Case #1

- 59 yr old female pt
- PMH: Afib on Eliquis, CHF, HTN, COPD, DVT, Tobacco dependence
- HPI: s/p fall 10/2022-→ open R tib/fib fx
 - ORIF, fasciotomy
- Transferred from OSH 12/20/222 for ortho care
 - Wound dehiscence, purulence since sutures were removed
 - Vanc/Zosyn given prior to transfer

FRI Case #1 cont.

- CT scan: no fluid collection or abscess formation
- Medial tibial plate, IM Nail at presentation
 - Taken to OR for I&D, medial plate removed, IM Nail exchanged, wound vac
- WBC 10.8, ESR 120, CRP 11.3



FRI case #1 cont

Final Report - 12/26/22 11:15:11
1 colony Staphylococcus aureus

Preliminary Report - 12/22/22 14:09:02
1 colony Staphylococcus aureus

Gram Stain Report - 12/21/22 13:20:30
No organisms seen.
1+ (few) Red Blood Cells

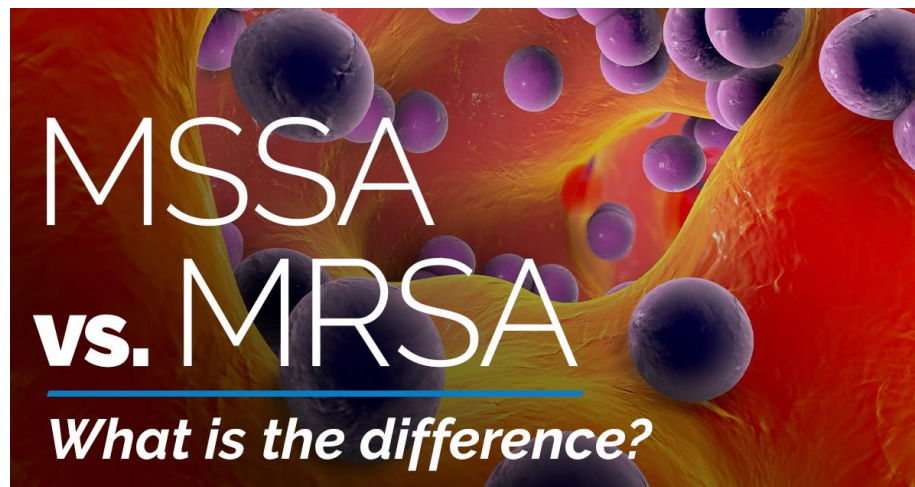STAPHYLOCOCCUS AUREUS

	MDIL	MINT
Vancomycin	<=0.5	S
Tetracycline	<=1	S
Trimethoprim/Sulfa	<=10	S
Rifampin	<=0.5	S
Oxacillin*	0.5	S

*** Oxacillin* Note:

Cephem agents, including cephalosporins, with clinical efficacy and administered at appr

Minocycline	<=0.5	S
Gentamicin	<=0.5	S
Erythromycin	>=8	R
Clindamycin	0.25	S
Cefazolin		S



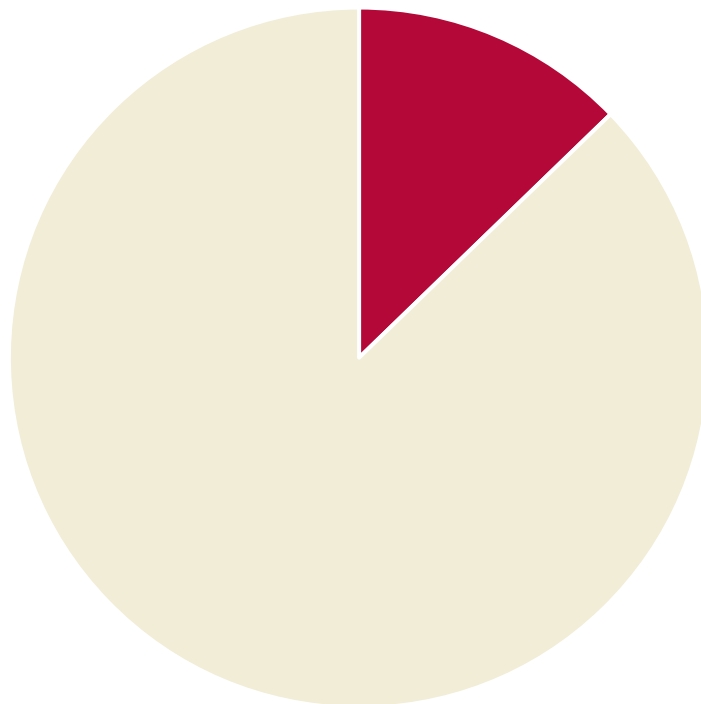
OVIVA Study

- 1054 participants (527 in each group- randomly assigned)
- UK
- Within 7 days of surgery or if infection being treated without surgery, within 7 days after start of antibiotic therapy
- Group 1: IV abx x 6 weeks
- Group 2: po abx x 6 weeks
- End point: definitive treatment failure within 1 year after randomization

IV abx

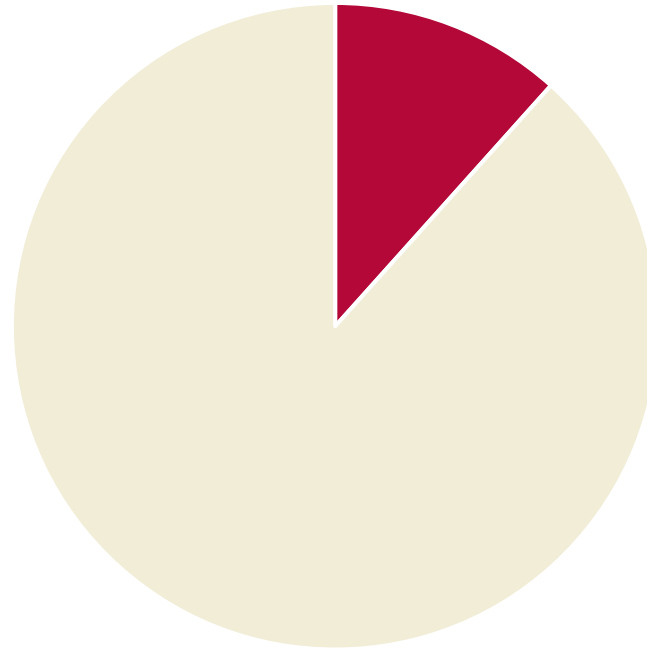
■ Treatment failure ■ Total participants

14.6%

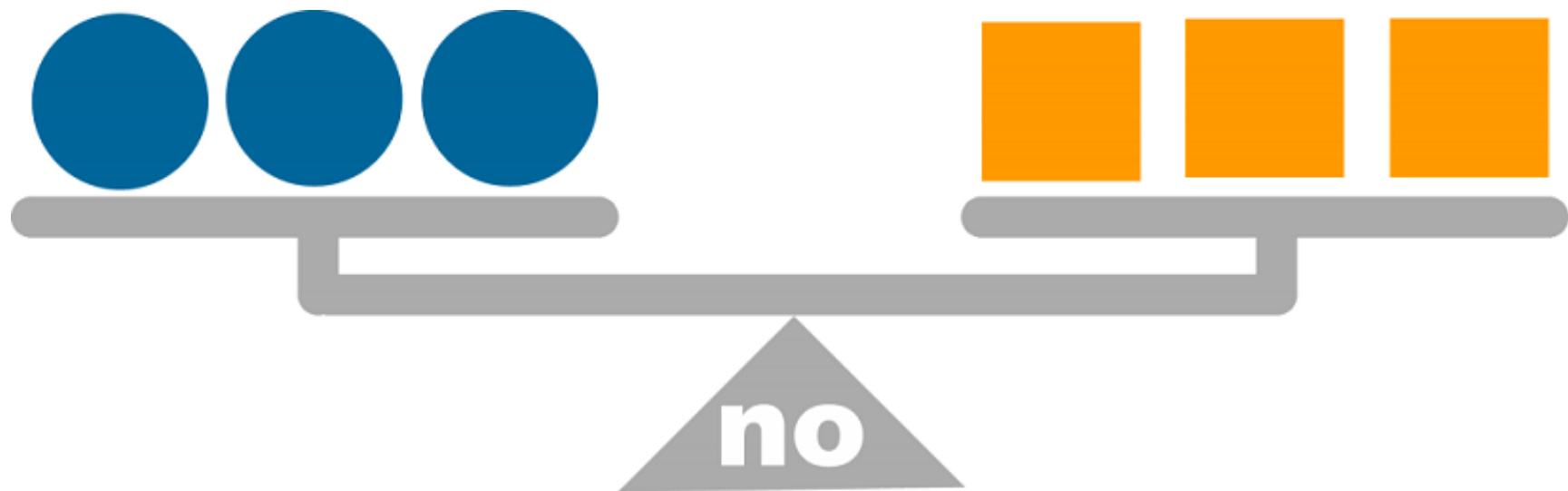


PO abx

13.2%



■ Treatment failure ■ Total participants



significant difference

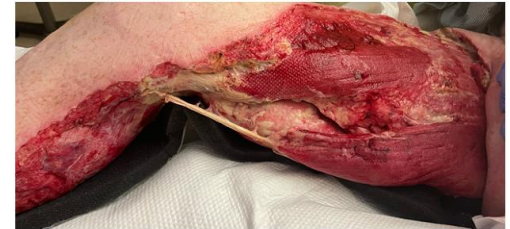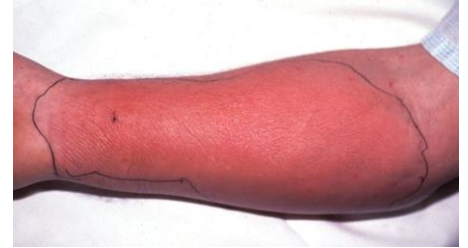Time and Place for Clindamycin

■ PRO

- Necrotizing fasciitis
 - Activity against toxin producing Staph aureus and Strep (invasive Group A Strep)

■ CONS

- DIARRHEA
- CDIFF
- Highly resistant to Staph and Strep
 - Minocycline, Doxycycline, Bactrim DS would be preferred in outpatient setting



R medial LE
>>>head

DALBAVANCIN



IU Health Physicians

Dalbavancin cont.

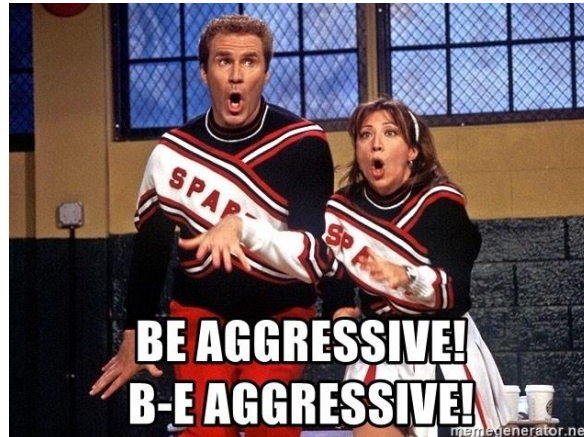
- Ordered by ID only
- FDA approved for cellulitis
 - We use for osteo
 - We reserve for options for IV drug users, leave SAR AMA
 - Half life is 2 weeks—detectable in the body for up to 40 days
 - 1 dose= therapeutic dosing for 4 weeks
 - 2 doses= 6 weeks
 - Good bone concentration


Antibiotic dosing

- Things to think about.....pt's weight, are they a dialysis patient, renal function, allergies, what are you treating?
- Bactrim DS (Trimethoprim 160 mg-sulfamethoxazole 800 mg)
 - Bone: 10mg/kg/day of Trimethoprim
 - **Caution: can cause kidney issues**
- Doxycycline 100 mg po BID
- Minocycline 100 mg po BID

Antibiotic dosing

- Cefazolin--→ inpatient--→ 1 gram IV q 6 or 2 gram IV q 8
- Cephalexin===1 gram po q 6 hr (1/2 absorbed)
- ☐ Ampicillin/Sulbactam (Unasyn) 3 gm IV q 6 hr
- ☐ Amoxicillin/Clavulanic Acid (Augmentin) 875/125 mg 1 tab po BID, use TID for bone and soft tissue (will cause more diarrhea)





- MRSA: Doxycycline, Bactrim DS
- MSSA: Keflex
- Pseudomonas: Cipro
- Strep: Amoxicillin

- Sanford Guide \$39.99 yearly

Antibacterial Agents: Spectra of Activity

Sanford Guide

Scroll anywhere on table (left, right, up, down) to view all data. Click any drug or organism to view its page.

Activity Spectra	Penicillins										Carbapenems				Fluoroquinolone							
	Penicillin G	Penicillin VK	Nafcillin	Oxacillin	Cloxacinil	Flucloxacillin	Dicloxacillin	Ampicillin	Amoxicillin	Amox-Clav	Amp-Sub	Pip-tazo	Draperem	Ertapenem	Meropenem	Imipenem	Aztreonam	Ciprofloxacin	Oloxacin	Levofloxacin	Moxifloxacin	Gatifloxacin
Aerobic gram-pos cocci																						
E. faecalis	++	0	0	0	0	0	0	++	++	+	+	+	+	+	+	+	0	±	±	+	+	+
E. faecium	±	0	0	0	0	0	0	±	±	±	±	±	0	0	0	0	0	0	0	0	±	±
VRE faecalis	±	0	0	0	0	0	0	±	±	±	±	±	0	0	0	0	0	0	0	0	0	0
VRE faecium	±	0	0	0	0	0	0	±	±	±	±	±	0	0	0	0	0	0	0	0	0	0
S. aureus MSSA	±	±	++	++	++	++	++	±	±	+	+	+	+	+	+	+	0	+	+	+	+	+
S. aureus HA-MRSA	0	0	0	0	0	0	0	0	0	0	0	0	0	0	0	0	0	0	0	0	0	0
S. aureus CA-MRSA	0	0	0	0	0	0	0	0	0	0	0	0	0	0	0	0	0	±	±	±	±	±
Staph coag-neg (S)	±	±	++	++	++	++	++	±	±	+	+	+	+	+	+	+	0	+	+	+	+	+
Staph coag-neg (R)	±	±	++	++	++	++	++	±	±	+	+	+	+	+	+	+	0	+	+	+	±	0
S. lugdunensis	±	±	++	++	++	++	++	±	±	+	+	+	+	+	+	+	0	+	+	+	+	+
S. saprophyticus	±	±	+	+	+	+	+	±	±	++	+	+	+	+	+	+	0	+	+	+	+	+
Strep. anginosus gp	++	++	+	+	+	+	+	+	+	+	+	+	+	+	+	+	0	±	±	±	±	±
Strep. gp A,B,C,F,G	++	++	+	+	+	+	+	+	+	+	+	+	+	+	+	+	0	±	±	±	±	±
Strep. pneumoniae	++	++	+	+	+	+	+	+	+	+	+	+	+	+	+	+	0	±	±	±	±	±
Viridans Strep.	±	±	±	±	±	±	±	±	±	±	±	±	+	+	+	+	0	0	0	+	+	+
Aerobic gram-pos bacilli																						
Arcanobacter, sp	+	+	?	?	?	?	?	+	+	+	+	+	+	+	+	+	0	+	+	+	+	+
C. diphtheriae	++	++	0	0	0	0	0	+	+	+	+	?	?	?	?	?	0	?	?	?	?	?
C. jeikeium	0	0	0	0	0	0	0	0	0	0	0	0	0	0	0	0	0	0	0	0	±	±
L. monocytogenes	+	0	0	0	0	0	0	++	+	+	+	?	?	?	?	+	0	0	0	+	+	+
Nocardia sp.	0	0	0	0	0	0	0	0	±	?	?	?	0	++	+	0	0	0	0	0	0	0
Aerobic GNB - Enterobacter																						
Aeromonas sp.	0	0	0	0	0	0	0	0	0	±	±	+	+	+	+	+	+	+	+	+	+	+
C. jejuni	0	0	0	0	0	0	0	0	0	0	0	+	0	+	+	+	?	+	+	+	+	+
Citrobacter sp.	0	0	0	0	0	0	0	0	0	0	0	++	+	+	++	++	±	+	+	+	+	+
Enterobacter sp.	0	0	0	0	0	0	0	0	0	0	0	+	+	+	+	+	+	+	+	+	+	+

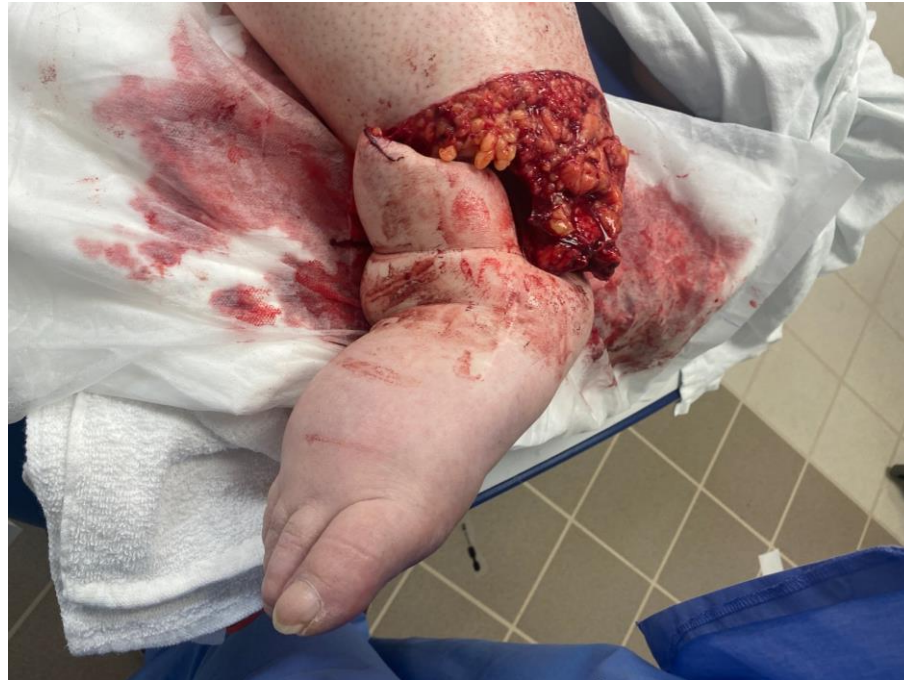

Case #1:

- 60 yr old female s/p fall in bathroom 4/4/23 → open R distal tib/fib fx near traumatic amputation
 - s/p I&D, ex fix day of injury
 - s/p Ex fix removal, repeat I&D, hindfoot fusion nail 2 days later
- 2 months later: drainage from ankle wound, subjective fever → directly admitted from ortho clinic
- PMH: Afib on Apixaban, OSA, HTN, Obesity

- ESR 90, CRP 22.7, WBC 11.3
- CTA RLE: new moderate size amorphous fluid collection along medial aspect lower leg w/skin wound
- Started IV Vanc/Cefepime

Case #1



Case #1

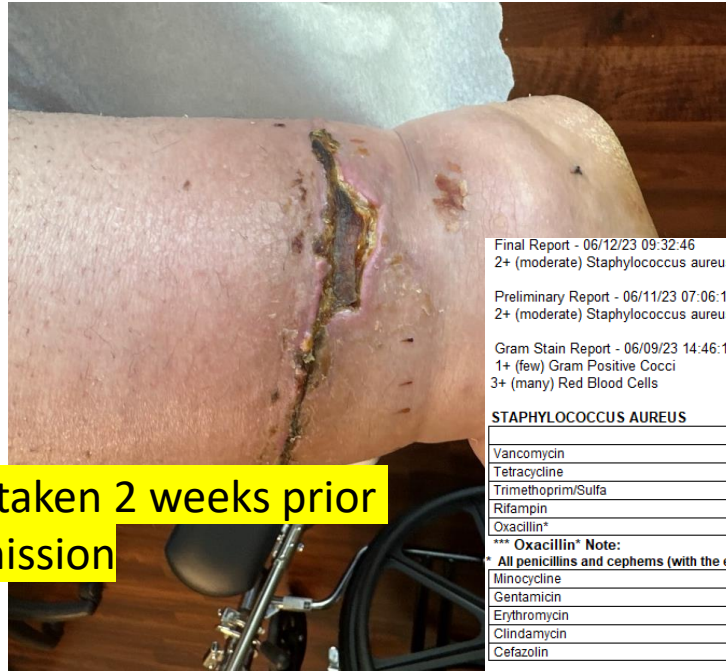

Photo taken 2 weeks prior to admission

- Taken to OR on day of ID consult for I&D, wound vac
- Intra op findings: anterior wound breakdown, blood and purulent fluid
- OR cx: MRSA

Final Report - 06/12/23 09:32:46
 2+ (moderate) Staphylococcus aureus (MRSA)

Preliminary Report - 06/11/23 07:06:15
 2+ (moderate) Staphylococcus aureus (MRSA)

Gram Stain Report - 06/09/23 14:46:18
 1+ (few) Gram Positive Cocci
 3+ (many) Red Blood Cells

STAPHYLOCOCCUS AUREUS

	MDIL	MINT
Vancomycin	<=0.5	S
Tetracycline	>=16	R
Trimethoprim/Sulfa	<=10	S
Rifampin	<=0.5	S
Oxacillin*	>=4	R

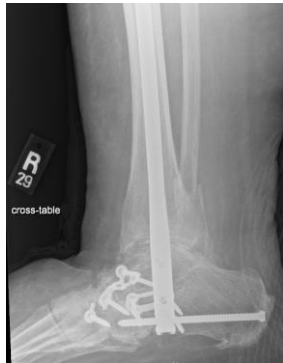*** Oxacillin* Note:

All penicillins and cepheims (with the exception of cephalosporins with anti-MRSA activity) should be considered resistant and will not be further tested

Minocycline	<=0.5	S
Gentamicin	<=0.5	S
Erythromycin	>=8	R
Clindamycin	<=0.12	S
Cefazolin		R

Case #1

- s/p complex wound repair by PLS
- D/C Plan:
 - IV Vancomycin x 6 weeks
 - What is your plan after completion of 6 wks of IV abx? Refer to cx results.
- Po abx suppression due to retained hindfoot fusion nail



Bactrim DS 2 tab po BID

**THINK
OUTSIDE
THE BOX**

Case #2

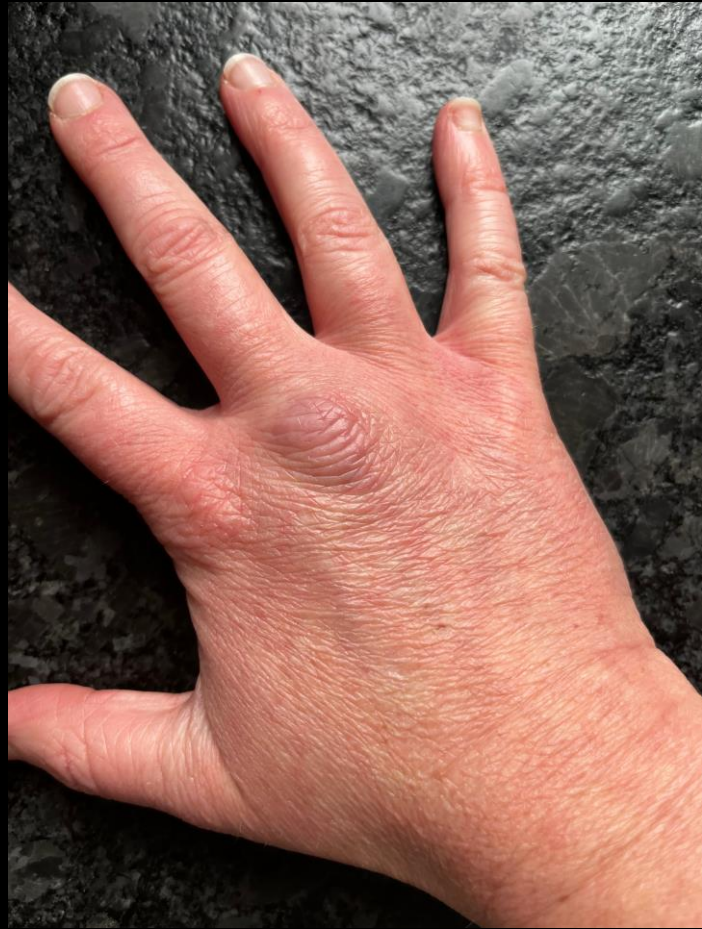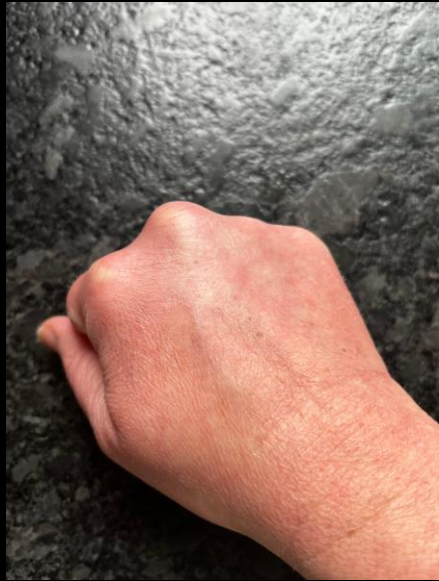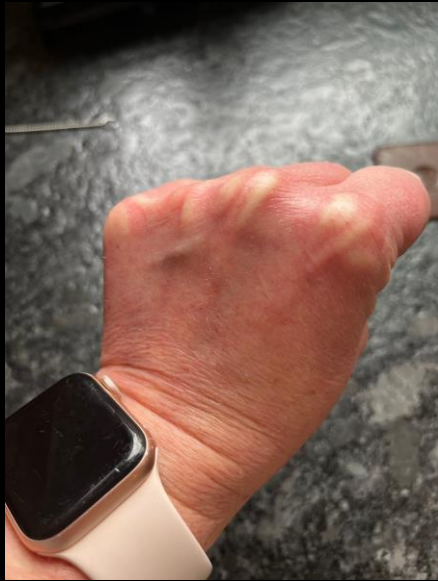- 33 yr old female patient presented to ED c/o bil hand pain/swelling
- Started 6 days prior after went swimming at Eagle Creek
- Started on IV Vanc/Cefepime/Flagyl at admission
- ESR 120, CRP 31.7, WBC 14.7, HIV neg, Hep ABC neg, no recent infxns, denies IV drug use, denies animal/pet exp., denies pain in other joints, no hx autoimmune/rheum disorders, no recent dental work
- EXAM: small abrasion on middle finger R hand (but bilateral nature)
- Rheumatoid factor neg, ANA neg
- Next step: Parvovirus serology and PCR, Lyme, Syphillis, G&C
- MRI wrist ordered next day: extensive synovitis, tenosynovitis—extensive involvement of multiple tendon sheaths and all 3 wrist compartments, earliest finding of osteo difficult to exclude, no abscess
- Gonorrhea +

Case #2 cont.

Needs tx 14 consecutive days of IV Ceftriaxone
1 gram q 24 hr

Case #3:

- 39 yr old female, no PMH
- Injury to R hand gardening 6 wks prior to ID consult
- Thorn from rose bush pierced the back of her hand through garden glove
- Swelling and redness to 3rd digit MCP
- Previous tx: Doxycycline, Augmentin without relief
- Referred by PCP to hand surgeon → I&D 3 wks prior to ID consult
- OR cx x 3 obtained:
 - OR cx 1, 2, 3 no growth
 - Fungus cx 1,2,3 no growth
 - AFB cx 1, 2 negative
 - AFB cx 3 labeled “middle finger 3” Alternaria species



Case #3 cont.

- Alternaria rare in immunocompetent host
- Tx of Choice: Itraconazole—min tx 3 months to 1 year

The first case report of thorn-induced *Alternaria alternata* infection of the hand in an immunocompetent host

Gyeongmin Kim¹, Seung Jin Yoo¹, Jeong Rae Yoo² and Kyu Bum Seo^{1*} 

Kim et al. *BMC Infectious Diseases* (2022) 22:304
<https://doi.org/10.1186/s12879-022-07280-y>

Case #4

- Called by Ortho surgeon for opinion
 - Young patient, 20s, healthy
 - Previous ORIF olecranon, healed, years later had issues
 - Taken to OR, HWR, hole in olecranon- saucerized
 - OR cx MSSA
 - Was d/c'd on Keflex 500 mg po BID x 7 days
- What does ID recommend?
 - All retained HW is out
 - Changes in olecranon consistent with osteomyelitis
 - Cx MSSA is a highly virulent organism
 - Keflex 1000 mg po q 6 hr x 4 weeks

Case #5

- 41 yr old female, ped struck by car sitting inside Coldstone
- First seen by ID 6 wks after incident
- Multiple traumatic injuries: mangled RLE resulted in AKA, R Acetabulum fx/SI disruption, multi ligament knee disruption L knee, Morel lavalle lesion LLE resulting in multiple operations
- Cellulitis R pelvis/hip/AKA stump → started on IV Vanc/Zosyn
- ESR 61, CRP 10.2
- Aspiration R hip: *Pseudomonas aeruginosa*

PSEUDOMONAS AERUGINOSA

	MDIL	MINT
Amikacin	4	S
Tobramycin	<=1	S
Piperacillin/Tazobactam	<=4	S
Meropenem	<=0.25	S
Gentamicin	2	S
Ciprofloxacin	<=0.25	S
Cefepime	<=1	S

Case #5 cont

- OR for I&D R acetabulum, pelvis, AKA; removed ex fix LLE, I&D morel lavalles lesion LLE, wound vac
- Intra op findings: AKA dehisced w/exposed residual distal limb, loose posterior column screw
- 4/7 OR cx:

PSEUDOMONAS AERUGINOSA

	MDIL	MINT
Amikacin	<=2	S
Tobramycin	<=1	S
Piperacillin/Tazobactam	<=4	S
Meropenem	<=0.25	S
Gentamicin	<=1	S
Ciprofloxacin	<=0.25	S
Cefepime	<=1	S

ENTEROCOCCUS FAECALIS

	MDIL	MINT
Vancomycin	1	S
Streptomycin synergy*	Syn-S	S

*** Streptomycin synergy* Note:

* Synergy is predicted if beta-lactam or glycopeptide and aminoglycoside test sensitive.

Penicillin	2	S
Gentamicin synergy*	Syn-S	S

*** Gentamicin synergy* Note:

* Synergy is predicted if beta-lactam or glycopeptide and aminoglycoside test sensitive.

Ampicillin	<=2	S
------------	-----	---

SERRATIA MARCESCENS

	MDIL	MINT
Amikacin	<=2	S
Tobramycin	<=1	S
Tetracycline	4	S
Trimethoprim/Sulfa	<=20	S
Meropenem	<=0.25	S
Gentamicin	<=1	S
Ciprofloxacin	<=0.25	S
Cefoxitin		R
Cefepime	<=1	S
Cefazolin	>=64	R

CORYNEBACTERIUM STRIATUM

	MDIL	MINT
Vancomycin	<=0.5	S
Penicillin	>=8	R
Erythromycin	>=4	R

Zosyn d/c'd
Cefepime started
Cont Vanc

ENTEROBACTER CLOACAE COMPLEX

	MDIL	MINT
Amikacin	<=2	S
Tobramycin	<=1	S
Tetracycline	<=1	S
Trimethoprim/Sulfa	<=20	S
Meropenem	<=0.25	S
Gentamicin	<=1	S
Ciprofloxacin	<=0.25	S
Cefoxitin	32	R
Cefepime	<=1	S
Cefazolin	>=64	R

STAPHYLOCOCCUS AUREUS

	MDIL	MINT
Vancomycin	<=0.5	S
Tetracycline	<=1	S
Trimethoprim/Sulfa	<=10	S
Rifampin	<=0.5	S
Oxacillin*	0.5	S

*** Oxacillin* Note:

* Cephem agents, including cephalosporins, with clinical efficacy and ac

Minocycline	<=0.5	S
Gentamicin	<=0.5	S
Erythromycin	<=0.25	S
Clindamycin	<=0.12	S
Cefazolin		S

Case #5 Fast Forward

- Underwent further sx for I&D, exchange R acetabulum HW, revision AKA
- D/C plans:
 - 6 weeks of IV Vancomycin/Cefepime
 - At completion of IV abx→ Doxycycline and Cipro initial plans for 3 months
 - CRP normal, ESR slightly elevated September
 - By November cellulitis of L hip had abscess I&D, d/c'd on Cipro/Doxy x 10 days

Common Questions

- Does the patient need to stay until cultures are back to discharge?
- Patient is scheduled as an outpatient procedure, what po abx should they be put on?
- When in doubt.....just call and ask ID for opinion.

