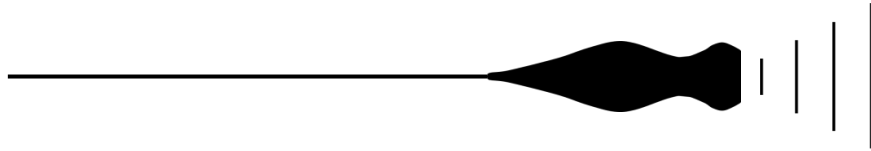


Using Point-of-Care Ultrasound

Mike Breunig, PA-C

AAPA 2024 | Houston, Tx

Disclosures



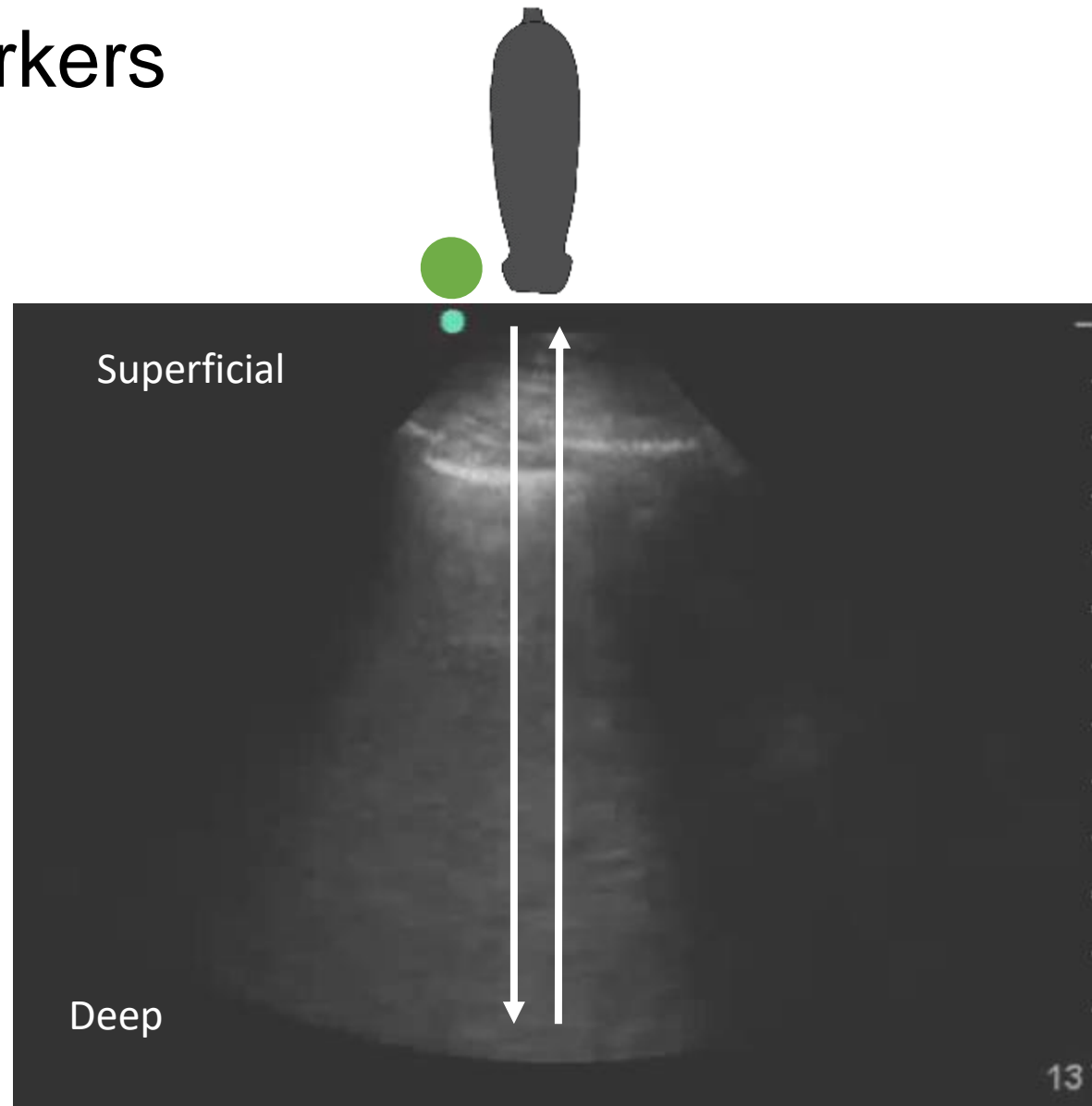
- None

Learning Objectives

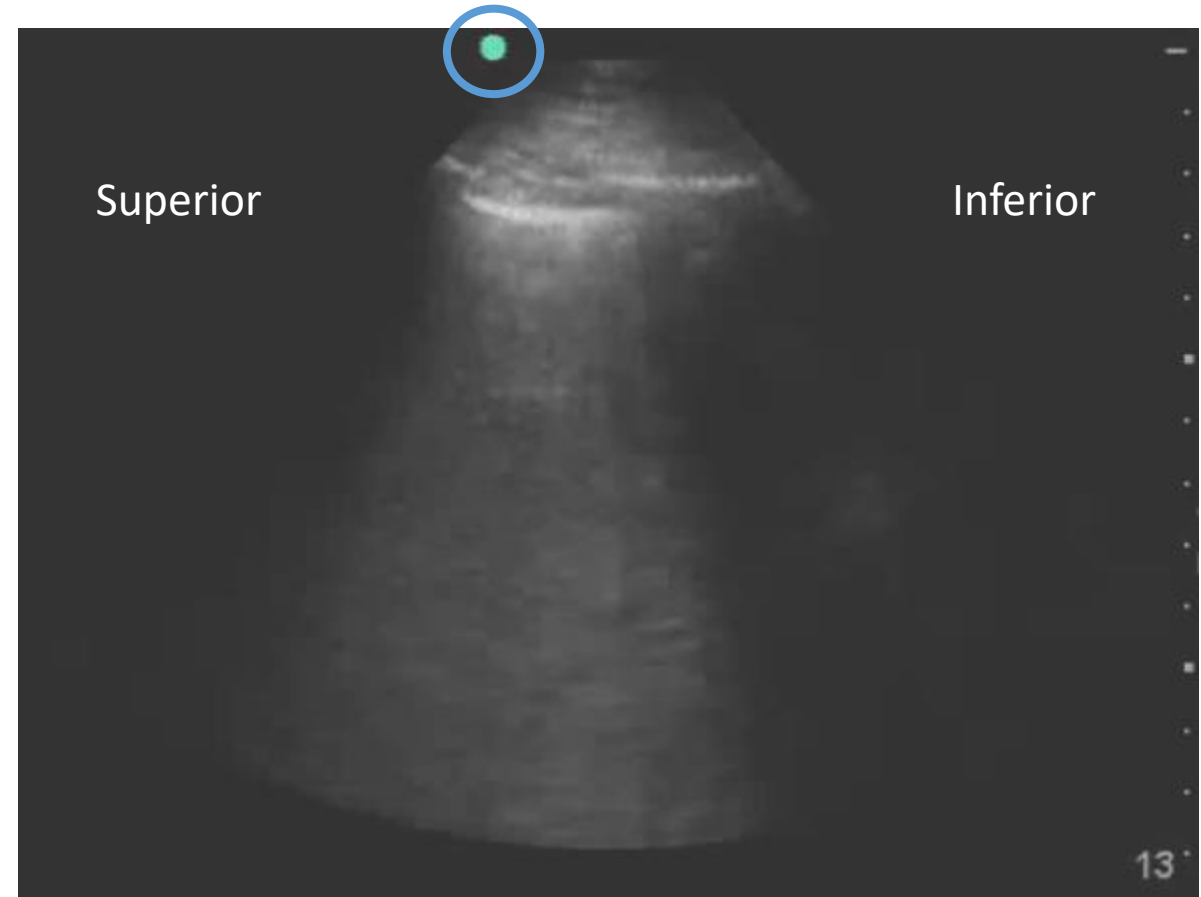
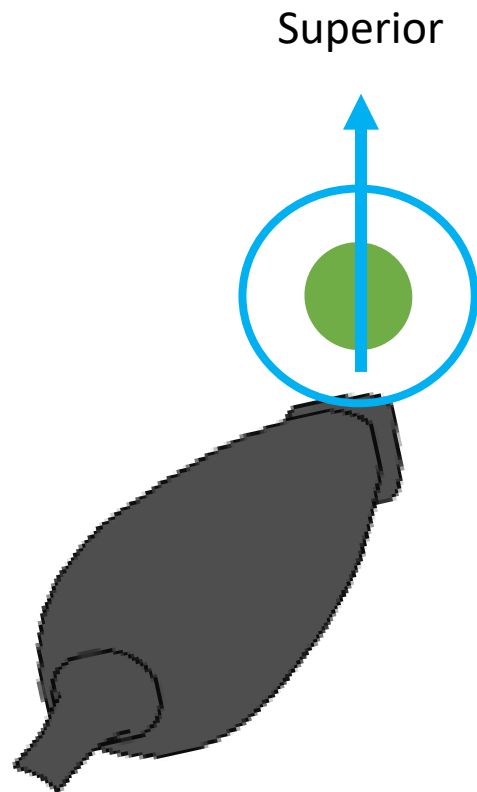


- Outline scope and indications for POCUS
- Contrast evidence of standard of care and POCUS
- Interpret POCUS images

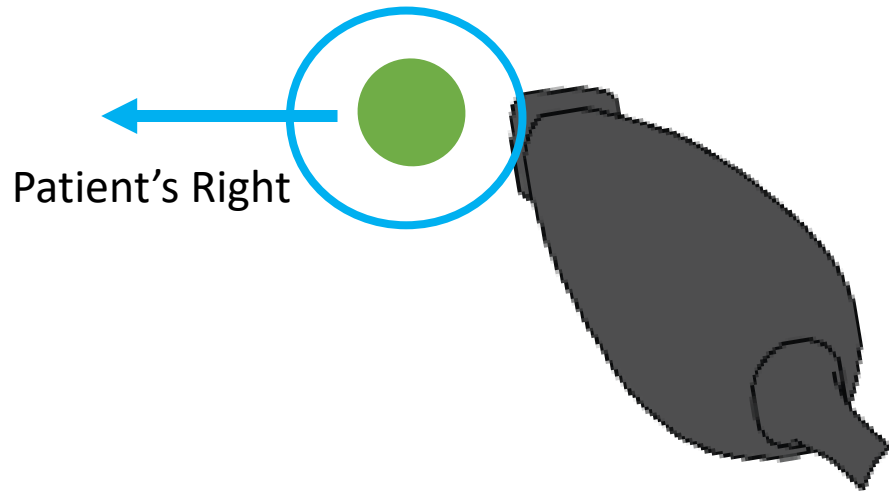
Indicator Markers



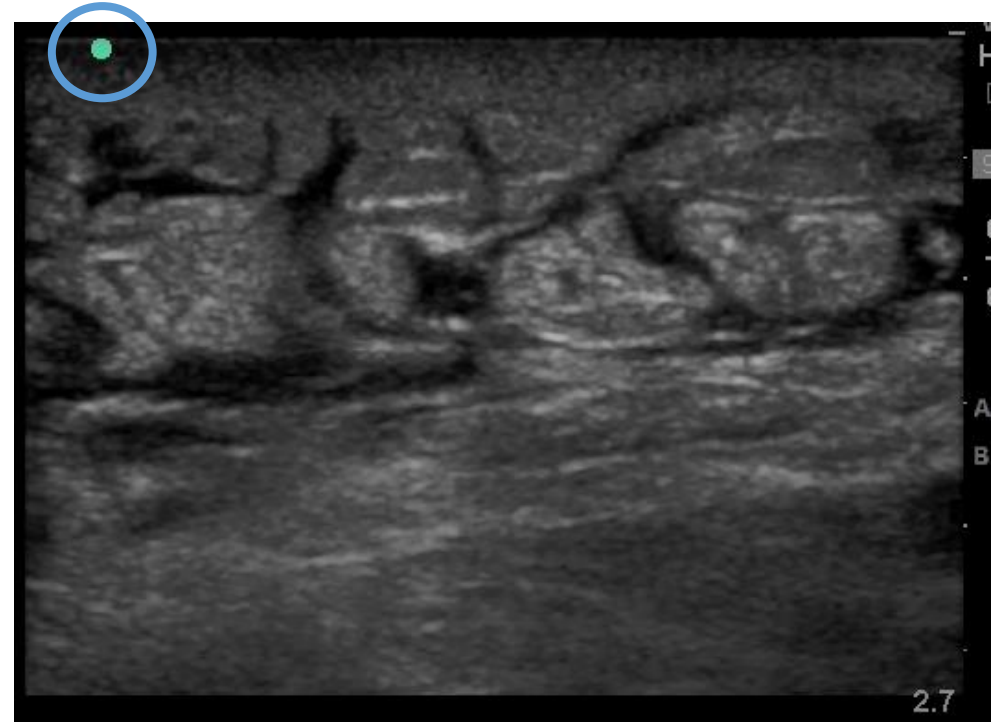
Indicator Markers



Indicator Markers

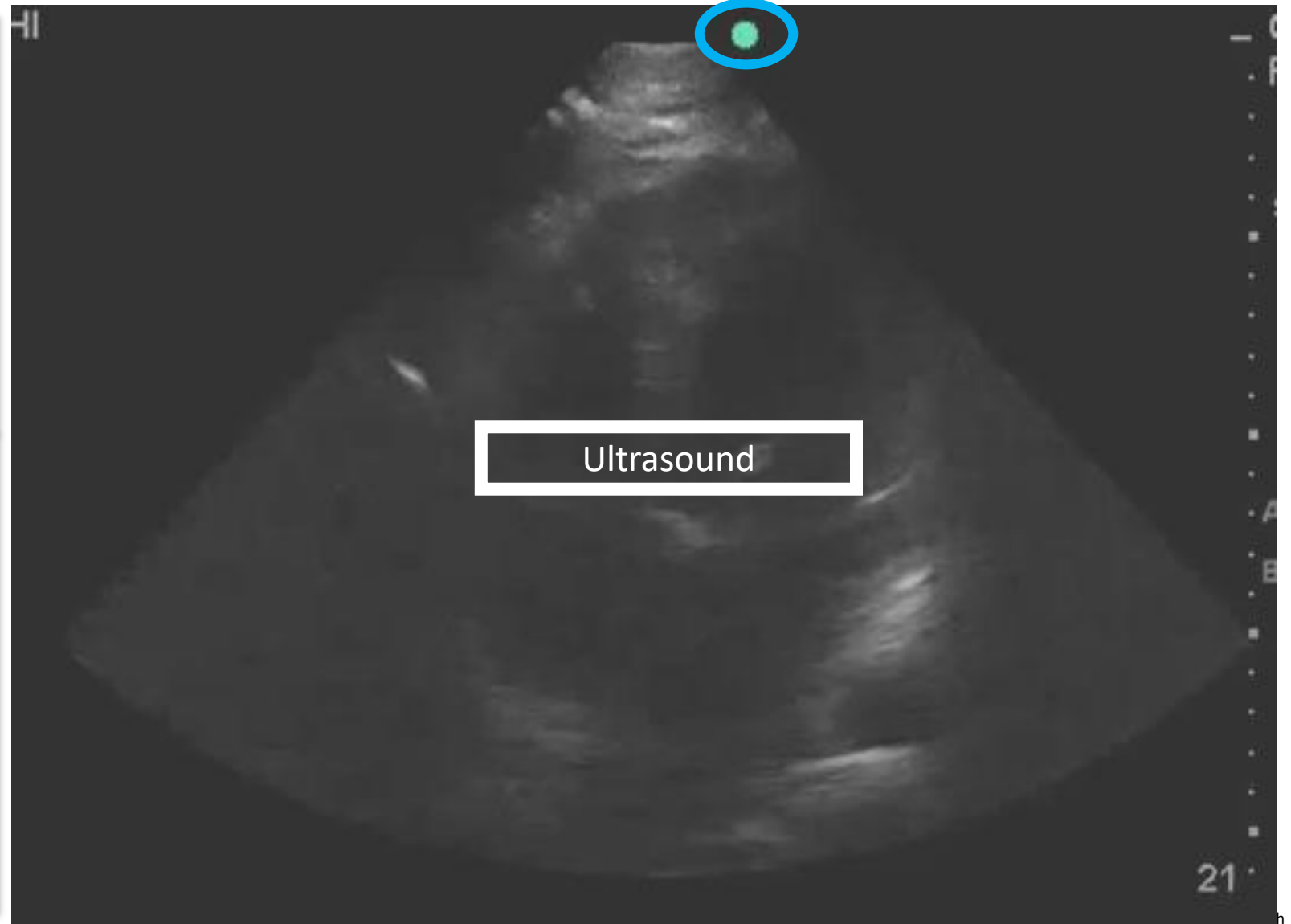
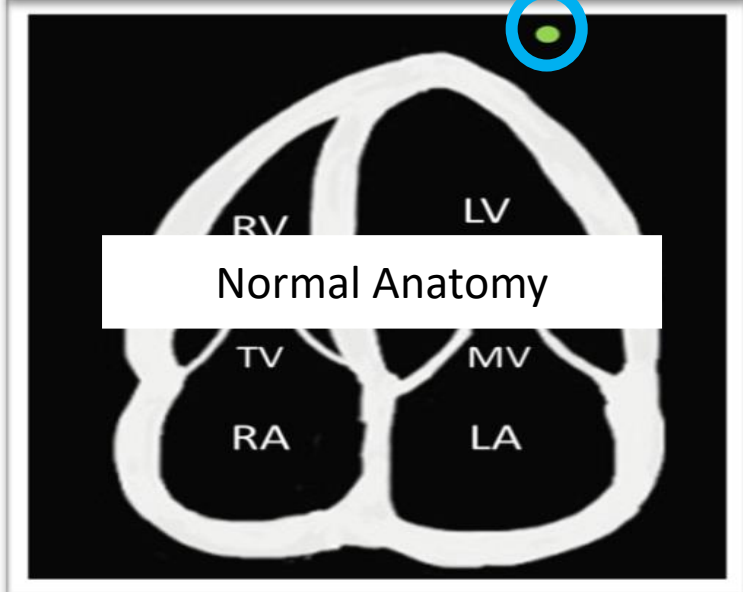
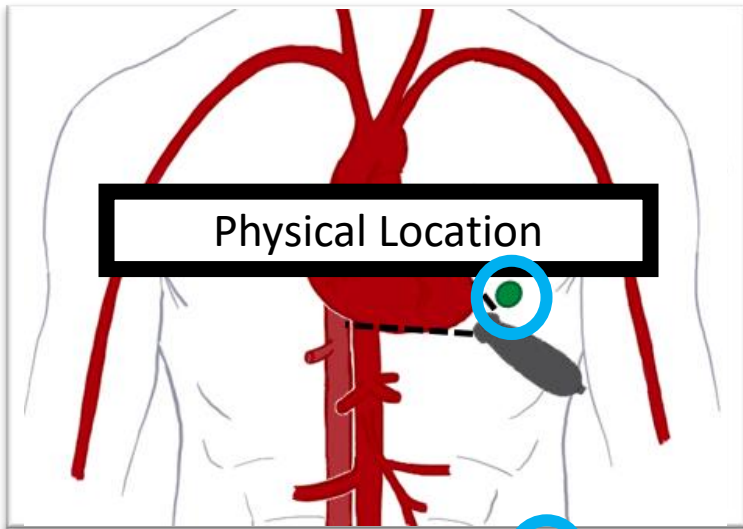



Patient's Right



Patient's Left


Slide convention






Case 1

Case 1



- A 64-year-old gentleman presents to the emergency department for evaluation shortness of breath, progressing over 3 – 4 days.
- He endorses cough with mild sputum production. He endorses fever but denies rigors. Denies hemoptysis.
- Past Medical / Surgical History:
 - COPD
 - Hypertension
 - Obesity
- Social History:
 - 60 pack year history of smoking

Case 1



Vital Signs:

- HR 92
- BP 156/52
- SpO2 84%
- RR 28
- T 37.6 Celsius

Exam:

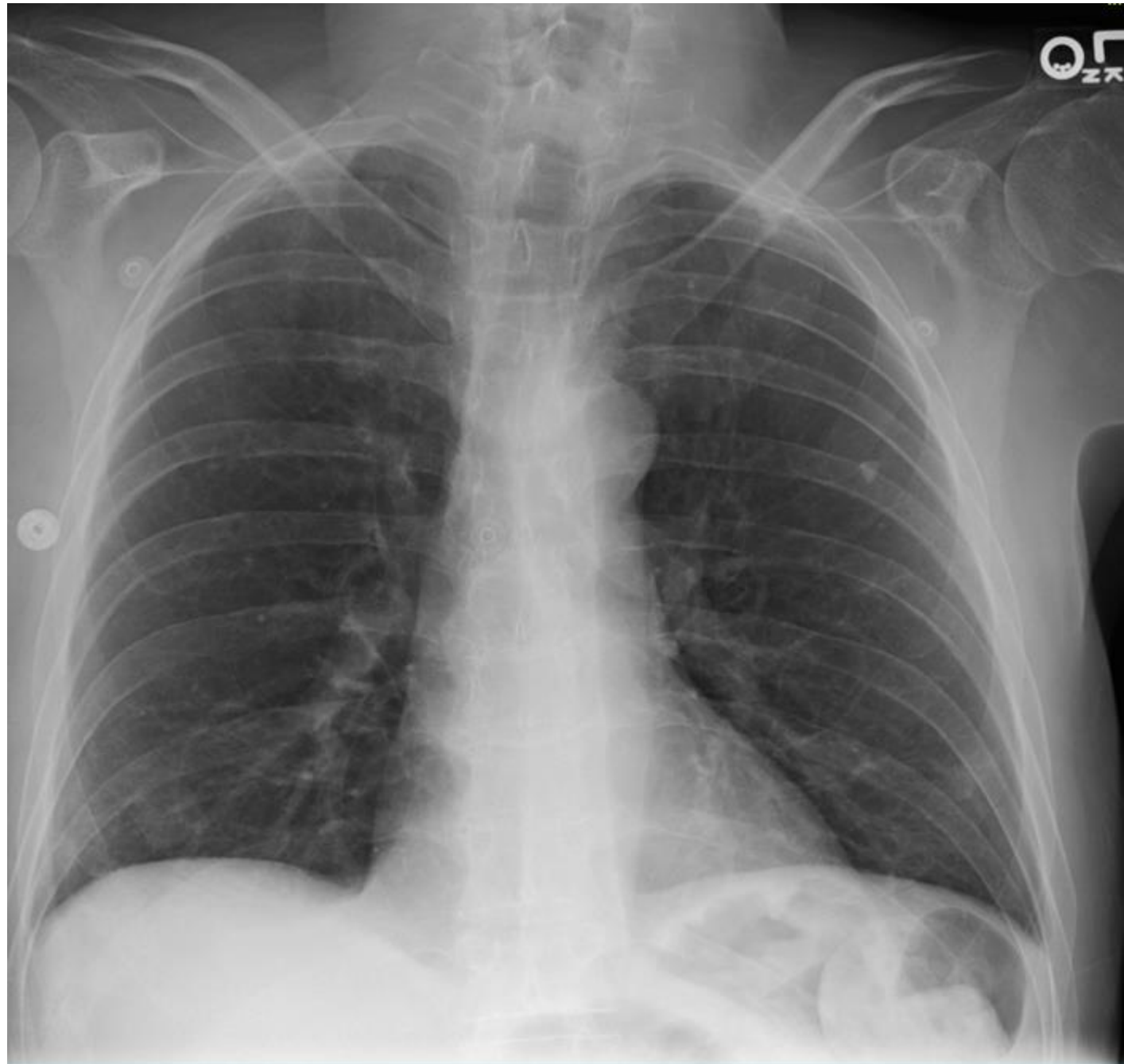- Mild distress
- Body habitus impairs JVD
- Normal S1 and S2.
- Diffuse wheezing throughout all lung fields
- 2+ pitting “chronic” edema

Case 1

10.2 13.4 260

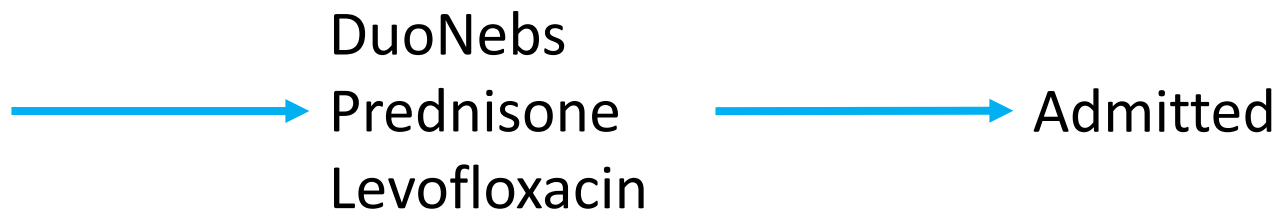
133 101 9 167
4.2 20 1.4

Lactate 1.7



Case 1

Presumptive Diagnosis:
COPD Exacerbation



Case 1

You admit the patient to the hospital, based on the information provided, what is your next step in caring for this patient?

- A. Complete a POCUS exam of the heart and lungs
- B. Continue treatment for COPD exacerbation
- C. Obtain a CTA of the chest to rule out PE
- D. Influenza / COVID-19 Swab

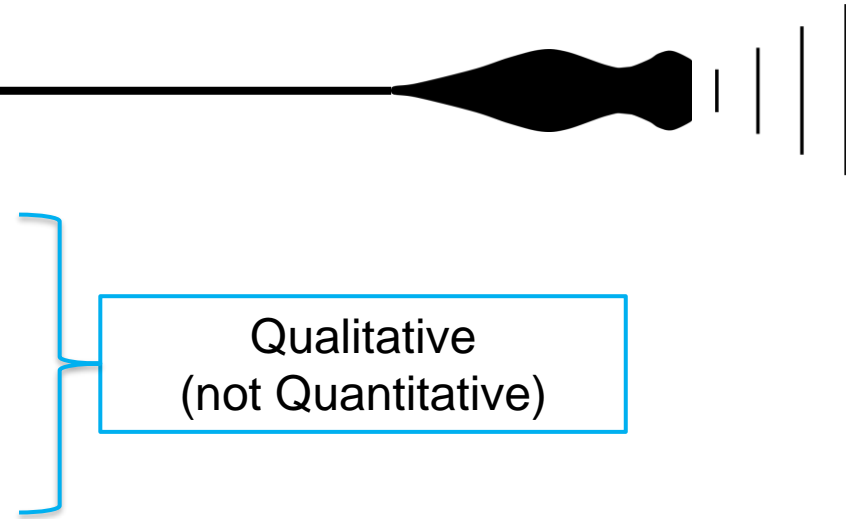
Case 1

You admit the patient to the hospital, based on the information provided, what is your next step in caring for this patient?

- A. Complete a POCUS exam of the heart and lungs
- B. Continue treatment for COPD exacerbation
- C. Obtain a CTA of the chest to rule out PE
- D. Influenza / COVID-19 Swab

Focused cardiac ultrasound (FOCUS)

- Scope:
 - LV size / systolic function
 - RV size / systolic function
 - IVC size and respiratory variation
 - Pericardial effusions / Cardiac Tamponade
- Indications:
 - Hypotension
 - Respiratory Failure
 - Intravascular volume assessment



Qualitative
(not Quantitative)

FOCUS

5 Cardinal Views of the Heart

- Parasternal Long Axis (PLAX)
- Parasternal Short Axis (PSAX)
- Apical 4 Chamber (A4C)
- Subcostal 4 Chamber (S4C)
- Inferior Vena Cava (IVC)

FOCUS

5 Cardinal Views of the Heart

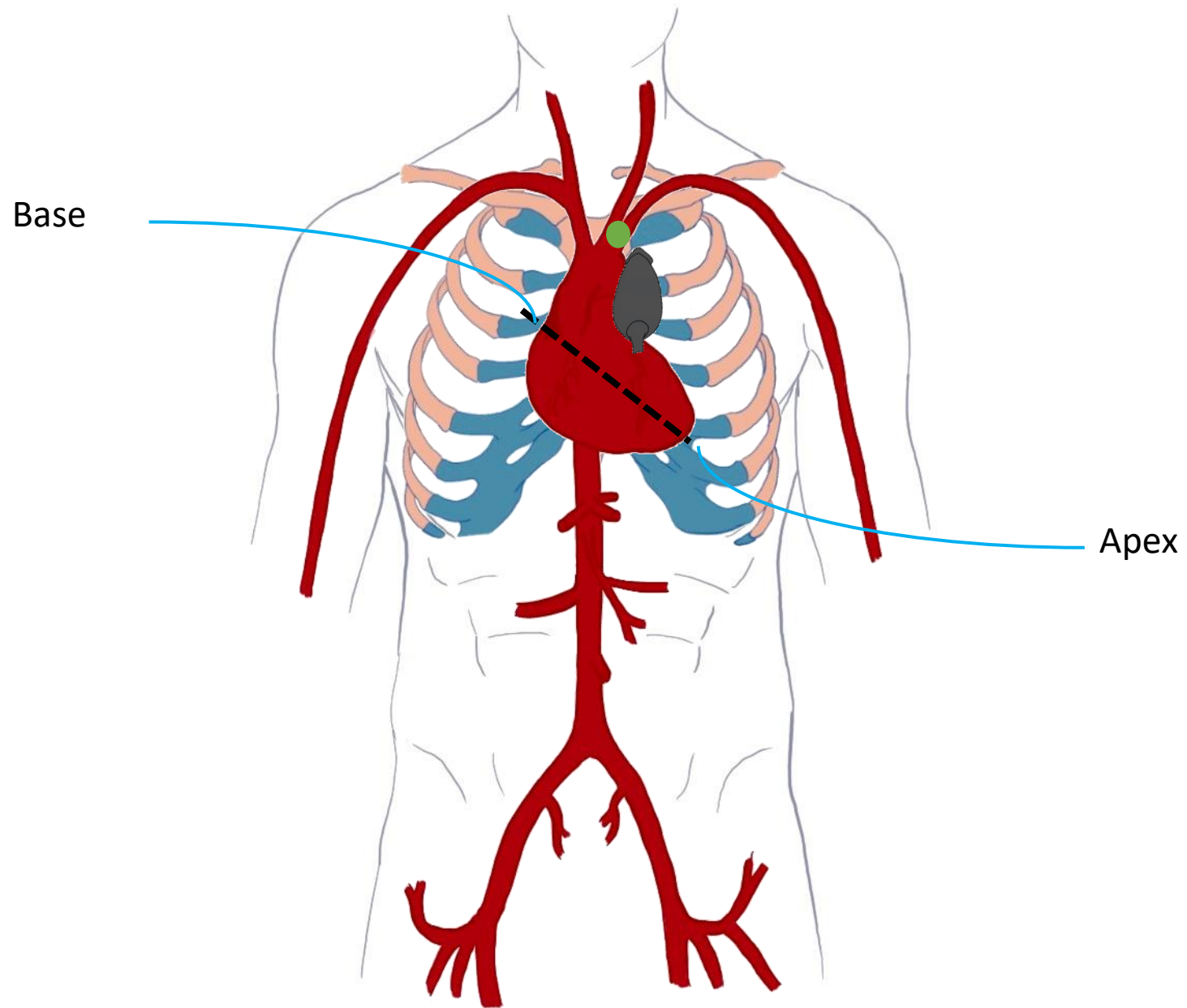
- Parasternal Long Axis (PLAX)
- Parasternal Short Axis (PSAX)
- Apical 4 Chamber (A4C)
- Subcostal 4 Chamber (S4C)
- Inferior Vena Cava (IVC)

FOCUS

LV Systolic Function:

- Hyperdynamic
- Normal
- Reduced / Severely Reduced

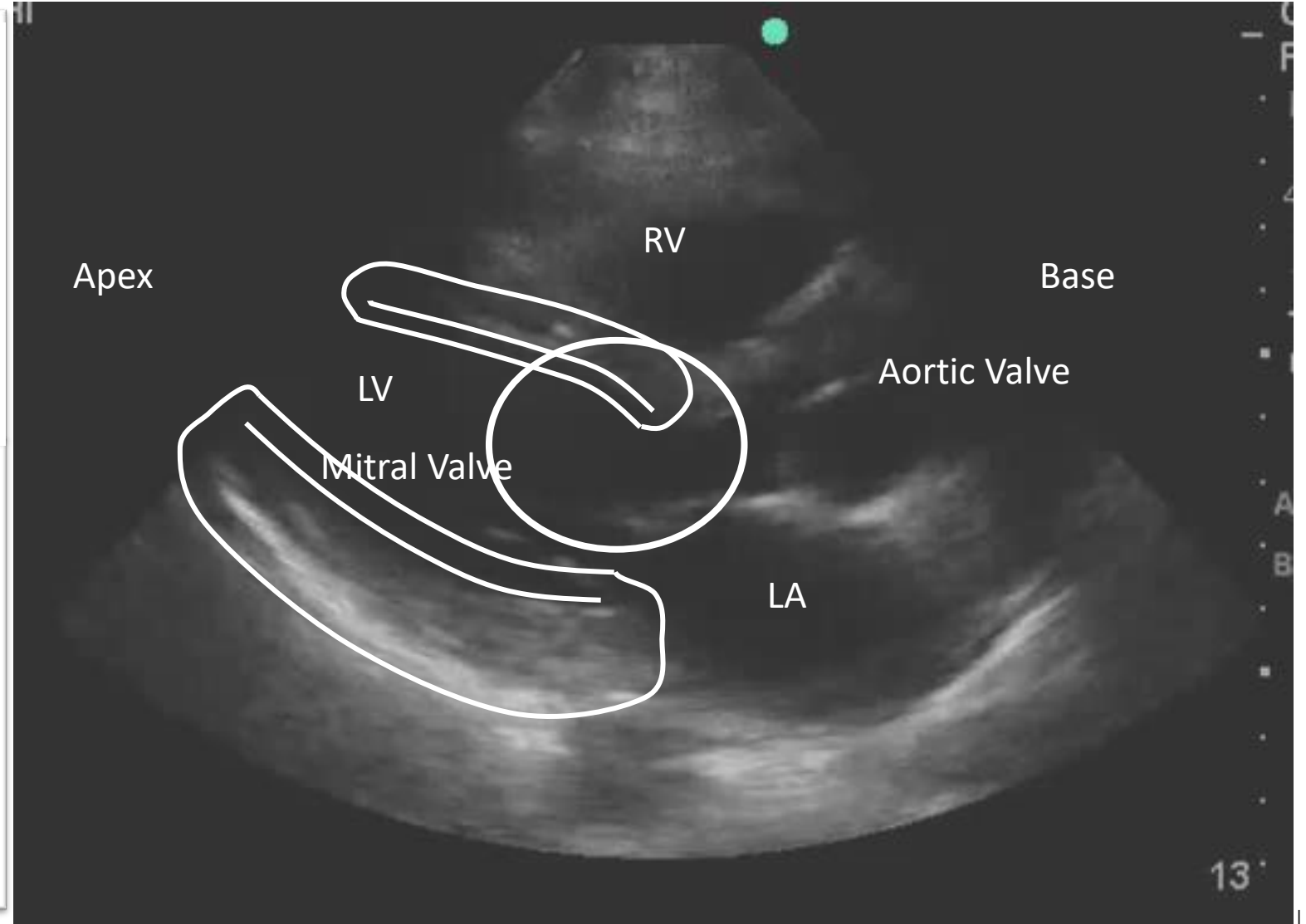
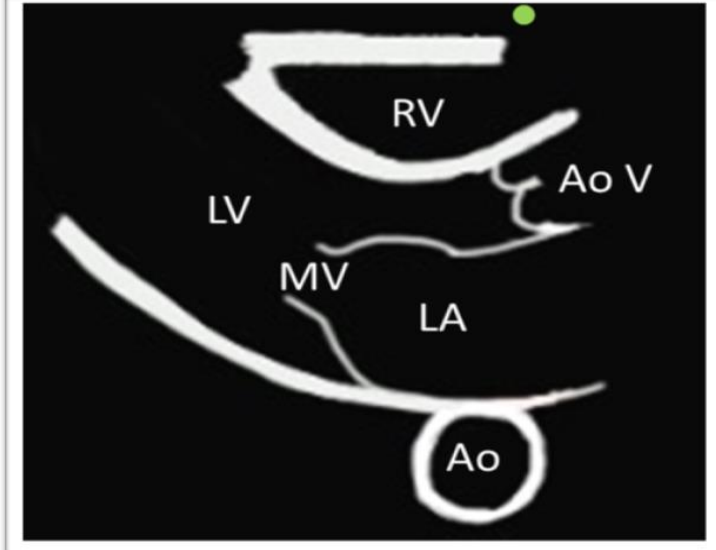
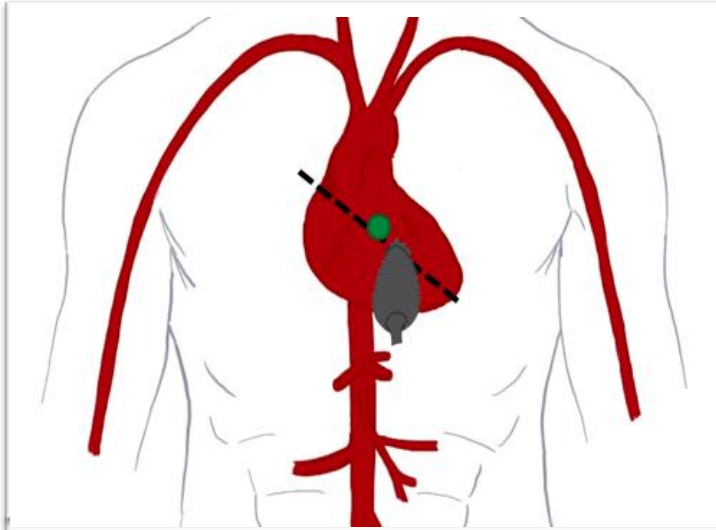
FOCUS PLAX



FOCUS

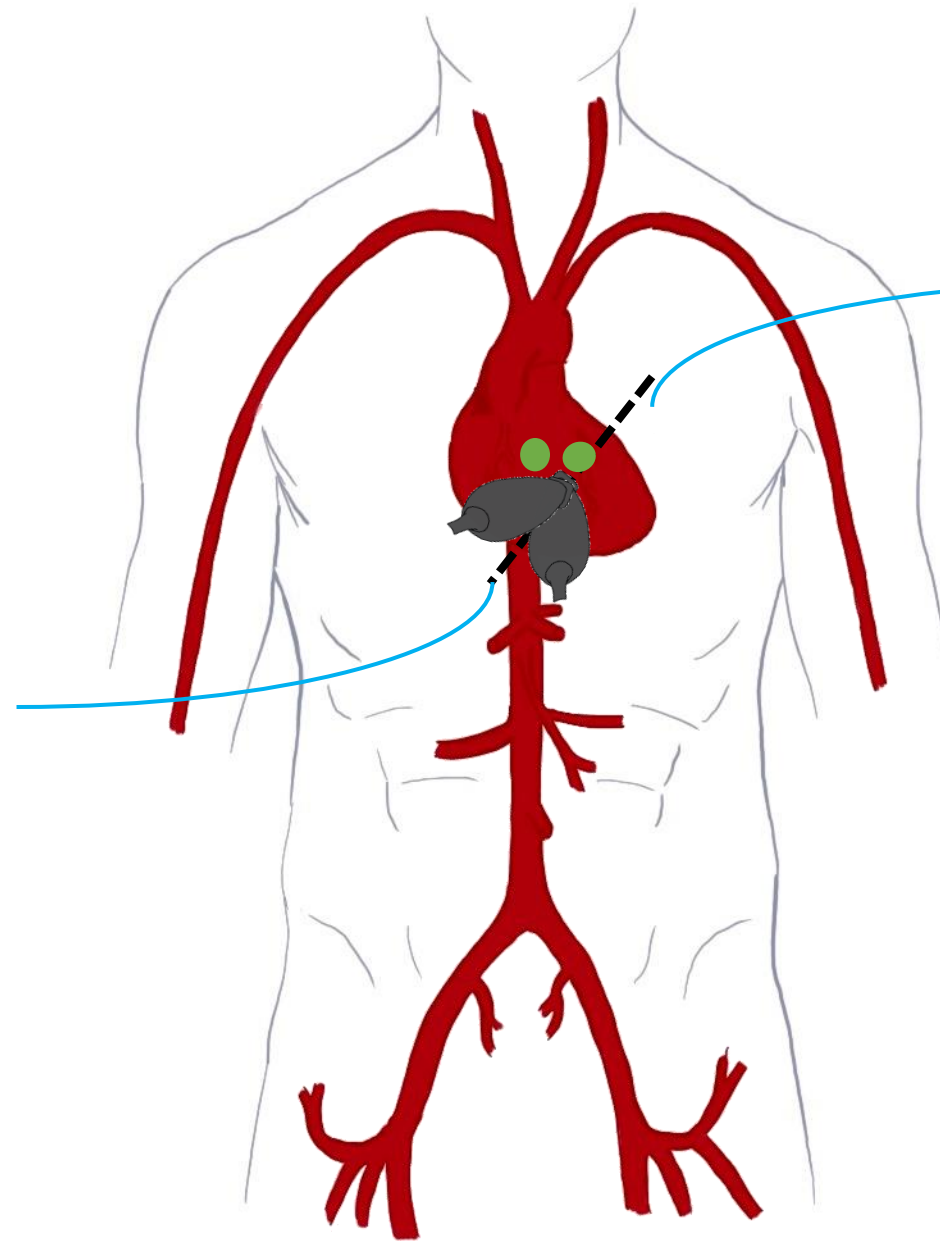
PLAX

1. Endocardial Excursion
2. Myocardial Thickening
3. E Point Septal Separation



FOCUS PSAX

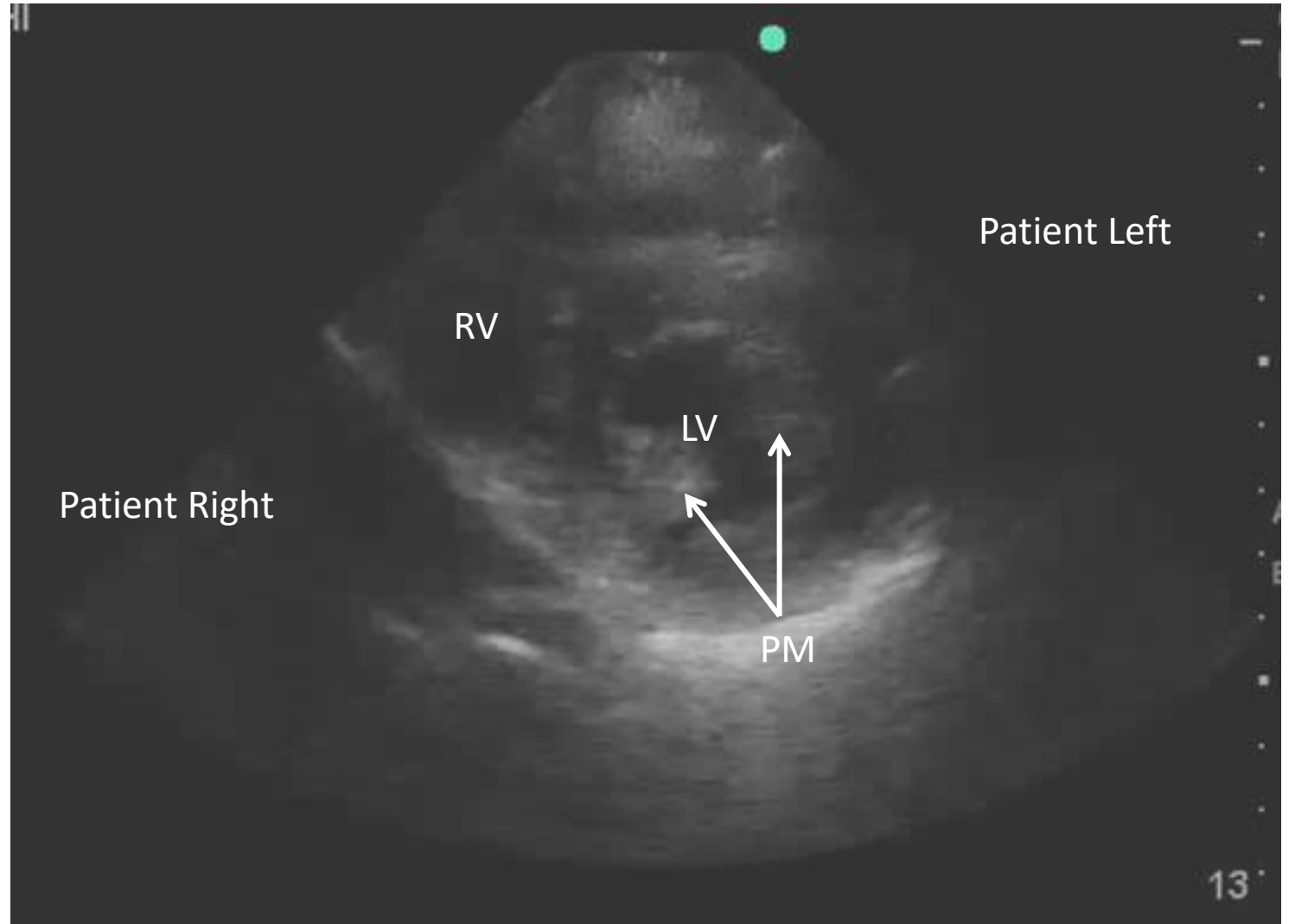
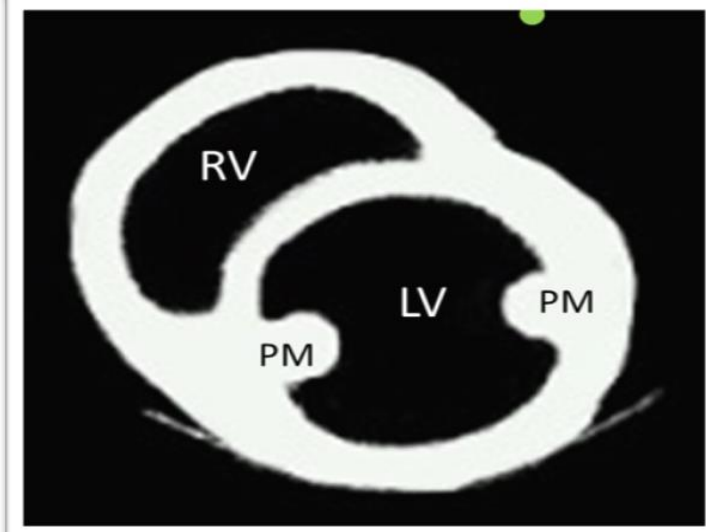
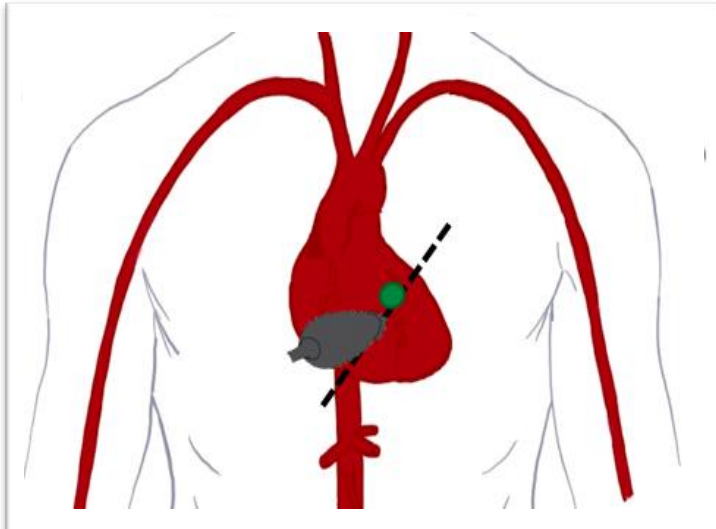
Patient Right



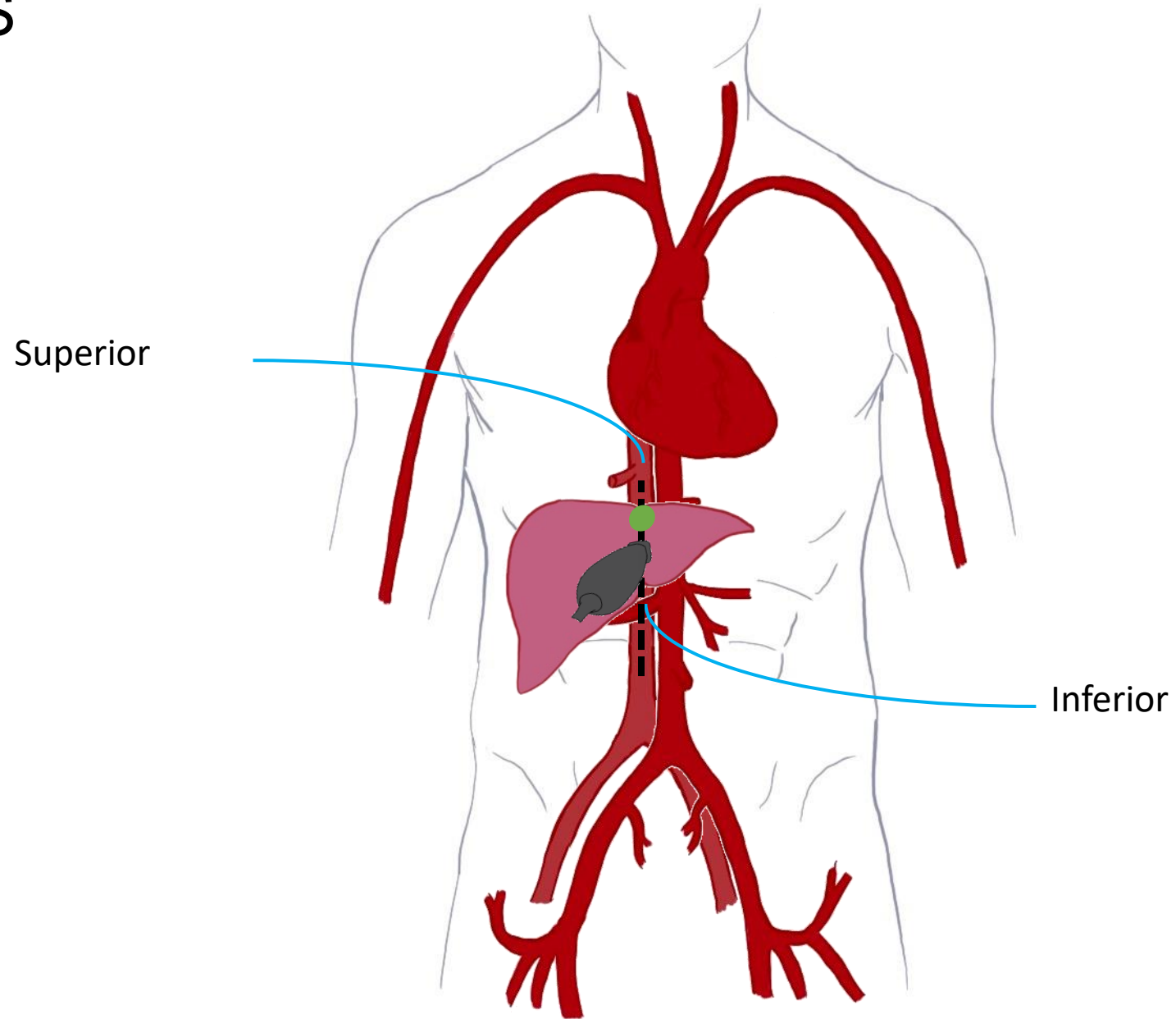
Patient Left

FOCUS

PSAX

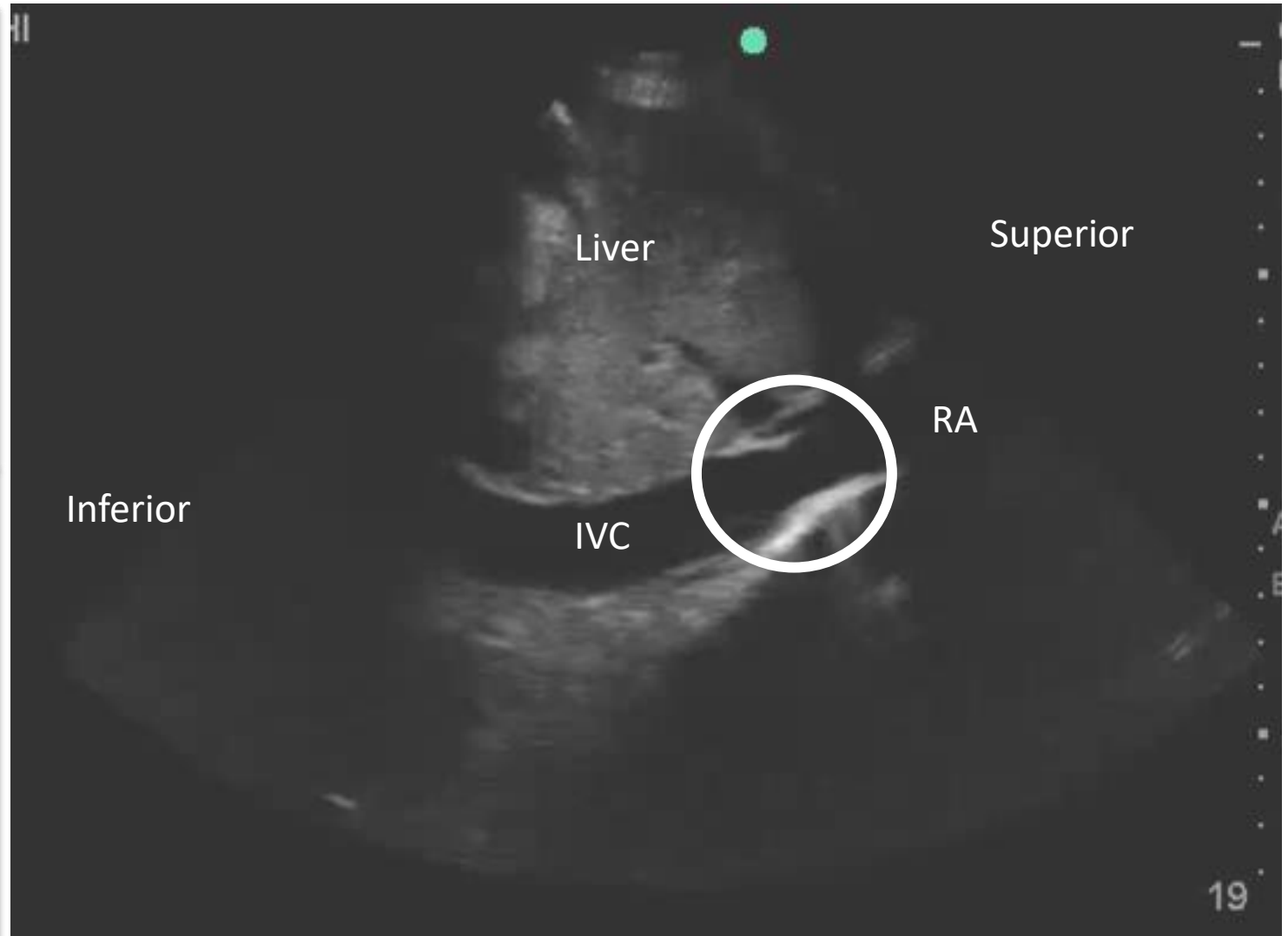
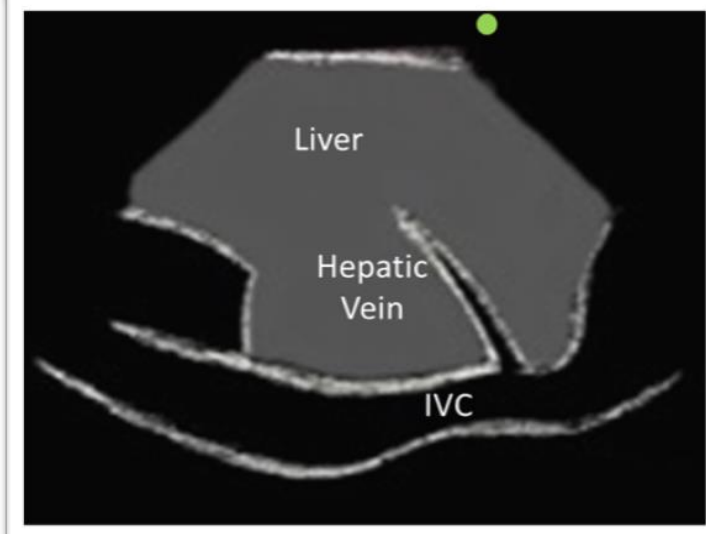
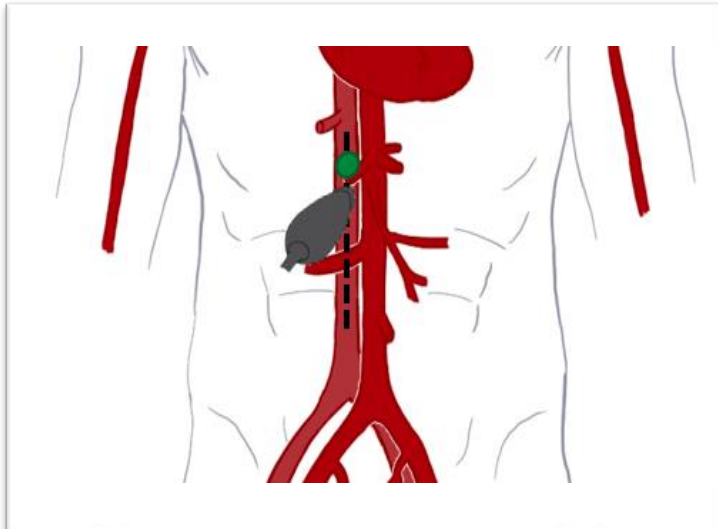


FOCUS IVC



FOCUS

IVC



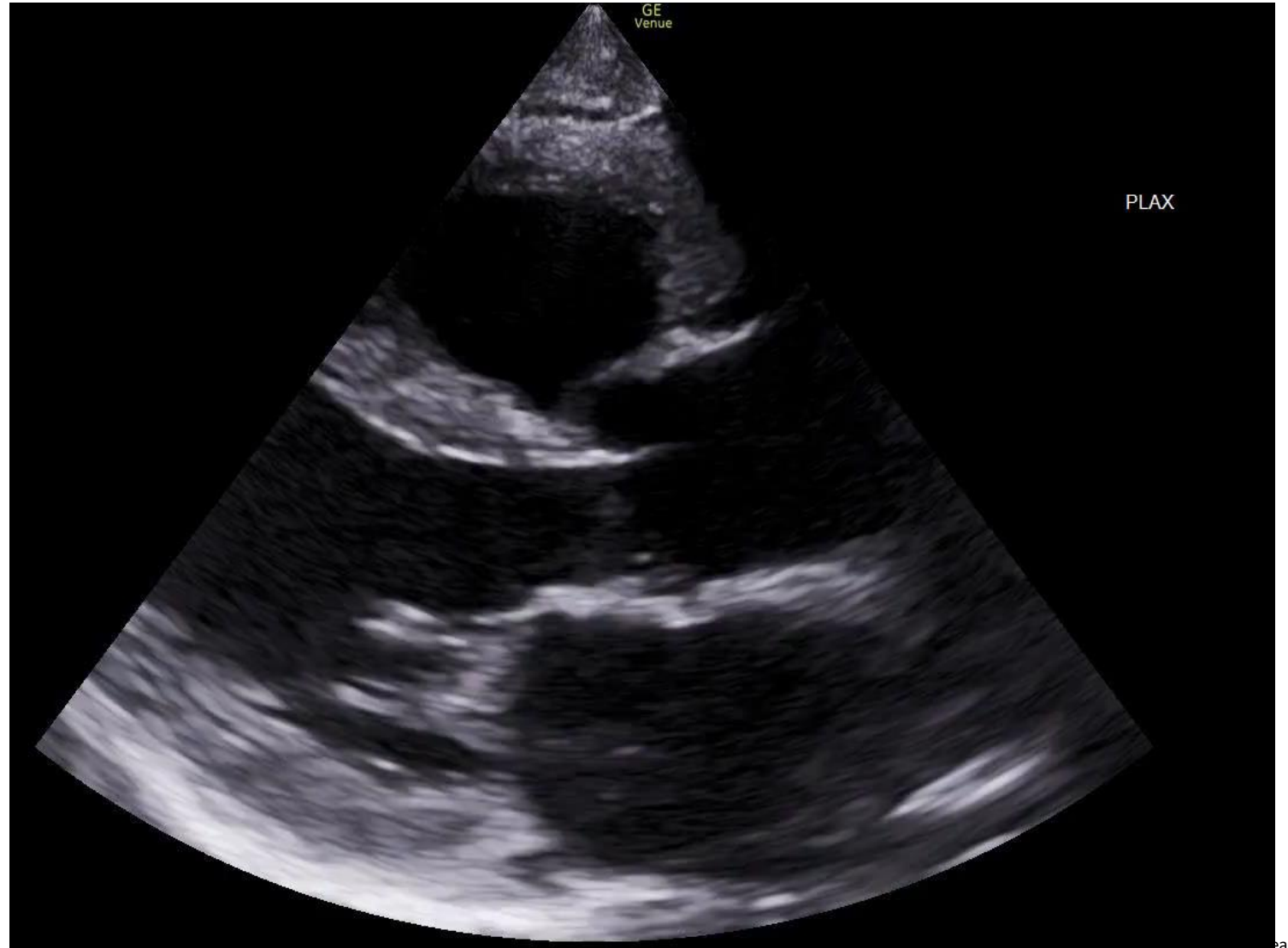
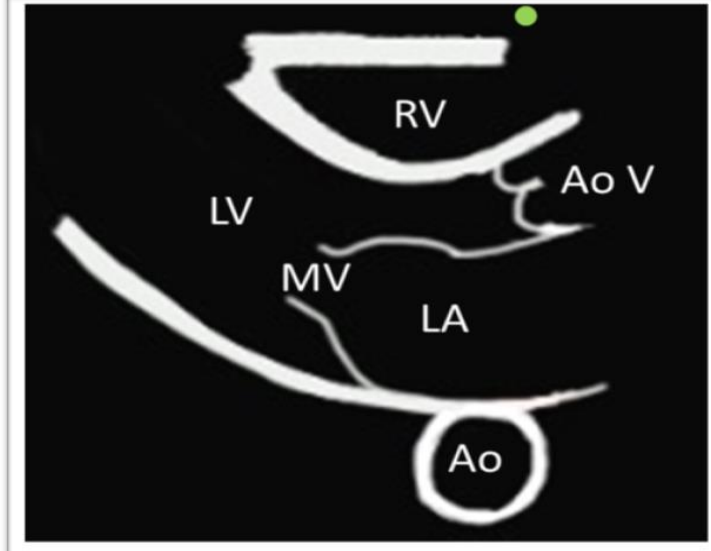
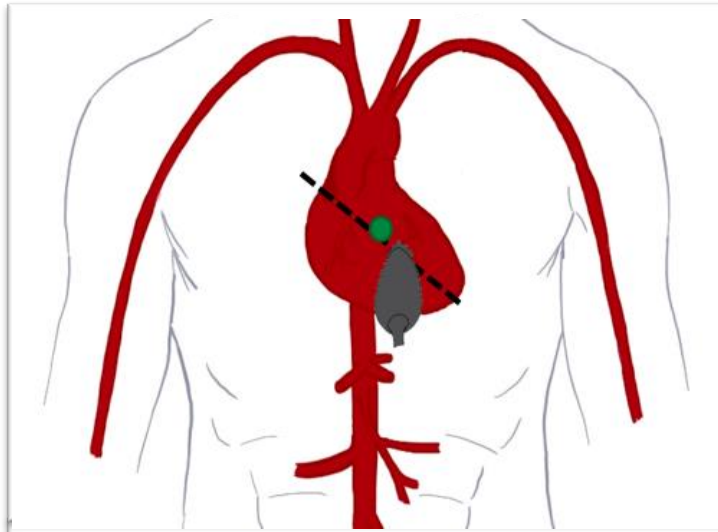
FOCUS

- Surrogate marker for RA Pressure / Central Venous Pressure
- JVP \approx IVC

IVC Findings	CVP (mm Hg)	Clinical Correlation
IVC < 2.1 cm, with > 50% collapse	3 (range 0 – 5)	Probable hypovolemia
IVC < 2.1 cm, with < 50% collapse IVC > 2.1 cm, with > 50% collapse	8 (range 5 – 10)	
IVC > 2.1, with < 50% collapse	15 (range 10 – 20)	Possible hypervolemia

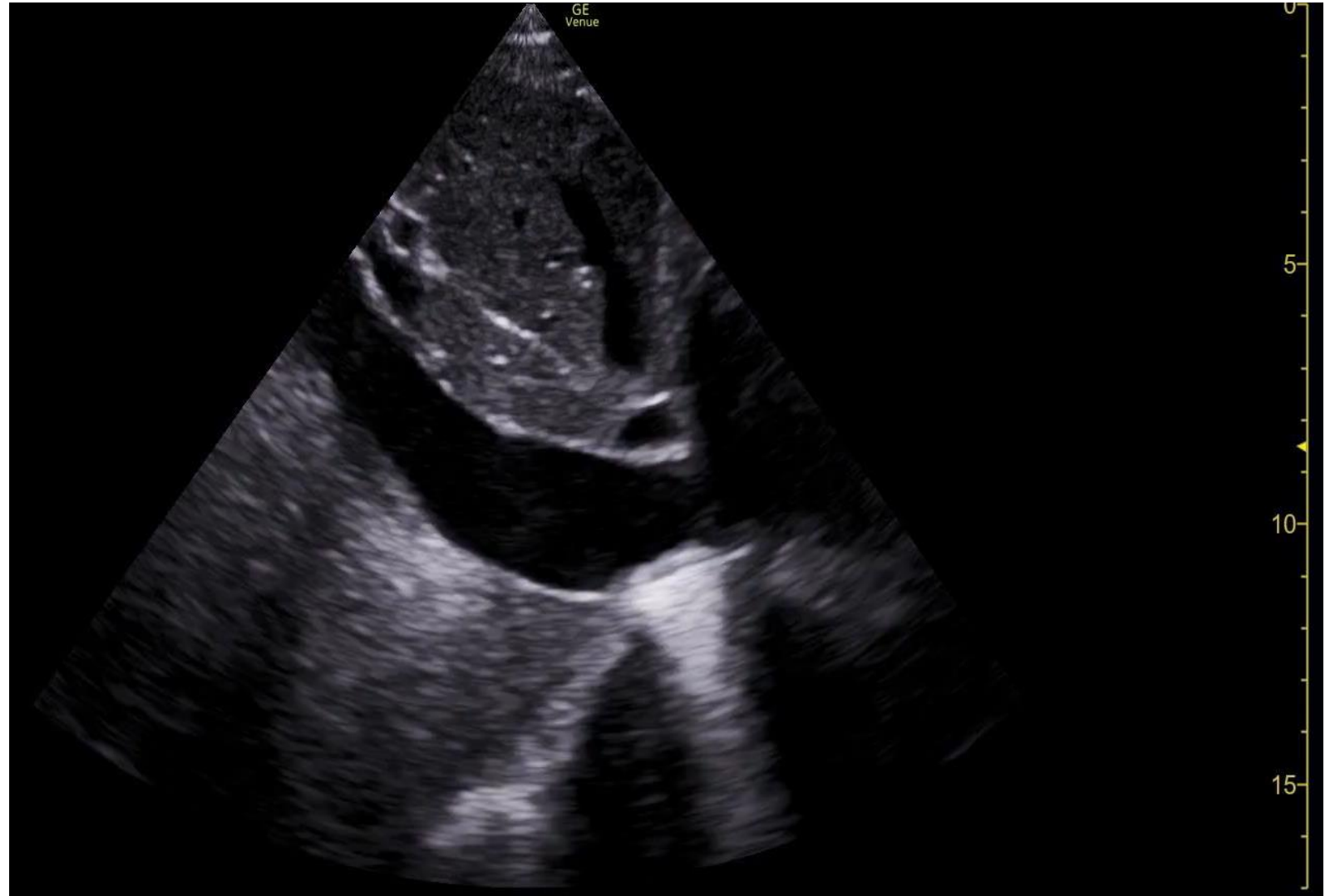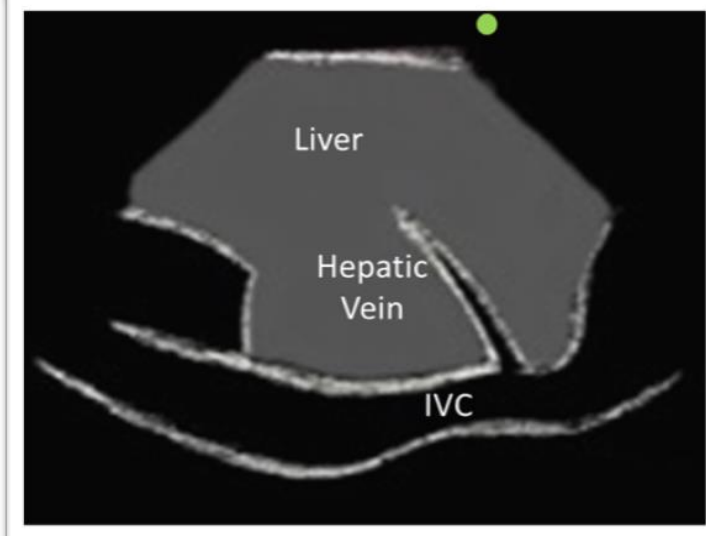
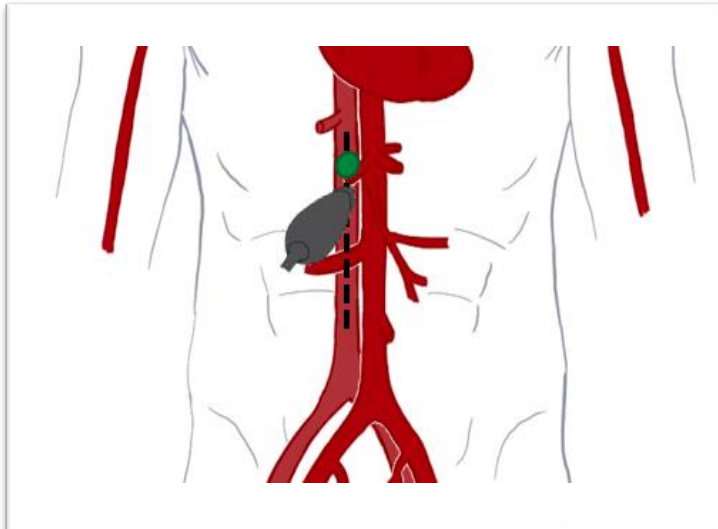
Case 1

PLAX



Case 1

IVC



Case 1

Based on the FoCUS obtained, what is the patient's qualitative LV function?

- A. Hyperdynamic
- B. Normal
- C. Reduced / Severely Reduced
- D. IDK... what do I look like? A Cardiologist?

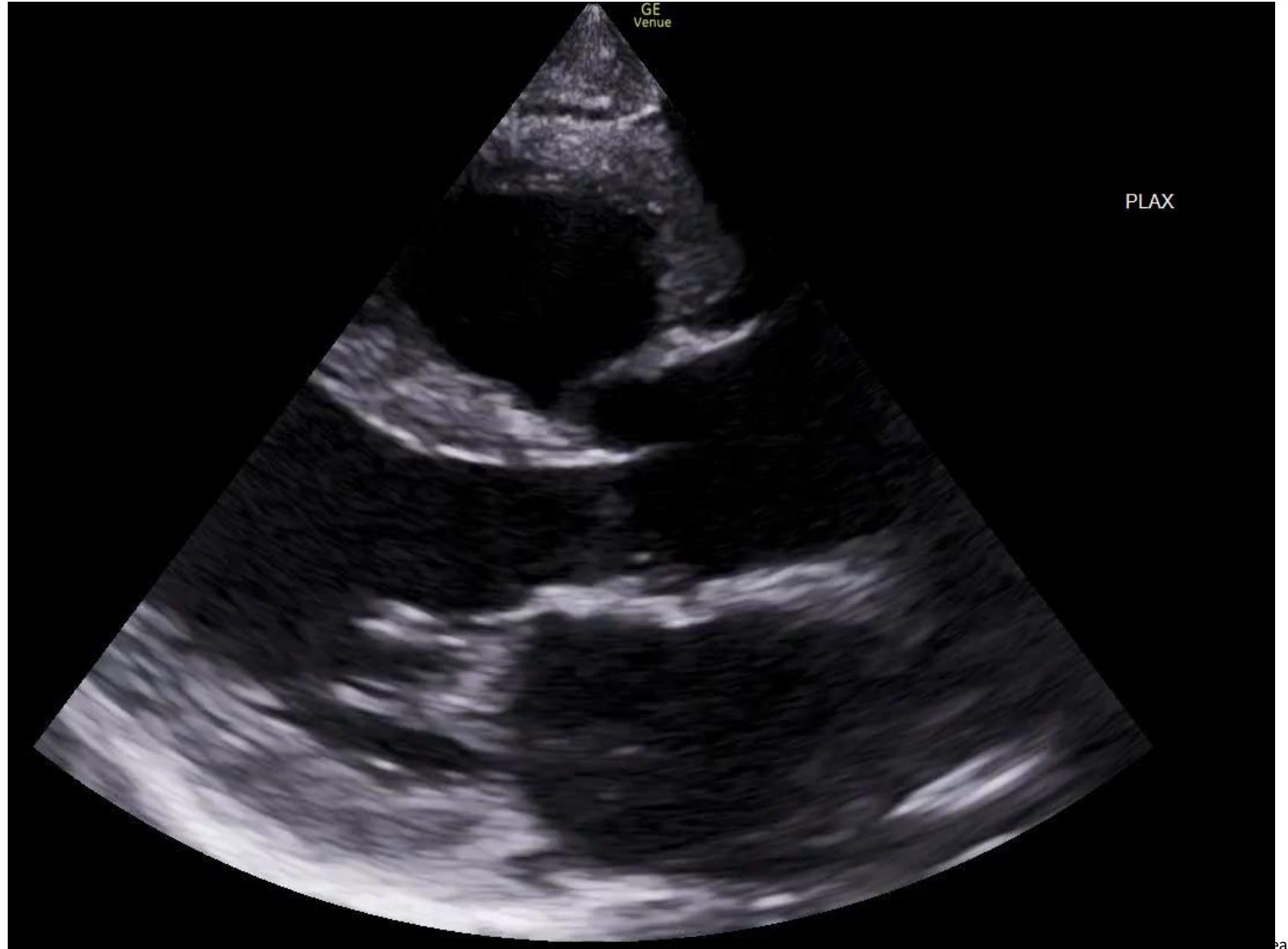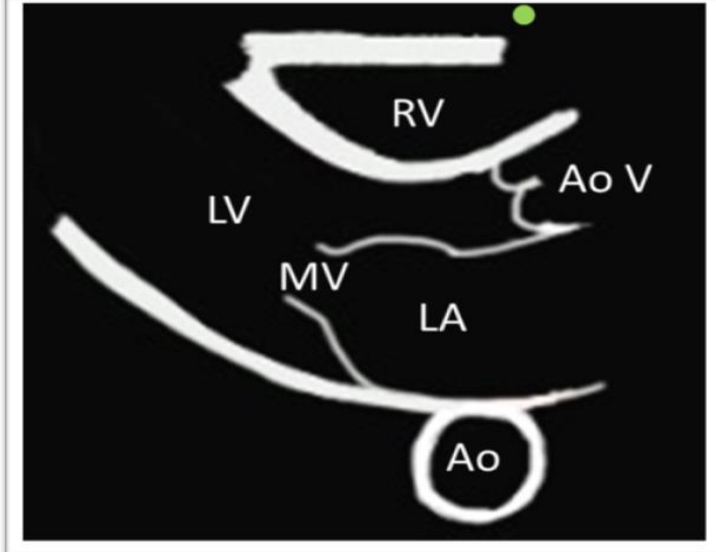
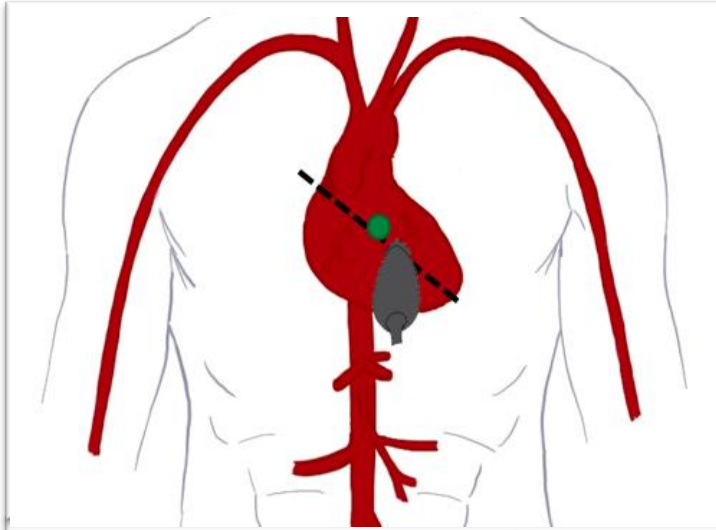
Case 1

Based on the FoCUS obtained, what is the patient's qualitative LV function?

- A. Hyperdynamic
- B. Normal
- C. Reduced / Severely Reduced
- D. IDK... what do I look like? A Cardiologist?

Case 1

PLAX

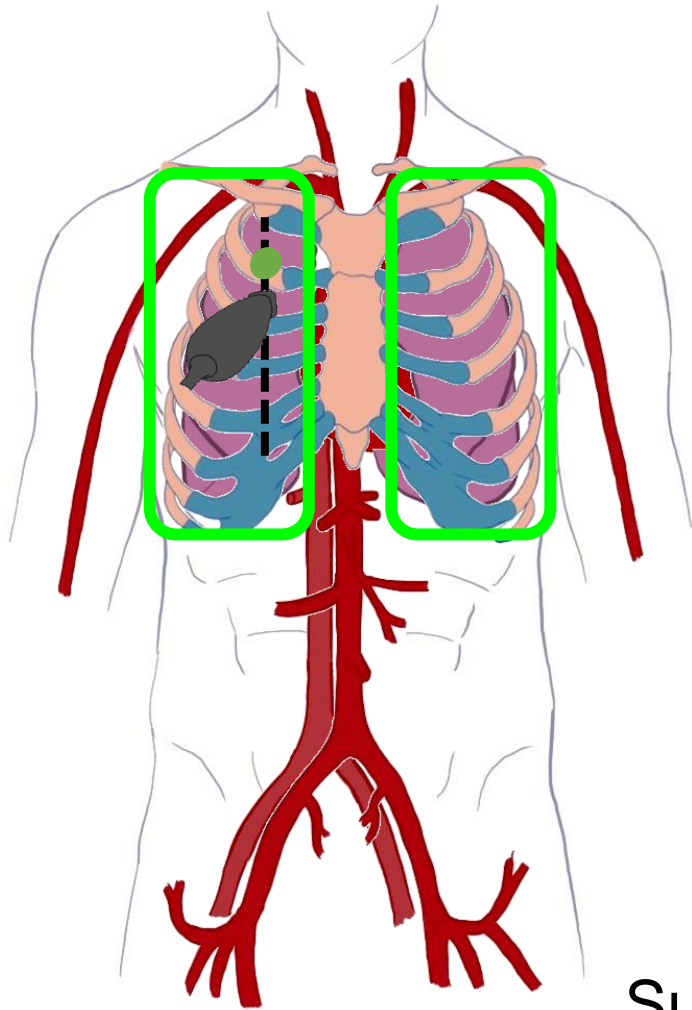


Lung ultrasound

- Scope:
 - Pulmonary Edema
 - Pneumonia (viral and bacterial)
 - Pleural effusions (simple vs complex)
 - Pneumothorax
- Indications:
 - Dyspnea
 - Hypoxia
 - Respiratory Failure
 - Intravascular volume assessment

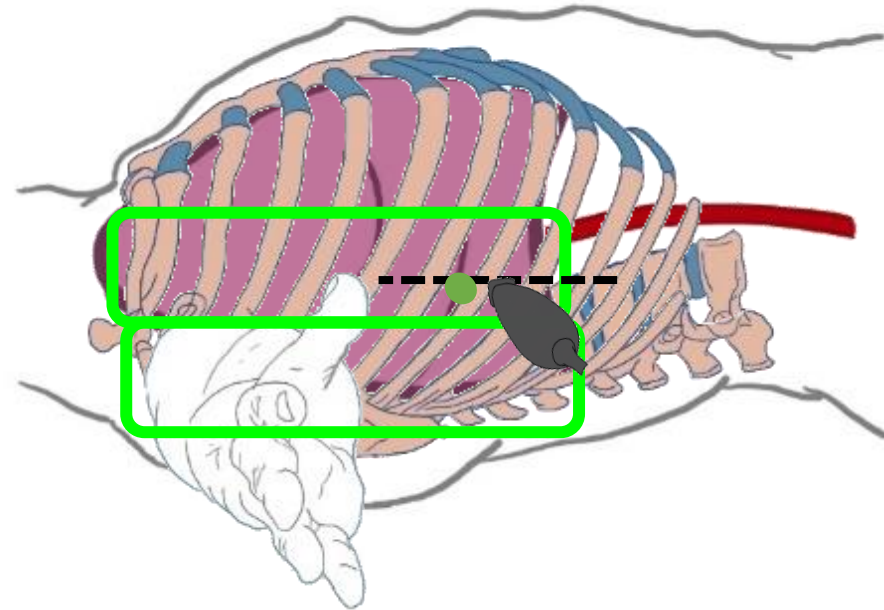
Lung Ultrasound

Zone 1



Zone 2

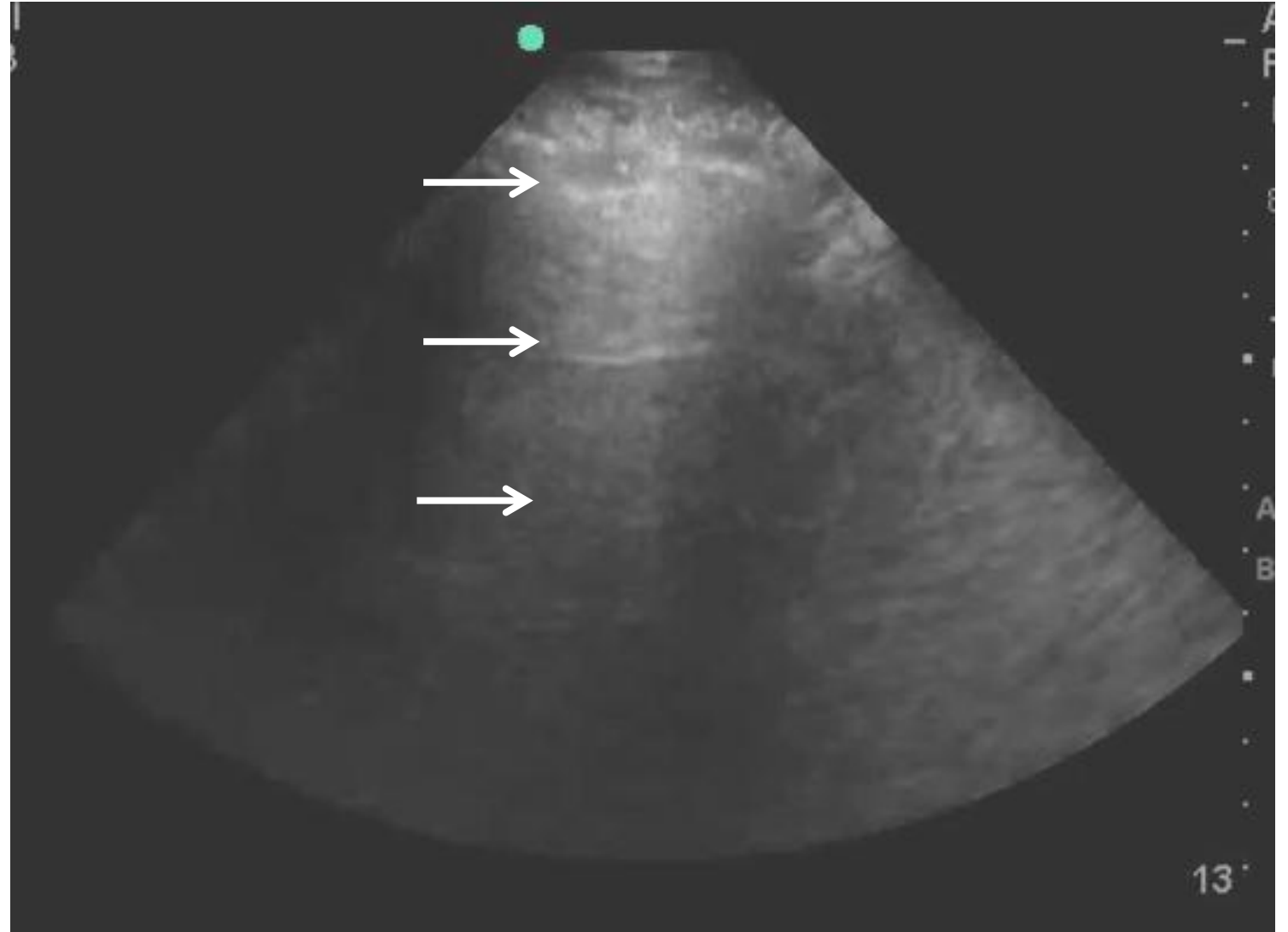
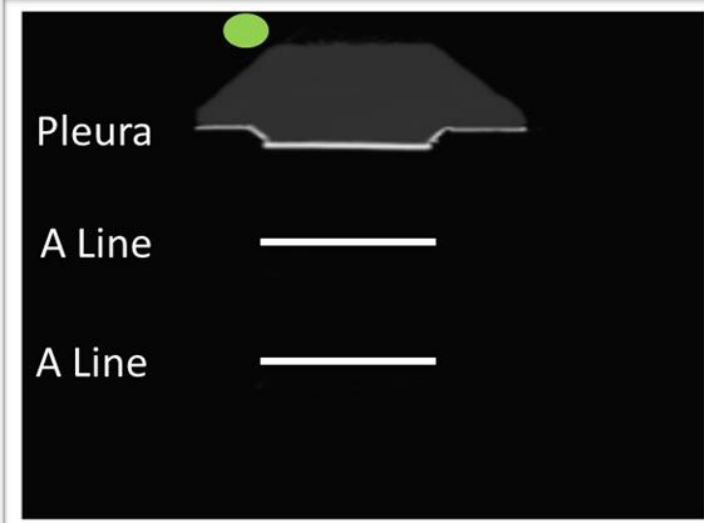
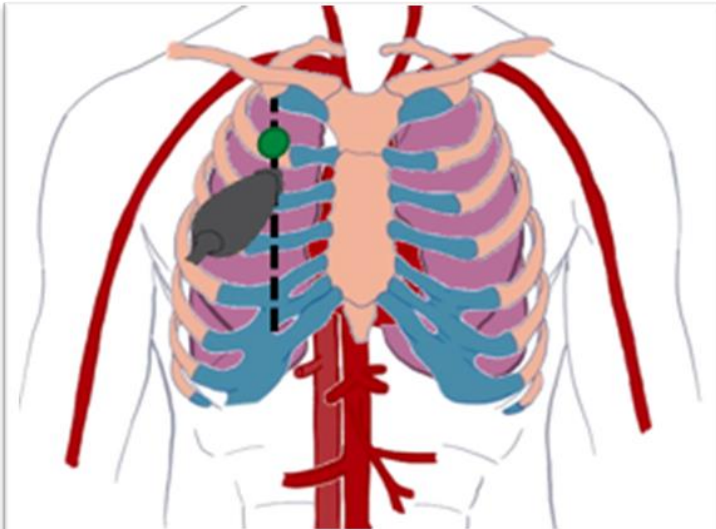
Zone 3



Superior + Inferior Points

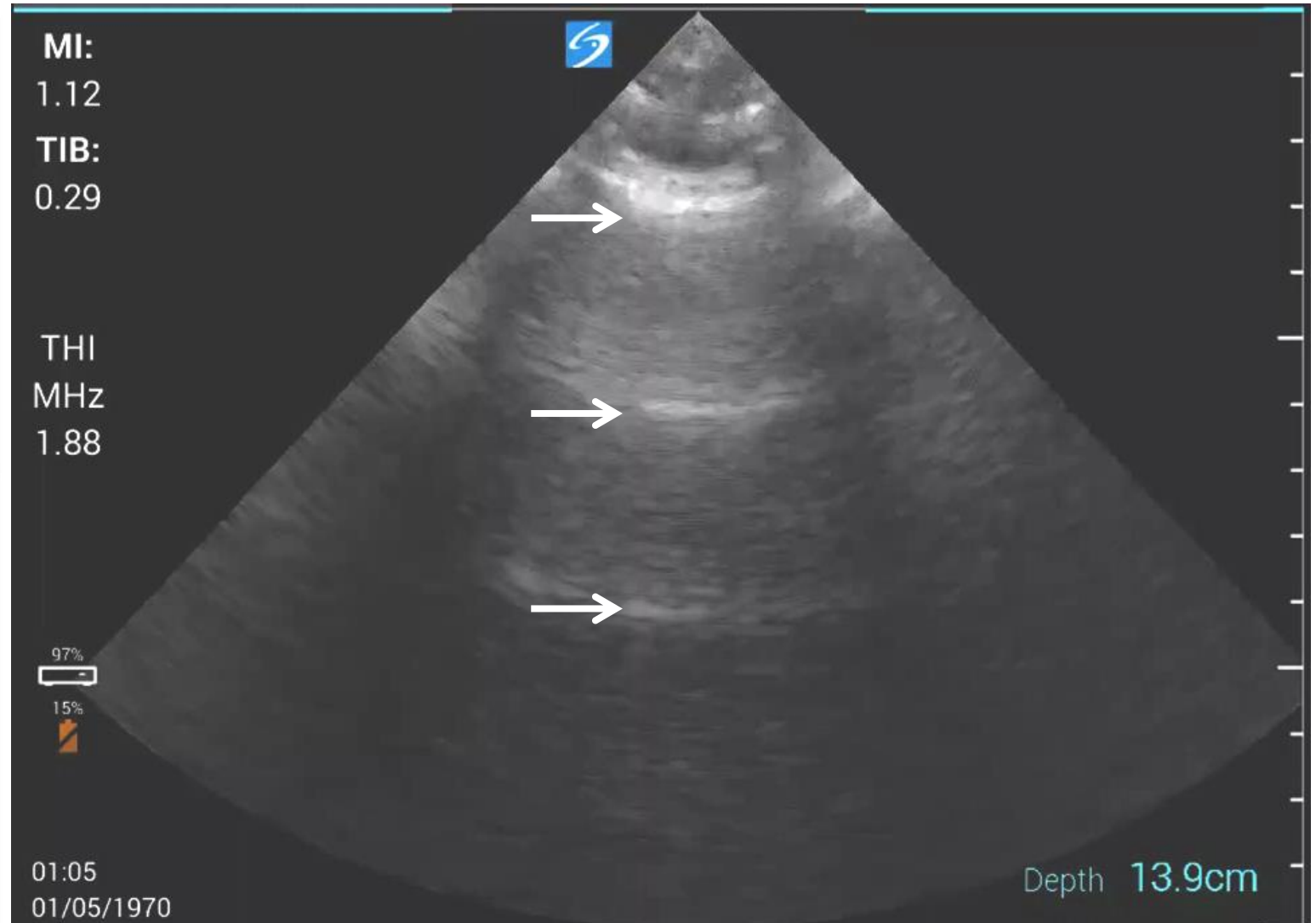
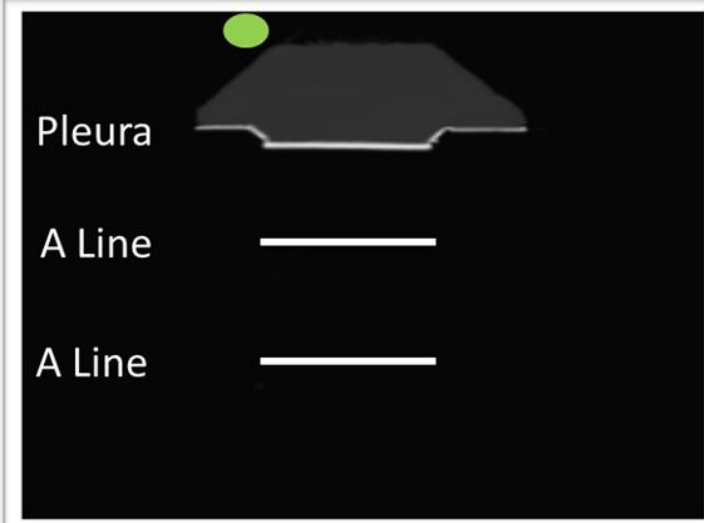
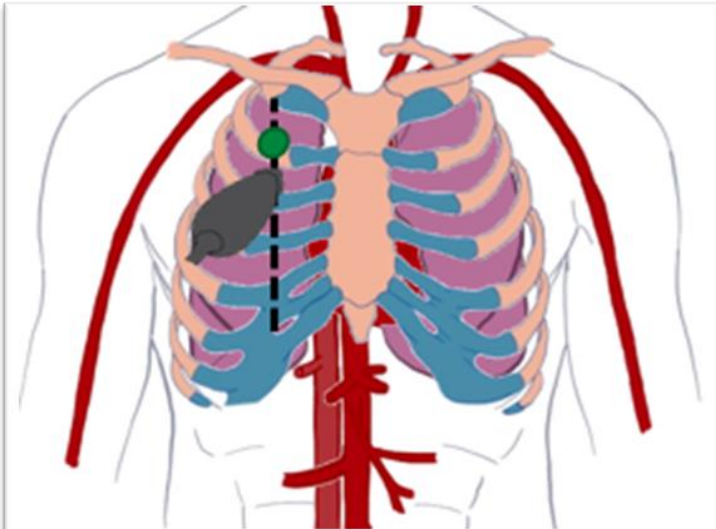
Lung Ultrasound

A Lines + Lung Sliding



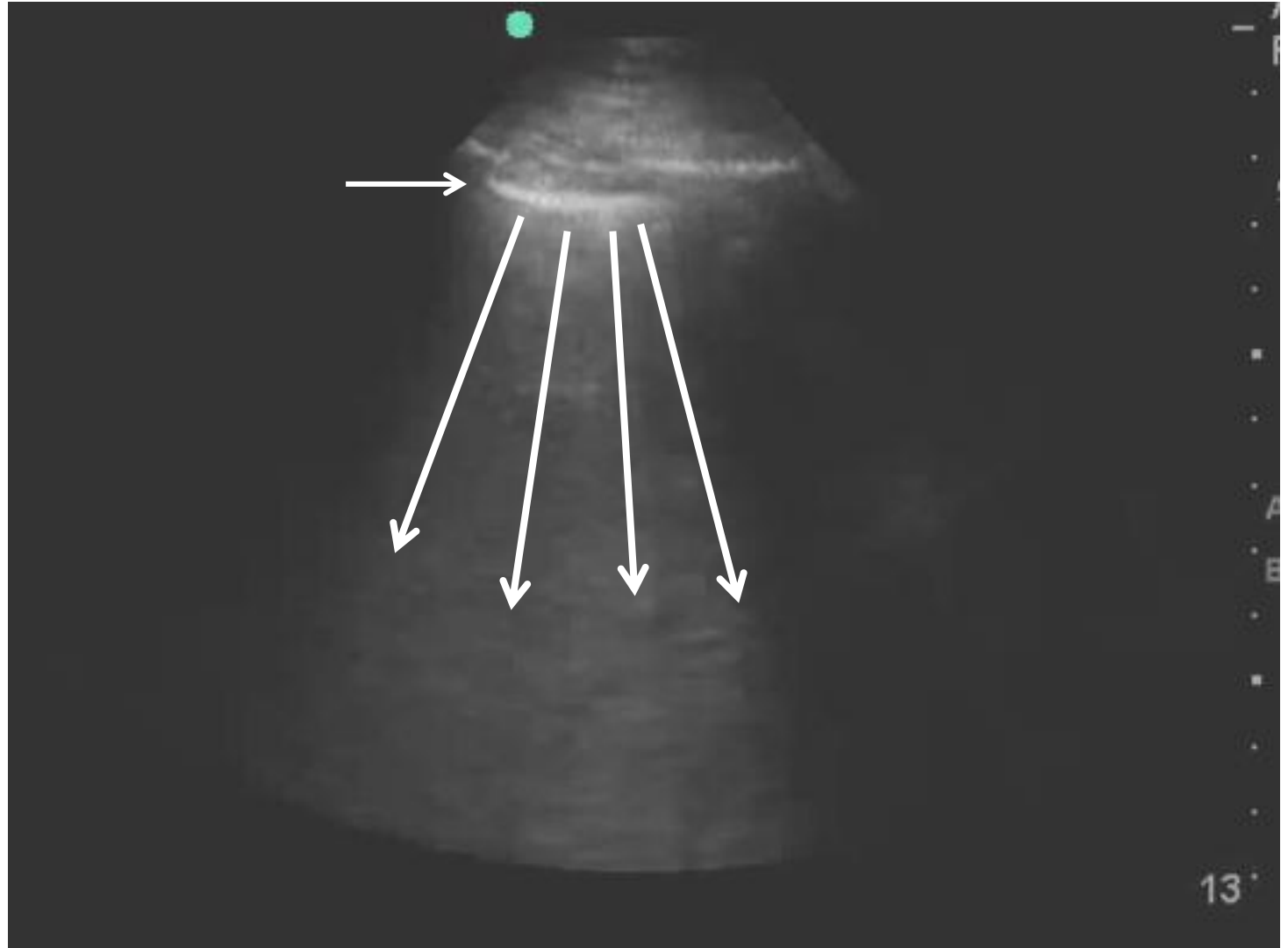
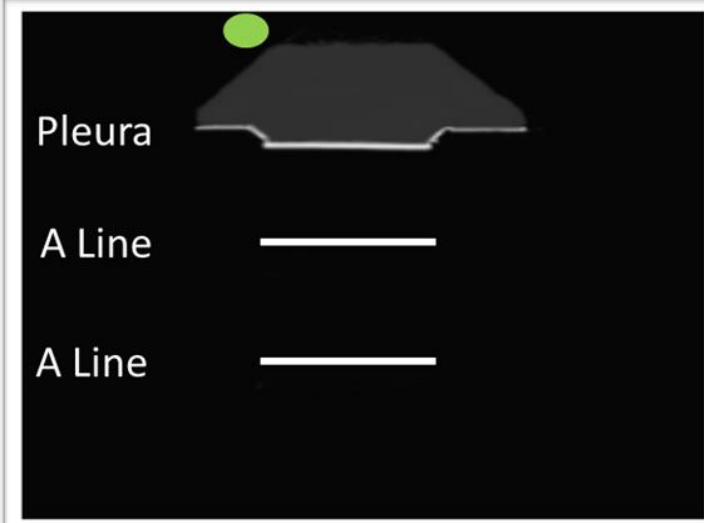
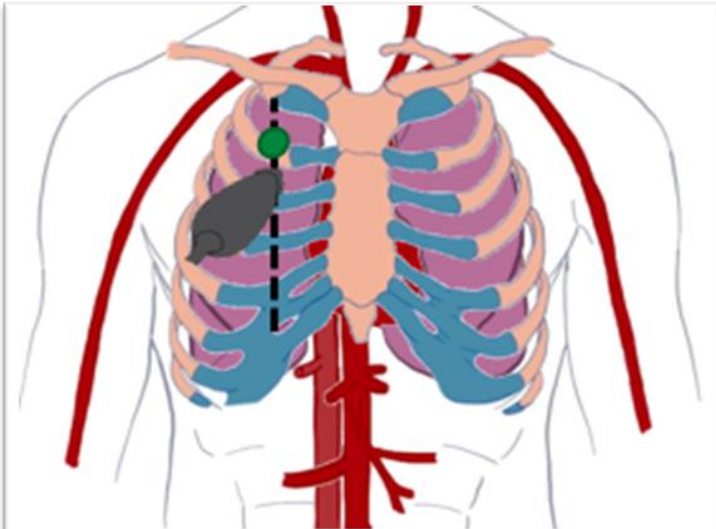
Lung Ultrasound

A Lines + Absent Lung Sliding



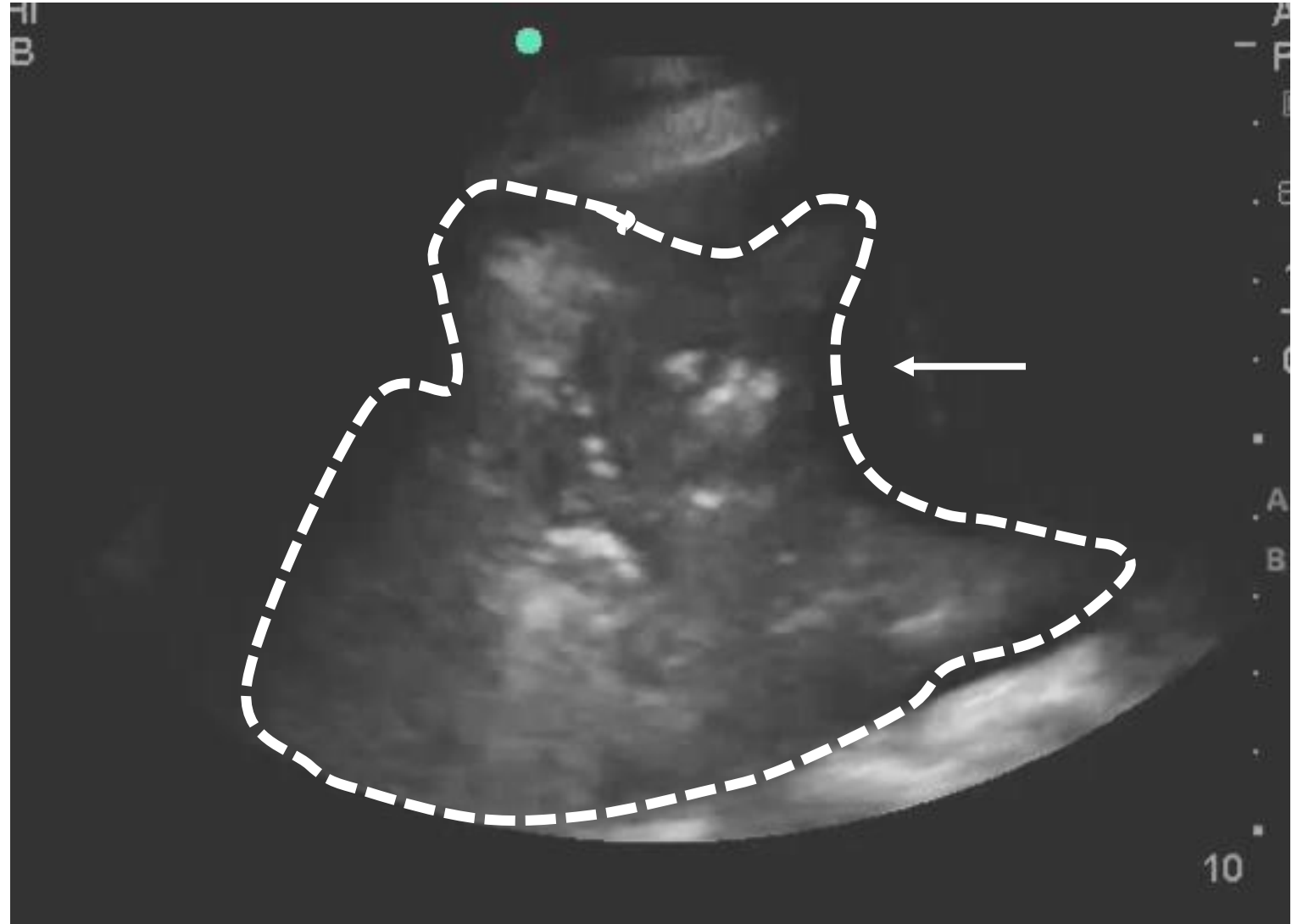
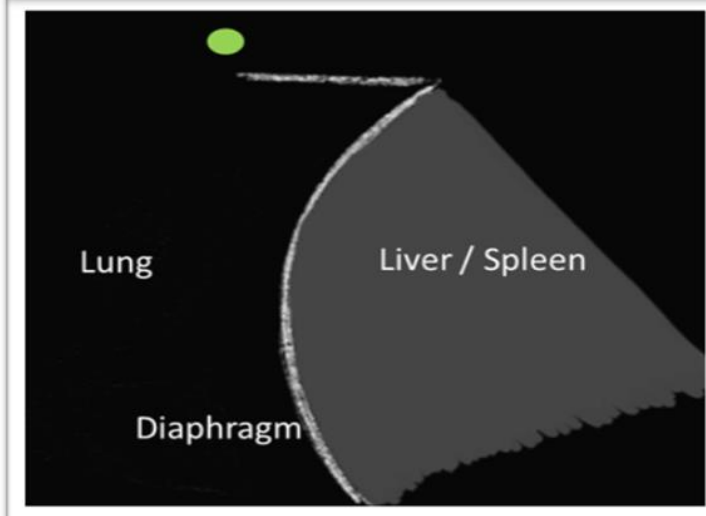
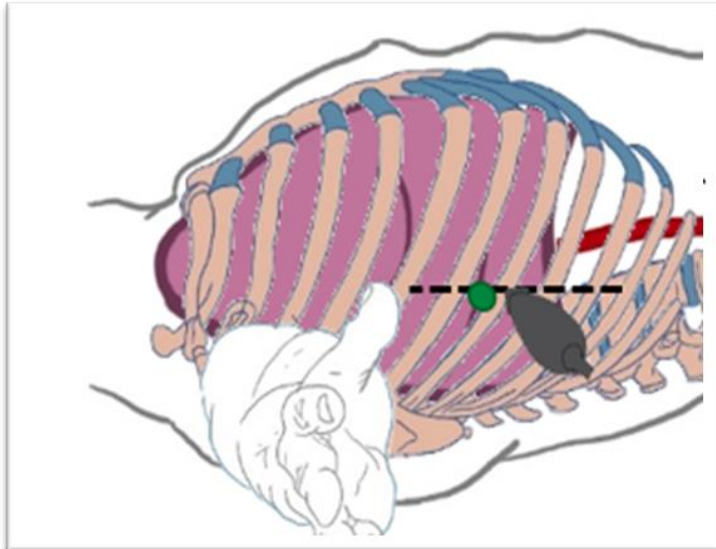
Lung Ultrasound

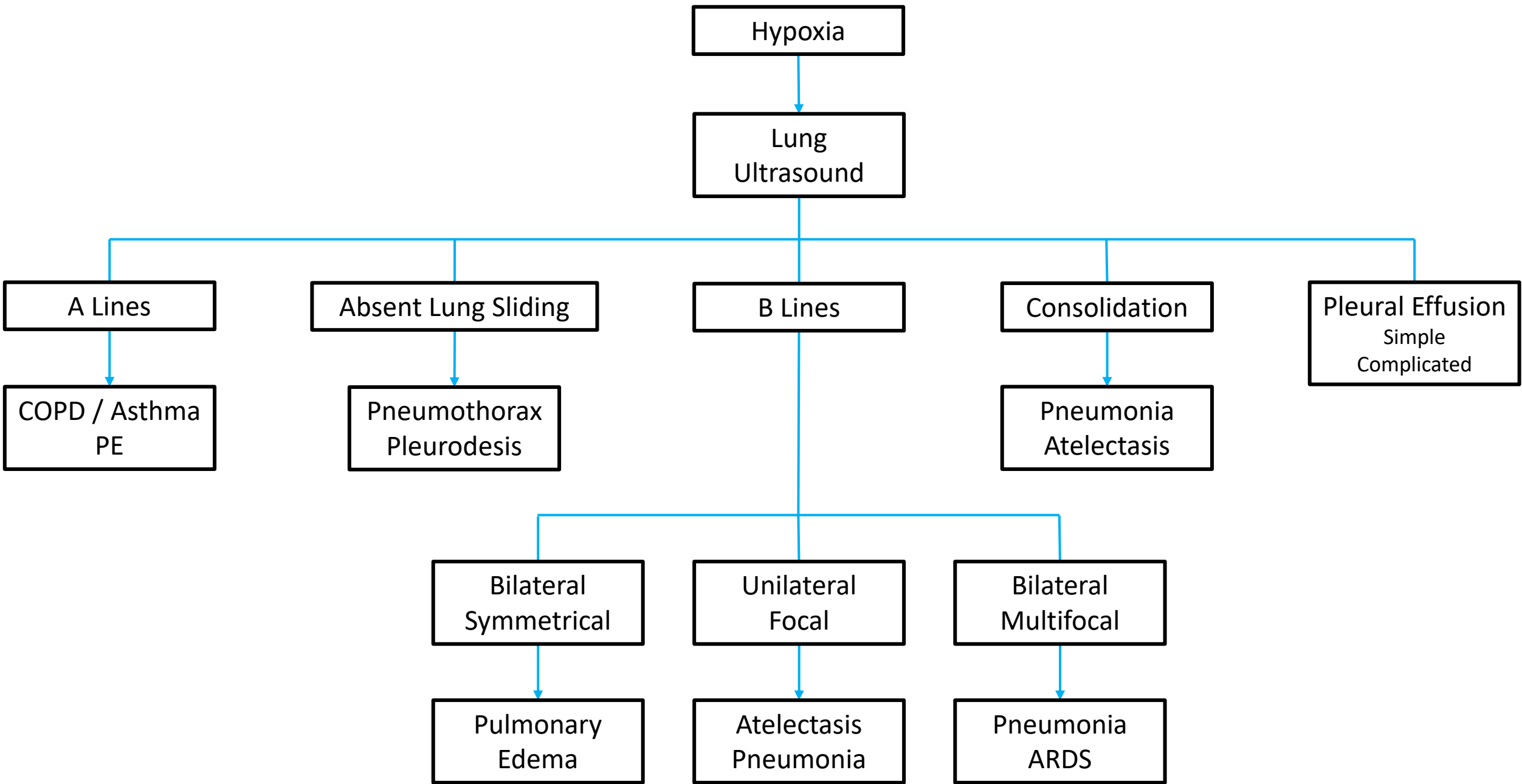
B Lines



Lung Ultrasound

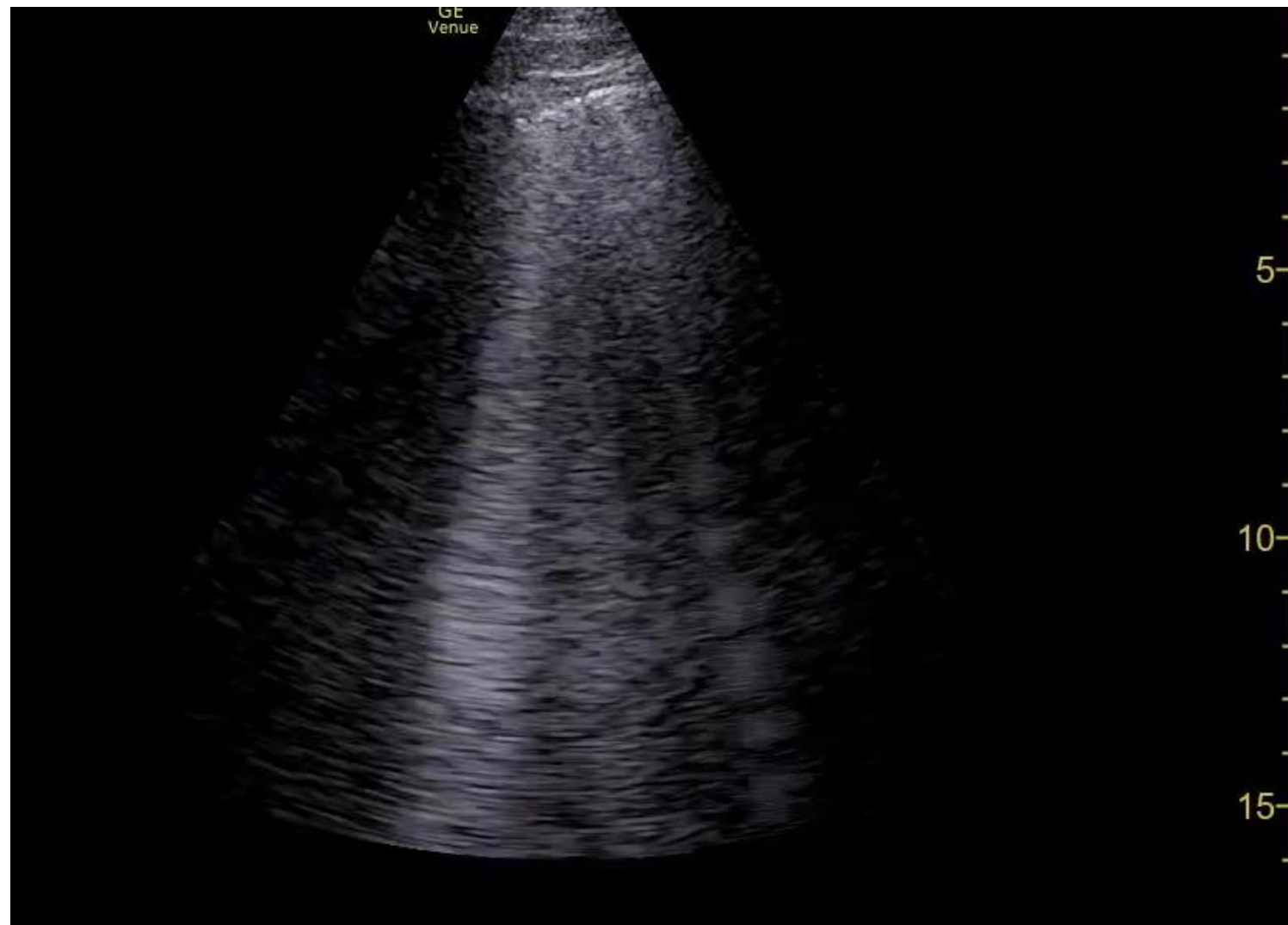
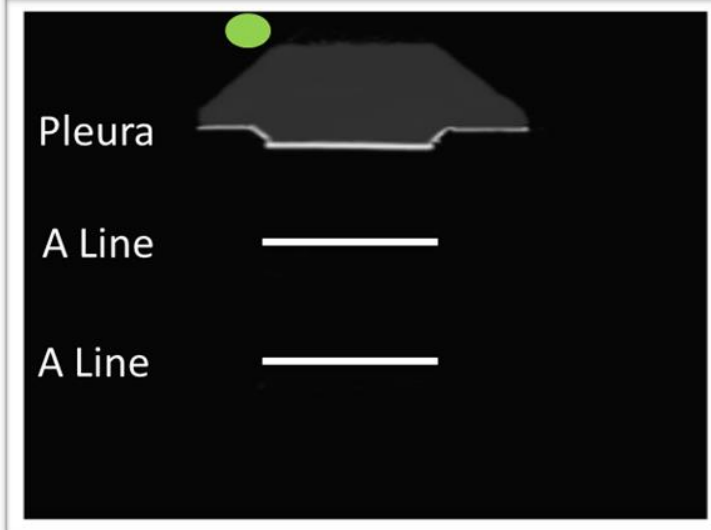
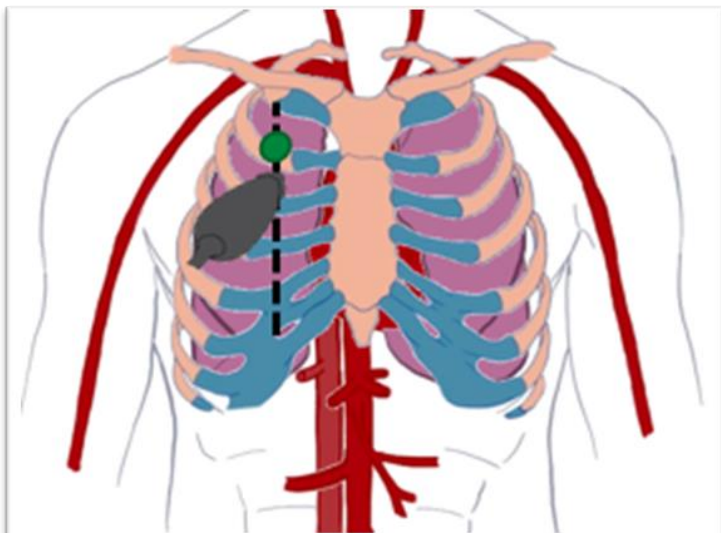
Consolidation + Pleural Effusion





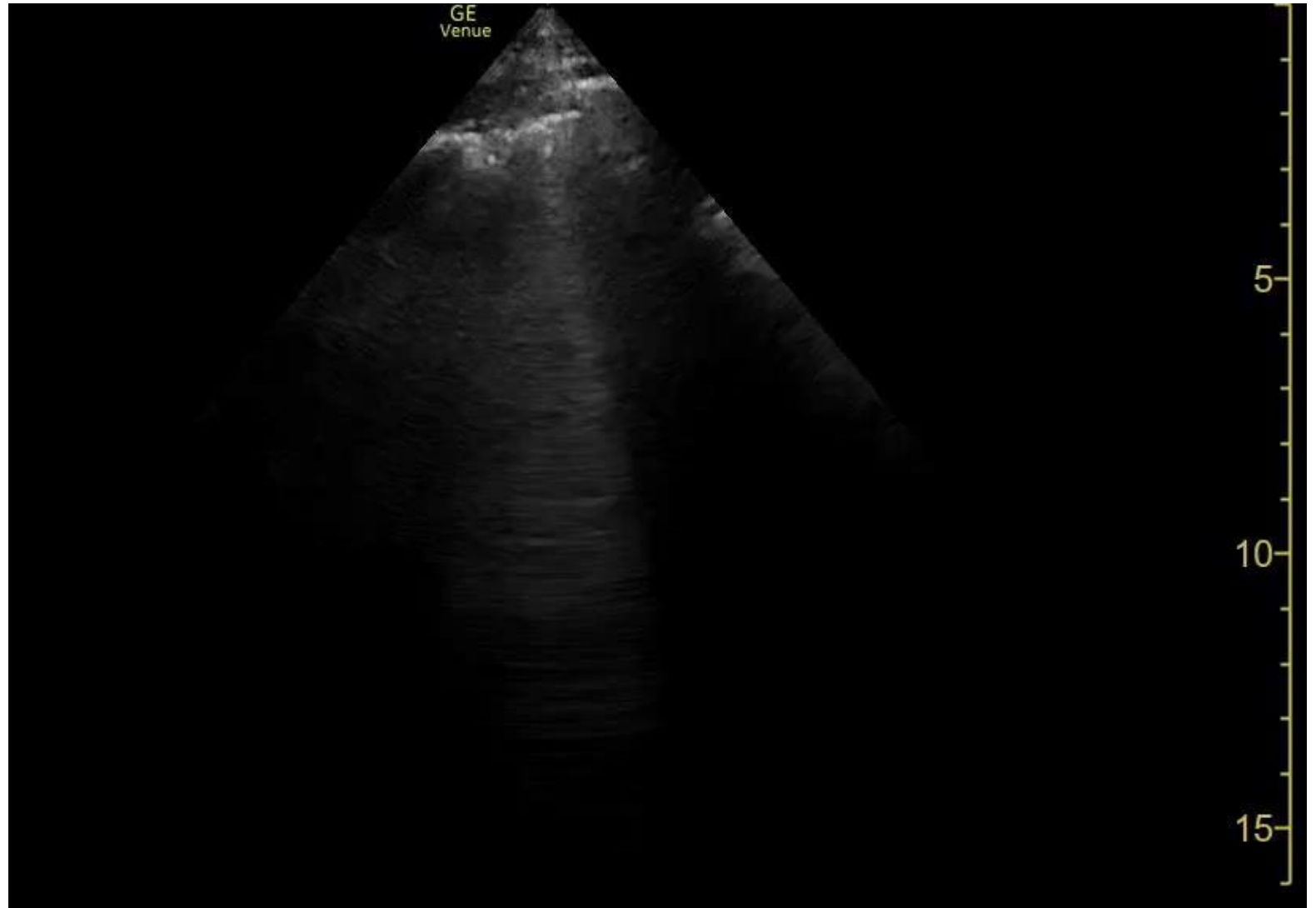
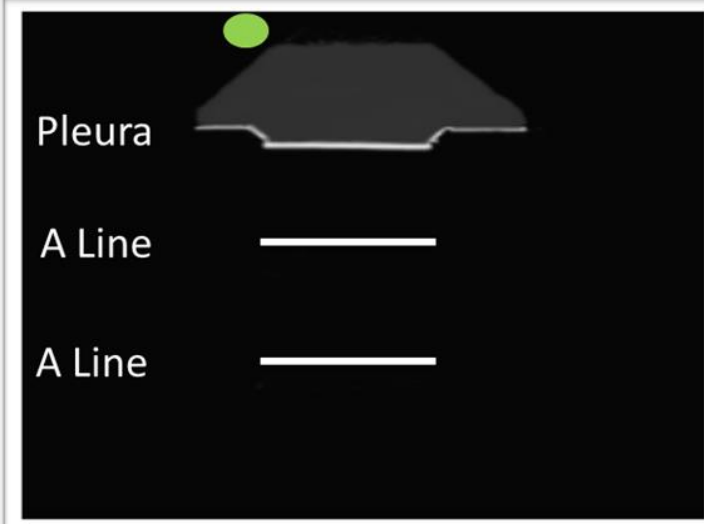
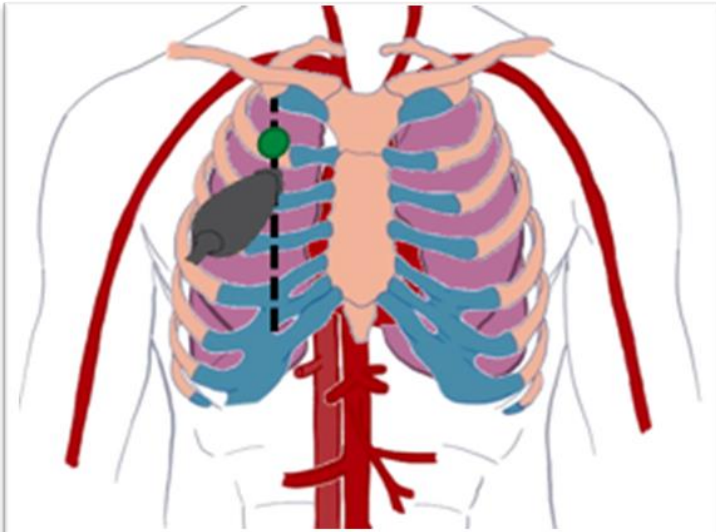
Case 1

Left Apex



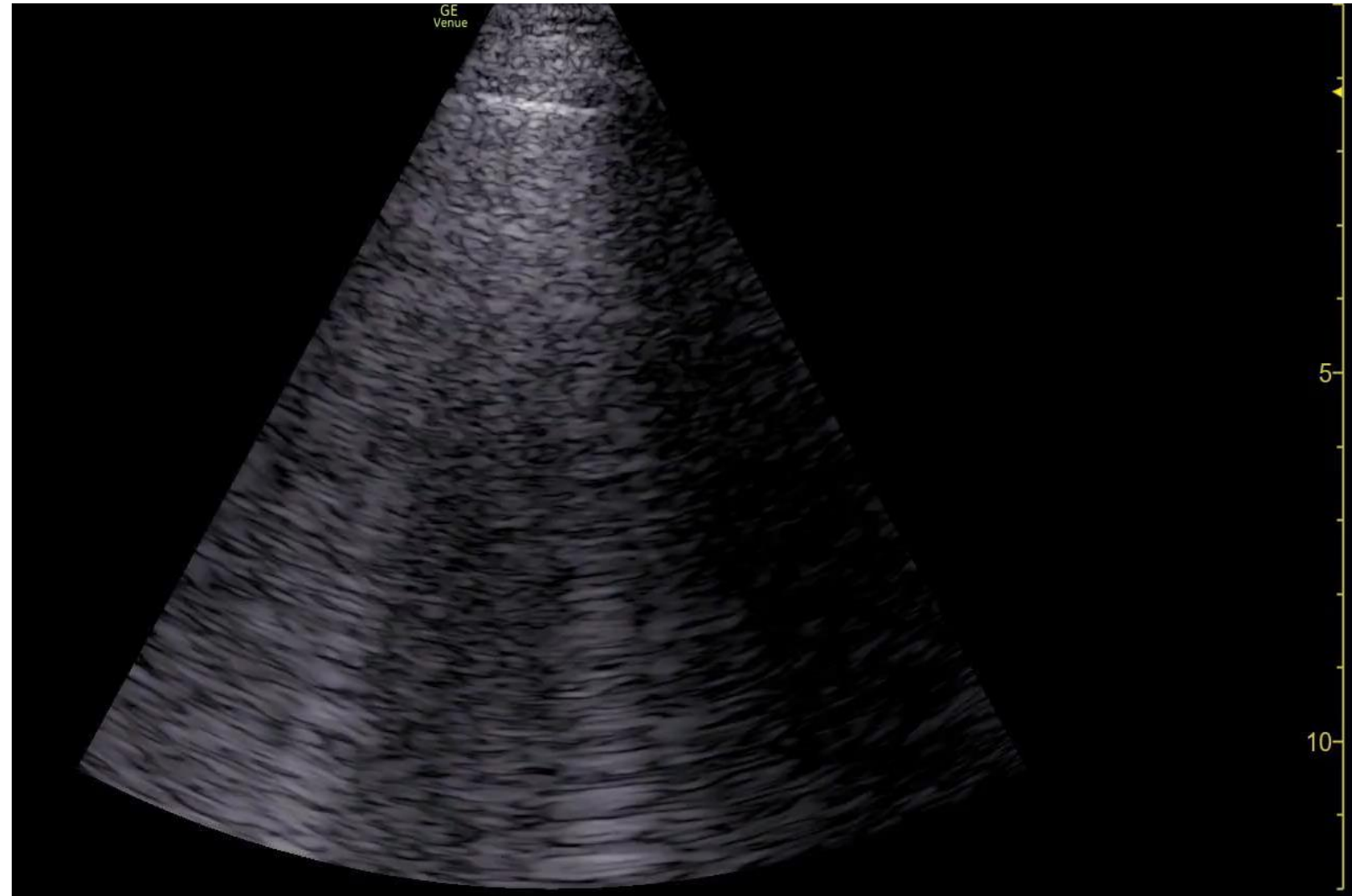
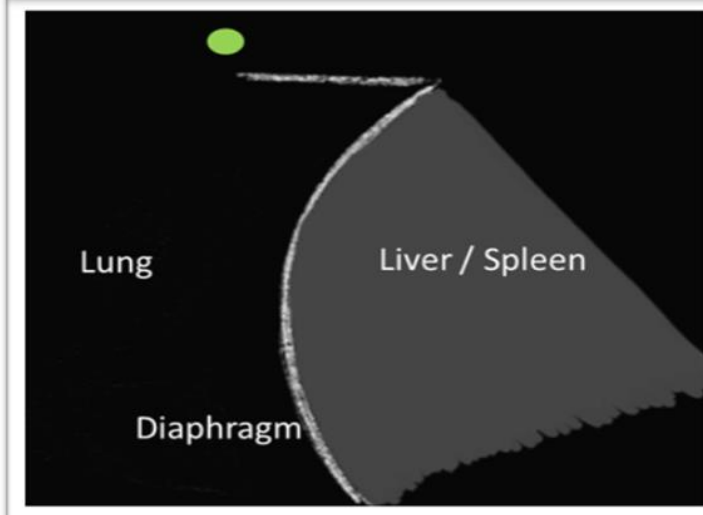
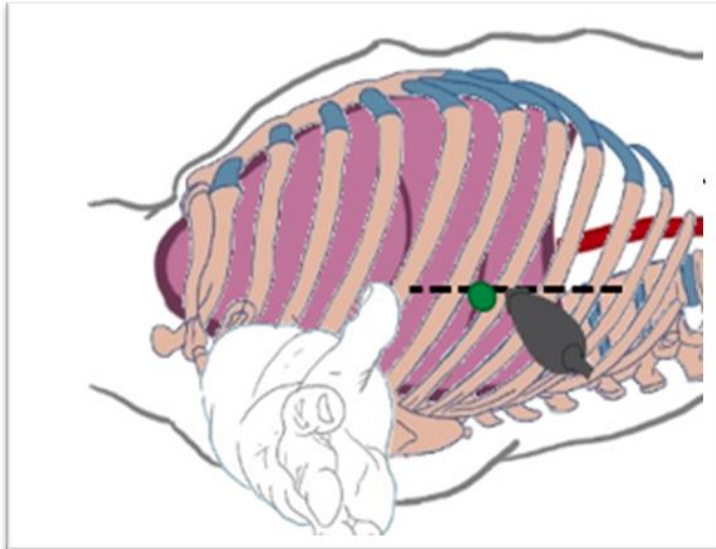
Case 1

Right Apex



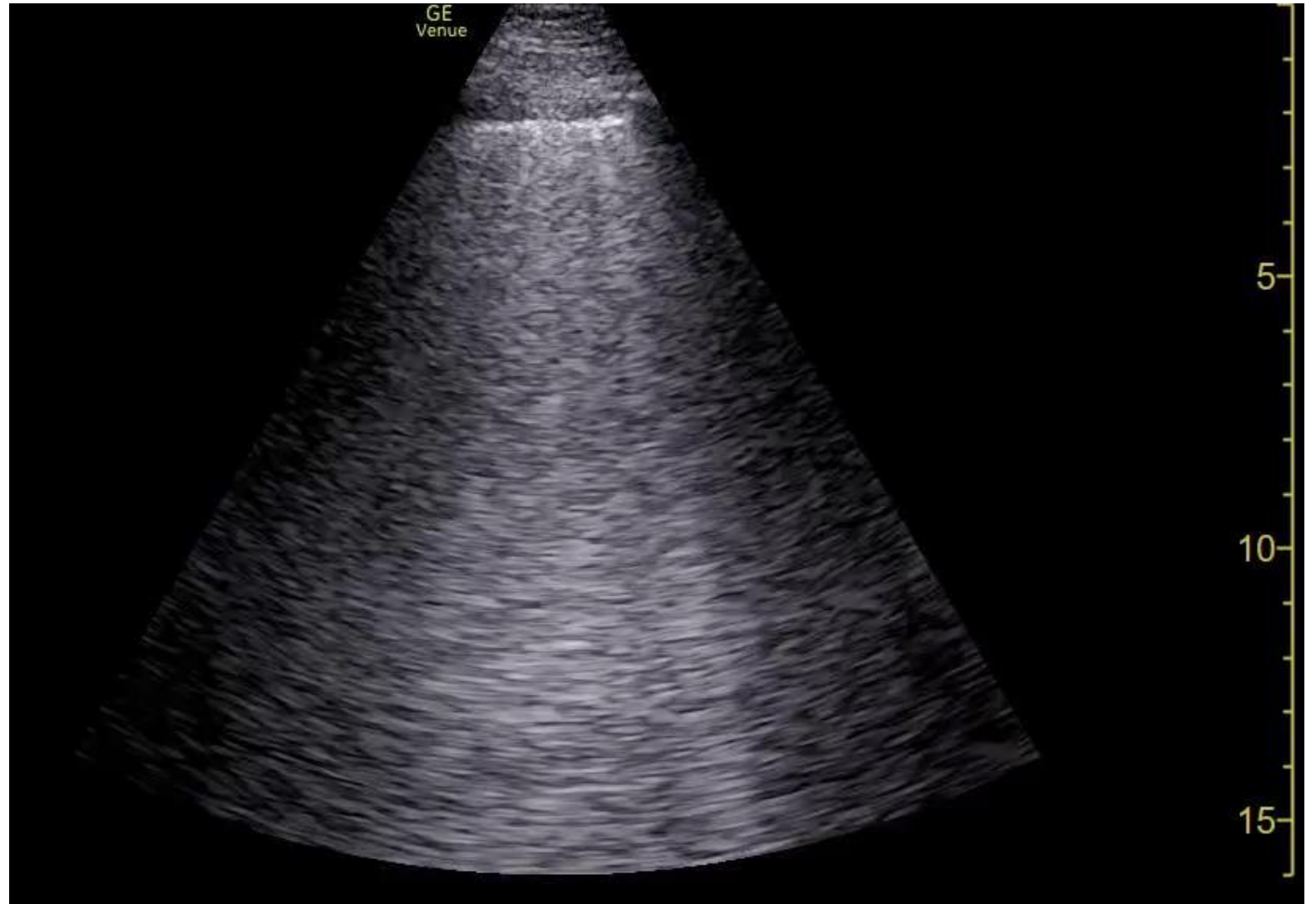
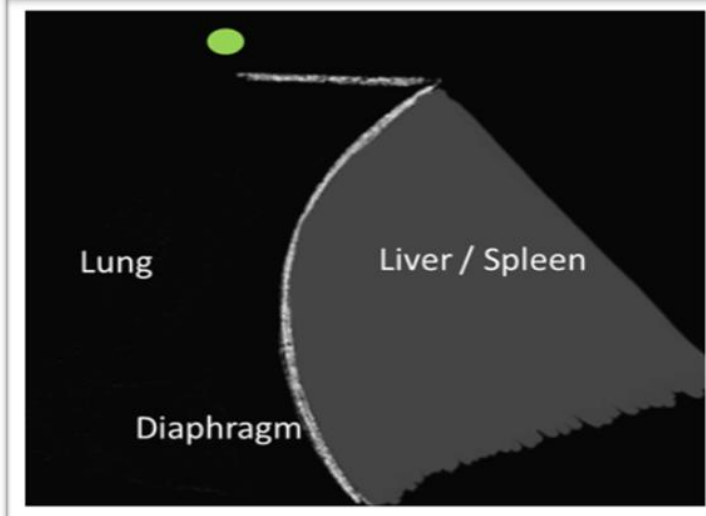
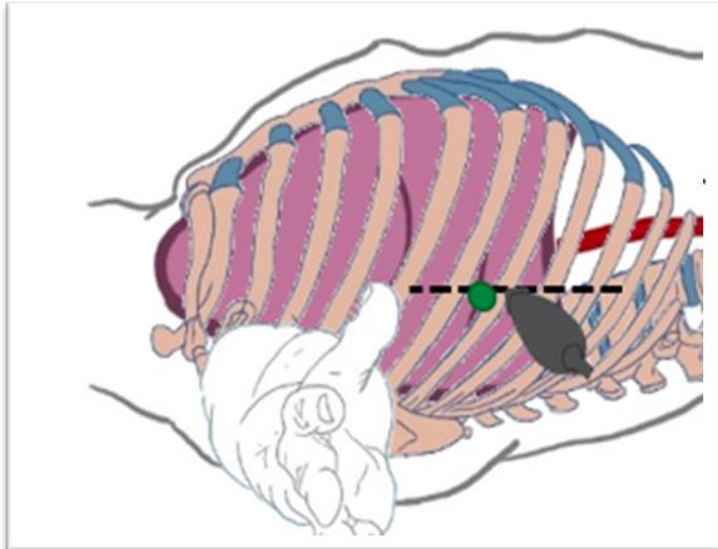
Case 1

Left Base



Case 1

Right Base



Case 1

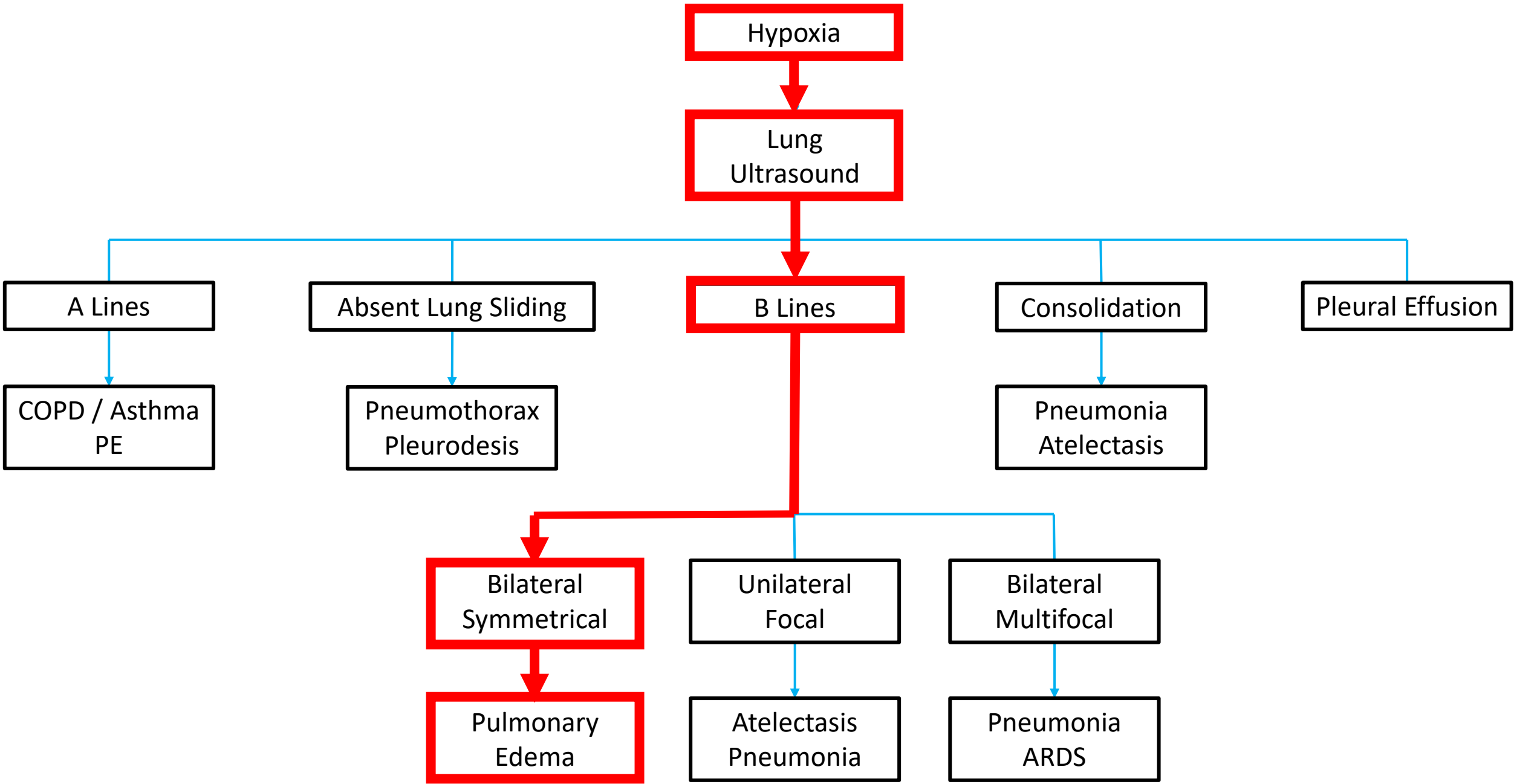
Based on the lung ultrasound findings, what is the most likely diagnosis for the patient's presentation?

- A. COPD Exacerbation
- B. Lobar pneumonia
- C. CHF Exacerbation
- D. Pneumothorax

Case 1

Based on the lung ultrasound findings, what is the most likely diagnosis for the patient's presentation?

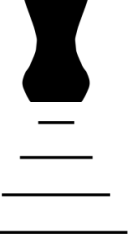- A. COPD Exacerbation
- B. Lobar pneumonia
- C. CHF Exacerbation
- D. Pneumothorax



Case 1

Diagnosed with acute decompensated heart failure with reduced ejection fraction

- NOT COPD
- Diuretics started, steroids/antibiotics stopped
- Echo
- HFrEF meds started
- Cardiology follow up



CHF

33.5% of patients with CHF exacerbation presenting to the ED with dyspnea are missed.¹

“Bedside lung US and echocardiography appear to be the **most useful test** for affirming the presence of AHF.”²

1. Collins SP, Lindsell CJ, Peacock WF, Eckert DC, Askew J, Storrow AB. Clinical Characteristics of emergency department heart failure patients initially diagnosed as non-heart failure. BMC Emergency Medicine. 2006;6:11. doi:10.1186/1471-227X-6-11.
2. Martindale JL, Wakai A, Collins SP, et al. Diagnosing Acute Heart Failure in the Emergency Department: A Systematic Review and Meta-analysis. Acad Emerg Med. 2016 Mar;23(3):223-42. doi: 10.1111/acem.12878. Epub 2016 Feb 13.

	Chest X-ray		Lung Ultrasound	
	Sensitivity	Specificity	Sensitivity	Specificity
Pulmonary Edema	56.9%	89.2%	85.3 – 94.1%	92%

- Alrajab S, Yousef AM, Akkus N, Caldito G. Pleural ultrasonography versus chest radiography for the diagnosis of pneumothorax: review of the literature and meta-analysis. *Critical Care* 2013, 17:R208.
- Martindale JL, Wakai A, Collins SP, et al. Diagnosing Acute Heart Failure in the Emergency Department: A Systematic Review and Meta-analysis. *Acad Emerg Med*. 2016 Mar;23(3):223-42. doi: 10.1111/acem.12878. Epub 2016 Feb 13.
- Al Deeb M, Barbic S, Featherstone R, Dankoff J, Barbic D. Point-of-Care ultrasonography for the diagnosis of acute cardiogenic pulmonary edema in patients presenting with acute dyspnea: a systematic review and meta-analysis. *Acad Emerg Med* . 2014 Aug;21(8):843-52. doi: 10.1111/acem.12435

	Chest X-ray		Lung Ultrasound	
	Sensitivity	Specificity	Sensitivity	Specificity
Pulmonary Edema	56.9%	89.2%	85.3 – 94.1%	92%
Pneumonia	38 – 64%	93%	85 – 96%	93 – 96%
Pneumothorax	39.8 – 50.2%	99%	90.9%	99%
Pleural Effusion	51%	91%	94%	98%
COVID-19	51.9%		88.9%	

- Alrajab S, Yousef AM, Akkus N, Caldito G. Pleural ultrasonography versus chest radiography for the diagnosis of pneumothorax: review of the literature and meta-analysis. *Critical Care* 2013, 17:R208.
- Martindale JL, Wakai A, Collins SP, et al. Diagnosing Acute Heart Failure in the Emergency Department: A Systematic Review and Meta-analysis. *Acad Emerg Med*. 2016 Mar;23(3):223-42. doi: 10.1111/acem.12878. Epub 2016 Feb 13.
- Al Deeb M, Barbic S, Featherstone R, Dankoff J, Barbic D. Point-of-Care ultrasonography for the diagnosis of acute cardiogenic pulmonary edema in patients presenting with acute dyspnea: a systematic review and meta-analysis. *Acad Emerg Med*. 2014 Aug;21(8):843-52. doi: 10.1111/acem.12435

Case 2



Case 2

- Asked to urgently evaluate a 74 year-old gentleman for confusion and hypotension.
 - Unable to provide history.
- Hospital Course:
 - Admitted for osteomyelitis of the left lower extremity, status post BKA
 - Diagnosed with critical limb ischemia of the right upper extremity and started on a heparin infusion.
- Past Medical History:
 - ESRD on HD
 - Diastolic left ventricular heart failure.
 - Diabetes mellitus type II.
- Past Social History:
 - Smoker (50 pack years).
 - Daily alcohol use.

Case 2

Vital Signs:

- HR 107
- BP 84/55 (from 148/90)
- SpO2 98%
- RR 18
- T 36.8 Celsius

Exam:

- Mental – Alert to person, not place or time. Lethargic. CAM positive.
- Heart – Regular rhythm and rate.
- Lungs – Faint crackles at the left base.
- Abdomen – Mildly tender to palpation.

POCUS in Shock

EGLS

RUSH: HI-MAP

FATE

ACES

RUSH: Pump, Tank, Pipes

FREE

- Weingart SD, Duque D, Nelson B. The RUSH Exam: Rapid Ultrasound for Shock and Hypotension. <https://emcrit.org/rush-exam/original-rush-article/>
- Perera P, Mailhot, T, Riley D, Mandavia D. The RUSH Exam: Rapid Ultrasound in Shock in the Evaluation of the Critically Ill. Emerg Med Clin N Am 2010;28:29–56.
- Lanctot JF, Valois M, Beaulieu Y. EGLS: Echo-Guided Life Support – An algorithmic approach to undifferentiated shock. Crit Ultrasound J 2001;3:123-129.
- Ferrada P, Murthi S, Anand RJ, Bochicchio GV, Scalea T. Transthoracic Focused Rapid Echocardiographic Examination: Real-Time Evaluation of Fluid Status in Critically Ill Trauma Patients. J Trauma. 2011;70:56-64.

POCUS in Shock

- Systematic POCUS evaluation to determine the cause / type of shock.
 - FoCUS
 - Lung
 - Aorta
 - Abdominal free fluid
 - DVT
 - Soft tissue

POCUS in Shock

Goal:

1. Quickly rule in / rule out specific pathology.
2. Narrow differential diagnosis.
3. Characterize type of shock / hypotension.

Pocus in shock

	Hypovolemic	Vasodilatory	Cardiogenic	Obstructive
Heart	Hyperdynamic LV function		Reduced / Severely Reduced IV fxn RV Dilation (MI)	+/- Dilated RV (PE) +/- Pericardial Effusion (Cardiac Tamponade)
IVC	Small IVC		Dilated IVC	Dilated IVC
Morrison's Pouch	+/- Abdominal free fluid (hemorrhage)	Normal	+/- Abdominal free fluid (ascites)	Normal
Aorta	+/- Aortic aneurysm / dissection	Normal	Normal	Normal
Pulmonary	Normal	+/- Consolidation (pneumonia)	B-Lines	+/- Absent lung sliding (pneumothorax)
Peripheral Veins	Normal	Normal	Normal	+/- DVT

POCUS in Shock

5 Cardinal Views of the Heart

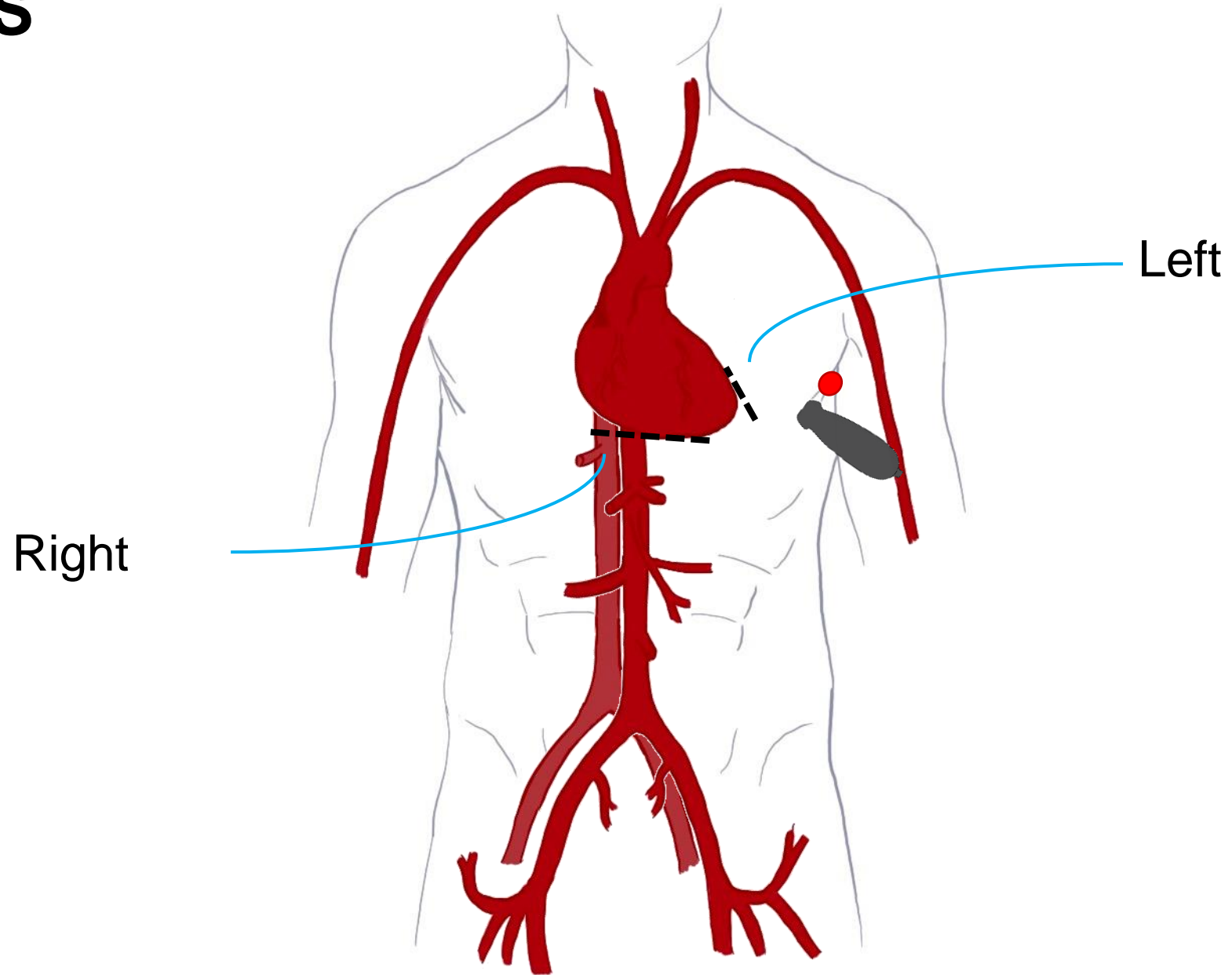
- Parasternal Long Axis (PLAX)
- Parasternal Short Axis (PSAX)
- Apical 4 Chamber (A4C)
- Subcostal 4 Chamber (S4C)
- Inferior Vena Cava (IVC)

POCUS in Shock

5 Cardinal Views of the Heart

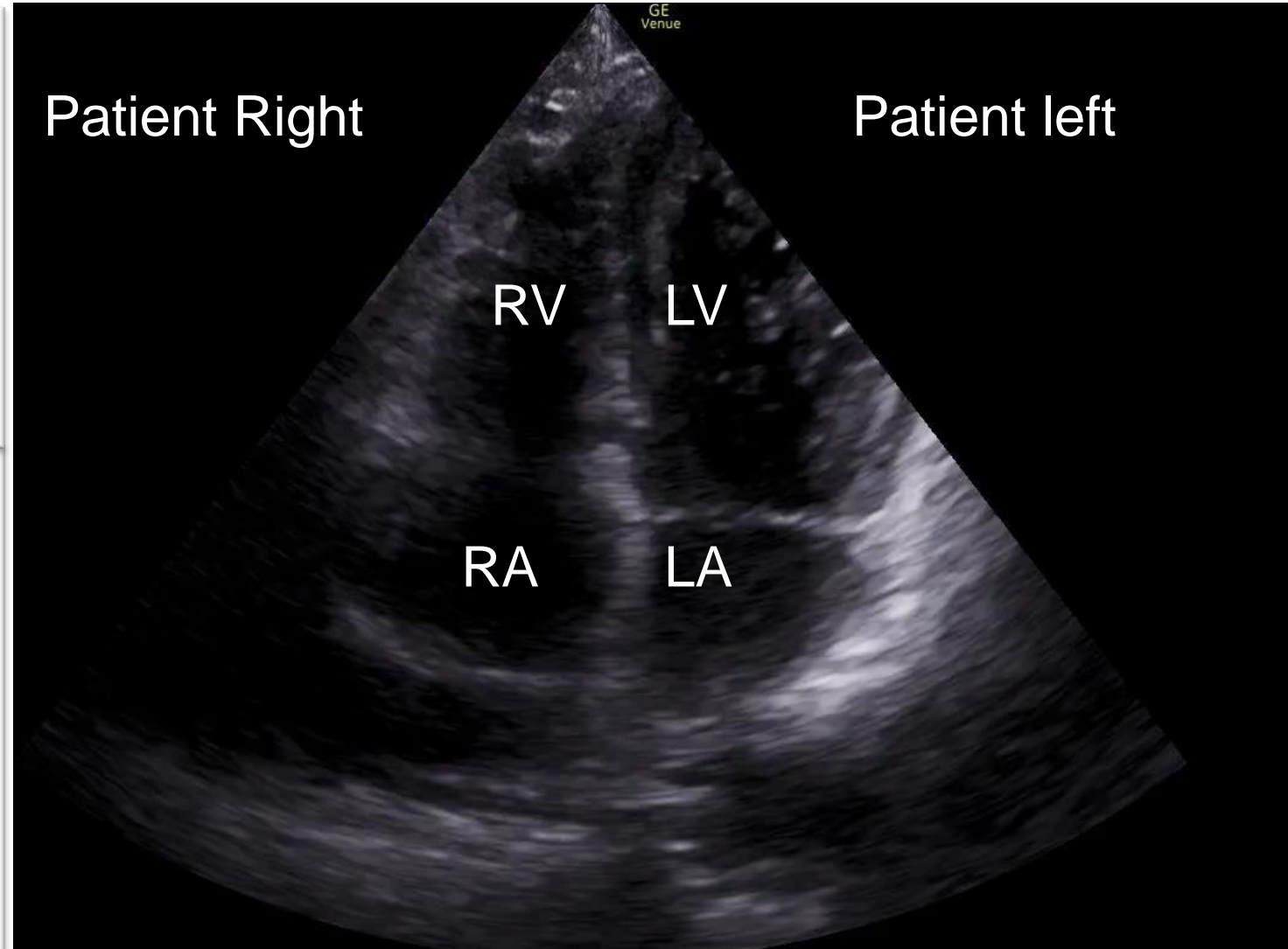
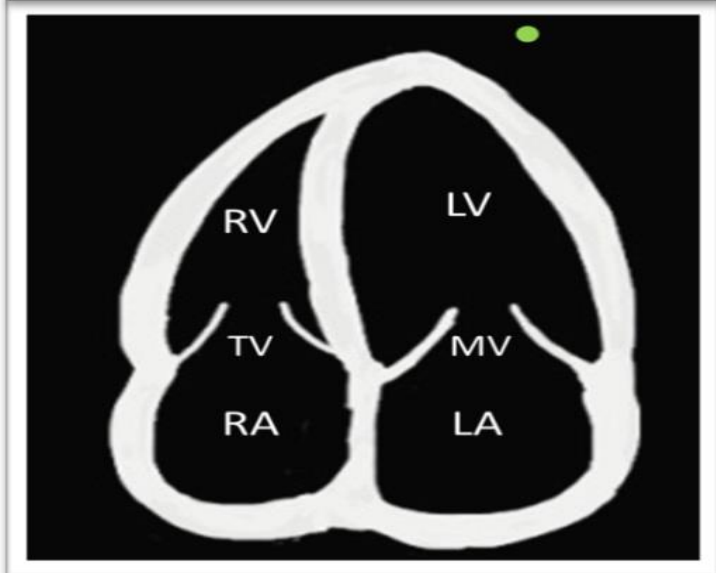
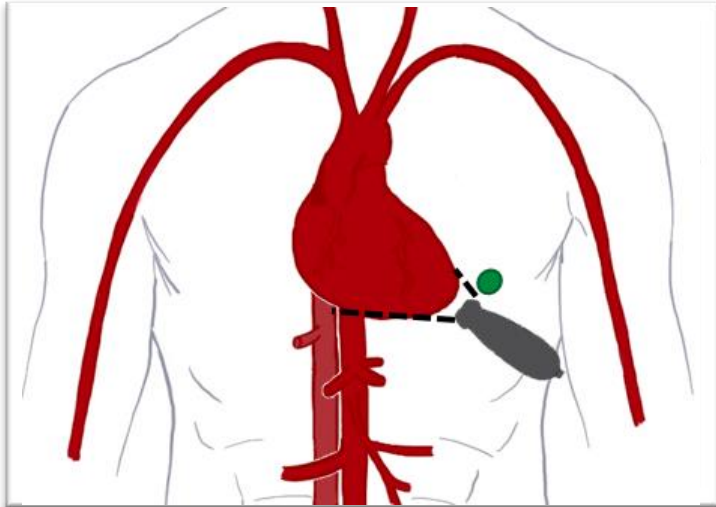
- Parasternal Long Axis (PLAX)
- Parasternal Short Axis (PSAX)
- Apical 4 Chamber (A4C)
- Subcostal 4 Chamber (S4C)
- Inferior Vena Cava (IVC)

FOCUS A4C

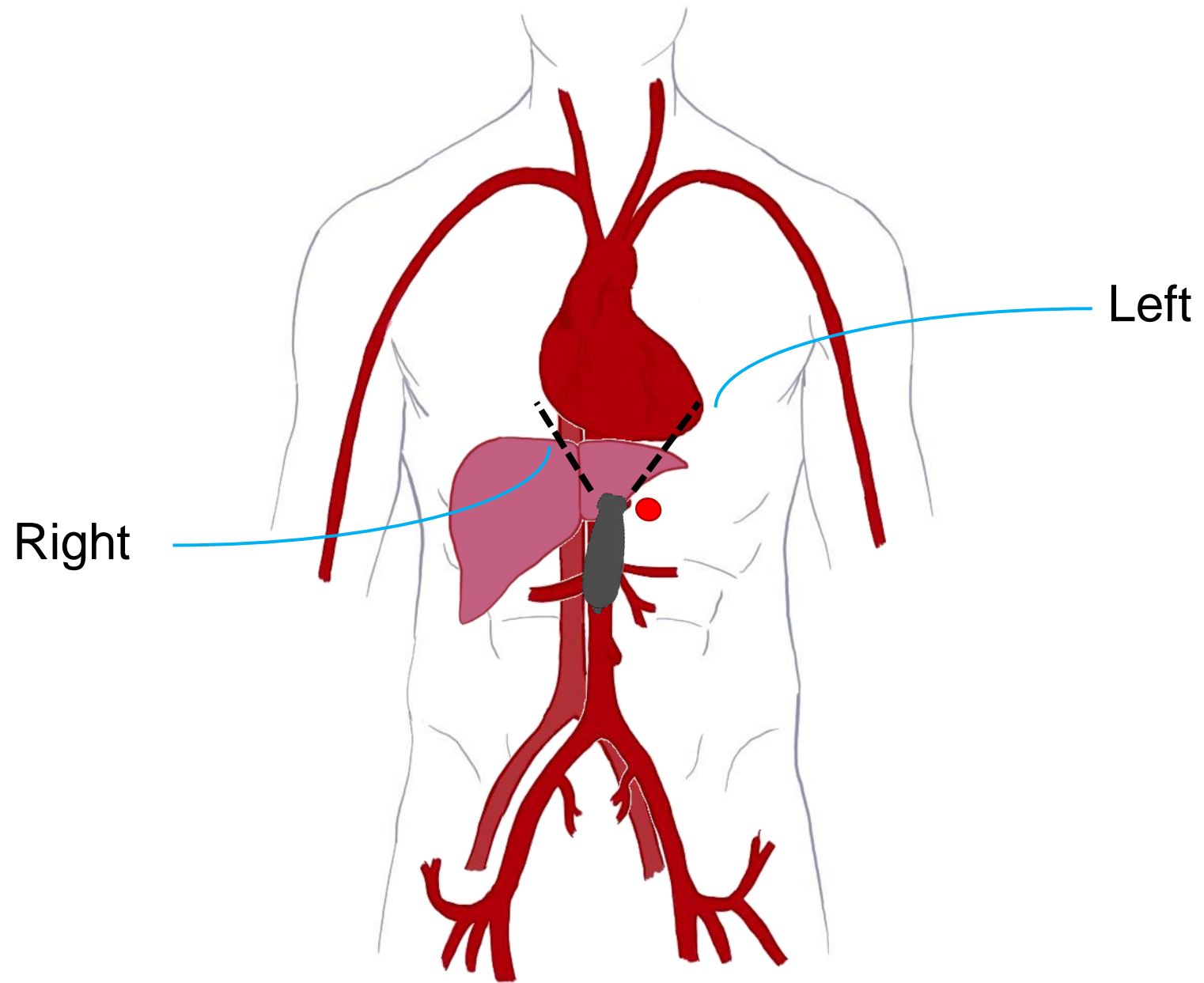


FOCUS

A4C

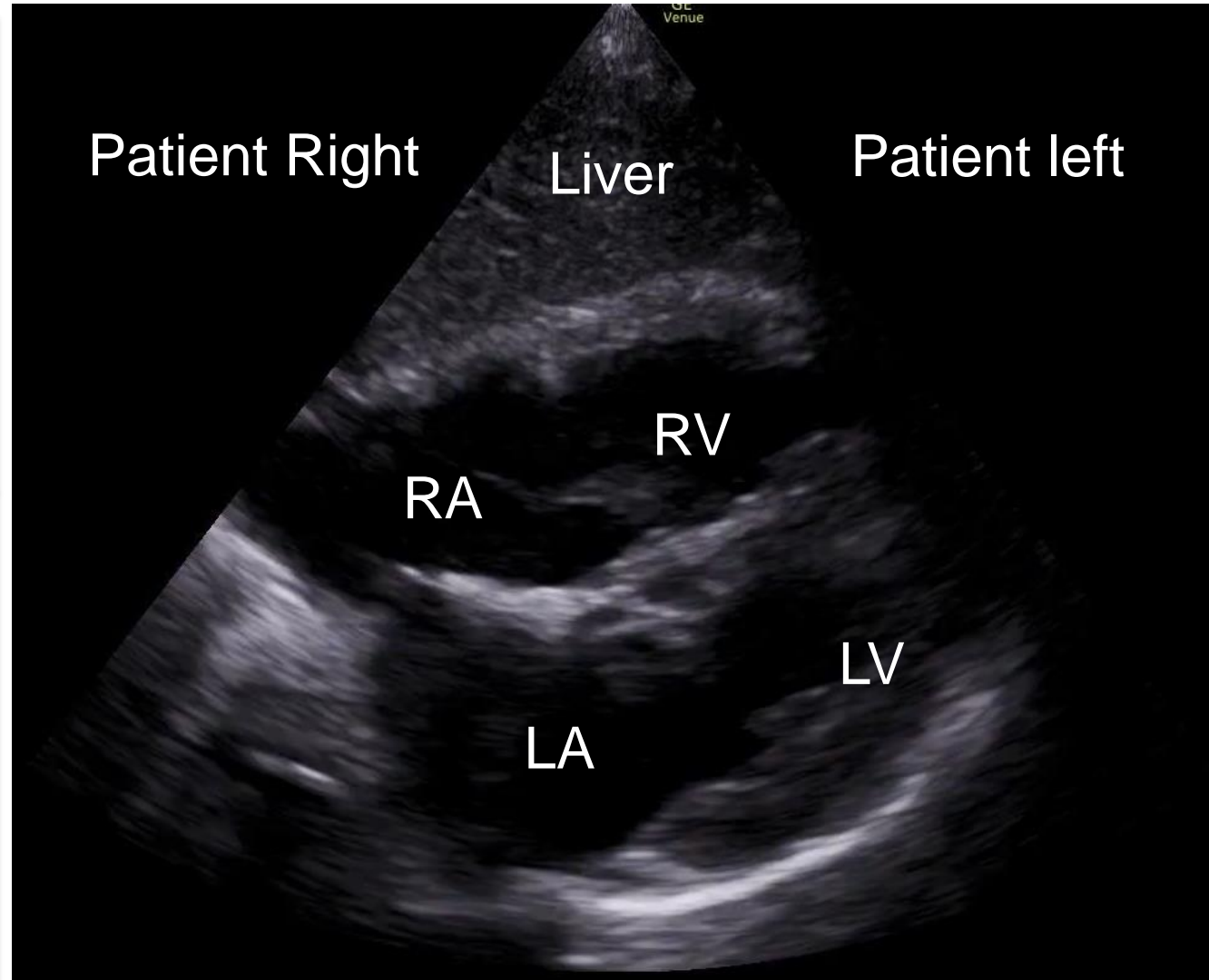
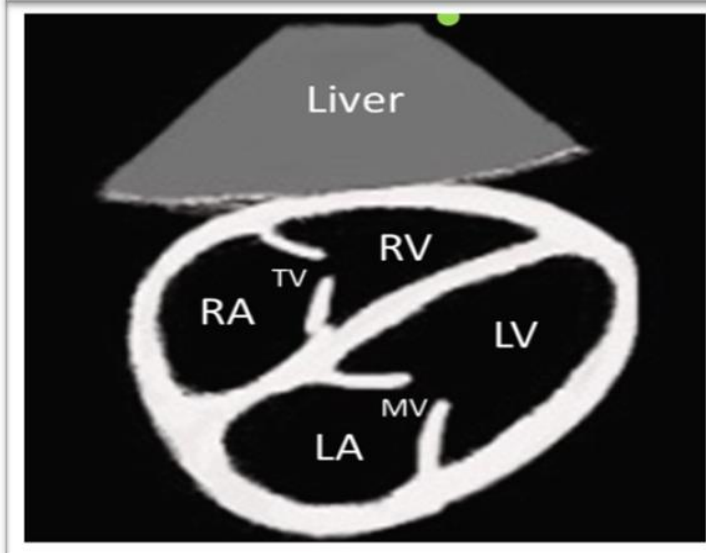
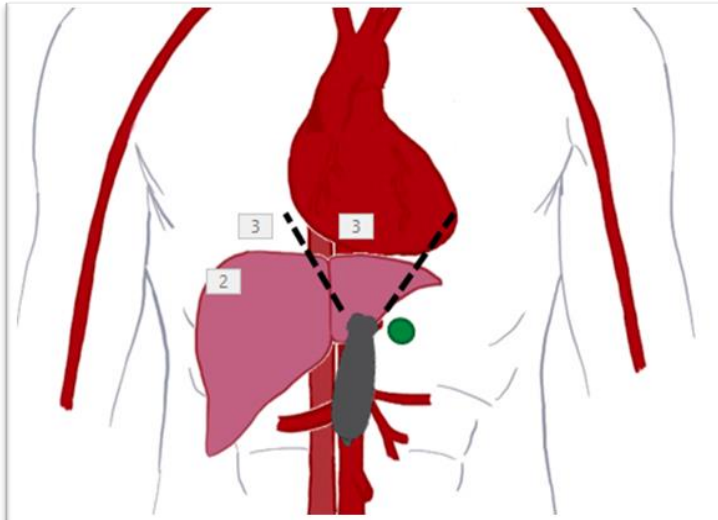


FoCUS S4C



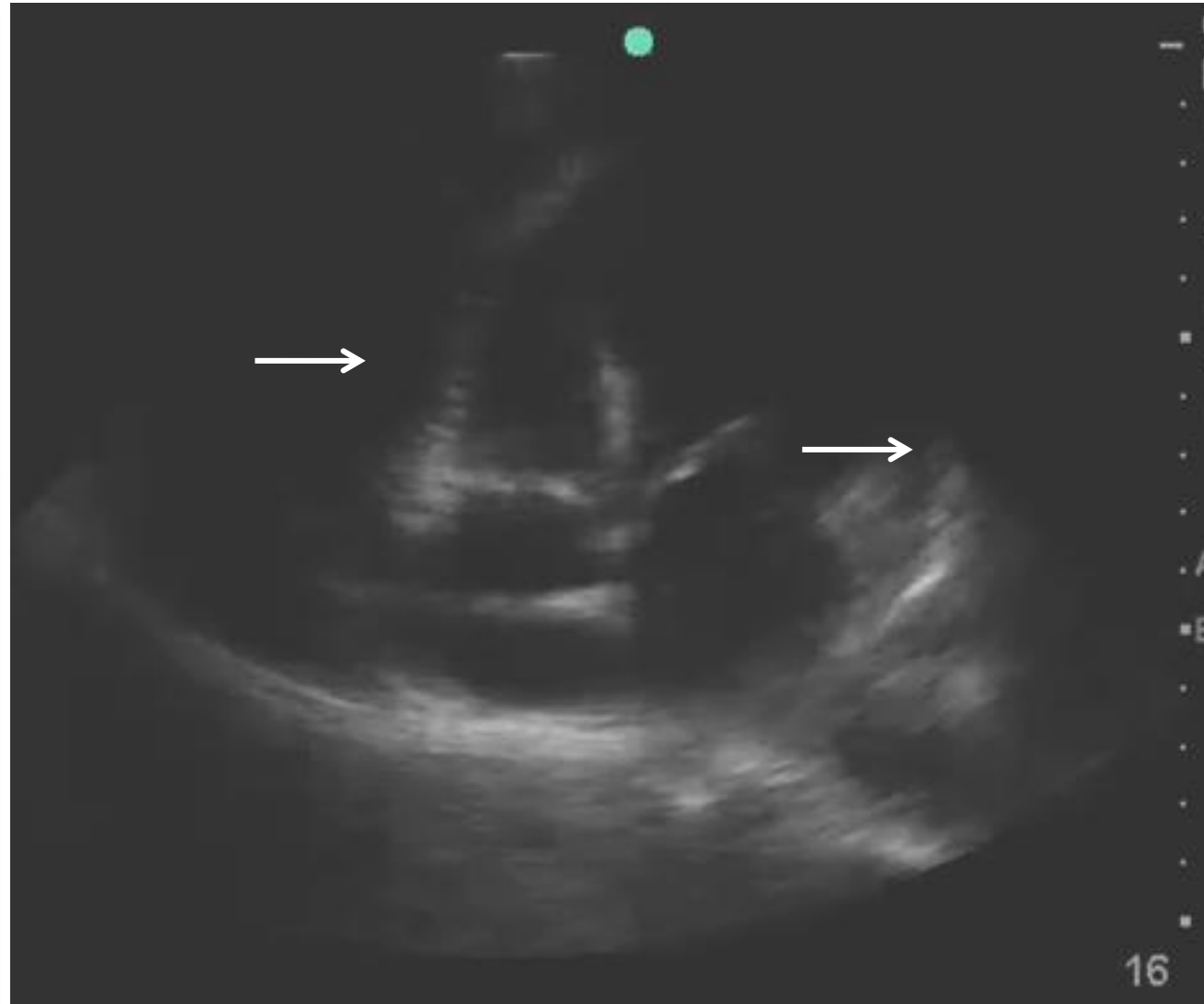
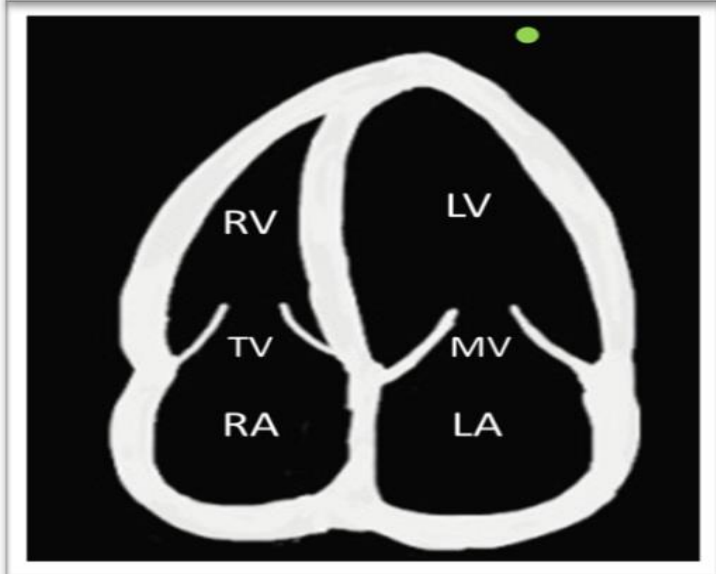
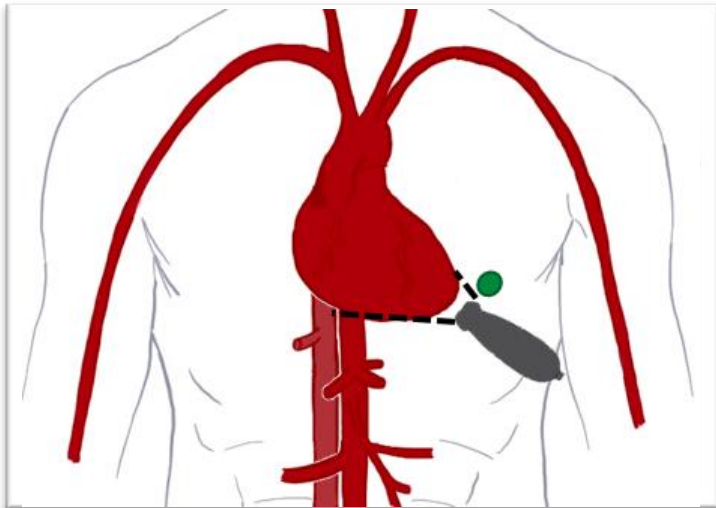
FOCUS

S4C



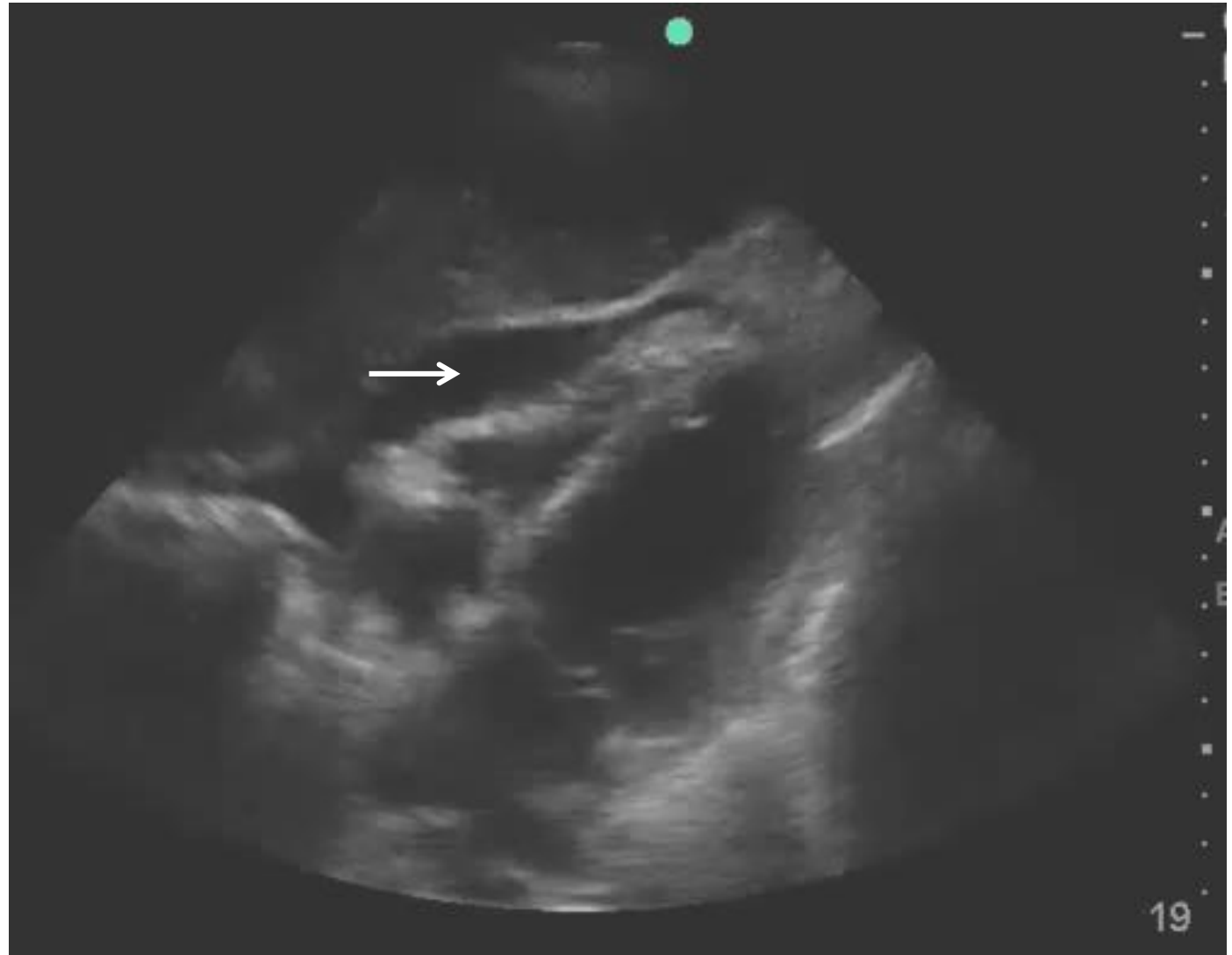
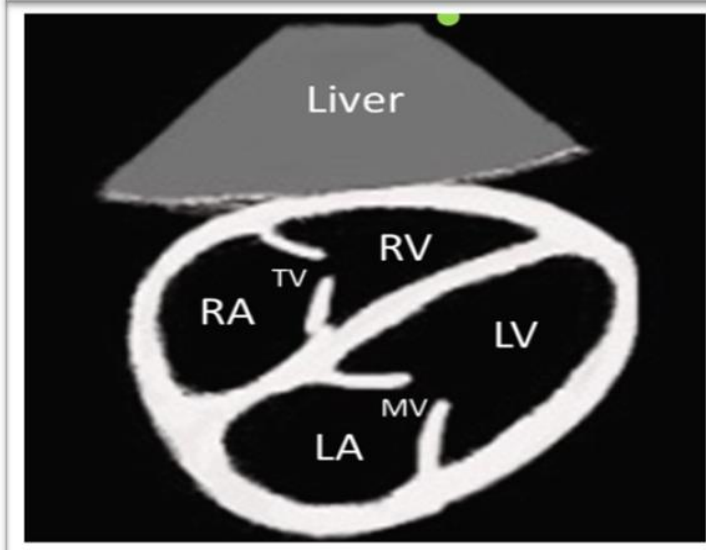
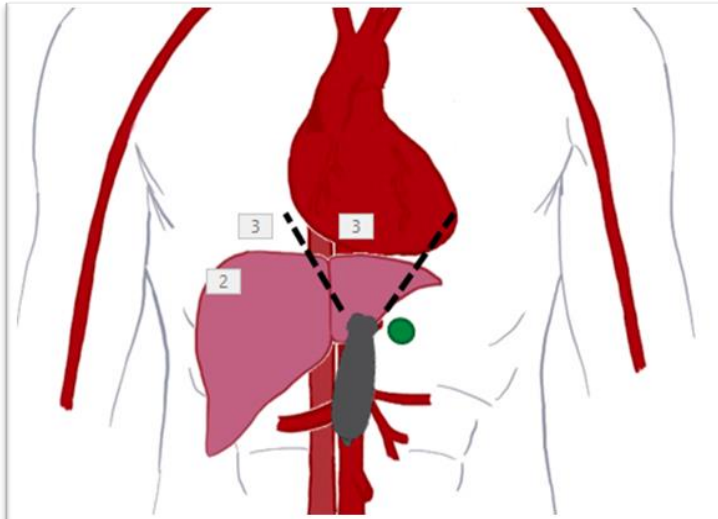
Case 2

A4C



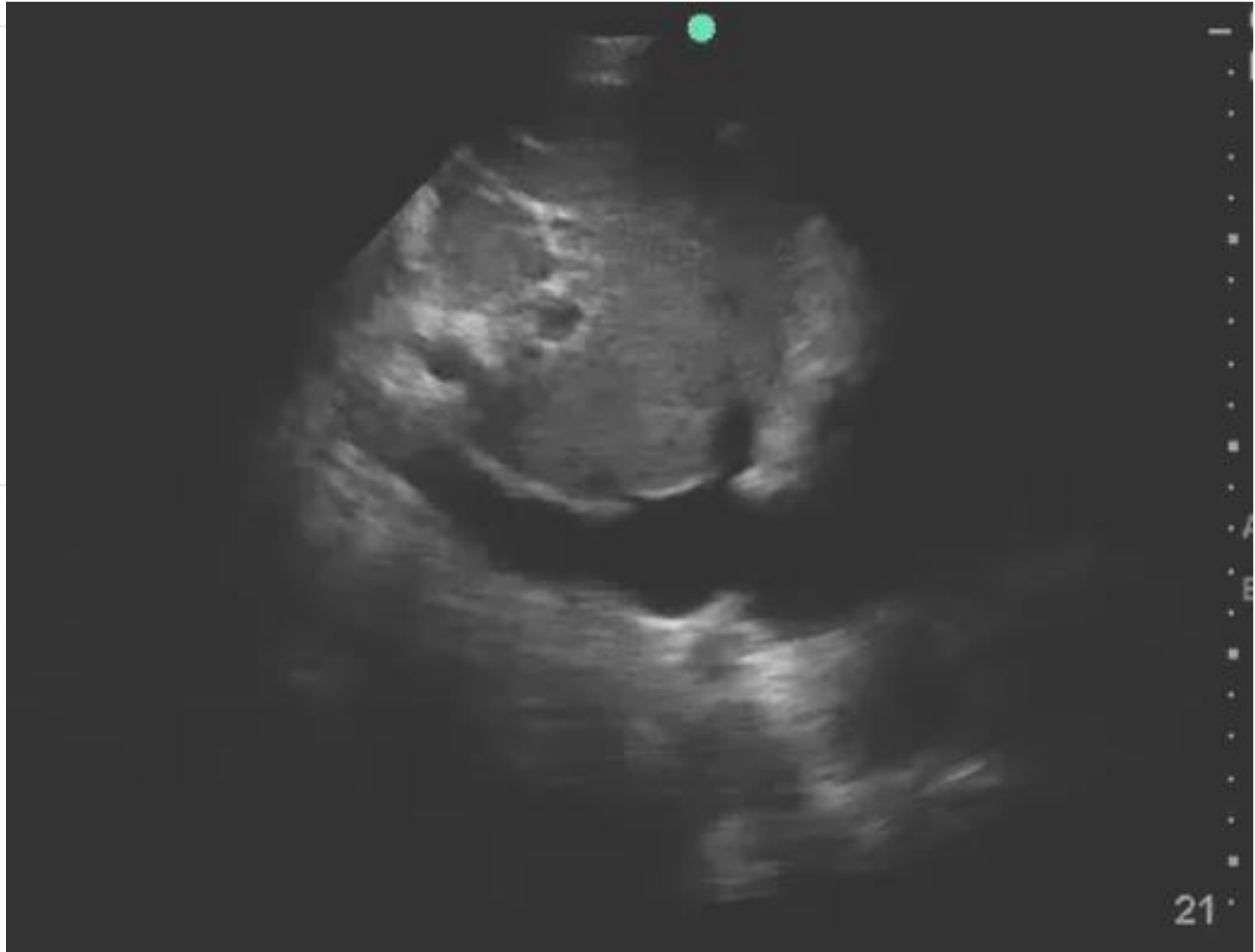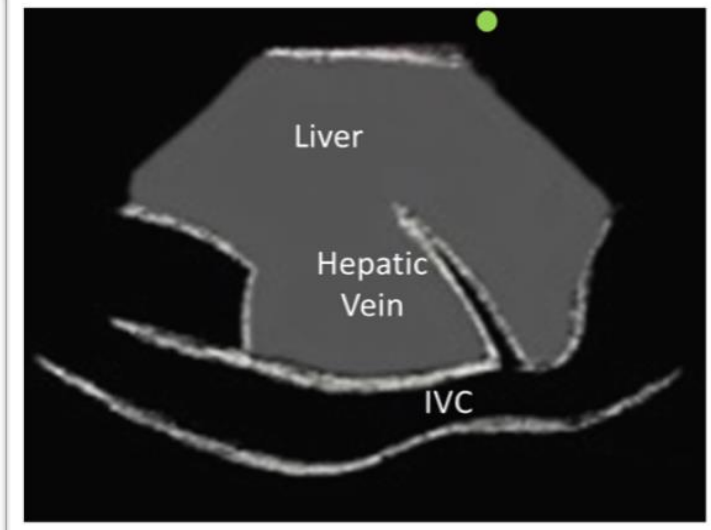
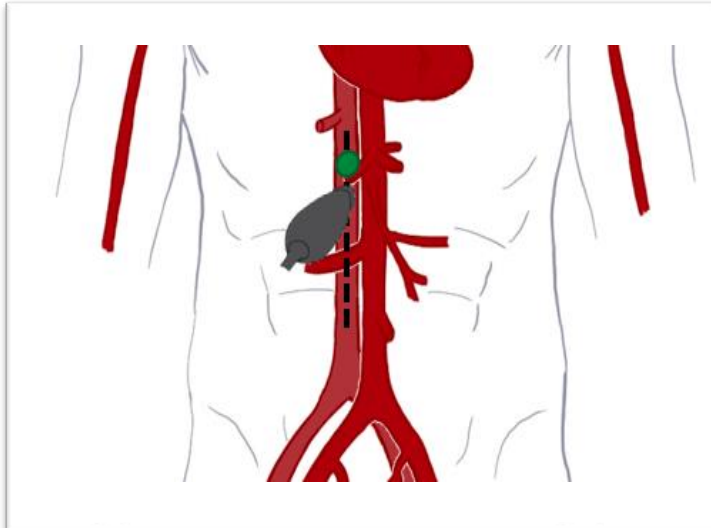
Case 2

S4C

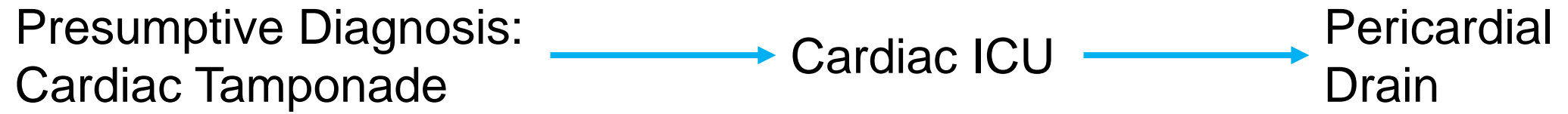


Case 2

IVC



Case 2



POCUS in Shock

Pericardial Effusion

- Sensitivity 96%
- Specificity 98%



Cardiac Tamponade

- RA Systolic Collapse
 - Sensitivity 64-100%
 - Specificity 82%
- RV Diastolic Collapse
 - Sensitivity 60-92%
 - Specificity 85-100%
- IVC with collapse
 - Sensitivity 97%



- Mandavia DP, Hoffner RJ, Mahaney K, Henderson SO. Bedside echocardiography by emergency physicians. *Ann Emerg Med.* 2001;38:377-382.
- Gillam LD, Guyer DE, Gibson TC, et al. Hydrodynamic compression of the right atrium: a new echocardiographic sign of cardiac tamponade. *Circulation.* 1983;68(2):294-301.
- Singh S, Wann LS, Schuchard GH, et al. Right ventricular and right atrial collapse in patients with cardiac tamponade – a combined echocardiographic and hemodynamic study. *Circulation.* 1984;70(6):966-971.

POCUS in Shock



Aids in Diagnosis

- Decreased uncertainty
- Narrower DDX
- More definitive diagnoses

No effect on Patient Centered Outcomes

- Mortality
- ICU / Hospital LOS



So far...

- Shokoohi H, Boniface KS, Pouramand A, Liu YT, et al. Bedside Ultrasound Reduces Diagnostic Uncertainty and Guides Resuscitation in Patients With Undifferentiated Hypotension. *Critical Care Medicine Journal* 2015;43(12):2562-2569.
- Jones AE, Tayal VS, Sullivan DM, et al: Randomized, controlled trial of immediate versus delayed goal-directed ultrasound to identify the cause of nontraumatic hypotension in emergency department patients. *Crit Care Med* 2004; 32:1703–1708
- Atkinson PR, Milne J, Diegelman L, Lamprecht H, Stander M, Lussier D, et al. Does Point-of-Care Ultrasonography Improve Clinical Outcomes in Emergency Department Patients With Undifferentiated Hypotension? An International Randomized Controlled Trial From the SHoC-ED. *Annals of Emergency Medicine* 2018.

POCUS in Shock

- The diagnostic accuracy of a point-of-care ultrasound protocol for shock etiology: A systematic review and meta-analysis (2019)
 - Hypovolemic shock: LR+ 8.25, LR- 0.19
 - Cardiogenic shock: LR+ 24.14, LR- 0.24
 - Obstructive shock: LR+ 40.54, LR-0.13
 - Distributive shock: LR+ 17.56, LR- 0.30
 - Mixed shock: LR+ 12.91, LR- 0.32

- Stickles SP, Carpenter CR, Gekle R, Kraus CK, Scoville C, Theodoro D, Tran VH, Ubiñas G, Raio C. The diagnostic accuracy of a point-of-care ultrasound protocol for shock etiology: A systematic review and meta-analysis. CJEM. 2019 May;21(3):406-417. doi: 10.1017/cem.2018.498. Epub 2019 Jan 30. PMID: 30686496

POCUS in Shock


Does Point-of-Care Ultrasonography Improve Clinical Outcomes in Emergency Department Patients With Undifferentiated Hypotension? An International Randomized Controlled Trial From the SHoC-ED Investigators

- Primary Outcomes:
 - 30 day mortality or discharge survival
- Results:
 - No difference between standard of care vs standard of care + POCUS

POCUS in Shock


Does Point-of-Care Ultrasonography Improve Clinical Outcomes in Emergency Department Patients With Undifferentiated Hypotension? An International Randomized Controlled Trial From the SHoC-ED Investigators

	POCUS (138)	Control (135)
Sepsis	74 (53.6%)	68 (50.4%)
Dehydration	17 (12.3%)	20 (14.8%)
LV failure	10 (7.2%)	12 (8.9%)
Other (medications, hemorrhage, autonomic dysfunction, arrhythmia, etc)	34 (24%)	34 (25%)
Aortic Dissection	2 (1.4%)	0
Tension Pneumothorax	1 (0.7%)	0 (0%)
Cardiac Tamponade	1 (0.7%)	1 (0.7%)



Case 3

Case 3



- A 62 year-old female was admitted to your service overnight from the ED for complaints of fevers and rigors over the last 2 days.
- She endorses:
 - Dysuria
 - Urinary frequency
 - Urinary urgency
- Past Medical / Surgical History:
 - Pseudomonas aeruginosa UTI (~3 months prior).
 - Hypertension
 - Left ventricular diastolic heart failure

Case 3

16.7 15.2 389

141 101 52 98
4.2 20 2.6

Lactate 3.7

- U/A –
 - Many gram negative bacilli
 - RBC normal
 - WBC > 100 / hpf

Case 3

Presumptive Diagnosis:
Sepsis due to UTI



LR 30 ml/kg
Cefepime



Admitted
Continued
Cefepime
Gentle IVF

Case 3

- HR 112
- BP 98/55
- RR 24
- SpO2 91%
- Tmax 39.0 C

14.1 15.2 389

141 101 52 98
4.2 20 2.2

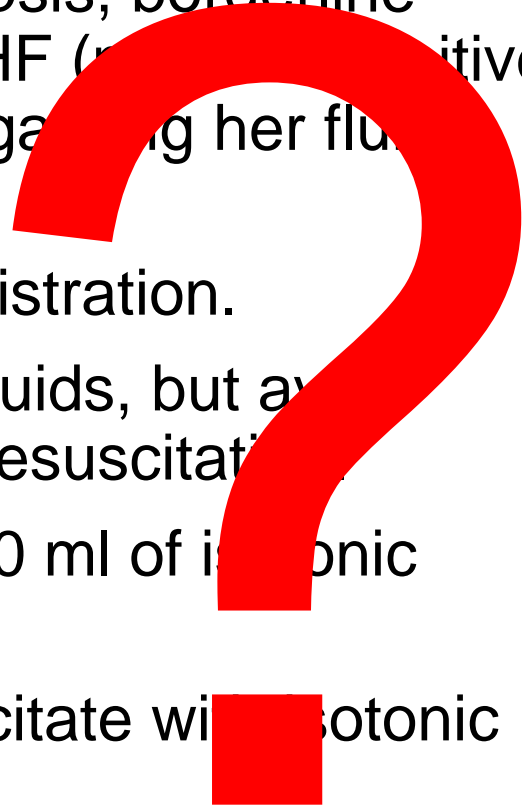
Lactate 2.4

I/O's +2.6L

Case 3

In the setting of ongoing sepsis, borderline hypotension, and known CHF (previously positive 2.5L) what would you do regarding her fluid administration?

- A. Avoid further fluid administration.
- B. Continue maintenance fluids, but avoid further aggressive fluid resuscitation.
- C. Give a small bolus of 500 ml of isotonic saline.
- D. Aggressively fluid resuscitate with isotonic saline (i.e. 2 L).



POCUS-Guided Fluid Resuscitation

- DO NOT IGNORE THE GUIDELINES

POCUS-Guided Fluid Resuscitation

- Fluid Responsiveness – An increase of stroke volume of 10-15% after the patient receives 500 ml of crystalloid over 10-15 minutes
 - IVC size / Respiratory variation

- Accuracy of Ultrasonographic Measurements of Inferior Vena Cava to Determine Fluid Responsiveness: A Systematic Review and Meta-Analysis (2020)
 - Pooled sensitivity 71%, specificity 75%; LR +2.8 LR -0.39.



POCUS-Guided Fluid Resuscitation

- Intravascular Volume Status
- Fluid Tolerance – The ability to receive IV fluids without developing adverse affects; such as, pulmonary edema/hypoxia.
 - Expert opinion

Cardiac Auscultation

JVP

Lung Auscultation



FoCUS

IVC

Lung Ultrasound



POCUS-Guided Fluid Resuscitation

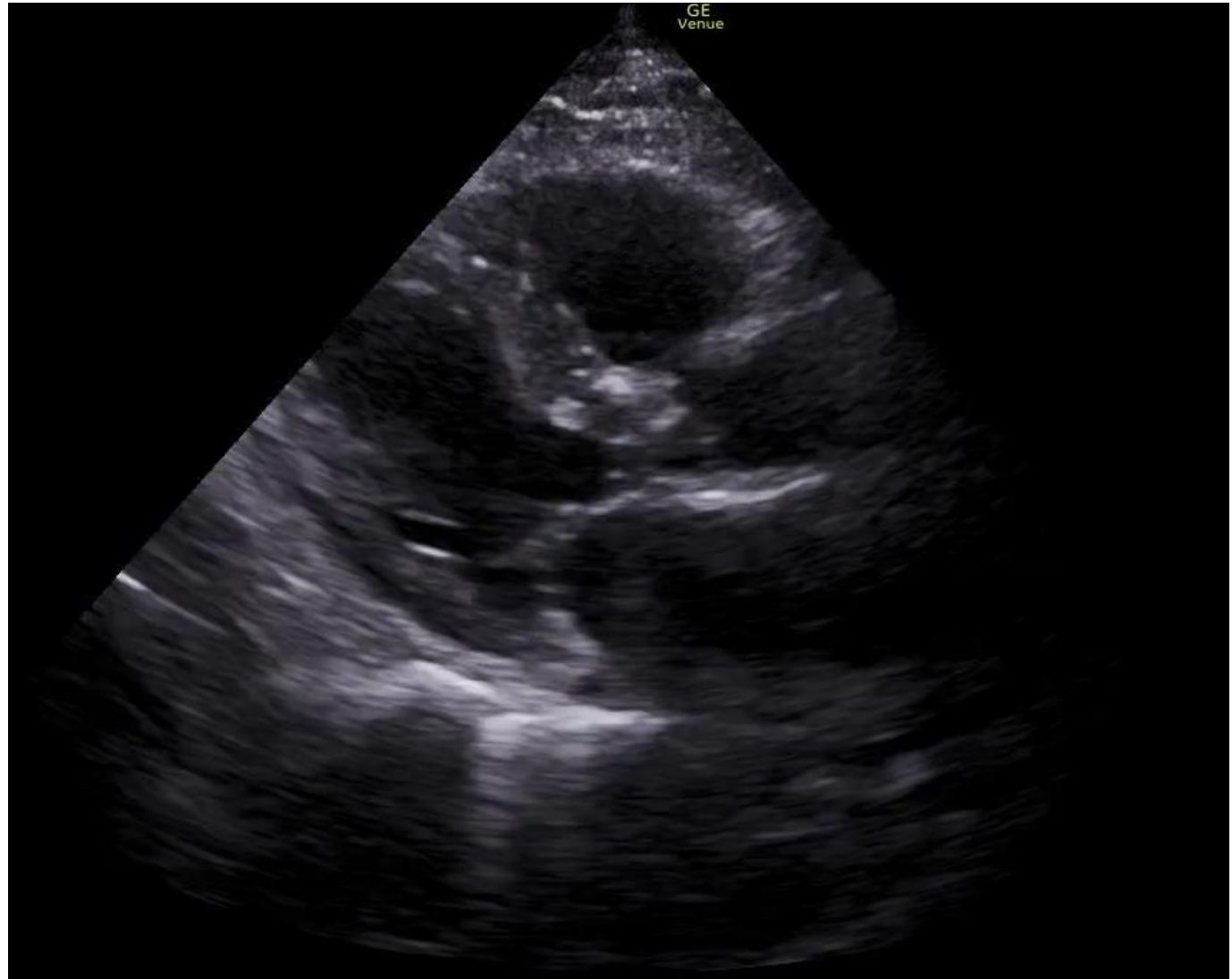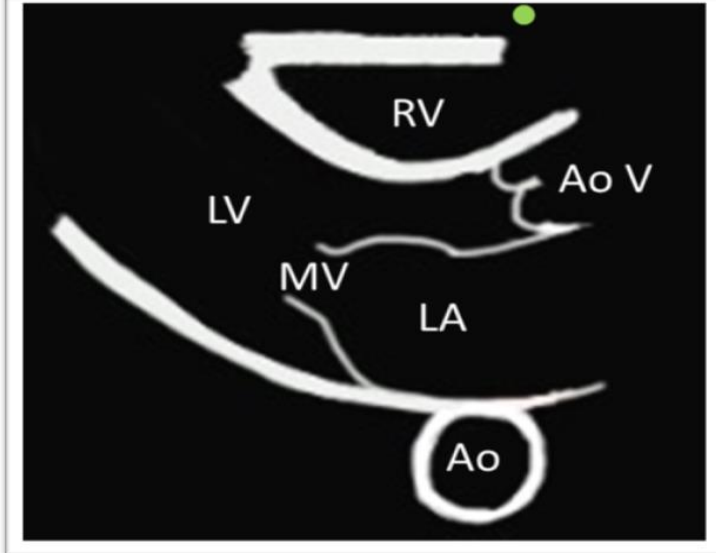
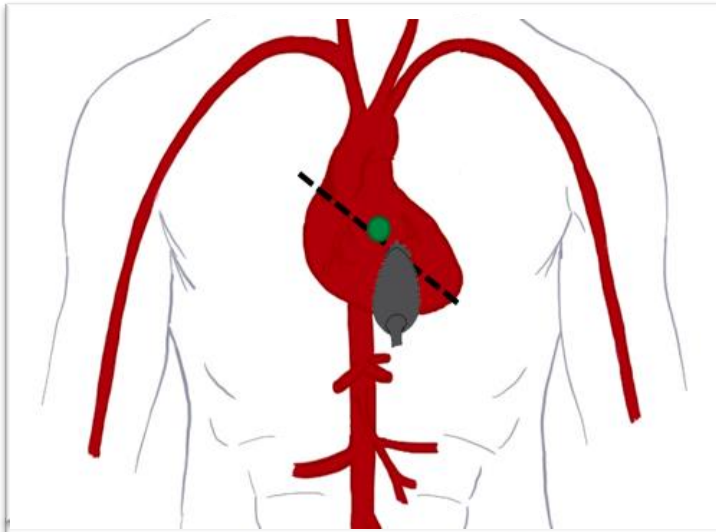


	Fluid Tolerance	Fluid Intolerance
Heart	Hyperdynamic LV Function Small RV / Normal RV Function	Reduced LV Function Dilated RV / reduced RV Function
IVC	Small Collapsing	Large Reduced collapse
Lung	A-Lines	B-Lines

- Theerawit P, Tomuan N, Sutherasan Y, Kiatboonsri S. Critical Care 2012,16(Suppl 1): P248. doi: 10.1186/cc10855.
- Lichtenstein D, Karakitsos D. Integrating lung ultrasound in the hemodynamic evaluation of acute circulatory failure (the fluid administration limited by lung sonography protocol). Journal of Critical Care (2012)27, 533.e11–533.e19.

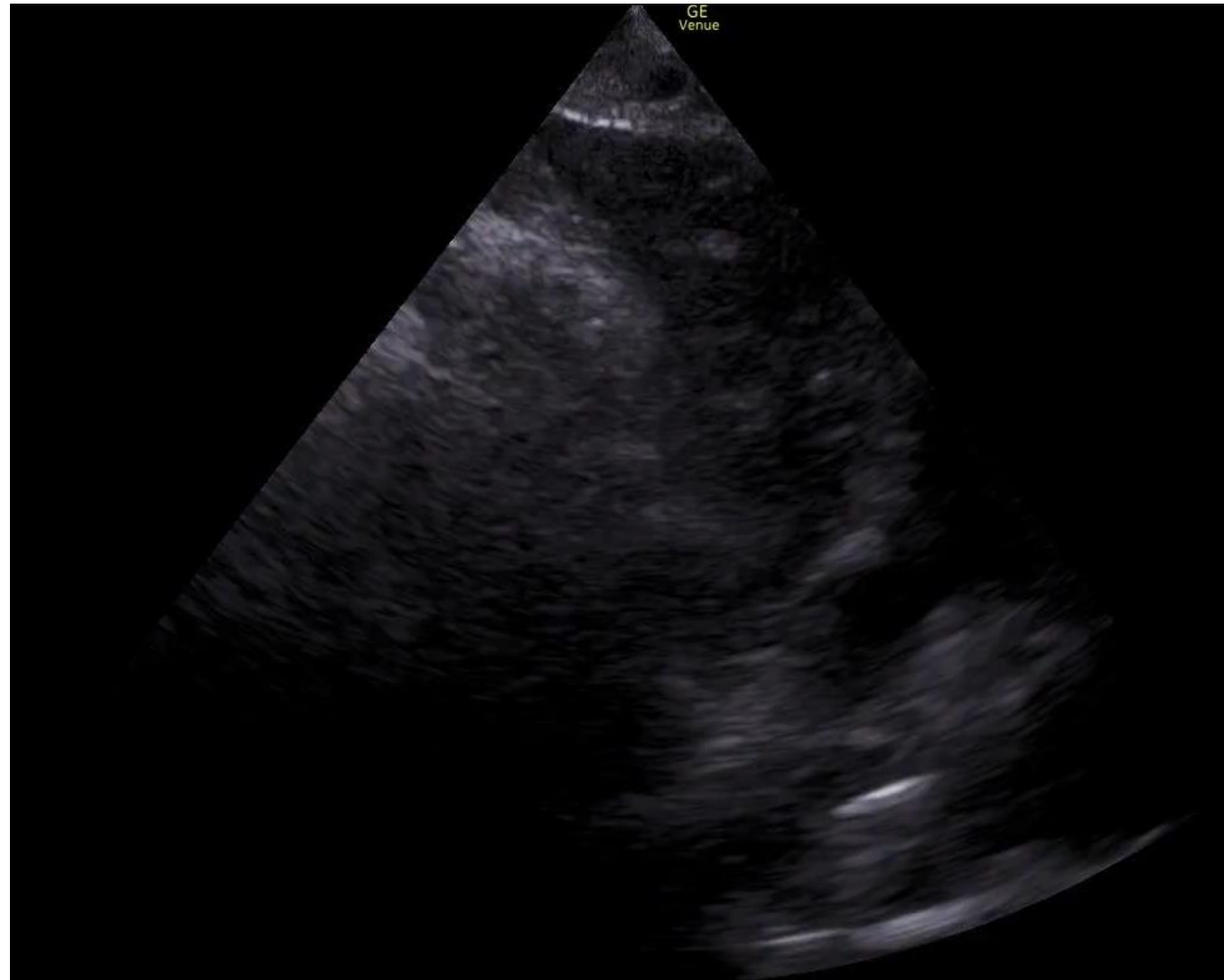
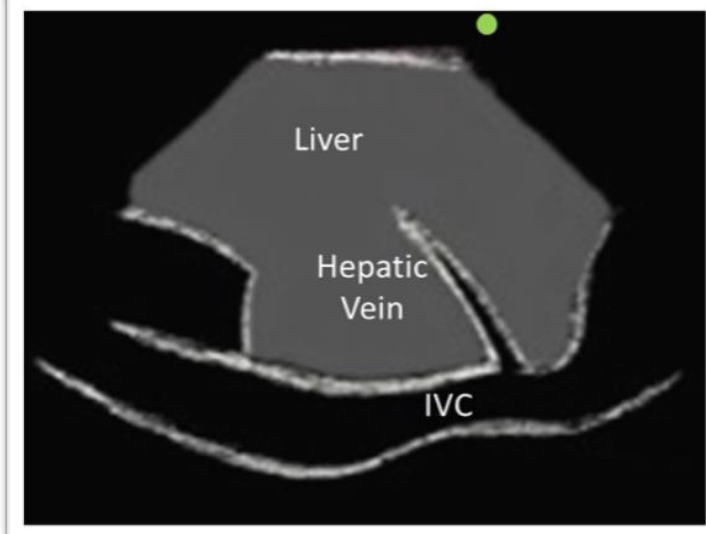
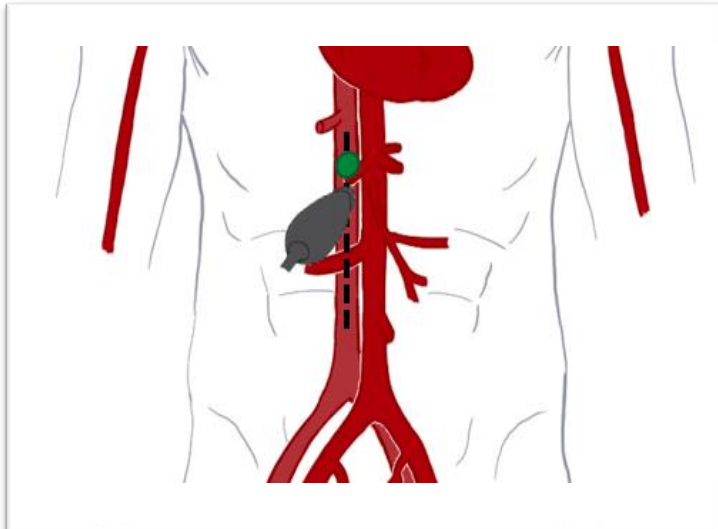
Case 3

PLAX




Case 3

IVC



POCUS-Guided Fluid Resuscitation



	Fluid Tolerance	Fluid Intolerance
Heart	Hyperdynamic LV Function Small RV / Normal RV Function	Reduced LV Function Dilated RV / reduced RV Function
IVC	Small Collapsing	Large Reduced collapse
Lung	A-Lines	B-Lines

- Theerawit P, Tomuan N, Sutherasan Y, Kiatboonsri S. Critical Care 2012,16(Suppl 1): P248. doi: 10.1186/cc10855.
- Lichtenstein D, Karakitsos D. Integrating lung ultrasound in the hemodynamic evaluation of acute circulatory failure (the fluid administration limited by lung sonography protocol). Journal of Critical Care (2012)27, 533.e11–533.e19.

POCUS IN SEPSIS

- Accuracy of point of care ultrasound to identify the source of infection in septic patients: a prospective study

Standard of Care (History / Physical / Basic labs)

vs

Standard of Care + Targeted POCUS (Kidneys, soft tissues, lungs, gallbladder, etc.)

POCUS IN SEPSIS



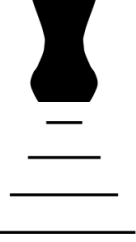- Accuracy of point of care ultrasound to identify the source of infection in septic patients: a prospective study

	Standard of Care	Standard of Care + POCUS
Sensitivity	48%	73%
Specificity	86%	95%
LR+	3.54	16.1
LR-	0.59	0.28
Diagnostic Accuracy	53%	75%

POCUS IN SEPSIS

- Accuracy of point of care ultrasound to identify the source of infection in septic patients: a prospective study
 - Antibiotic Regimen altered in 24% of cases
 - Diagnosis made substantially quicker

POCUS of the kidneys

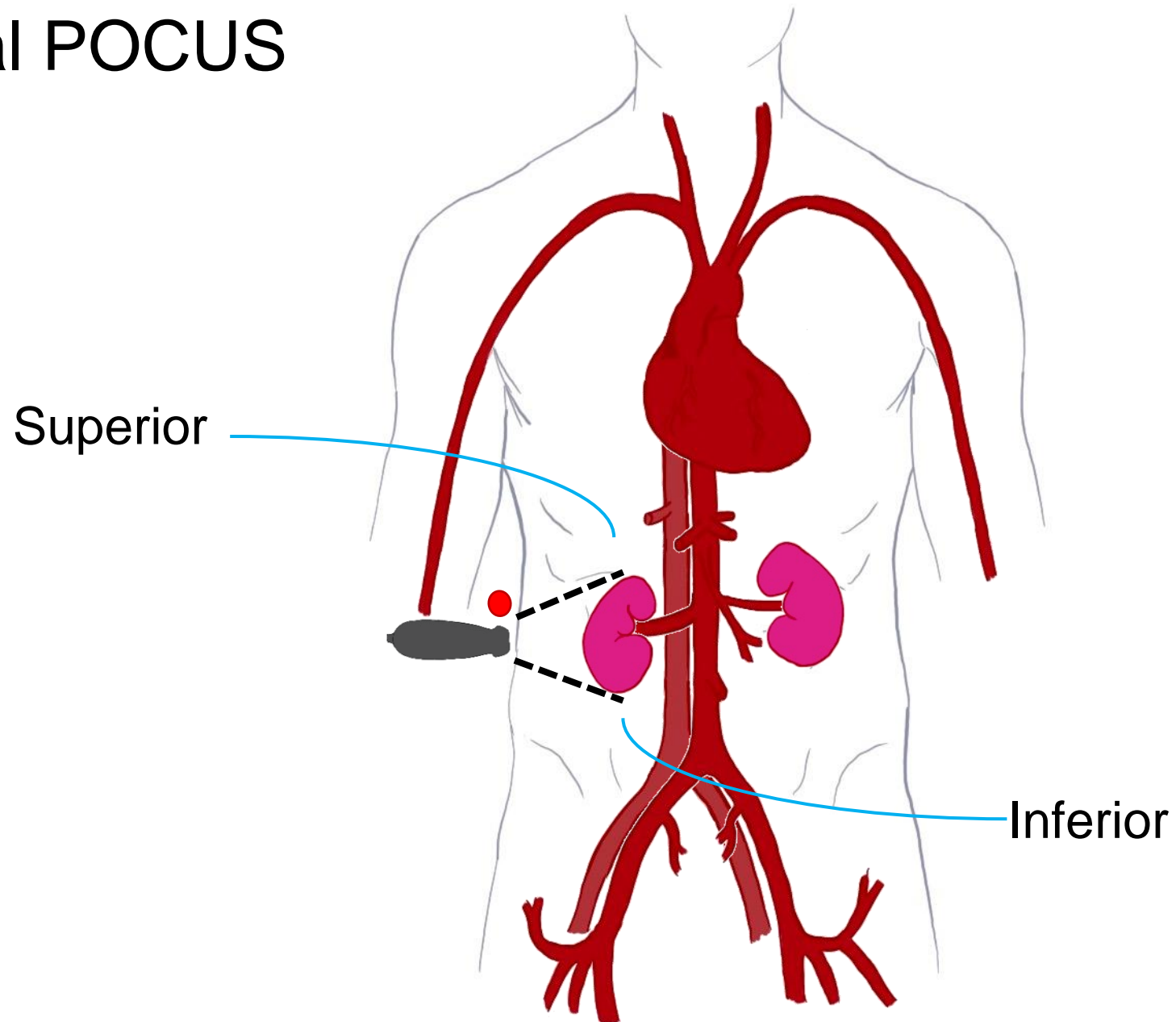


- Scope:
 - Nephrolithiasis
 - Hydronephrosis
- Indications:
 - AKI
 - UTI with Sepsis
 - Renal colic

	Sensitivity	Specificity
Nephrolithiasis	19 – 62%	90 – 98%
Hydronephrosis	72 – 97%	73 – 93%

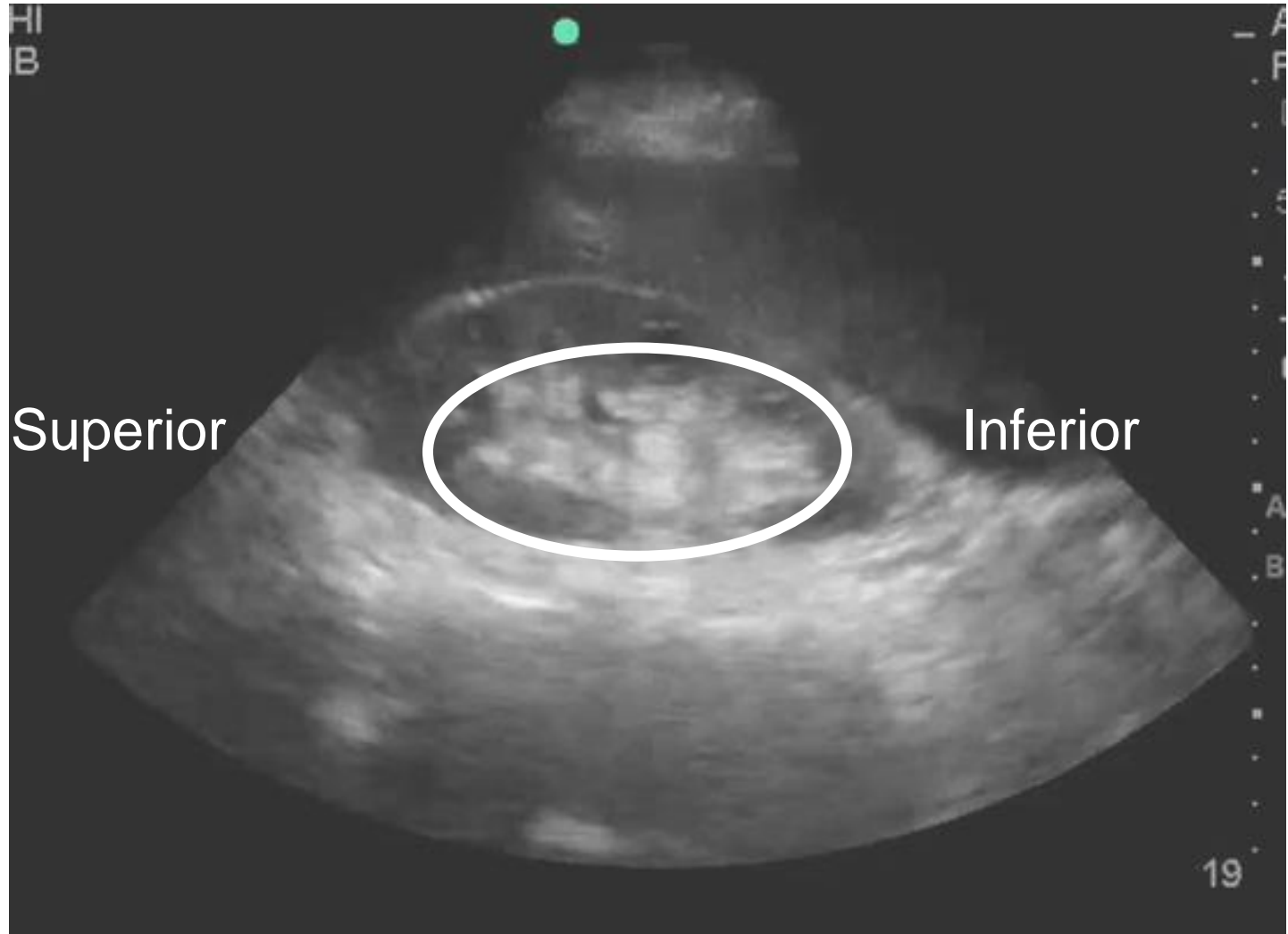
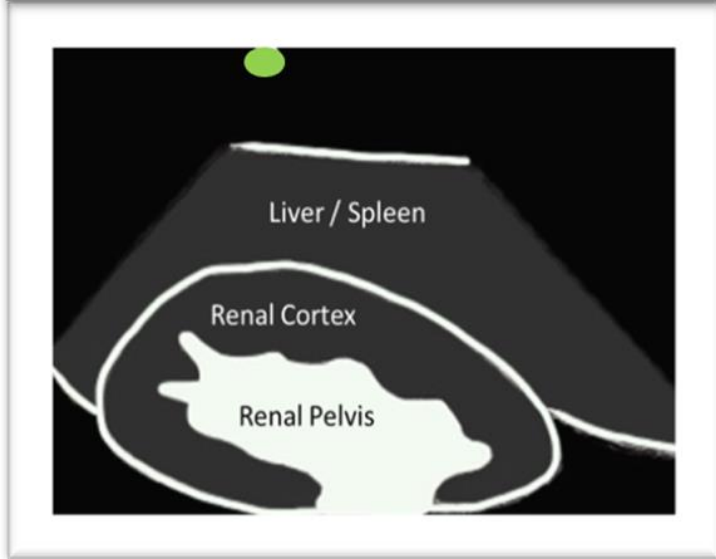
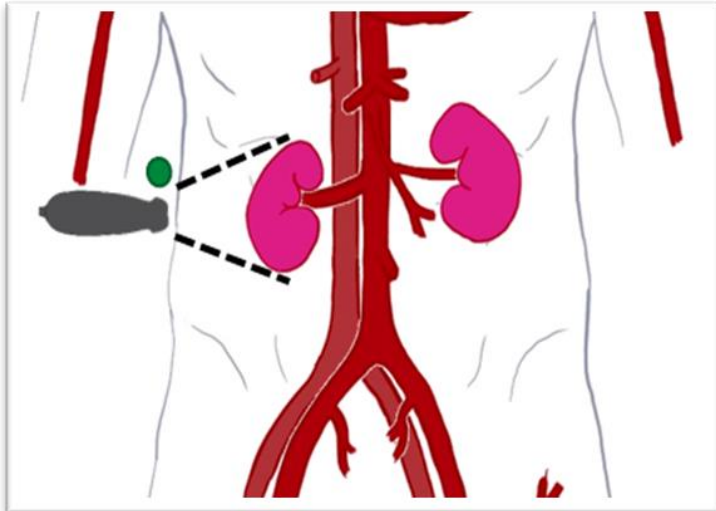
- Yilmaz S, Sindel T, Arslan G, Ozkaynak C, Karaali K, et al. Renal colic: Comparison of spiral CT, US, and IVU in detection of ureteral calculi. *Eur Radiol.* 1998;8:212-217.
- Sheafor DH, Hertzber BS, Freed KS, Carroll BA, Keogan MT, Paulson EK, DeLong DM, Nelson RC. Nonenhanced Helical CT and US in the Emergency Evaluation of Patients with Renal Colic: Prospective Comparison. *Radiology.* 2000;217:792–797.
- Fowler KA, Locken JA, Duchesne JH, Williamson MR. US for Detecting Renal Calculi with Nonenhanced CT as a Reference Standard. *Radiology.* 2002; 222:109–113.
- Kanno T, Kubota M, Sakamoto H, Nishiyama R, Okada T, Higashi Y, Yamada H. Determining the Efficacy of Ultrasonography for the Detection of Ureteral Stone. *Urology.* 2014;84:533-537.

Renal POCUS



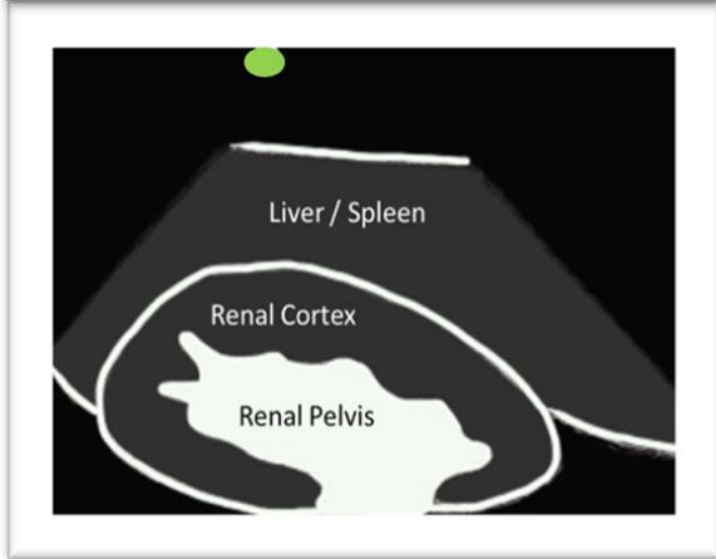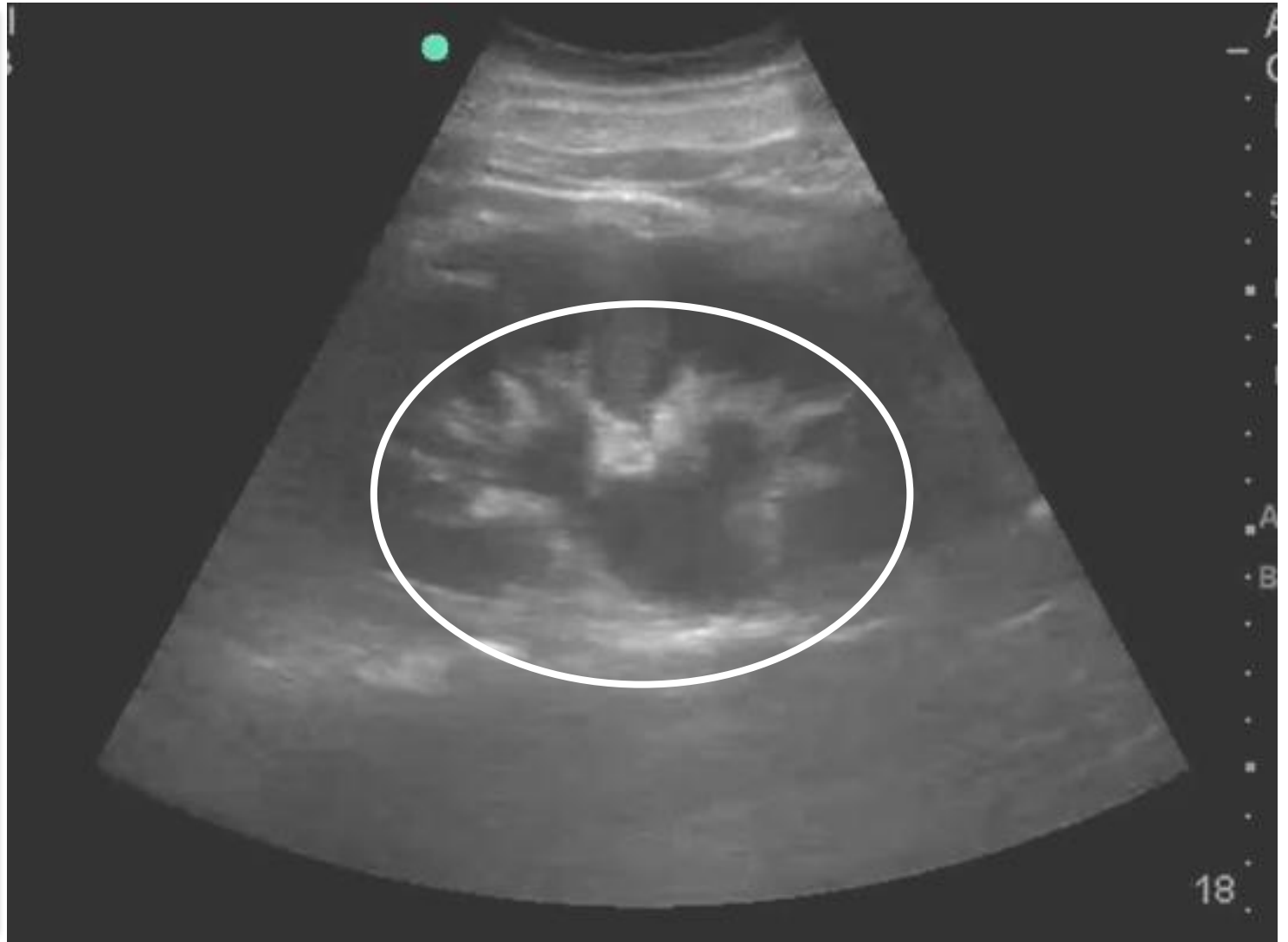
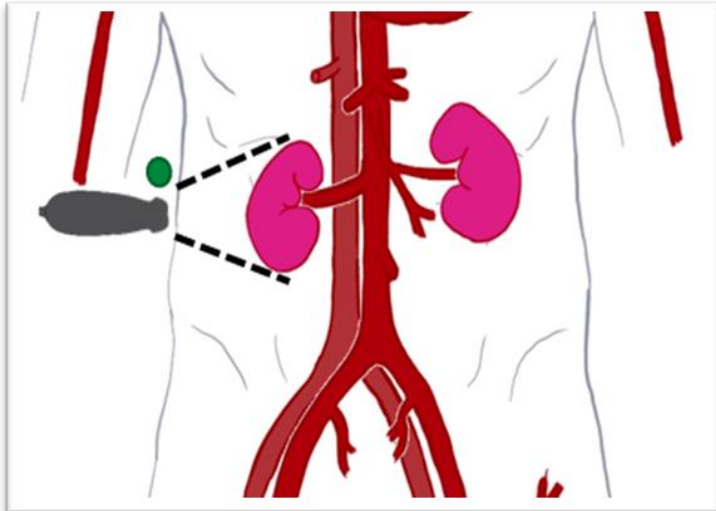
Renal POCUS

Longitudinal



Case 3

Longitudinal



Case 3

Hypovolemic / Fluid
Tolerant



Obstructive
Uropathy



IVF
Emergent CT
Nephrostomy Tube

Summary



POCUS USES				
FOCUS	Lung	Shock	Volume Status	Renal

Summary



POCUS USES				
FOCUS	Lung	Shock	Volume Status	Renal
Aorta	Bladder	Trauma	Abdominal free fluid	Soft tissues
Musculoskeletal	OB	Ocular	Gallbladder	Appendicitis
Small bowel obstruction	AKI	Testicular	Sepsis	Foreign body
Cardiac arrest	Trauma	Procedural Guidance	Vascular access	Nerve blocks

Questions and Discussion

Breunig.Michael@mayo.edu

