



# Transgender Health: How to Provide Culturally Competent Care to Patients Undergoing Gender Affirming Surgery

Lauren Eisenbeis-Thome, DMSc, MS, PA-C

AAPA Houston 2024

# Introduction

- PA in Plastic Surgery for 6 years
  - First three years spent at The Johns Hopkins Center for Transgender Health in Baltimore, MD
  - Current lead APP for Luminis Health Plastic Surgery Group in Annapolis, MD
- Published multiple articles related to transgender care
- Three-time textbook chapter author specific to transgender surgical care

No disclosures

# Goals

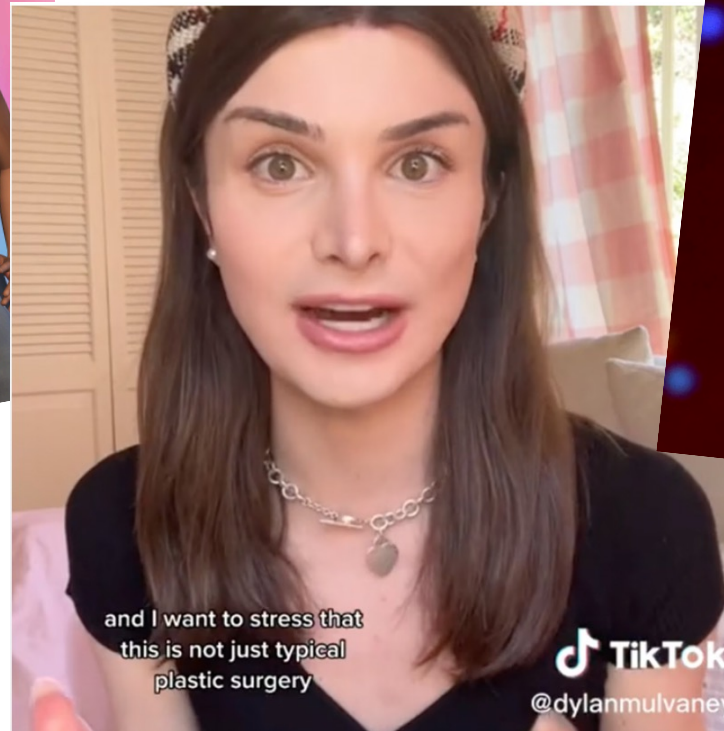- At the conclusion of this session, participants should be able to:
  - Provide culturally competent and diverse care
  - Recognize surgical procedures specific to the transgender population
  - Identify the necessary tests and preventative care patients need during, or after, surgical transition

# DISCLAIMER

**AAPA Vision: “PAs transforming health through patient-centered, team-based medical practice”**


The image features a large blue speech bubble with a white outline, centered on a white background. The speech bubble has a tail pointing downwards. Inside the bubble, the text "General Overview" is written in a white, sans-serif font. The background is decorated with several thin, light gray concentric circles and dashed lines, creating a subtle pattern.

# General Overview




## Definitions

- All the following definitions are taken from the World Professional Association of Transgender Health (WPATH) Standards of Care (SOC) version 8
  - WPATH is an international non-profit group dedicated to education
  - WPATH publishes the SOC which helps to articulate a professional consensus about the psychiatric, psychological, medical, and surgical management of gender dysphoria and help professionals understand the parameters within which they may aid those with these conditions.

- 
- **GENDER IDENTITY** refers to a person's deeply felt, internal, intrinsic sense of their own gender
  - **GENDER EXPRESSION** refers to how a person enacts or expresses their gender in everyday life
    - Appearance: dress, hairstyle, hormonal and surgical interventions
    - Mannerisms, speech
    - May or may not conform to a person's gender identity
  - **SEXUAL ORIENTATION** refers to a person's sexual identity, attractions, and behaviors in relation to people
  - **GENDER DYSPHORIA** describes a state of distress or discomfort when a person's gender identity differs from that which is physically and/or socially attributed to their sex assigned at birth
    - **SEX ASSIGNED AT BIRTH:** female, male, or intersex as defined by physical characteristics at birth



- 
- **TRANSGENDER** people are those whose gender identities and/or gender expressions are not what is typically expected for the sex to which they were assigned at birth.
  - **TRANSGENDER MEN** or **TRANS MEN** are people who have gender identities as men and who were assigned female at birth.
  - **TRANSGENDER WOMEN** or **TRANS WOMEN** are people who have gender identities as women and who were assigned male at birth.
  - **NONBINARY** refers to those with gender identities outside the gender binary. People with nonbinary gender identities may identify as partially a man and partially a woman or identify as sometimes a man and sometimes a woman

## Mistrust of Health Care Providers

- **For many years there has been a mistrust between transgender patients and healthcare providers**
  - **Lack of education for medical providers**
  - **Lack of understanding the medical needs**
  - **Insurance barriers**
  - **Fear of seeking care**

# Pronouns

Always ask a patient's pronouns!

- May not be the same as their gender expression

She/Her/Hers

He/His/Him

They/Theirs

Patient's name



## Creating a Culture of Trust

Cultural training protocols

Do not use stereotypical language

- “preference”
- “lifestyle”
- “choice”

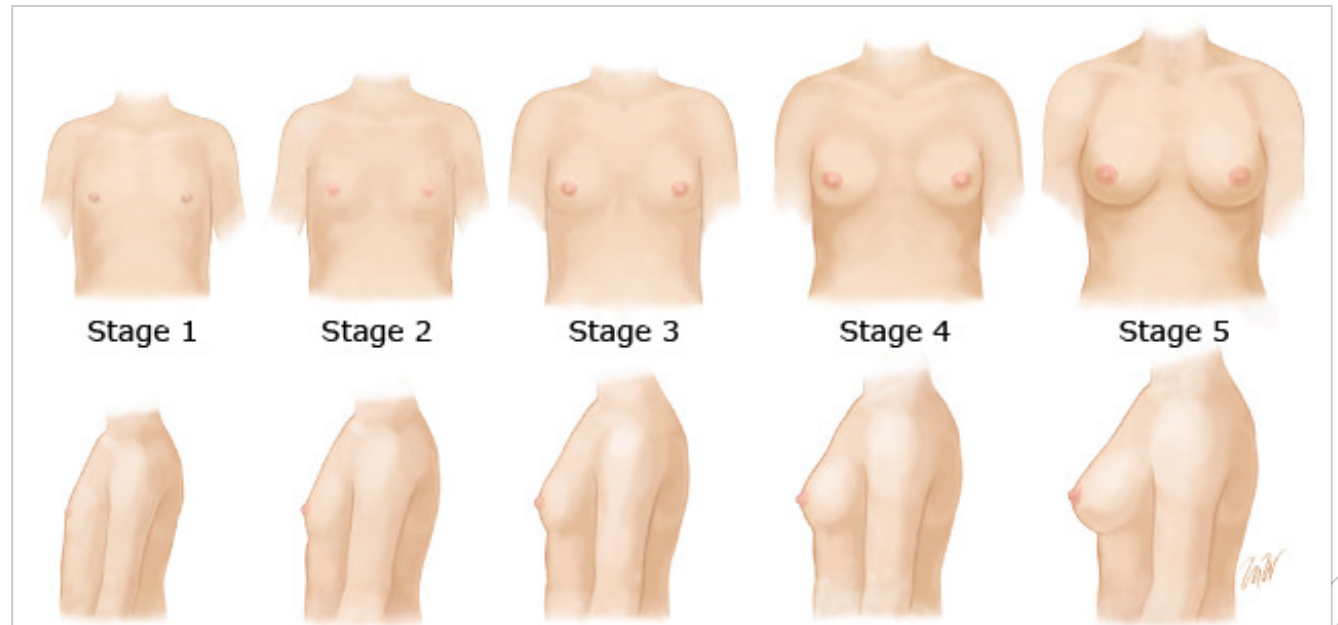
Respecting patient decisions

# Breast Augmentation

Transwoman

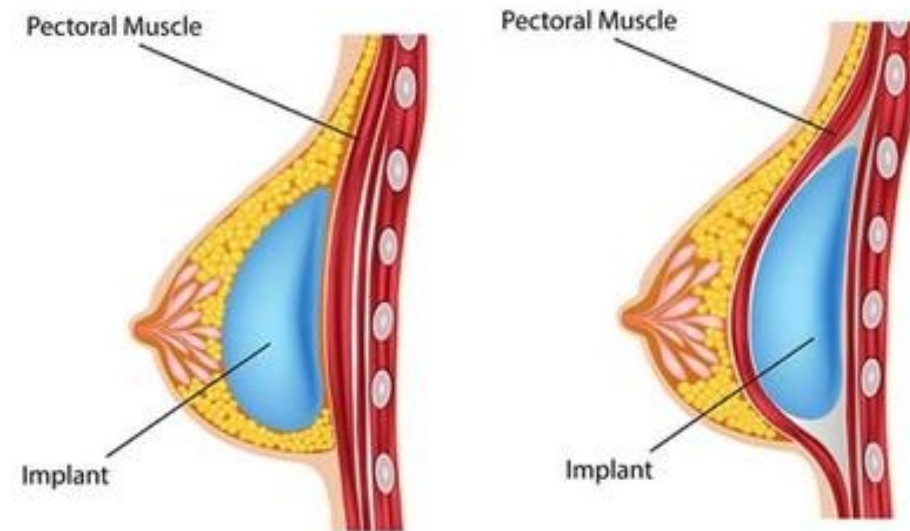
# Breast Development

- Exogenous estrogen → Breast development
  - After 3-6 months on estrogen, there is development of breast bud
  - "Full" breast development reached after 2-3 years on hormone therapy



# Procedure

- Implantation of silicone or saline implant
- Implant is placed either in the sub-glandular (below the breast tissue) or sub-pectoral (behind pectoral muscle) plane



# Breast Augmentation – Aftercare

- **Capsular Contracture**
  - Definition: fibrotic scar forming around breast implant
  - Common complaints: "Breast discomfort," "implant in wrong spot," "implant less mobile"
  - Risk Factors:
    - Implant rupture
      - Exogenous silicone injection - "pumping"
    - Fluid in surgical site – hematoma, seroma
    - Subglandular implant placement
  - Defined by Baker Grade I-IV
  - Treatment: Surgery and removal of capsule
- MRI monitoring
  - MRI without contrast to assess implant integrity



# Gender Affirming Mastectomy

Trans male / nonbinary

# “Top Surgery”

- The most common gender affirming procedures preformed
- Disconnect between breast tissue on the body and gender identity
  - Trans males
  - Nonbinary

As a primary care provider, few considerations:

- Does the patient plan to have children / breast feed in the future?
- Family history of breast cancer?
- If age >40, history of a mammogram?

	<b>Double Incision</b>	<b>“Keyhole”</b>
<b>Type of Incision</b>	Breast tissue is removed through bilateral incisions strategically placed along the inferior pectoralis. The NAC is taken as a skin graft and moved to a masculine location on the chest wall.	A small incision is made below the NAC to remove breast tissue.
<b>Benefits</b>	The patient’s former sagging skin can be placed taut against their chest for a flat appearance. Nipple size and location are changed to reflect a more masculine appearance.	Little to no scarring occurs with this procedure.
<b>Risks</b>	Patients will have a loss of nipple sensation and larger, more prominent scars.	Patients with excess breast tissue may have excess skin sagging or rippling after surgery, as well as no change in NAC size or location.



# Rates of Breast Cancer in Transgender Population

- Female to male (trans male)
  - Higher rate of developing breast cancer than cisgender males
  - Lower risk than cisgender females
- Male to female (trans female)
  - Higher risk of developing breast cancer than cisgender males
  - Lower risk than cisgender females
    - Patterns of breast cancer were more hormone responsive

# Gender Affirming Mastectomy – Aftercare

## Patient Complaint:

- Bump, irregularity, tenderness, erythema
- (+) family history

## Physical Exam:

- Size, location, shape, texture
- Assess axillary lymph nodes

## Workup:

- Mammogram vs ultrasound
- Could also consider MRI

Breast Cancer  
Screening in  
trans male  
population

**UCSF Recommendation (Pending 2024 update):**

- **Do not recommend yearly chest exams, unless there is a new patient complaint (i.e. lump)**

## Breast Cancer Screening in trans female population

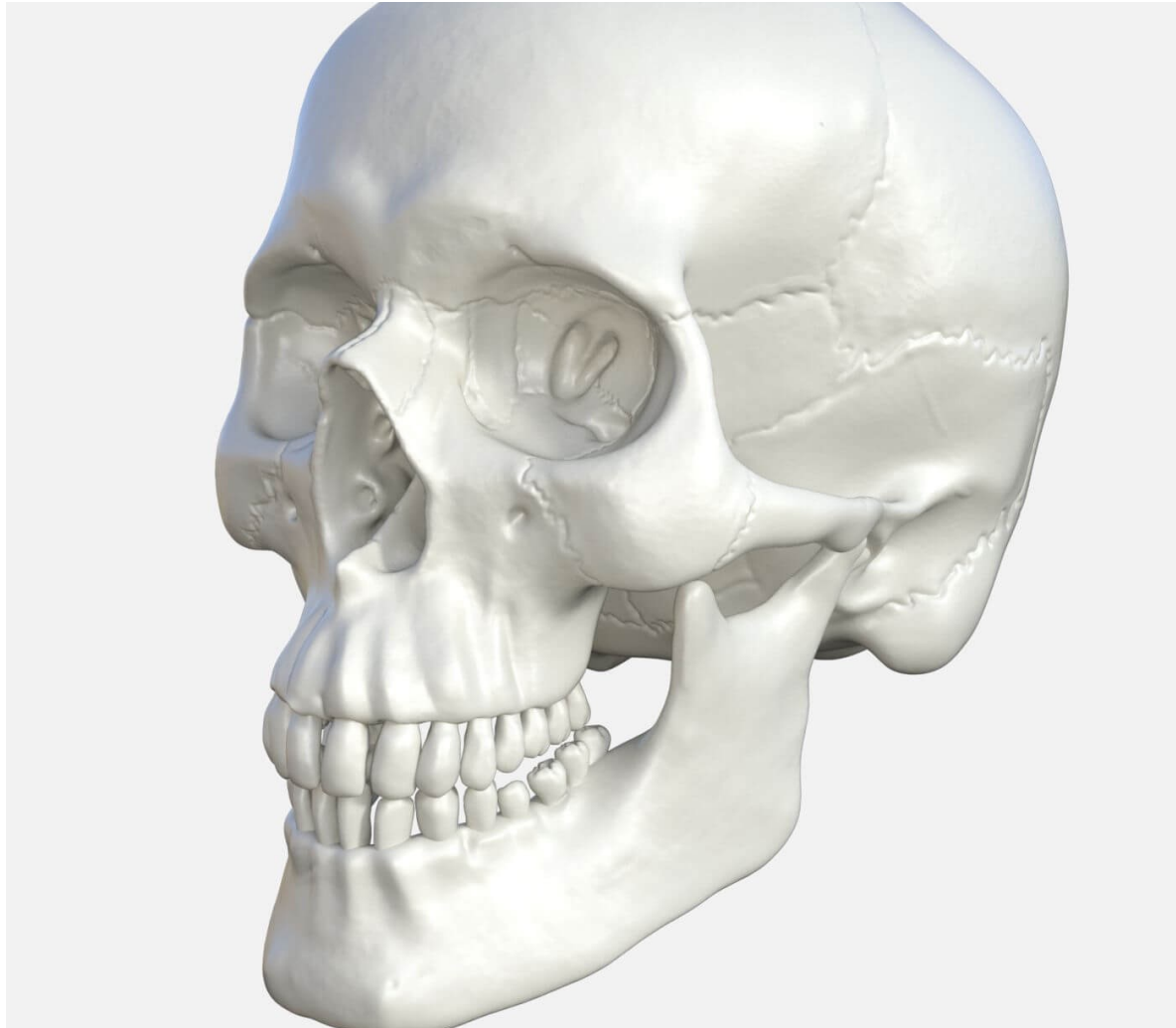UCSF Recommendation (Pending 2024 update):

- A screening mammography should be performed every 2 years, *once*
  - The patient reaches the age of 50 and they have 5-10 years of feminizing hormone use.

The image features a blue speech bubble with a white outline, pointing downwards. Inside the bubble, the text "Facial Gender Surgery" is written in a white, sans-serif font. The background is white with faint, light gray concentric circles and dashed lines, creating a subtle geometric pattern.

# Facial Gender Surgery





# Facial Gender Surgery

- **Multi-staged procedures**
  - **Forehead reconstruction**
    - Hairline lowering / transplant
    - Orbit contouring
  - **Septoplasty & Rhinoplasty**
  - **Lip lift**
  - **Midface reconstruction**
    - Malar implants – make midface larger
    - Zygomatic osteotomies – make midface narrower
  - **Genioplasty**
    - Gonial angle reduction
    - Chin augmentation
  - **Facelift**
  - **Hair removal**

## Facial Gender Surgery - Aftercare

- Swelling can persist for 9-12 months
- Continue to provide reassurance to patients

### Always assess symmetry

- If more acute, make sure asymmetry is not infectious (i.e. abscess)
- If occurs late post-op, may have to do with scar tissue or surgical technique

Patients often need post-operative CT scan to assess bony anatomy

Would recommend patients follow up with original surgeon for any major issues / concerns

# Vaginoplasty

Transwomen

# Procedure

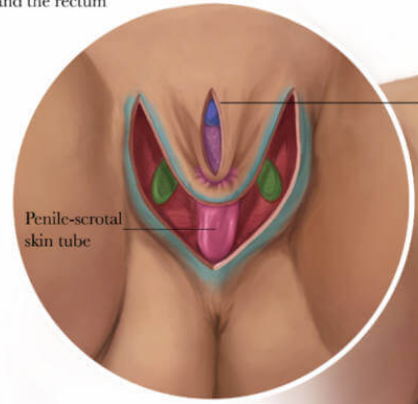- **Generally: the creation of a vaginal canal and external female genitalia**
  - Penectomy – removal of penis
  - Orchiectomy – removal of testicles
  - Clitoroplasty – creation of clitoris
  - Urethroplasty – creation of urethra
  - Vulvoplasty – creation of vulva
  - Vaginoplasty – creation of vaginal canal

Some patients forgo a vaginoplasty, creation of the vaginal canal, and have a “minimal depth” procedure

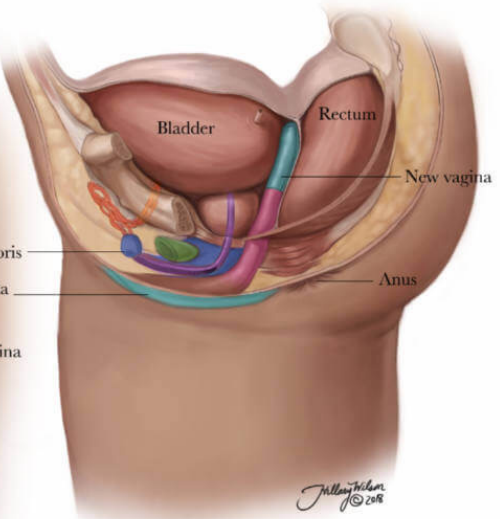
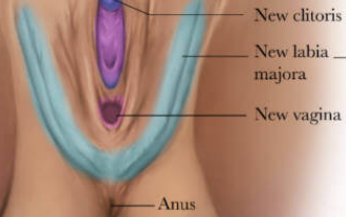- Typical for patients uninterested in vaginal intercourse

## Male to Female Vaginoplasty

The penile-scrotal skin tube is turned inside-out and inserted into the space between the bladder and prostate, and the rectum



A cut is made to expose the clitoris and urethra



- Scrotum
- Corpus Cavernosum
- Penile skin
- Corpus Spongiosum and Glans
- Urethra
- Neurovascular Bundle

*Jillany Wilson © 2018*

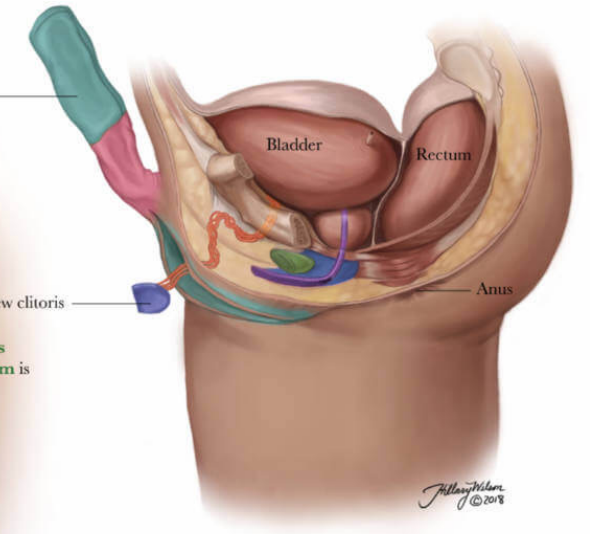
## Male to Female Vaginoplasty

A skin graft is taken from the **scrotum** and attached to the end of the **penile skin tube**.

Most of the **urethra** is removed, and the rest is spread open like a book

3 of 4 in series

Penile-scrotal skin tube



New clitoris

The **corpus cavernosum** is removed

- Scrotum
- Corpus Cavernosum
- Penile skin
- Corpus Spongiosum and Glans
- Urethra
- Neurovascular Bundle

*Jillany Wilson © 2018*

# Procedure

4 of 4 in series

# Acute Post-Op: Vaginoplasty



## Dilation:

- Twice daily dilation
  - Most vaginal canal made with scrotal skin
    - Skin contracts, most within 6-8 weeks
    - Important to trouble shoot problems early to prevent future problems
  - May consider pelvic floor PT or need to surgery if canal becomes stenotic

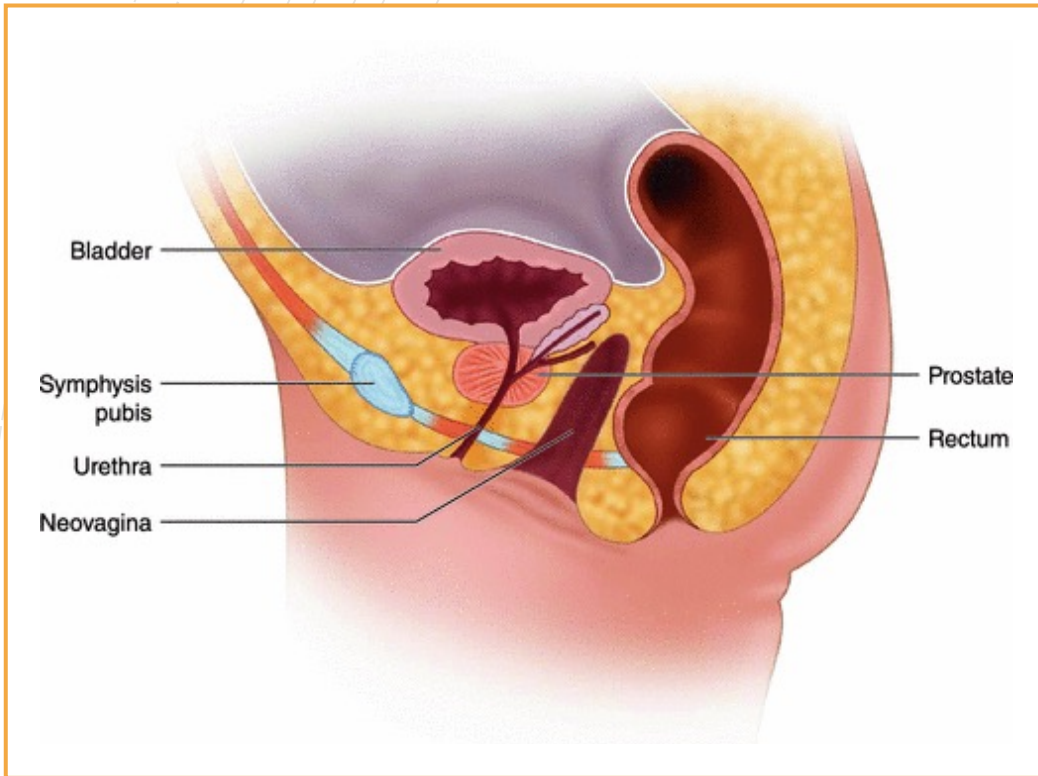
## Douching

- Saline or vinegar douches every 3-4 days
  - Neo-vaginal canal lacks 'peristalsis' to rid of vaginal discharge, requires manual cleaning
  - As time progresses, develop normal flora

## Hygiene

- Daily showering!
- Keeping incisions dry

# Long-Term Post-Op: Vaginoplasty



## Routine Screenings

- No recommendations on 'annual' exams, however, many patients seek visits
- Careful consideration of speculum size
  - X-Small vs Small speculum
- STI
  - NO cervix, ovaries, uterus– do not have to do PAP smears
  - Still risk of chlamydia, gonorrhea, HIV/AIDS, HPV, etc.
- Prostate still present
  - If having urinary problems, easier to palpate prostate via vaginal canal
  - Small, difficult to palpate
  - Routine screening not indicated unless problems arise

# Long-Term Post-Op: Vaginoplasty

## Vaginal Health

- Lack of hair removal = increased risk of infection
- Colon vaginoplasty = increase lubrication and mucoid discharge
- Proper cleaning after intercourse, dilation, etc

## Cancer Screening

- Colon vaginoplasty
  - Diverticular disease
  - Ulcerative colitis
  - Adenocarcinoma
- Scrotal/peritoneal vaginoplasty
  - Skin cancer

## Foley Insertion

- Urethra may look different than in cis-female
- Will still be in same anatomic position, between clitoris and vaginal canal



# Phalloplasty

Trans male

## Procedure

### ■ Phalloplasty is the creation of a penis

- Phalloplasty – creation of a penis
- Scrotoplasty – creation of a scrotum
- Urethroplasty – creation of a urethra
- Vaginectomy – removal / closure of the vaginal canal
- Clitoral burying – burying of the clitoris into the shaft of the penis
- Glansplasty – creation of a glans or “head” of the penis

Phalloplasty is highly individualized – not all patients are the same!

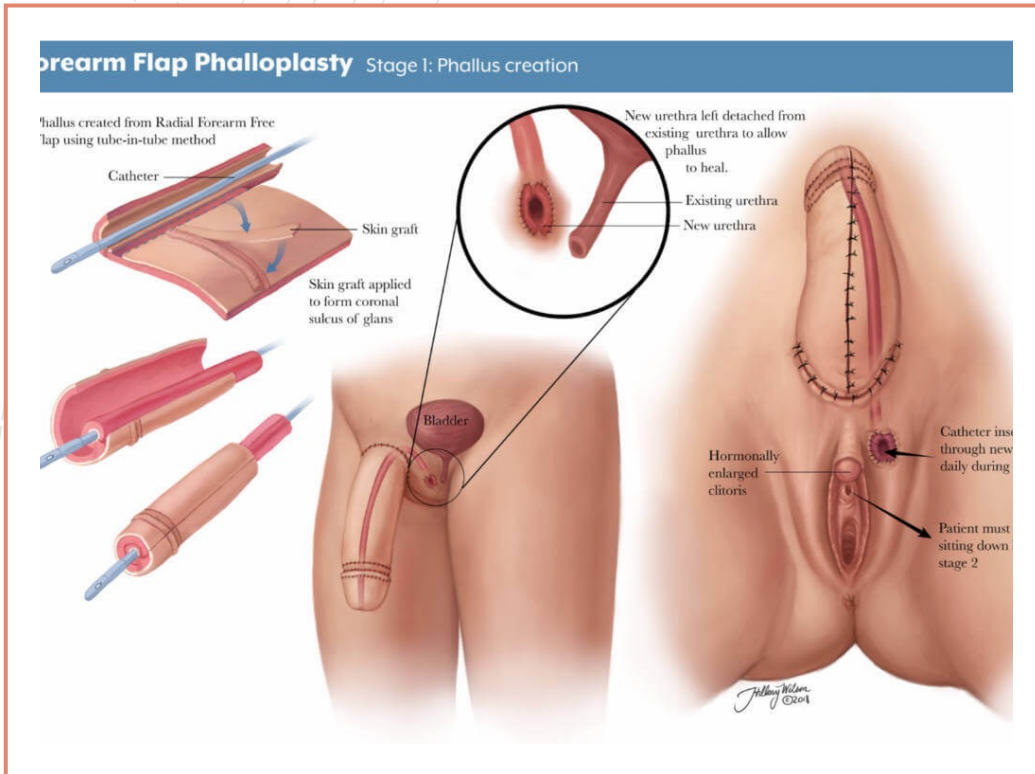
# Phalloplasty: Everyone is Unique

- Each patient's surgical plan is customized to their goals
- Functional options:
  - Stand to pee
    - Determines ability to keep / leave vaginal canal
  - Desire for erogenous sensation
    - Different donor sites have greater potential for nerve regeneration
  - Ability to have penetrative intercourse
  - Aesthetics
- Donor site options:
  - Arm – radial forearm free flap
  - Leg – anterolateral thigh free flap
  - Back – myocutaneous latissimus dorsi free flap



As a provider, you must be sensitive  
to the surgical stage that the  
patient is currently in

# Stage I Phalloplasty



## ■ Procedure:

1. Creation of phallus using patient's preferred donor site and covering donor site with biologic material and/or skin graft
2. Micro-anastomosis of arteries, veins, and nerves to groin

## May also include:

1. Creation of a neo-urethra in the neo-phallus
  - This neo-urethra does NOT connect to the patient's native urethra

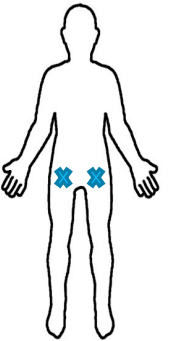
Patients in hospital for 5-7 days

## Acute Post-op: Stage I Phalloplasty

### ■ Phallus

#### ■ #1 concern = flap loss

- Positioning: Must keep phallus at 90 degree angle away from body
  - Should not sit at 90 degrees or bend at the waist for first 4 weeks
  - **Red flag**: cold phallus
- Hygiene decreases bacterial burden
  - Native anatomy is still present and often swollen
  - Very important for daily washing to prevent bacteria from traveling to surgical site



# Stage 2 Phalloplasty

- Procedure
  1. Glansplasty
    - Creation of the 'head' of the phallus
  2. Clitoral Burying
    - Burring of clitoris into base of phallus for erogenous sensation
  3. Scrotoplasty
    - Creation of scrotum
  4. +/- Vaginectomy
    - Removal and closure of the vaginal canal
  5. +/- Urethral lengthening
    - Connecting native urethra to neo-urethra in neo-phallus

## Acute Post-op: Stage 2 Phalloplasty

- Urethral Lengthening
  - Patients require a suprapubic tube to divert urine for 4-6 weeks to allow new urethra to heal
  - Common problems:
    - Bladder irritation – urge, abdominal pressure, spasms
    - Spasms – oxybutynin (ditropan)



# Long-Term Post-op: Phalloplasty

- Donor Site – Forearm
  - Neuroma
    - Inflammation of the nerves in the forearm
    - Most common the radial sensory nerve that runs parallel to radial artery used to make phallus
    - Complaints: tingling, numbness, shooting pains
    - Diagnosis: MRI
    - Treatment: surgery
  - Lymphedema
    - Excess lymphatic tissue located in hand
    - Often have decreased range of motion and function, limiting mobility
    - Treatment: Hand PT/OT, lymphatic massage, compression garments
  - Vascular access
    - **No radial artery** and veins have different anatomy on donor arm!
    - Cannot do arterial lines, should avoid IV and BP cuffs

- **Genital Region**
- **Special consideration to patient's unique surgical plan**
  - **Vaginal canal still present**
    - **Yearly vaginal exams, PAP smears**
    - **If uterus/ovaries are present, will need bimanual exam**
  - **Important for informed consent and chaperone to be present**

Long-Term  
Post-op:  
Phalloplasty

# Urethral Considerations

## Genital Region

### Urethral anatomy

#### Urinary complications

##### Stricture – tight area

Complaints: difficulty emptying bladder, urgency, bladder fullness, post-void dribbling

##### Fistula – passage between urethra and other structure

Complaints: urine leaking from site other than urethral meatus

##### Diverticulum – outpouching within urethra

Complaints: urine trapped, "sitting on fluid"

Treatment: procedure (office vs OR)

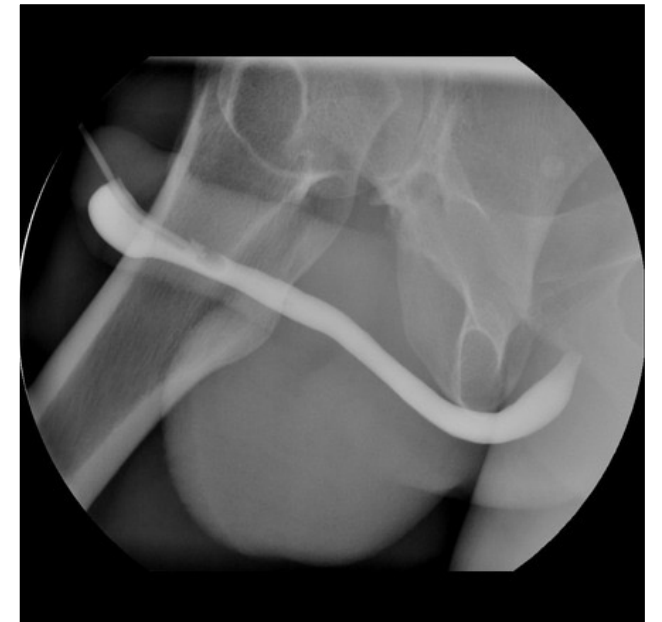
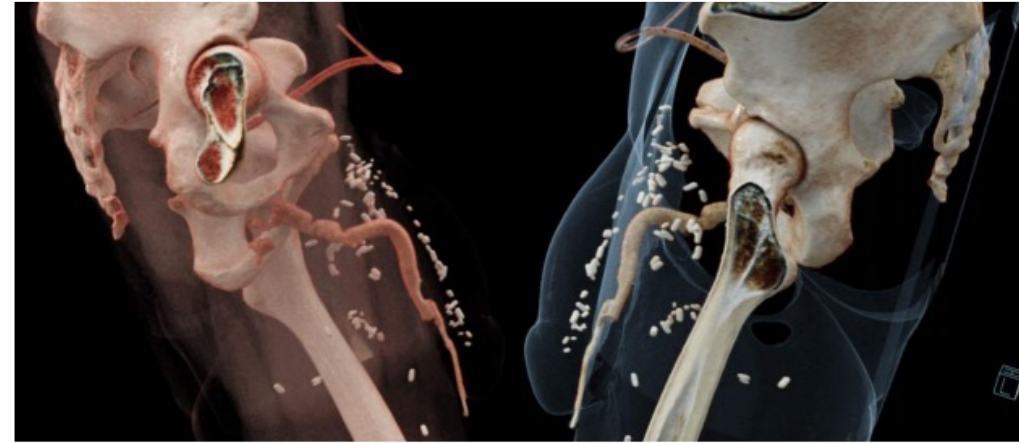
#### Insertion of Foley catheter

Neourethra is very tortuous

Even most skilled gender surgeons need direct visualization

May consider SPT vs Foley insertion if in acute setting

NO prostate!



The image features a central blue speech bubble with a white outline and a small tail pointing downwards. Inside the bubble, the word "Questions" is written in a clean, white, sans-serif font. The background is white and decorated with several concentric circles of varying radii, some solid and some dashed, creating a subtle geometric pattern.

Questions