

AAPA MSK Galaxy Injection Workshop

Introduction to MSK injections in upper and lower extremity

Chuck Dowell, MS, PA-C, ATC
Colorado Springs Orthopedic Group

Disclosure Statement

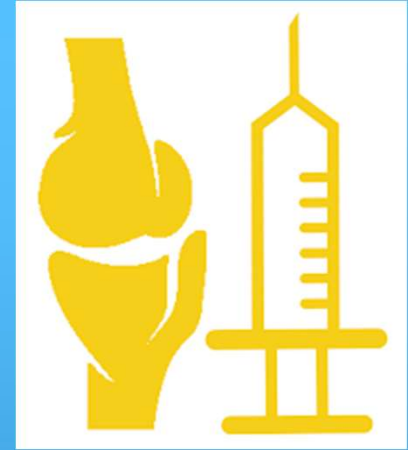I have no relevant relationships with commercial interests to disclose

Learning Objectives

At the conclusion of this session, participants should be able to:

- Identify indications, contraindications, risks, benefits, materials and proper technique of common MSK injection therapy*
- Identify common conditions of the upper and lower extremity that may benefit from injection therapy*
- Demonstrate beginning competencies regarding the location and identification of important functional anatomical landmarks and correct needle placement for injection therapy*
- Review acute inflammatory response and common complications from MSK injections*

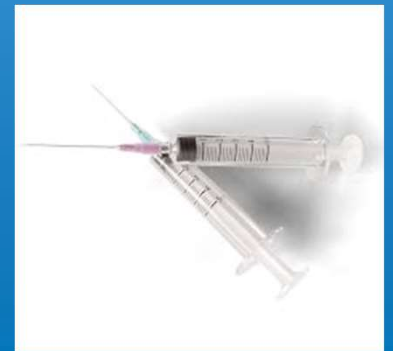MSK injections



- Important Adjunct for the management of MSK disease and pain
- Corticosteroid injections into articular, periarticular, or soft tissue structures relieve pain, reduce inflammation and improve mobility.
- Injections can provide therapeutic and diagnostic information.
- Local anesthetics can be used to provide more rapid relief while awaiting improvement from corticosteroids.

MSK Injections

- If the underlying diagnosis is unknown, aspiration and synovial fluid analysis should be performed for diagnostic purpose.
- Informed consent should always be obtained before performing the procedure.
- Injections should always be performed using aseptic technique.
- Research based on RA patients suggest it is safe to perform multiple injections in the same joint, but no more than every 3 months.

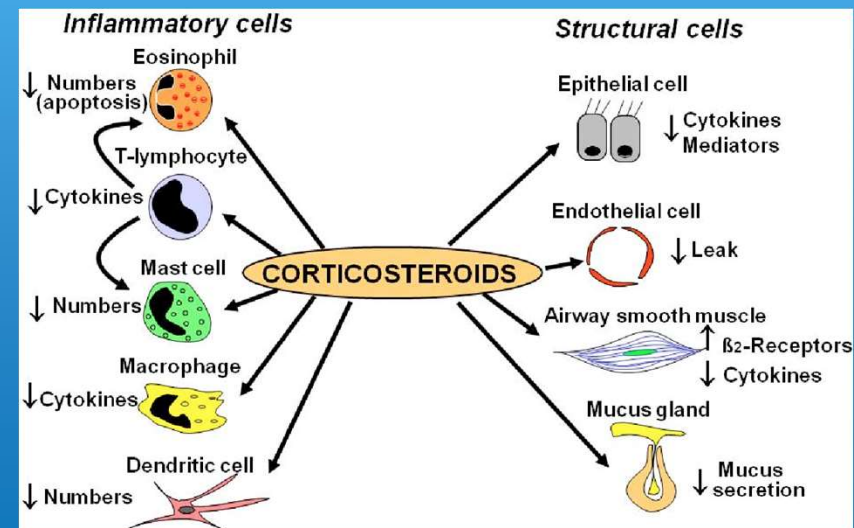
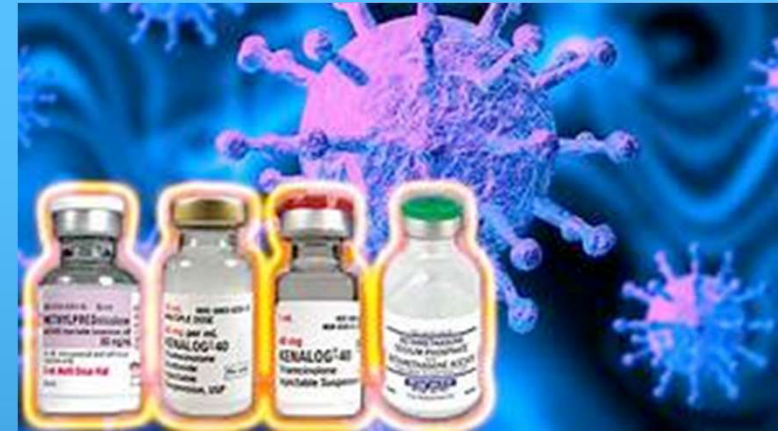

MSK Injections

- Types of Injections
 - Corticosteroids
 - Hyaluronic Acid
 - Orthobiologics

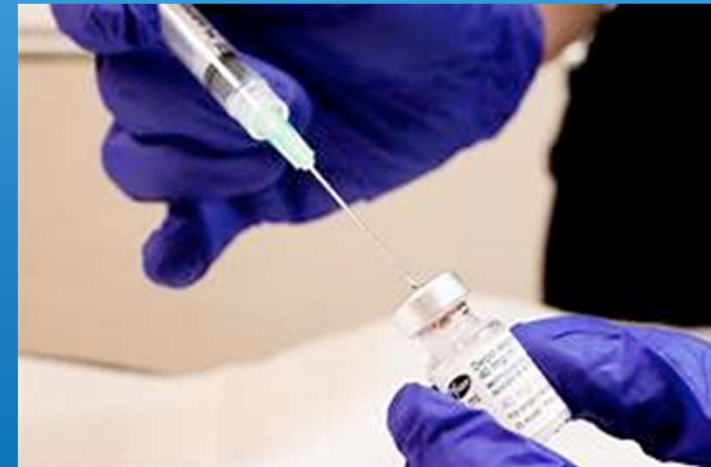MSK Injections

- Glucocorticoids are potent anti-inflammatories
 - Primary mechanism
 - Inhibits various leukocyte inflammatory events
 - Inhibits the two main products of inflammation
 - Prostaglandins
 - Leukotrienes
 - Intra-articular injections reduce synovial blood flow, lower local leukocyte and inflammatory modulator response, and alter local collagen synthesis.
 - These effects combine to reduce pain and inflammation



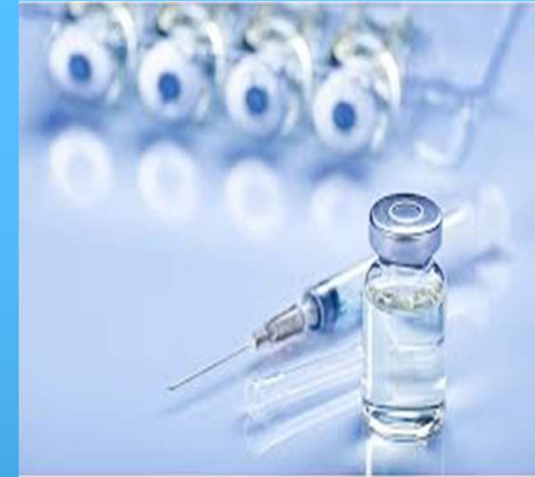Corticosteroids

- There is little evidence to guide corticosteroid selection for injections.
 - Most recommendations are based on clinical experience and personal preference.
- Clinically insoluble steroids have a longer duration of action and higher incidence of cutaneous side effects.
- Solubility
 - More soluble: less duration; less chance of flare
 - Less soluble; longer duration, more chance of flare



Corticosteroid Solubility

- Triamcinolone hexacetonide (Aristospan) is the least soluble of the commonly used injectable steroids, followed by triamcinolone acetonide (Kenalog)
- Methylprednisolone acetate (Depo-Medrol) is the most commonly used, followed by Triamcinolone hexacetonide (Aristospan) and triamcinolone acetonide (Kenalog)
- Most tend to use the above for intra-articular injections including large joints due to the lower solubility and longer duration of action.
- Small joint injections prefer hydrocortisone or Depo-medrol
- Typically use Betamethasone (Celestone) for soft tissue injections due to higher solubility, shorter duration of action and fewer cutaneous side effects.



Classification

Soluble	Insoluble
Dissolve freely in water Non-particulate (clear) Quick onset of action Shorter duration of action	Require hydrolysis by cellular esterase's Particulate Longer onset of action Longer duration of action
Dexamethasone Betamethasone	Trimcinolone Methylprednisolone

Types of Corticosteroids

Steroid Solution	Potency	Half-Life	Onset/Duration	Dose/Volume
Hydrocortisone	Low	8-12 hr	Short/Short	50mg/ml
Triamcinolone act (Kenalog)	Interm	12-36 hr	Intrm/Intrm	4mg/ml
Triamcinolone (Aristospan)	Interm	12-36 hr	Intrm/Intrm	40mg/ml
Methylprednisolone (Depo-Medrol)	Interm	12-36 hr	Intr-long/Intr-long	40mg/ml
Betamethasone acetate (Celestone)	High	26-54 hr	Long/long	6mg/ml
Dexamethasone acetate	High	26-54 hr	Long/Long	8mg/ml

Equivalent dose

Corticosteroid	Dose (mg)
Depo-medrol	40
Kenalog	40
Dexamethasone acetate	8
Betamethasone	8
Hydrocortisone acetate	200

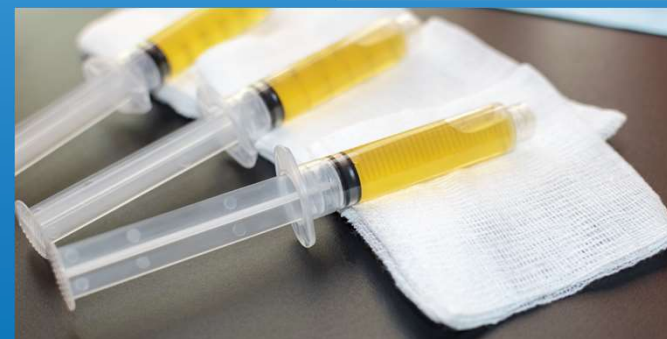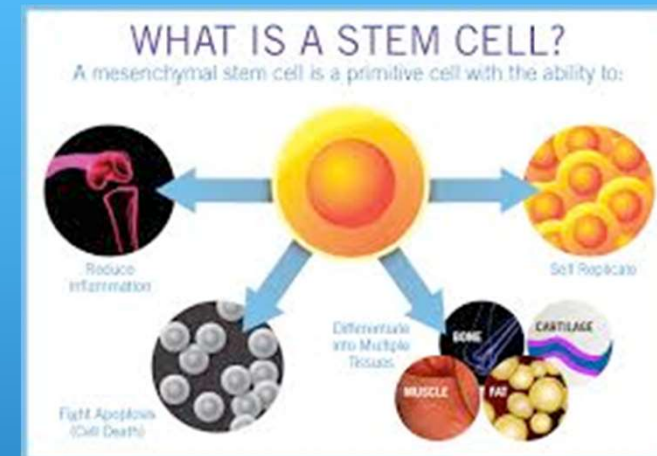
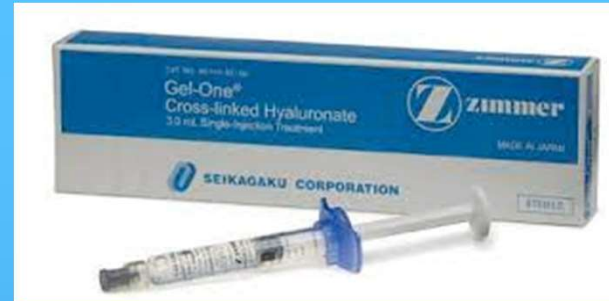Adjunct Injections

Hyaluronic Acid

- Multiple different manufactures
- Evidence of Synergistic effect with CS or HA injections

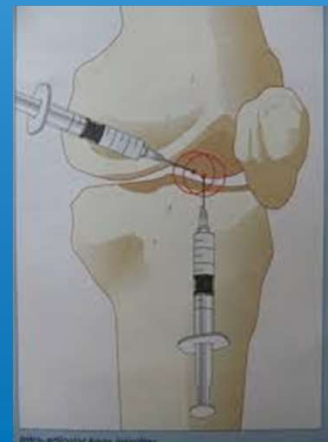
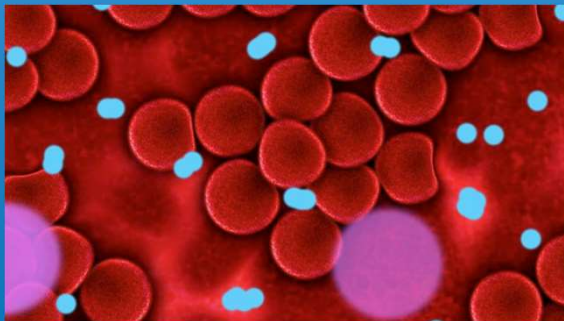
Orthobiologics

- Platelet Rich Plasma
 - Chondroprotective effect up to one year in moderate knee OA
 - Average cost \$500-\$2000
 - Some evidence of synergistic effect with HA
- Cell Based therapies
 - Adipose Derived “Stem Cells”
 - Placental and Amniotic Allogenic Cells



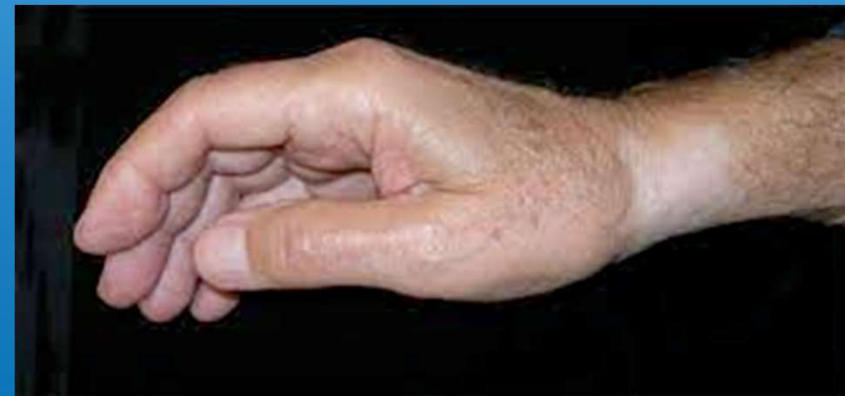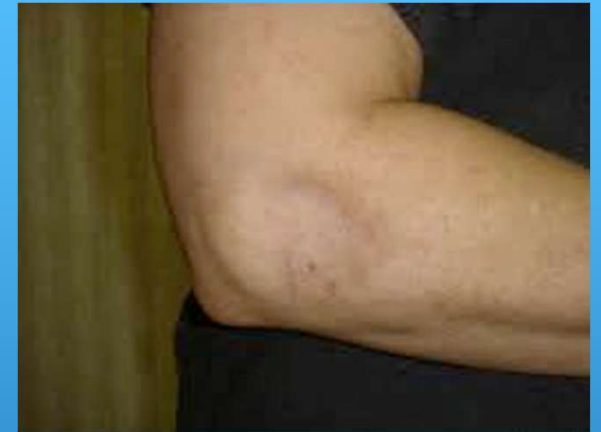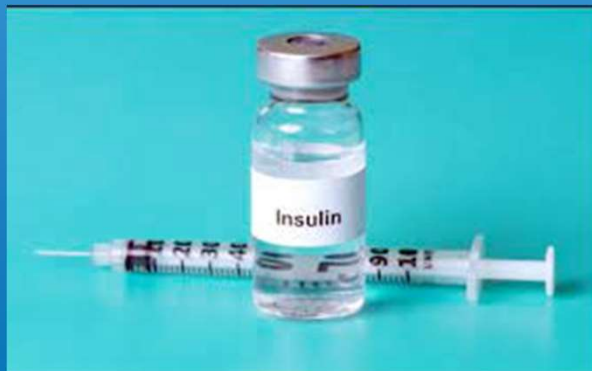Contraindications to MSK injections

- Absolute
 - Infection, Corticosteroid allergy, Intra-articular Fracture, Unstable joint
- Relative
 - Coagulopathy, Indwelling prosthesis, Uncontrolled diabetes mellitus, Recent intra-articular injection < 3months, Multiple intra-articular injections (max 3-4 per year at specific site).



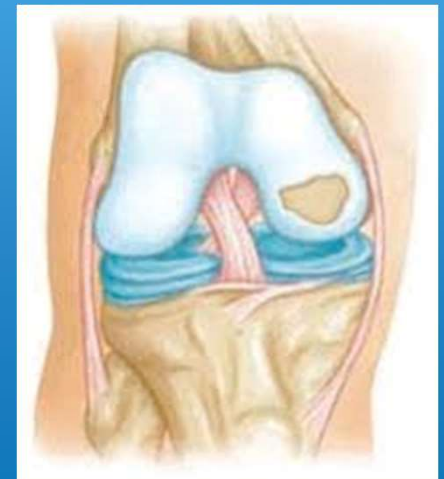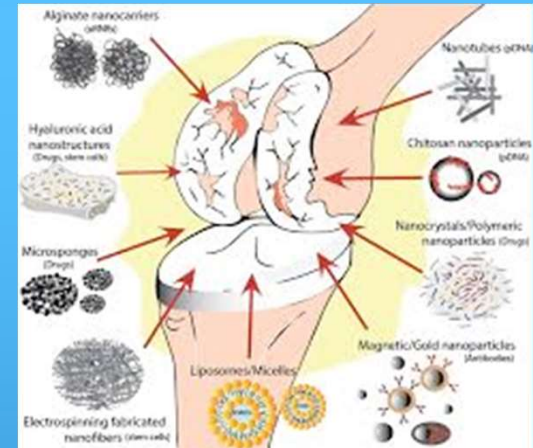Common risk and side effects of MSK Injections

- Elevation in blood sugar
 - 2-5 days post injection, need to warn diabetics that this can persist for 21 days.
 - Intra-articular injections typically have little or no effect, however soft tissues or peritendinous injections can cause elevation.
- Skin pigmentation changes (5%)
 - Develops 2 months post-injection, typically normalizes in 12 months
- Fat/ skin atrophy (8%)
 - Develops 1-4 months post injection, may take 1-2 years to normalize
- Infection (0.01 - 0.03%)
- Chondral Toxicity
- Steroid Flare (2-25%)
- Tendon Rupture (<1%)
- Wound healing issues



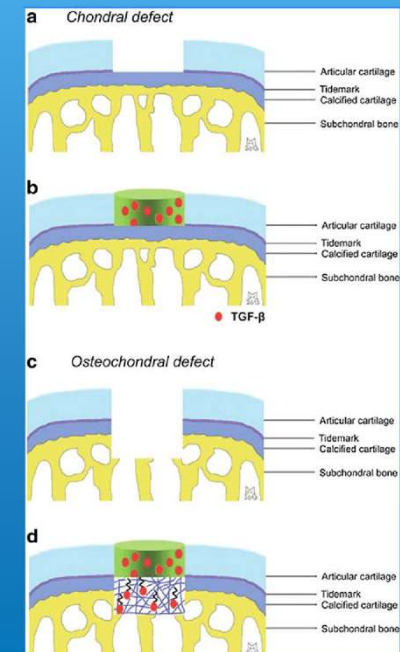
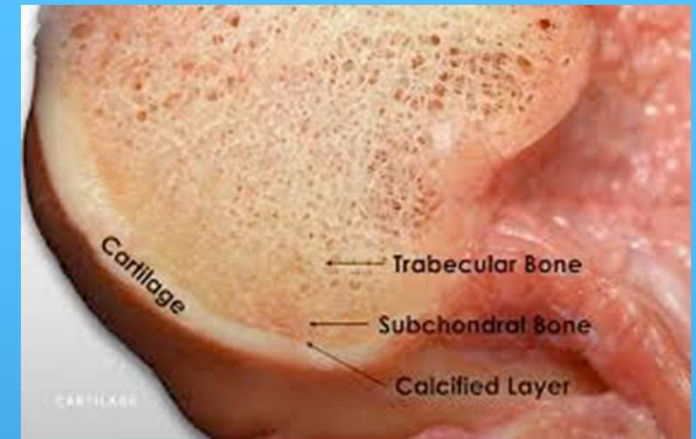
Chondral Toxicity

- Intra-articular use of local anesthetics may have lasting detrimental effects on human articular cartilage and chondrocytes, although the clinical relationship between local anesthetic exposure and chondrolysis requires further study.
- Bupivacaine and lidocaine have been found to be more chondrotoxic than mepivacaine and ropivacaine.
- Osteoarthritic cartilage seems to be more vulnerable compared to intact cartilage.
- The cytotoxicity of local anesthetics on chondrocytes is dependent on dose, time, and type of local anesthetics.
- Assuming similar changes in humans, any descent to clinically appreciable chondrosis or arthritis possibly related to chondrocyte morbidity following single injection of 0.5% bupivacaine would likely take years, even a decade or more

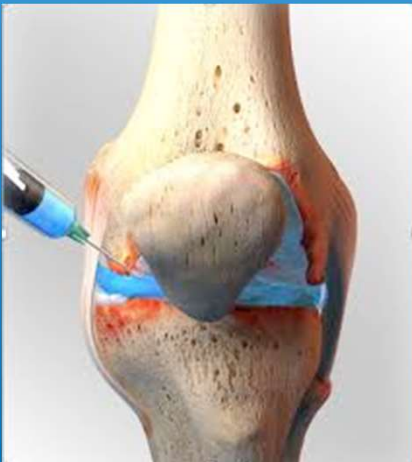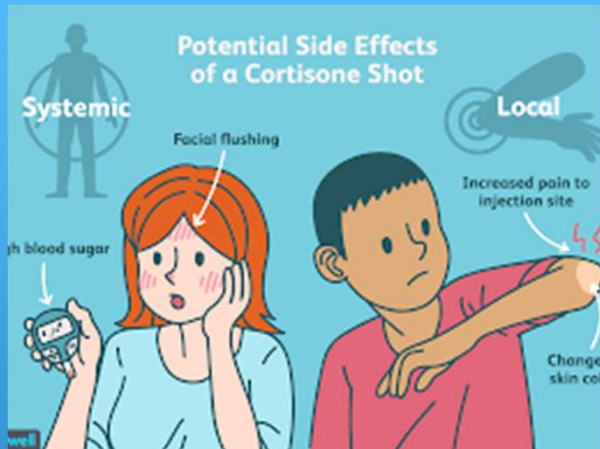


Chondral Toxicity

- In regards to single injection, use the lowest dosage for the shortest period of time to achieve the desired clinical effect.
- It was found that 3 cc to 5 cc of 1% lidocaine is sufficient. Minimizing the frequency of single injections of local anesthetics alone or in combination with corticosteroids remains a sound basic principal.



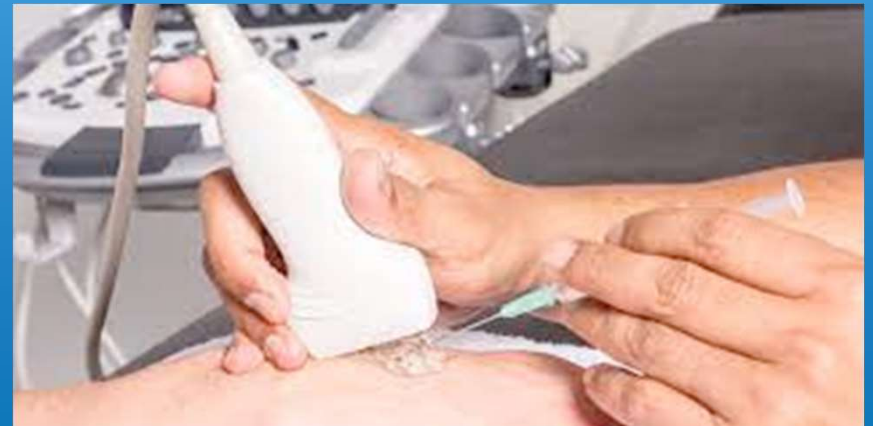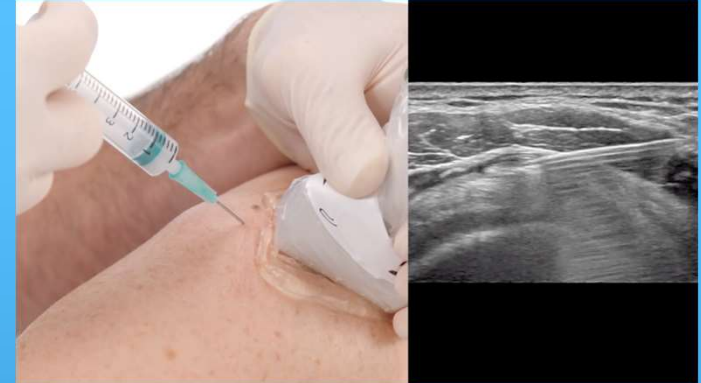Steroid Flare



- Cortisone is an injected anti-inflammatory drug that can cause a painful side effects known as “steroid flares” which are caused by cortisone crystallizing at the injection site.
- Typically occur 1-2 days after the injection.
- Insoluble, cortisone crystals forming on the synovial membrane cause macrophages to collect at the cite of crystallization. This immune response, leads to the release of synovial fluid, swelling and pain at the injection site.
- These have been documented to occur in 5-20% of injections, tend to be more common in small joints.
- More often caused by insoluble (long-acting) agents including Depo-Medrol and Kenalog

Traditional vs Ultrasound

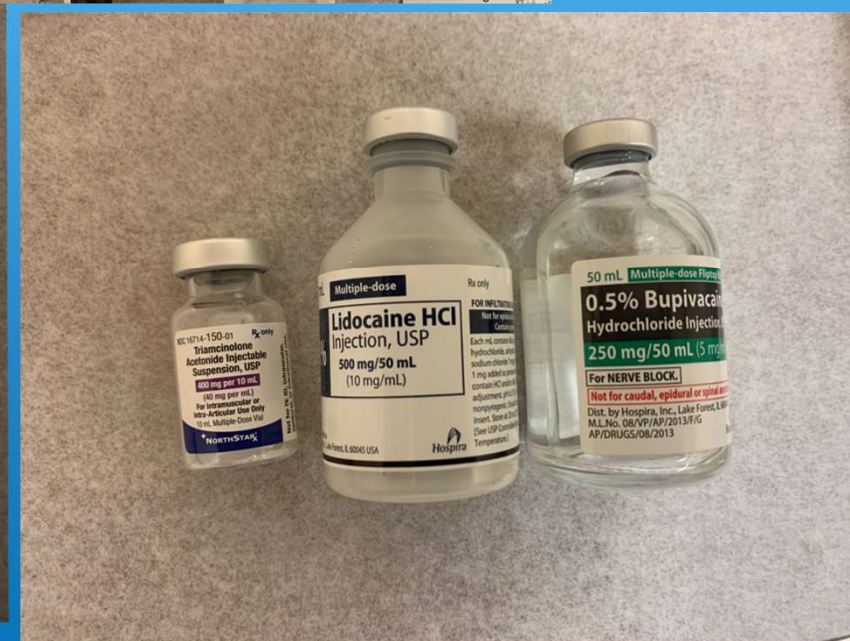

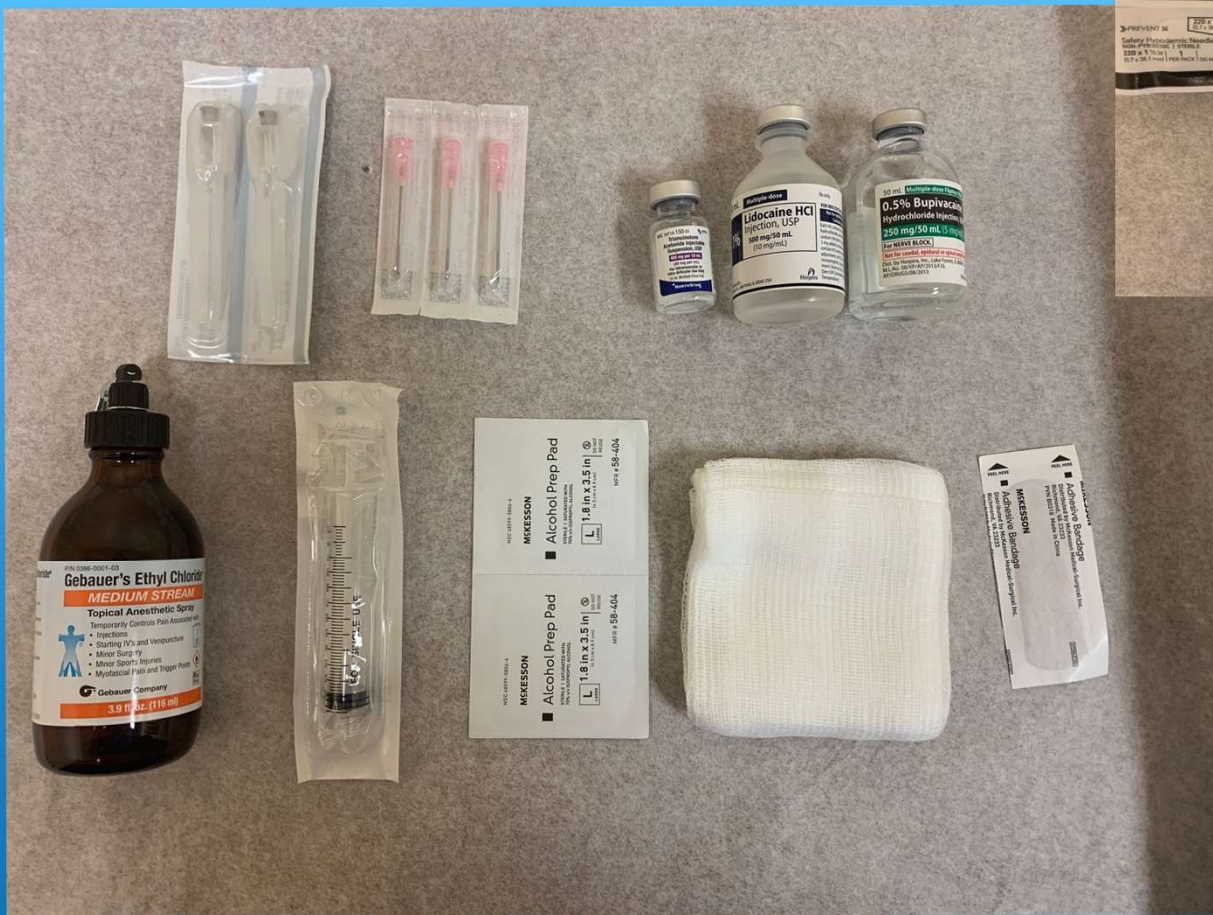
- US guided Injections - Ensures accuracy of injection location
 - Accuracy of US guidance vs palpation
 - Suacromial injections 100% vs 60-75%
 - Glenohumeral Injections 92-95% vs 40-79%
 - AC joint Injection 100% vs 40-67%
 - Biceps Tendon Sheath Injection 100% vs 67%
 - Improved comfort of patient - No probing or repeated poking
 - Aid in Diagnosis
 - Reimbursement
- Disadvantage
 - Time commitment
 - May need assistant
 - Dependent on skill set



Pre-injection checklist

- Patient positioning
- Skin evaluation
- Anatomic landmarks for injection
- Preparation of injection solution
- Sterile skin prep
- Procedure
 - Confirm injection/aspiration landmarks
 - Anesthetize skin (ethyl chloride spray)
 - Needle position and direction
- Post injection instructions

MSK Injections



Which injections we will cover

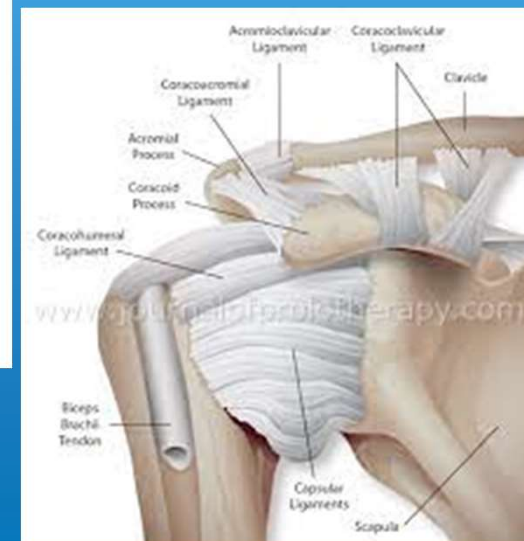
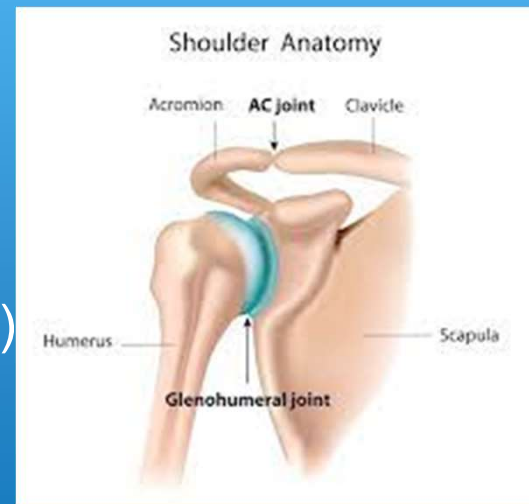
- Upper Extremity
 - Glenohumeral joint
 - Acromioclavicular joint
 - Subacromail bursa
 - Long head of the biceps tendon sheath
 - Lateral and Medial epicondylitis
 - Olecranon bursitis
 - First CMC joint
 - De Quervain's Tenosynovitis
 - Trigger Finger
- Lower Extremity
 - Trochanteric bursitis
 - Pes Anserine bursitis
 - Knee joint injection and aspiration
 - Plantar fasciitis
 - Morton's Neuroma

MSK Injections

- Upper Extremity
 - Glenohumeral joint
 - Acromioclavicular joint
 - Subacromail bursa
 - Long head of the biceps tendon sheath
 - Lateral and Medial epicondylitis
 - Olecranon bursitis
 - First CMC joint
 - De Quervain's Tenosynovitis
 - Trigger Finger

Glenohumeral Joint

- Articulation of the humerus with the glenoid fossa, it is the most mobile joint in the body
- The articulation is stabilized by the soft tissue configurations of a number of ligaments and muscles.
- Three major indications for injections:
 - Osteoarthritis
 - Adhesive capsulitis (frozen shoulder)
 - Rheumatoid arthritis



Glenohumeral joint injection

Patient Position: Patient is sitting with arm resting comfortably at the side, shoulder is externally rotated.

Landmarks: Depends on anterior or posterior approach, coracoid process and posterior lateral acromial angle.

Tissue to Avoid: Humeral head, axillary nerve is 4 finger breaths below the posterior acromial angle.

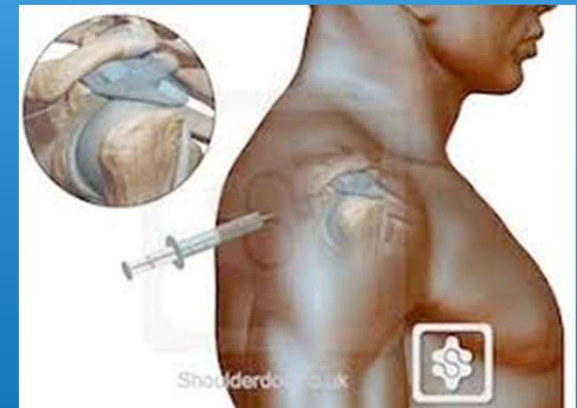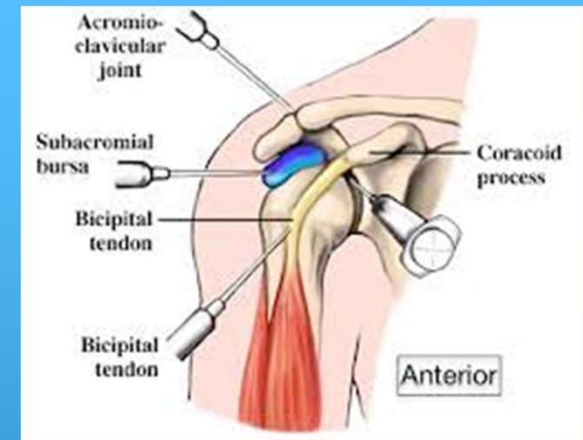
Prep: Chlorhexidine/Betadine/alcohol wipe, can use topical ethylchloride

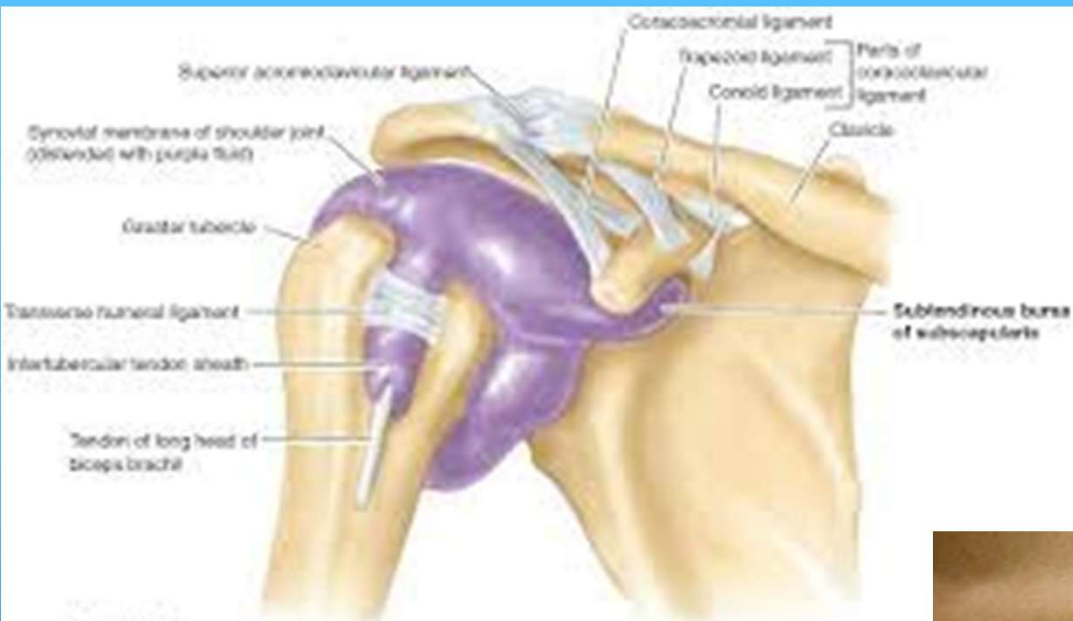Needle Insertion: Mark area with pen or needle cap, insert 25g 1.5" needle thru anesthetized skins, Anterior - 1cm lateral to coracoid process directed posteriorly and slightly superiorly and laterally. Posteriorly - 2-3 cm inferior to the posterolateral corner of the acromion and directed anteriorly in the direction of the coracoid process.

Injection: Alone or mixture of 2-4ml 1% lidocaine and 0.5% Bupivacaine, Selected corticosteroid.

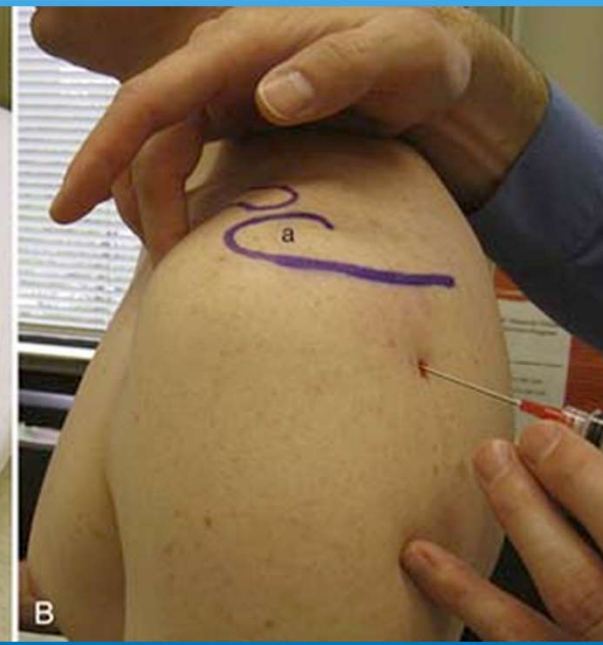
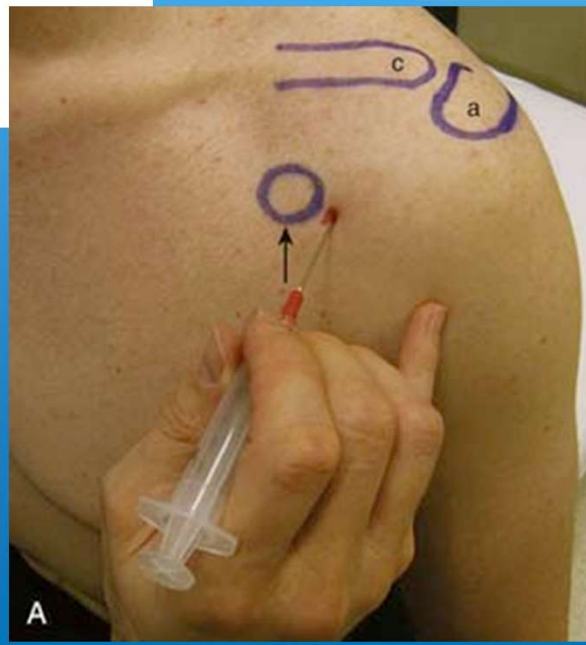
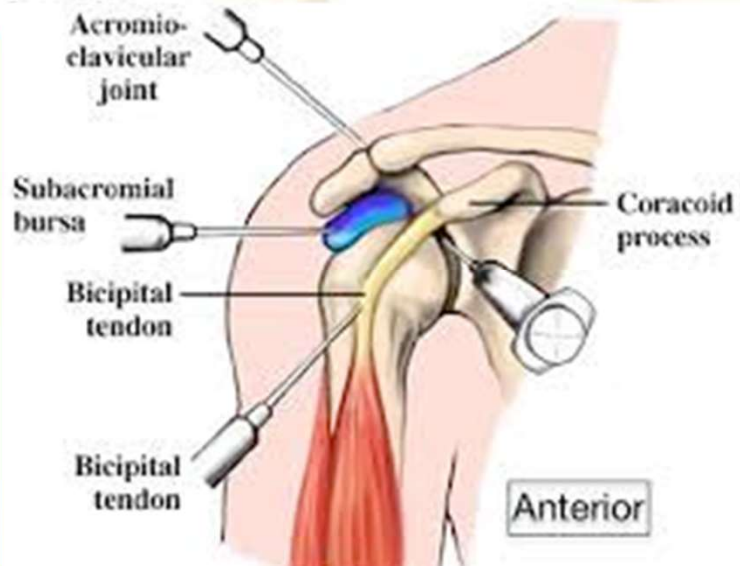
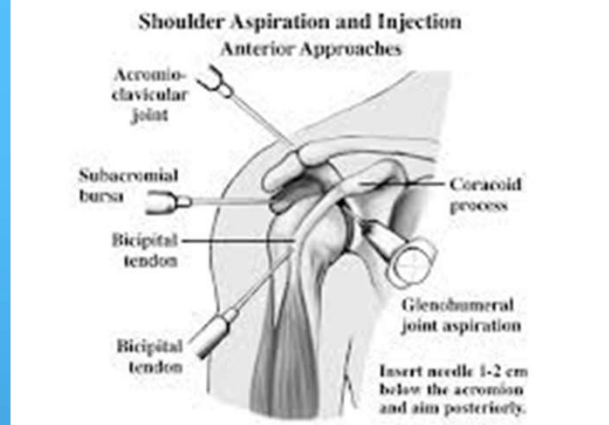
Observe patient: Watch for vaso-vagl reaction, rub area of injection to reduce pain, discuss with patient improvement of symptoms from local anesthetic.

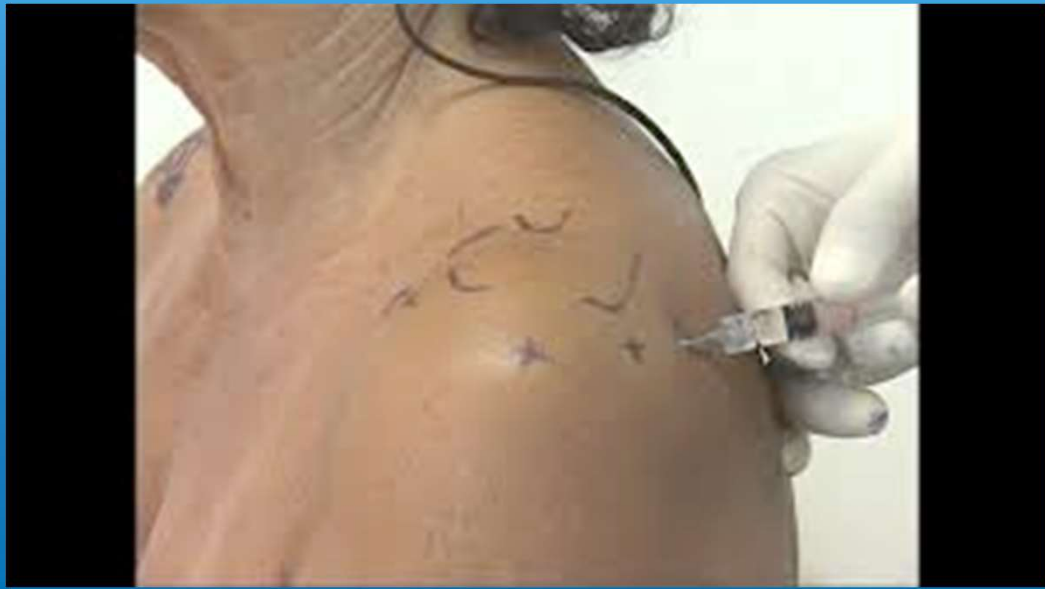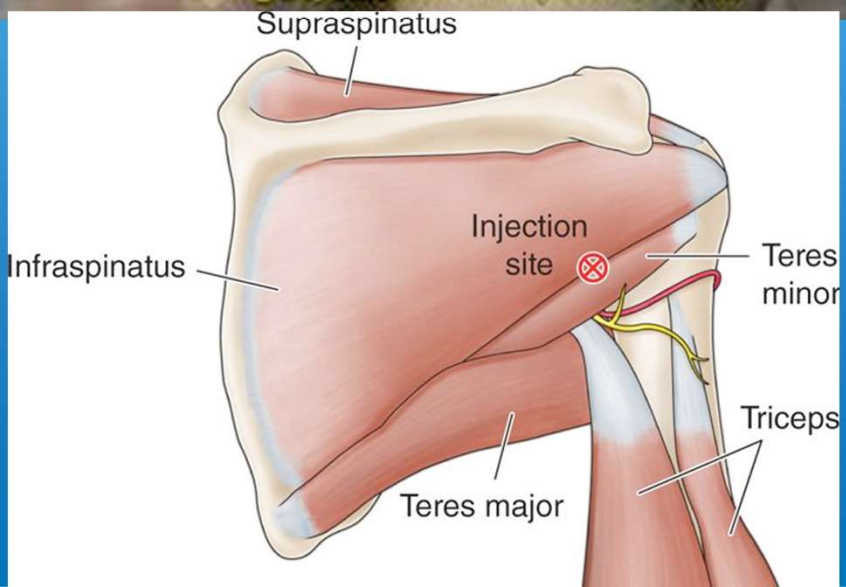
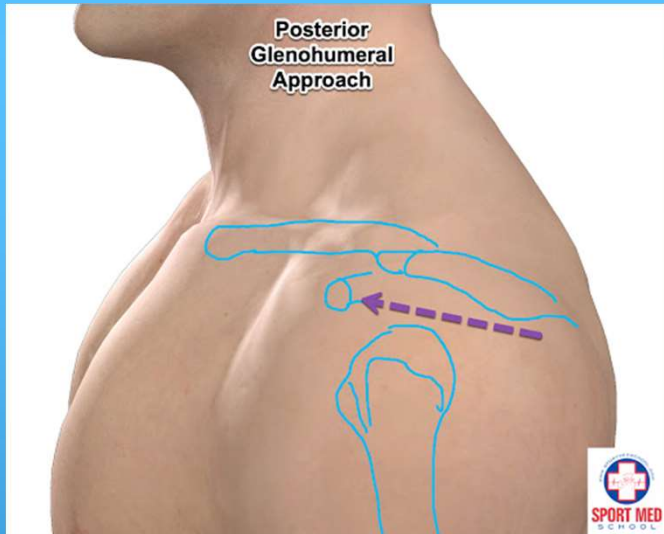
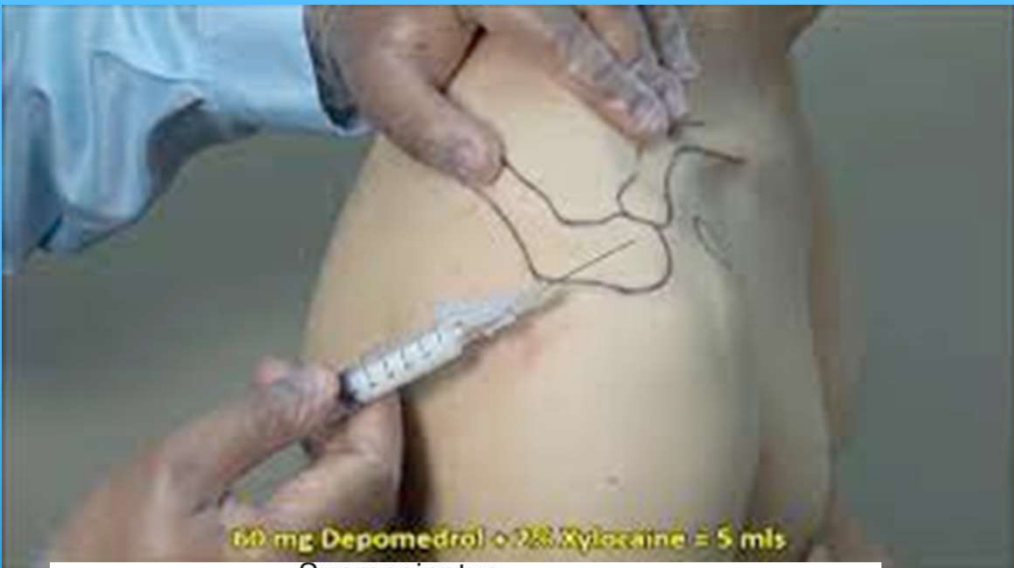Patient Education: Provide with post injection instructions, typically will provide pressure dressing for 48 hours to reduce symptoms from returning.





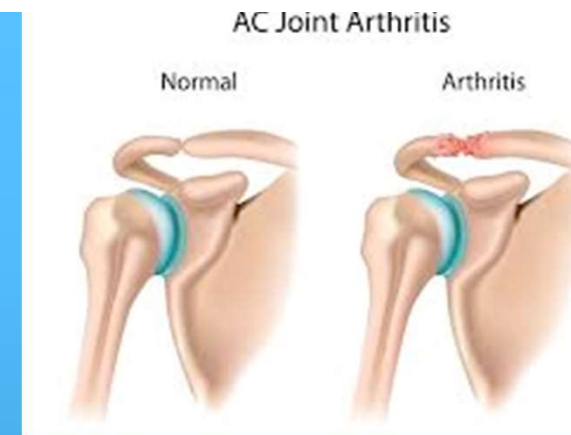
Shoulder – Anterior Approach





Acromioclavicular Joint

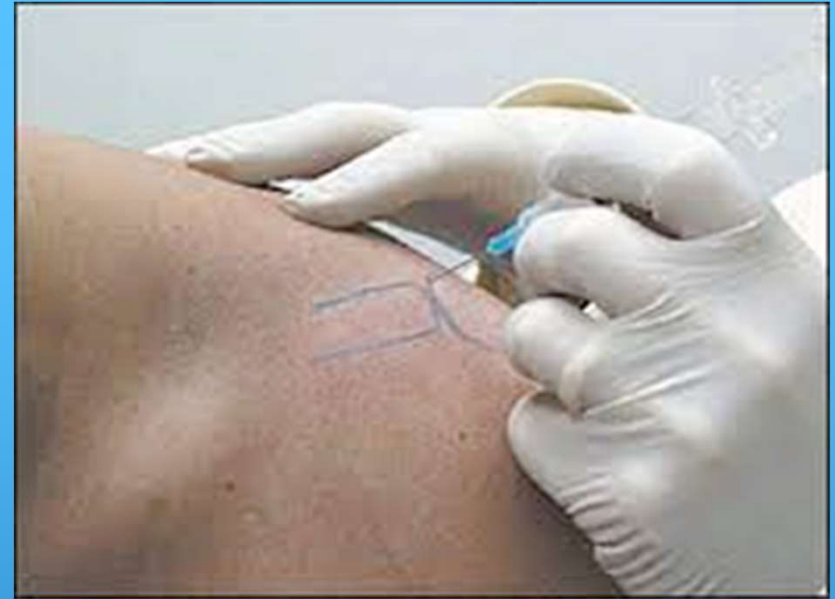- Diarthrodial joint that connects the acromion to the distal clavicle
- AC ligament is weak and provides little joint stability, coracoclavicular ligament provides the major structural support for the joint.
- Indications for injection:
 - Osteolysis - typically seen secondary to trauma or repetitive weight training
 - Osteoarthritis - typically develops secondary to previous trauma or injury
- Tenderness to palpation over the AC joint, pain with active or passive adduction.
- In some cases can be difficult to differentiate and may require diagnostic lidocaine injection.

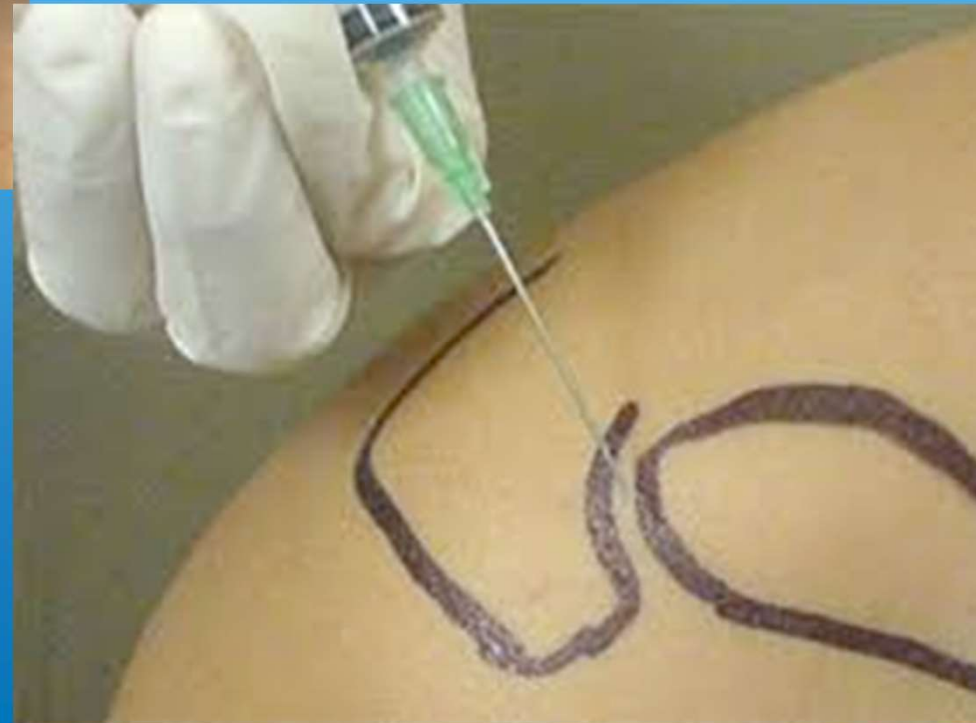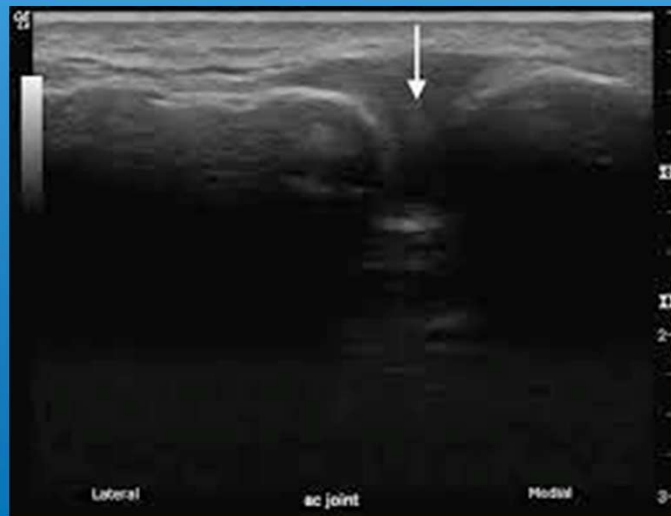

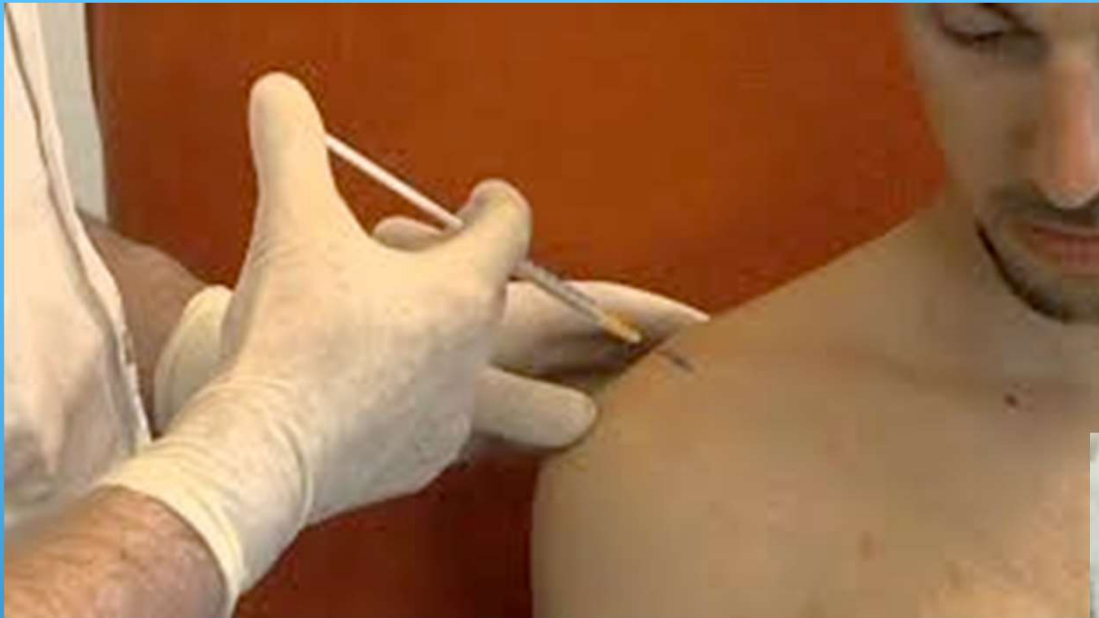
Acromioclavicular Joint

- Technique

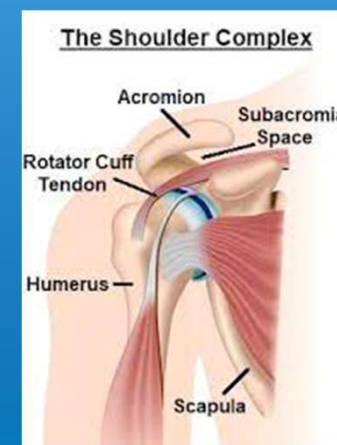
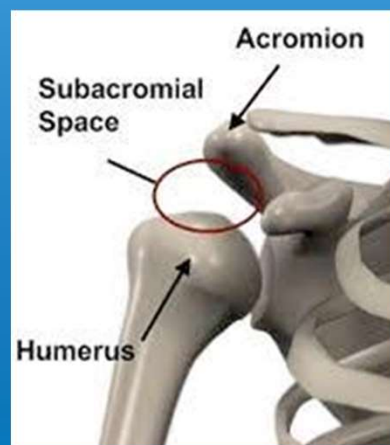
- Patient is in supine or seated position with arm at the side
- Palpate the clavicle distally to its endpoint at which point a slight depression will be felt at the joint articulation.
- The needle is inserted from superior and anterior approach into the AC joint and directed inferiorly.





Subacromial Space

- Subacromial space is defined by the acromion, sub deltoid bursa, coracoacromial ligament, and supra-spinatus tendon.
- The shape of the acromion affects the subacromial space and is a contributor to impingement syndrome (rotator cuff syndrome). Can often perform injection to improve pain control and allow patient to participate in PT.
- Can also use injection to differentiate shoulder weakness caused by impingement (shoulder strength improves after injection) and a true rotator cuff tear (no change in strength is noted following injection)
 - The susceptibility to impingement syndrome increases as the degree of curve in the acromion increases.
- Indications
 - Subdeltoid bursitis
 - Rotator cuff impingement
 - Rotator cuff tendinosis
 - Adhesive capsulitis



Subacromial Space

Patient Position: Patient is sitting with arm resting comfortably at the side, maybe even hanging down for a little traction

Landmarks: Lateral and posterior lateral corner of the acromion, AC joint

Tissue to Avoid: Humeral head and rotator cuff tendon

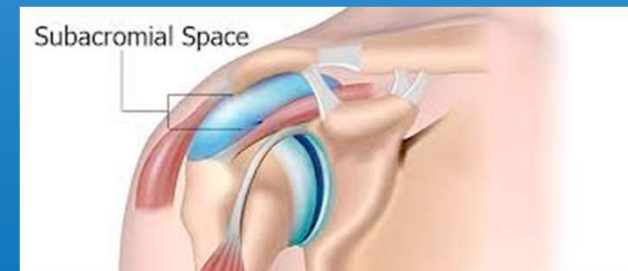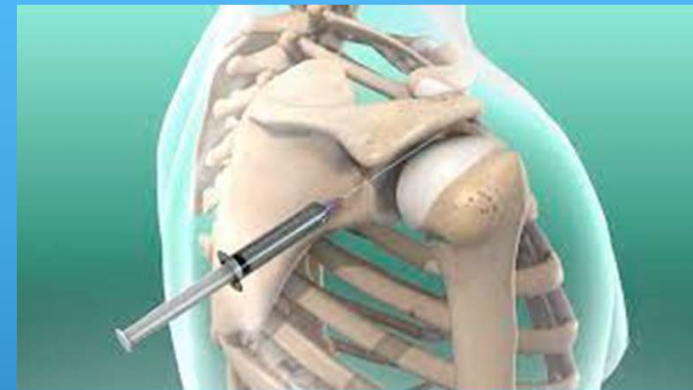Prep: Chlorhexidine/Betadine/alcohol wipe, can use topical ethylchloride

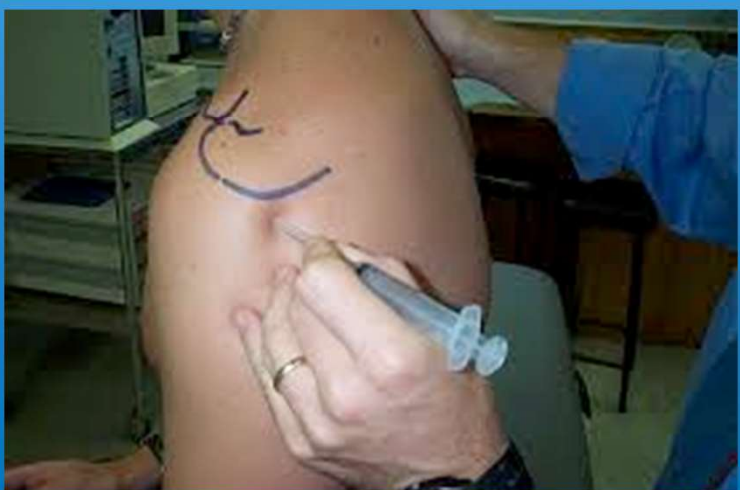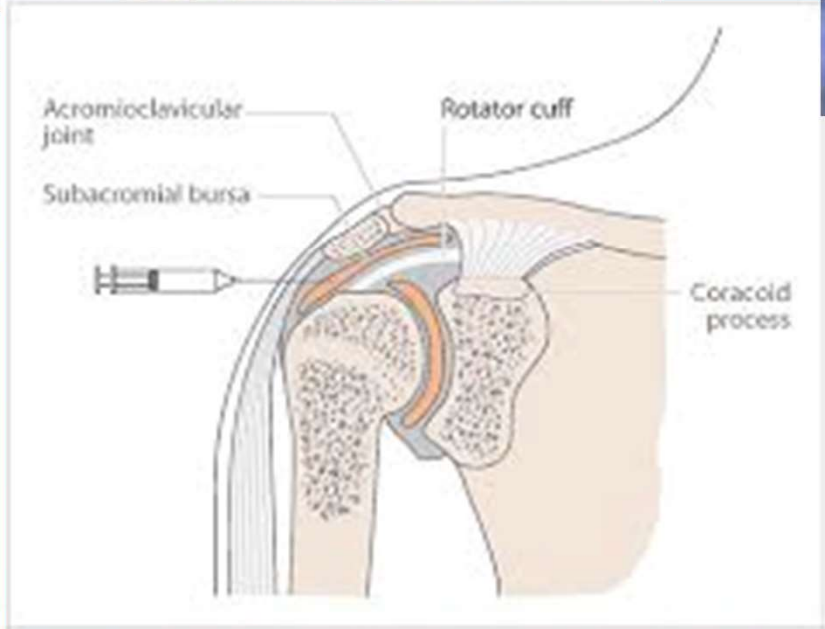
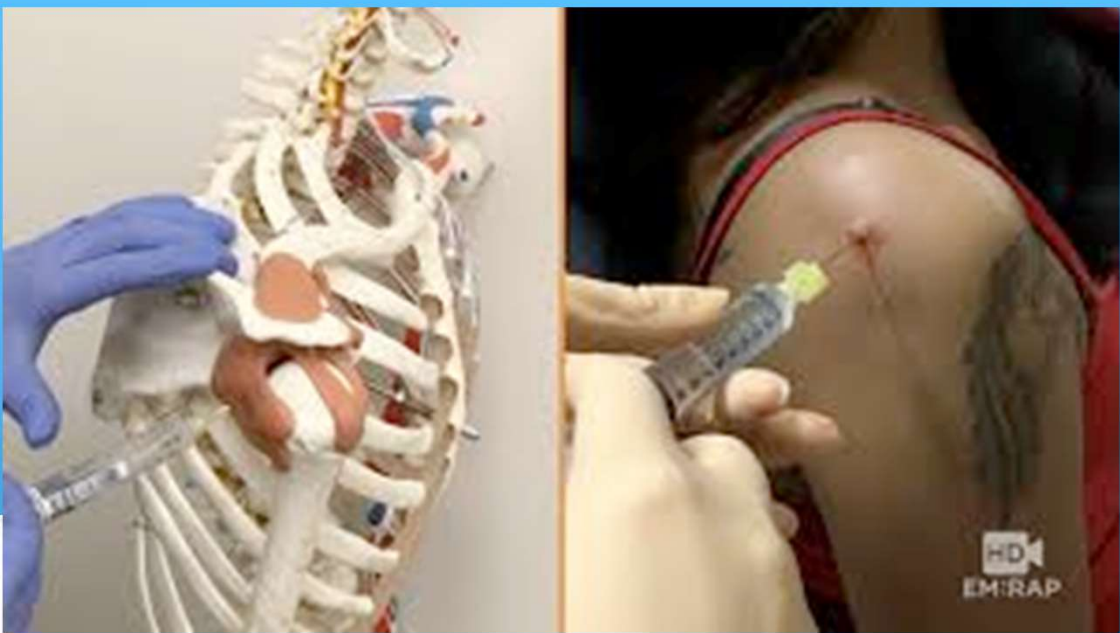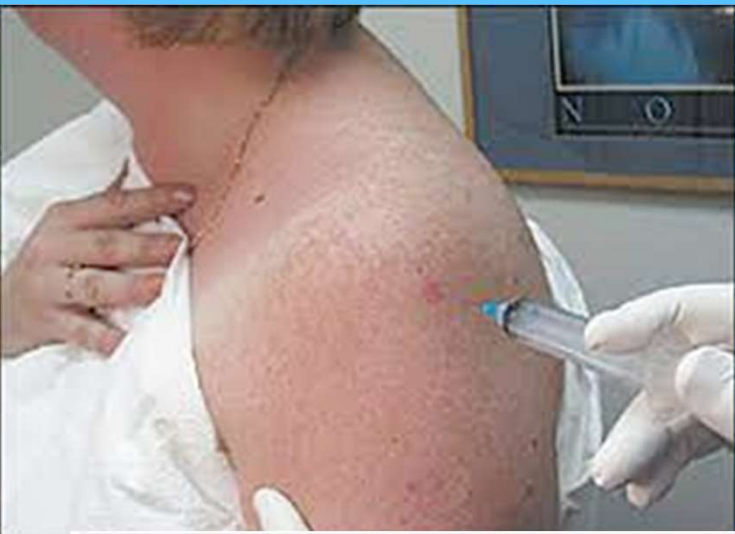Needle Insertion: Mark area with pen or needle cap, 25g 1.5" needle thru anesthetized skins, Direct lateral - Insert needle 2cm below the lateral acromion border and over the humeral head with slight superior angle. Posterior lateral - Insert needle 2-3cm inferior to the posterior lateral corner of acromion, direct anteriorly with 10 degree upward angle. If after aspiration there is resistance then may be within the rotator cuff tendons, withdraw and angle more superiorly.

Injection: Alone or mixture of 2-4ml 1% lidocaine and 0.5% Bupivacaine, Selected corticosteroid.

Observe patient: Watch for vaso-vagl reaction, rub area of injection to reduce pain, discuss with patient improvement of symptoms from local anesthetic. Direct lateral tends to have more frequent post injection pain and can be intramuscular.

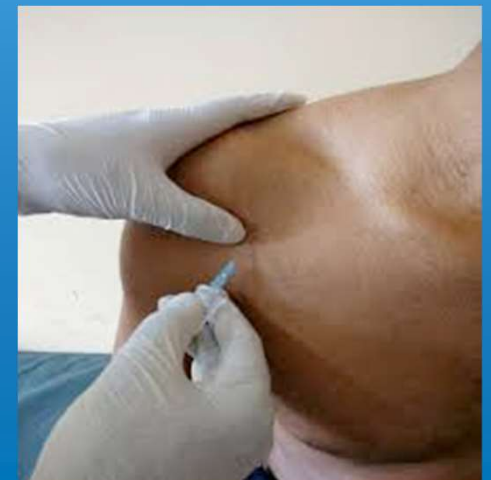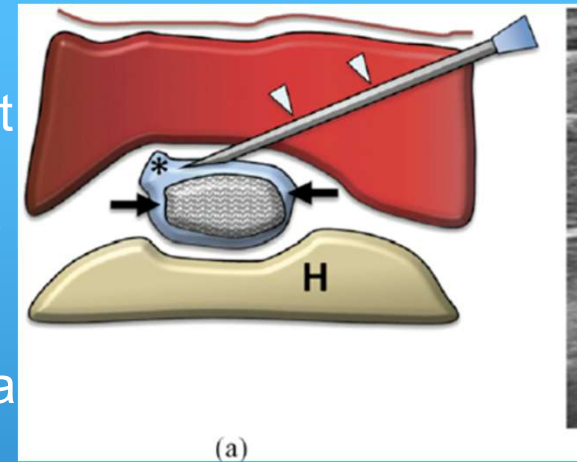
Patient Education: Provide with post injection instructions





Long head of Biceps Tendon sheath injection

- The long head of the biceps muscle has a proximal insertion at the glenoid where the tendon is intra-articular, held within the proximal bicipital groove by the coracohumeral and transverse humeral ligaments.
- Repetitive shoulder motion can cause inflammation in this area that can often lead to anterior shoulder pain.
- Patient typically has anterior shoulder pain, tenderness to palpation of the bicipital groove, positive speeds test.
- This is often best done under ultrasound guidance to avoid direct injection into the tendon which can cause complications including tendon rupture.



Long head of Biceps Tendon sheath injection

Patient Position: Patient is seated with arm at the side, elbow flexed, wrist in supination, possible slight external rotation of the shoulder.

Landmarks: Humeral head, bicipital groove, find point of maximal tenderness

Tissue to Avoid: Long head of biceps tendon

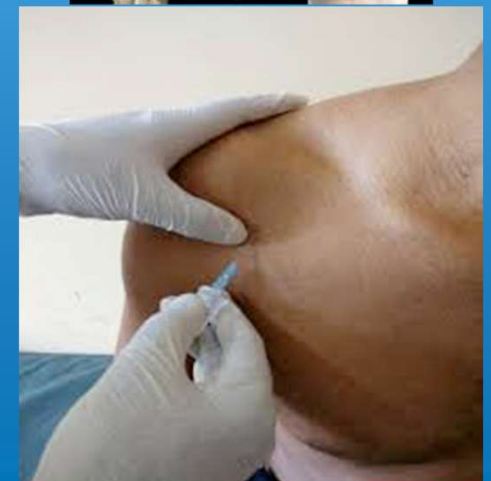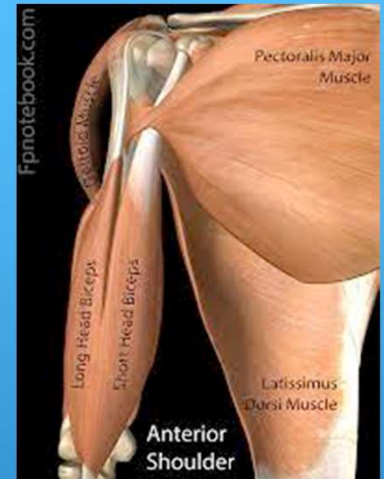
Prep: Chlorhexidine/Betadine/alcohol wipe, can use topical ethylchloride

Needle Insertion: Mark area with pen or needle cap, insert 25g 1.5" needle thru anesthetized skins, into the area of maximal tenderness at 20-30 degrees angle, if you feel resistance to injection, gritty/tough tissue sensation likely means you are in the tendon, retract 1-2mm and redirect at more shallow angle. Aspirate then inject.

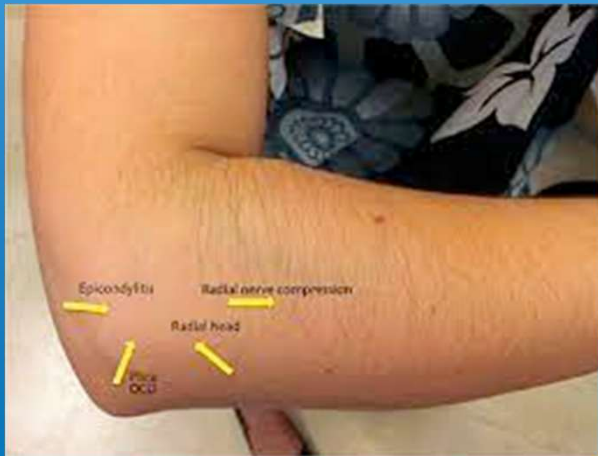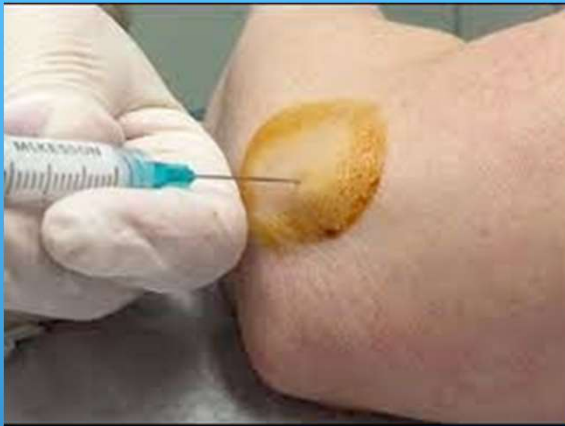Injection: Alone or mixture of 1-2ml 1% lidocaine and 0.5% Bupivacaine, Selected corticosteroid.

Observe patient: Watch for vaso-vagl reaction, rub area of injection to reduce pain, discuss with patient improvement of symptoms from local anesthetic.

Patient Education: Provide with post injection instructions.



Lateral Epicondylitis



- The lateral epicondyle is the site of origin of the wrist extensor/supinator muscle group. (ECRB)
- Chronic degenerative changes can occur at the tendon insertion due to repetitive activities such as tennis.
- Patient has failed all other treatments including PT, NSAID's, rest and ICE.
- Research has shown that corticosteroid injections yields a predictable short-term decrease in pain and is superior to NSAID's and PT.
- After six weeks however PT reduces symptoms more than injection. Therefore may consider more for patients who's symptoms limit PT participation.

Lateral Epicondylitis

Patient Position: Patient is seated in chair, with arm supported on exam table, elbow flexed to 45-90 degrees, , wrist pronated.

Landmarks: Radial head, lateral epicondyle, mark area of maximal tenderness.

Tissue to Avoid: None in this area

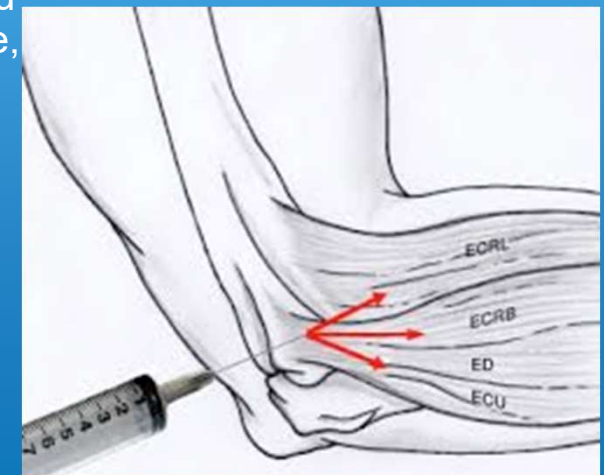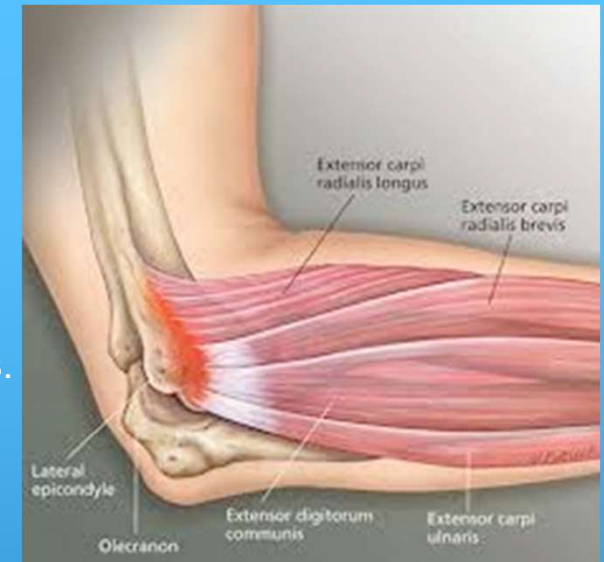Prep: Chlorhexidine/Betadine/alcohol wipe, can use topical ethylchloride

Needle Insertion: Mark area with pen or needle cap, insert 25g 1.5" needle thru anesthetized skins, into the area of maximal tenderness at 45-90 degree angle, caress the bone withdraw 1mm aspirate and inject.

Injection: Alone or mixture of 1-2ml 1% lidocaine and 0.5% Bupivacaine, Selected corticosteroid.

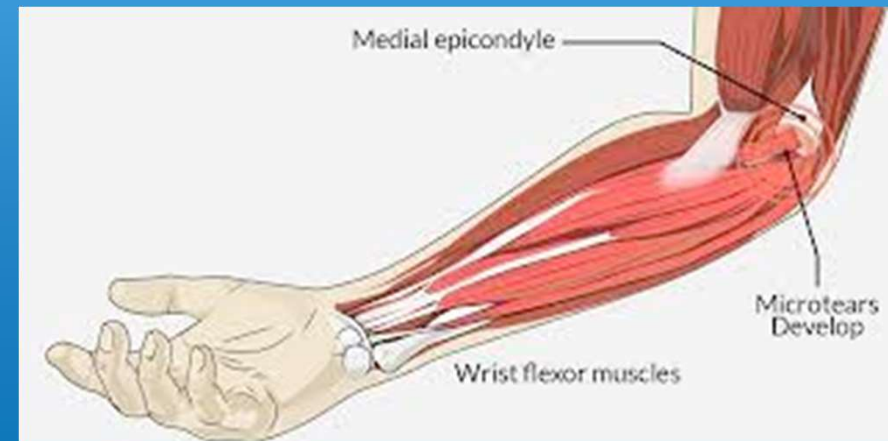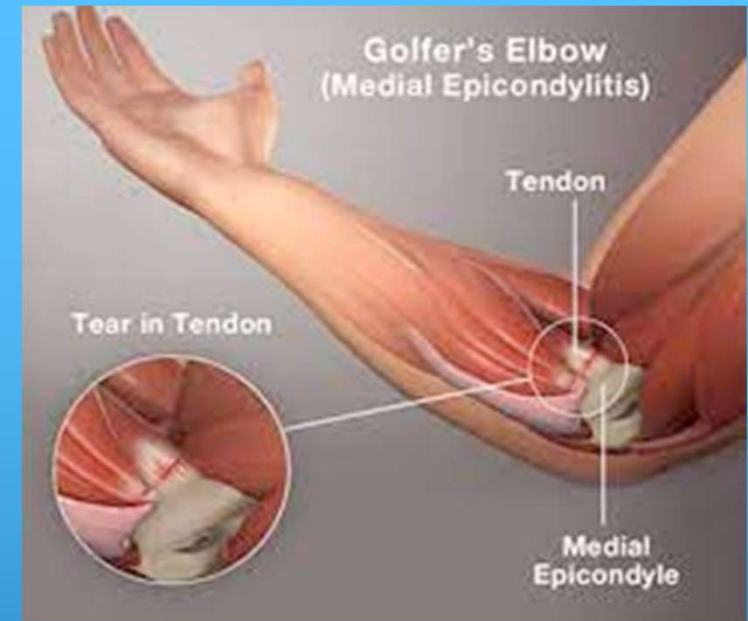Observe patient: Watch for vaso-vagl reaction, rub area of injection to reduce pain, discuss with patient improvement of symptoms from local anesthetic.

Patient Education: Provide with post injection instructions, discuss need for ICE, PT (tyler twist) exercise.

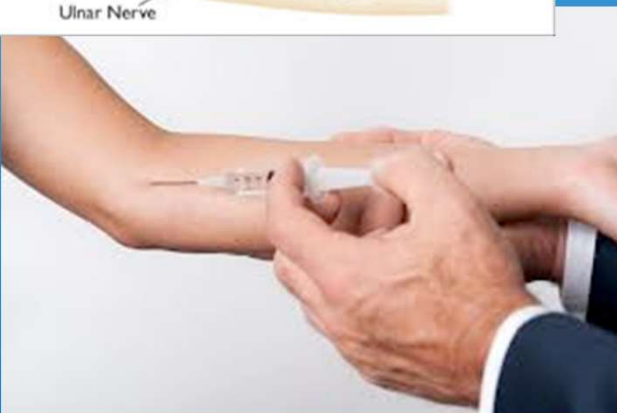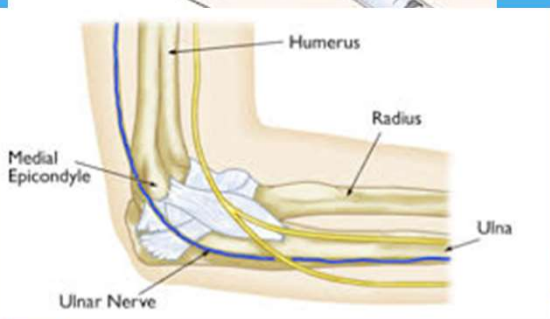

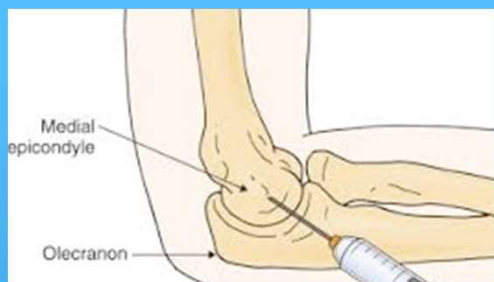
Medial Epicondylitis

- Medial epicondyle is the insertion of the flexor-pronator tendon. repetitive activity with forced wrist extension and forearm supination causes injury to this area, which it is commonly referred to as golfers elbow.
- Tenderness to palpation is noted near the wrist flexor insertion on the medial epicondyle.
- Less common than lateral epicondylitis.
- Pain is worse with restive wrist flexion and pronation.



Medial Epicondylitis



Patient Position: Patient is seated in chair, with arm supported on exam table, in full extension, abduction and supination

Landmarks: Medial epicondyle, mark area of maximal tenderness.

Tissue to Avoid: Ulnar nerve

Prep: Chlorhexidine/Betadine/alcohol wipe, can use topical ethylchloride

Needle Insertion: Mark area with pen or needle cap, insert 25g 1.5" needle thru anesthetized skins, into the area of maximal tenderness at 45-90 degree angle, caress the bone withdraw 1mm aspirate and inject.

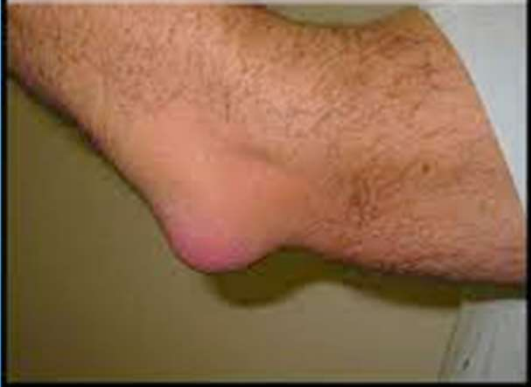Injection: Alone or mixture of 1-2ml 1% lidocaine and 0.5% Bupivacaine, Selected corticosteroid.

Observe patient: Watch for vaso-vagl reaction, rub area of injection to reduce pain, discuss with patient improvement of symptoms from local anesthetic.

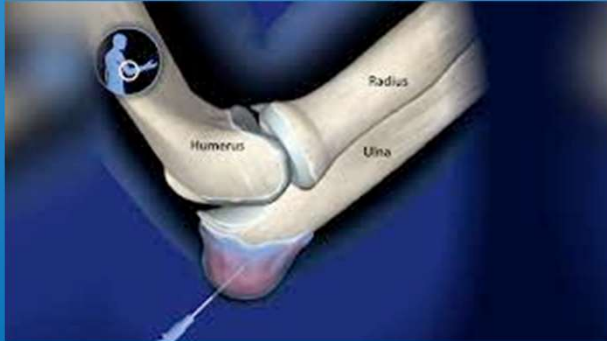Patient Education: Provide with post injection instructions, discuss need for ICE, PT exercise.

Olecranon Bursitis

TREATMENT ALGORITHM FOR OLECRANON BURSTITIS



- Commonly occurs after repetitive trauma to the elbow or in patients with rheumatoid or crystalloid arthritis.
- Exam shows a swollen, fluid-filled sac over the olecranon. Typically this is painless.
- If pain is present with redness, warmth and possible drainage may be a sign of infection in the bursa, this is frequently caused by staph aureus.
- Aspiration can be performed with or without signs of infection, if infection present corticosteroid injection should not be performed.



Olecranon Bursitis

Patient Position: Patient is sitting or supine with elbow flexed as much as comfortable, flexion allows for easier aspiration.

Landmarks: Lateral and Medial epicondyles, olecranon process

Tissue to Avoid: Ulnar nerve

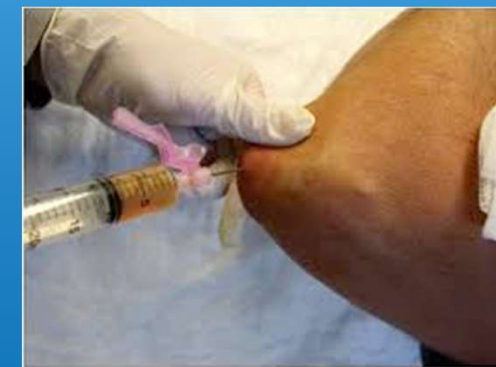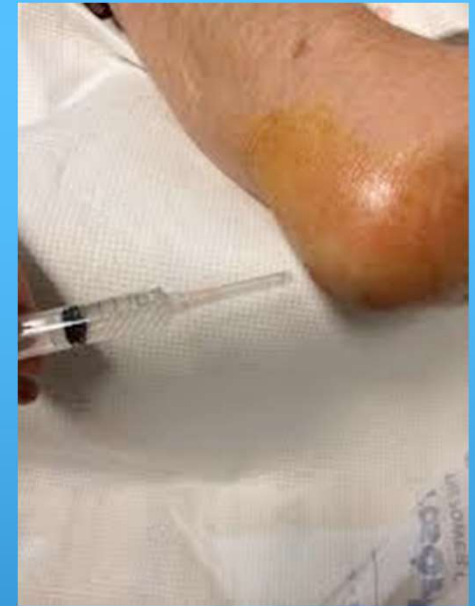Prep: Chlorhexidine/Betadine/alcohol wipe, can use topical ethylchloride

Needle Insertion: Mark area with pen or needle cap, insert 18-20g 1.5" needle thru anesthetized skin, directly into the bursa with aspiration performed. If no infection is suspected can hold needle with hemostat, change syringe and inject local with steroid.

Injection: Alone or mixture of 1-2ml 1% lidocaine and 0.5% Bupivacaine, Selected corticosteroid.

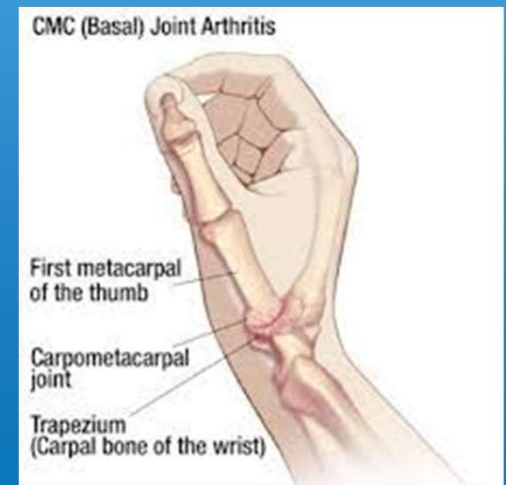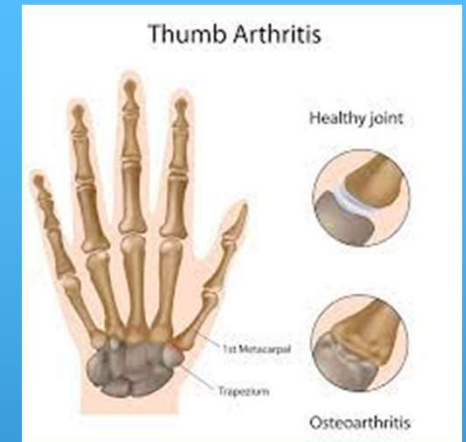Observe patient: Watch for vaso-vagl reaction, rub area of injection to reduce pain, discuss with patient improvement of symptoms from local anesthetic.

Patient Education: Provide with post injection instructions, typically will provide pressure dressing for 48 hours to reduce symptoms from returning.



First Carpometacarpal (CMC) OA

- Thumb is a saddle-shaped surface that articulates with the trapezium
- Typically has limited motion and tenderness to palpation, with possible crepitus in the joint.
- Due to overuse from repetitive pinching and gripping activities
 - Most often seen in women between 40-70 y/o
- Pain is noted to worsen with compression and rotation of the joint



First Carpometacarpal (CMC) Injection

Patient Position: Patient is seated in chair, with arm supported on exam table

Landmarks: Joint space between the trapezium and the 1st metacarpal, mark area of maximal tenderness.

Tissue to Avoid: Radial artery

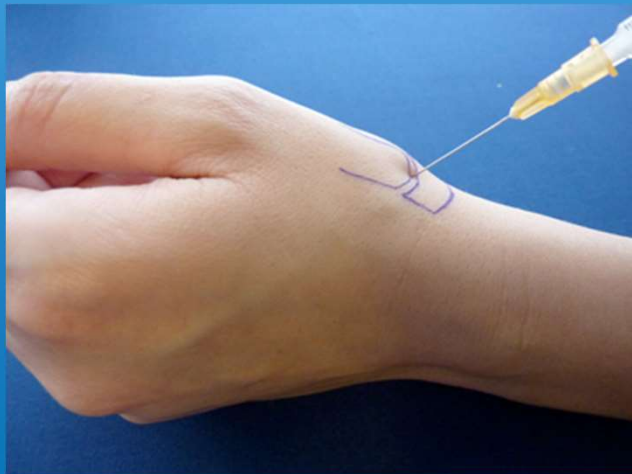
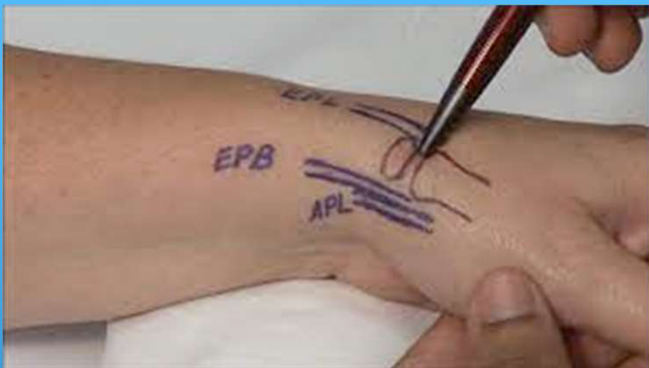Prep: Chlorhexidine/Betadine/alcohol wipe, can use topical ethylchloride

Needle Insertion: Mark area with pen or needle cap, insert 25g or 30g 1/2" needle thru anesthetized skins, Should enter just proximal to the 1st CMC joint on the extensor surface toward the dorsal (ulnar) side of the extensor polices braves tendon. The needle should fall into the joint space, may apply traction to open the joint space.

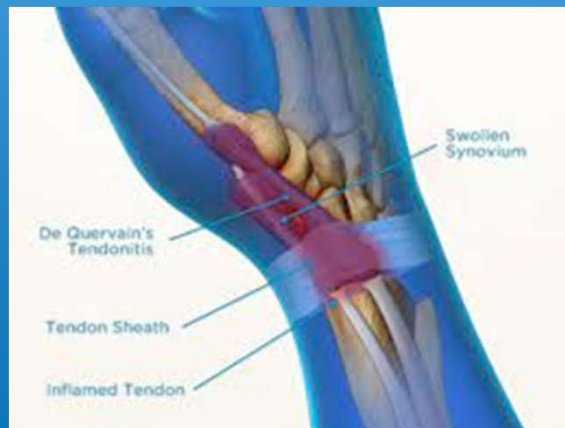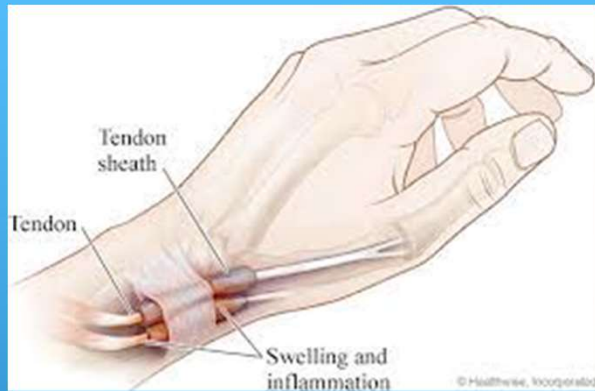Injection: Alone or mixture of 1-2ml 1% lidocaine and 0.5% Bupivacaine, Selected corticosteroid.

Observe patient: Watch for vaso-vagl reaction, rub area of injection to reduce pain, discuss with patient improvement of symptoms from local anesthetic.

Patient Education: Provide with post injection instructions



De Quervain's Tenosynovitis



- Stenosing tenosynovitis that involves the abductor pollicis longus and extensor pollicis brevis tendons.
- Typically occurs secondary to repetitive use of the thumb
- Tenderness and thickening is noted of the tendon sheath just distal to the radial styloid process, in the first dorsal compartment
- Finkelstein test is positive, this test can give false positive and should be compared to the opposite side
- Patient has failed immobilization and NSAID's use

De Quervain's Tenosynovitis

Patient Position: Patient is seated in chair, with arm supported on exam table

Landmarks: Anatomical snuff box created by extensor polices brevis and abductor polices longus

Tissue to Avoid: Radial artery, sensory branch of the radial nerve

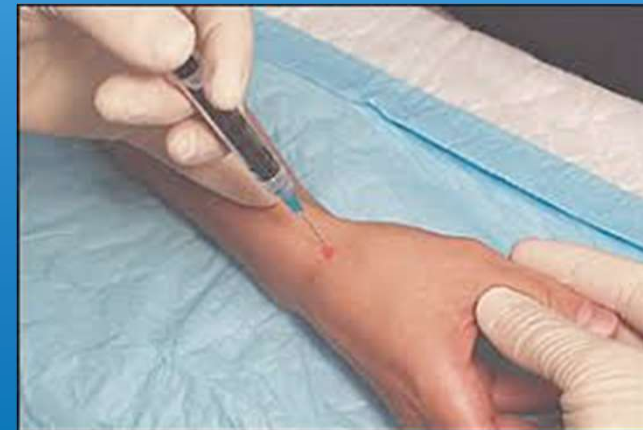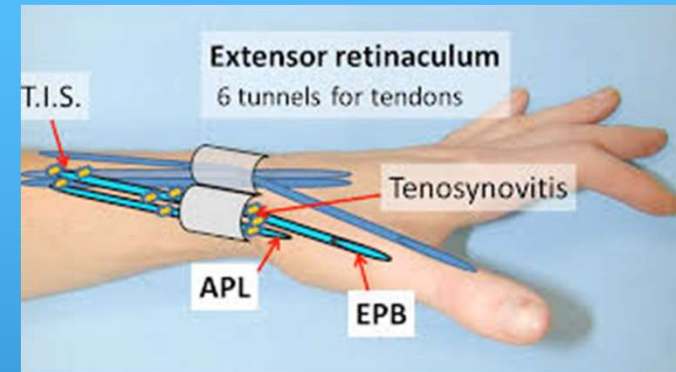
Prep: Chlorhexidine/Betadine/alcohol wipe, can use topical ethylchloride

Needle Insertion: Mark area with pen or needle cap, insert 25g or 30g 1/2" needle thru anesthetized skins, at 45 degree angle into the first dorsal compartment parallel to EPB and ABL. Do not inject directly into tendon.

Injection: Alone or mixture of 1-2ml 1% lidocaine and 0.5% Bupivacaine, Selected corticosteroid.

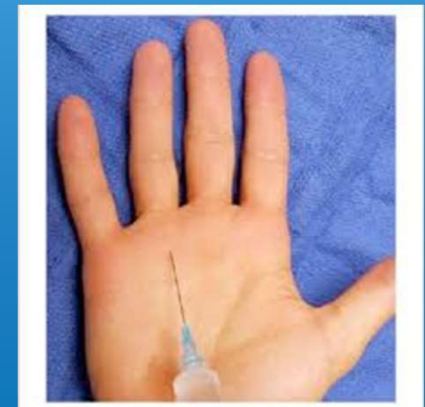
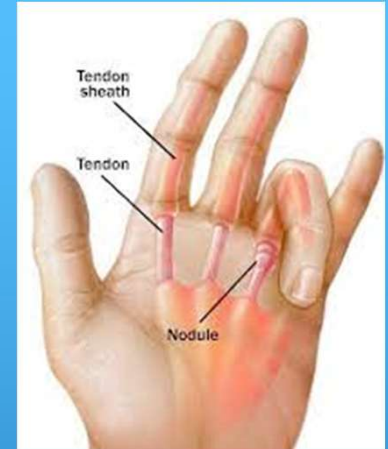Observe patient: Watch for vaso-vagl reaction, rub area of injection to reduce pain, discuss with patient improvement of symptoms from local anesthetic.

Patient Education: Provide with post injection instructions

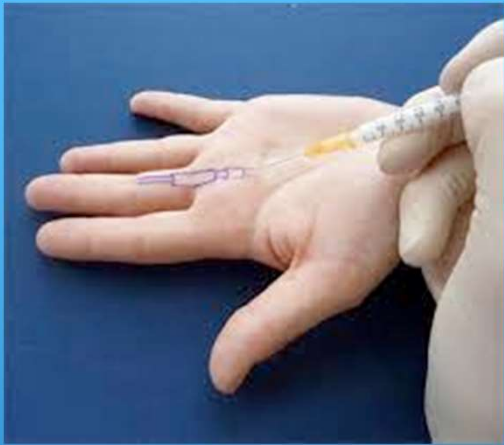

Trigger Finger injection

- Tenosynovitis of the flexor tendon of the hand
- Tendon cannot glide within its sheath due to thickening or nodule that catches at the first annular pulley. Ring finger is the most common, in dominant hand.
- Prevents smooth extension or flexion of the finger. Will complain of catching or locking with movement of finger, and pain with gripping activities.
- Common in patient with RA, DM, hypothyroidism or repetitive injuries
- Injection can be first line treatment for this.



Trigger Finger injection



Patient Position: Patient is seated in chair, with arm supported on exam table in supinated position

Landmarks: Distal Palmar crease, may palpate for tender or swollen nodule

Tissue to Avoid: Digital neuromuscular bundle

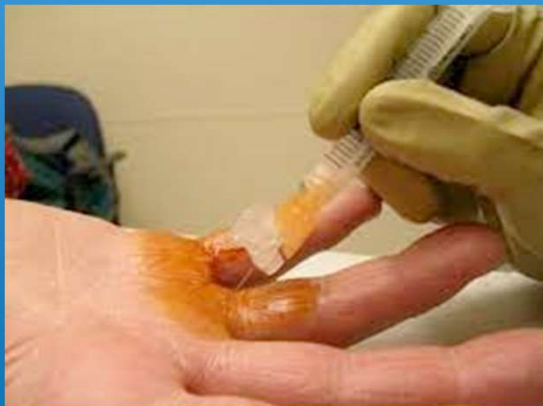Prep: Chlorhexidine/Betadine/alcohol wipe, can use topical ethylchloride

Needle Insertion: Mark area with pen or needle cap, insert 25g or 30g 1/2" needle thru anesthetized skins, over the palmar aspect of the distal metacarpal head at a 30 degree angle directed proximally. Can ask the patient to move the finger and needle should not move, if movement of needle is noted should retract 1mm. Aspirate and Inject.

Injection: Alone or mixture of 1-2ml 1% lidocaine and 0.5% Bupivacaine, Selected corticosteroid.

Observe patient: Watch for vaso-vagl reaction, rub area of injection to reduce pain, discuss with patient improvement of symptoms from local anesthetic.

Patient Education: Provide with post injection instructions

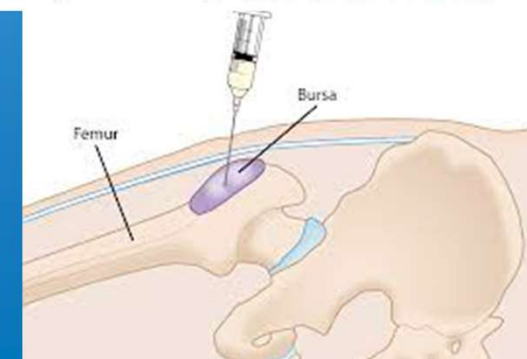
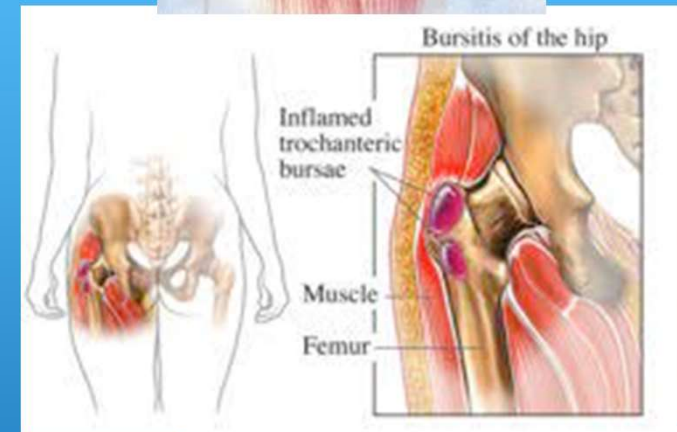
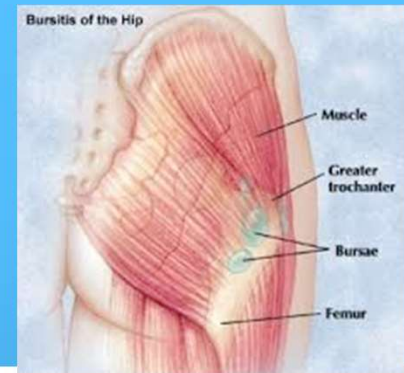

MSK Injections

- Lower Extremity
 - Trochanteric bursitis
 - Pes Anserine bursitis
 - Knee joint injection and aspiration
 - Plantar fasciitis
 - Morton's Neuroma

Trochanteric Bursitis

- Second leading cause of hip pain in adults
- Lateral hip pain is often referred to as greater trochanteric pain syndrome, which most often originates from gluteal medius and minimus tendinopathy, sometimes associated with bursitis.
- The deep bursae lie between bone and overlying tendons.
- Bursitis of the deep bursa rarely is associated with visible swelling or erythema.
- Most common affected trochanteric bursae are the sub gluteus maximus bursa (multiloculated, lies between the greater trochanter and the gluteus maximus tendon) and the bursae between the greater trochanter and gluteus medius and minimus tendons.



Trochanteric Bursitis

Patient Position: Patient is placed lying laterally on the unaffected side, the affected leg is slightly flexed and adducted to move the lateral muscles away from the greater trochanter.

Landmarks: Greater trochanteric process, Find the point of maximal tenderness

Tissue to Avoid: No important neuro/vascular structures

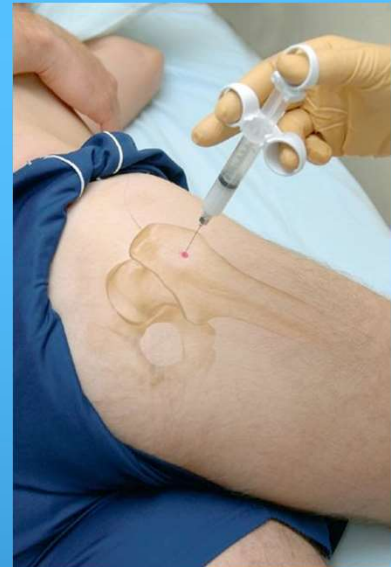Prep: Chlorhexidine/Betadine/alcohol wipe, can use topical ethylchloride

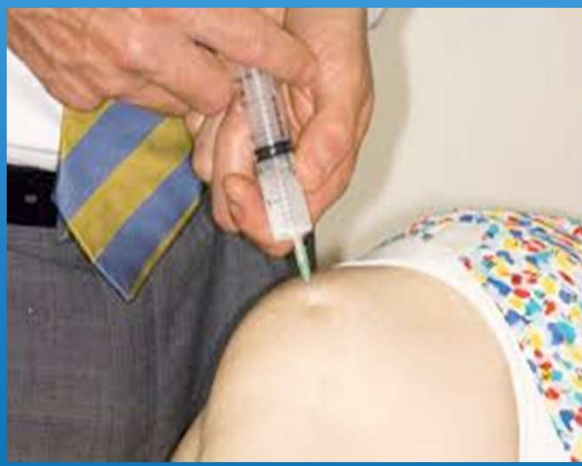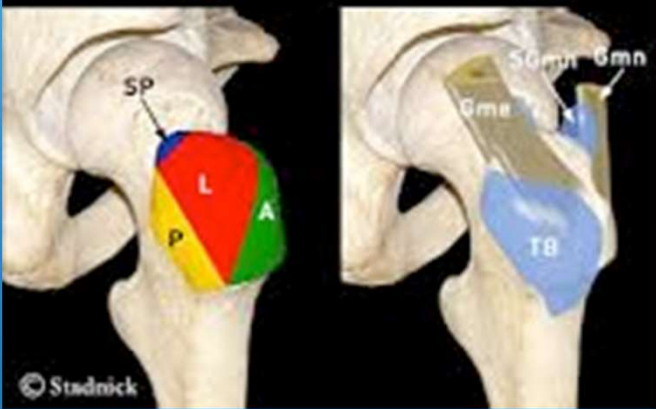
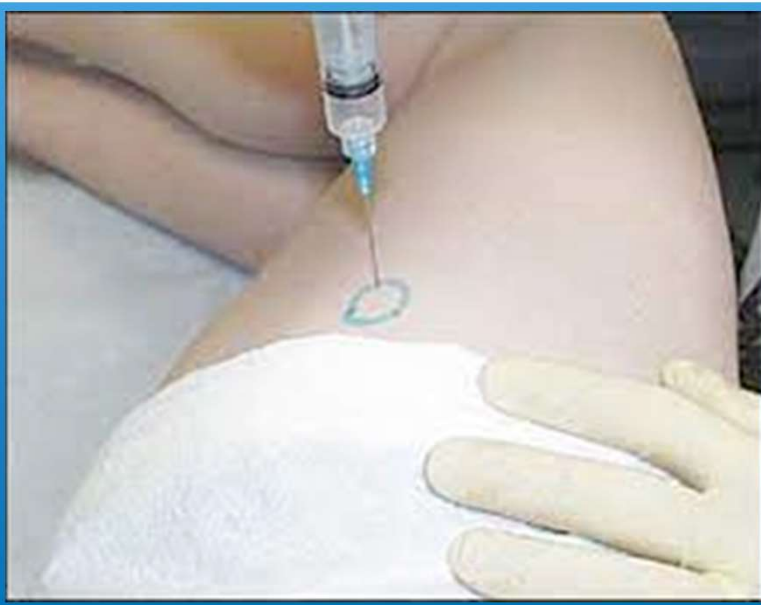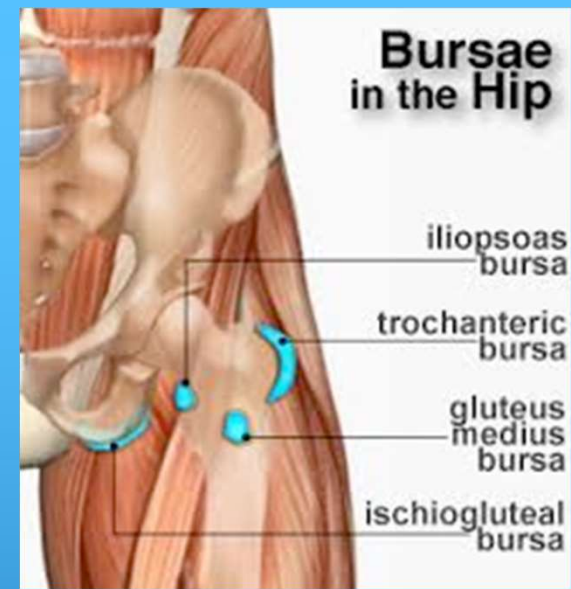
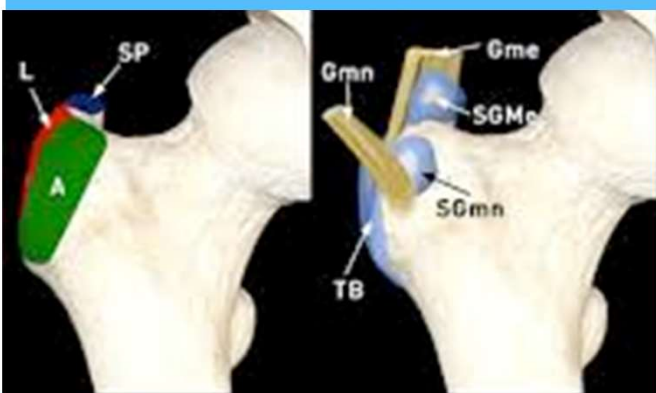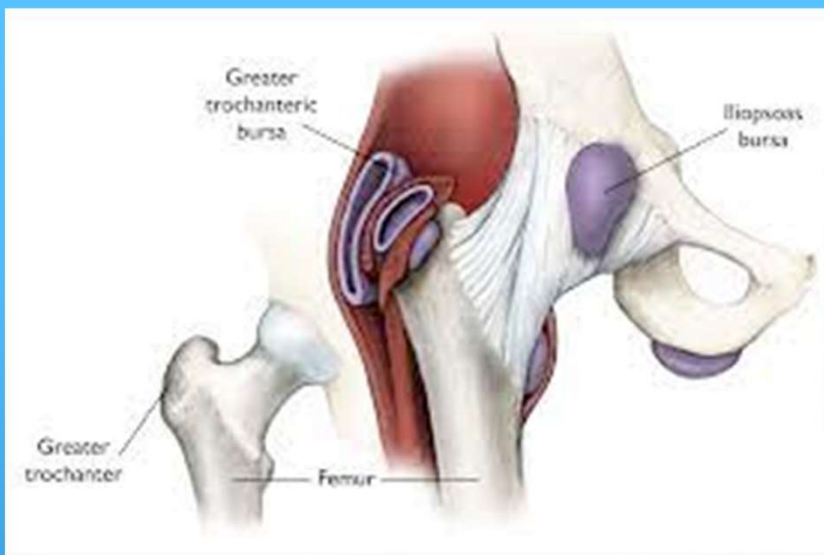
Needle Insertion: Can mark area of maximal tenderness with pen or needle cap, 22-25 g 1.5-3.5 inch needle, perpendicular to the skin, at the location of maximal tenderness, caress the bone then withdraw 1-3mm, should flow easily.

Injection: Alone or mixture of 2-4ml 1% lidocaine and 0.5% Bupivacaine, Selected corticosteroid.

Observe patient: Watch for vaso-vagl reaction, rub area of injection to reduce pain, discuss with patient improvement of symptoms from local anesthetic.

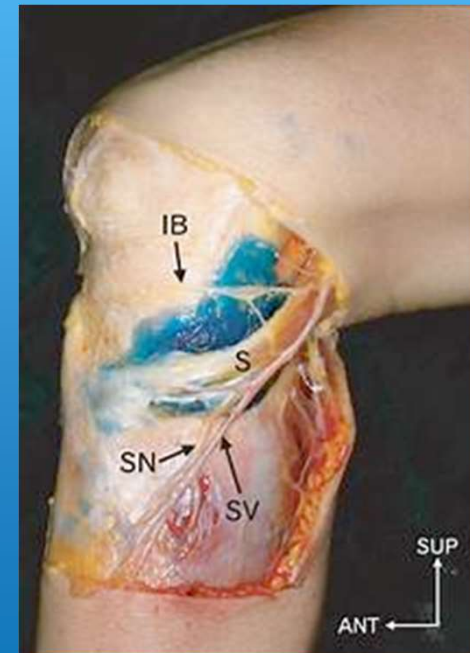
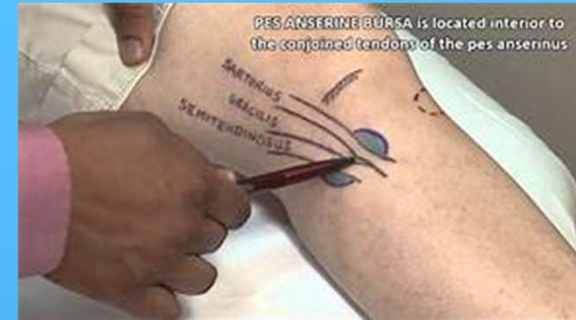Patient Education: Reinforce ICE, NSAID's, and stretching, with post injection instructions and follow up, Can sometime consider second injection >3 weeks after first if patient does not have complete symptom relief.



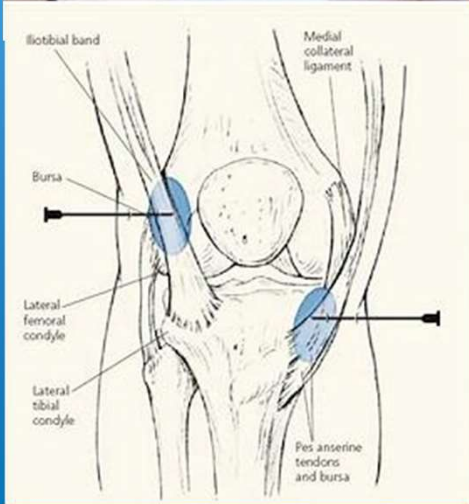
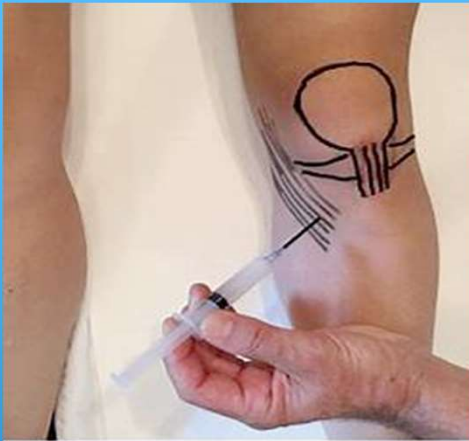

Pes Anserine Bursitis

- Commonly seen in patient complaining of medial knee pain, likely due to mechanical overload of the tendons on the medial side of the knee.
- Conjoined insertion of the sartorial, gracilis, and semitendinosus.
- Much like trochanteric bursitis, this is often associated with tendinopathy with possible underlying bursitis.
- Typically causes pain on the inside of the knee during running or taking stairs. May experience spontaneous anteromedial knee pain on climbing or descending stairs. There may be some swelling of tenderness to palpation 2 inches below the knee pain, at the proximal medial flare.



Pes Anserine Bursitis



Patient Position: Patient is placed lying supine with knee bent to 90 degrees, or sitting with knee hanging over table bent at 90 degrees

Landmarks: Point of maximal tenderness located over bursa typically located 2" below medial joint line and medial to tibial tubercle.

Tissue to Avoid: No important neuro/vascular structures

Prep: Chlorhexidine/Betadine/alcohol wipe, can use topical ethylchloride

Needle Insertion: Mark area with pen or needle cap, 22-25g 1.5-2" needle thru anesthetized skin perpendicular to point of maximal tenderness, caress bone and withdraw 1-3mm.

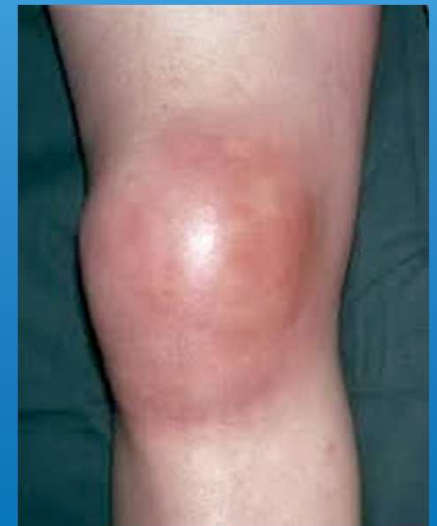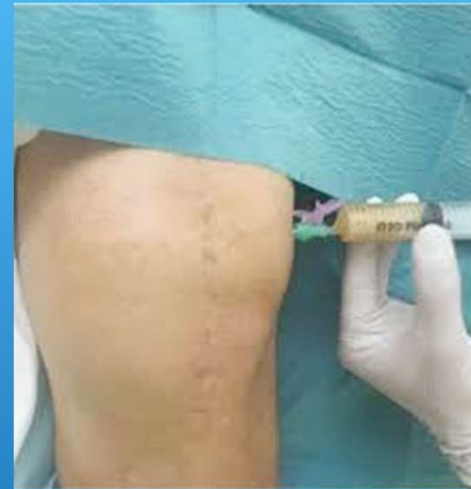Injection: Alone or mixture of 2-4ml 1% lidocaine and 0.5% Bupivacaine, Selected corticosteroid.

Observe patient: Watch for vaso-vagl reaction, rub area of injection to reduce pain, discuss with patient improvement of symptoms from local anesthetic.

Patient Education: Provide with post injection instructions

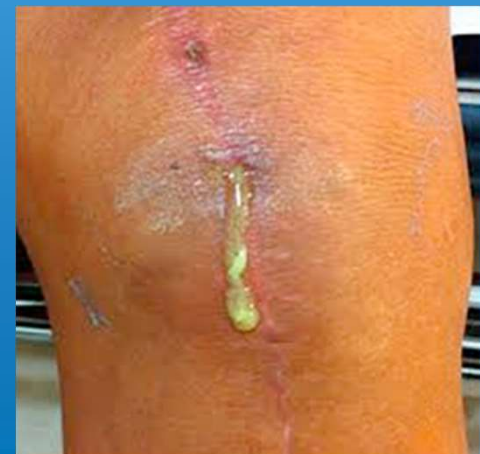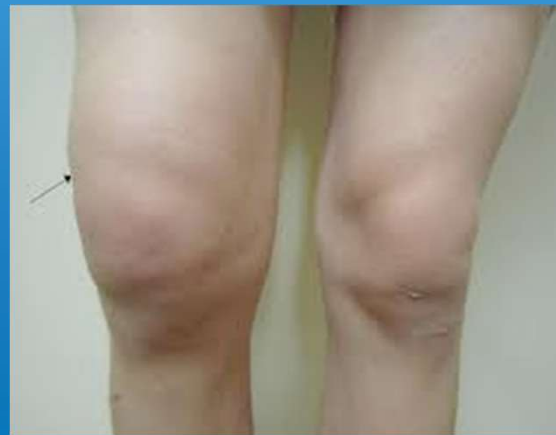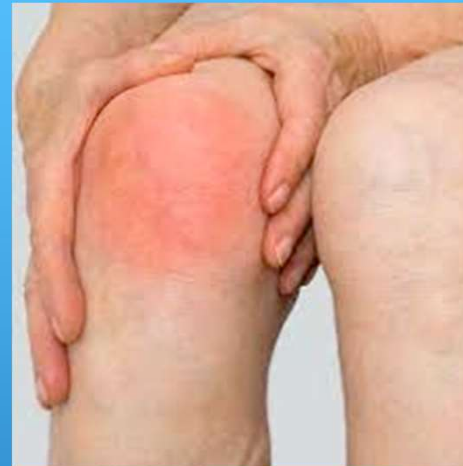Knee Joint Aspiration and Injection

- Performed to establish diagnosis, relieve discomfort, drain off infected fluid, or instill medication. May also help distinguish inflammatory arthropathies from crystal arthropathy or osteoarthritis.
- One of the easiest joints to inject or aspirate.
- Indications for Arthrocentesis:
 - Crystal-induced arthropathy
 - Hemarthrosis
 - Limiting joint damage from infectious process
 - Symptomatic relief of a large effusion
 - Unexplained joint effusion
 - Unexplained monoarthritis



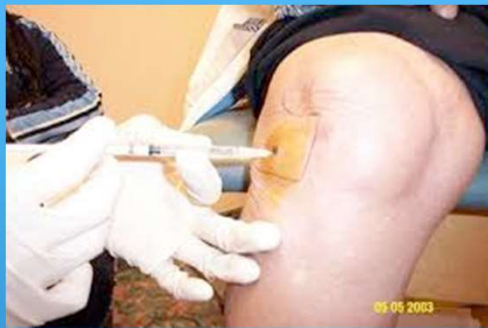Knee Joint Aspiration and Injection

- Contraindications to Intra-articular Injection :
 - Adjacent osteomyelitis
 - Bacteremia
 - Hemarthrosis
 - Impending joint replacement surgery (should wait 90 days)
 - Infectious arthritis
 - Joint prosthesis
 - Osteochondral fracture
 - Periarticular cellulitis
 - Poorly controlled diabetes mellitus



Knee Joint Aspiration and Injection

Technique for patient without a knee effusion



Patient Position: Patient is placed lying supine with knee bent to 90 degrees, or patient sitting with knee hanging over table bent to 90 degrees.

Landmarks: Inferior pole of patella, patellar tendon, medial or lateral tibial plateau and femoral condyle

Tissue to Avoid: Bone, patellar tendon, No important neuro/vascular structures

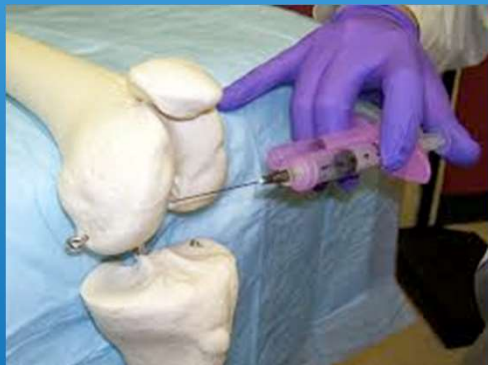Prep: Chlorhexidine/Betadine/alcohol wipe, can use topical ethylchloride

Needle Insertion: Mark area with pen or needle cap, Insert 22-25g 1.5" needle thru soft spot lateral to the patellar tendon, parallel to tibial plateau, aiming towards the intercondylar notch.

Injection: Alone or mixture of 2-4ml 1% lidocaine and 0.5% Bupivacaine, Selected corticosteroid.

Observe patient: Watch for vaso-vagl reaction, rub area of injection to reduce pain can go through passive ROM to disperse medication especially with HA injections

Patient Education: Provide with post injection instructions



Knee Joint Aspiration and Injection

Technique for patient with a knee effusion

Patient Position: Patient is placed lying supine with knee straight or slightly bent with pillow under it

Landmarks: Superior pole of the patella, lateral aspect of the patella, anterior cortex of femur

Tissue to Avoid: Bone, No important neuro/vascular structures

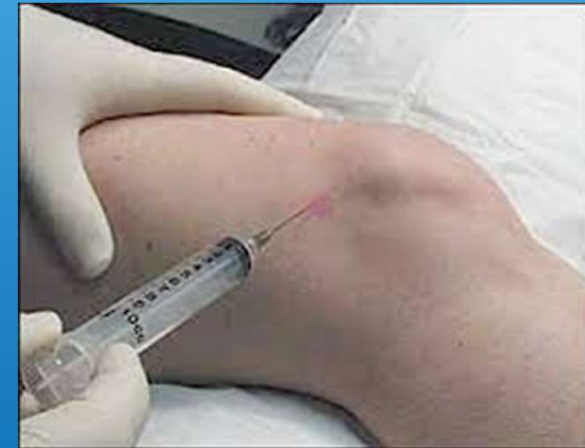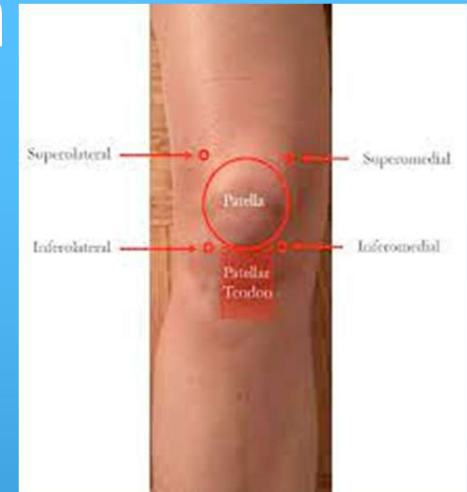Prep: Chlorhexidine/Betadine/alcohol wipe, can use topical ethylchloride

Needle Insertion: Mark area with pen or needle cap, 18-19g 1.5" needle insert thru anesthetized skin at the marked site which is 1cm above and 1cm lateral to the superior pole of patella, aiming 45 degrees distally towards the joint.

Injection: Alone or mixture of 2-4ml 1% lidocaine and 0.5% Bupivacaine, Selected corticosteroid.

Observe patient: Watch for vaso-vagl reaction, rub area of injection to reduce pain, discuss with patient improvement of symptoms from local anesthetic.

Patient Education: Provide with post injection instructions



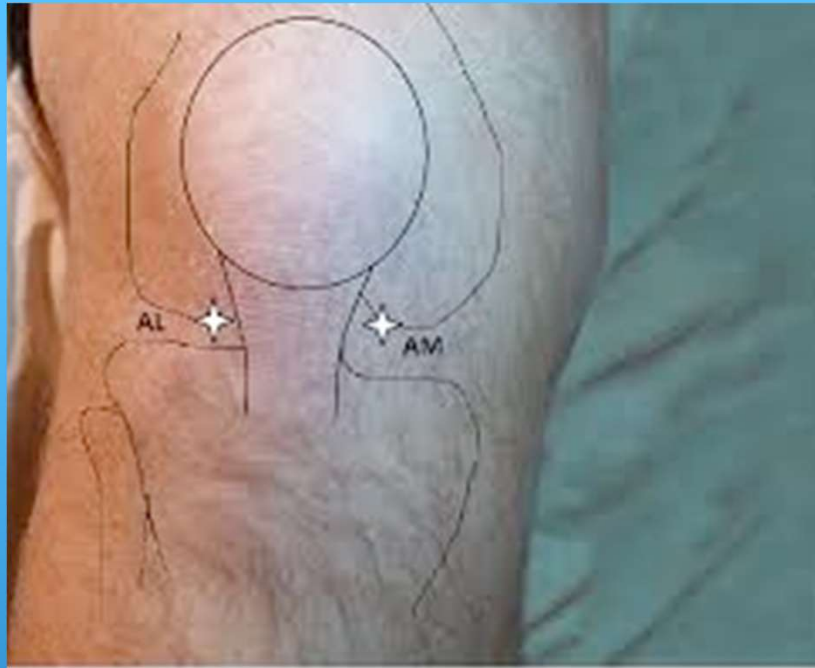
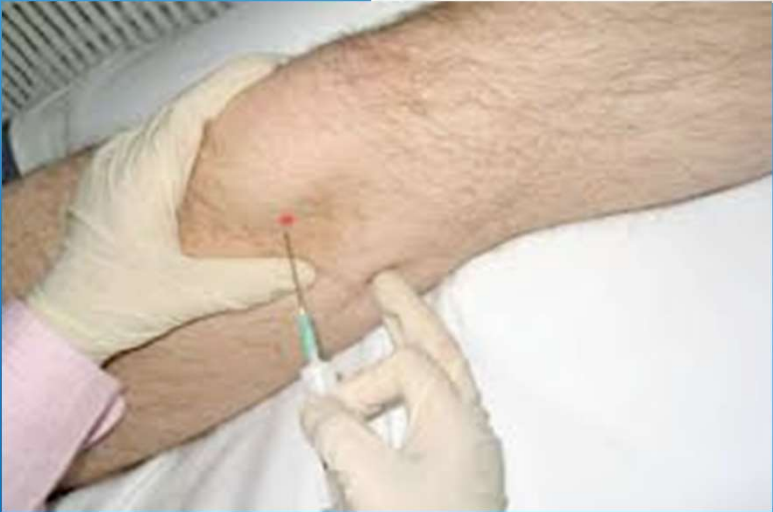
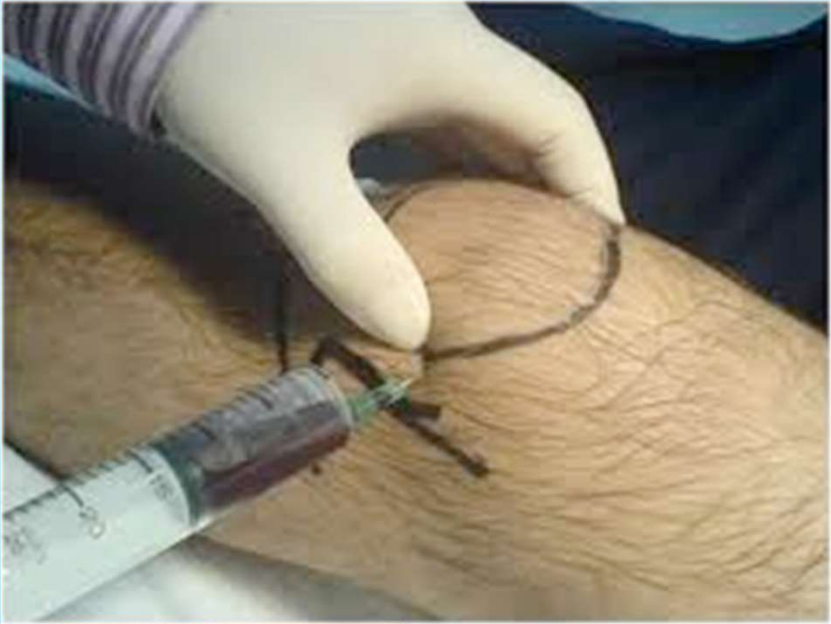Figure 1: Schematic representation Anterolateral (AL) and Anteromedial



Knee Joint Aspiration and Injection

- Common Complications:
 - Patient complains of sever pain. Typically as a result of coming into contact with highly innervated cartilaginous surface
 - Effusion was sterile, but became infected after injection. Introduction of infection is rare, occurring in less than 0.01% of injections
 - Patient complaints that the joint hurts after injection. If done through anterior later approach may have injected into fatpad, can inject lidocaine to reduce symptoms.
 - May also represent cortisone flare, caused by steroid crystals causing inflammatory reaction.
 - Large Effusion Re-accumulates - if only aspiration is performed not uncommon to rapidly re-accumulate. Often including Steroid injection to aspiration can reduce this if infection is not present. Can also place compressive dressing after aspiration for 48 hours.
 - Patient pain returns soon after injection. Major disadvantage is the possible short duration of action.

Pre Patellar Bursitis

Patient Position: Patient is placed lying supine with knee straight or sitting with knee hanging over table bent at 90 degrees

Landmarks: Pre Patella Bursa

Tissue to Avoid: No important neuro/vascular structures

Prep: Chlorhexidine/Betadine/alcohol wipe, can use topical ethylchloride

Needle Insertion: Mark area with pen or needle cap, 18-20g needle thru anesthetized skin into bursa aspirate and examine fluid, if no infection present can add steroid injection.

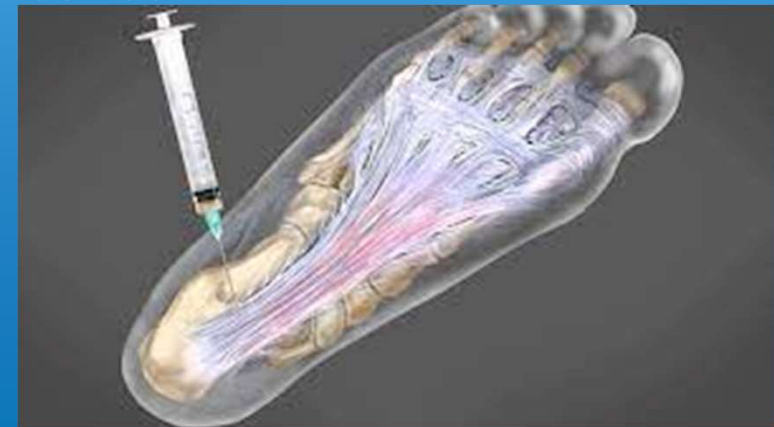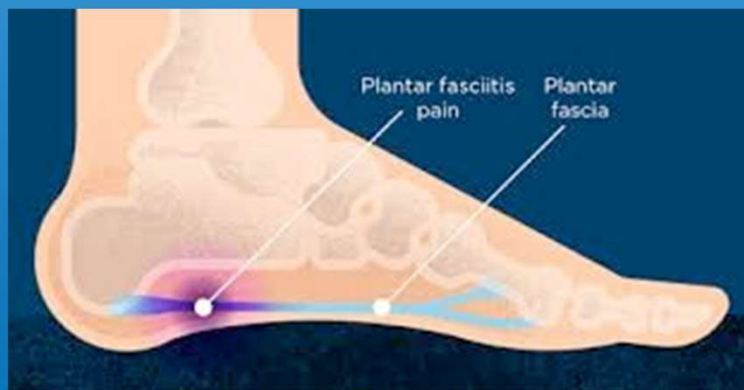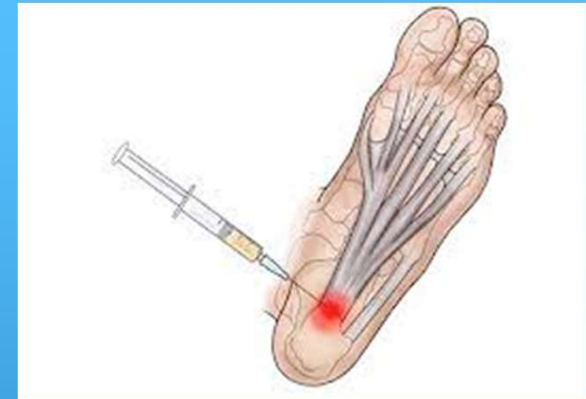Injection: Alone or mixture of 2-4ml 1% lidocaine and 0.5% Bupivacaine, Selected corticosteroid.

Observe patient: Watch for vaso-vagl reaction, rub area of injection to reduce pain, discuss with patient improvement of symptoms from local anesthetic.

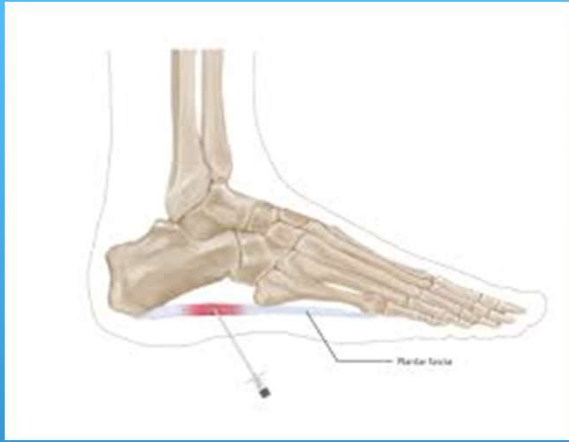
Patient Education: Provide with post injection instructions, typically will provide pressure dressing for 48 hours to reduce symptoms from returning.

Plantar Fasciitis

- Overuse injury that presents on the inside and/or bottom of the heel that is worse with the first few steps in the morning or after prolonged sitting.
- Pain can also increase when the toes are extended or passive dorsiflexion of the foot.
- Injection can be done with or without ultrasound guidance



Plantar Fasciitis



Patient Position: Patient is placed lying prone or lateral decubitus

Landmarks: Point of maximum tenderness, typically around the medial calcaneal tubercle, can be found easier with ankle dorsiflexion

Tissue to Avoid: No important neuro/vascular structures

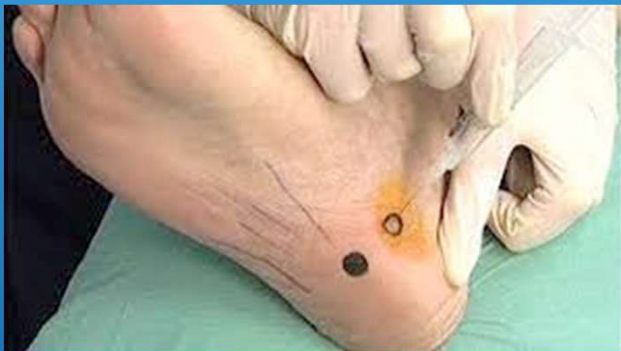Prep: Chlorhexidine/Betadine/alcohol wipe, can use topical ethylchloride

Needle Insertion: Mark area with pen or needle cap, insert 22-25g 1.5" needle thru anesthetized skin at the medial aspect of heel, aiming toward point of maximal tenderness if fascia (thick gritty sensation) or bone is felt with needle then withdraw 1-2mm

Injection: Alone or mixture of 2-4ml 1% lidocaine and 0.5% Bupivacaine, Selected corticosteroid.

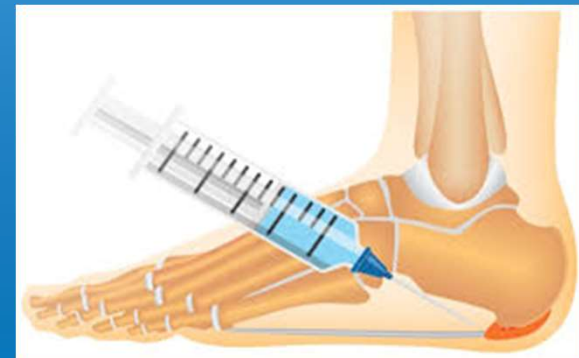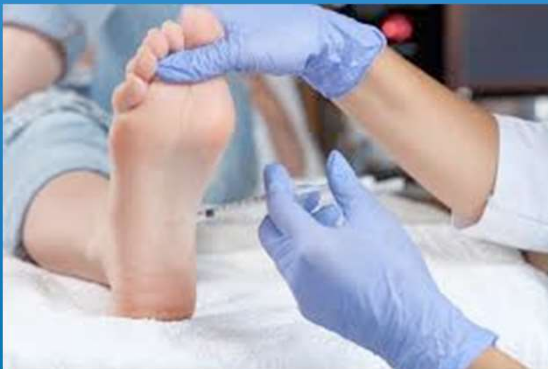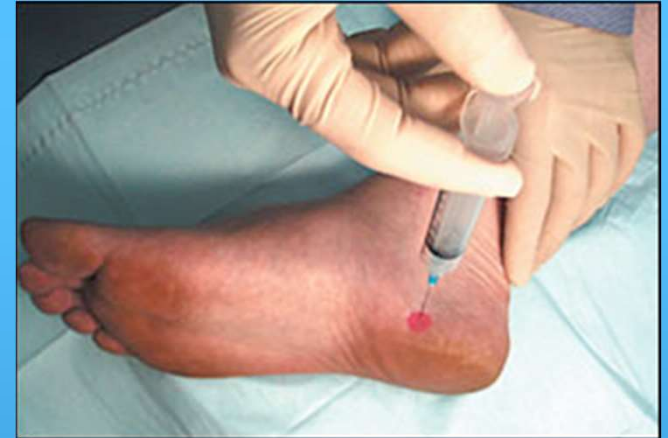Observe patient: Watch for vaso-vagl reaction, rub area of injection to reduce pain, discuss with patient improvement of symptoms from local anesthetic.

Patient Education: Provide with post injection instructions



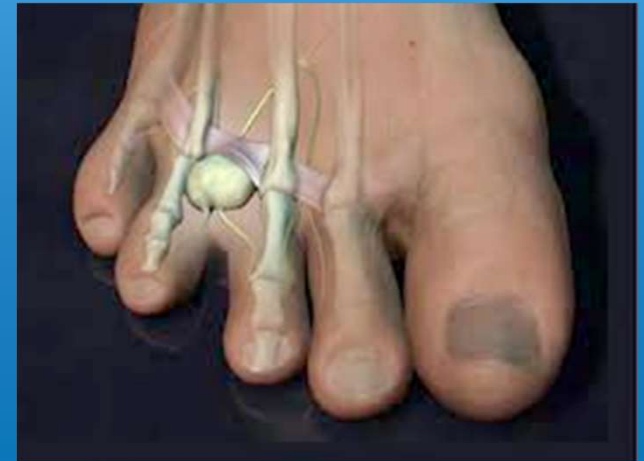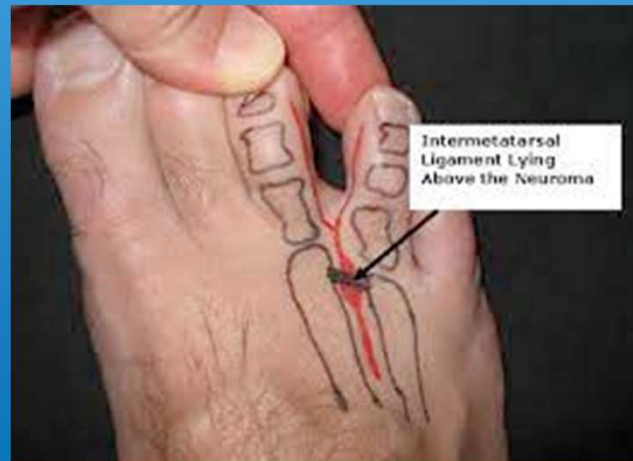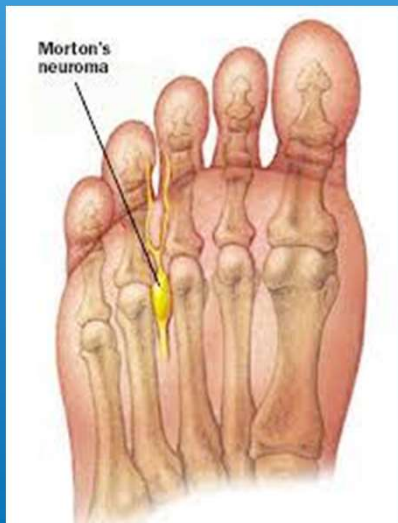
Plantar Fasciitis

- Side effects
 - Plantar fascial rupture 2.4% - 5.7%
 - No stress to the foot for 2 weeks after injection
- Fat Atrophy 1%
- Less soluble agents increased risk of soft tissue atrophy



Morton's Neuroma

- Condition that causes pain on the ball of the foot.
- Caused from weakening of connective tissues between metatarsal heads, the increased motion this causes results in nerve irritation and swelling.
- Typically occurs between the third and fourth toes.



Morton's Neuroma

Patient Position: Patient is placed lying supine with knee straight or sitting with knee hanging over table bent at 90 degrees

Landmarks: Metatarsal heads

Tissue to Avoid: Digital artery and nerve

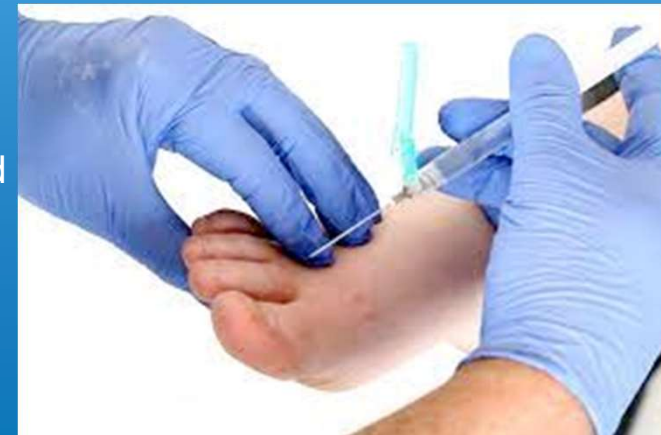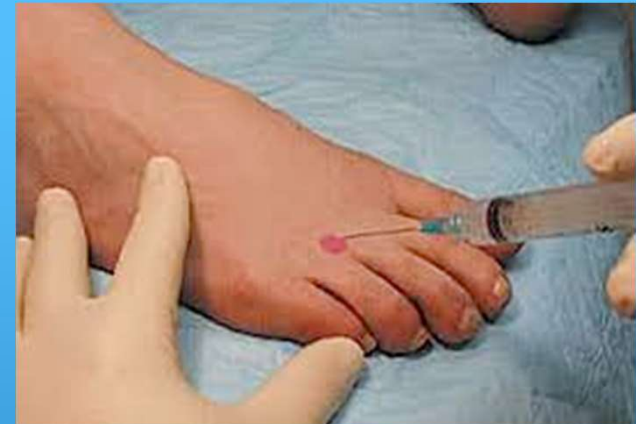Prep: Chlorhexidine/Betadine/alcohol wipe, can use topical ethylchloride

Needle Insertion: Mark area with pen or needle cap, insert 22-25g 1.5 needle thru anesthetized skin at dorsal aspect between metatarsal heads at 45 degree angle towards plantar surface, be careful not to go too far as you can end up injecting the plantar fat pad and cause atrophy. For this reason I tend to use more soluble steroid like Celestone.

Injection: Alone or mixture of 2-4ml 1% lidocaine and 0.5% Bupivacaine, Selected corticosteroid.

Observe patient: Watch for vaso-vagal reaction, rub area of injection to reduce pain, discuss with patient improvement of symptoms from local anesthetic.

Patient Education: Provide with post injection instructions



Documentation

- Develop a smart phrase or injection template
 - Include NDC# (often required by billing)
 - Document anatomic location of injection (glenohumeral vs subacromial)
 - Document Technique used and medication used

Take Home Points

- It is important to have knowledge of functional anatomy and identify underlying etiology prior to injection.
- Know the potential side effects and how to minimize these during and after injection.
- Always obtain informed consent prior to any injections.
- Injections can be diagnostic and therapeutic, it is important to let the patient know they need to document immediate pain relief and long term relief. Can also have them wait in the office for 10 minutes and re-examine to evaluate pain relief.

References

- Kreuz PC, Steinwachs M, Angele P. Single-dose local anesthetics exhibit a type-, dose-, and time-dependent chondrotoxic effect on chondrocytes and cartilage: a systematic review of the current literature. *Knee Surg Sports Traumatol Arthrosc.* 2018 Mar;26(3):819-830. doi: 10.1007/s00167-017-4470-5. Epub 2017 Mar 13.
- Farmer T, Morris SC, Quigley R, Amin NH, Wongworawat MD, Syed HM. Chondrotoxicity of Local Anesthetics: Liposomal Bupivacaine Is Less Chondrotoxic than Standard Bupivacaine. *Adv Pharmacol Pharm Sci.* 2020 Jan 4;2020
- Piper SL, Kramer JD, Kim HT, Feeley BT. Effects of local anesthetics on articular cartilage. *Am J Sports Med.* 2011 Oct;39(10):2245-53. doi: 10.1177/0363546511402780. Epub 2011 Apr 22.
- Alsop, R., Khondker, A., Hub, J. *et al.* The Lipid Bilayer Provides a Site for Cortisone Crystallization at High Cortisone Concentrations. *Sci Rep* 6, 22425 (2016).
- Stephens MB, Beutler AI, O'Connor FG. Musculoskeletal injections: a review of the evidence. *Am Fam Physician.* 2008 Oct 15;78(8):971-6.
- Cardone DA, Tallia AF. Diagnostic and therapeutic injection of the elbow region. *Am Fam Physician.* 2002 Dec 1;66(11):2097-100.

References

- Zuber TJ. Knee joint aspiration and injection. *Am Fam Physician*. 2002 Oct 15;66(8):1497-500, 1503-4, 1507.
- Tallia AF, Cardone DA. Diagnostic and therapeutic injection of the wrist and hand region. *Am Fam Physician*. 2003 Feb 15;67(4):745-50.

Questions?

- Feel free to email me with any questions at orthopac2@gmail.com