

Ultrasound Knee Anatomy and Pathology

David Westerdahl MD FAAFP RMSK

www.sportshealthnorthwest.com

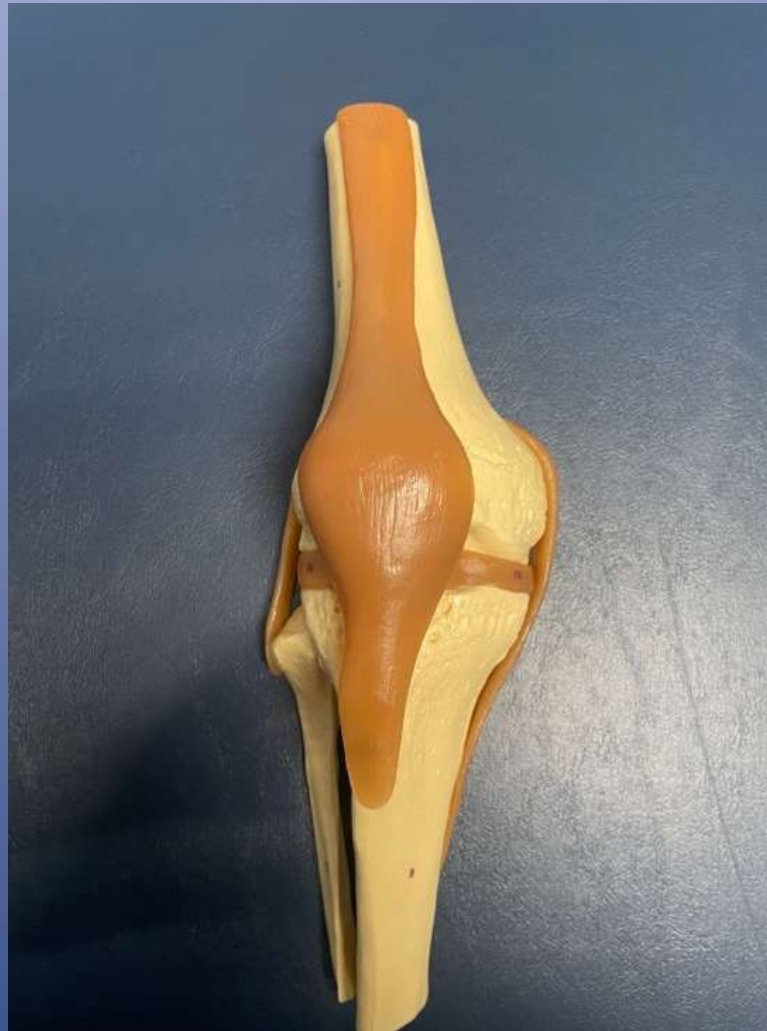Acknowledgement

- Jacobson, Jon. Fundamentals of Musculoskeletal Ultrasound. 3rd Ed. 2018
- Netter Atlas of Anatomy. 6th Ed. 2014
- Evan Peck, MD



MSKUS of Knee

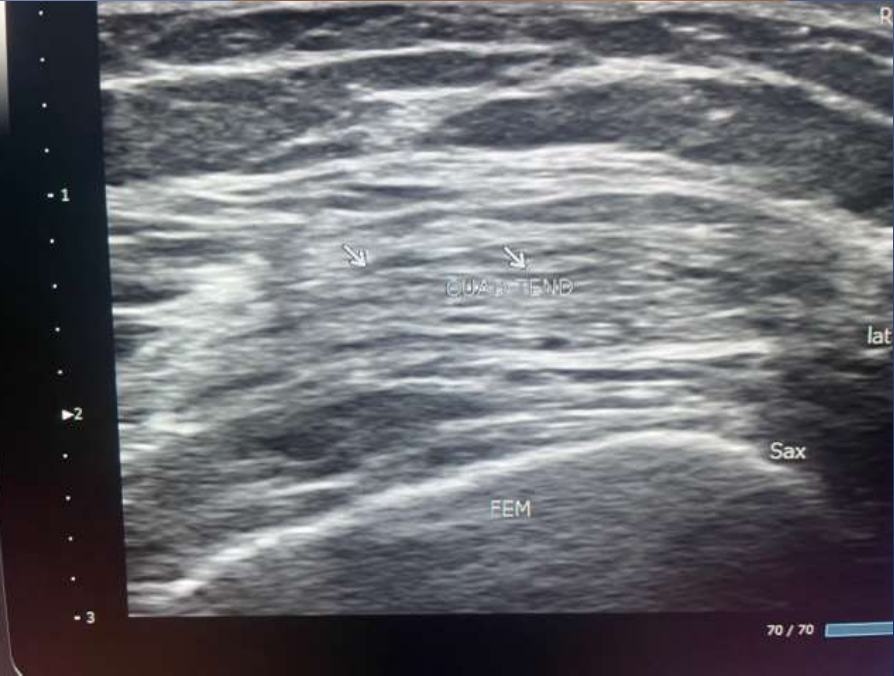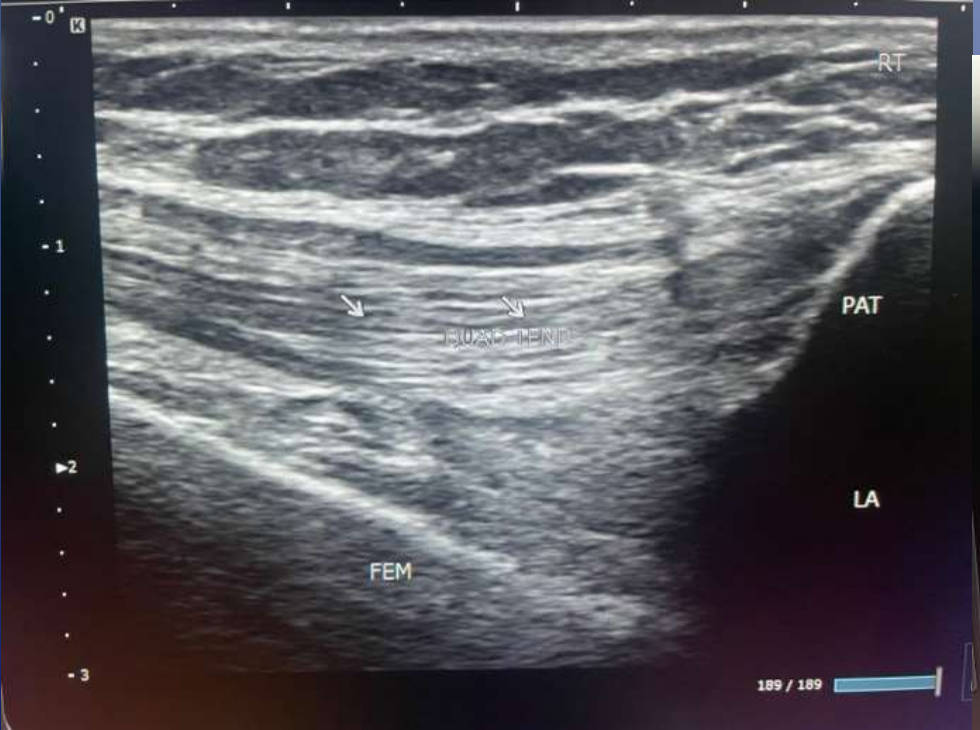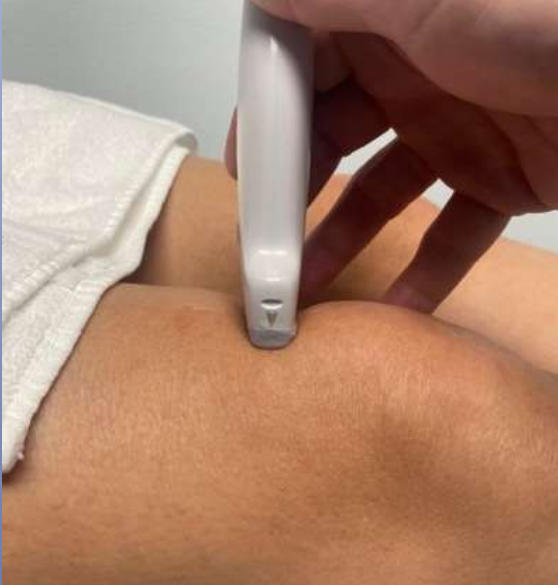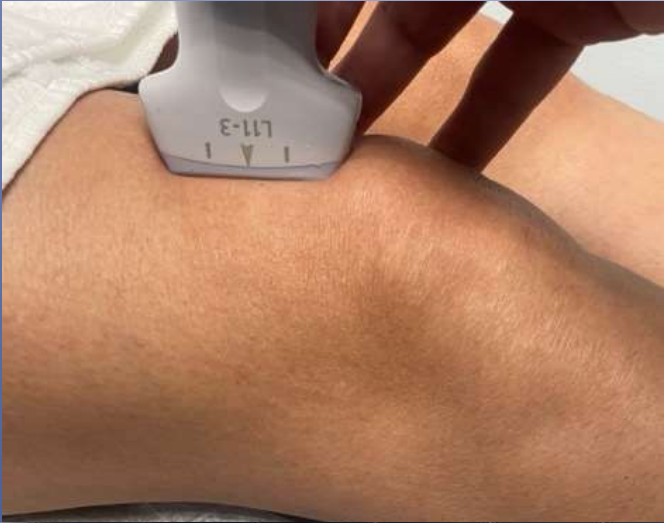- Soft tissue
 - Tendons
 - Muscle
 - Ligaments
 - Bursa
 - Synovia
- Cartilage
 - Articular
 - Meniscus



Knee Checklist

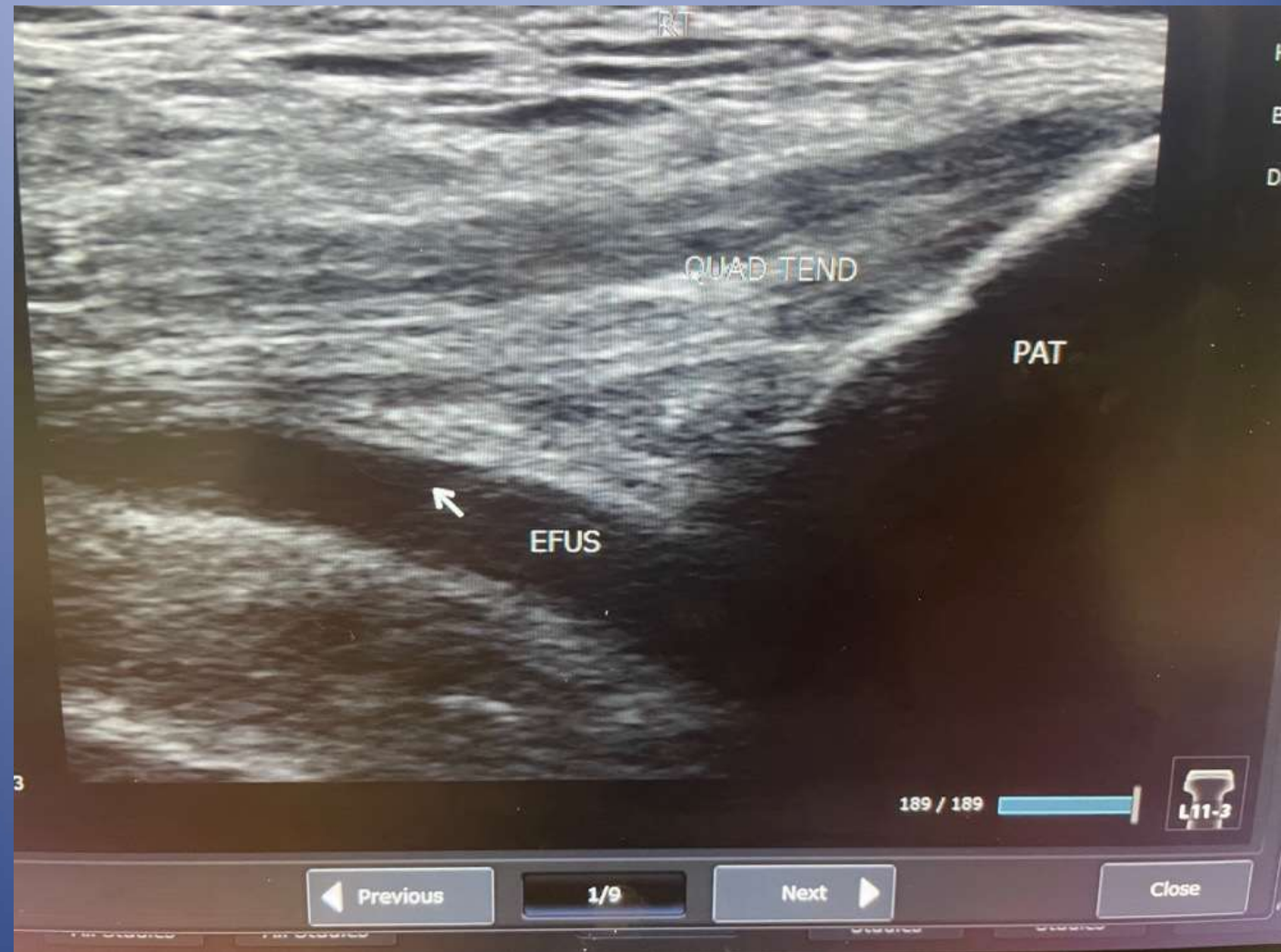- Anterior
 - Quadricep Tend
 - Suprapat recess
 - Femoral Trochlea
 - Patellar Tendon
- Medial Knee
 - MCL
 - Med Meniscus
 - Pes Anserine
- Lateral Knee
 - IT Band
 - LCL
 - Lat Meniscus
- Posterior
 - Popliteal NV bundle
 - Semi tendinosis
 - Semi membranous
 - Bicep femoris

Anterior Knee

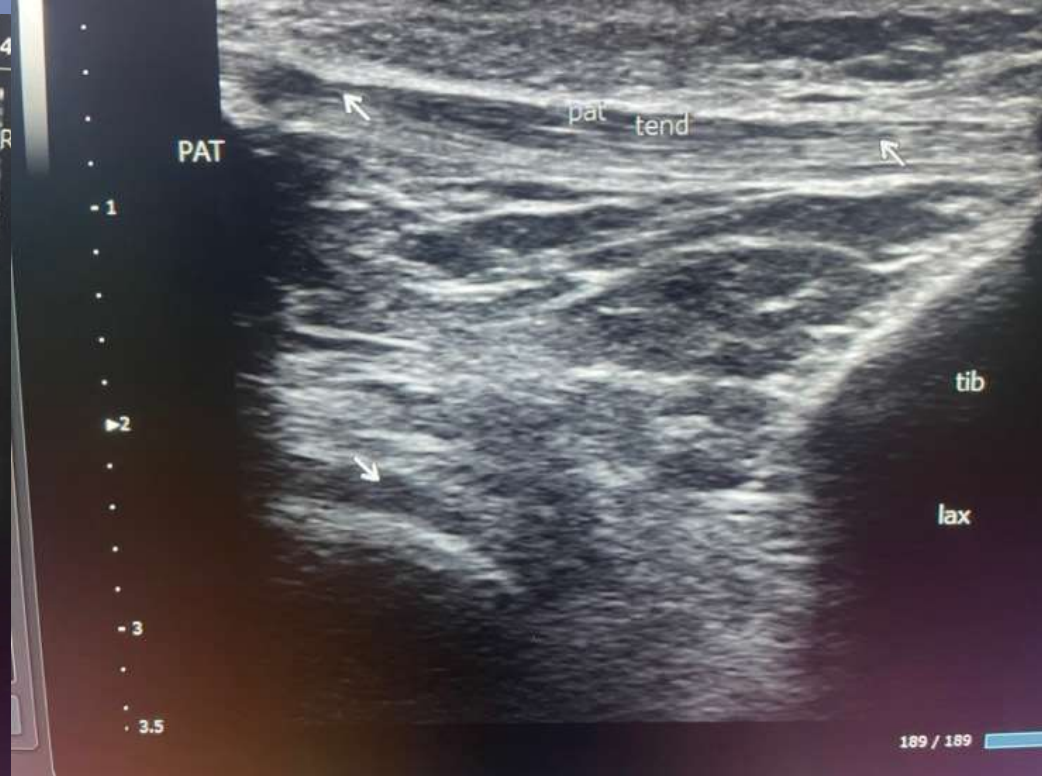
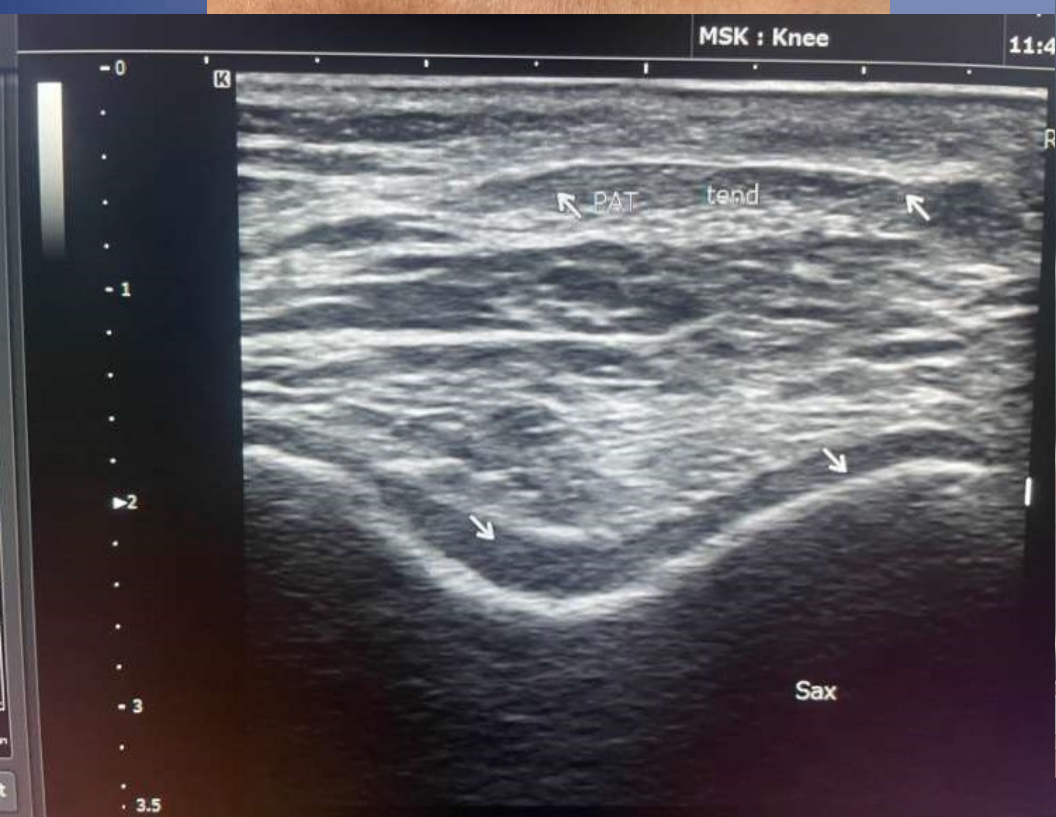
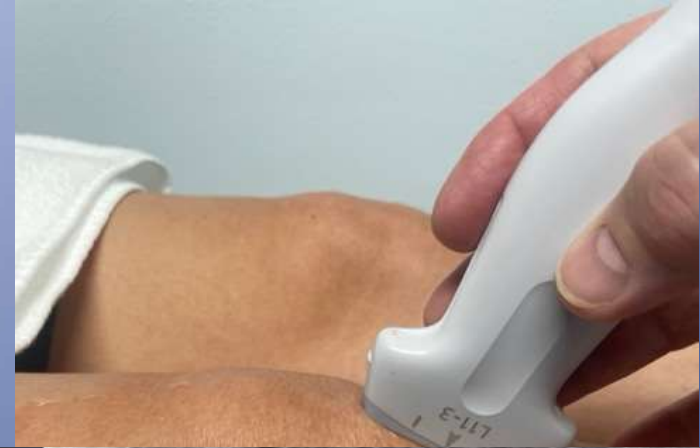
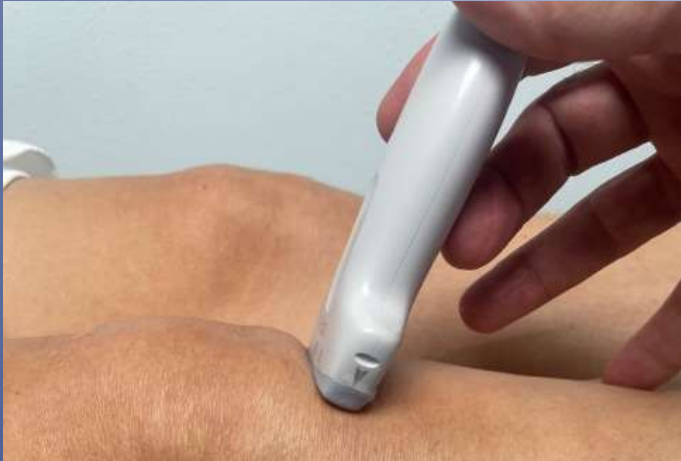Knee Effusion

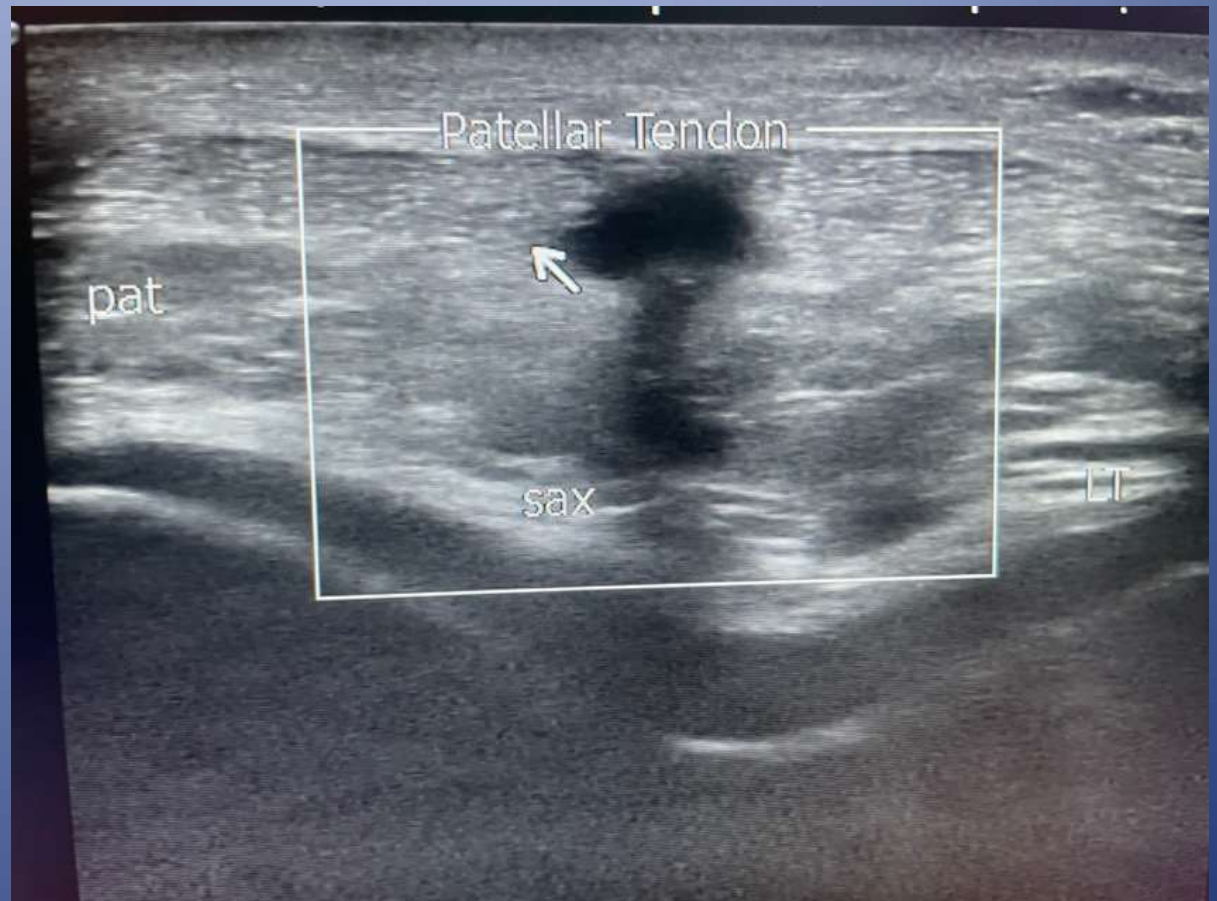- Commonly see synovitis
- Fairly easy target



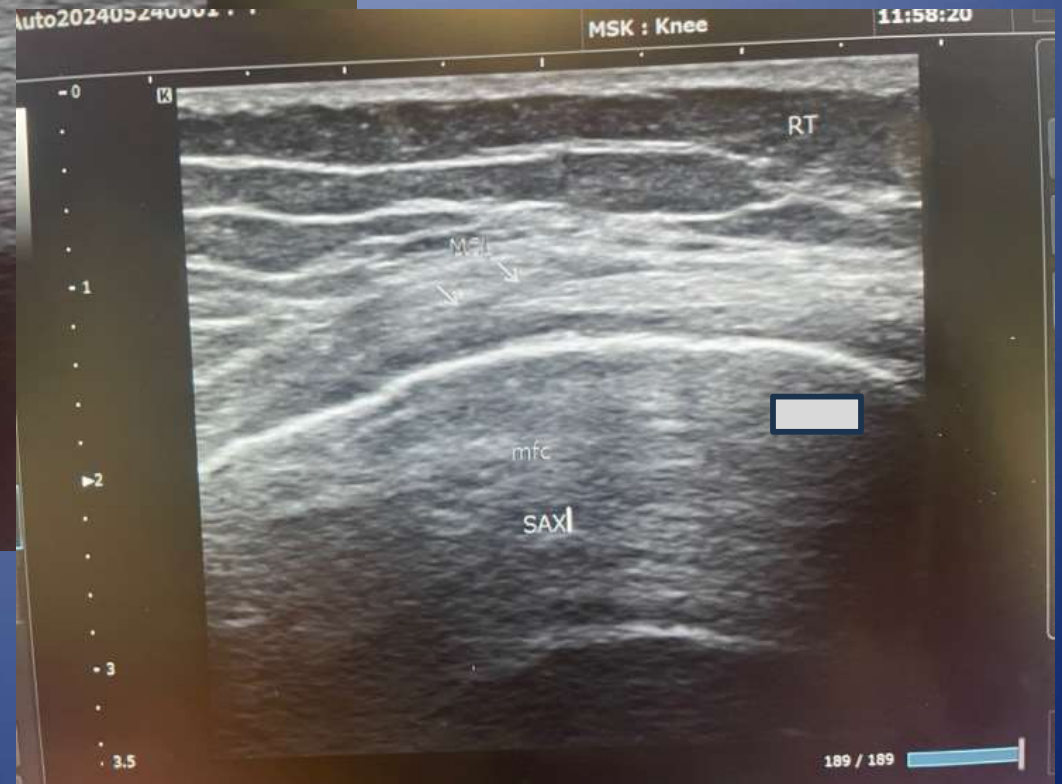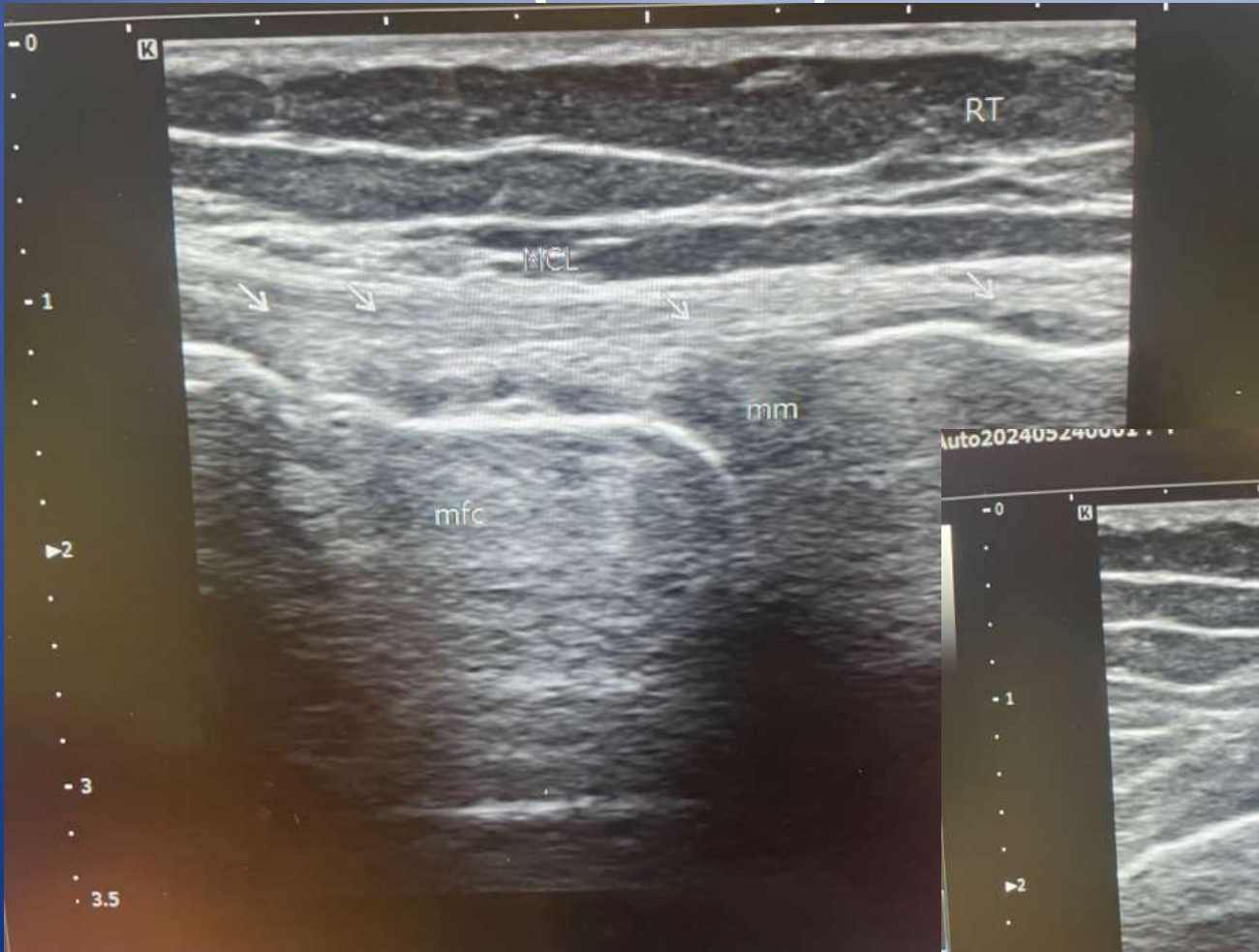Normal Patella Tendon



Patellar Tendonitis

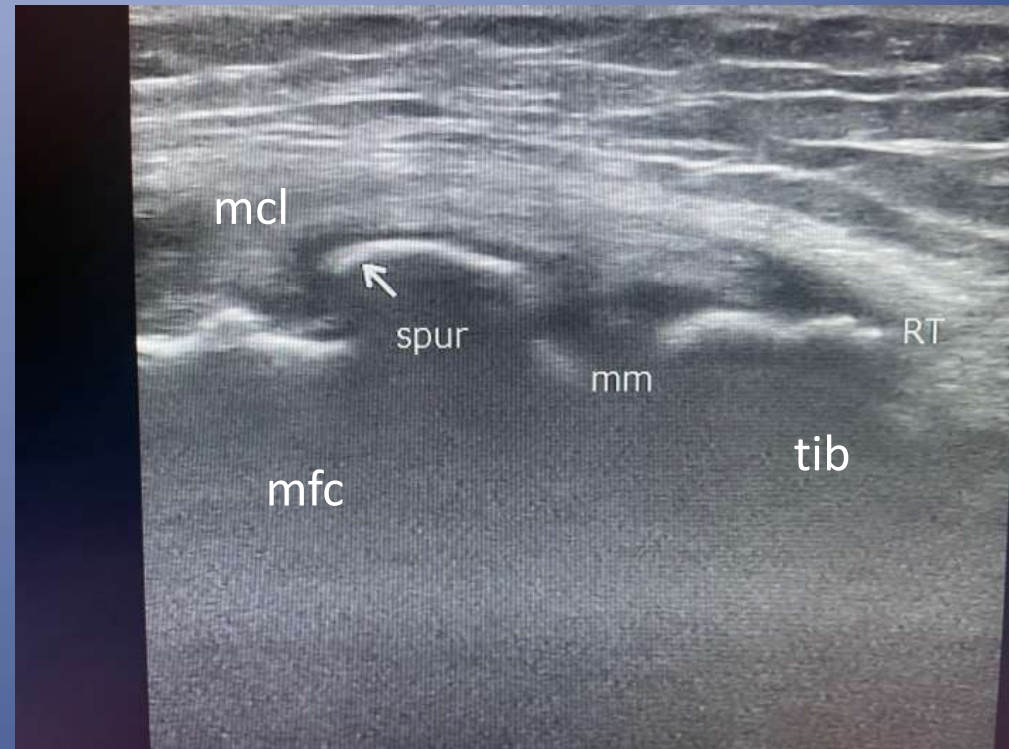


Medial (Tibia) Collateral Ligament



Knee Arthritis

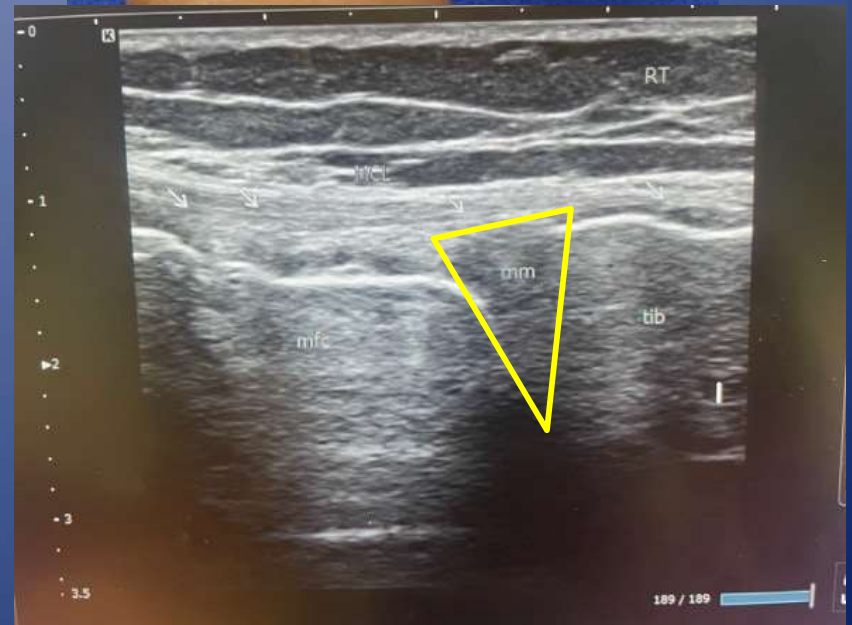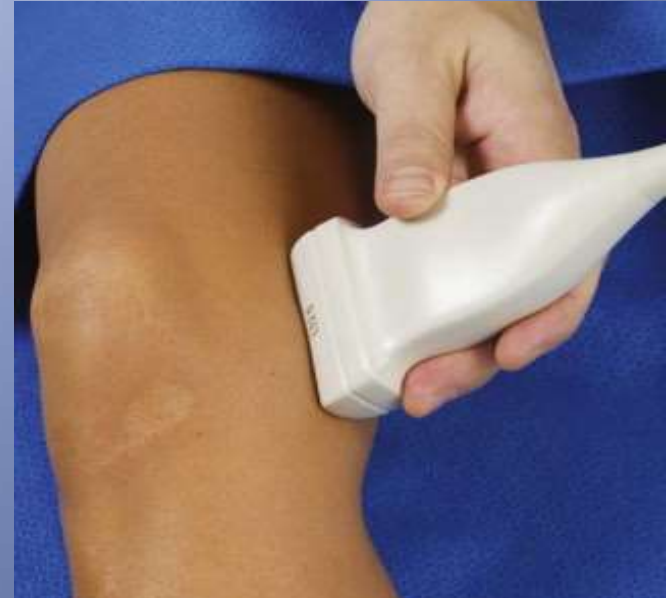- X-ray is best for diagnosing arthritis
- Joint space narrowing
- Bone spurs
- Degenerative meniscus tearing



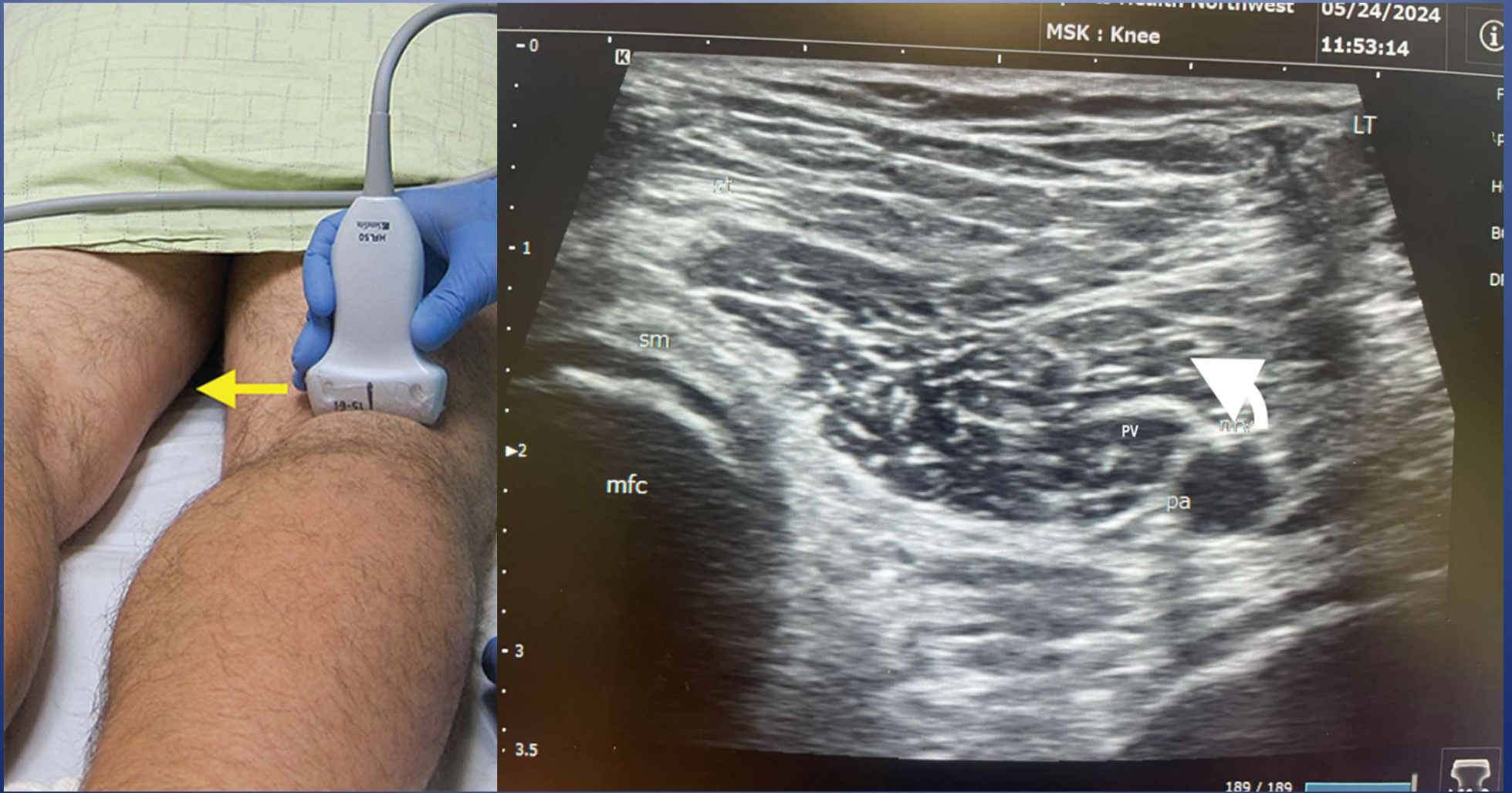
Medial Meniscus

- MRI is preferred Imaging
 - MSKUS can have limited visualization
 - MSKUS has been reported to have sensitivity and specificity of 85% and 77% respectively in athletes*

*J Sports Med Phys Fitness
. 2017 May;57(5):589-594.

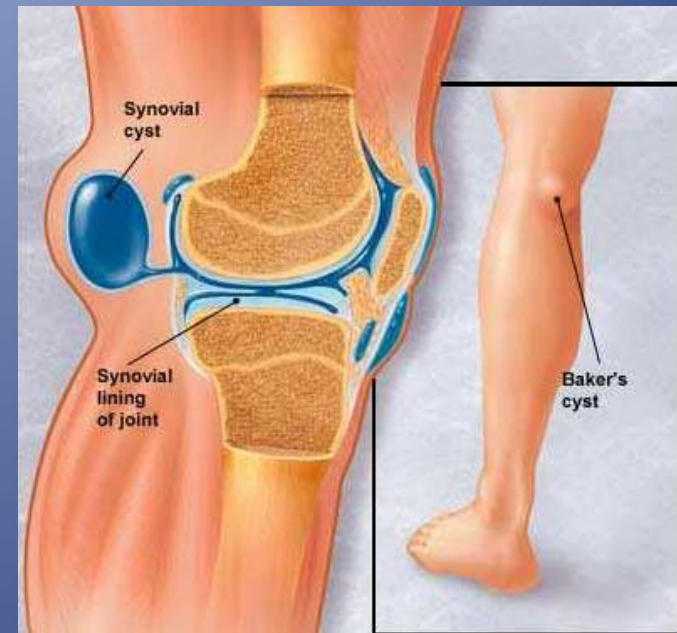


Posterior knee



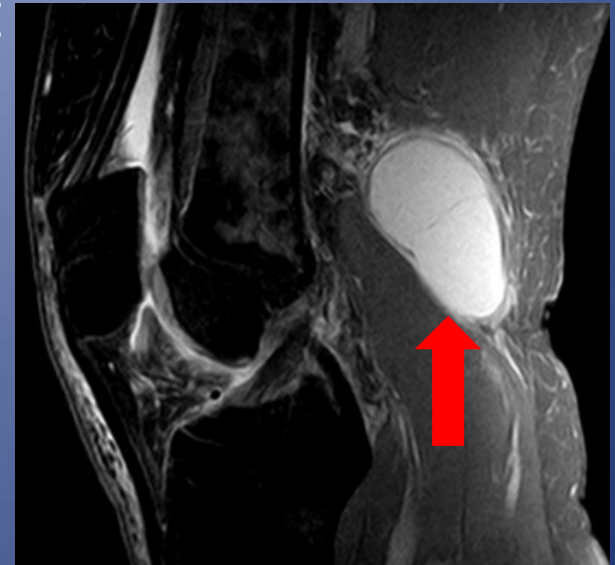
Baker's Cyst

- Distention of semimembranous-medial gastrocnemius bursa
- Common in adults over 50
- Dx relies on identification of the neck that connects the bursa to the knee joint
- Usually wraps around the medial head of gastroc tendon and muscle

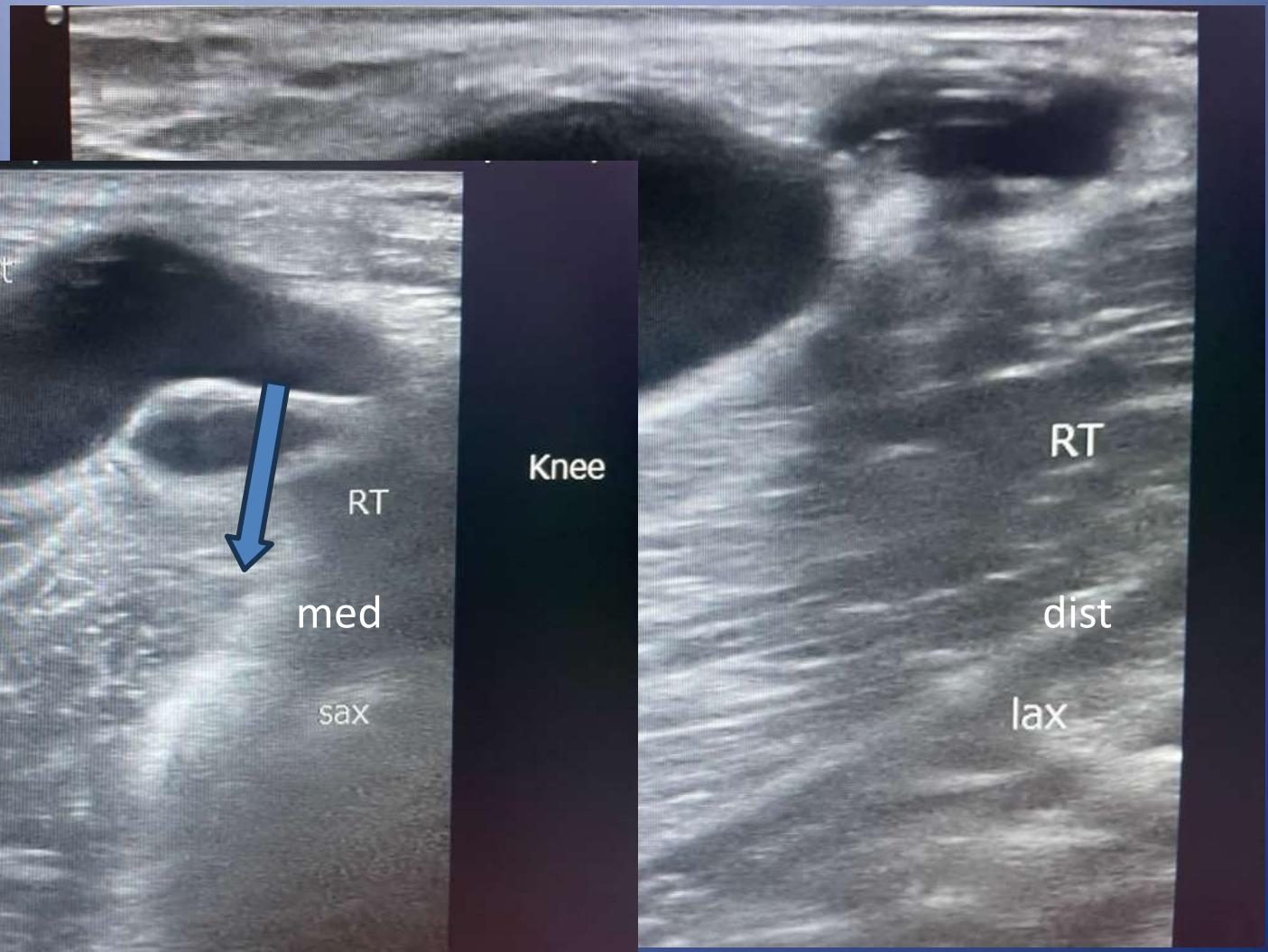


Baker's Cyst

- Anechoic or hypoechoic fluid is most common
 - Iso or hyperchoic fluid may represent hemorrhage or inflammatory synovitis
- Evaluate inferior margin of cyst to look for rupture
- USG aspiration +/- injection can provide relief, but re-accumulation of fluid from knee is likely



Baker Cyst



pop cyst



RT

med

sax

Knee

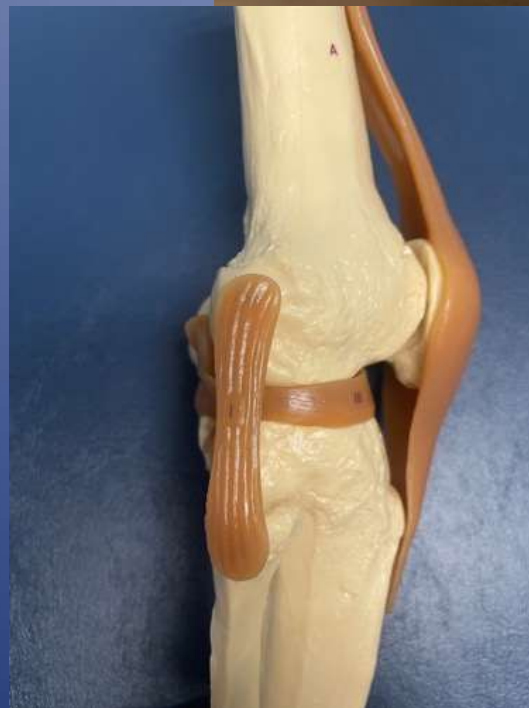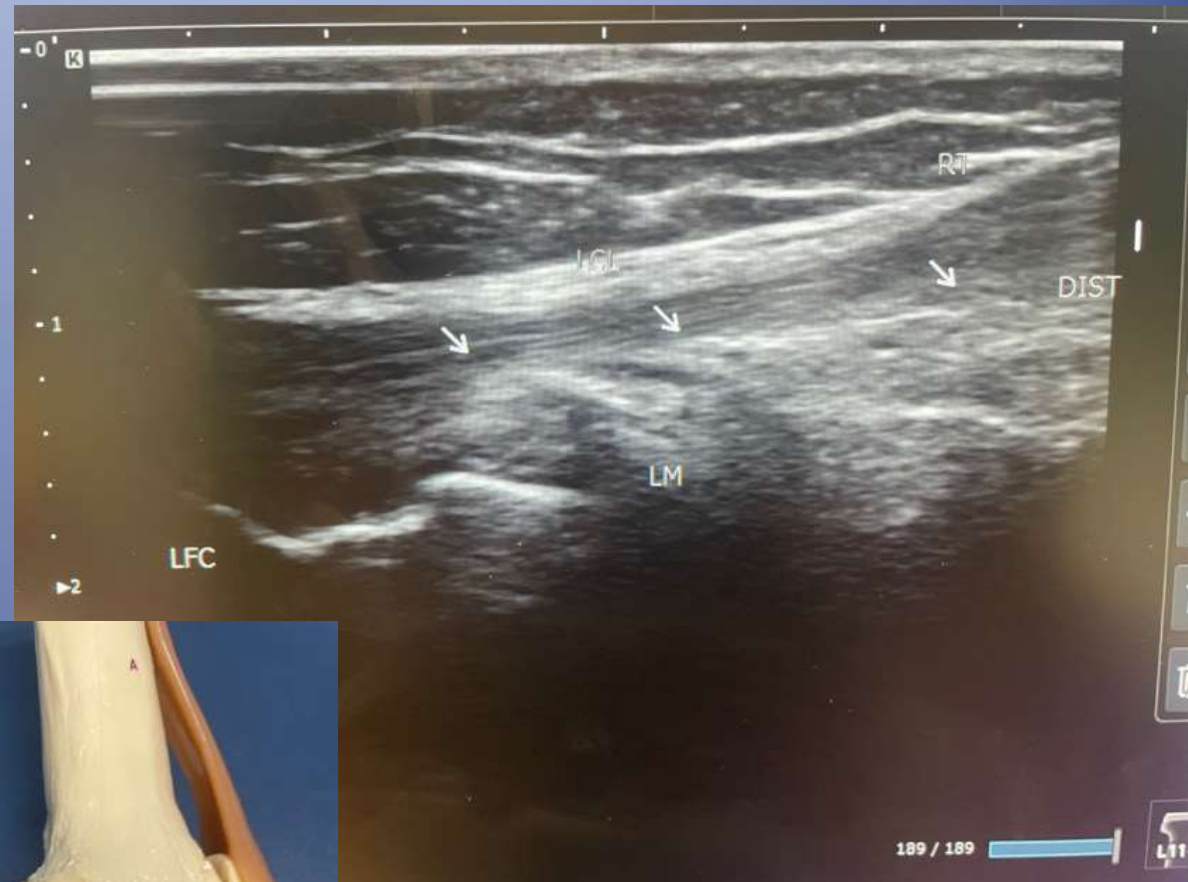RT

dist

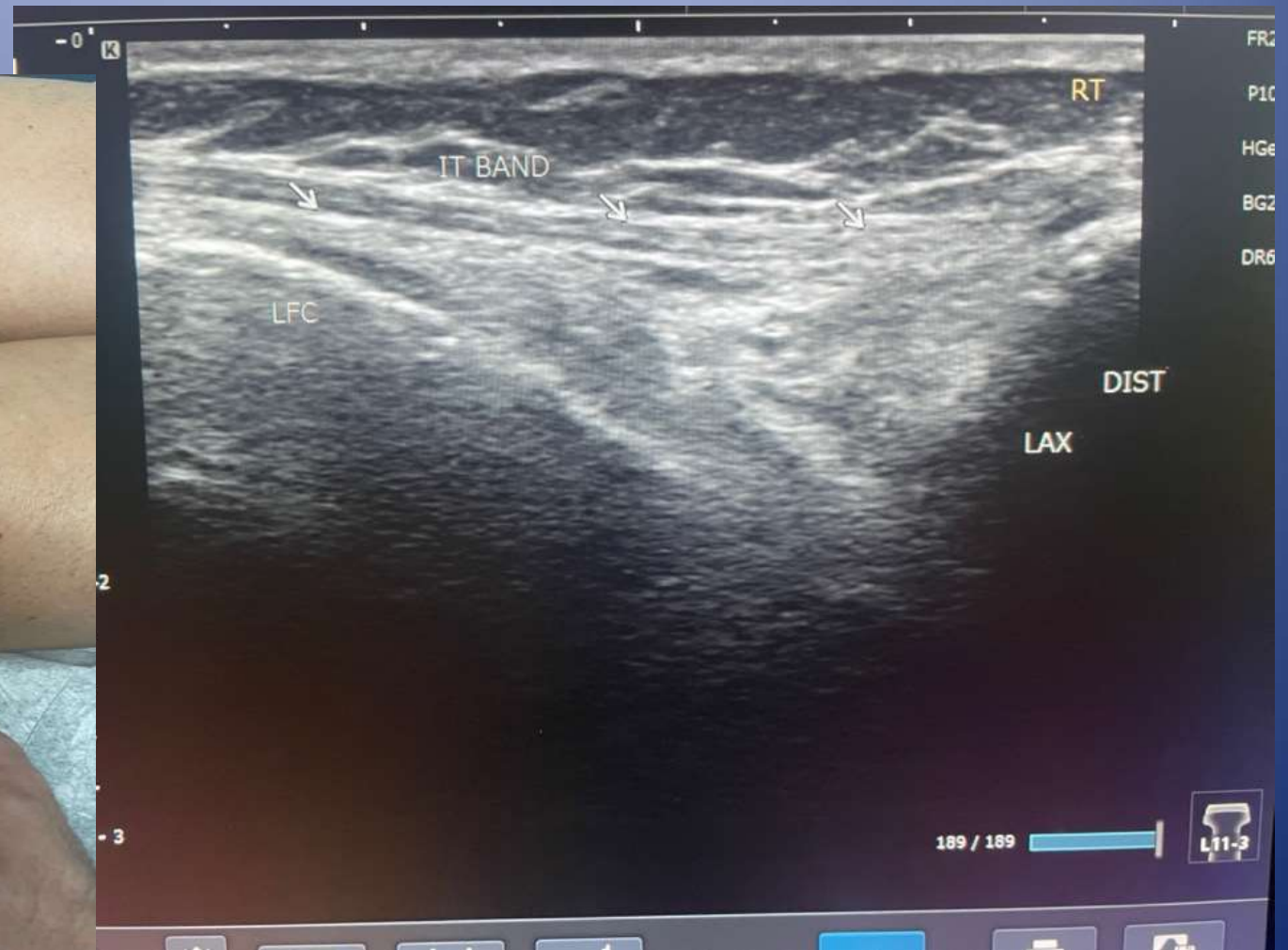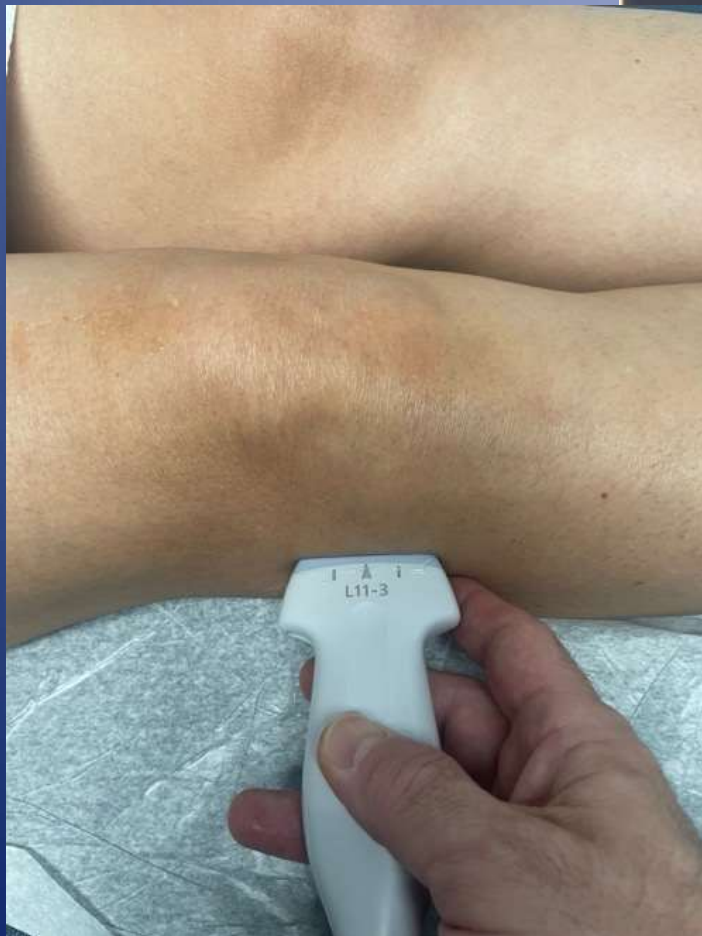lax

Lateral knee US

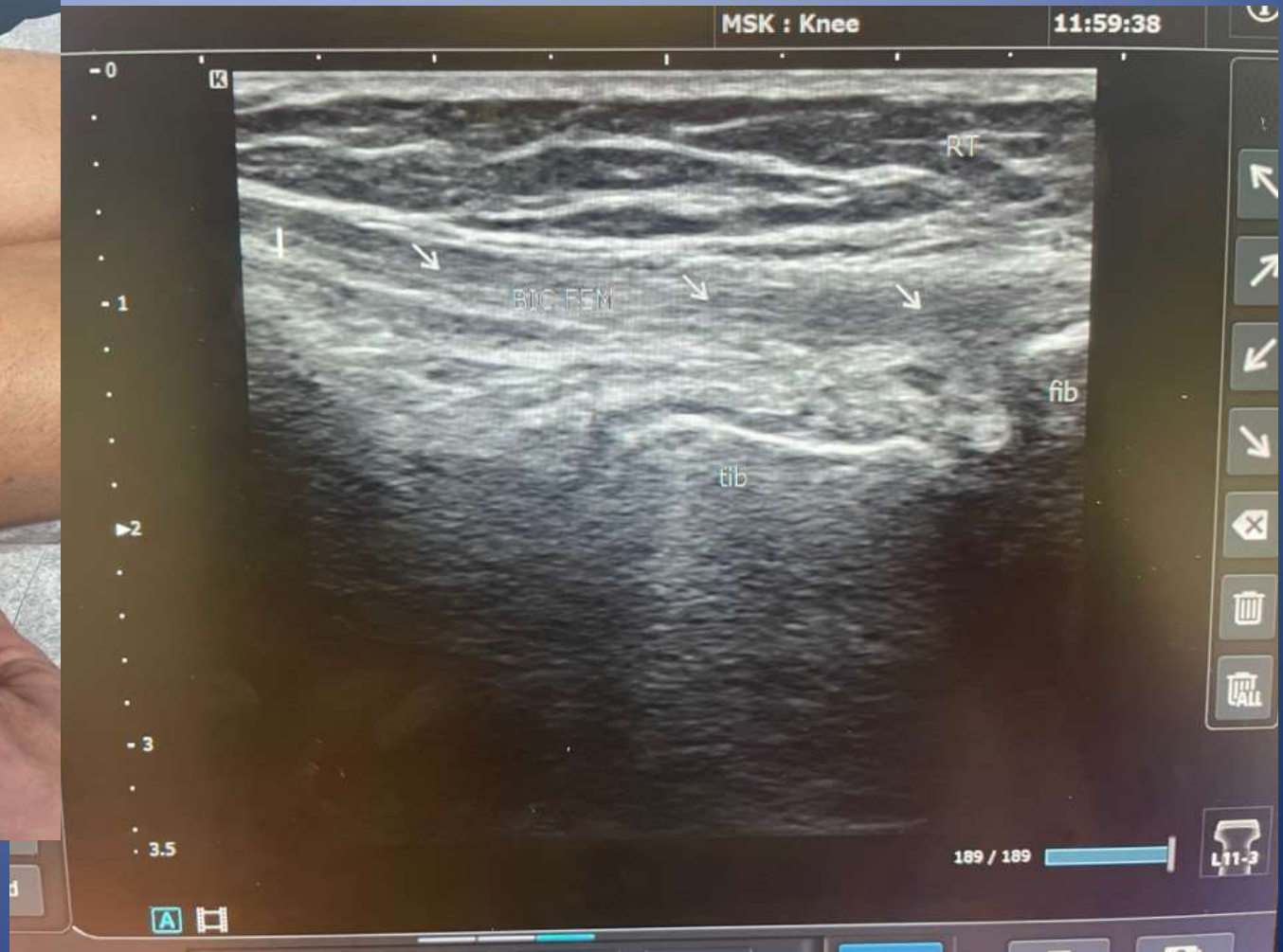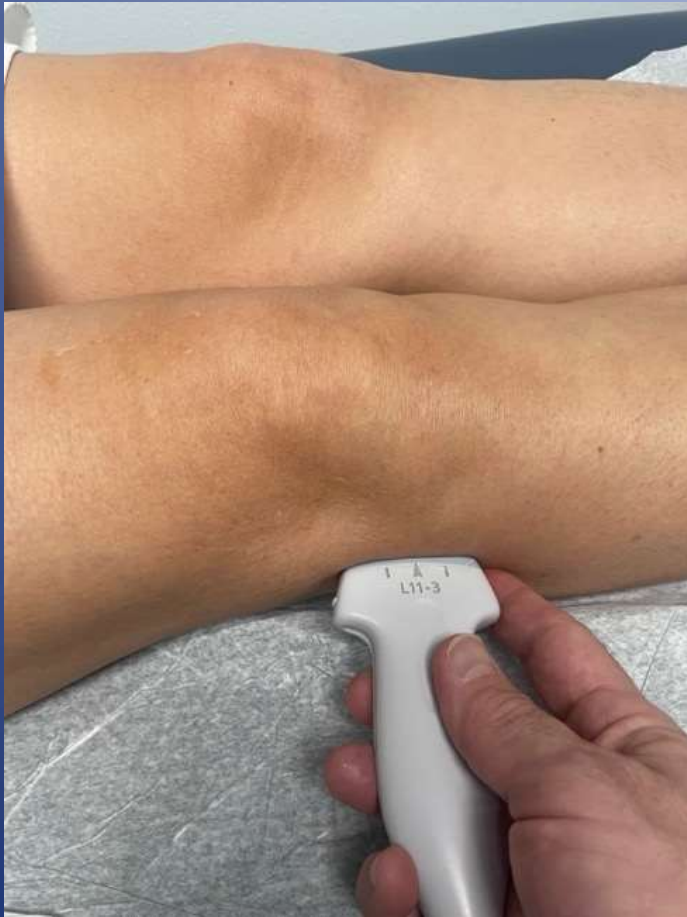- Lateral collateral ligament
- IT band
- Popliteus tendon
- Bicep femoris tendon



IT Band



Bicep femoris US



Summary

- MSKUS
 - Extensor mechanism
 - Knee effusion
 - Ligament injury (MCL,LCL)
 - Articular cartilage
 - Meniscal Cartilage
 - Baker cyst

