

Common Orthopaedic Conditions of the Shoulder in the Young Athlete

Christopher V. Bensen, M.D.

A PA's Guide to the Musculoskeletal Galaxy
June 5-9, 2024
Portland, OR

Disclosures

- Partner, Keys Medical Group
- Medical Staff, Lower Keys Medical Center
 - ❖ Key West, Florida
- No corporate affiliation, interests, or royalties
- bensencv@gmail.com
- 828-773-9227



Objectives

- You've worked really hard to get where you are
- It's a marathon, not a sprint!
- Find a hobby or avocation that interests you
- Spend some time away from work
- Cherish your family
- Find a happy place
- Enjoy the ride!

Objectives

- Know how to properly evaluate an athlete with a shoulder injury or other symptoms
- Formulate an appropriate differential diagnosis based on history and PE findings
- Recommend initial treatment plans for patients with AC separations, shoulder instability, and labral injuries



AMBITION

THE JOURNEY OF A THOUSAND MILES SOMETIMES ENDS VERY, VERY BADLY.

The Shoulder - An Intern's View

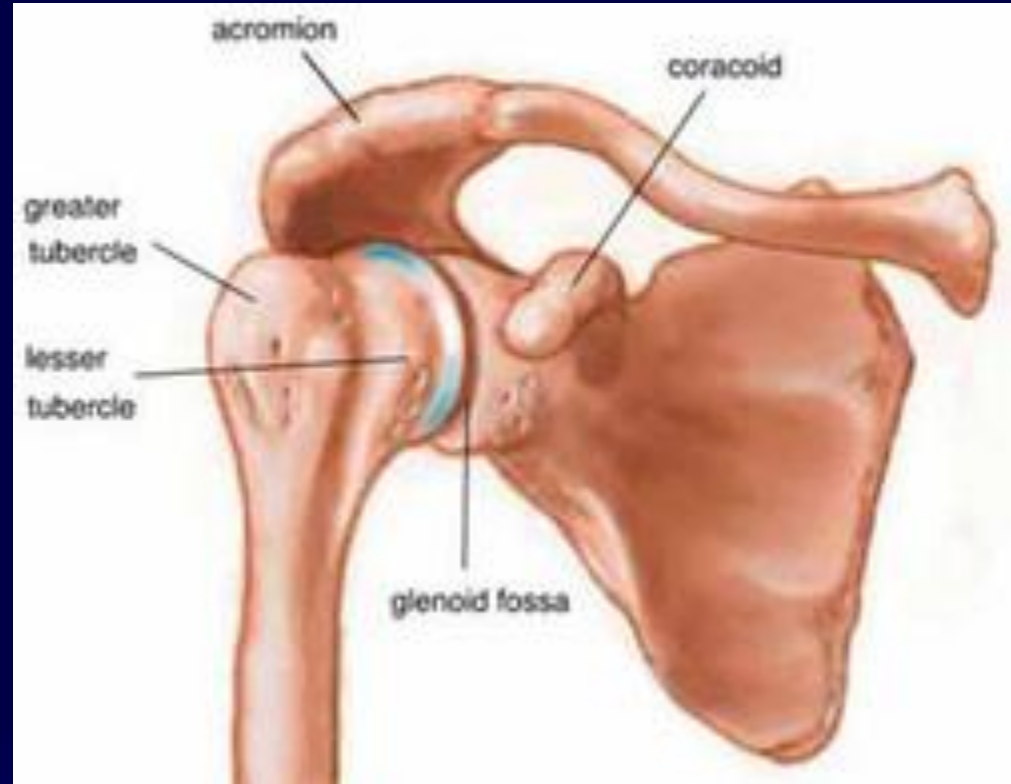


Introduction

- Shoulder anatomy
- SLAP Lesions
- Shoulder dislocations
- Shoulder instability
- Labral injuries
- AC joint separations

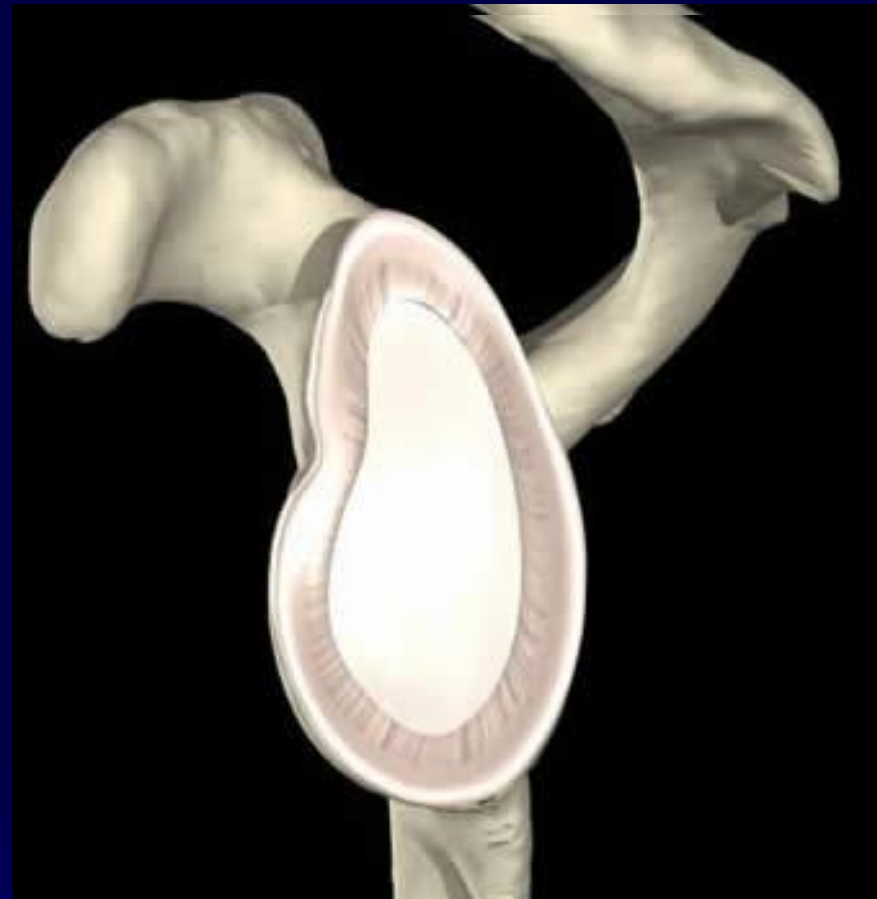Shoulder anatomy

- Three bones
 - ❖ Scapula
 - ❖ Humerus
 - ❖ Clavicle
- Joints
 - ❖ Glenohumeral
 - ❖ Acromioclavicular
 - ❖ Sternoclavicular
 - ❖ Scapulothoracic

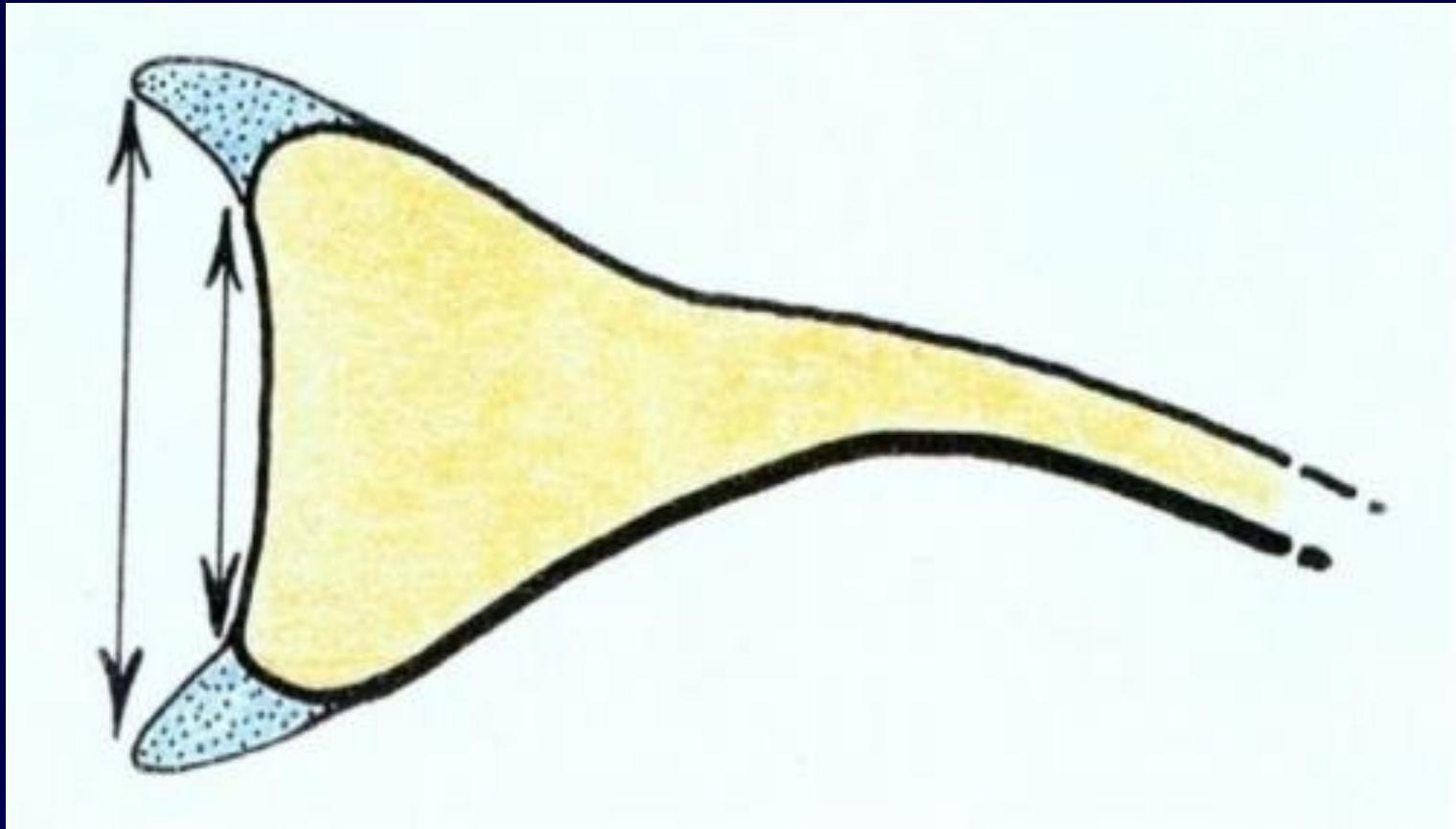


Labral anatomy

- Soft tissue sleeve surrounding glenoid
- Contiguous with joint capsule
- Clock face nomenclature
- LH Biceps attaches on the supraglenoid tubercle at 12 o'clock



Labral anatomy



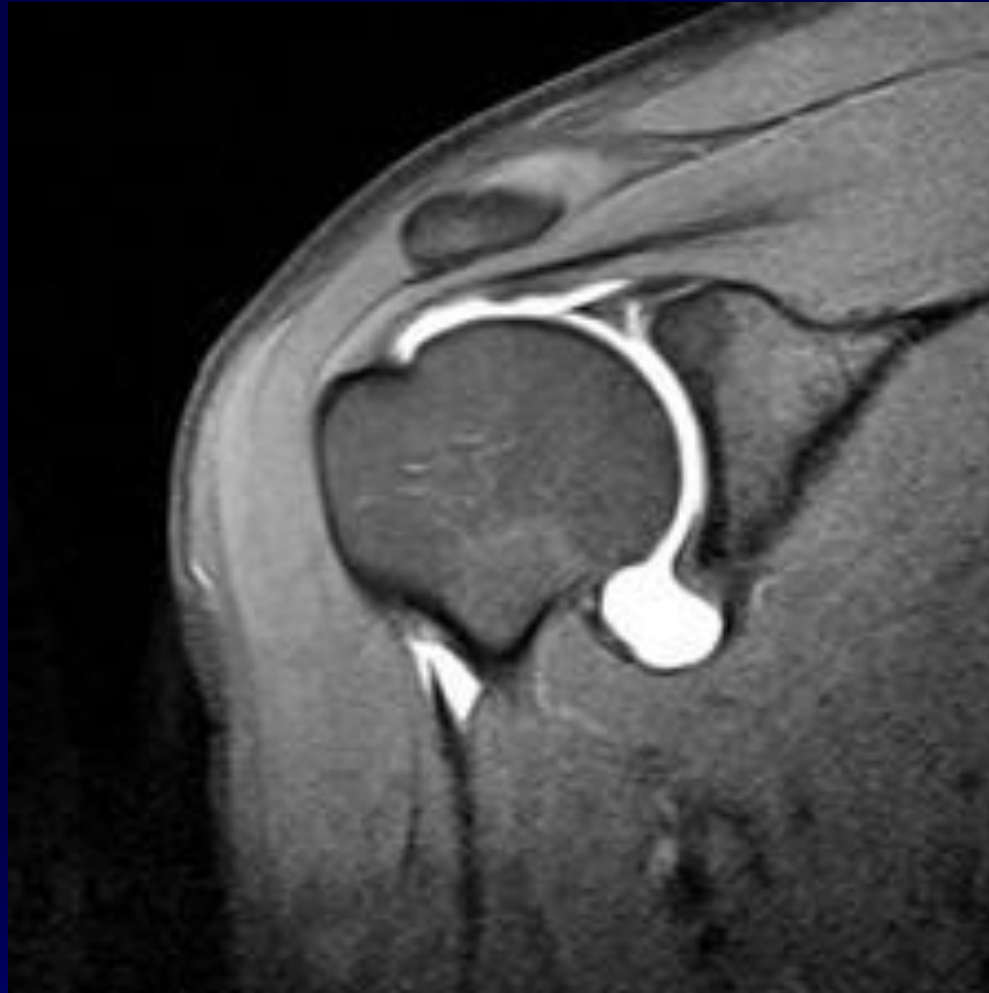Case #1

- 20yo RHD collegiate baseball pitcher presents with 3 month h/o intermittent right shoulder pain
- Exacerbated by throwing, lost velocity
- Localized deep and radiates down the front of his upper arm
- Aggravated by overhead reaching
- Partially relieved by NSAIDs

Case #1

- Exam reveals good ROM except slightly limited internal rotation
- Positive O'Brien's test
- Positive biceps load test
- No significant weakness
- Plain x-rays normal
- Any other studies?

Case #2



Case #1

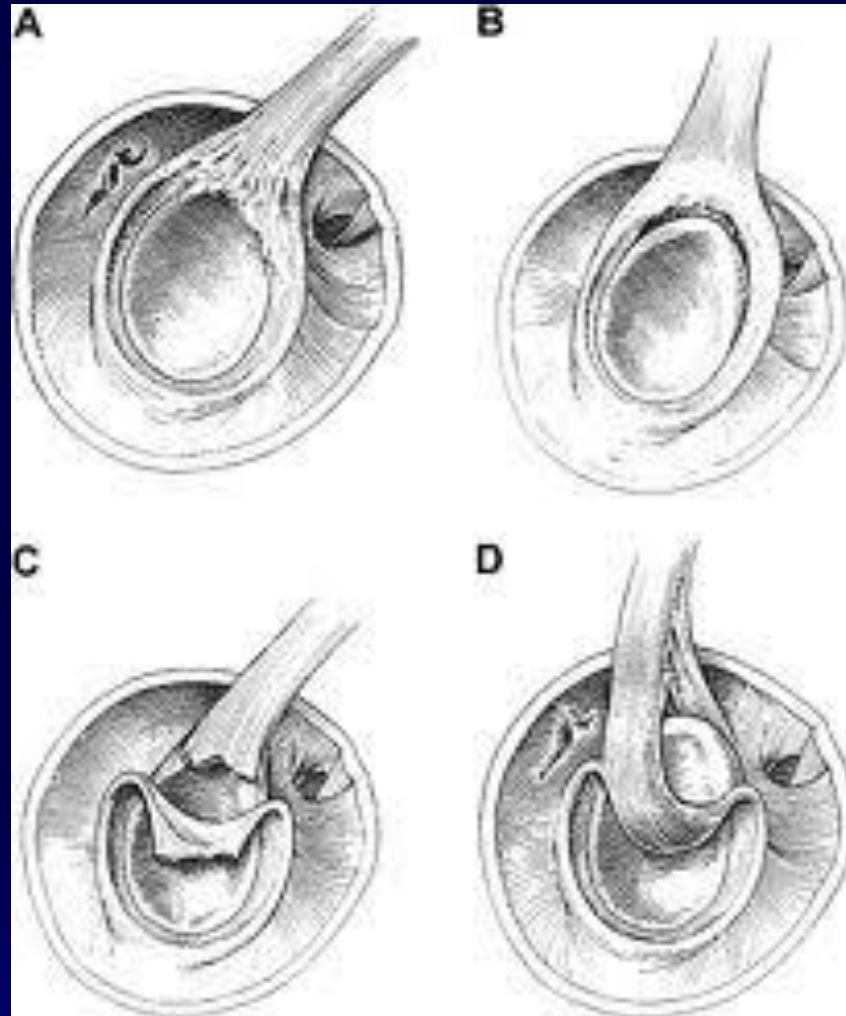
- Diagnosis?

SLAP Lesions

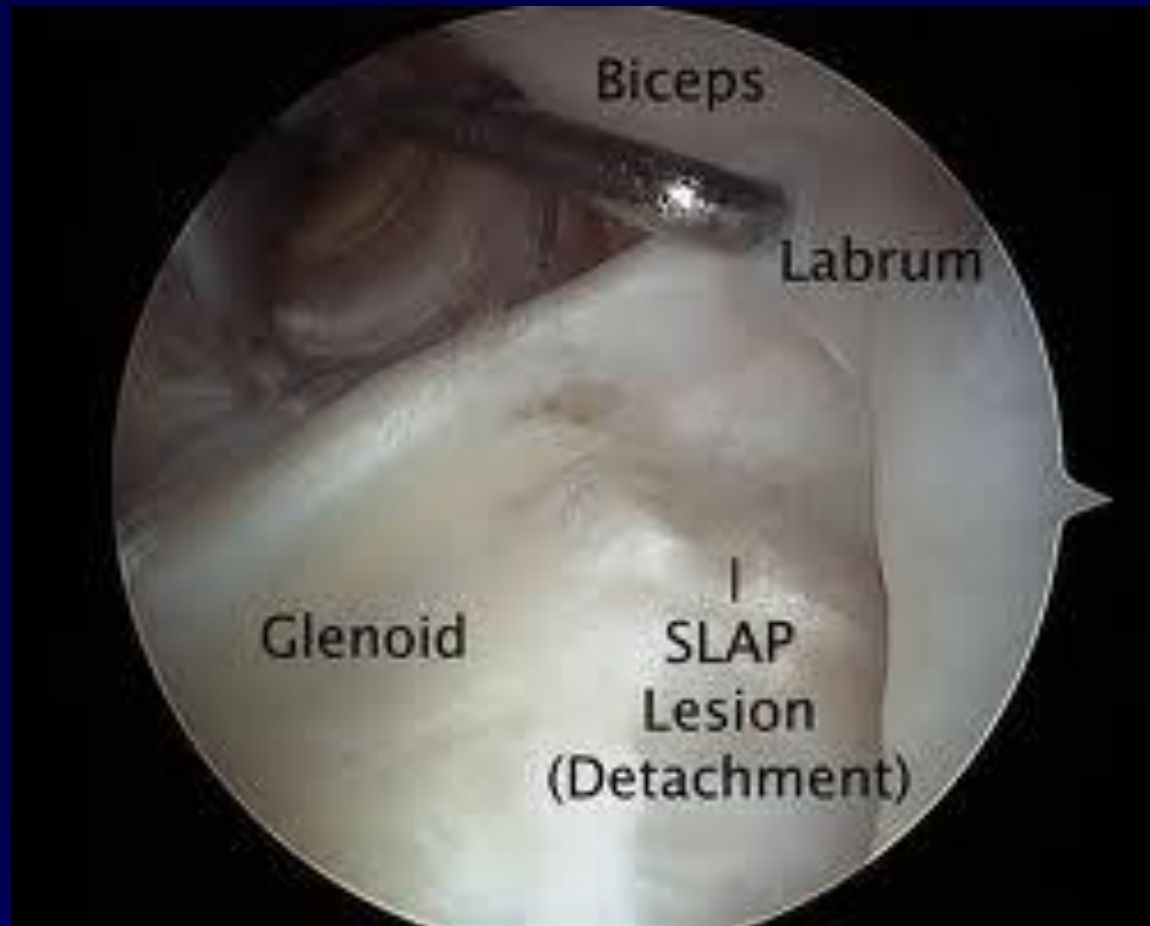- Superior Labral Anterior Posterior
- Common in overhead athletes
- Degenerative, attritional injury
- Labral tear of variable size at biceps anchor
- May involve a portion of the biceps

Snyder et al. Arthroscopy, 1990.

SLAP Lesions



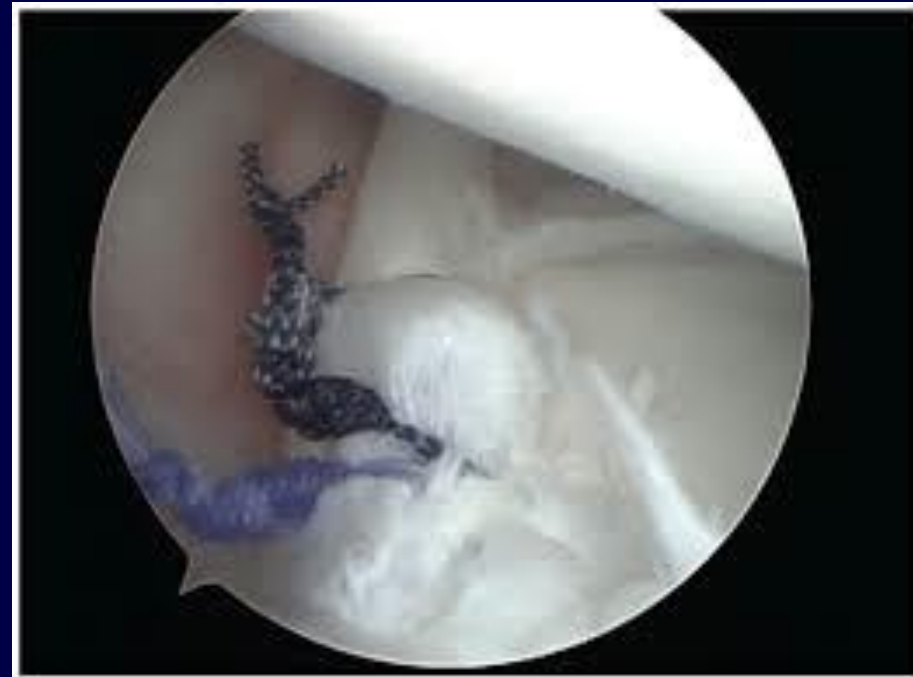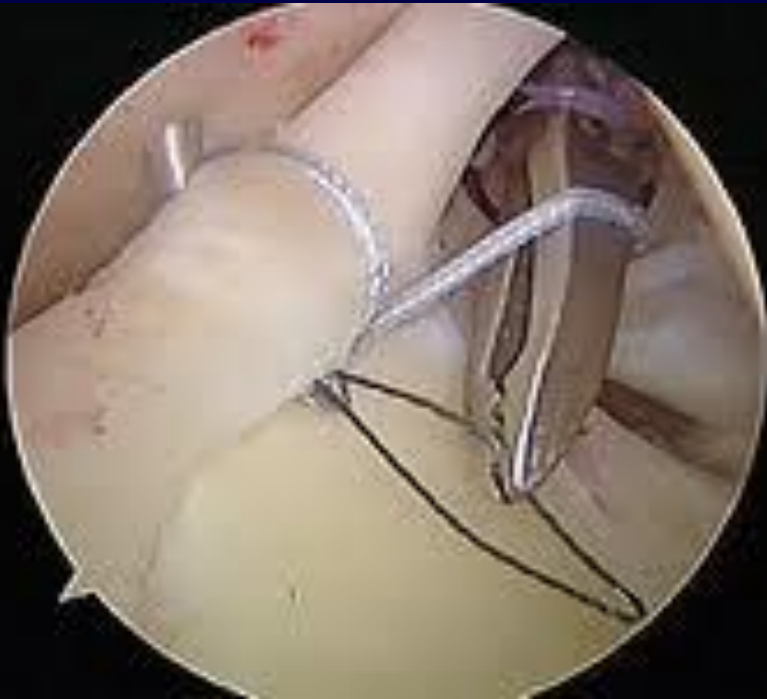SLAP Lesions

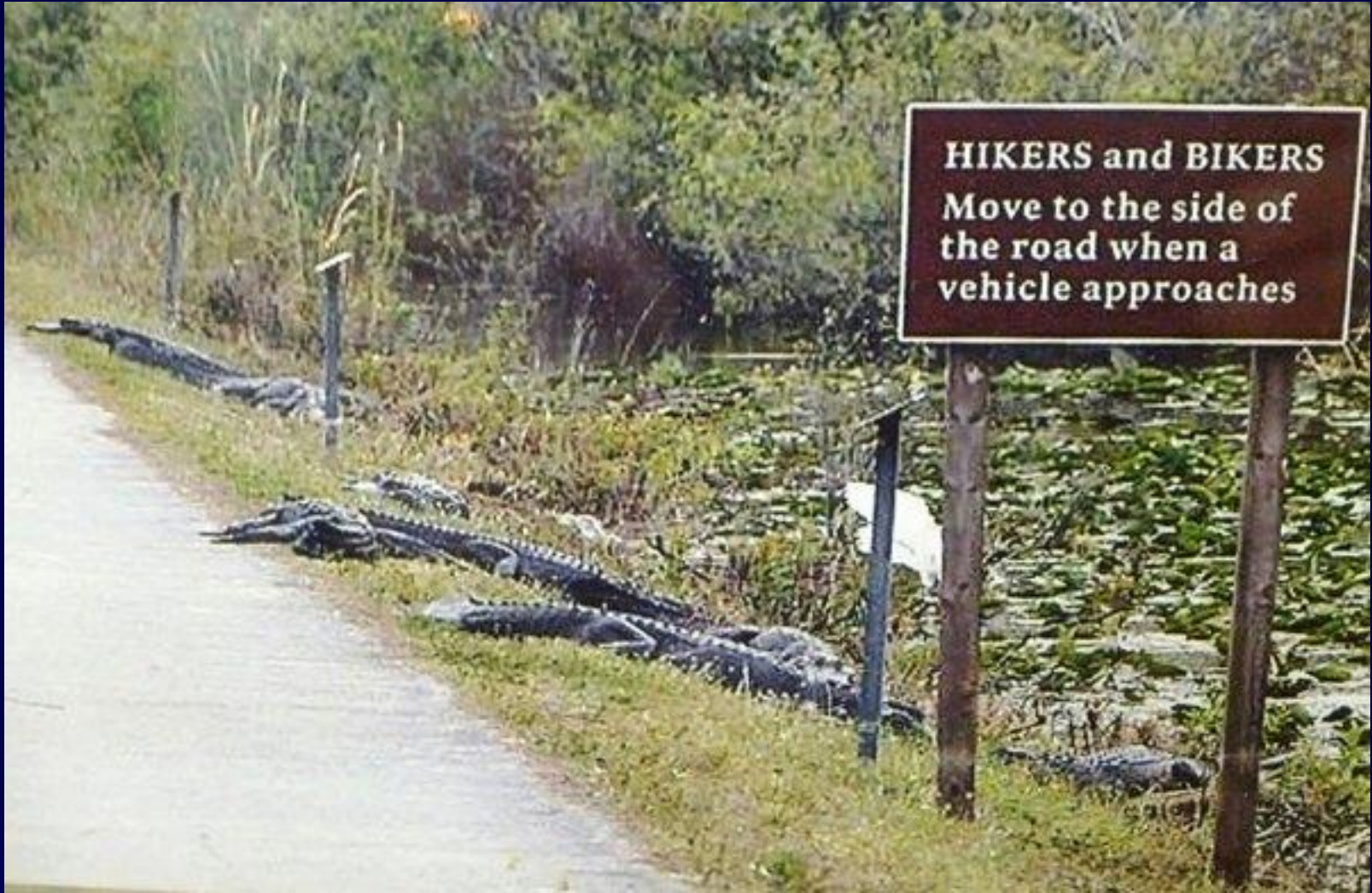

SLAP Lesions

- Conservative treatment includes rest, PT with ROM and terminal stretching exercises
- Associated GIRD
- NSAIDs for pain
- Activity modification – difficult for pitchers!
- Most often result in arthroscopic repair in young patients

SLAP Repair





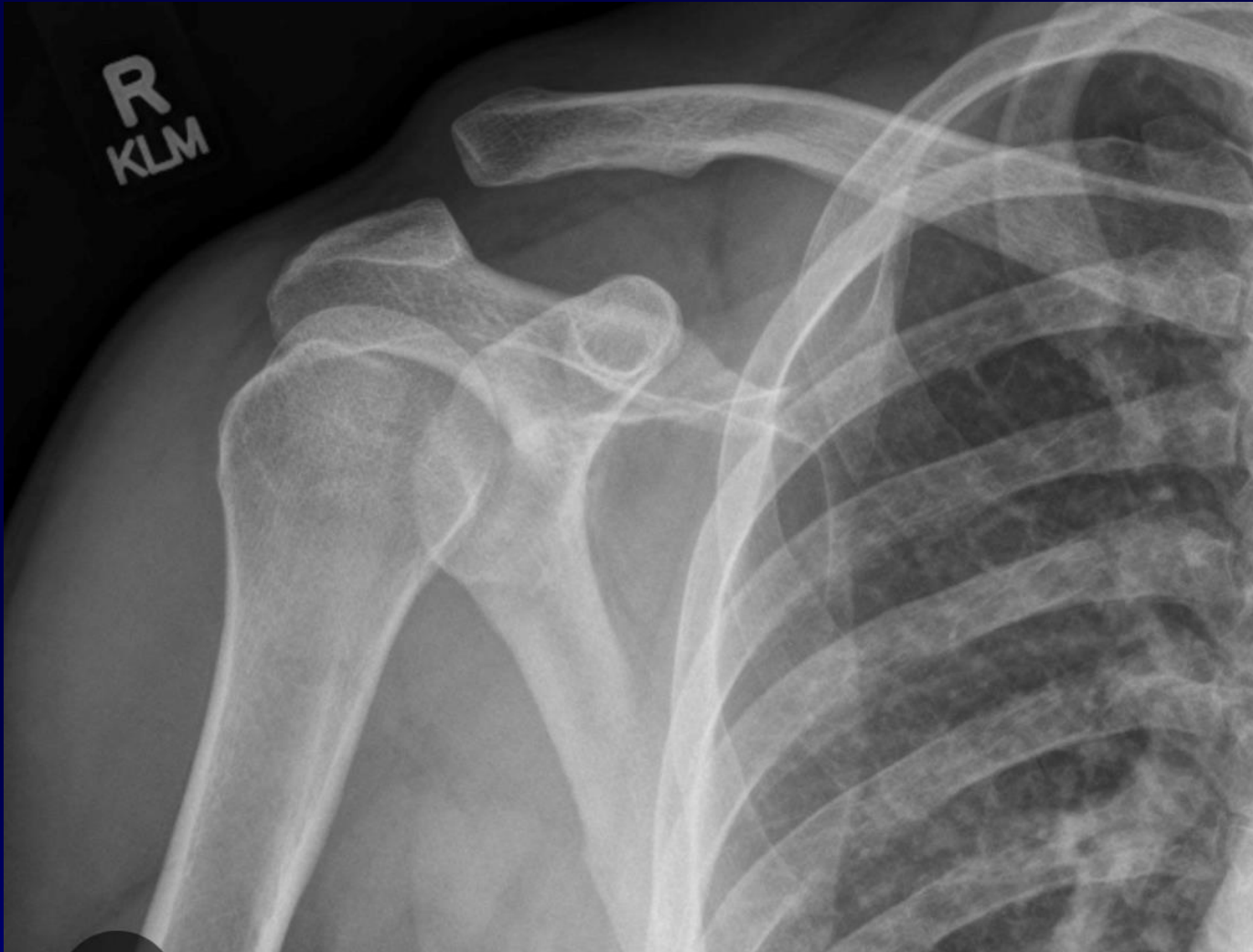
Case #2

- 28 yo male skier attempting a “jump” crashes and lands awkwardly
- Notices pain and deformity at top of his right shoulder
- Presents to the ED

Case #2



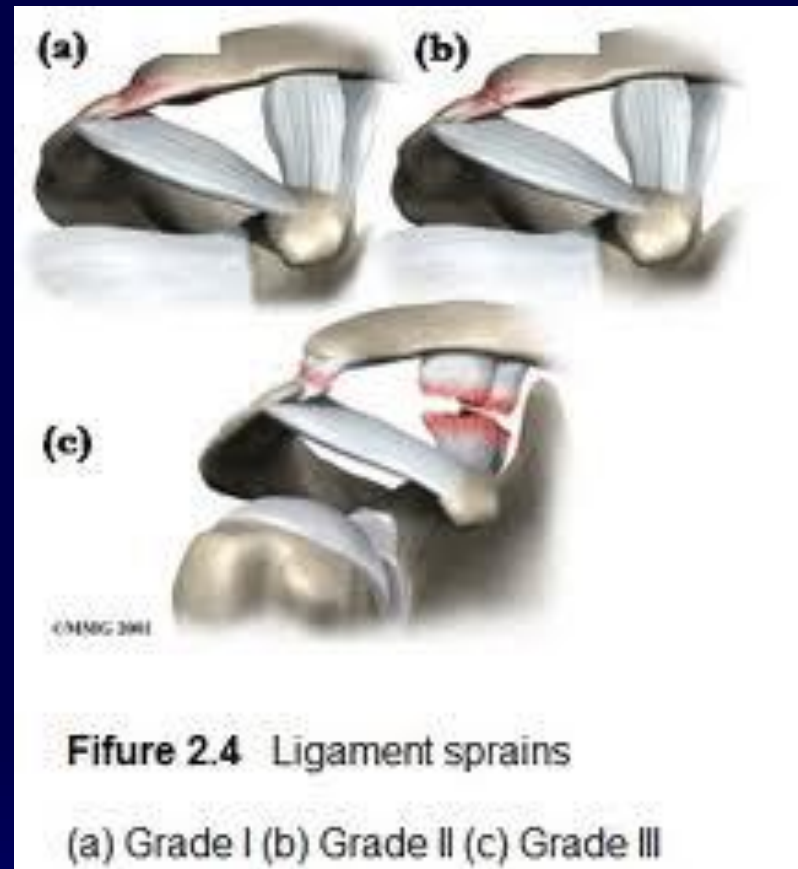
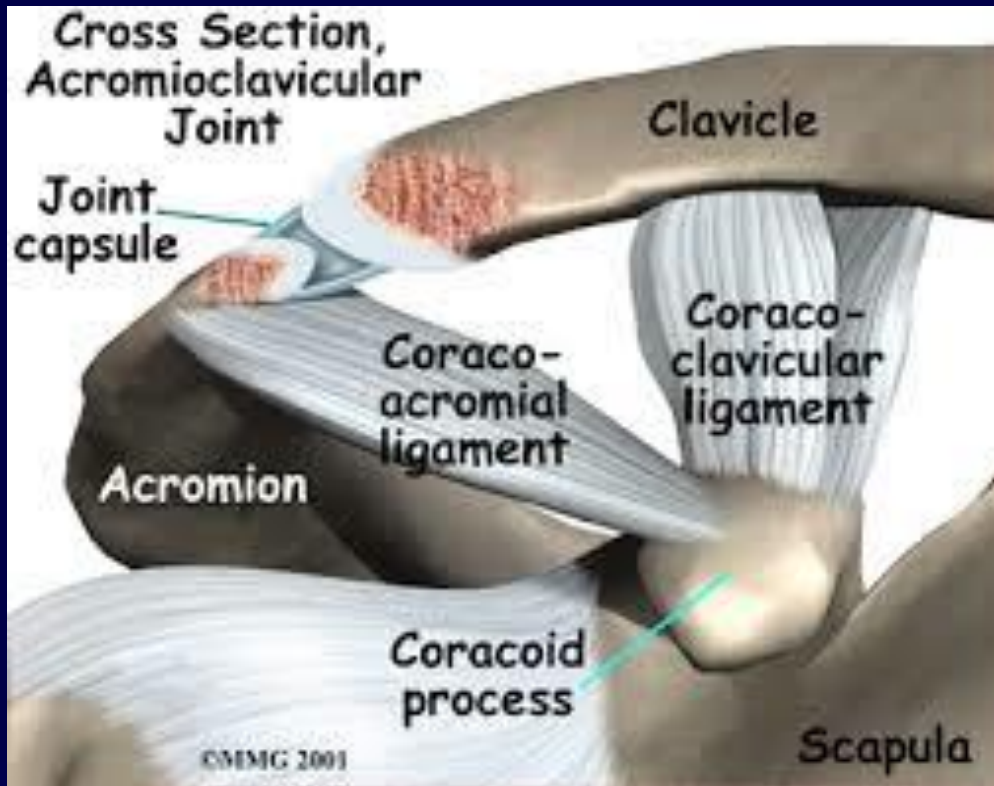
Case #2



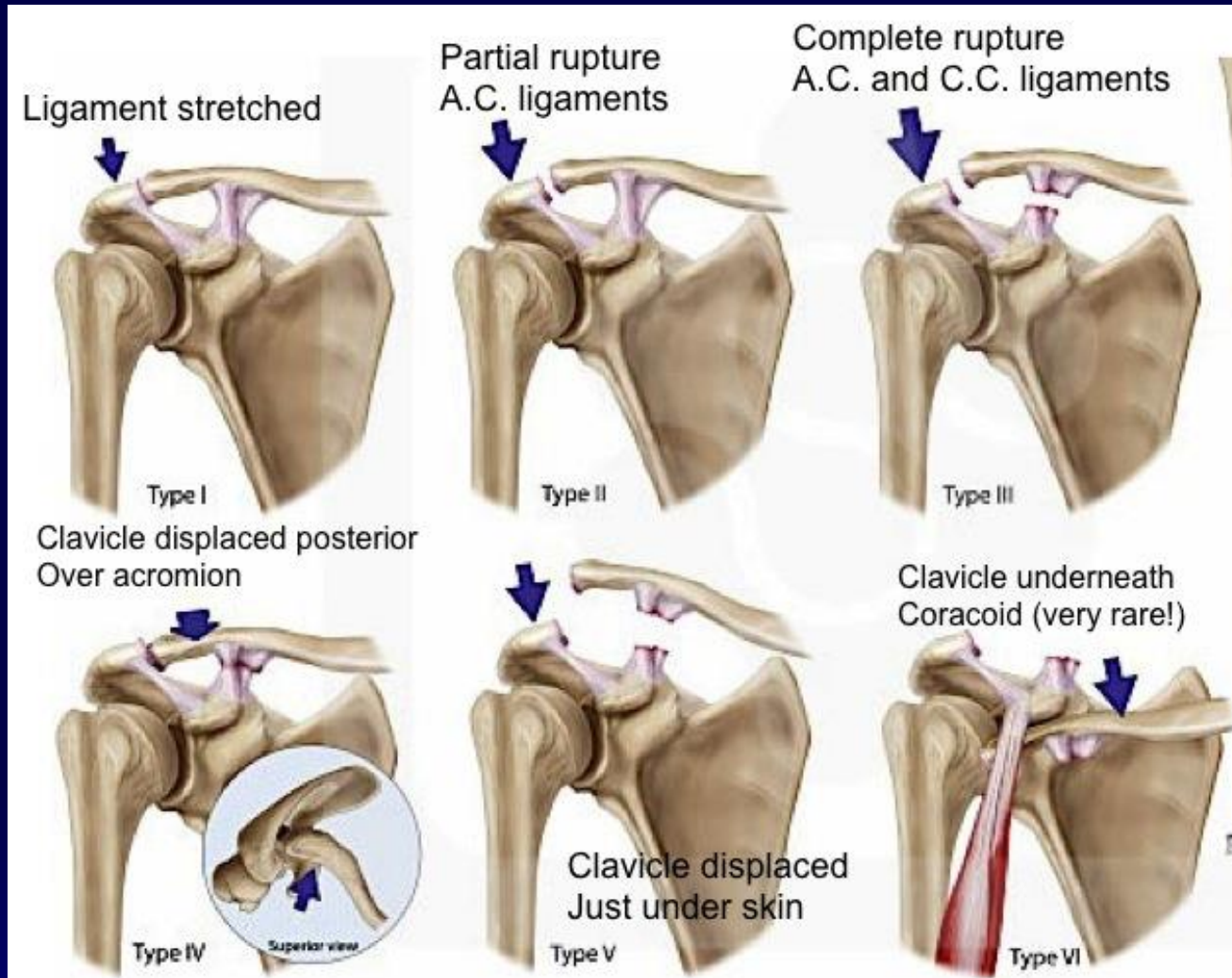
Acromioclavicular separations

- Relatively common injury resulting from a direct blow to top of shoulder
 - ❖ Bicycling
 - ❖ Snowboarding
 - ❖ Skateboarding
 - ❖ Football

Acromioclavicular Separations



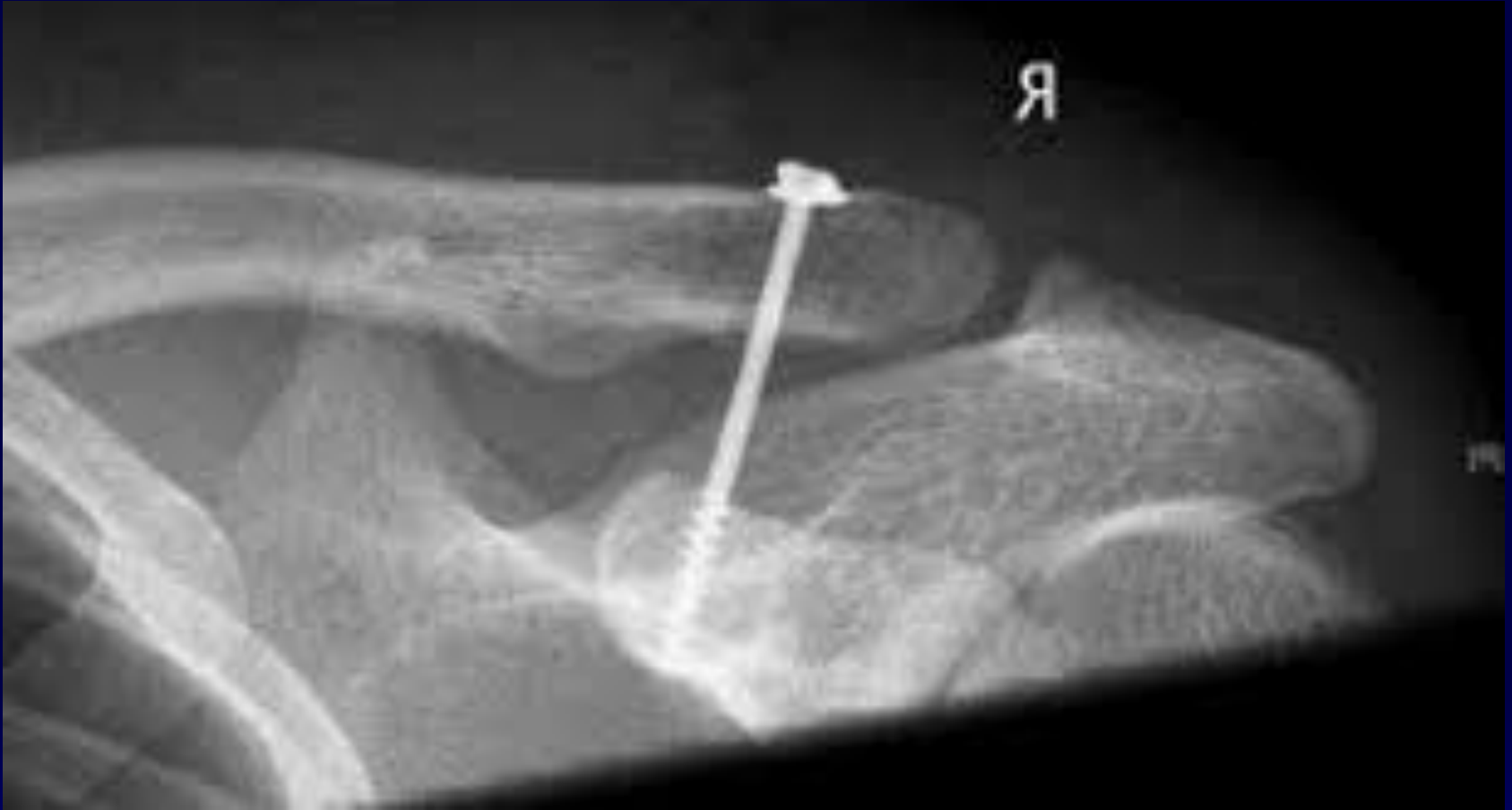Acromioclavicular separations



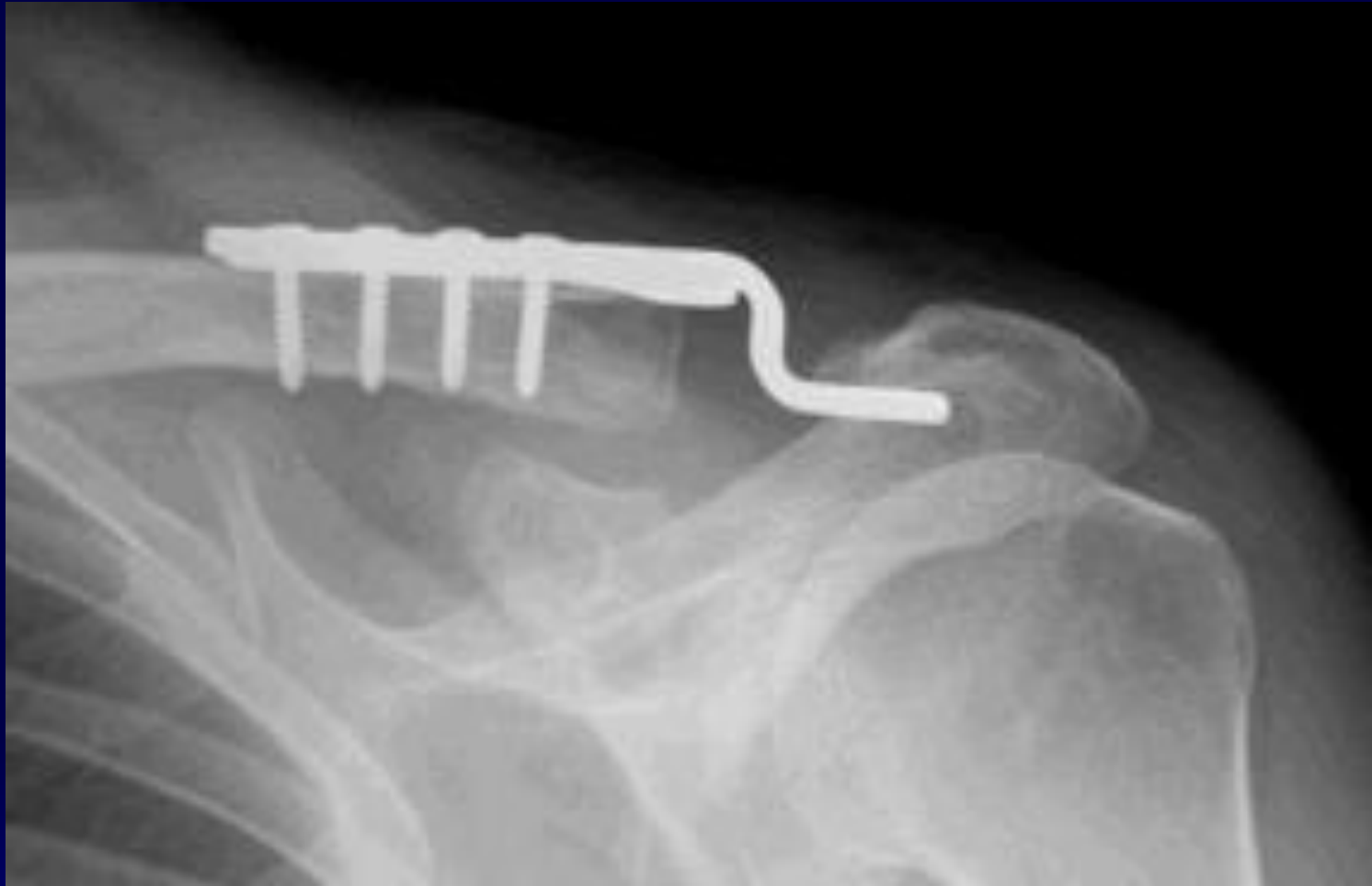Acromioclavicular separations

- Grade of injury directs management
 - ❖ 1-2: Conservative
 - ❖ 3: Controversial
 - ❖ 4+: Operative
- Numerous procedures described
- Acute injuries can be repaired/stabilized
- Anatomic reconstruction of coracoclavicular ligaments is probably best in chronic cases

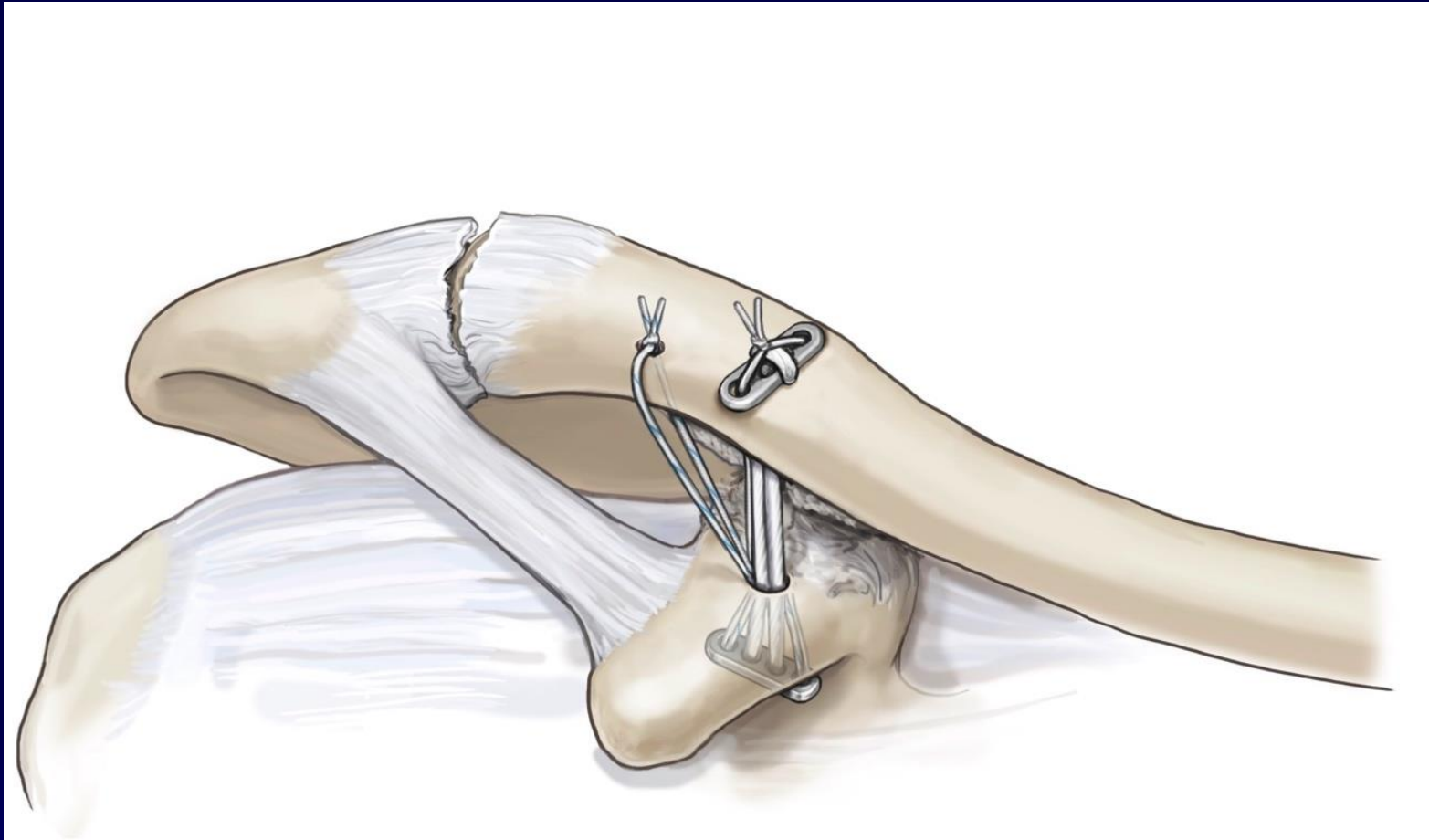
Acromioclavicular separations



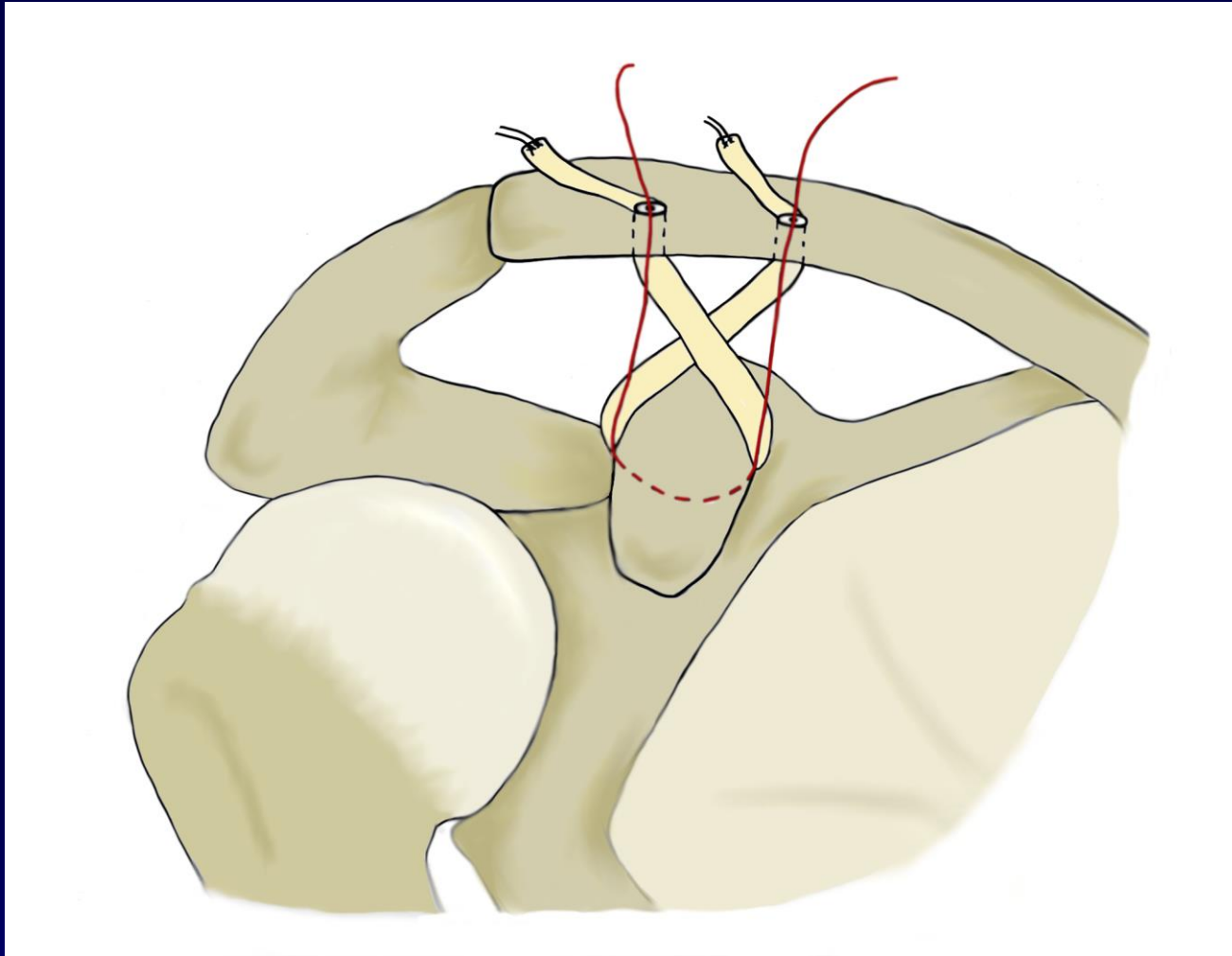
Acromioclavicular separations



Acromioclavicular separations



Acromioclavicular separations





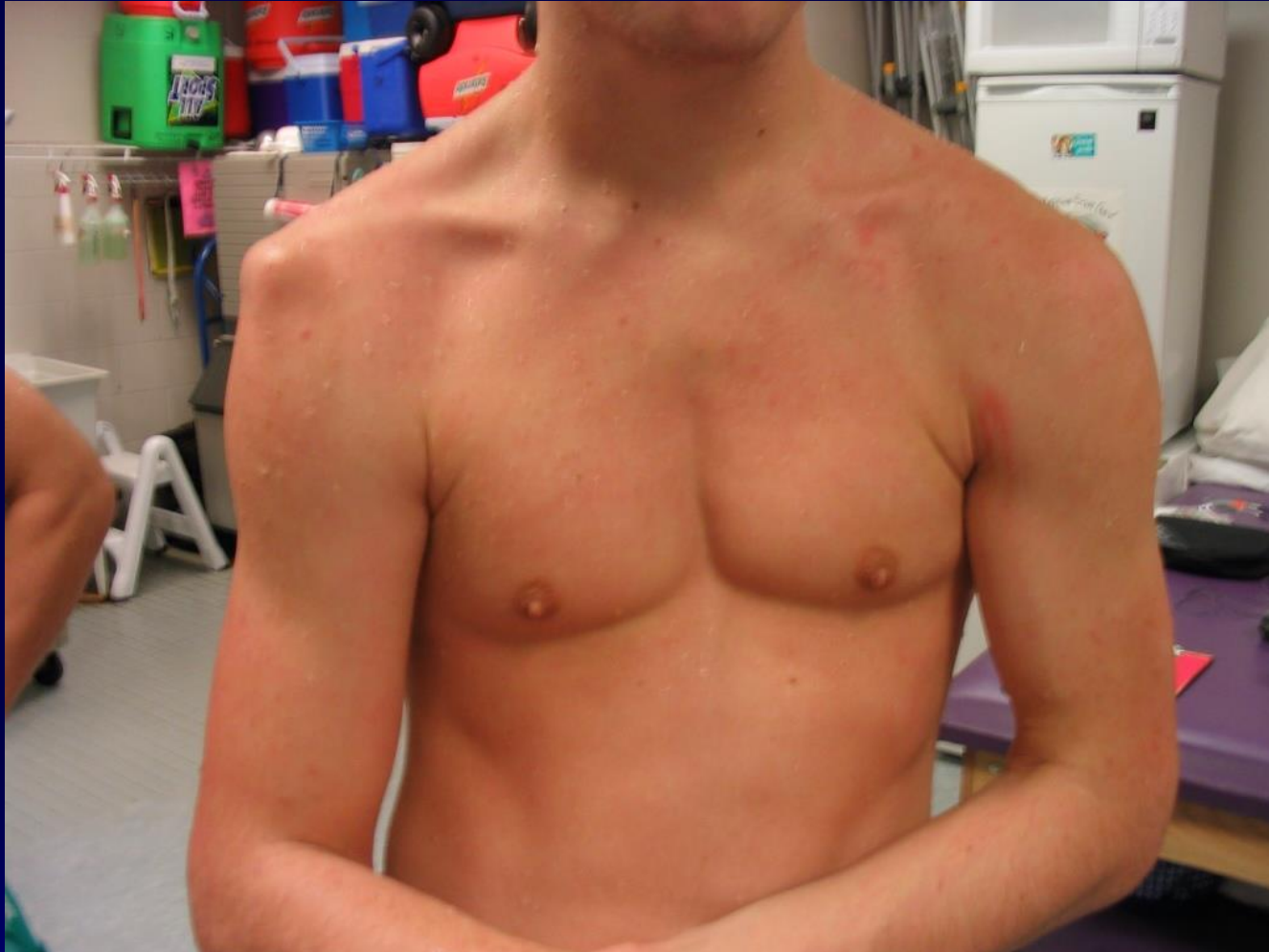TOURISTS

Maybe you should go to Disney Land next year.

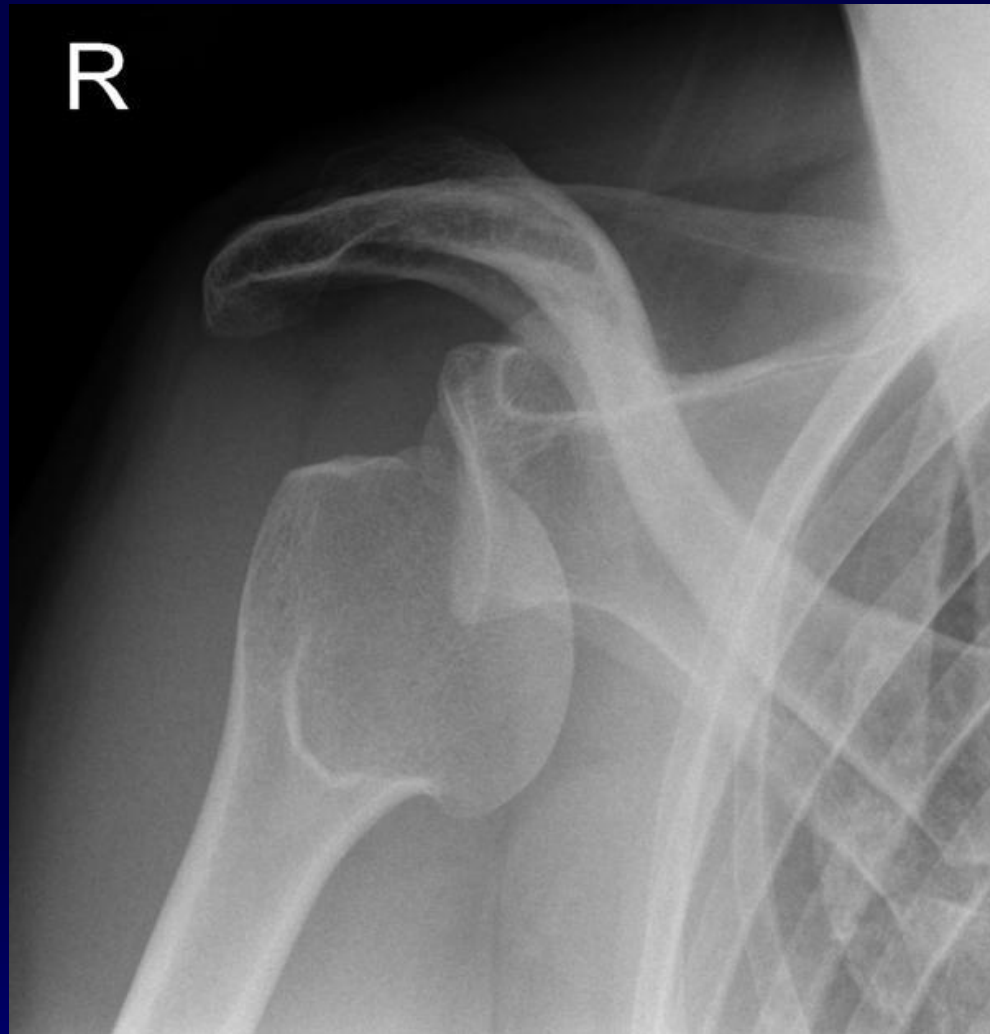Case #3

- 18yo high school football player is tackled, landing on his right extended arm
- Immediate deep pain
- Unable to move shoulder
- Taken to training room for evaluation

Case #3



Case #3



Case #3

- Diagnosis?

Glenohumeral Dislocations

- Very common injury in younger age groups
- Males (9:1)
- FOOSH
- ABER position
- Majority of traumatic dislocations are anterior/anteroinferior
- Posterior associated with epileptic seizures and electrocution

Glenohumeral Instability

- Loosely divided between traumatic and atraumatic etiology.
- Traumatic usually unidirectional
- Atraumatic usually multidirectional
- TUBS
- AMBRI

Glenohumeral Instability

- TUBS
 - ❖ Traumatic
 - ❖ Unilateral
 - ❖ Bankart lesion
 - ❖ Surgical management

Glenohumeral Instability

- AMBRI
 - ❖ Atraumatic
 - ❖ Multidirectional
 - ❖ Bilateral
 - ❖ Rehabilitation
 - ❖ Inferior capsular shift

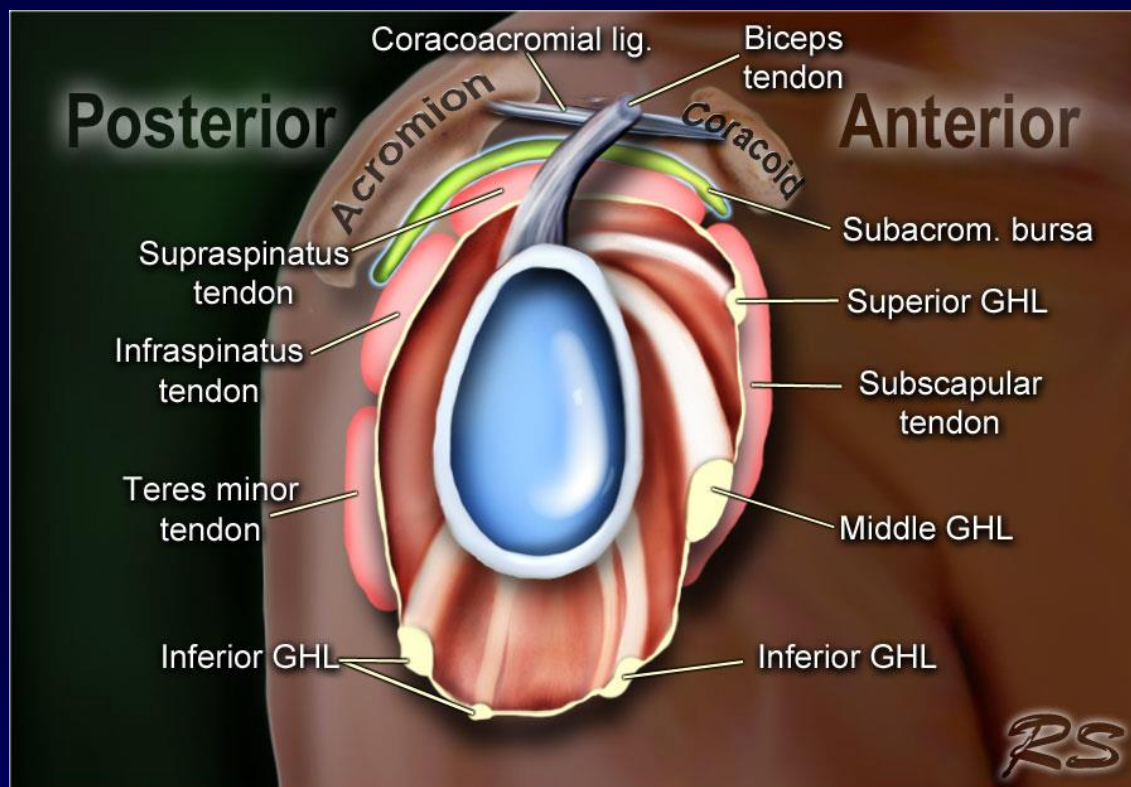
Multidirectional Instability

- Usually atraumatic
- Multiple subluxation episodes
- Often never required reduction
- “Loose-jointed”
- Positive sulcus/apprehension signs
- Management is PT, then PT, and more PT
- Inferior capsular shift or arthroscopic plication

Glenohumeral Dislocations

- Anatomy review

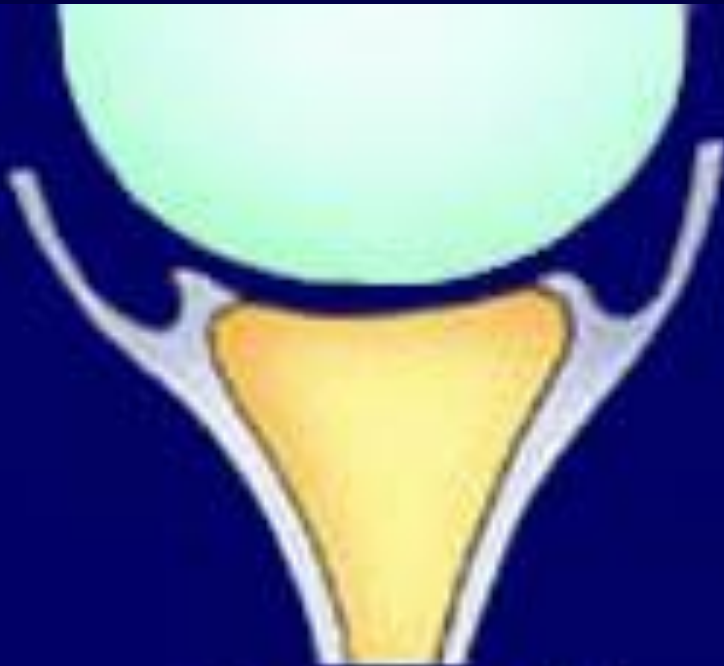
- ❖ Glenoid
- ❖ Labrum
- ❖ Capsule



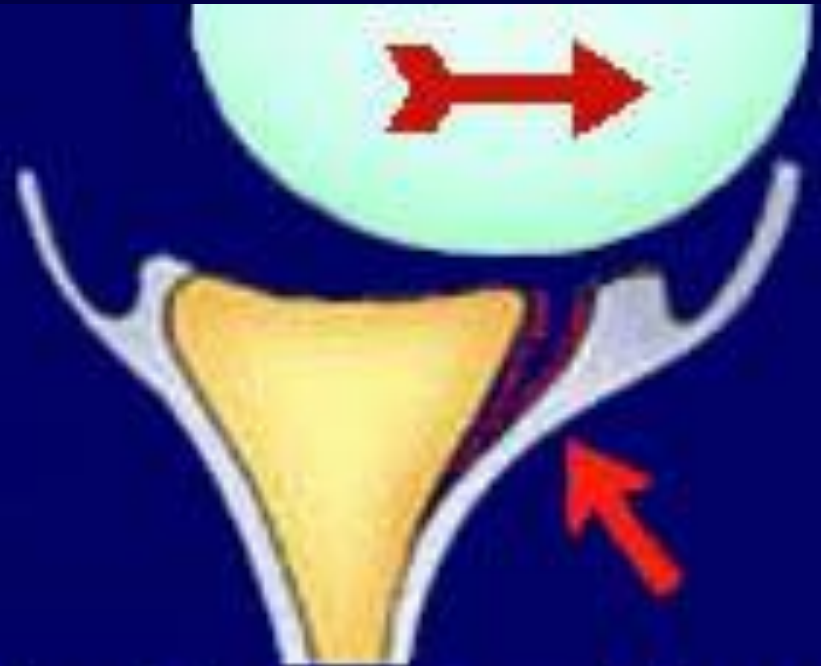
Glenohumeral Dislocations

- Bankart lesion is nearly an “essential” injury in traumatic glenohumeral dislocation
 - ❖ Capsulolabral injury
 - ❖ Bony Bankart
- Hill-Sachs lesion is a frequent concomitant injury to posterior humeral head

Glenohumeral Dislocations

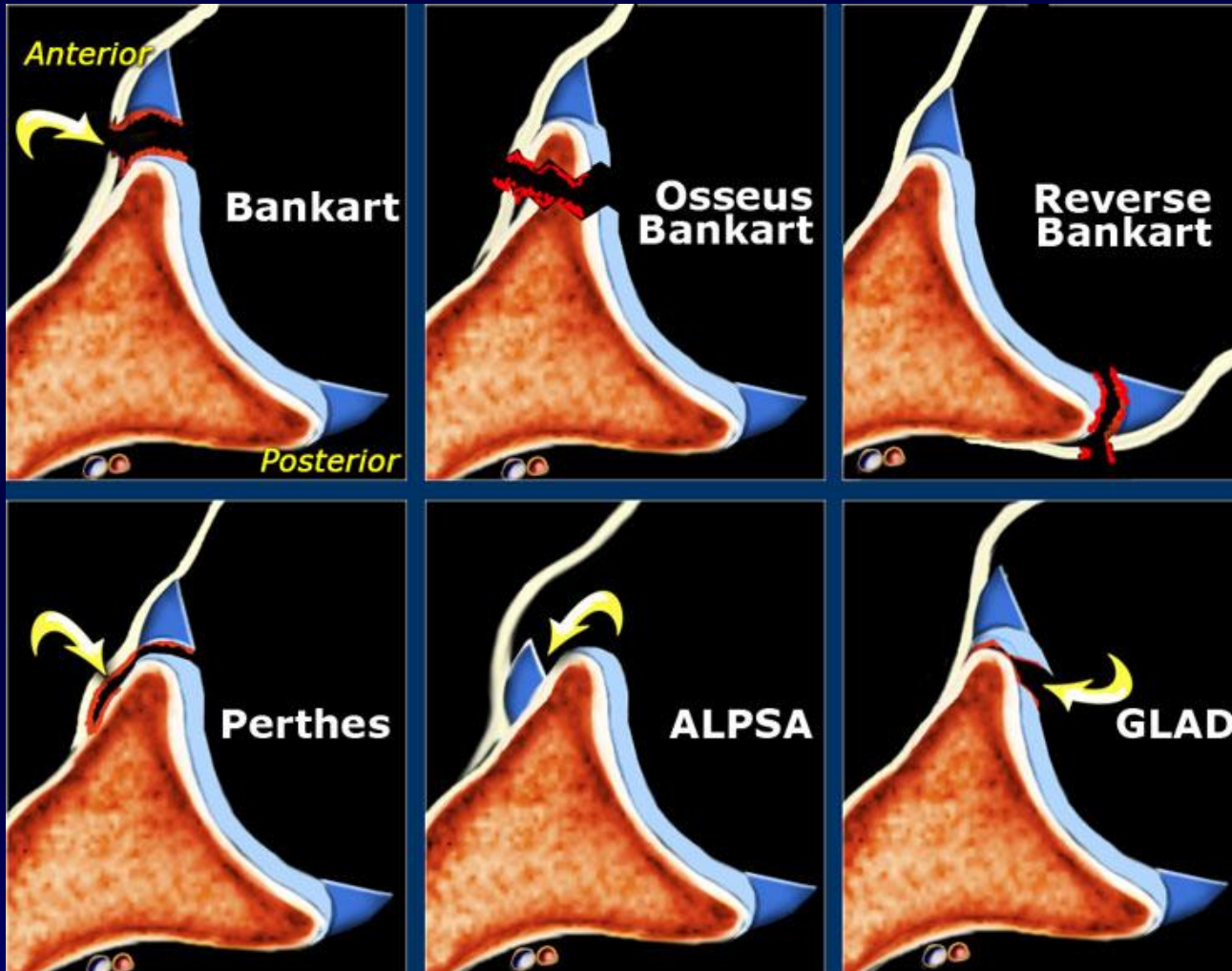


Normal

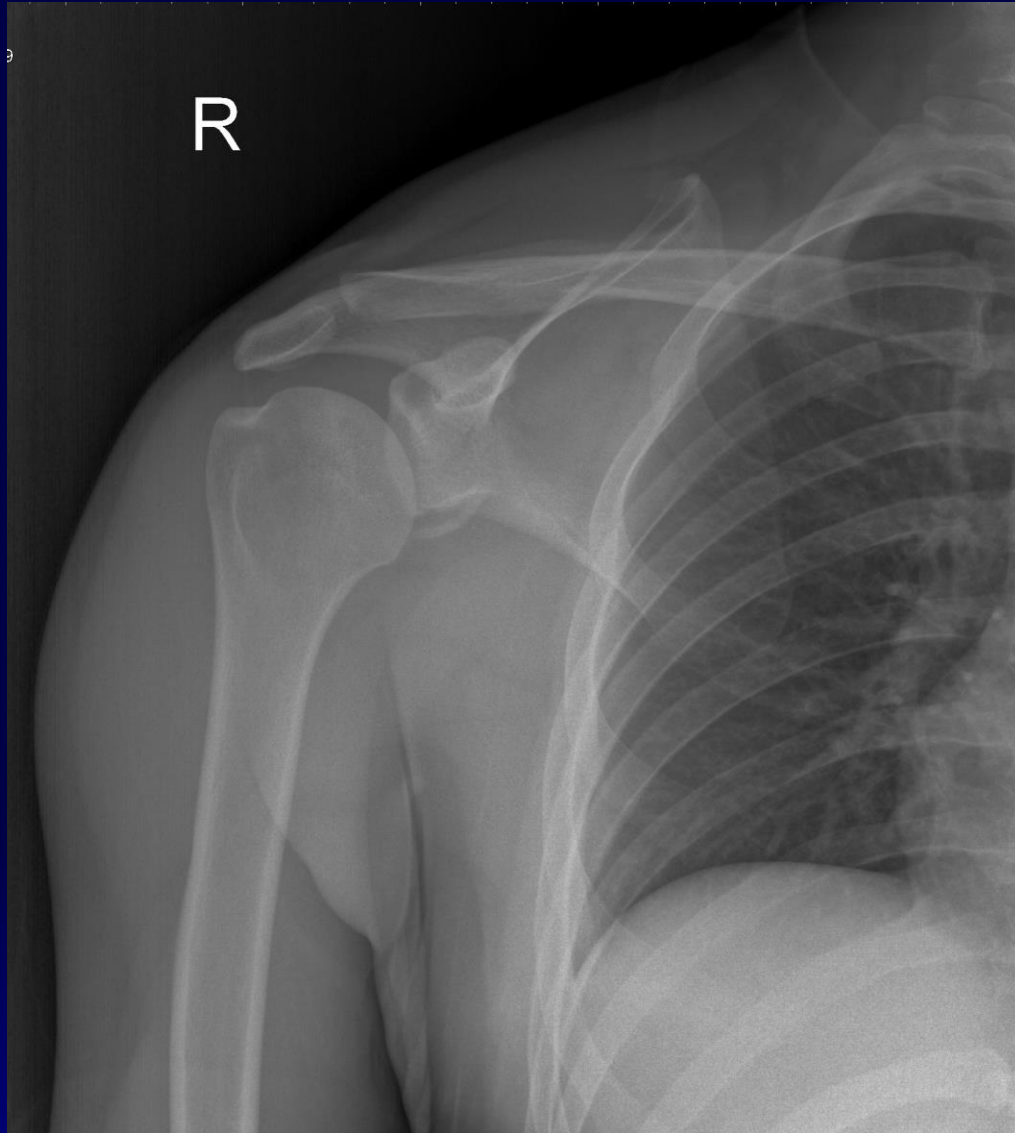


Bankart Lesion

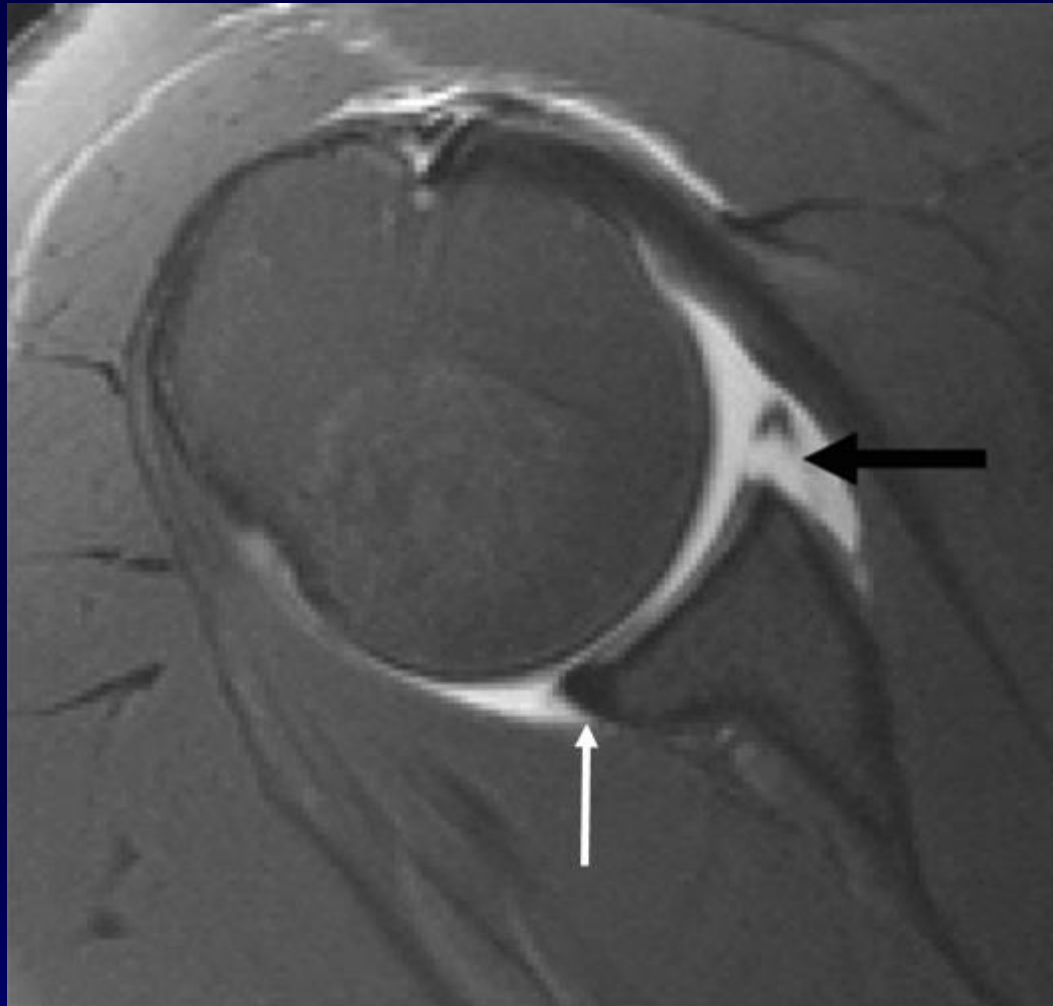
Bankart and Friends



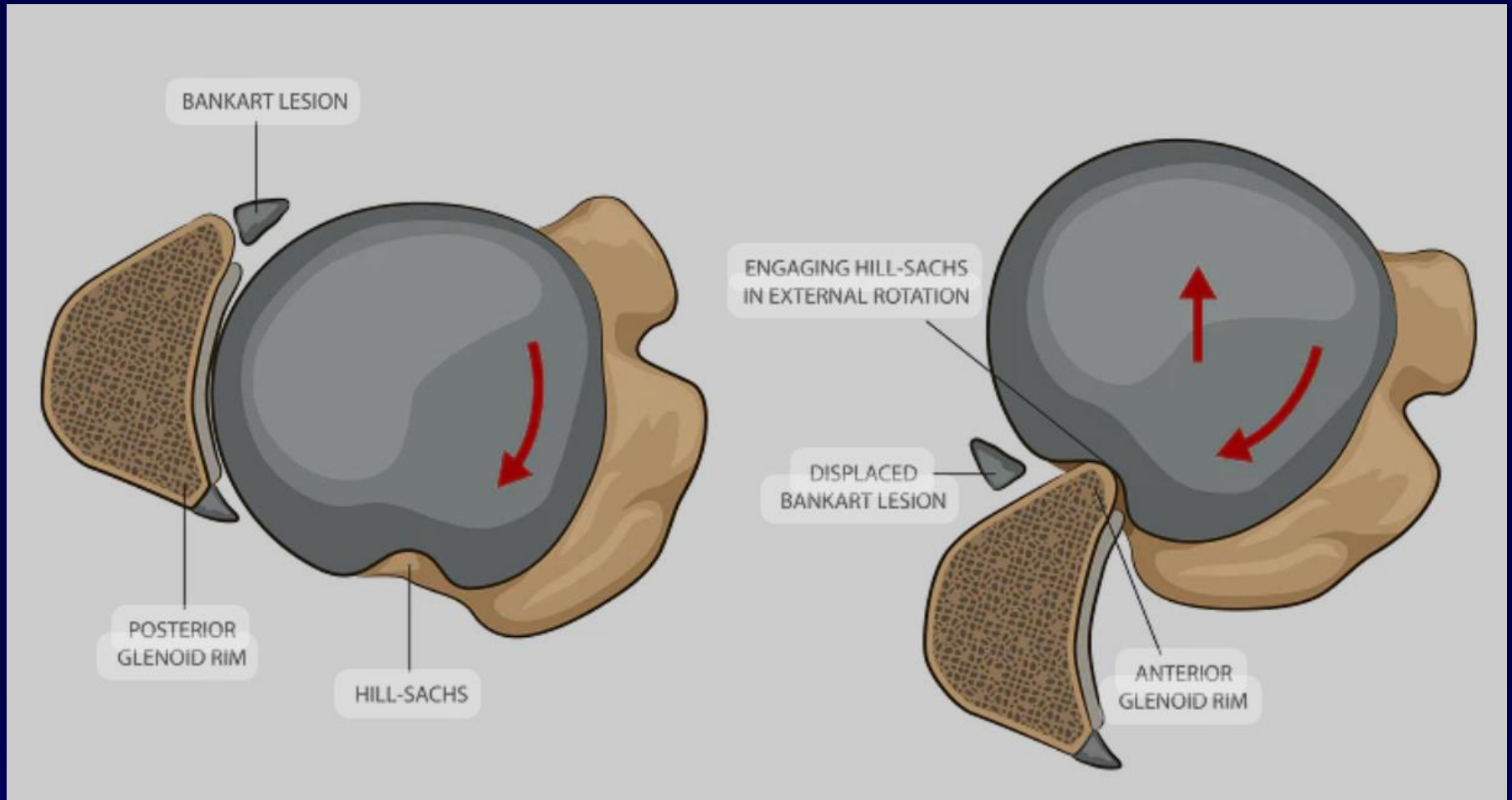
Bony Bankart – X-Rays



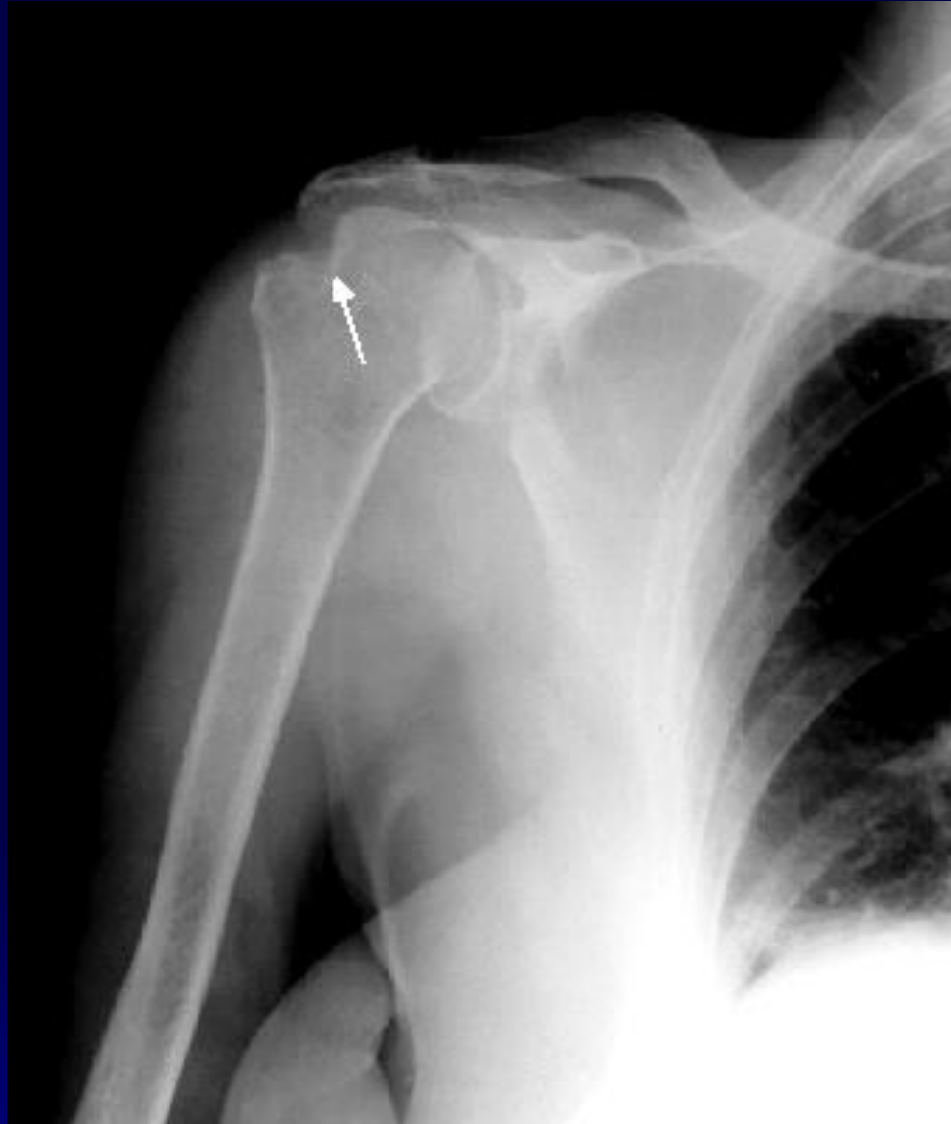Bankart - MRI



Hill-Sachs Lesion



Hill-Sachs Lesion



Glenohumeral Dislocations

- Examination
 - ❖ Sulcus sign
 - ❖ Prominent acromion
 - ❖ Held in IR with limited AROM/PROM
- Imaging
 - ❖ Plain X-rays diagnostic (axillary view!)
 - ❖ MRI arthrogram shows Bankart
 - ❖ CT best for determining glenoid bone loss

Glenohumeral Dislocations

- Management
 - ❖ Closed reduction under anesthesia
 - ❖ Sling immobilization
 - ❖ Pain management
 - ❖ PT/Rehabilitation
 - ❖ Surgery?
 - ❖ Recurrent instability

Glenohumeral Dislocations

- Recurrent instability
 - ❖ Rates of re-dislocation higher in young Pts
 - ❖ 67% of first time dislocators will have a second
 - ❖ 90% of two-time dislocators will have a third

Simonet and Cofield. Am J Sports Med, 1984.
- Some surgeons have recommended operative management of first time dislocators, especially young athletes

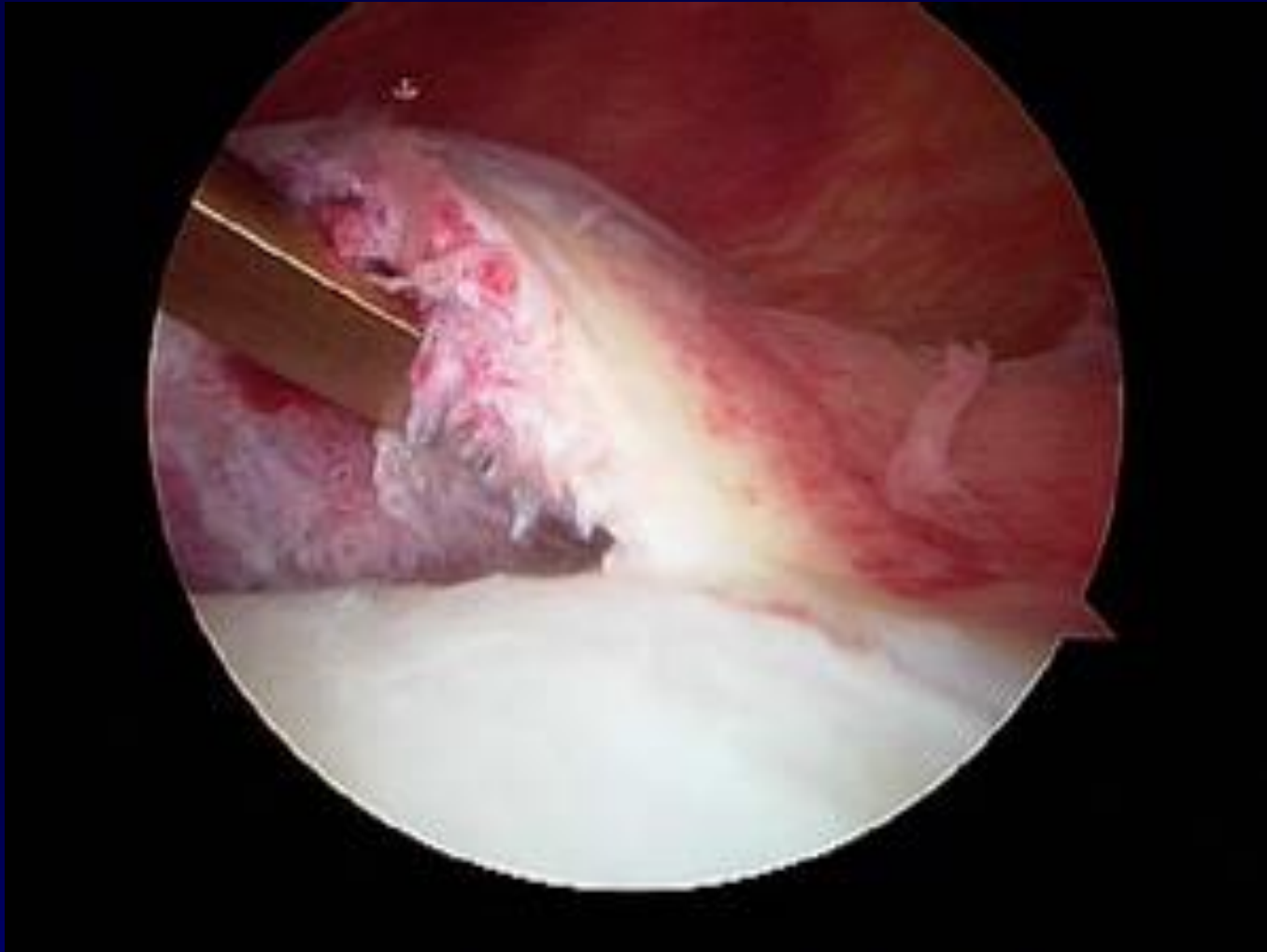Recurrent Instability

- Age at first dislocation is most important factor in predicting recurrence
 - ❖ 0-20% in Pts older than 40 years
 - ❖ 40-60% in Pts 20-30 years old
 - ❖ 66-95% in Pts younger than 20 years old
 - ❖ Almost 100% in Pts with open growth plates

Simonet and Cofield. Am J Sports Med, 1984.

Nevaiser et al. J Shoulder Elbow Surg, 1995.

Bankart Lesion



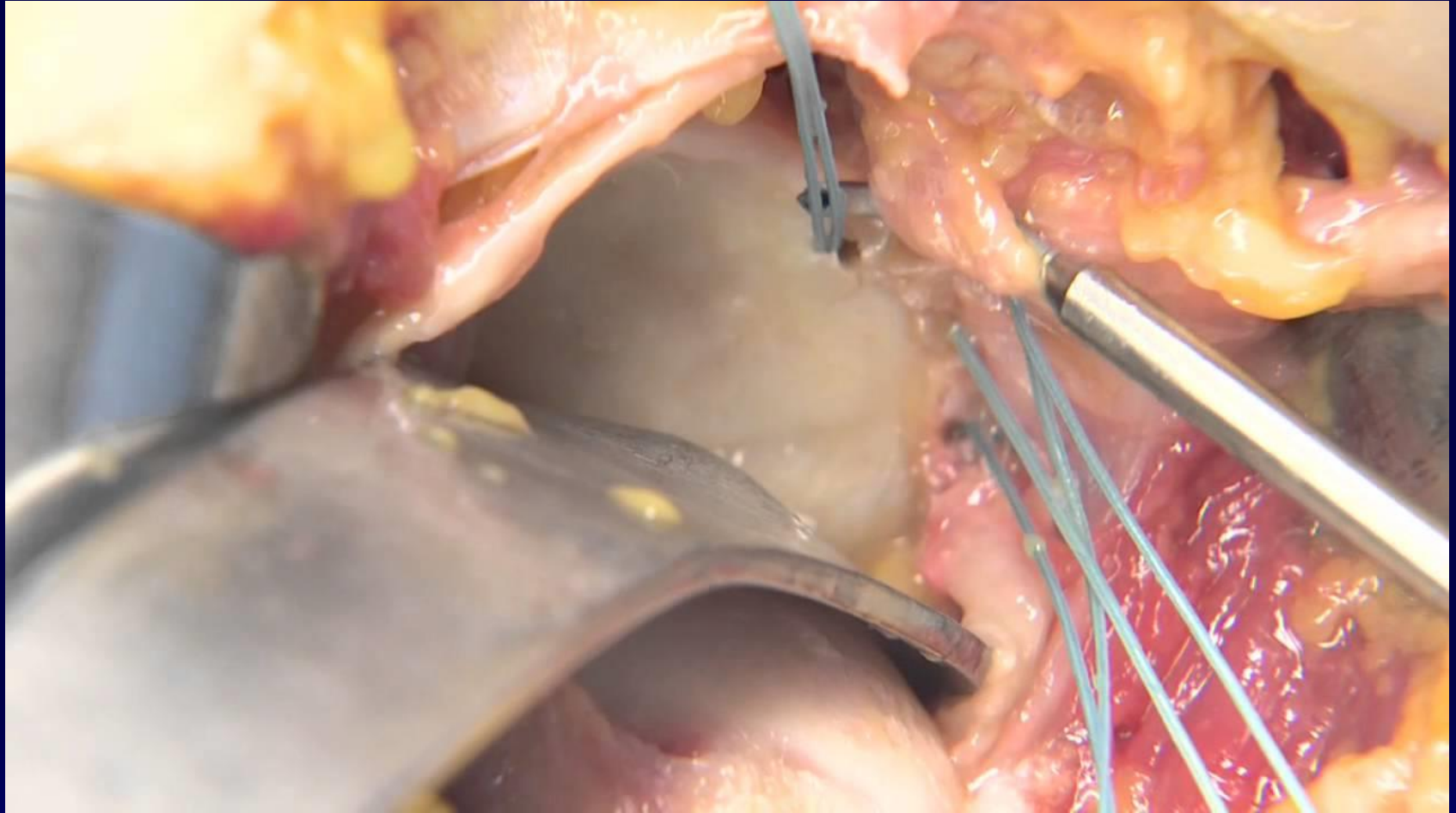
Treatment Options

- Conservative
- Surgical
 - ❖ Open Bankart repair/capsular shift
 - ❖ Arthroscopic Bankart repair

Open Bankart Repair

- Limited deltopectoral incision
- Labrum reattached to articular edge
 - ❖ Bone tunnels
 - ❖ Suture anchors
- Knots on outside of capsule
- Independent lateral capsular shift
- Overlapped capsular flaps

Open Bankart Repair



Open Bankart Repair

- 161 Pts
- Bone defects
 - ❖ Glenoid 77%
 - ❖ Hill-Sachs 78%
- Only 5 recurrences
- 97% satisfied

Rowe. J Bone Joint Surg 1978

Open Bankart Repair

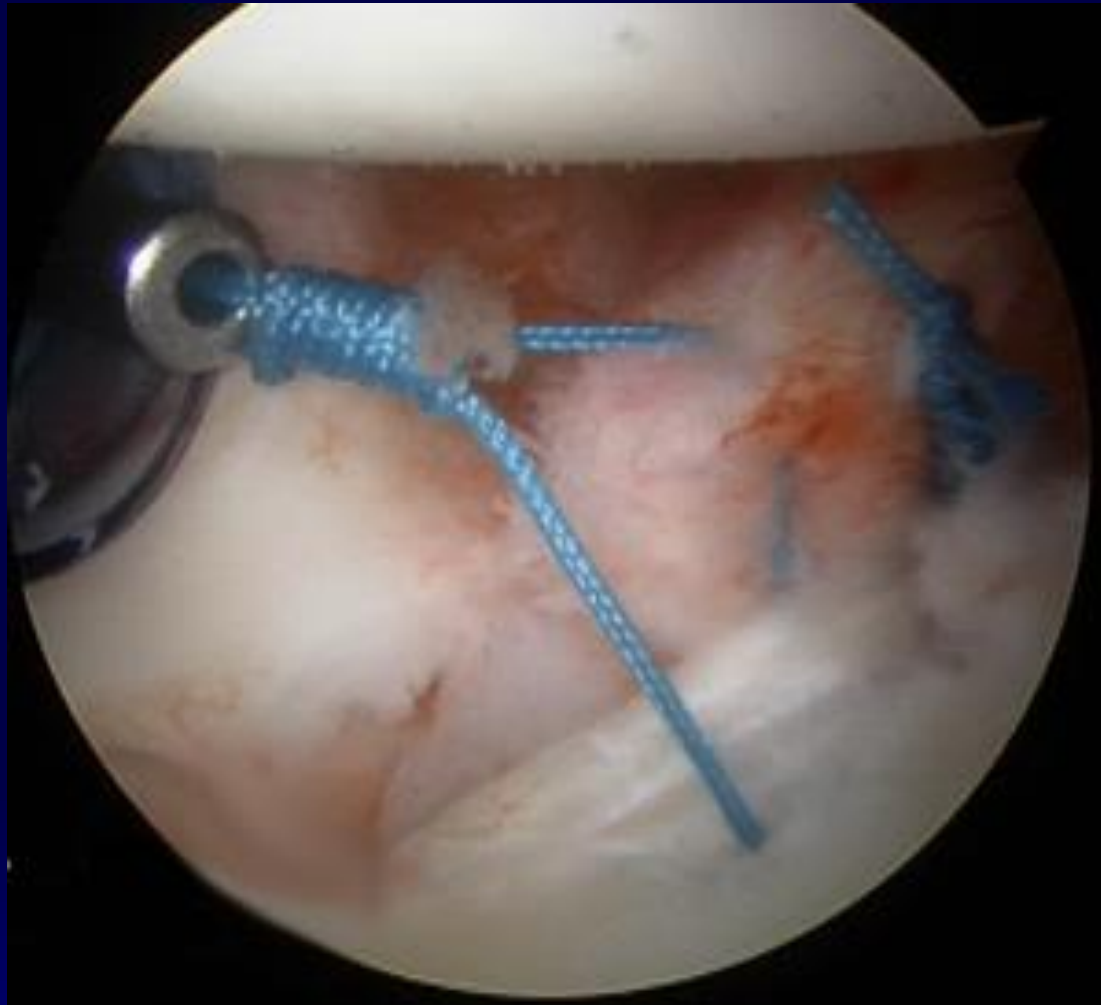- 103 Pts
- 85% collision athletes
- Bone defects
 - ❖ Glenoid bone loss 14%
 - ❖ Hill-Sachs 84%
- 2 recurrences!

Pagnani. Am J Sports Med 2008

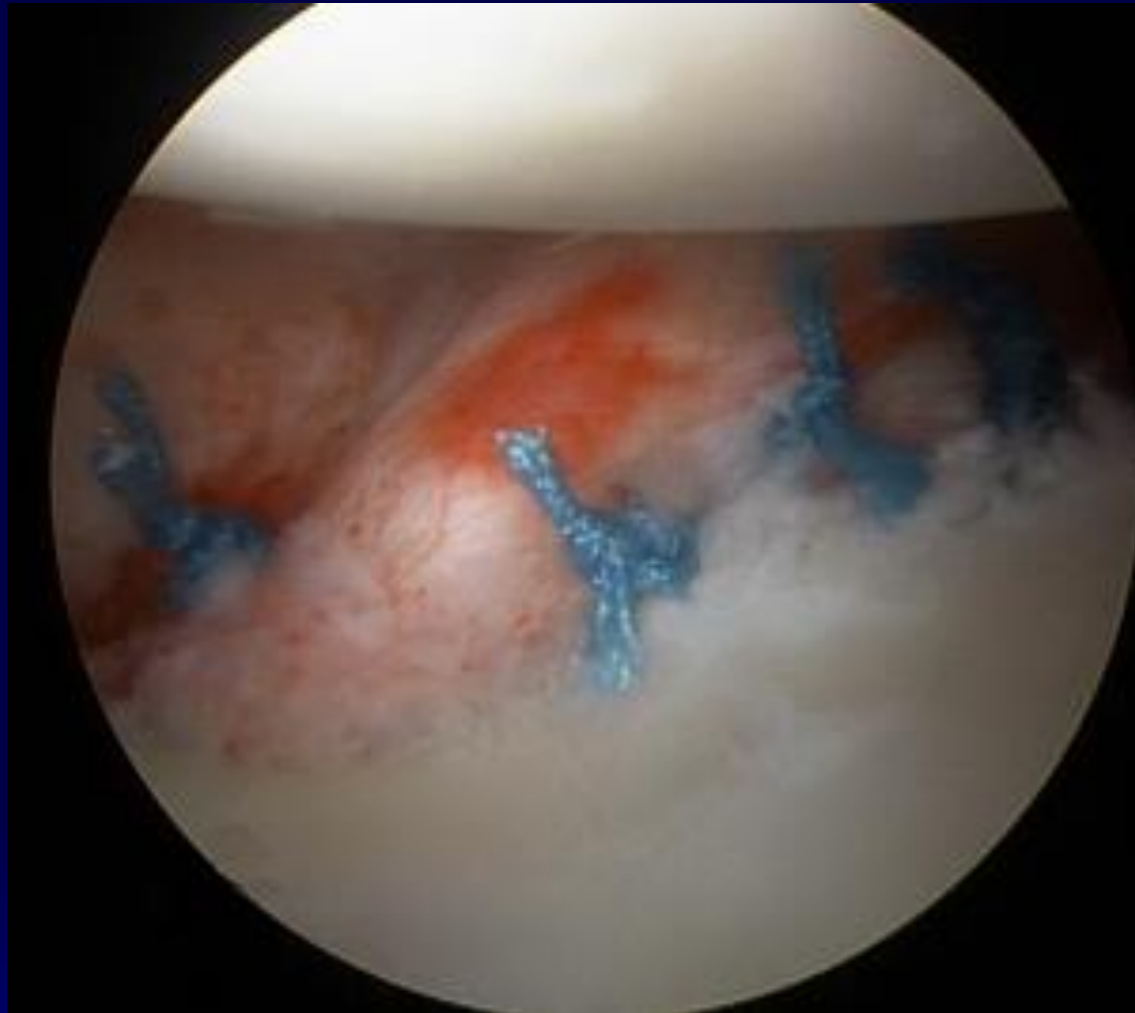
Arthroscopic Bankart Repair

- Less invasive, smaller incisions
- Shorter operative time
- Faster recovery
- Lower incidence of neurovascular injury
- More elegant
- Better in every way?!?

Arthroscopic Bankart Repair



Arthroscopic Bankart Repair



“Those who do not remember the past are
condemned to repeat it”

--George Santayana

Recurrent Instability

- 79 open repairs, 83 arthroscopic
- WOSI scores: No difference
- Recurrence rates:
 - ❖ Open 11%
 - ❖ Arthroscopic 23%

Mohtadi et al. J Bone Joint Surg, 2014

Recurrent Instability

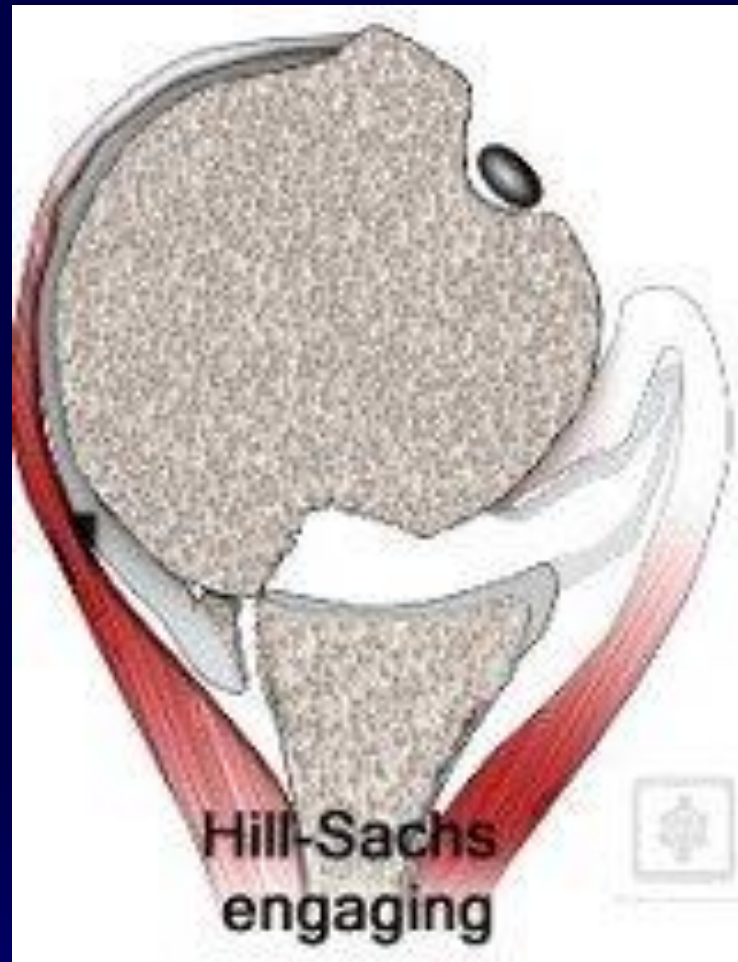
- Consider mechanism
- Beware of glenoid bone loss, especially in multiple time dislocators
- CT scan with 3D recons
- Most will require surgical management
- Bone augmentation
 - ❖ Latarjet
 - ❖ Bone graft

Bone Loss

- Humeral side
- Glenoid side
- Both (“Bipolar”)

- “On track” vs. “Off track” lesions

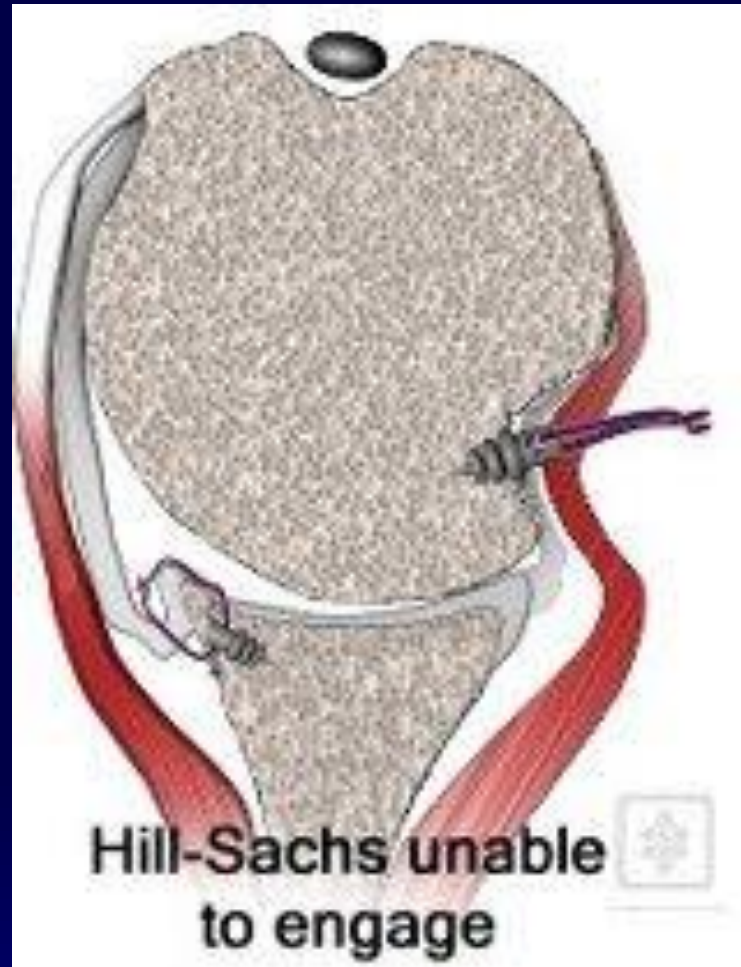
Itoi 2017



Remplissage

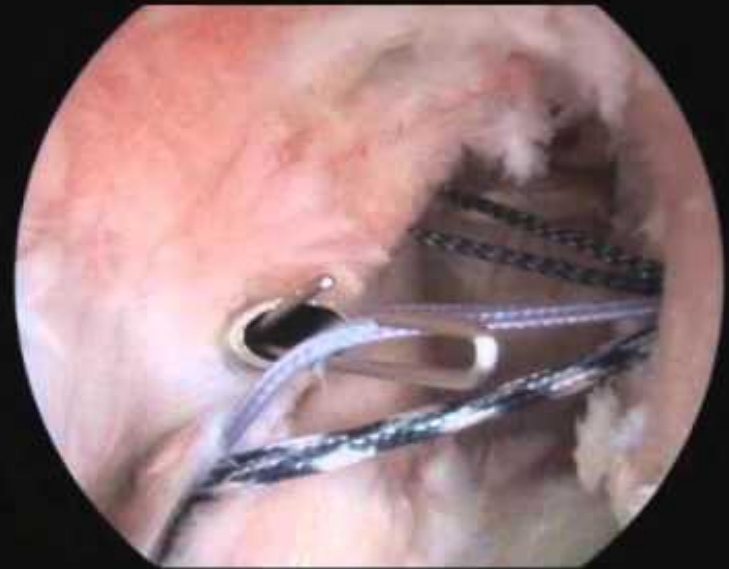
- Insertion of infraspinatus tendon into Hill-Sachs lesion

Wolf et al. J Shoulder Elbow Surg, 2014.



Remplissage

- Can be done arthroscopically!
- Learning curve
- Adds +/- 10 min. to Bankart repair

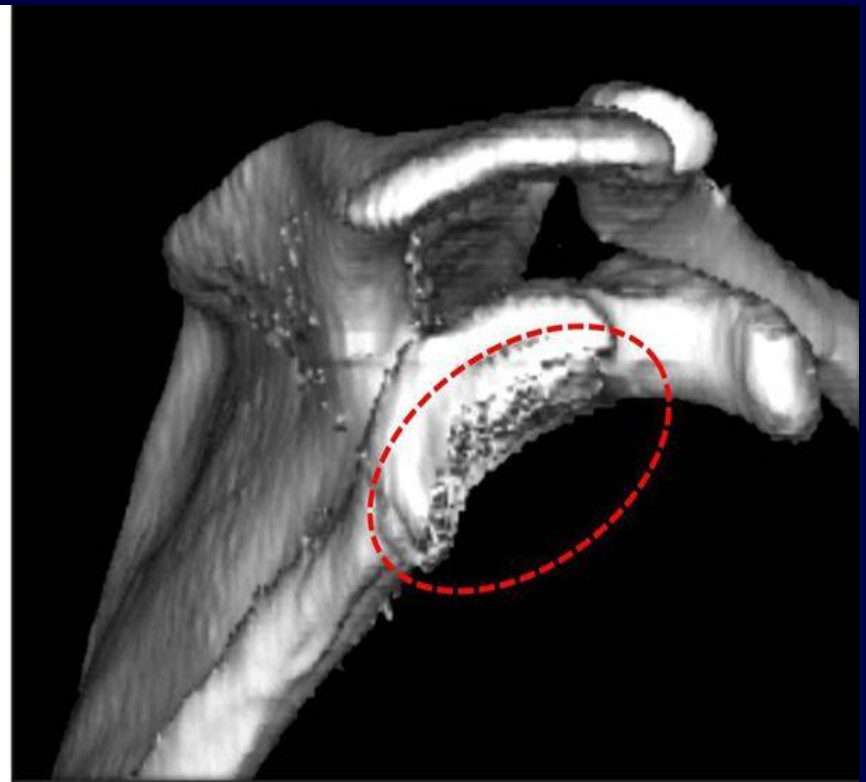
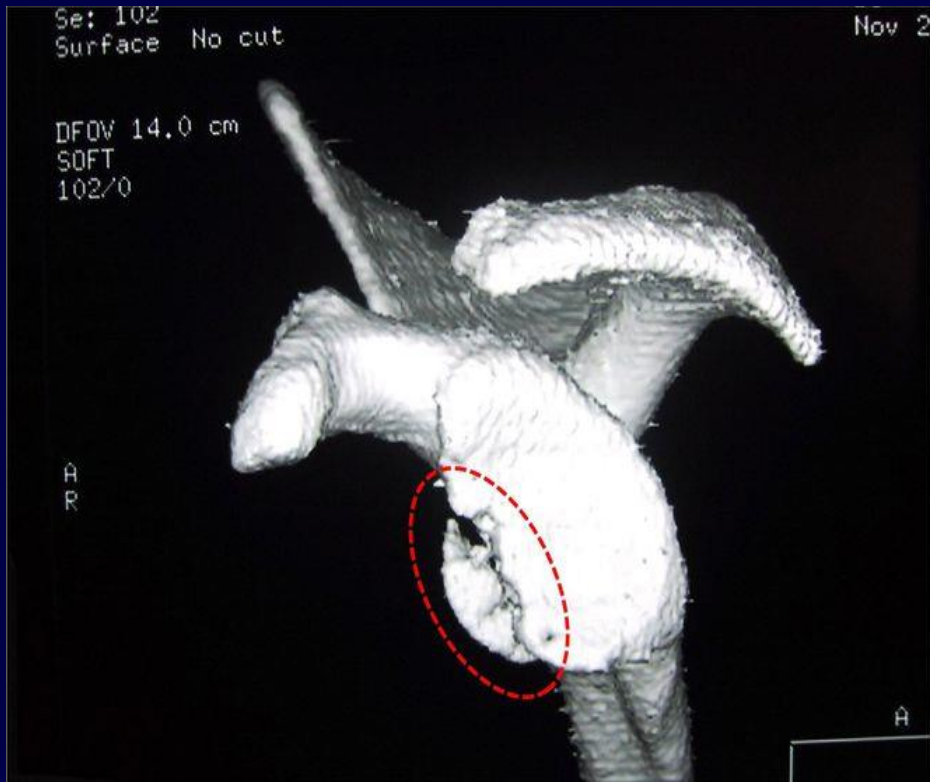
Remplissage

- 50 patients (Average 29 yo)
- “Off track” Hill-Sachs lesions
- 60 months average follow-up
- Redislocation rate 11%
- 95.5% return to sport
- Loss of ER 5.3 degrees

Garcia et al. Am J Sports Med, 2016.

Glenoid Bone Loss



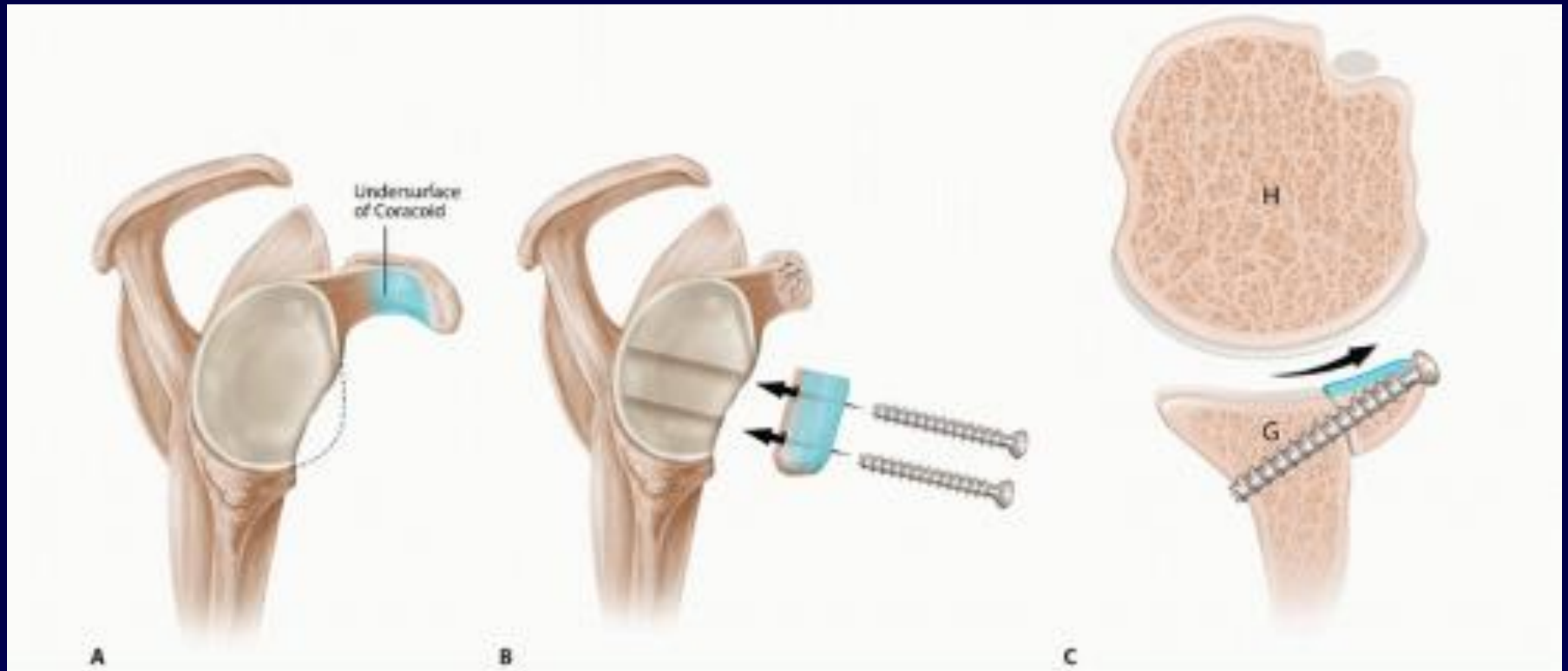
A

B

Latarjet Procedure

- Described in 1954
- Modified to be performed through subscapularis split
- “Triple blocking effect”
 - ❖ Increased bony arc
 - ❖ Sling effect of subscapularis
 - ❖ Capsular tightening
- Some surgeons performing arthroscopic

Latarjet Procedure

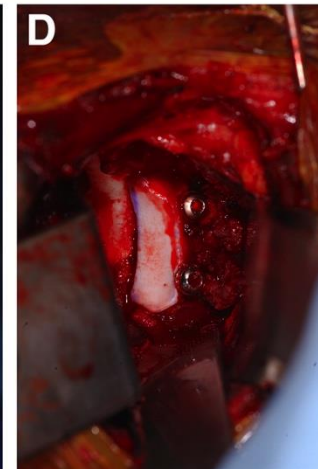
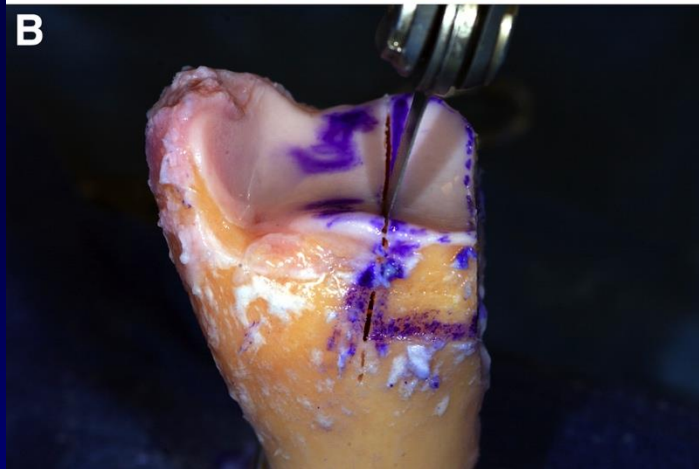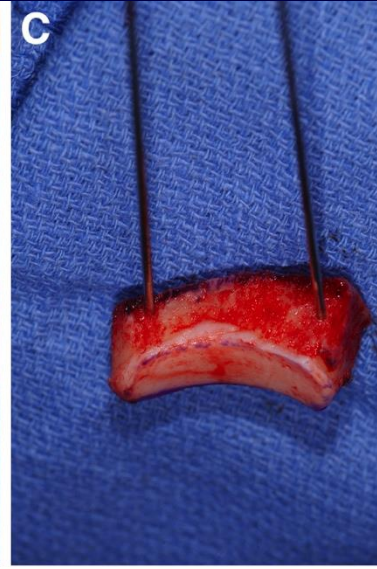
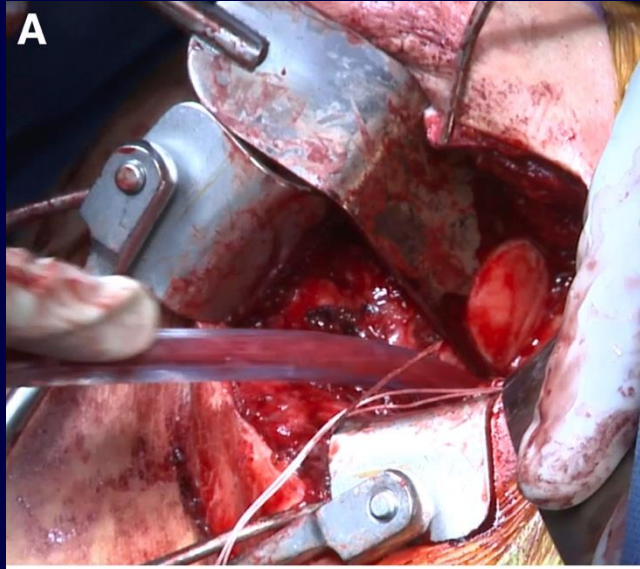


Distal Tibial Allograft

- Easy to prepare
- No morbidity from coracoid harvest
- Less pain/easier recovery
- Comparable results to Latarjet
- Fewer complications?

Provencher et al. Arthroscopy 2009

Distal Tibia Allograft



Take Home Points

- Recognize common shoulder injuries in the young athlete
- Formulate differential diagnoses
- Recommend initial treatment plans:
 - ❖ Immobilization
 - ❖ Pain Management
 - ❖ Imaging
 - ❖ Definitive treatment
 - ❖ Rehabilitation



Thank You!
bensencv@gmail.com
828-773-9227