

# The Larson Maneuver: A Lesser-Known Technique for Managing Laryngospasm



Craig I. Matsumoto, DHSc, PA -C

Institute for Physician Assistant Education  
College of Health & Human Services

## Abstract

**Objective:** To inform Physician Assistants (PAs) and PA Students on the laryngospasm relieving technique of Laryngeal Notch Pressure (LNP) also known as the Larson Maneuver.

**Methods:** The primary databases utilized to retrieve the salient medical literature presented in this review were Publisher MEDLINE (PubMed), the Cumulative Index to Nursing and Allied Health Literature (CINAHL Complete), and Google Scholar. The search terms, used both separately and in combination, included: "Larson Maneuver," "laryngospasm," "laryngospasm notch," "laryngeal notch," "intervention," "mechanism," and "anesthesia." Only articles or published correspondence in English or with English translation were included.

**Results:** Ten (10) publications met search criteria. Seven (7) of those were reviewed as directly reporting to LM deployment. No well controlled studies on LM technique, utilization, or effectiveness were identified. All publications were case reports reflecting successful technique utilization.

**Conclusion:** While LNP has not been established as effective via controlled studies, case reports seem to indicate this technique can provide a high yield result against a low cost of time and effort. LM seems easy to learn, use, and is easily integratable into established guidelines for acute laryngospasm management.

## Introduction

Laryngospasm is a feared and often unpredictable emergency airway event. It involves the spastic complete or partial closure of the glottis. An exaggerated airway protection reflex occurs, which should normally maintain the sterility of the lower airway. The resulting compromised airflow results in hypoventilation and hypoxia.<sup>1</sup> Lack of timely recognition or ineffective treatment is associated with significant morbidity and mortality. The internal branch of the superior laryngeal nerve (as a branch of the vagus nerve) normally innervates the extrinsic and intrinsic muscles of the larynx. Periods of anesthetic transition (induction and emergence) are associated with a higher risk of abnormal reflexive excitation resulting in laryngeal spasm. The incidence of laryngospasm in both adults and children across all occurrences has been estimated at just below 1% laryngospasm occurrence is greater in children than adults.<sup>2</sup>

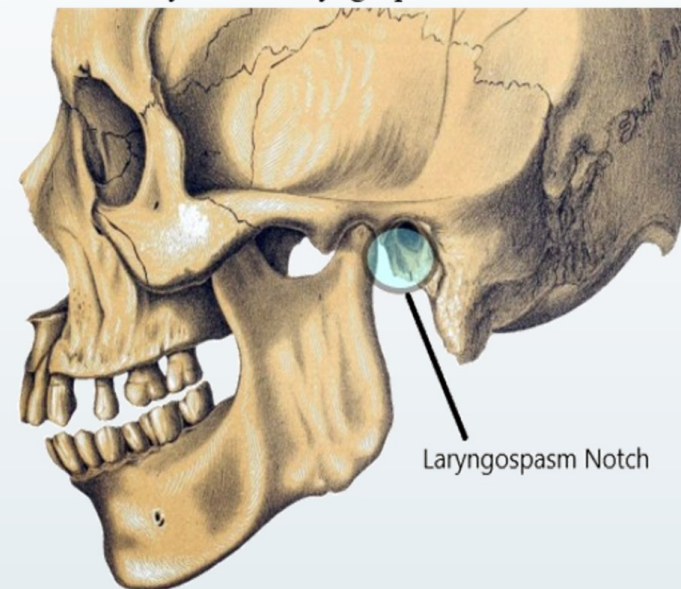
Airway management for laryngospasm is categorized as procedure management, mechanical, and pharmacologic intervention. Timely actions are paramount as laryngospasm severity and duration increase hypoxia potential. Michelet & Truchot, et al. outlined accepted interventions for anesthesia management of laryngospasm.<sup>3</sup> An author modified listing of these interventions is listed in Table 1.

## Methodology

The primary databases utilized to retrieve the salient medical literature presented in this review were Publisher MEDLINE (PubMed), the Cumulative Index to Nursing and Allied Health Literature (CINAHL Complete), and Google Scholar. The search terms, used both separately and in combination, included: "Larson Maneuver," "laryngospasm," "laryngospasm notch," "laryngeal notch," "intervention," "mechanism," and "anesthesia." Only articles or published correspondence in English or with English translation were included.

Figure 1.

## The Anatomy of the Laryngospasm Notch



## Technique: Laryngeal Notch Pressure (Larson's Maneuver)

C. Philip Larson, Jr., MD is considered the first to describe a newer mechanical technique in the management of laryngospasm. In Larson's journal correspondence, he described the application of firm, bilateral medial, and anterior finger point pressure at a location he termed the laryngospasm notch. This pressure should be continuous and associated with a modified jaw thrust/chin lift. Figure 1 illustrates the notch location.

The laryngeal notch is bilaterally symmetrical and posterior to the ascending mandibular ramus at the level of the condylar process. The superior and posterior borders of the notch are defined by the base of the skull and the superior-anterior aspect of the mastoid process, respectively.<sup>4</sup>

Definitive evidence of the physiology of why this technique is effective has yet to be established. Larson opined that the corrective mechanism may be twofold. First, mandible displacement corrects some lingual airway obstruction. Second, the nociceptive effects of notch pressure on the facial nerve or to the deep lobe of the parotid gland activate the glossopharyngeal nerve. This, in turn, stimulates the vagus nerve and the superior cervical sympathetic ganglion by way of the petrosal ganglion.<sup>5</sup> The pain would then stimulate vocal cord relaxation due to autonomic nervous system activation. Larson went on to report that this technique was successfully integrated into years of his teaching practice but was not previously documented in the literature. Since Larson's first report, there has been surprisingly little published on the utilization of his technique in medical literature. No class I studies, or abstracts have been reported. Level IV. evidence is also limited.

## Case Reports: Non-Directly Visualized Laryngospasm

Several additional references have been published outlining the anecdotal evidence of laryngospasm notch efficacy. Andaloussi & Touab published a case report of laryngospasm after deep extubation of a 42-year-old COVID-19 infected male in the intensive care unit. Rapid restrictive breathing assessment with falling pulse oximetry and rising tachycardia was quickly identified as laryngospasm. The LM was quickly applied and within seven respiratory cycles, the laryngospasm resolved, and vital signs returned to normal within twenty-five minutes of unobstructed breathing.<sup>6</sup>

Two patients reported by Kino and Hirata in 2009 showed clinical effectiveness of LM. A 48-year-old male after a laparoscopic cholecystectomy and a 68-year-old female who underwent a lumbar laminectomy had unremarkable surgical courses. Both patients were intubated under general anesthesia. Both followed commands and showed spontaneous respirations prior to extubation. Immediately after endotracheal tube removal, both showed pulse oximetry drops of 76% and 81%, respectively. While reintubation was prepared, positive pressure ventilation was performed. The first patient showed adequate volume exchange while the second did not. LNP was applied to both patients with near immediate resolution of ventilation difficulty and a return of pulse oximetry to 100% SpO<sub>2</sub>.<sup>7</sup>

In 2011, Kino also reported on a 43-year-old female under general anesthesia with a laryngeal mask airway (LMA) for conization. Although the surgical course was uneventful, respiratory insufficiency was noted at the end of the procedure before emergence. When positive pressure ventilation failed to relieve the issue, LNP provoked resolution of the airway obstruction. The description of the notch has been incorrectly reported as anterior to the tragus. Therefore, it is unclear if this is a translational problem (from the original report in Japanese) or an actual anatomic error in locating the therapeutic target zone.<sup>8</sup>

Table 1.

## Interventions Associated with Laryngospasm Management<sup>3</sup>

- Cessation of patient stimulation
- Repositioning of the airway (chin lift, jaw thrust) with 100% FiO<sub>2</sub>
- Consider Larson Maneuver with modified jaw thrust\*
- Deepening of anesthetic depth utilizing sevoflurane
- Pressure support ventilation with
  - Continuous positive airway pressure (CPAP) or
  - Positive end expiratory pressure (PEEP)
- Consider propofol administration
- For partial obstruction consider nebulized lidocaine administration\*
- Steady, slow single external chest compression to increase expiratory pressure
- Positive pressure ventilation with facemask
- Neuromuscular blockade with a rapid acting pharmacologic agent
- Consider surgical airway

\* Indicates insertion by the author of this work

## Case Reports: Visualization of Laryngospasm

Several reports of LM under fiberoptic visualization of the larynx have been reported. Hill, Zundel, & Pagel reported an experience with a 65-year-old male with a history of ischemic cardiomyopathy. The patient suffered cardiopulmonary arrest in the intensive care unit. After spontaneous return of circulation status-post arrest, the decision was made to intubate the patient. Under video-laryngoscope visualization, the vocal cords spasmed as soon as they were contacted by the endotracheal tube. Clinicians applied laryngospasm notch pressure. Abduction of the vocal cords was visualized. A second attempt at intubation again showed spasmodic action. LNP facilitated successful endotracheal tube placement.<sup>9</sup>

Shinjo, et al reported two cases where relief from laryngospasm was visualized. A 61-year-old male undergoing subtotal esophagectomy developed glottic closure after propofol induction. On bronchoscope advancement, the vocal cords suddenly closed. LNP was applied. Clinicians were able to visualize cord opening in real time.

The second patient was a 22-year-old woman extubated after an emergency caesarean section under general anesthesia. Post-extubation stridor was noted. An ultrasonographic exam revealed vocal cord closure as her pulse oximetry dropped to 80% SpO<sub>2</sub>. Laryngospasm notch pressure was applied resulting in opening of the cords. The authors were able to visualize this opening on ultrasound, which occurred with the cessation of stridor and a return of pulse oximetry to 100%.<sup>10</sup>

## Discussion

Although documented as an option in the acute management of laryngeal spasm in both adults and pediatric patients, laryngeal notch pressure has yet to be studied for efficacy, appropriate utilization in select patient populations, or physiologically explained with proof-of-concept modeling. However, some book chapters and publications on procedural priorities in the acute management of laryngospasm in all patient populations and medical environments, continue to include Larson's Maneuver in the list of considerations. This has been accepted into some practices without the benefit of high-class, well-designed studies to define its use. The low incidence of acute laryngospasm may logistically be retarding this effort. Additionally, a lack of ethically compliant study design (one, which does not preclude potentially lifesaving procedures from patients at risk during airway emergencies) is significantly problematic. Additional data will need to be collected and analyzed.

## Conclusion

In the absence of well-constructed efficacy studies, Larson's Maneuver appears to be a procedure of clinical value based solely on anecdotal data. The simplicity of laryngeal notch pressure execution and the apparent rapid airway restoring effects result in a high benefit-to-cost ratio. The technique is easily incorporated into a clinical guideline, emergency checklist, or procedural outline. It takes little time or effort and can be performed in parallel with preparation for other interventions. Until more data is available, the technique may prove to be the difference between life and death of patients experiencing airway compromising laryngospasm.

## References

1. Collins, S., Schedler, P., Veasey, B., Kristofy, A., McDowell, M. Prevention and Treatment of Laryngospasm in the Pediatric Patient: A Literature Review. *J. Amer. Acad. Nurse Anesth.*, 2019;87(2):145-151. *Erratum in: AANA J.*, 2019;87(3):229. PMID: 31587728.
2. Olson, G., Hallen, B. Laryngospasm during anaesthesia. A computer-aided incidence study in 136,929 patients. *Acta Anaesthesiol Scand.* 1984;28(5):567-75. doi: 10.1111/j.1399-5076.1984.tb02121.x. PMID: 6496018.
3. Michelet, D., Truchot, J., Piot, M., Drummond, D., Cecaldi, P., Plaisance, P., Tesnière, A., Dahmani, S. (2018). Perioperative laryngospasm management in pediatrics: a high-fidelity simulation study. *BMJ Simulation and Technology Enhanced Learning.* 10.1136/bmjstel-2018-000364.
4. Larson, C.P. Jr. Laryngospasm--the best treatment. *Anesthesiology.* 1998;89(5):1293-4. doi: 10.1097/00000542-199811000-00056. PMID: 9822096.
5. Larsell, O. The nervous system. *Morris' Human Anatomy*, 11th edition. Edited by Schaeffer JP. New York, The Bloliscian Company, 1953;1007-10.
6. Andaloussi, M. R., Touab, R. Laryngospasm Following Deep Extubation in the Era of COVID-19 Successfully Managed with Larson's Maneuver. *AANA Journal*, 2021;89(5):379-380.
7. Kino, A., Hirata, S., Mishima, T. The use of "laryngospasm notch" in two patients whose oxygen saturations dropped after tracheal extubation. *Mosui Japanese Journal of Anesthesiology*, 2009;58(11):1430-1432.
8. Kino, A. The use of laryngospasm notch in a patient who was unable to breathe during general anesthesia with a ProSeal laryngeal mask airway--the effect of Kino's approach. *Mosui Japanese Journal of Anesthesiology*, 2011; 60(4):448-450.
9. Hill, G., Zundel, M. T., Pagel, P. S. Larson's Maneuver to Facilitate Endotracheal Intubation Using Video Laryngoscopy. *Journal of Cardiothoracic and Vascular Anesthesia*, 2019; 33(8):883-884. <https://doi.org/10.1053/j.jvca.2018.10.028>
10. Shinjo, T., Inoue, S., Egawa, J., Kawaguchi, M., Furuya, H. Two cases in which the effectiveness of "laryngospasm notch" pressure against laryngospasm was confirmed by imaging examinations. *Journal of Anesthesia*, 2013;27(5):761-763. <https://doi.org/10.1007/s00540-013-1592-x>