

INTRODUCTION

- The incidence of diverticulitis has continued to increase worldwide over the past several decades.¹
- Additionally, prevalence of the disease has significantly increased among younger populations in recent years.²
- A recent retrospective, single center study revealed an increased risk of developing inflammatory bowel disease (IBD) in patients with history of diverticulitis, particularly in those with complicated diverticulitis.³
- This study describes a case suspected to involve this newly observed correlation between the two diseases.

OBJECTIVES

- Understand the changing epidemiology of diverticulitis and its correlation with the increasing prevalence of inflammatory bowel disease (IBD), particularly in patients with a history of complicated diverticulitis.
- Discuss the proposed link between diverticulitis, alterations in the microbiome, and subsequent immune dysregulation hypothesized to lead to IBD development.

THE CASE

A 71-year-old female with a history of sigmoid colectomy secondary to complicated diverticulitis presented to the emergency department with several weeks of worsening hematochezia. She recently underwent a rectal biopsy which revealed severe ulcerative proctitis and superimposed scattered CMV inclusions; she was subsequently prescribed metronidazole and mesalamine with no relief. Upon arrival to the ED, CT abdomen/pelvis showed findings consistent with severe proctocolitis. Quantitative serum CMV was mildly elevated. In light of her biopsy findings, an interdisciplinary team composed of infectious disease and gastroenterology was engaged. She was continued on a 2 week course of IV ganciclovir. Additionally, given concern for underlying IBD, we requested pathology review her sigmoid colectomy from 12 months prior for evidence of IBD. The review was inconclusive, as histologic changes were indistinguishable between segmental colitis of diverticular disease and IBD. Ultimately, the frequency and texture of her hematochezia improved over a 7 day hospital course on oral and suppository formulations of mesalamine, and she was determined to be medically stable for discharge. She was prescribed these medications on discharge and close outpatient follow-up with GI and ID was arranged. On 1 month follow-up, her CMV count was undetectable, and the frequency and texture of her stools continued to improve on mesalamine.

FIGURE 1

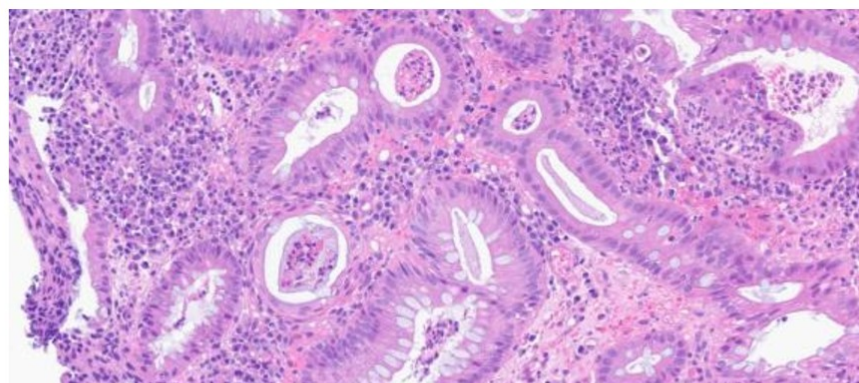


Figure 1. Histology of the colonic mucosa from the case patient demonstrating distortion of colonic glands, a pattern seen in ulcerative colitis.

FIGURE 2

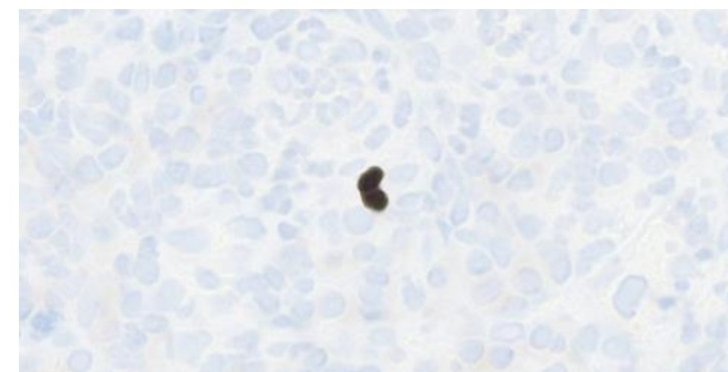


Figure 2. Antibody directed stain showing one of very few CMV inclusions noted on the case patient's histology

DISCUSSION

It is difficult to ascertain whether this was the pattern observed in this patient given her prior histopathologic findings. Notably, several months following her sigmoid colectomy, she noted symptoms of mild hematochezia and underwent follow-up colonoscopy which revealed no signs of IBD or diverticulitis. This apparent disease-free interval further adds to the possibility that her history of diverticulitis contributed to the development of ulcerative colitis. However, no repeat biopsy had been taken at that time, so the relationship between these two diseases in our case remains unclear. Additionally, the presence of CMV inclusions likely played a smaller role in her overall disease course, as they were observed in low quantities upon biopsy.

CONCLUSION

IBD has often been characterized to occur earlier in life. However, recent studies have shown an increasing frequency of onset in patients over the age of 65 years.⁴ Interestingly, as observed in our case, patients observed to develop de novo IBD with history of diverticulitis were overwhelmingly female in one study, with ulcerative colitis being the more common phenotype of IBD.³ Given the proposed microbiome changes in patients with diverticulitis, it is hypothesized that this may lead to the immune dysregulation ultimately seen in IBD.³

REFERENCES

1. Bharucha AE, Parthasarathy G, Ditah I, et al. Temporal Trends in the Incidence and Natural History of Diverticulitis: A Population-Based Study. *American Journal of Gastroenterology*. 2015;110(11):1589-1596. doi:10.1038/ajg.2015.302
2. Elisei W, Brandimarte G, Tursi A. Management of diverticulosis: what's new? *Minerva Med*. 2017;108(5). doi:10.23736/S0026-4806.17.05201-6
3. Ur Rahman A, Hussain I, Hasan B, Ur Rashid M, Tandon KS, Castro F. Association of Complicated Diverticulitis With Development of De Novo Inflammatory Bowel Disease. *Inflammatory Bowel Diseases*. 2021;27(7):1061-1067. doi:10.1093/ibd/izaa299
4. Shi HY, Chan FKL, Leung WK, et al. Natural History of Elderly-onset Ulcerative Colitis: Results from a Territory-wide Inflammatory Bowel Disease Registry. *ECCOJC*. 2016;10(2):176-185. doi:10.1093/ecco-jcc/jjv194