

Introduction

- The term perivascular epithelioid cell tumor (PEComa) refers to a family of ultrarare soft-tissue sarcomas defined by a combination of melanocytic and smooth muscle spindle cell phenotype.¹
 - Lymphangiomyomatosis (LAM)¹
 - Angiomyolipoma (AML)¹
 - Clear cell "sugar" tumors (CCST)¹
 - PEComa not otherwise specified (PEComa-NOS)²
- PEComas are highly vascular mesenchymal tumors without a known cell of origin.¹
- Although often benign, an estimated 7 per 100 million people per year are diagnosed with a 'malignant' PEComa secondary to high risk morphologic and histologic stratification.³
- Malignant PEComas are most commonly arise in females over the age of 60 within the gynecologic tract.^{3,4}
- Patient presentation ranges from general abdominal pain to bloating,⁵ anemia, weight loss,⁶ or paresthesia.⁷
- Imaging is nonspecific, so diagnosis relies immunochemical tissue staining;⁵ human melanocytic black 45 (HMB-45) is present in almost all malignant PEComas.⁴
- Despite often poor prognoses, nab-sirolimus has improved overall survival in cases of malignant PEComa associated with a tubular sclerosis complex 2 (TSC2) gene mutation, with overall median survival of ~40 months.⁸

Malignant PEComa Risk Stratification Criteria^{4,9}

- Tumor size ≥ 5 cm
- An infiltrative pattern of growth
- High mitotic rate of division ($\geq 1/50$ high per field)
- High nuclear grade and cellularity
- Presence of tumor necrosis
- Presence of vascular invasion

Case Description

Chief Complaint: 78-year-old Bengali female presented to the ED with worsening diffuse lower abdominal pain radiating to her back and pelvis over the past 8 months.

- In the prior 2 months, she noted unintentional weight loss, dry cough, exercise intolerance, cramping, fatigue, and constipation. Additionally, she endorsed 10-12 years of lower extremity edema. She denied fevers, night sweats, nausea, hematuria, and vaginal nor rectal bleeding.
- Initially diagnosed in Bangladesh as gastric reflux, but antacids had not resolved her pain.
- On exam, she was hypertensive (146/72), afebrile, and pale. The entire abdomen was tender to light palpation without an appreciable mass. 2+ pitting lower leg edema was noted. Bilateral lower lung sounds were decreased, no wheezing or crackles. Rectal and pelvic exams deferred.

Patient History

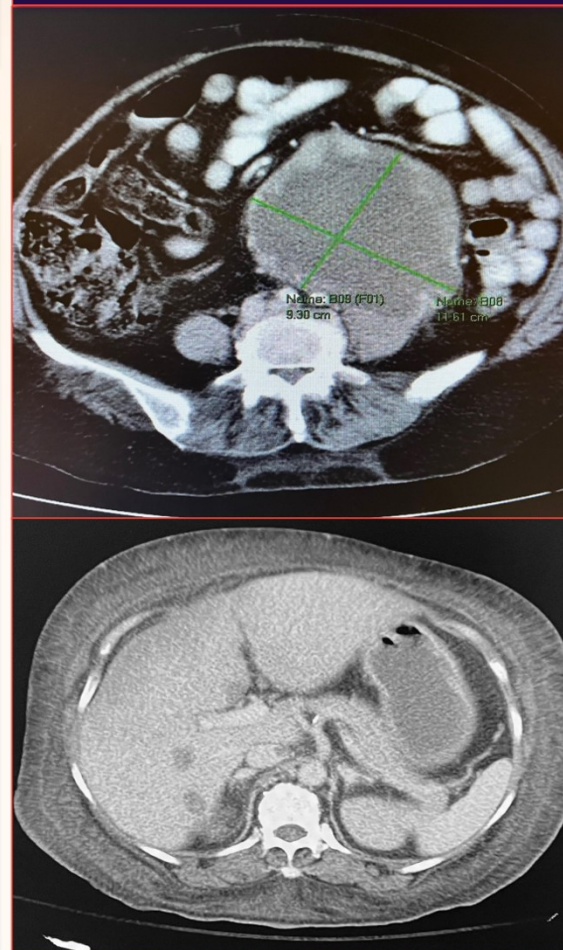
PMH: Uterine leiomyosarcoma. No hepatitis.
PSH: Hysterectomy (1995)
Allergies: NKDA
Medications: Non-contributory
Family History: Mother died of unknown cancer (~50 years old)
Social history: No alcohol or tobacco use

Significant Initial Blood Work

WBC: 12.55 x10⁹/L
***Neutrophil Percentage:** 72.1%
Hgb: 7.5 g/dL
BMP: within normal limits
Bilirubin: within normal limits
AST: 84 units/L
ALT: 35 units/L
Alkaline Phosphatase: 337 IU/L

CT Scan with IV contrast

- Bilobed left abdominopelvic retroperitoneal mass replacing the left ovary.
- Contiguous tumor thrombus within the entirety of the left gonadal vein and into renal vein.
- Numerous pulmonary, hepatic, and lumbar vertebral metastases.



Course of Disease

- CT scan with IV contrast of the abdomen and pelvis revealed a heterogeneously enhancing, highly vascular, left abdominopelvic retroperitoneal mass measuring 12.8 x 8.9 x 15.0cm. The left ovary could not be visualized. No evidence of cirrhosis.
- Outpatient needle-core biopsy of a hepatic lesion was interpreted as hepatocellular carcinoma (HCC). However, low clinical suspicion for HCC prompted confirmatory histologic analysis.
 - Immunoreactive staining was positive for HMB-45, and focally negative for desmin and S-100.
 - Molecular study positive for a TSC2 frameshift mutation.
- Nab-sirolimus chemotherapy was started and initially achieved symptomatic relief with regression of tumor bulk.
- After 4 months of treatment, repeat CT scans displayed increasing tumor size, new metastases, and expansion of tumor thrombus into the IVC causing pitting edema up to the thigh.
- Unfortunately, her treatment was complicated by worsening fatigue, severe anemia, thrombocytopenia, bowel obstructions, and sepsis.
- The family opted for hospice care, and she passed away shortly thereafter.

Discussion

- PEComas are sarcomas which express varying levels of smooth muscle and melanocytic biomarkers (i.e., HMB-45, actin, S-100, desmin).⁴
- This patient's PMH of uterine leiomyomas with hysterectomy is suspicious, as PEComas ranging predominance of mixed spindle cell and epithelioid cell morphology, associate it with many differential diagnoses including melanoma, leiomyosarcoma, and primary cell tumors dependent on tumor location.⁴
- This patient was diagnosed later in life. However, long history of lower extremity edema suggests venous tumor thrombosis may have begun earlier in her life.
- Although most often within the uterus,⁴ 10.5% of malignant PEComas arise from the abdominopelvic wall,³ and they present nonspecifically.⁷
- Nab-sirolimus is the only approved chemotherapy for malignant PEComa.⁸ It inhibits mammalian target of rapamycin (mTOR), which is commonly over activated in those with TSC2 mutations.¹⁰
 - Side effects include persistent anemia, thrombocytopenia, and frequent infection.⁸

Conclusion

PEComas are ultrarare mesenchymal soft-tissue sarcomas. Thorough histologic investigation in atypical tumors is necessary, as malignant PEComas present similarly to other soft-tissue and primary cell tumors. Despite malignant PEComas initial positive response to nab-sirolimus, the chemotherapy can lead to myelosuppression and frequent infection, complicating treatment course. More research is needed to improve malignant PEComa recognition and patient prognosis.

References

- Zamboni G, Pea M, Martignoni G, et al. Clear cell "sugar" tumor of the pancreas: a novel member of the family of lesions characterized by the presence of perivascular epithelioid cells. *Am J Surg Pathol*. 1996;20(6):722-730. doi:10.1097/0000478-199606000-00010
- Bleeker JS, Quereho JF, Folpe AL. "Malignant" perivascular epithelioid cell neoplasm: risk stratification and treatment strategies. *Sarcoma*. 2012;2012:541626. doi:10.1155/2012/541626
- de Pinieux G, Karanian M, Le Louer F, et al. Nationwide incidence of sarcomas and connective tissue tumors of intermediate malignancy over four years using an expert pathology review network. *PLoS One*. 2021;16(2):e0246958. doi:10.1371/journal.pone.0246958
- Folpe AL, Mentzel T, Lehr HA, Fisher C, Baker HL, Weiss SW. Perivascular epithelioid cell neoplasms of soft tissue and genitocytologic origin: a clinicopathologic study of 26 cases and review of the literature. *Am J Surg Pathol*. 2005;29(12):1558-1575. doi:10.1097/0000478-200512000-00010
- Tan Y, Zhang H, Xiao EH. Perivascular epithelioid cell tumour: dynamic CT, MRI and clinicopathological characteristics—analysis of 32 cases and review of the literature. *Clin Radiol*. 2013;68(6):555-561. doi:10.1016/j.crad.2012.10.021
- Meredith L, Chao Y, Bowker A, et al. A rare metastatic mesenteric malignant PEComa with TSC2 mutation treated with palliative surgical resection and nab-sirolimus: a case report. *Diagn Pathol*. 2023;16(1):45. doi:10.1186/s13000-023-01323-z
- Singer E, Yau S, Johnson M. Retroperitoneal PEComa: case report and review of literature. *Drugs Case Rep*. 2018;19:99-100. doi:10.1016/j.drugs.2018.03.012
- Wagner AJ, Ravi V, Rishi RF, et al. Nab-sirolimus for patients with malignant perivascular epithelioid cell tumors. *J Clin Oncol*. 2021;39(33):3665-3670. doi:10.1200/JCO.2021.01.728
- Jiang Y, Liu X, Zhang S, et al. Risk stratification and outcomes in 210 genitocytologic perivascular epithelioid cell tumors (PEComas) cases. *Arch Gynecol Obstet*. 2023;307(3):681-687. doi:10.1007/s00044-022-04647-y
- Huang J, Dobbie CC, Matuzaki M, Manning BD. The TSC1-TSC2 complex is required for proper activation of mTOR complex 2. *Mol Cell Biol*. 2008;28(12):4104-4115. doi:10.1128/MCB.00289-08