

Acne Vulgaris: A Case Based Approach

Scott Freeman PA-C
ADCS
St. Petersburg
Florida



Disclosures

- None



Objectives

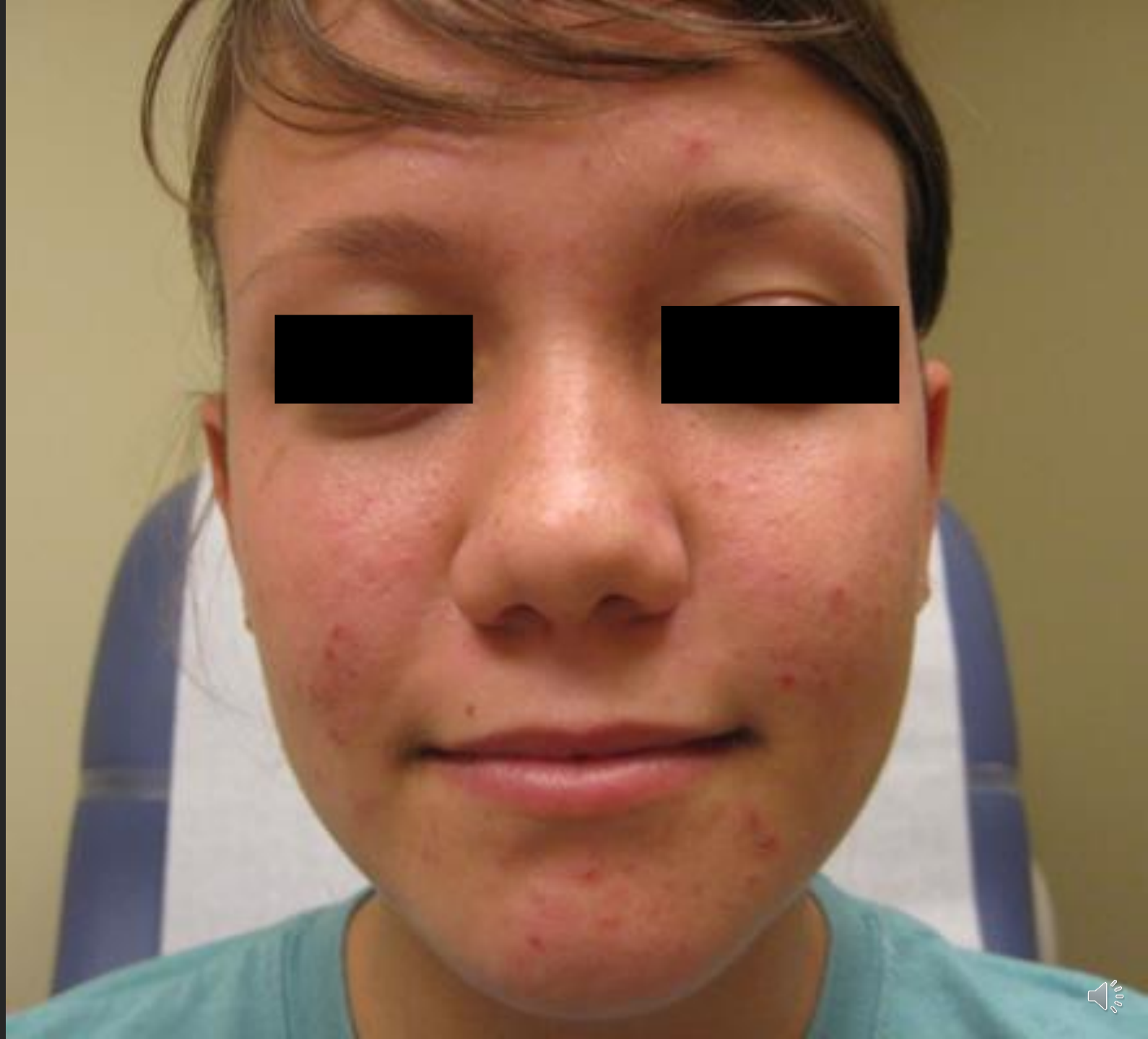- What exactly is Acne.
- Appreciate the need to treat patients who suffer from acne
- Learn treatment strategies for different types of acne
- Identify the severity and types of the most common acne presentations



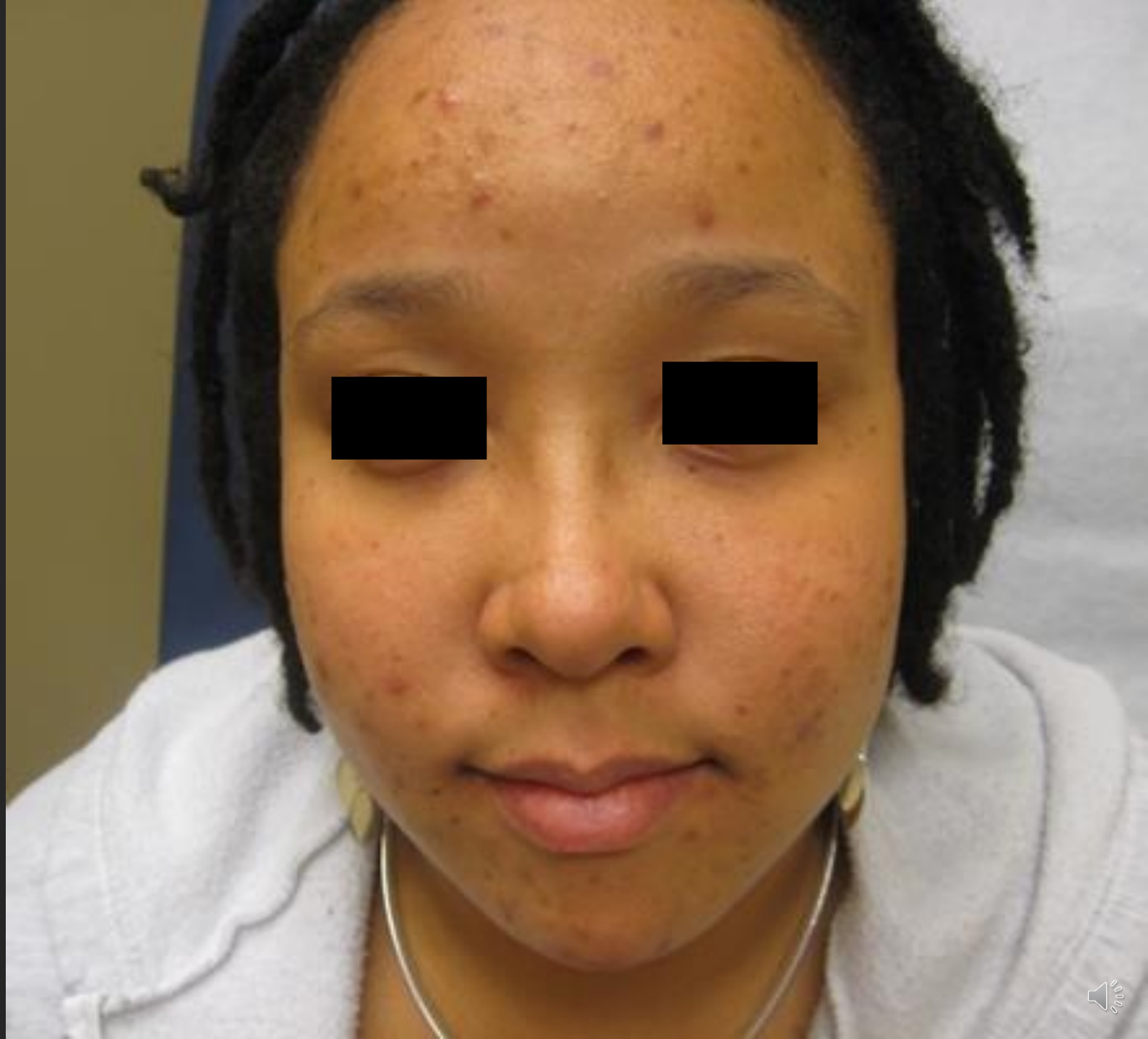Practice cases (3)



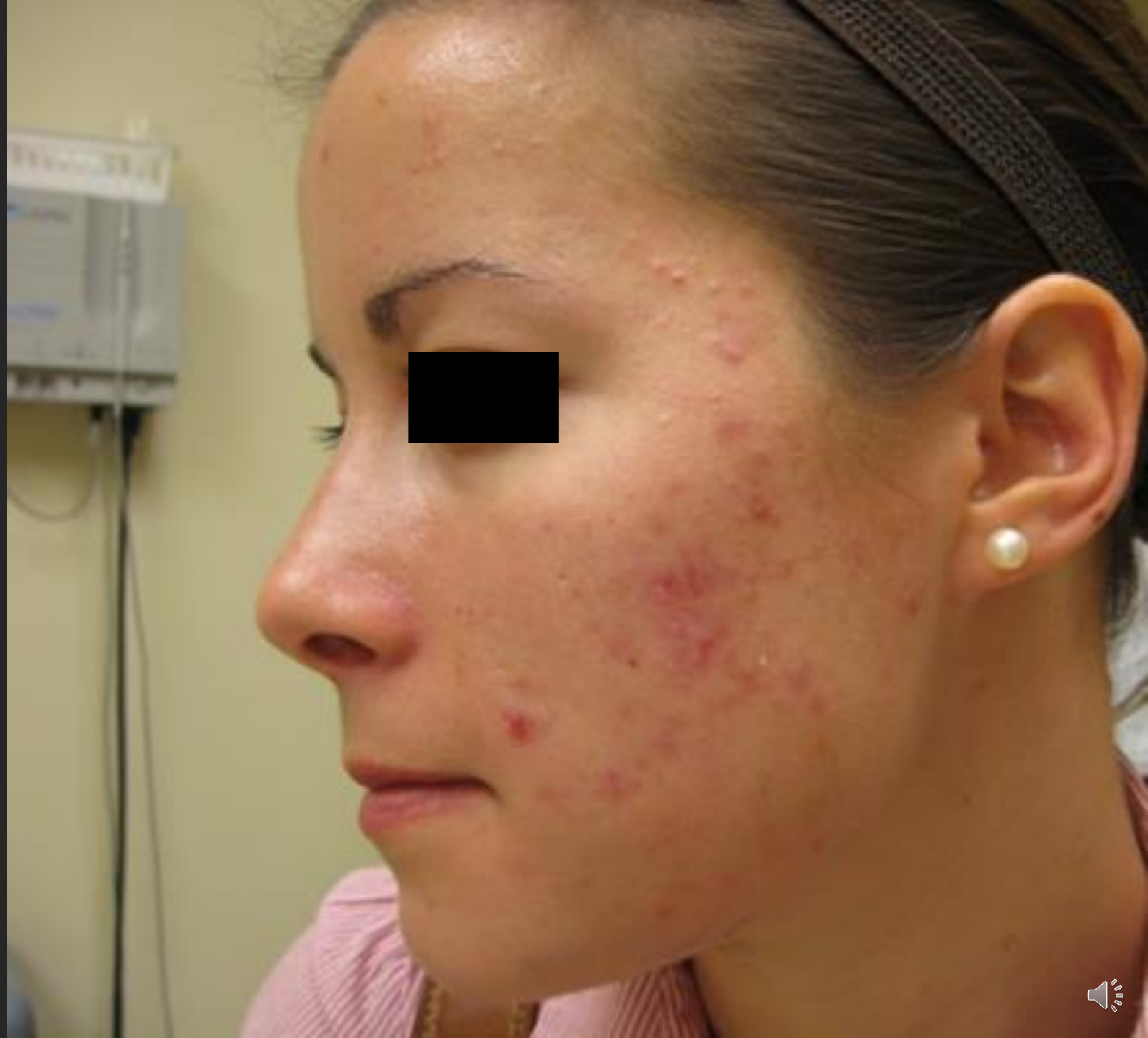Case 1



Case 2




Case 3



Introduction to Acne

- Most common skin condition in the USA
- Why we need to treat acne...
- Mental Health
 - Devastating condition at a very vulnerable time in life
 - Treatment leads to a “decrease in depressive symptoms”¹ in a population where depression and anxiety is common.
- Physical Health
 - Lifelong scars could be avoided
 - Acne is a medical condition that necessitates treatment
 - It is not a “right of passage”



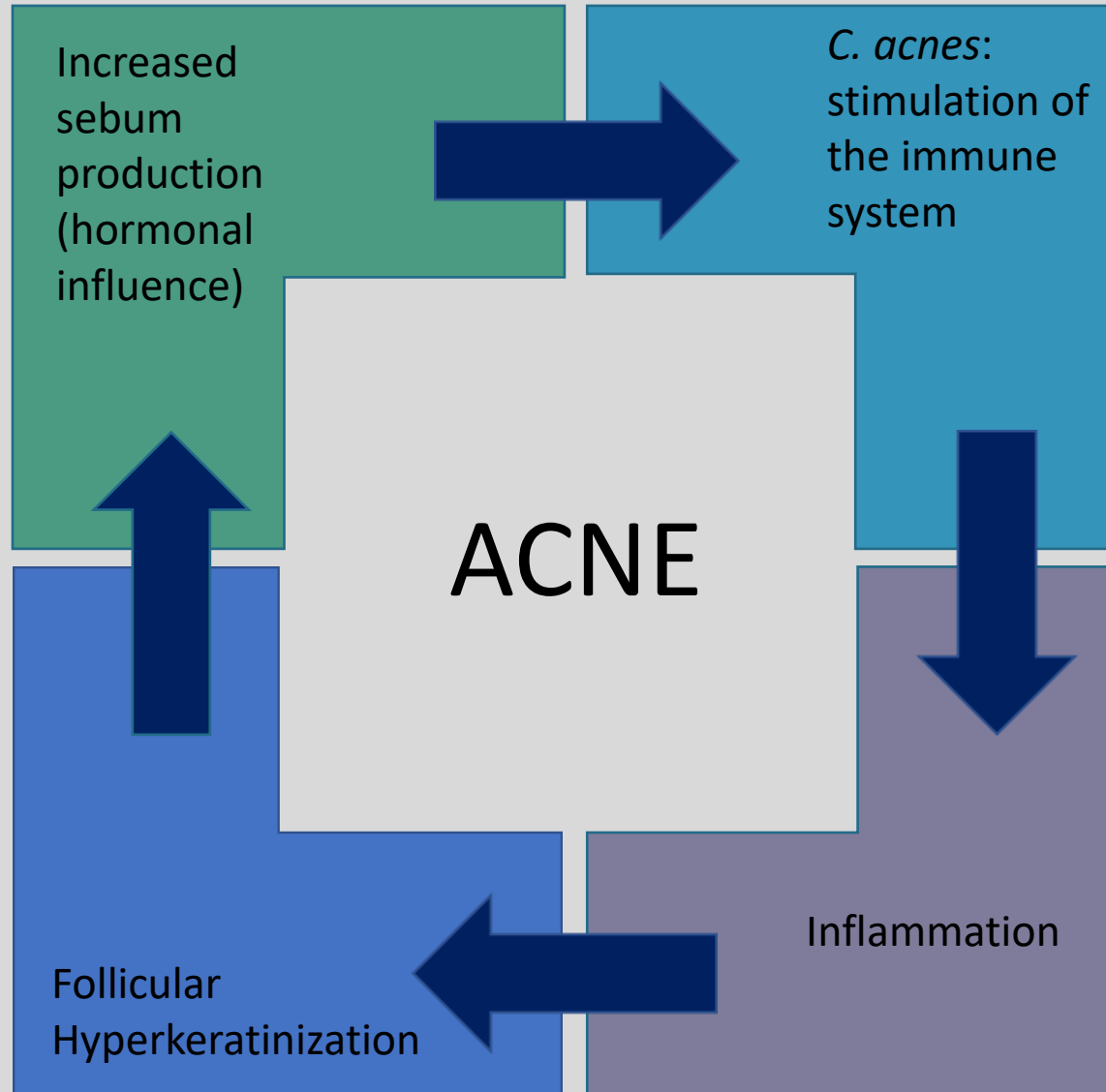


Acne's Financial Impact on the “System”

- In the United States, the combined amount of money spent on acne treatment and loss of productivity at work exceeds \$3 billion each year.
- Americans spend about \$400 million dollars each year on OTC acne products.



Pathogenesis of Acne



PEARL:

The most important aspect of acne therapy is to reduce the skin's sebaceous load.

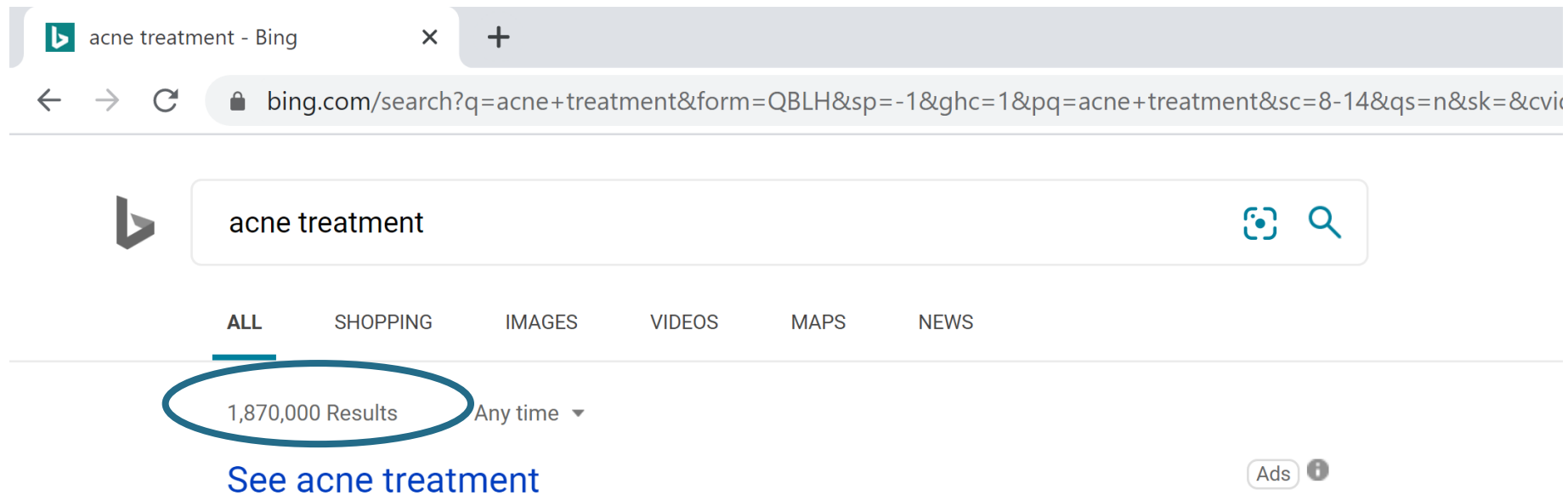
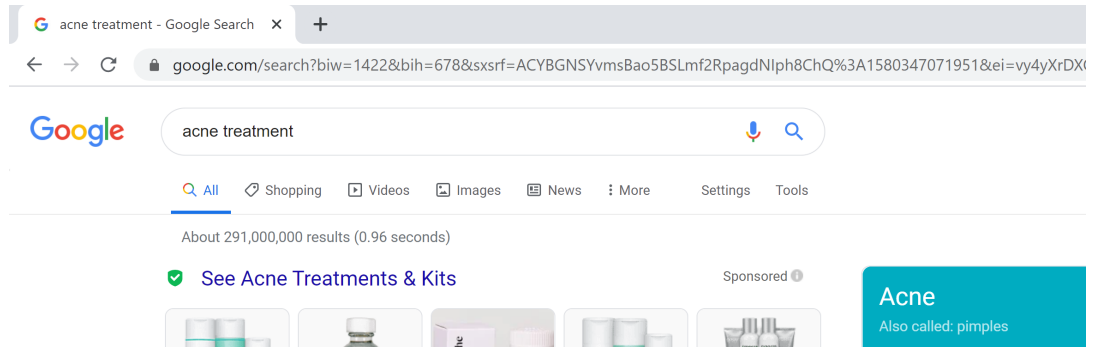


Treatments

The image shows a Google search interface for the query "acne treatment". The browser's address bar displays the search URL. Below the search bar, navigation options include "All", "Shopping", "Videos", "Images", "News", "More", "Settings", and "Tools". The search results indicate "About 291,000,000 results (0.96 seconds)", with the text circled in blue. A sponsored advertisement is visible, featuring a green checkmark icon, the text "See Acne Treatments & Kits", and a "Sponsored" label. Below the ad are five small images of acne treatment products. To the right of the ad is a teal box with the text "Acne" and "Also called: pimples".



Treatments

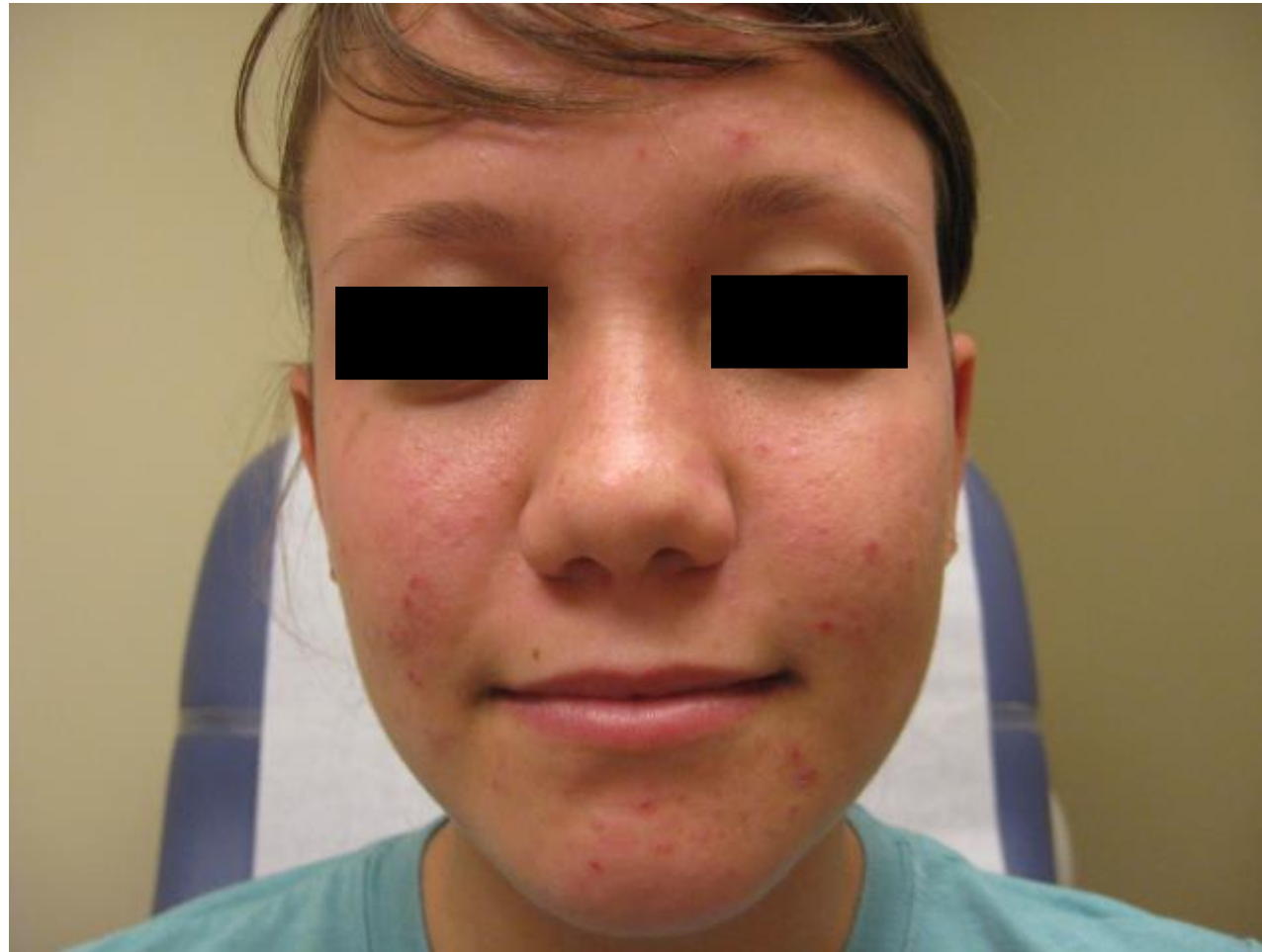

Cases for Discussion

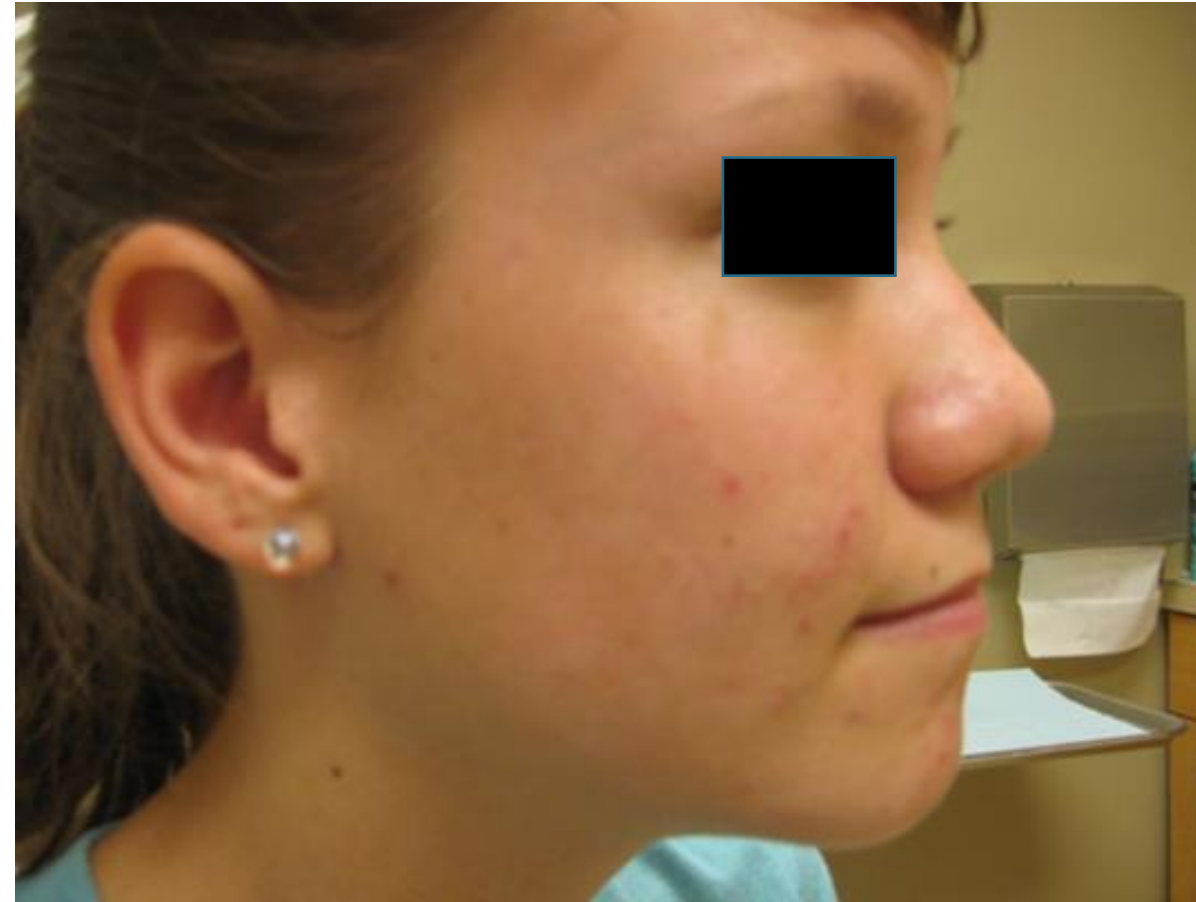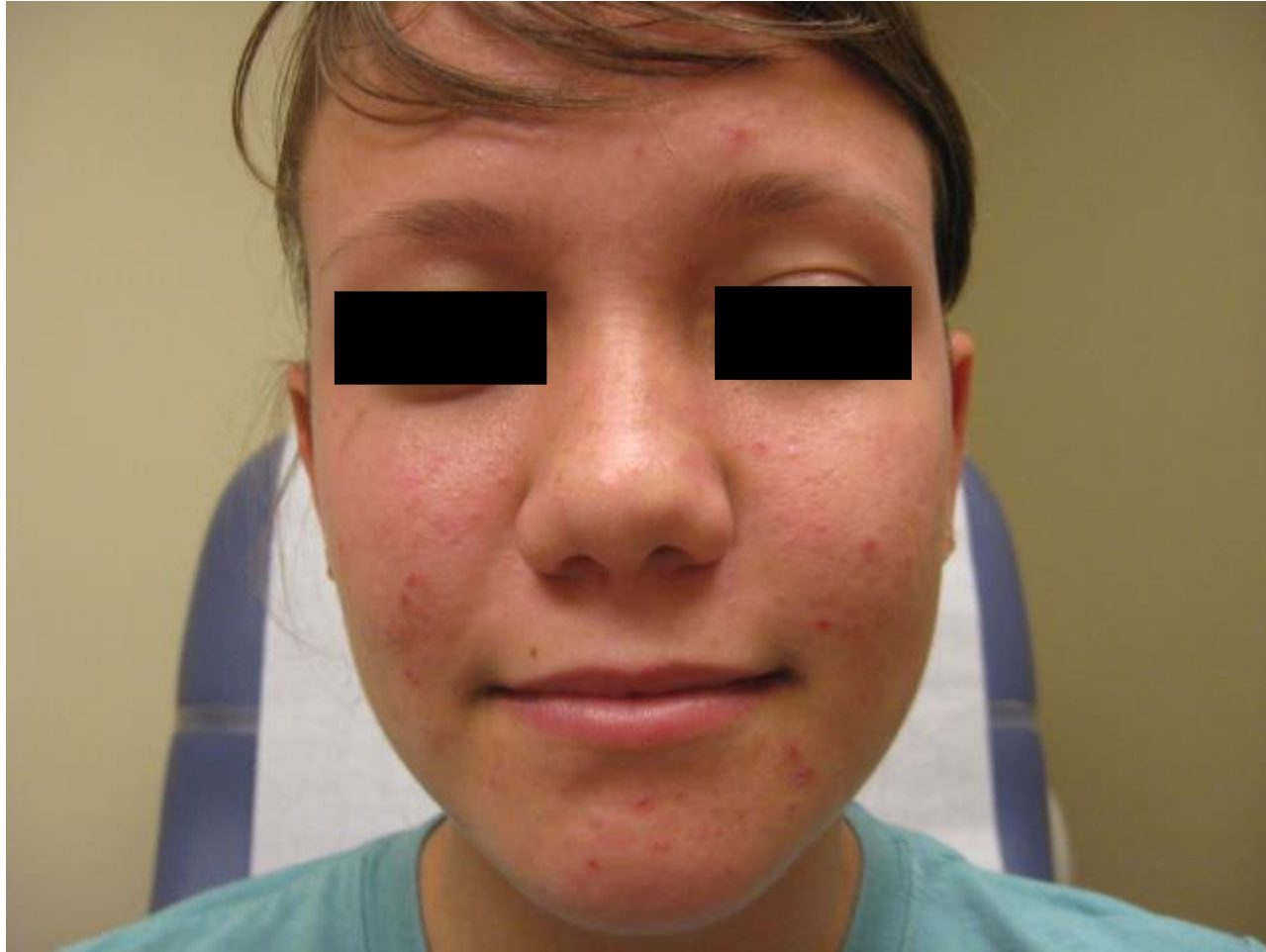Details of therapeutics will be discussed in the following case-based format.



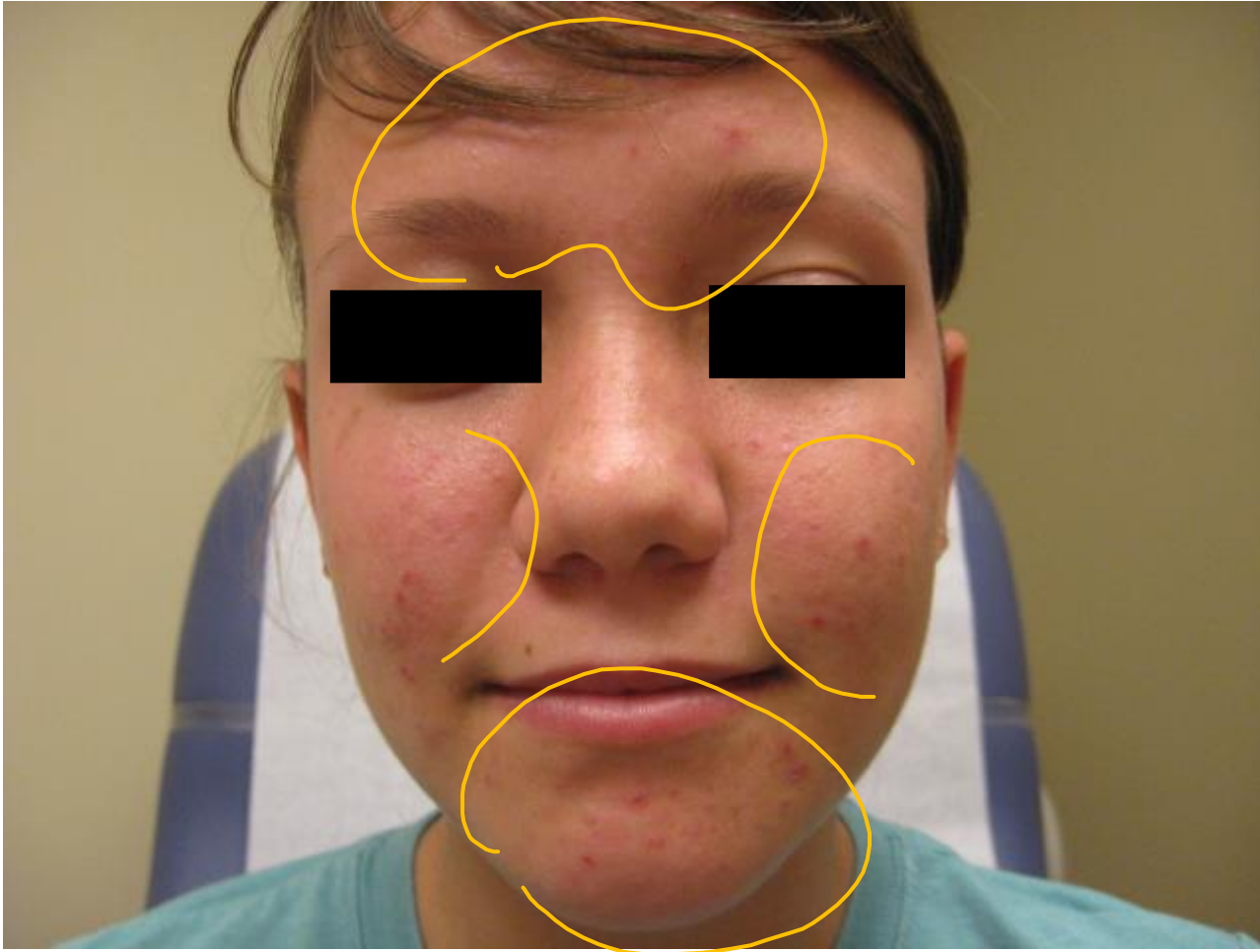
Pediatric Patient (Pre-menstrual)



Pediatric Patient (Pre-menstrual)



Pediatric Patient (Pre-menstrual)



Clinical exam shows:

Positives

- Open comedones
- Closed comedones
- Mild inflammation

Mild picking of papules








Scattered distribution

Negatives:

- No nodular lesions
- No scarring
- No pigmentary changes



Managing Acne

						
MILD		MODERATE		SEVERE		
Comedonal	Papular/pustular	Papular/pustular	Moderately Severe - Severe			
Topical Retinoid or Fixed combination with retinoid > BPO or Azelaic Acid > Salicylic Acid	Fixed Combination or BPO or Topical Retinoid or Azelaic Acid	Fixed Combination Preferred ± Hormonal therapy and/or Oral Antibiotic*	Fixed Combination + Oral Antibiotic Preferred Or + Oral Isotretinoin Or + Oral Hormonal Therapy			

If patient responds, treat until clear or almost clear

Maintenance Therapy: Topical Retinoid or Retinoid/BPO Combination

* Particularly if the trunk is involved

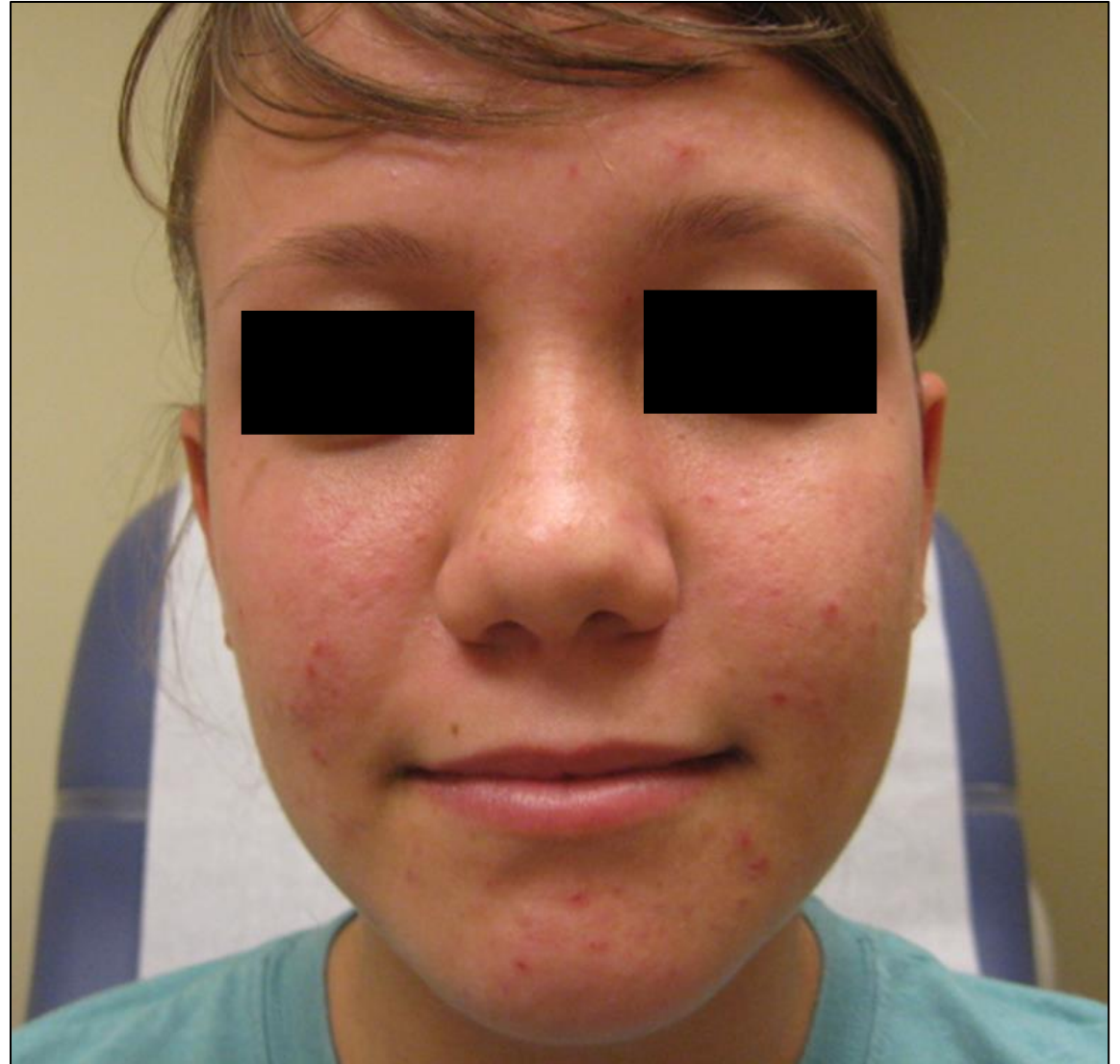Actions if Response is Poor

- ✓ Check non-drug related reasons (seborrhea, stress and diet, Malassezia furfur, G- bacteria, comedogenic skin care products, endocrine profile)
- ✓ Check drug-related reasons (adapt vehicle to skin type and environmental conditions, change topical agent, mechanically remove comedones, change from monotherapy to fixed-combination, change to higher concentration of topical). For females, check type of contraception.
- ✓ Probe patient's adherence (application technique, missed doses, tolerability)
- ✓ Ask about adverse events



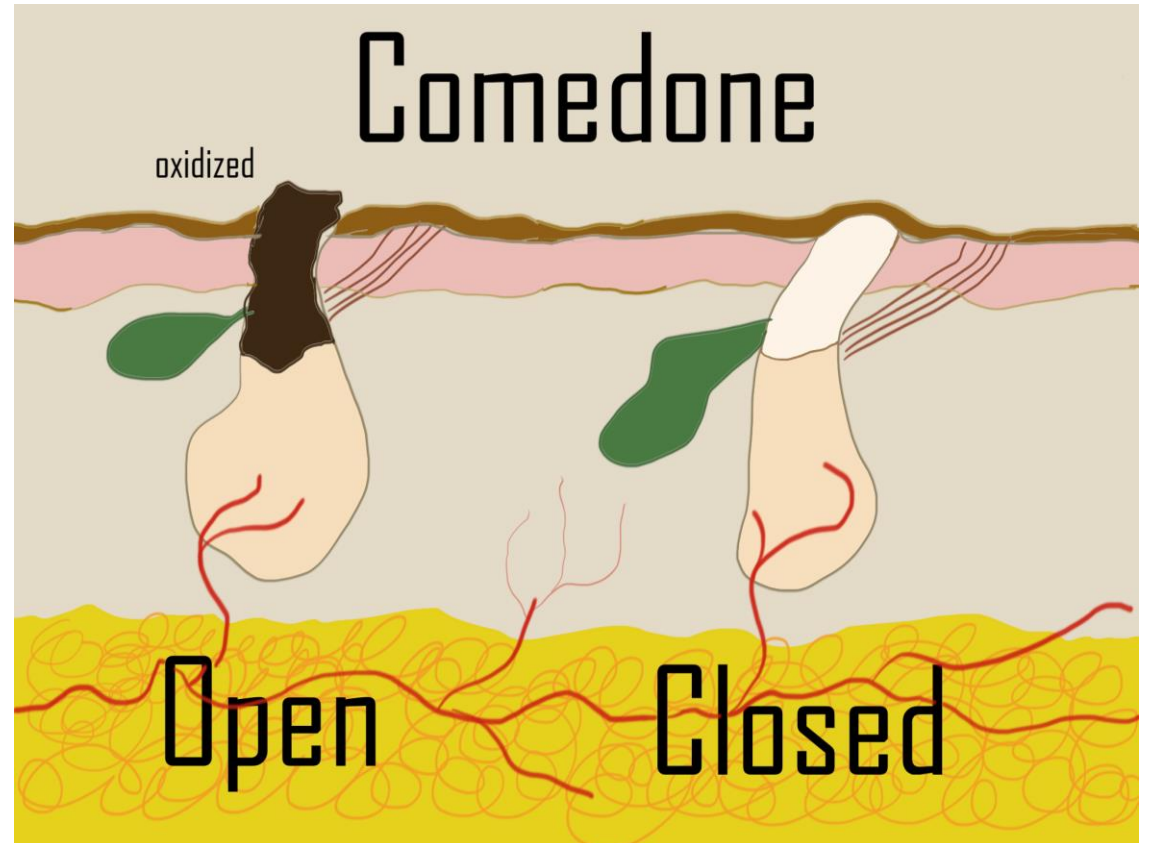
Pediatric Patient

- Non-inflamed Mild Comedonal subtype
 - Topical Retinoid
 - Combination of Retinoid with Benzoyl Peroxide (BPO) or Azeliac Acid
 - Salicylic acid
- Treat until clear
- Maintenance
 - Topical Retinoid w/wo BPO



The Comedone

- Without comedones, you do not have acne.
 - Both open and closed comedones are present.
- Micro-comedone (the engine)
 - Microscopic genesis of acne
 - Vulnerable to medications
- Do not spot treat
 - Miss the micro-comedone



Topical Retinoids

	photostable	+ BPO	age	pregnancy
Tretinoin	No	No	9 - 12	caution
Tazarotene	Yes	~	12	caution
Adapalene	Yes	Yes	9 -12	caution
Trifarotene	No	No	9	caution

- Derivatives of retinoids are weaker than Rx molecules.



Topical Retinoids

Promote skin turnover

Decreases comedone formation

Helps clear sebum within the follicle

Prevents keratosis

stimulates cell proliferation

	photostable	+ BPO	age	pregnancy
Tretinoin	No	No	9 - 12	caution
Tazarotene	Yes	~	12	caution
Adapalene	Yes	Yes	9 -12	caution
Trifarotene	No	No	9	caution

Most common retinoid for acne therapy is tretinoin.

Strength and formulation vary depending on prescriber preference and tolerability

Other beneficial effects of topical retinoids:

Stimulates collagen formation

Regulates sebum

Stimulates epidermal cell proliferation

Photoprotective

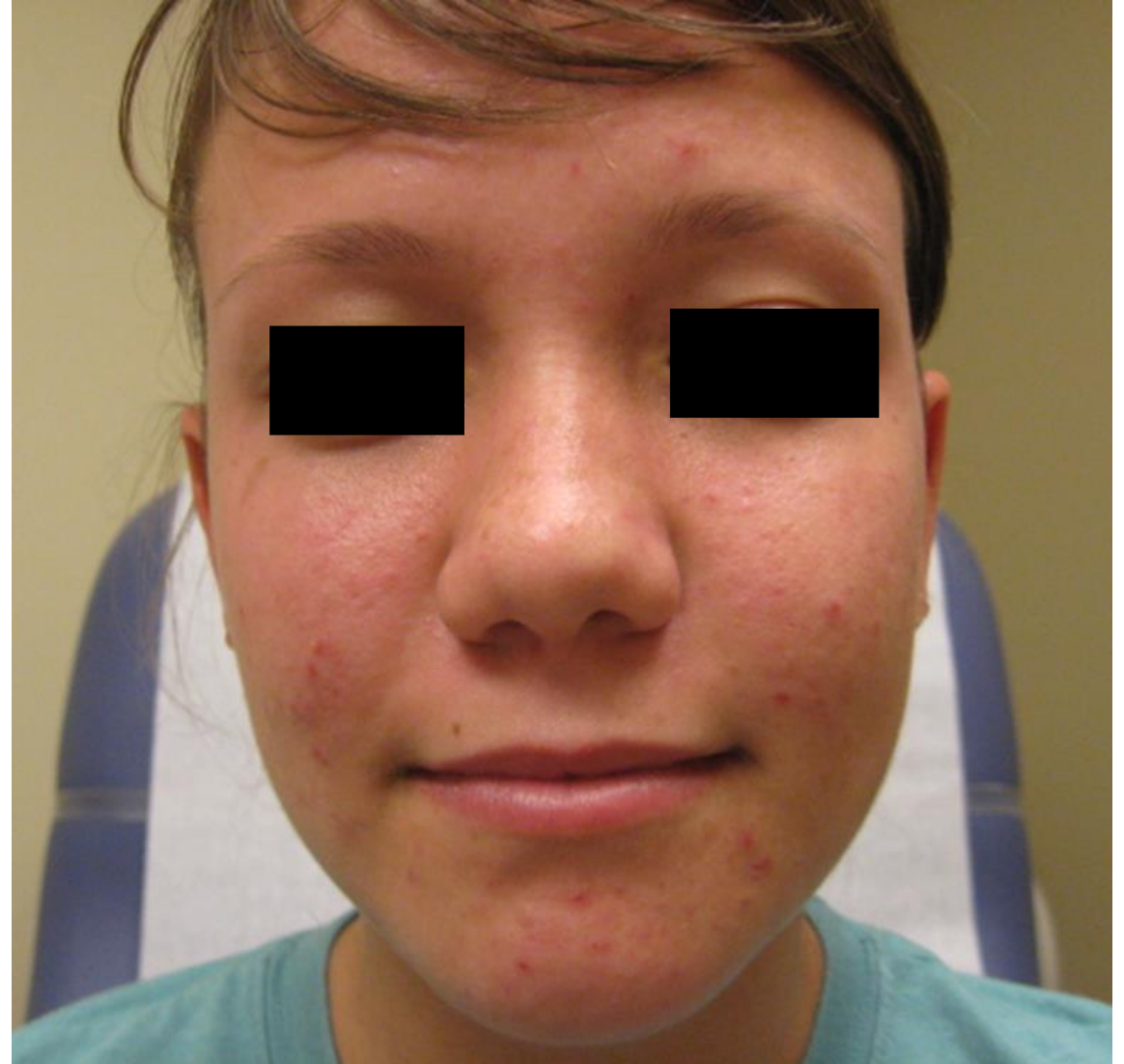Anti-inflammatory

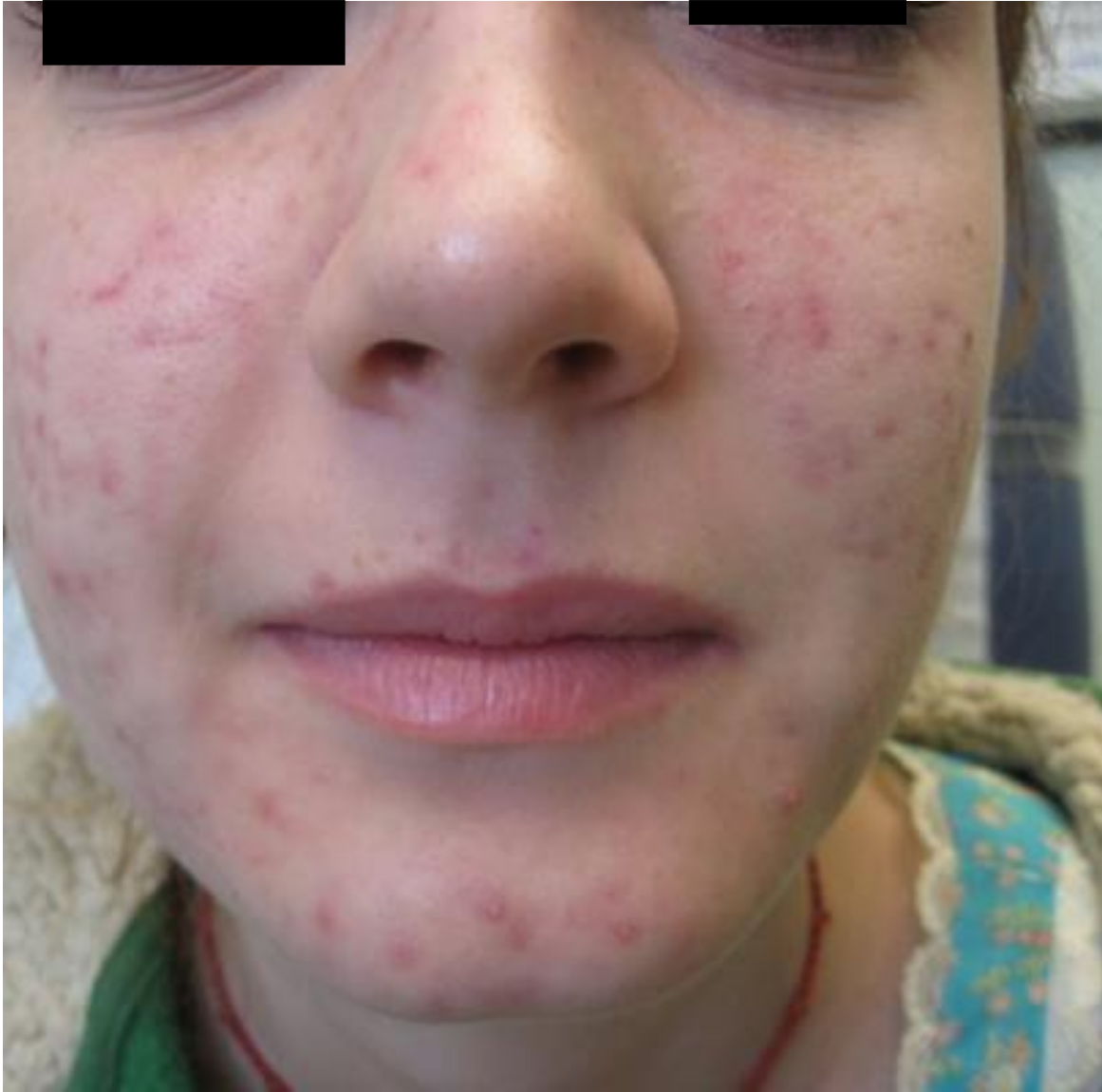- Derivatives of retinoids are weaker than Rx molecules.



Pediatric Patient

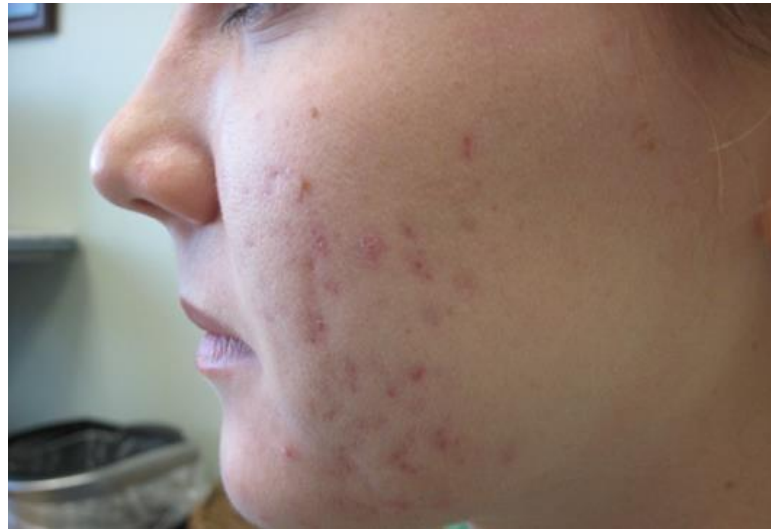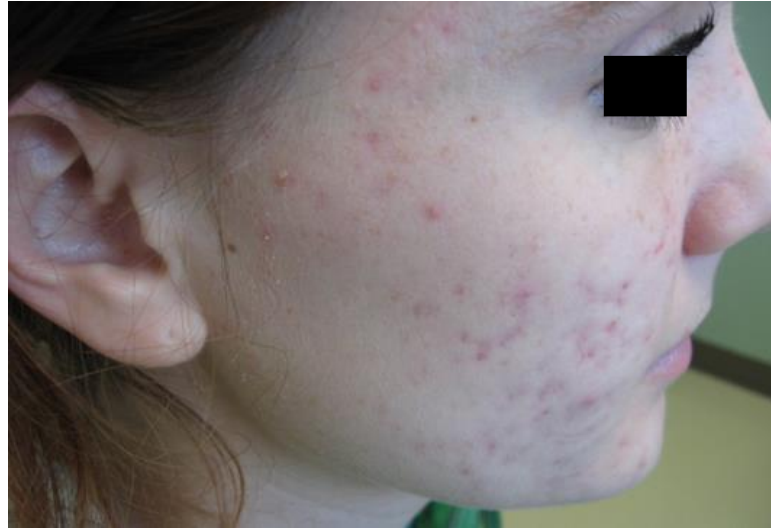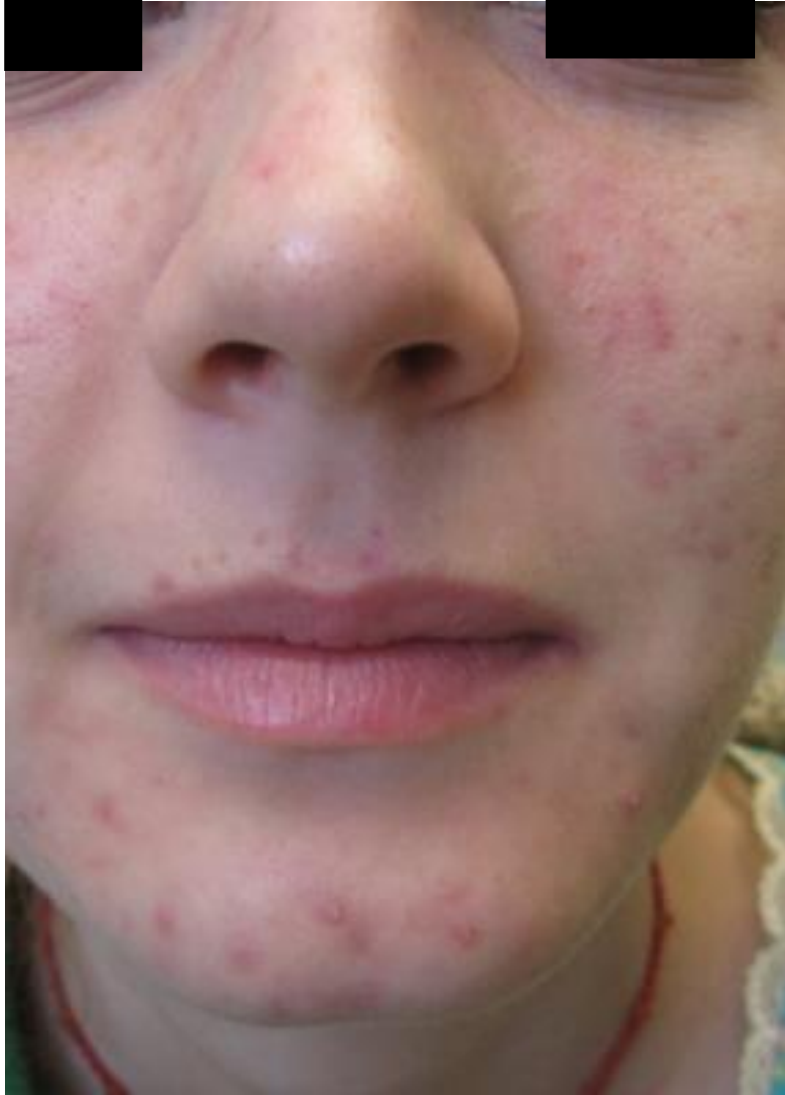- Pearls:
 - Involve the parents
 - Simple treatment protocol
 - One or two medications only
 - No picking/instrumentation
 - Paint the picture of acne
 - Share stories of success
 - Talk with them in clinic
 - They are the patient, not their parents
 - Earlier follow up (4 weeks sometimes)
 - Photos





Inflammatory Acne Case

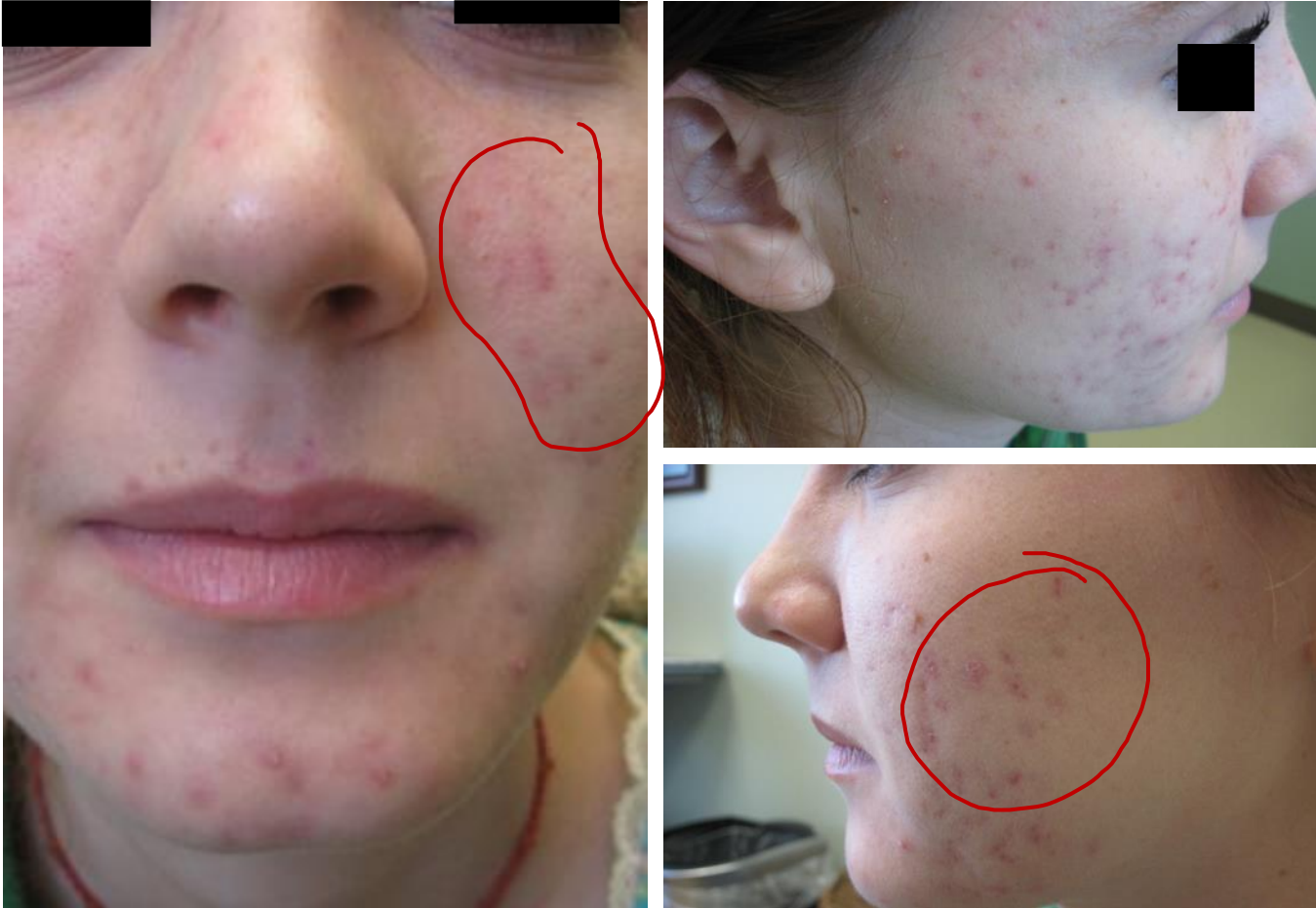



Inflammatory
Acne Case



Inflammatory Acne Case



Clinical exam shows:

Positives:

Increased inflammatory lesions

Scarring usually present

Both open and closed comedones








Scattered distribution +/- torso

Negatives:

Nodules are often absent but can be present.



Managing Acne

						
MILD		MODERATE		SEVERE		
Comedonal	Papular/pustular		Papular/pustular	Moderately Severe - Severe		
Topical Retinoid or Fixed combination with retinoid > BPO or Azelaic Acid > Salicylic Acid	Fixed Combination or BPO or Topical Retinoid or Azelaic Acid		Fixed Combination Preferred ± Hormonal therapy and/or Oral Antibiotic*	Fixed Combination + Oral Antibiotic Preferred Or + Oral Isotretinoin Or + Oral Hormonal Therapy		

If patient responds, treat until clear or almost clear

Maintenance Therapy: Topical Retinoid or Retinoid/BPO Combination

* Particularly if the trunk is involved

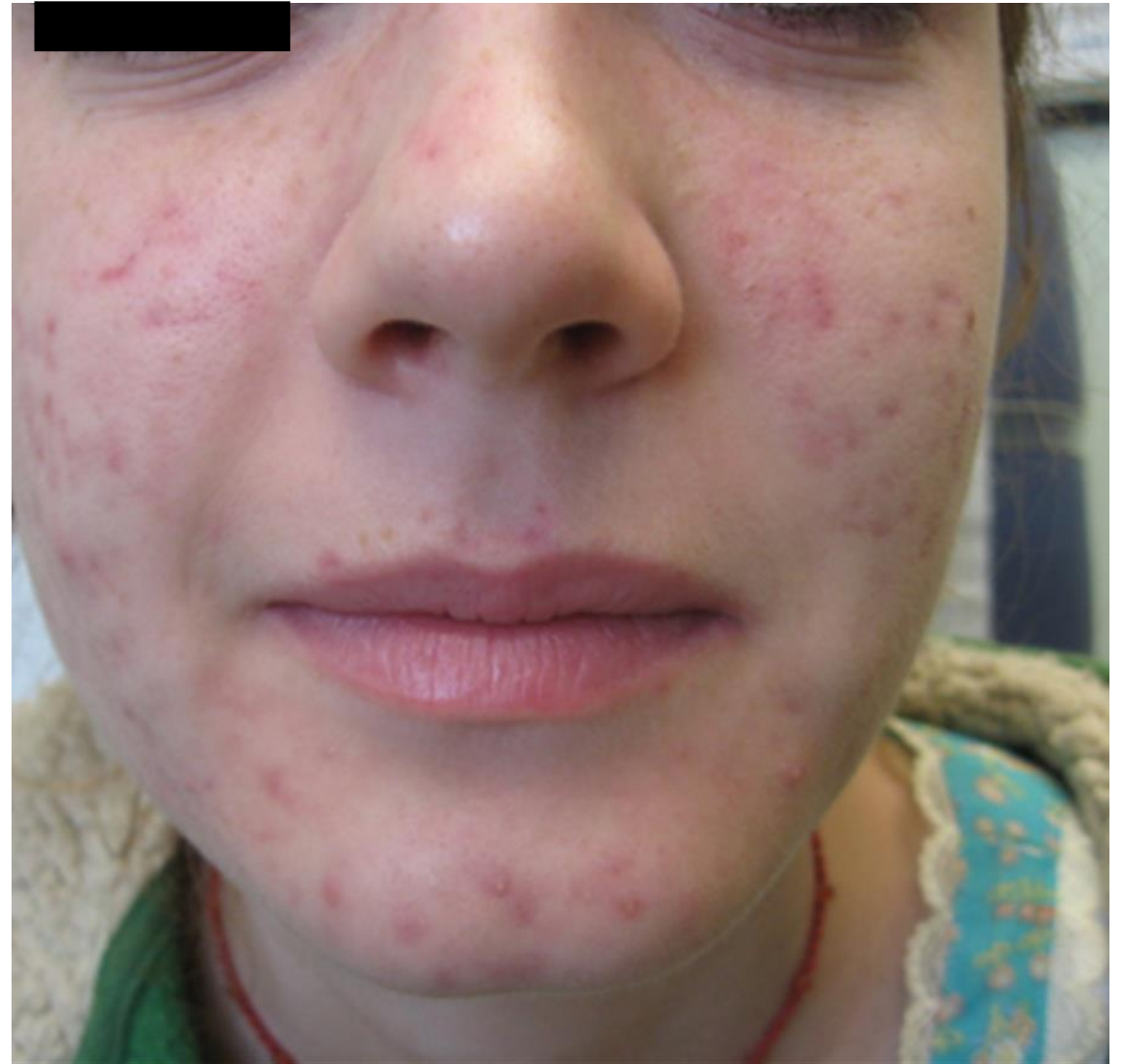Actions if Response is Poor

- ✓ Check non-drug related reasons (seborrhea, stress and diet, Malassezia furfur, G- bacteria, comedogenic skin care products, endocrine profile)
- ✓ Check drug-related reasons (adapt vehicle to skin type and environmental conditions, change topical agent, mechanically remove comedones, change from monotherapy to fixed-combination, change to higher concentration of topical). For females, check type of contraception.
- ✓ Probe patient's adherence (application technique, missed doses, tolerability)
- ✓ Ask about adverse events



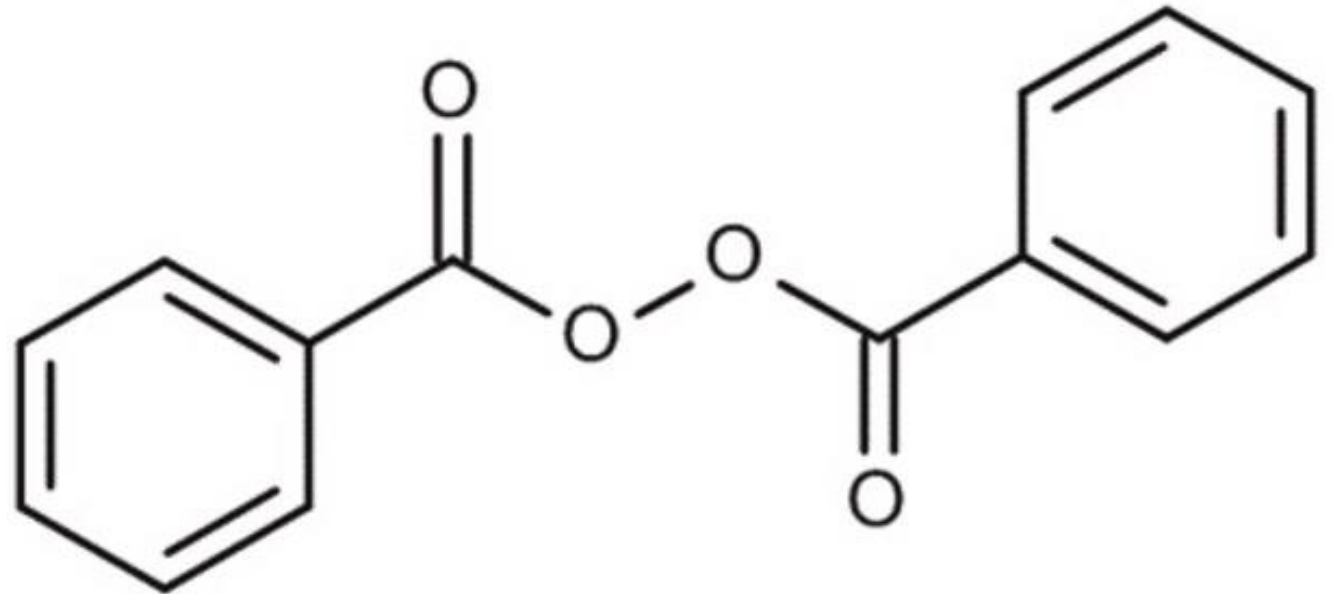
Inflammatory Acne

- First line therapy
 - Topical retinoid
 - Topical BPO
 - Topical or oral antibiotics
 - Hormone therapy
- Might consider talking with the patient about picking at her acne
 - Increases scarring potential
 - Prolongs erythema of the involved skin



Benzoyl Peroxide in acne management

- FDA cleared for OTC use
- Why does it work?
 - Oxidizes bacteria
 - No known bacterial resistance develops to BPO
 - Keratolytic agent
- Inexpensive, short exposure is effective
- Readily available at stores
- **Maintains effect of antibiotics**
- **Can cause burning and irritation**





Acne and Antibiotics

- Used longer than regular infection protocols
 - Stewardship
 - Used often in acne
 - Anti-inflammatory properties
- Bacterial counts do not correlate with acne severity
- Tetracycline is the leading class choice
- Erythromycin?
- Clindamycin?
- Others?
 - Macrolides, sulfa, amoxicillins



Acne and Antibiotics

Antibiotic	Positive	Negatives	Strengths	Misc.
Doxycycline	Anti-inflammatory Works well Standard choice	Photo sensitivity GI upset Dairy restrictions	200 mg first day then 100 mg qd	Can discolor teeth that have not come in yet
Minocycline	Anti-inflammatory Works well Standard choice Lipophilic	Found in CSF Vertigo Lupus like reaction	100 mg qd	May discolor skin with long term use
Sulfonamides	Works well against C. acnes.	FDA states "Short Term" use Allergic potential	800/160 SMZ/TMP twice daily	Long term use has been proven safe
Macrolides (NOT ERY)	Nearly equivalent to tetracyclines	No anti- inflammatory effect	500 mg day one then 250 mg for 4 days	Repeat every other week
Penicillins and cephalosporins	Case reports show good results	Temporary relief, no anti-inflammatory properties	Mutiple	Not well studied, no long term recommendations Safe in peds





Acne and Antibiotics

- Tetracycline Class
 - **INCORPORATE BPO WITH ABx**
-





Acne and Antibiotics

- Tetracycline
 - Doxycycline and minocycline are excellent first choices
- Macrolides
 - Azithromycin
 - ~~Erythromycin~~ DO NOT USE
- Clindamycin
 - Topical over oral

• INCORPORATE BPO WITH ABx



Inflammatory Acne

Treatment therapy might include:

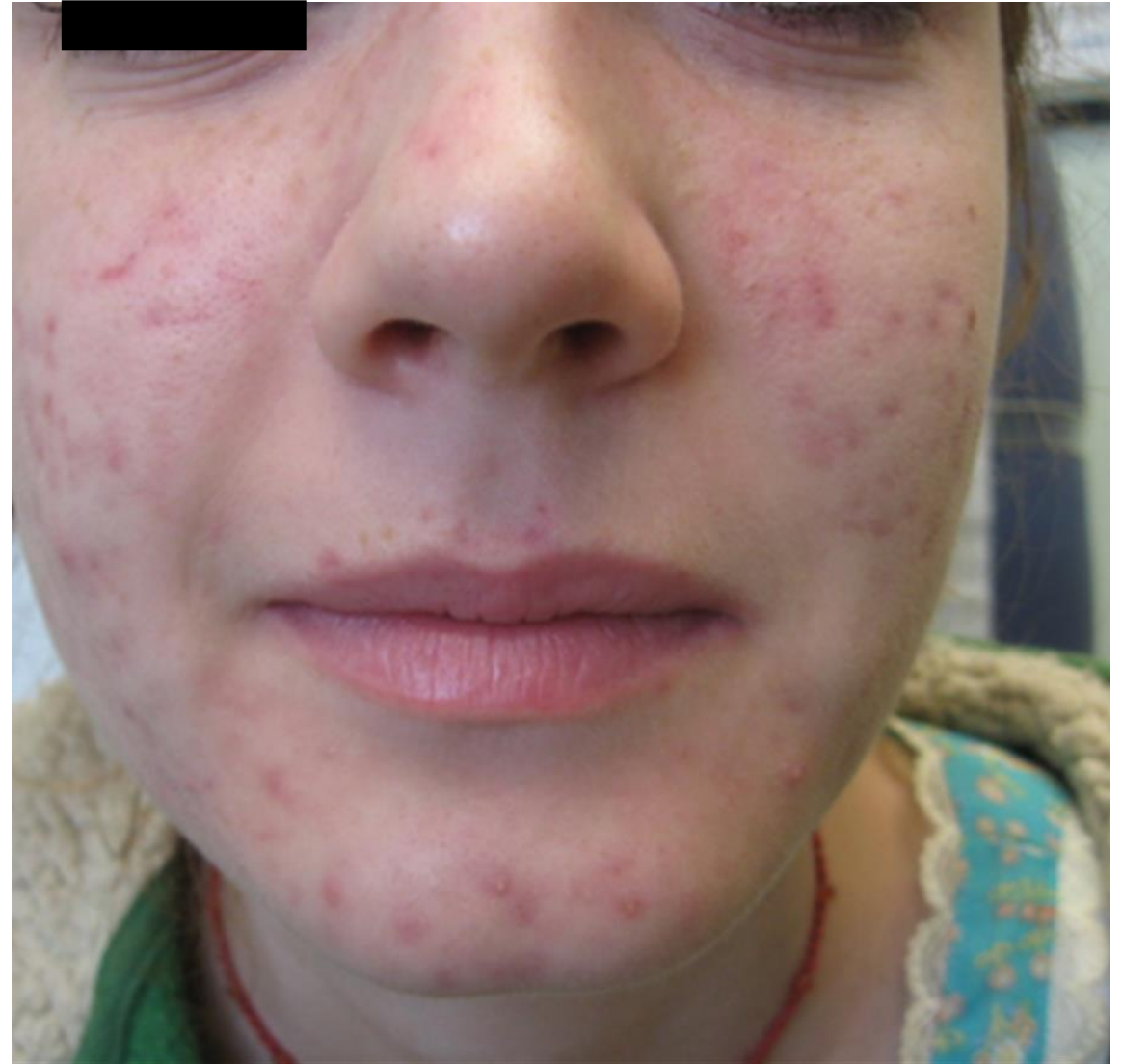Topical retinoid/BPO combo qhs

Oral doxycycline 100mg qd

Might consider

Oral contraceptive

pills with estrogen and progestin



Inflammatory Acne

Pearls:

Educate the likelihood of scarring

Screen for PCOS

 certain location of acne

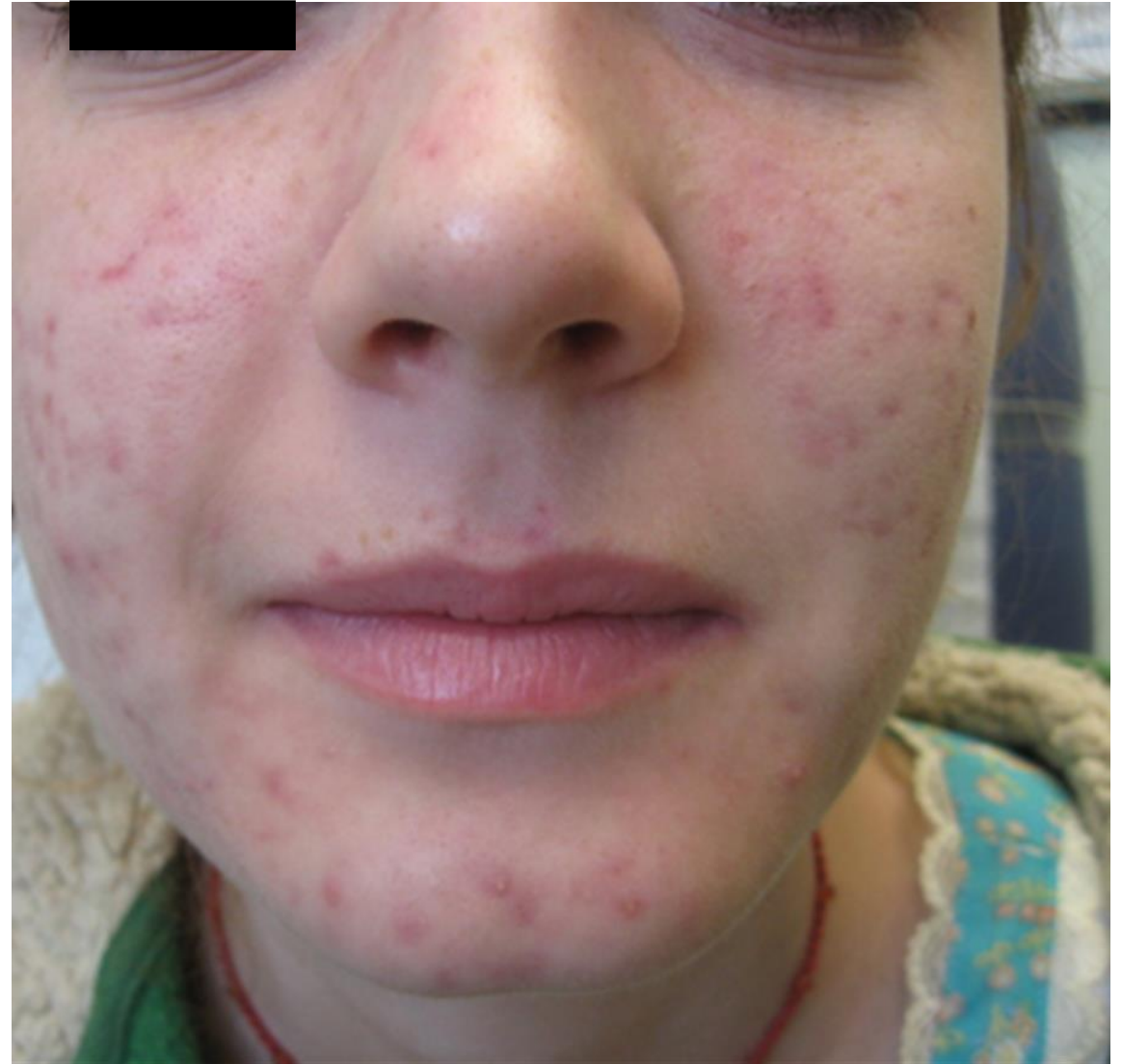Could it be G- issue?

My Favorite Management

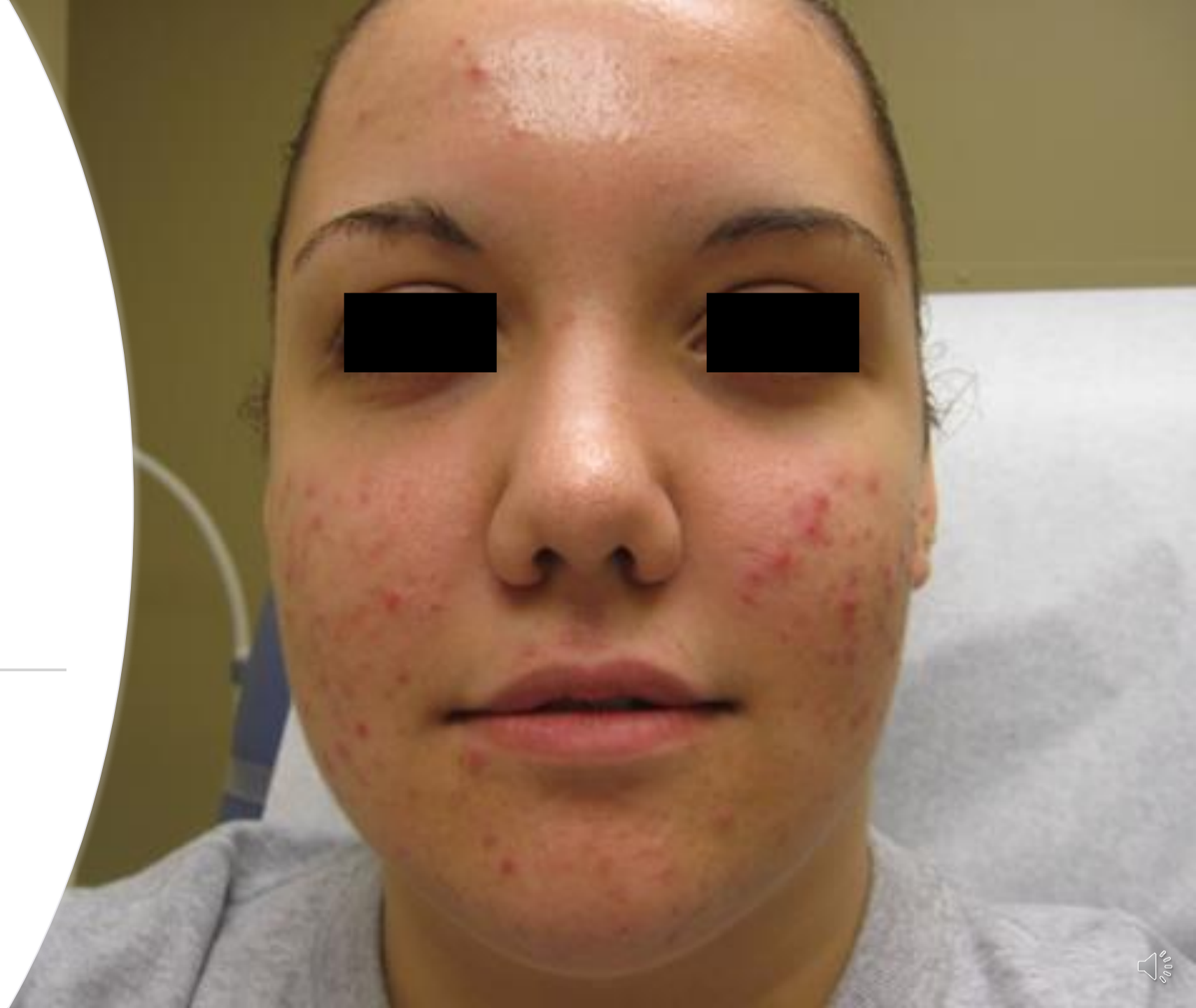Oral Antibiotic (doxy 100 qd)

Topical retinoid/BPO combo

Oral contraceptive

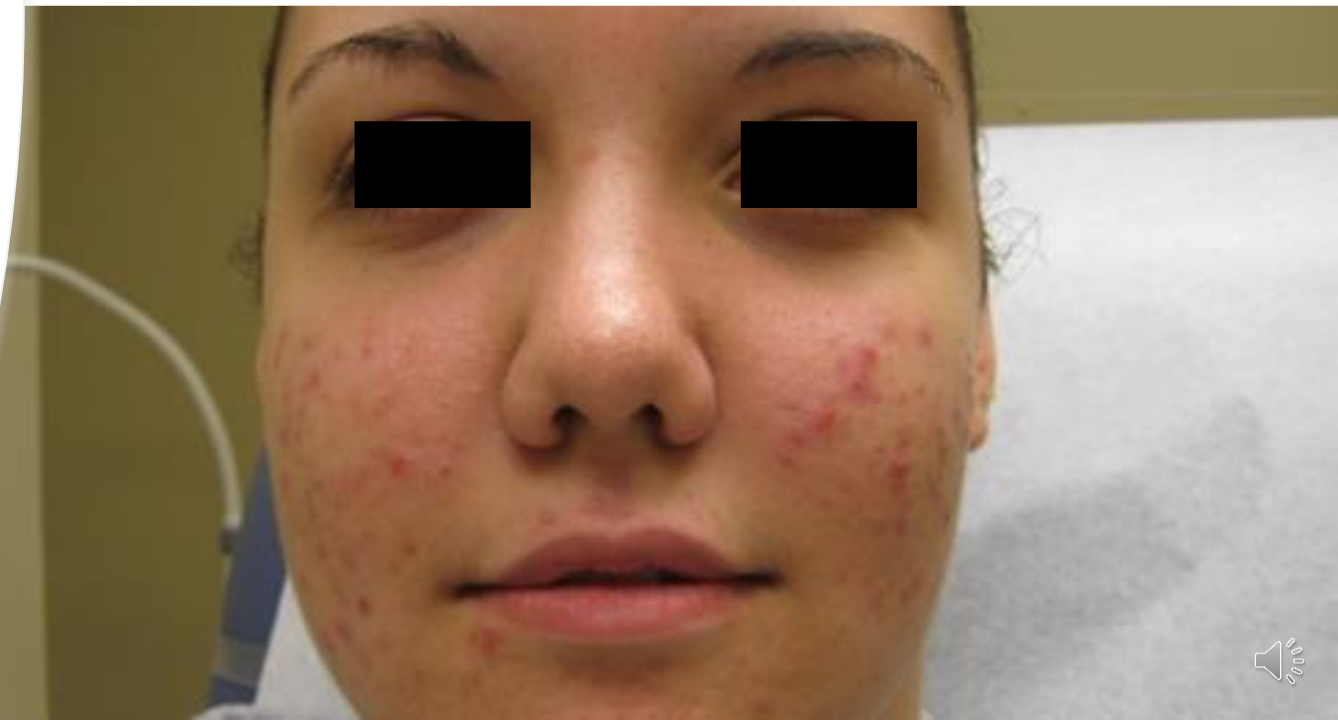
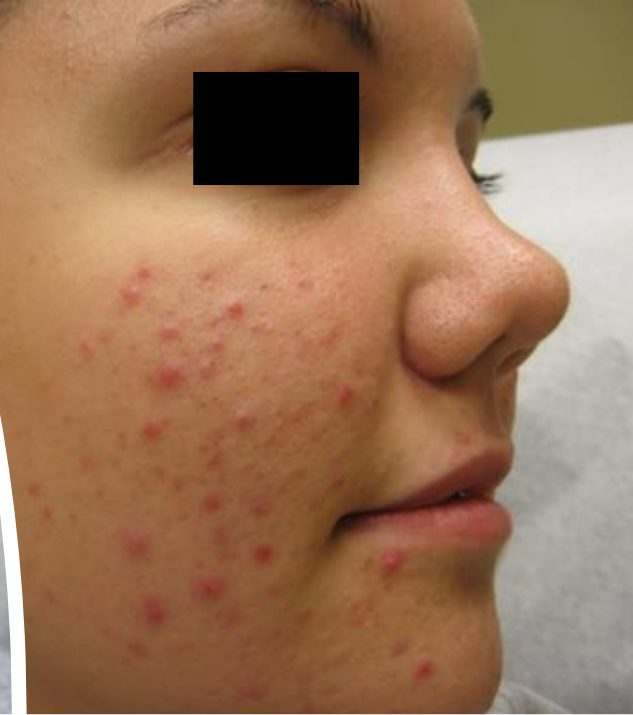
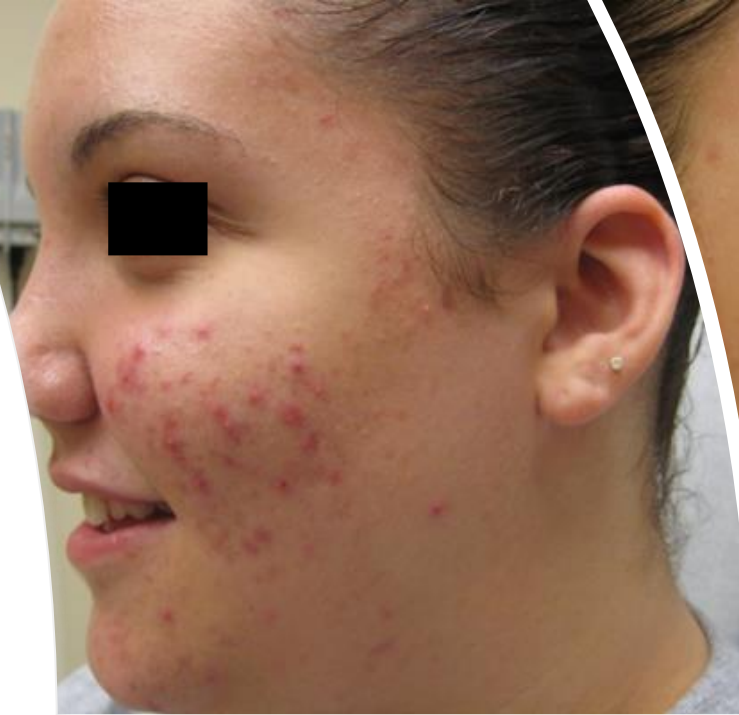
Acne in the
Pregnant
Patient



Acne in Pregnancy

- Range from mild to severe
- 1st and 2nd trimester
- Hormones stimulate sebum production
- Subsequent pregnancies may be associated with worsening acne



Treatment Options for Pregnant Patients

- Topical
 - Erythromycin
 - Clindamycin
 - Metronidazole
 - Azelaic acid
 - Sodium sulfacetamide
 - Salicylic acid
 - Dapsone
 - Glycolic acid peels
- Oral
 - Beta-Lactams (1st line)
 - Penicillins
 - Cephalosporins
 - Macrolides
 - Erythromycin base
 - Ethylsuccinate
 - Azithromycin
 - Metronidazole
 - AVOID: tetracyclines, TMP-SMZ, fluoroquinolones, retinoids
 - CAUTION: prednisone



Typical Treatment Plan for Pregnant Patients

Mild: Topical BPO +/- antibiotic (BPO and topical clinda) or azelaic acid mono therapy

Moderate: Topical BPO with antibiotic +/- oral antibiotic or azelaic acid with oral antibiotic (oral abx of choice is amoxicillin)

Severe: Oral antibiotic + topical BPO/antibiotic, consider prednisone for more severe cases (consult with OB/GYN)

Refractory cases:

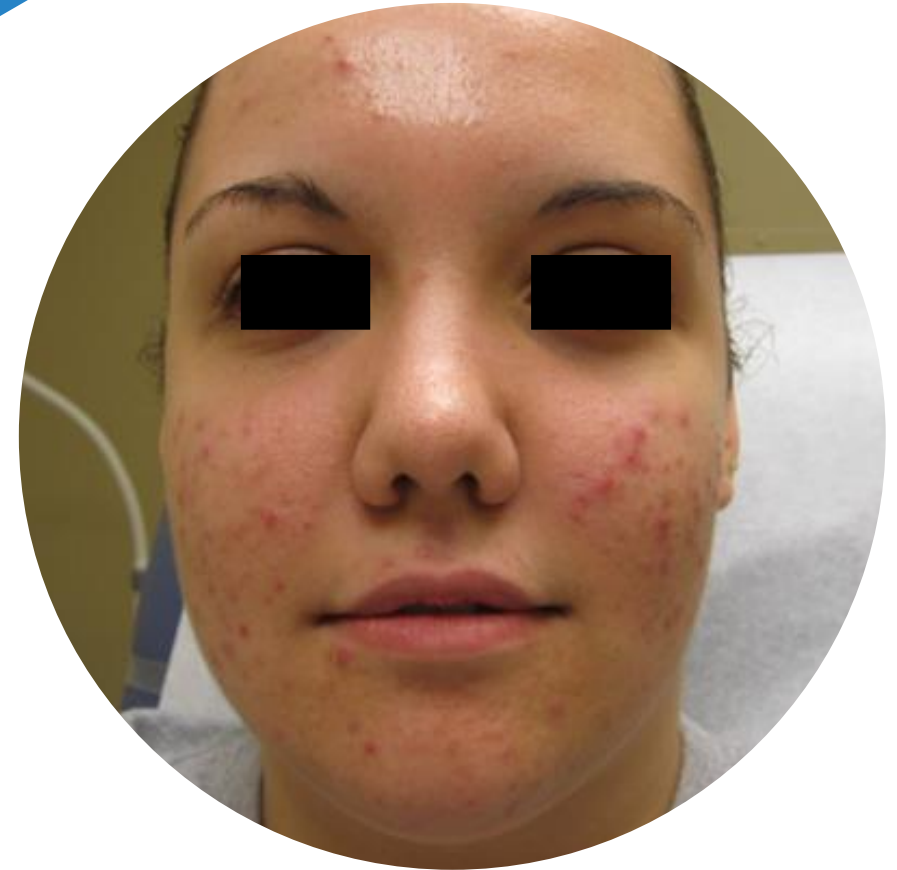Photodynamic therapy (folate deficiency may occur)

Skin peels or hygienic care that is non-inflammatory

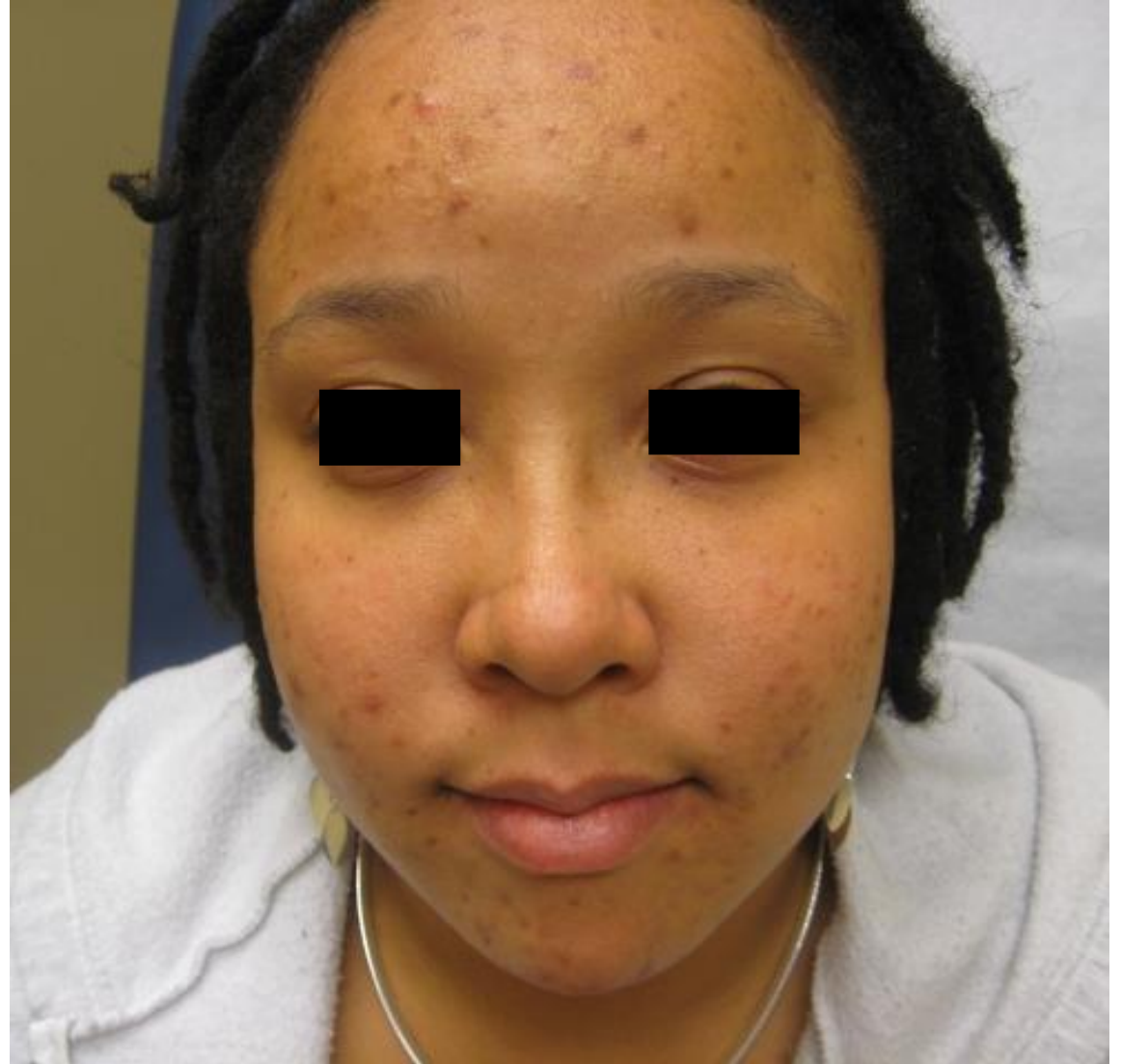Pulsed Dye Laser

IPL

Microneedling with topical

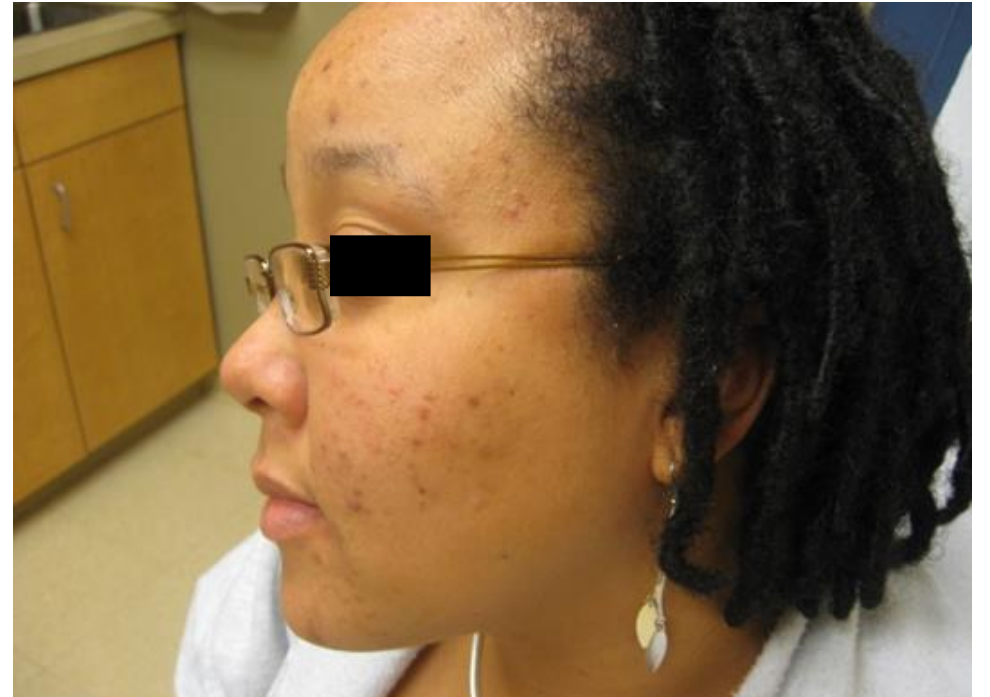
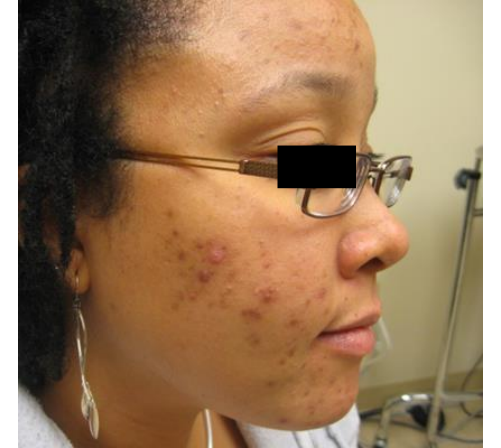
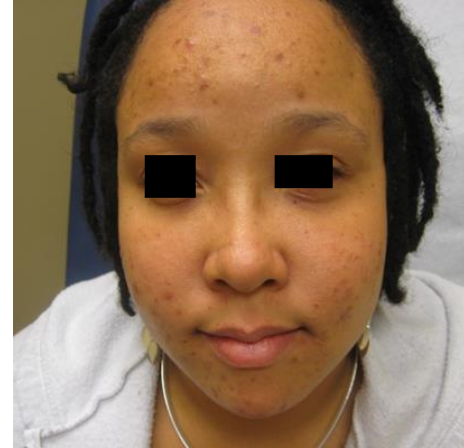Acne in Skin of Color



Acne in Skin of Color

- Pigmentation concerns
 - Post inflammatory Hyperpigmentation
- Minimize inflammation to control color changes
- Tolerated similar treatment plans as light skin patients



Acne in Skin of Color Treatment Options

- Focus on effective treatment with minimal inflammation
 - Mild (comedonal only)
 - Topical retinoid +/- BPO +/- topical dapsone (yellowing of the skin is transient)
 - Moderate (papular/pustular variant)
 - Topical retinoid with BPO or
 - Azelaic Acid
 - Hormone therapy and Oral antibiotics as needed
 - Mod/Severe to Severe
 - Fixed combination (top retinoid/BPO) +
 - oral antibiotic OR
 - Oral isotretinoin (dosed as 0.5 mg/kg bid until 125-150 mg/kg cumulative dose) OR
 - Oral hormone therapy



Acne in Skin of Color Treatment Options

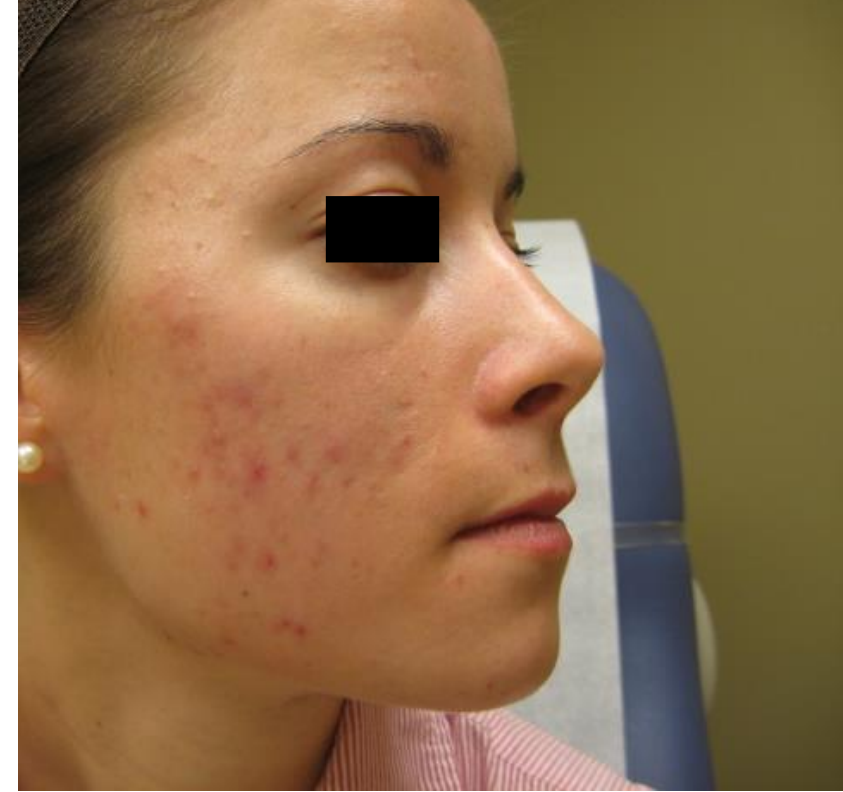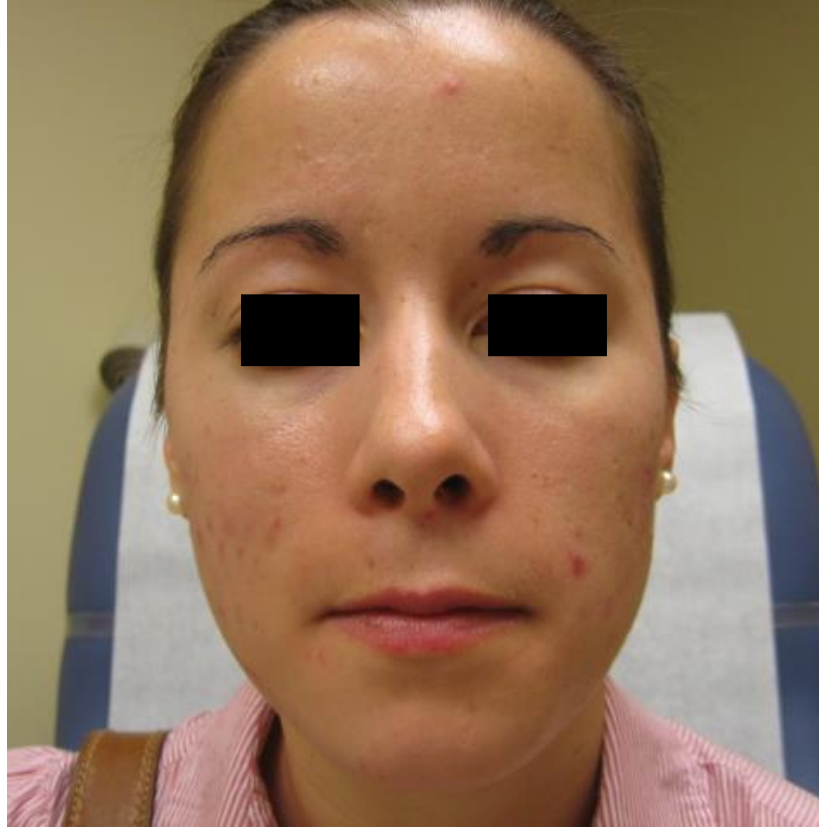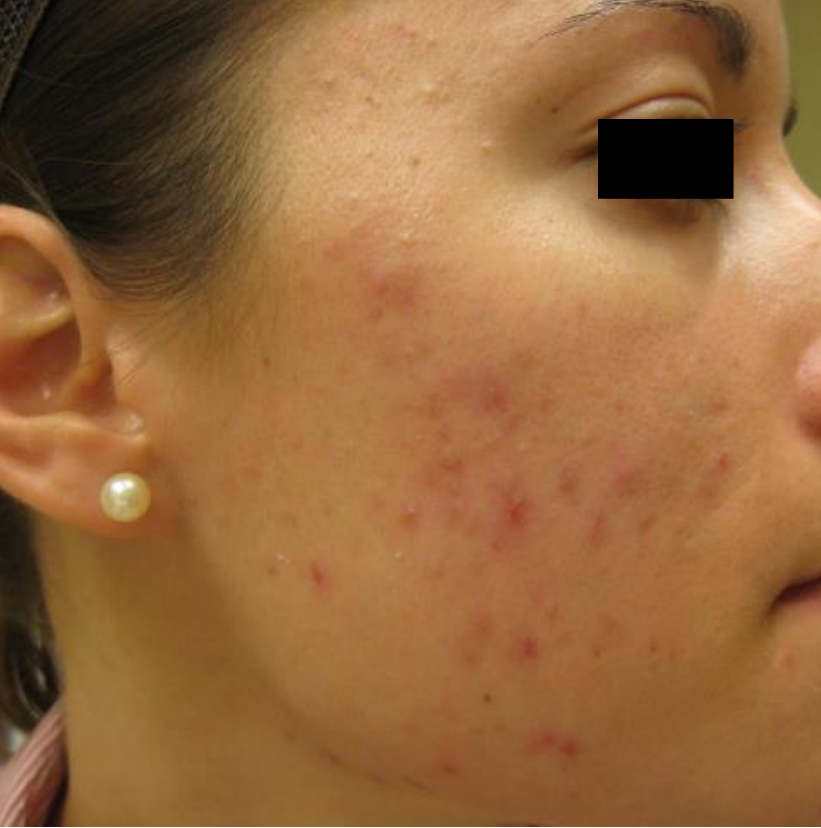- Focus on effective treatment with minimal inflammation
 - Mild (comedonal only)
 - Topical retinoid +/- BPO +/- topical dapsone (yellowing of the skin is transient)
 - Moderate (papular/pustular variant)
 - Topical retinoid with BPO or
 - **Azelaic Acid**
 - **Hormone therapy** and Oral antibiotics as needed
 - Mod/Severe to Severe
 - Fixed combination (top retinoid/BPO) +
 - oral antibiotic OR
 - Oral isotretinoin (dosed as 0.5 mg/kg bid until 125-150 mg/kg cumulative dose) OR
 - Oral hormone therapy



Acne in Skin of Color Treatment Options

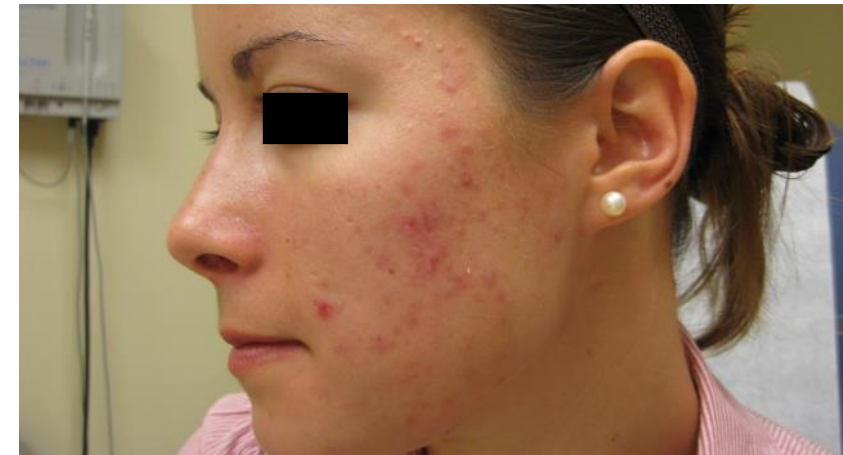- **Azelaic Acid (15% gel, foam)**
 - FDA approved as monotherapy
 - Similar to BPO and clindamycin topicals
 - Can cause irritation initially
 - Side effect of hypopigmentation
 - Reduces free radical production
 - Suppresses melanocyte activity
- **Hormone therapy**
 - Oral contraception
 - Spironolactone (lowest effective dose)
 - Both reduce androgen effects and can minimize hyperpigmentation by decreasing inflammation





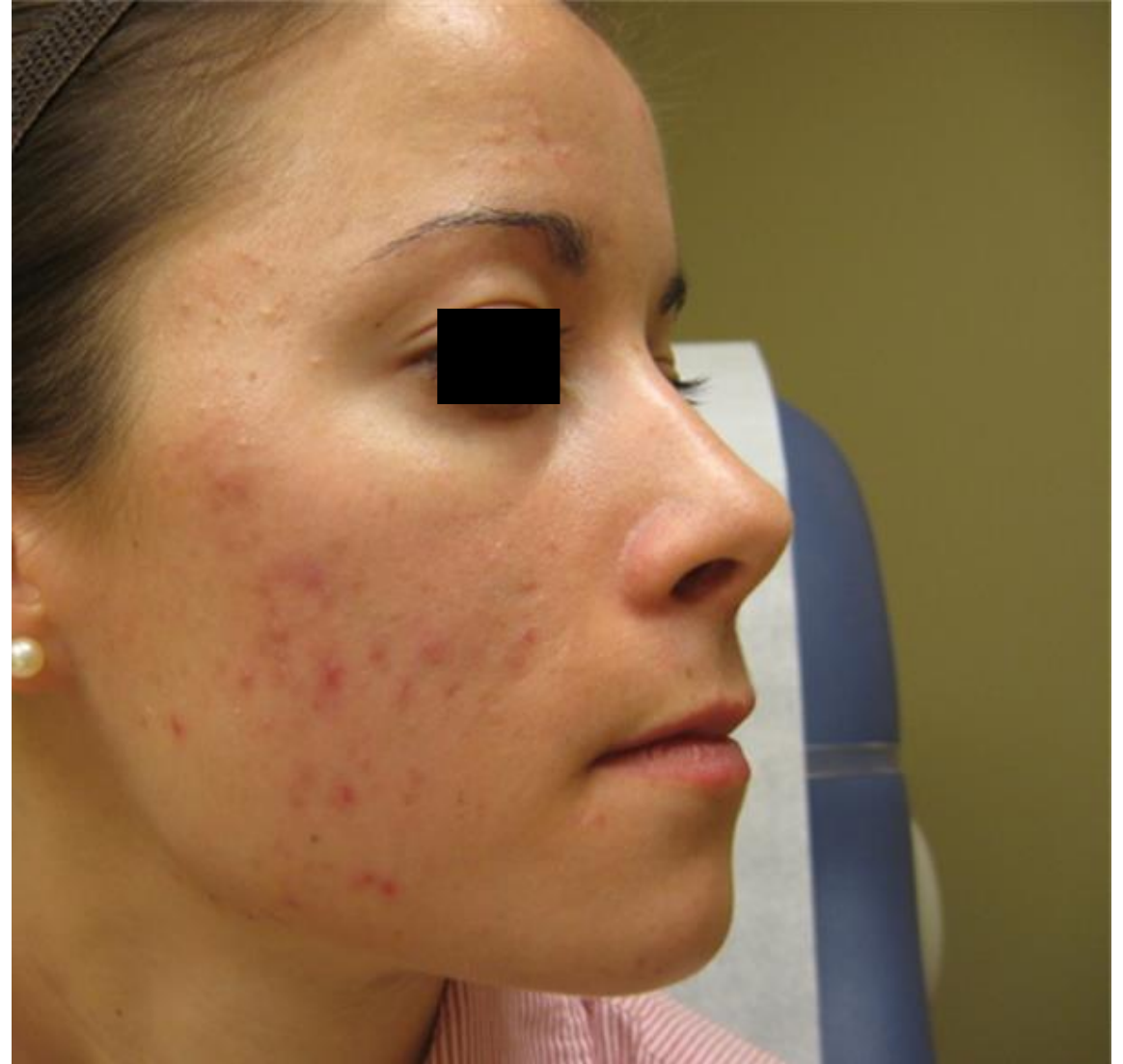Adult Women
Is this a special
Population?


- Slightly different presentation
- Possible reasons WHY this is a phenomenon



Adult Acne in Women

- Biology is arguably the same as in younger patients
- Consider:
 - Hormonal changes/therapy
 - Stress levels (releases pro-inflammatory cytokines)
 - Tobacco use





Treating these adult women...

- Similar to treatments for the younger population
- Focus on hormonal changes
- Consider treatment with:
 - Hormones and Spironolactone
 - Topical retinoids to help exfoliate photodamaged skin
 - Dapsone topical
 - Decreased inflammatory mediators



Women and PCOS

- Polycystic Ovarian Syndrome (PCOS)
 - Excessive ovarian androgen production
 - Failure of ovulation (irregular menses)
 - Multiple peripheral ovarian follicles that appear as cysts on enlarged ovaries
- 5-10% of reproductive age women
- Symptoms:
 - Hyperandrogenemia
 - Hirsutism
 - Acne vulgaris
 - Androgenic Alopecia
 - Associated with an increase in BMI



Women and PCOS

- Treatment options
 - Ovarian Suppression
 - Oral contraception combinations of estrogen and progestin
 - Estrogen: stimulates sex-hormone binding globulin thereby decreasing availability of testosterone
 - Progestin: lowers the androgen effect by inhibiting 5- α -reductase (decreases conversion of testosterone to DHT)
 - Anti-androgen therapy
 - Spironolactone (widely used in dermatology 50-100mg)
 - Competes for the androgen receptor
 - Suppression of cytochrome P450 and steroidgenesis
 - Suppresses 5- α -reductase activity
 - K⁺ sparring diuretic, eval as needed

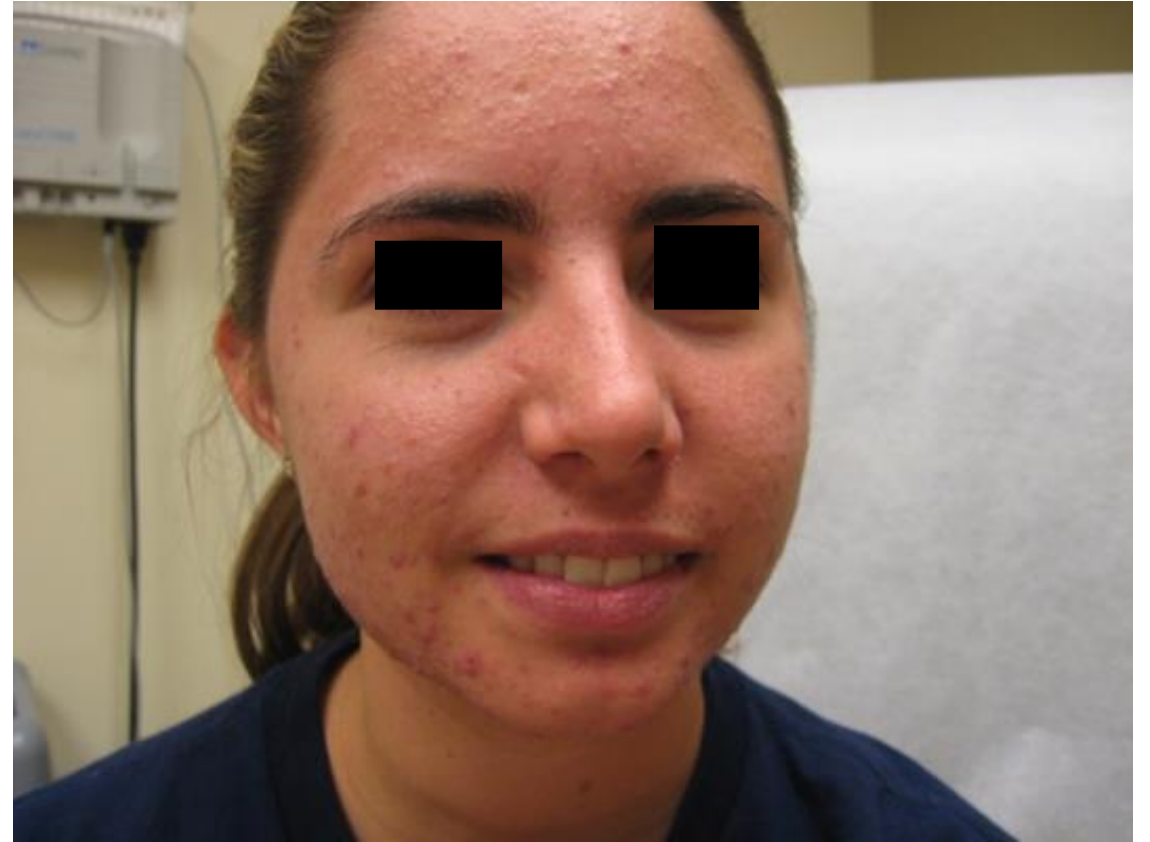
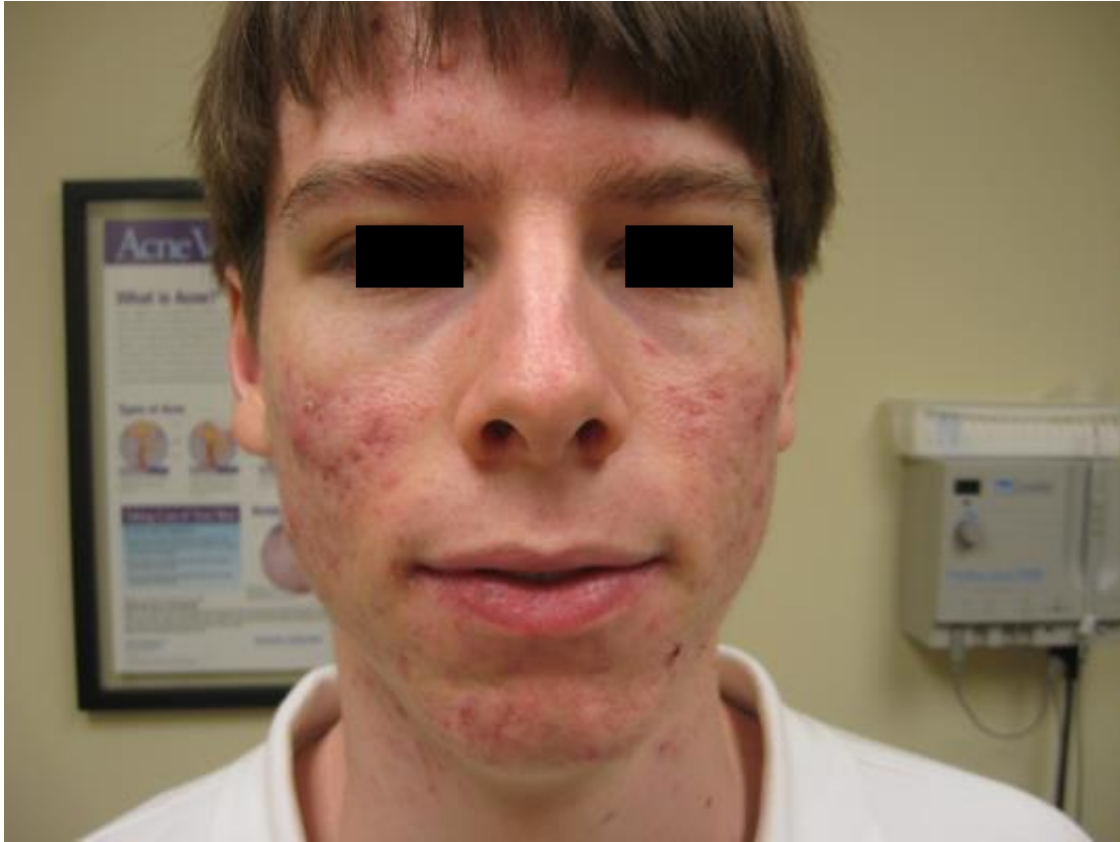
Women and PCOS

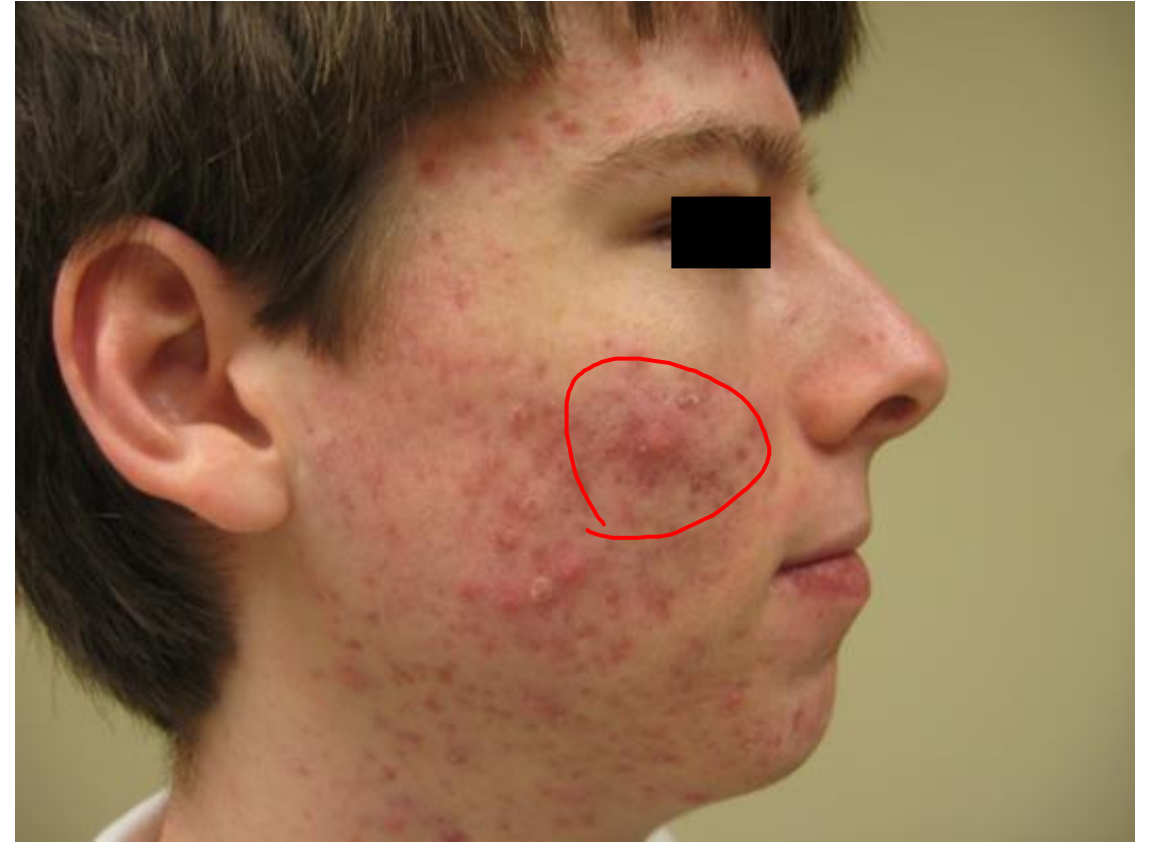
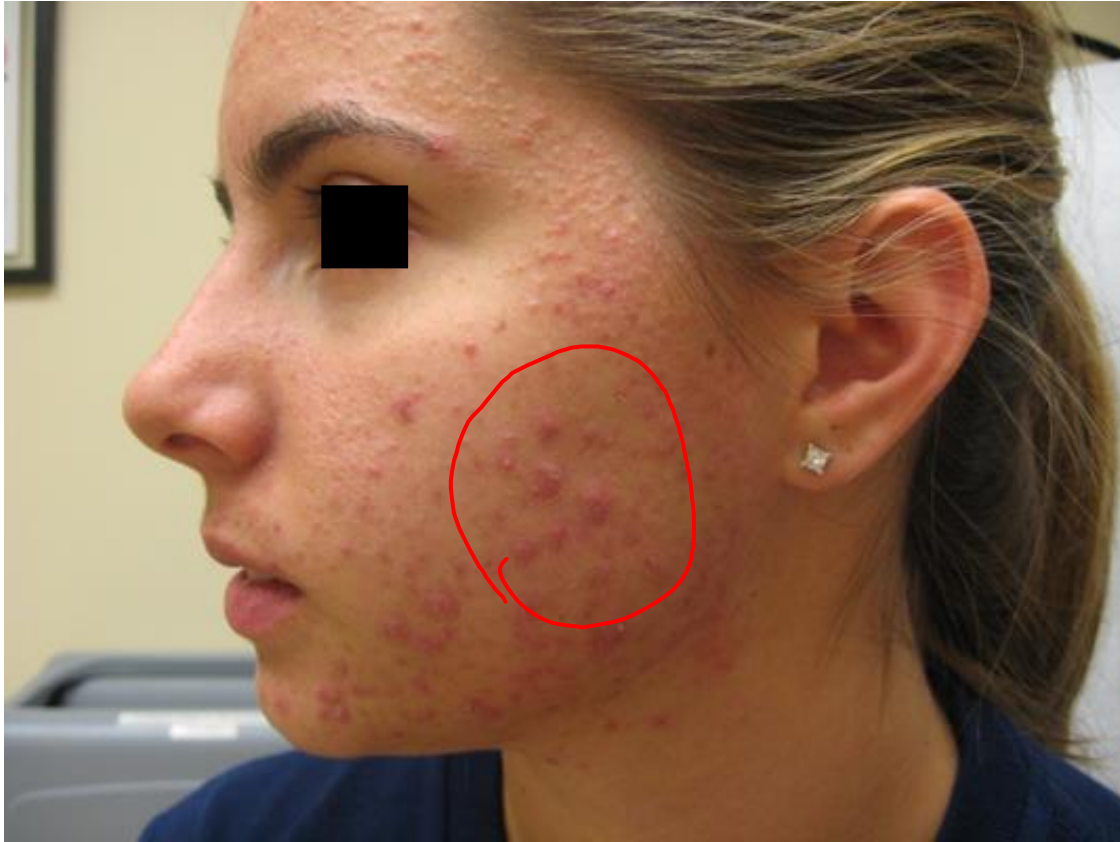- Treatment suggestions
 - Oral OCP (combination pill)
 - Add Spironolactone (50-100mg daily) if there is no significant improvement 3 months
 - Tretinoin topical
- Referral to Primary Care, GYN, or Endocrinology for evaluation
- Diet modification to avoid high-glycemic foods (not strongly supported)



Severe Acne



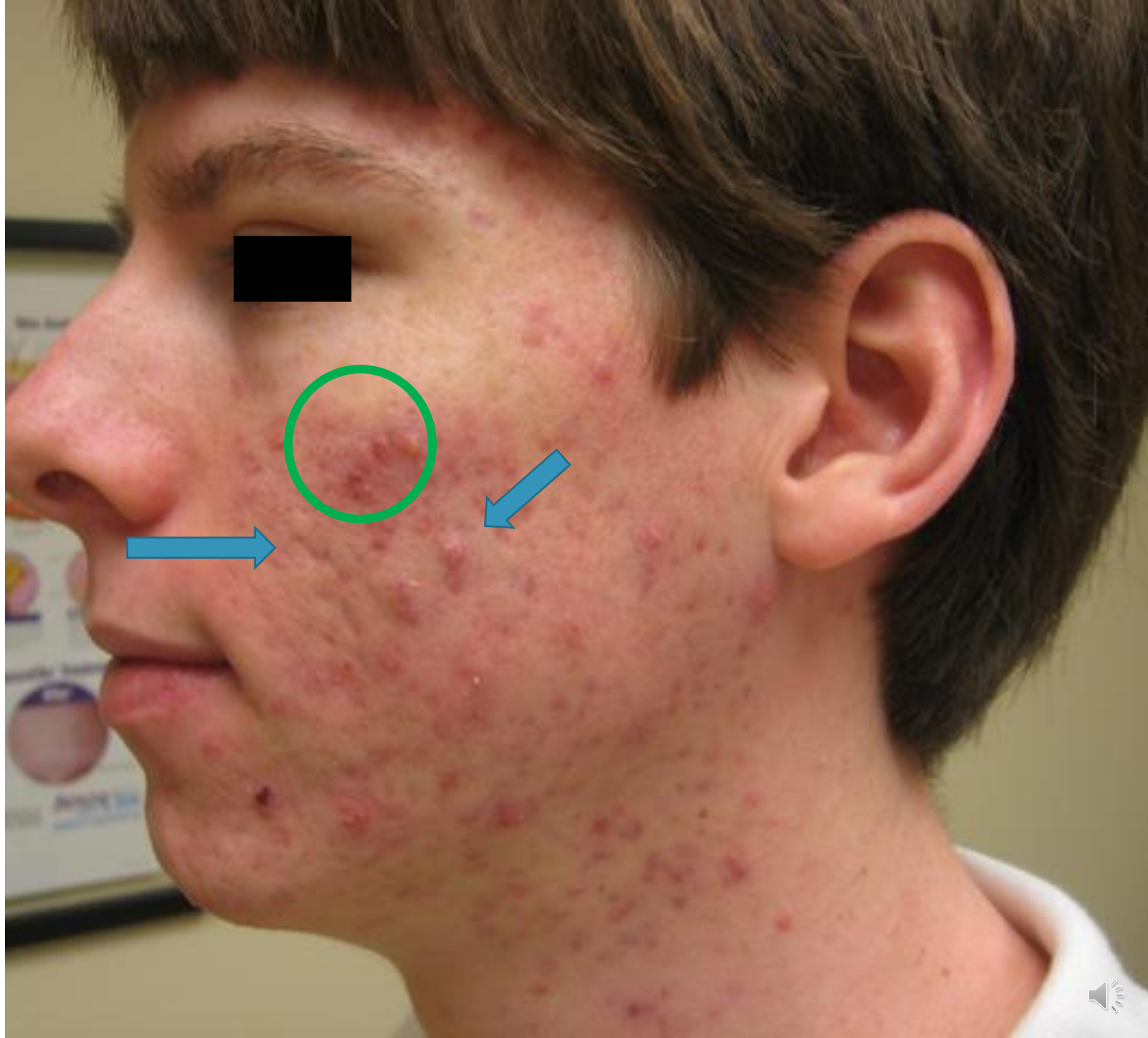
Severe Acne



Severe Acne

- Scarring
- Nodules
- Inflammation

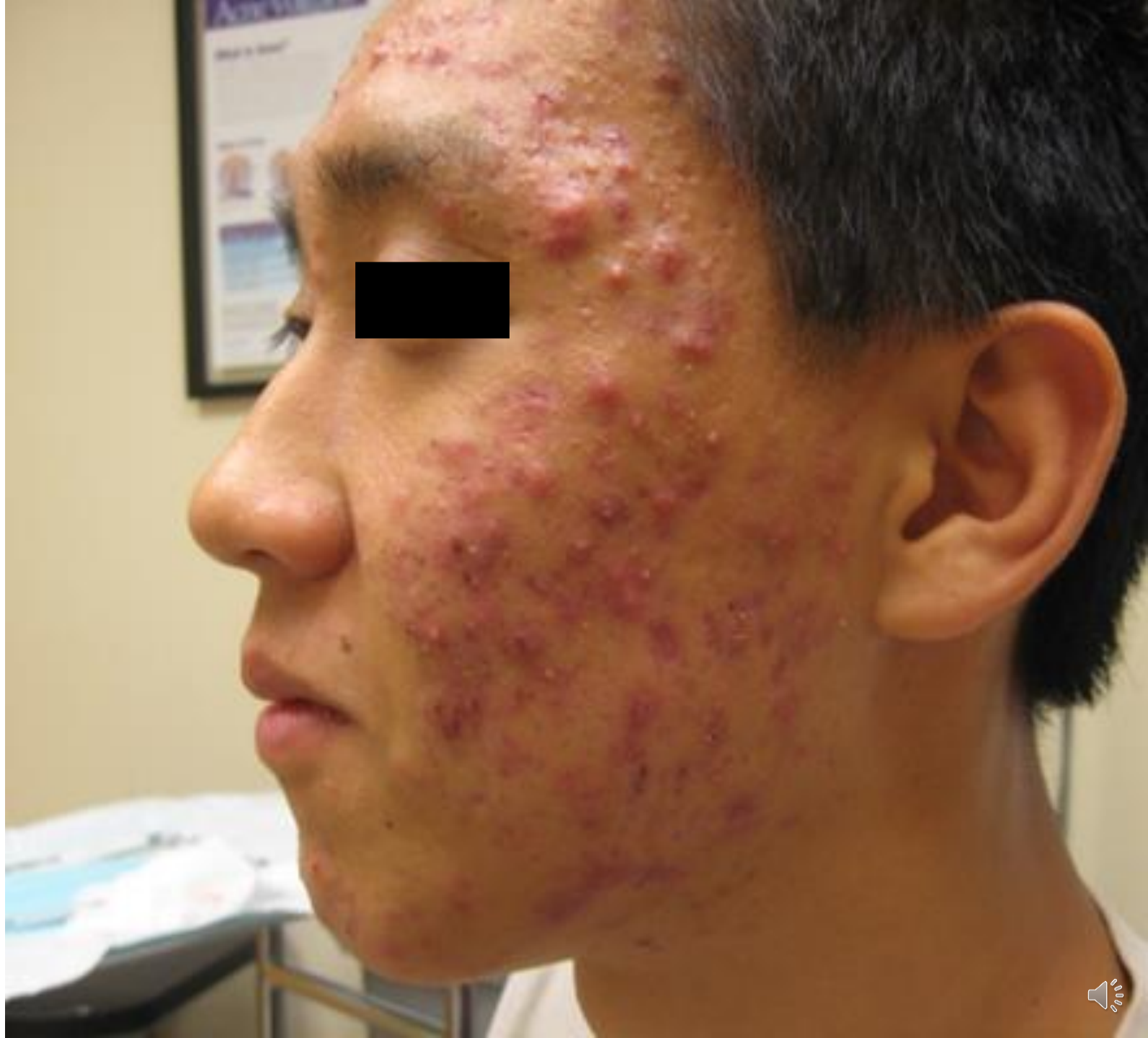- Numerous and widespread pathology
- Chronic disease with lasting effects



Severe Acne and Isotretinoin

- Do not withhold if indicated
- Not only for severe acne
 - Recalcitrant acne
 - Persistent patients
- High scarring potential pts.

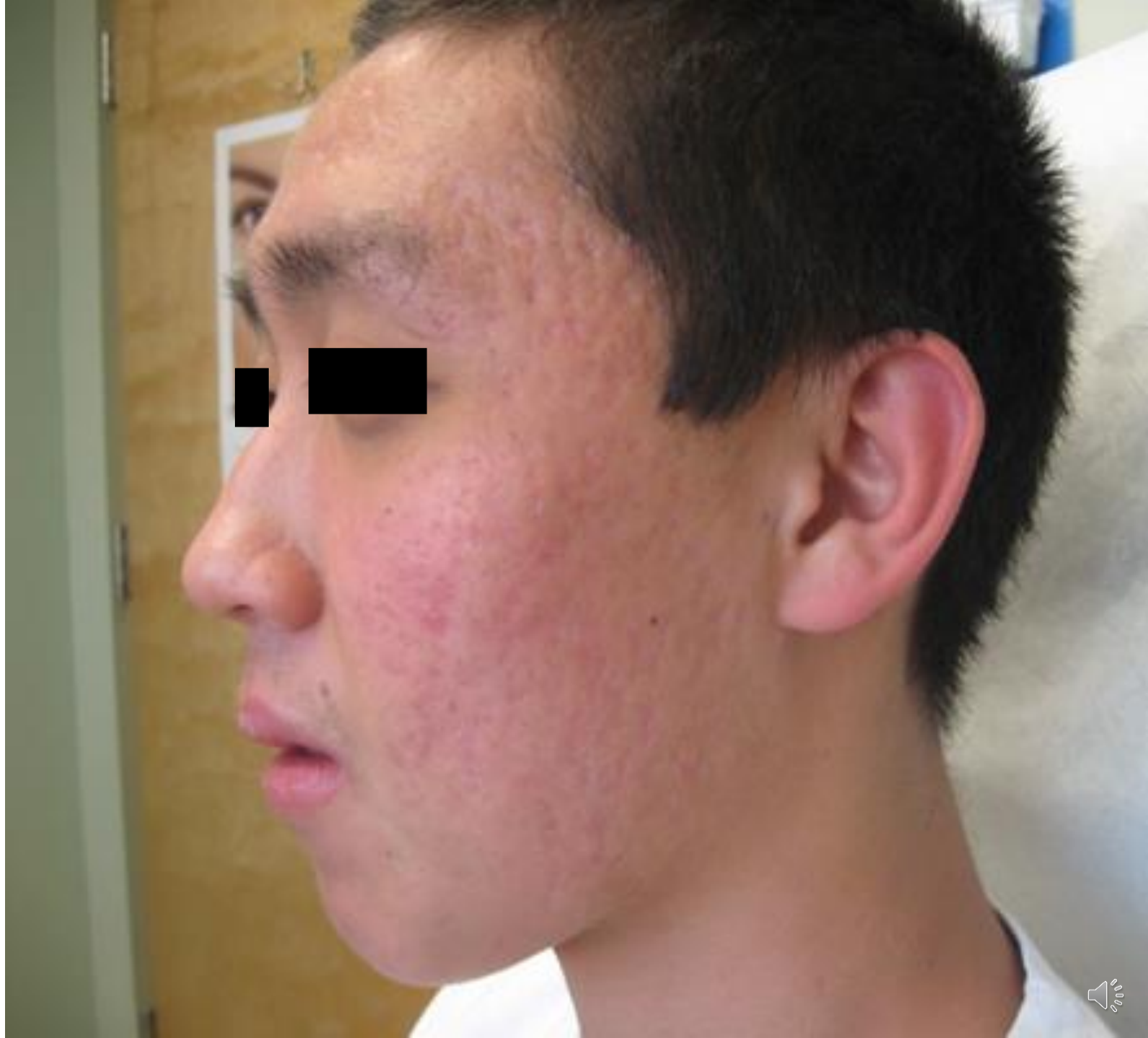- The American Academy of Dermatology's position paper:
 - Depression
 - Bowel disease



Severe Acne and Isotretinoin

- Do not withhold if indicated
- Not only for severe acne
 - Recalcitrant acne
 - Persistent patients
- High scarring potential pts.


- The American Academy of Dermatology's position paper:
 - Depression
 - Bowel disease



Citations

- Chia CY, Lane W, Chibnall J, Allen A, Siegfried E. Isotretinoin Therapy and Mood Changes in Adolescents With Moderate to Severe Acne: A Cohort Study. *Arch Dermatol*. 2005;141(5):557–560. doi:10.1001/archderm.141.5.557
- Consumer Reports web-site <https://www.consumerreports.org/cro/news/2011/11/clearing-up-the-confusion-over-acne-products/index.htm>
- C.B. Boswell, MD, Skincare Science: Update on Topical Retinoids, *Aesthetic Surgery Journal*, Volume 26, Issue 2, March 2006, Pages 233–239
- Zasada M, Budzisz E. Retinoids: active molecules influencing skin structure formation in cosmetic and dermatological treatments. *Postepy Dermatol Alergol*. 2019;36(4):392–397. doi:10.5114/ada.2019.87443
- Stopień R, Milewska E, Rynio P, Męczekalski B. Use of oral contraceptives for management of acne vulgaris and hirsutism in women of reproductive and late reproductive age. *Prz Menopauzalny*. 2018;17(1):1–4. doi:10.5114/pm.2018.74895
- Kawashima M, Nagare T, Doi M. Clinical efficacy and safety of benzoyl peroxide for acne vulgaris: Comparison between Japanese and Western patients. *J Dermatol*. 2017;44(11):1212–1218. doi:10.1111/1346-8138.13996
- Awan SZ, Lu J. Management of severe acne during pregnancy: A case report and review of the literature. *Int J Womens Dermatol*. 2017;3(3):145–150. Published 2017 Jul 13. doi:10.1016/j.ijwd.2017.06.001
- Treatment of Acne in Pregnancy Anna L. Chien, Ji Qi, Barbara Rainer, Dana L. Sachs, Yolanda R. Helfrich *The Journal of the American Board of Family Medicine* Mar 2016, 29 (2) 254-262; DOI: 10.3122/jabfm.2016.02.150165
- Pandey N, Cascella M. Beta Lactam Antibiotics. [Updated 2019 Sep 30]. In: StatPearls [Internet]. Treasure Island (FL): StatPearls Publishing; 2020 Jan-. Available from: <https://www.ncbi.nlm.nih.gov/books/NBK545311/>
- Microneedling in skin of color: A review of uses and efficacy, Cohen, Brandon E. et al., *Journal of the American Academy of Dermatology*, Volume 74, Issue 2, 348 – 355
- Versatility of azelaic acid (AzA) 15% gel in treatment of acne vulgaris: A review of clinical literature, *Journal of the American Academy of Dermatology*, Volume 56, Issue 2, AB18
- Bandyopadhyay D. Topical treatment of melasma. *Indian J Dermatol*. 2009;54(4):303–309. doi:10.4103/0019-5154.57602
- Bagatin E, Freitas THP, Rivitti-Machado MC, et al. Adult female acne: a guide to clinical practice [published correction appears in *An Bras Dermatol*. 2019 Mar-Apr;94(2):255. Machado MCR [corrected to Rivitti-Machado MC]]. *An Bras Dermatol*. 2019;94(1):62–75. doi:10.1590/abd1806-4841.20198203
- McCarty M, Rosso JQ. Chronic administration of oral trimethoprim-sulfamethoxazole for acne vulgaris. *J Clin Aesthet Dermatol*. 2011;4(8):58–66.
- Zaenglein AL, Pathy AL, Schlosser BJ, Alikhan A, Baldwin HE, Berson DS, et al. Guidelines of care for the management of acne vulgaris. *J Am Acad Dermatol*. 2016 Feb 15.
- Titus S, Hodge J. Diagnosis and Treatment of Acne. *Am Fam Physician*. 2012 Oct 15;86(8):734-740
- Tan, A. U., Schlosser, B. J., & Paller, A. S. (2017). A review of diagnosis and treatment of acne in adult female patients. *International journal of women's dermatology*, 4(2), 56–71. doi:10.1016/j.ijwd.2017.10.006
- Chuan SS, Chang RJ. Polycystic ovary syndrome and acne. *Skin Therapy Lett*. 2010;15(10):1–4





Thank You from Me and Your Patients!

Contact Information:

Scott Freeman MS, PA-C
scottfreeman.74@gmail.com

- Treat aggressively
- Treat accurately
- Treat the patient as a person

Your patients will love you
And they will love you if you try

