
Introduction to Point of Care Ultrasound (POCUS)

Adrijana Anderson, PA-C
Mayo Clinic Arizona

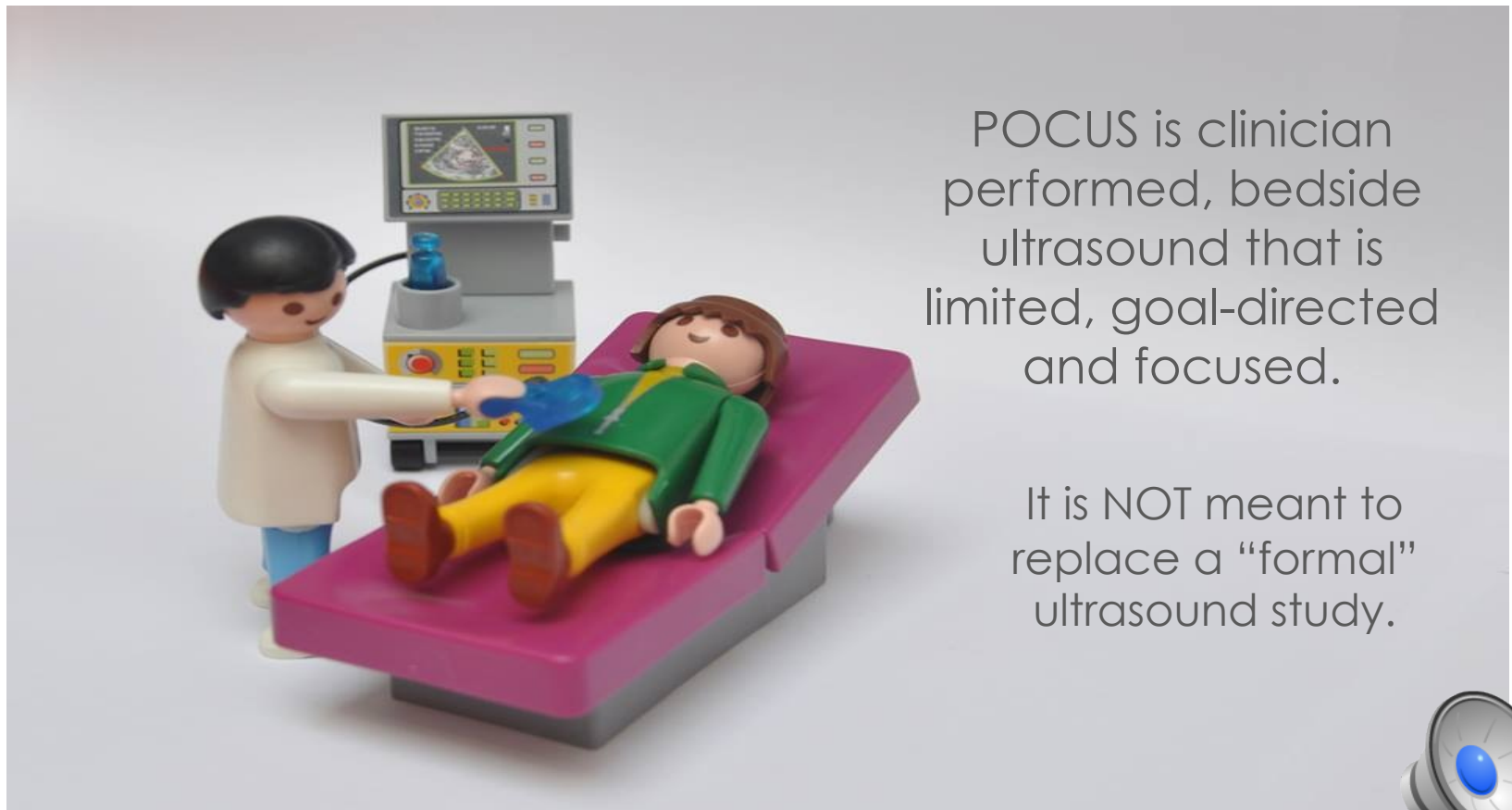


Objectives

- Explain the indications for the use of bedside, point-of-care ultrasound (POCUS).
- Describe the basics of ultrasound technology, and “knobology”.
- Be able to perform basic cardiac, lung, and eFAST ultrasound exams.



Point-Of-Care Ultrasound (POCUS)



POCUS is clinician performed, bedside ultrasound that is limited, goal-directed and focused.

It is NOT meant to replace a “formal” ultrasound study.



Why should I learn ultrasound?

- ▣ It will make you a **better clinician**
- ▣ It will improve your procedural skills
- ▣ You can be reimbursed for this!

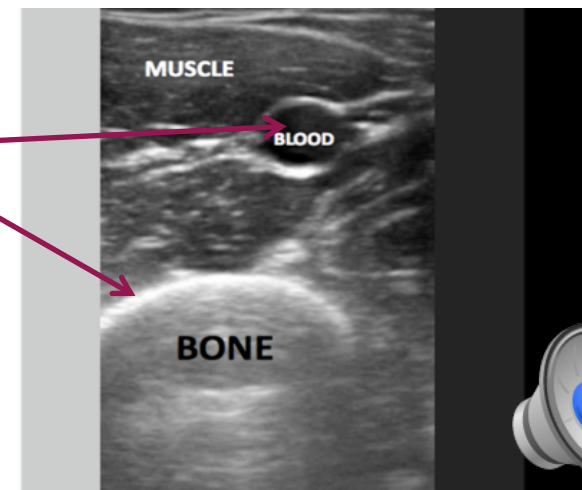
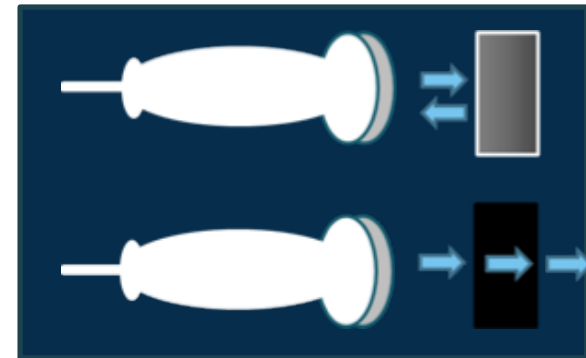


Basics of Ultrasound

Principle of Ultrasound:

sound waves are emitted from the probe and reflect on objects depending on impedance.

- ❑ Returned hyperechoic signals appear white
- ❑ Anechoic appears black (eg. fluid)
- ❑ Frequency \propto resolution



Basic “Knobology”

1. Power button
2. Exam type
3. Depth
4. Gain



Transducers



Linear
(high frequency)
"Vascular"



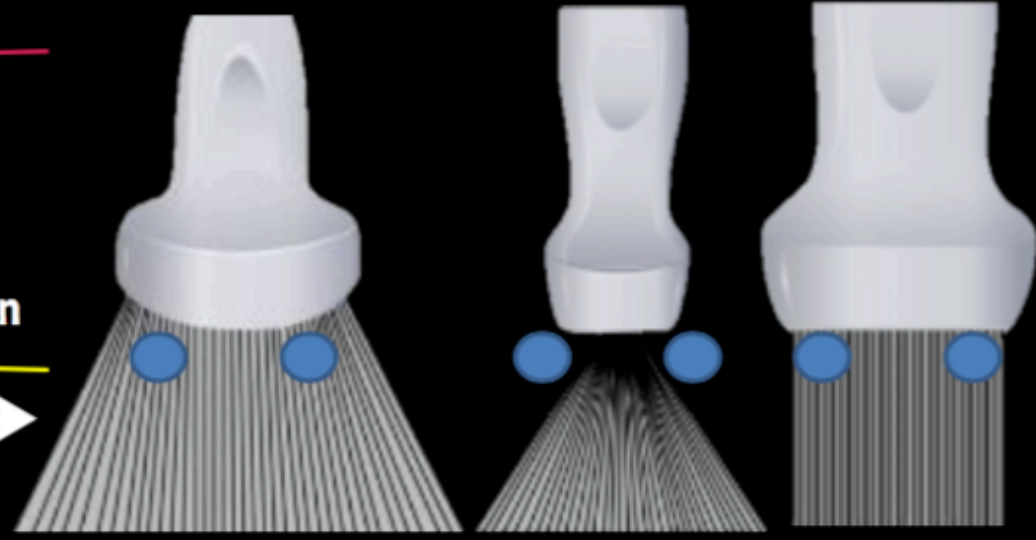
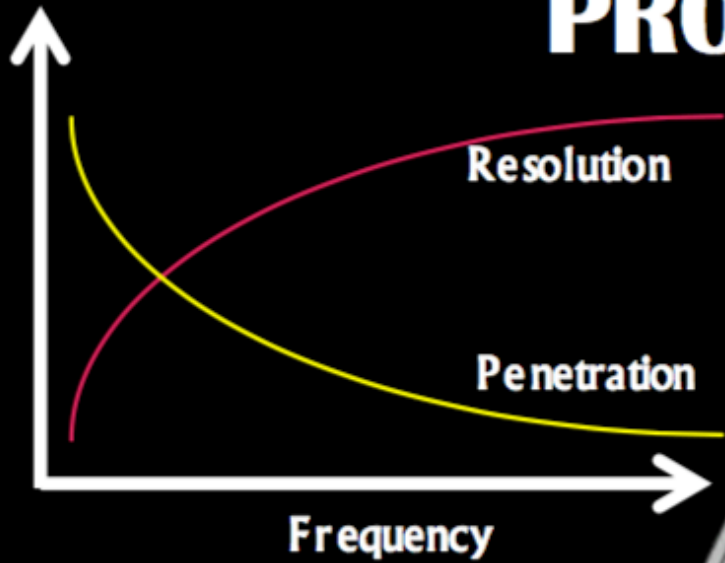
Phased Array
(low frequency)
"Cardiac"



Curvilinear
(low frequency)
"Abdominal"



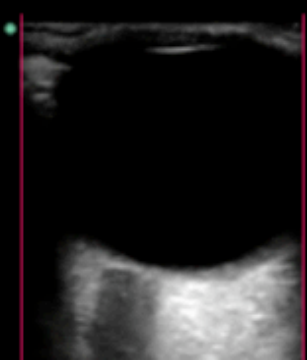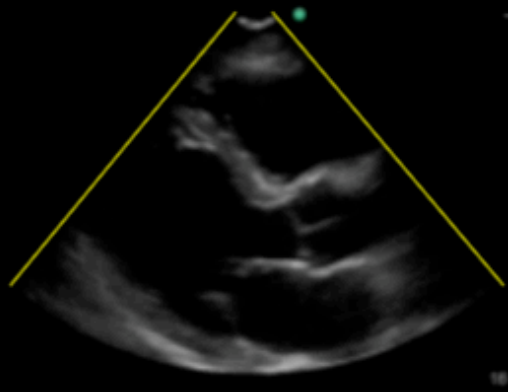
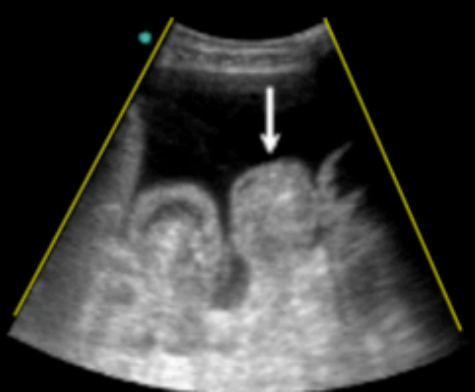
PROBOLOGY



Curvilinear Phased Array Linear

Deep
↓ Frequency
↓ Resolution
↑ Penetration

Superficial
↑ Frequency
↑ Resolution
↓ Penetration

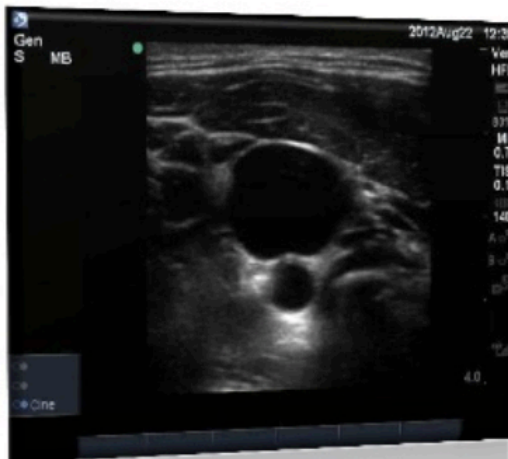

Indicator!

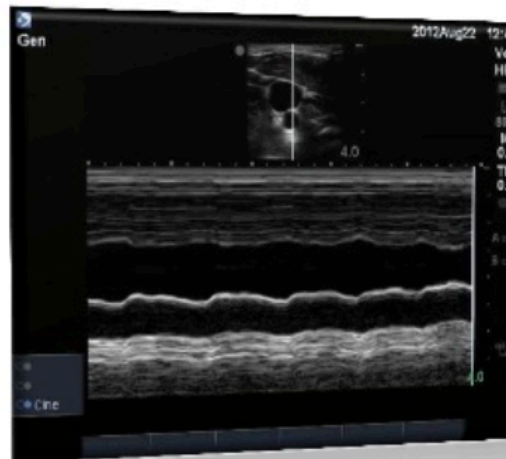

UNDERSTANDING THE IMAGE

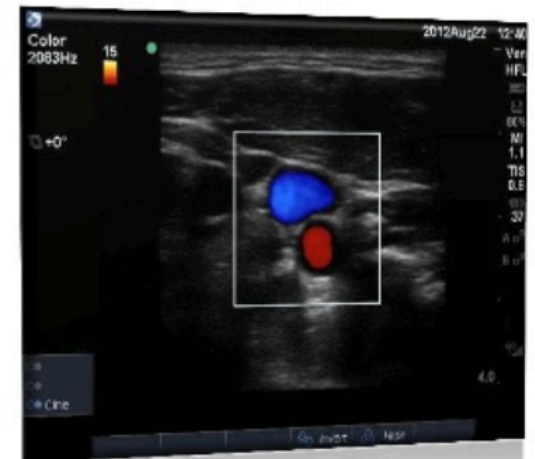There are a variety of scanning modes used in point of care ultrasound. Here we will discuss **B-** or **brightness mode**, **M-** **mode** or **motion mode** and **D-** or **doppler mode**.



B-MODE



M-MODE



DOPPLER

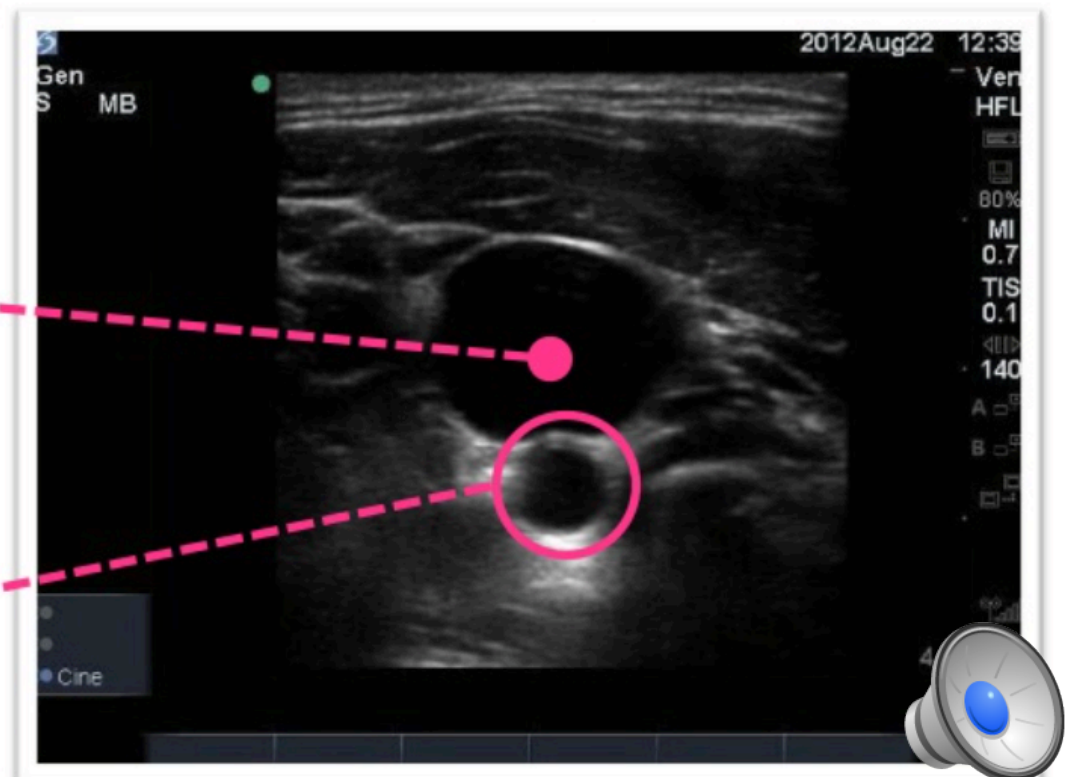


UNDERSTANDING THE IMAGE

B-mode (also called **2D mode**) converts echo waveforms into a **256 shade** grayscale image. The shade of gray depends on the amplitude of the returning echo.

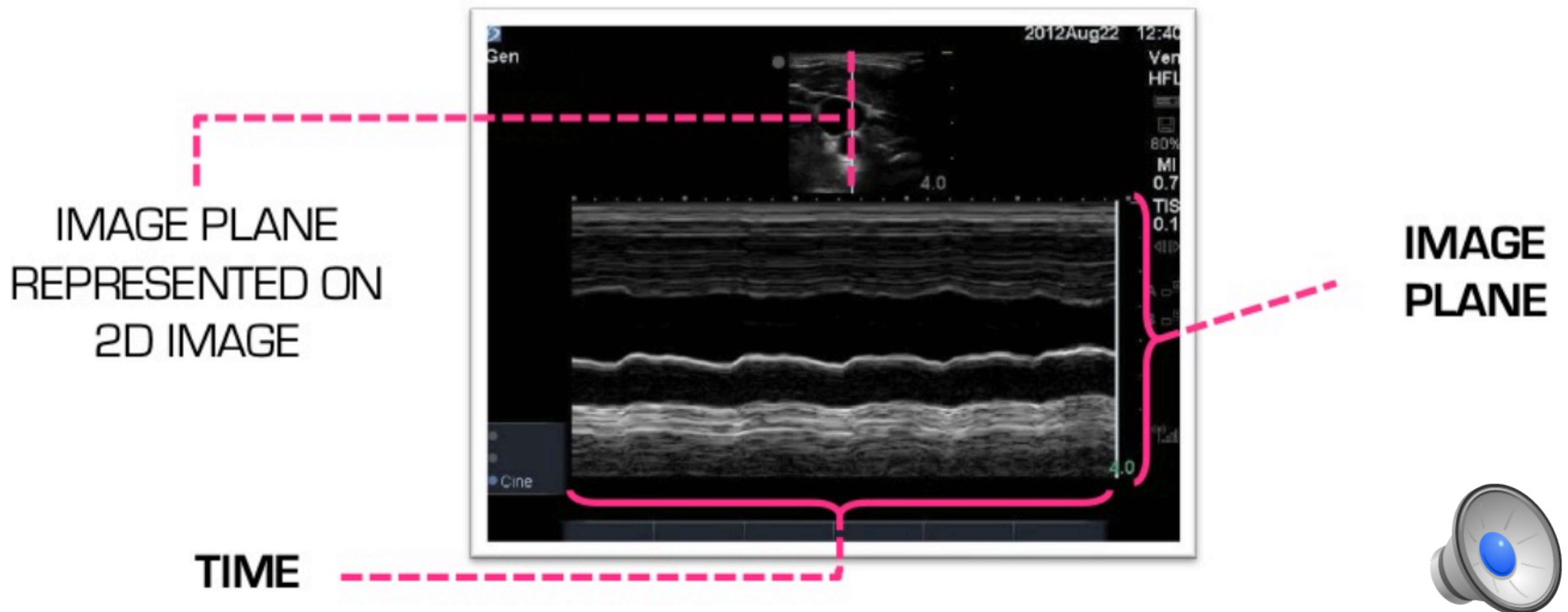
INTERNAL
JUGULAR VEIN

CAROTID
ARTERY



UNDERSTANDING THE IMAGE

M-mode plots the motion of a structure of interest. The probe's **image plane** is plotted on a vertical axis and **time** is plotted on a horizontal axis.



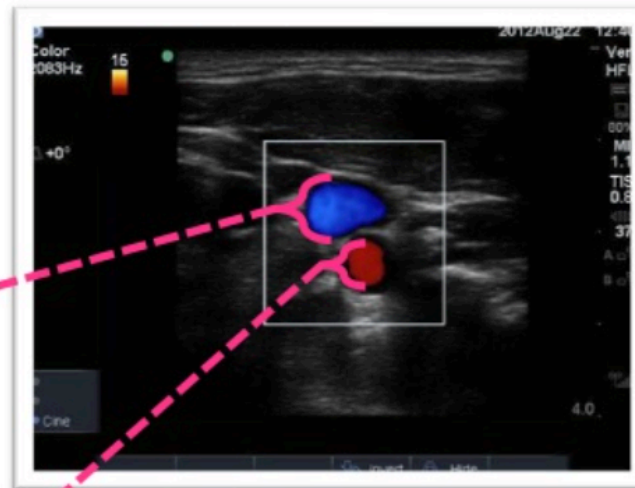
UNDERSTANDING THE IMAGE

Doppler mode can determine movement of reflected ultrasound waves toward or away from the probe. This can be represented by colour changes or graphical peaks.

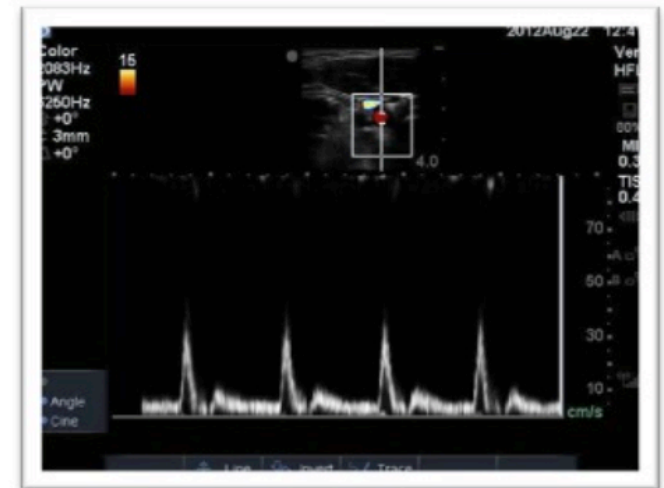
Doppler flow- “BART” -Blue Away, Red Towards

BLUE REPRESENTS
MOTION **AWAY** FROM
TRANSDUCER

RED REPRESENTS
MOTION **TOWARDS**
TRANSDUCER



COLOUR DOPPLER



SPECTRAL DOPPLER



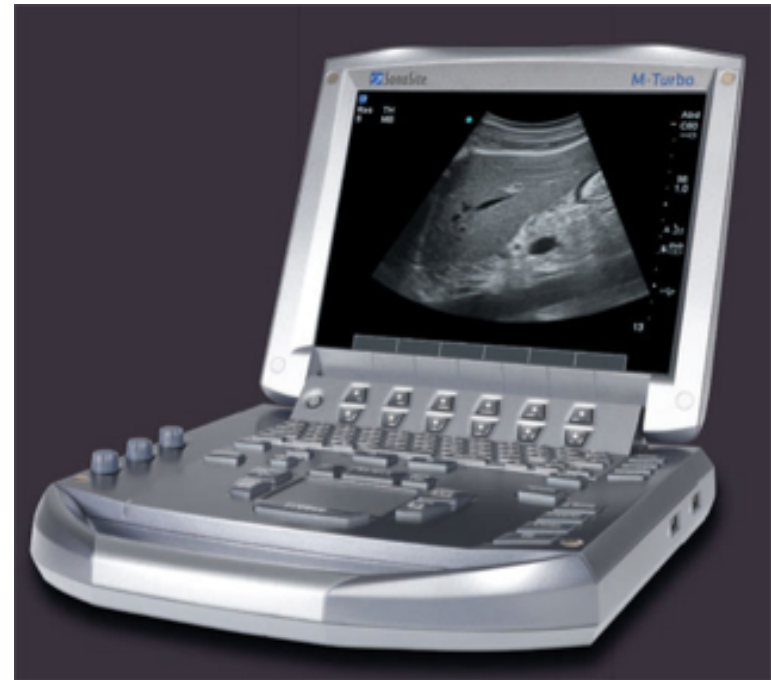Advantages of POCUS

- Repeatable as clinical status changes
- Portable
- Non-invasive
- Non-ionizing radiation
- Low cost
- Easy to learn



Disadvantages of POCUS

- ❑ Air/Gas
- ❑ Body Habitus
- ❑ Experience / operator dependent
 - ❑ This is **NOT** a formal echo or ultrasound evaluation



Indications for POCUS

- ❑ Hypotension
- ❑ Respiratory Distress
- ❑ Assessment of fluid status

- ❑ No impact on mortality!



Uses for Ultrasound

- Foreign body
- Cardiac standstill
- Appendicitis
- Fractures
- Retinal Detach
- DVT

- Pneumothorax
- CHF
- Optic nerve
- Vascular access
- Paracentesis
- Pyloric stenosis

There are many!!

- Hemothorax
- Abscess
- Urinary retention
- Ovarian cyst
- Tendon rupture
- AAA
- Arthrocentesis
- Ectopics

- Hydronephrosis
- Baker's Cyst
- IUP
- Bowel Obstruction
- Hernia
- Ascites
- Cellulitis
- Joint effusion
- Thyroid



Our Focus

- ▣ **Cardiac Ultrasound**
 - ▣ IVC/Fluid Assessment
- ▣ **FAST (Focused Assessment Sonography in Trauma)**
- ▣ **Lung**
- ▣ **Vascular**



Sonographic Assessment of Medical Emergencies

1. Use a structured approach
2. Perform quickly at the bedside
3. Limited and focused exam

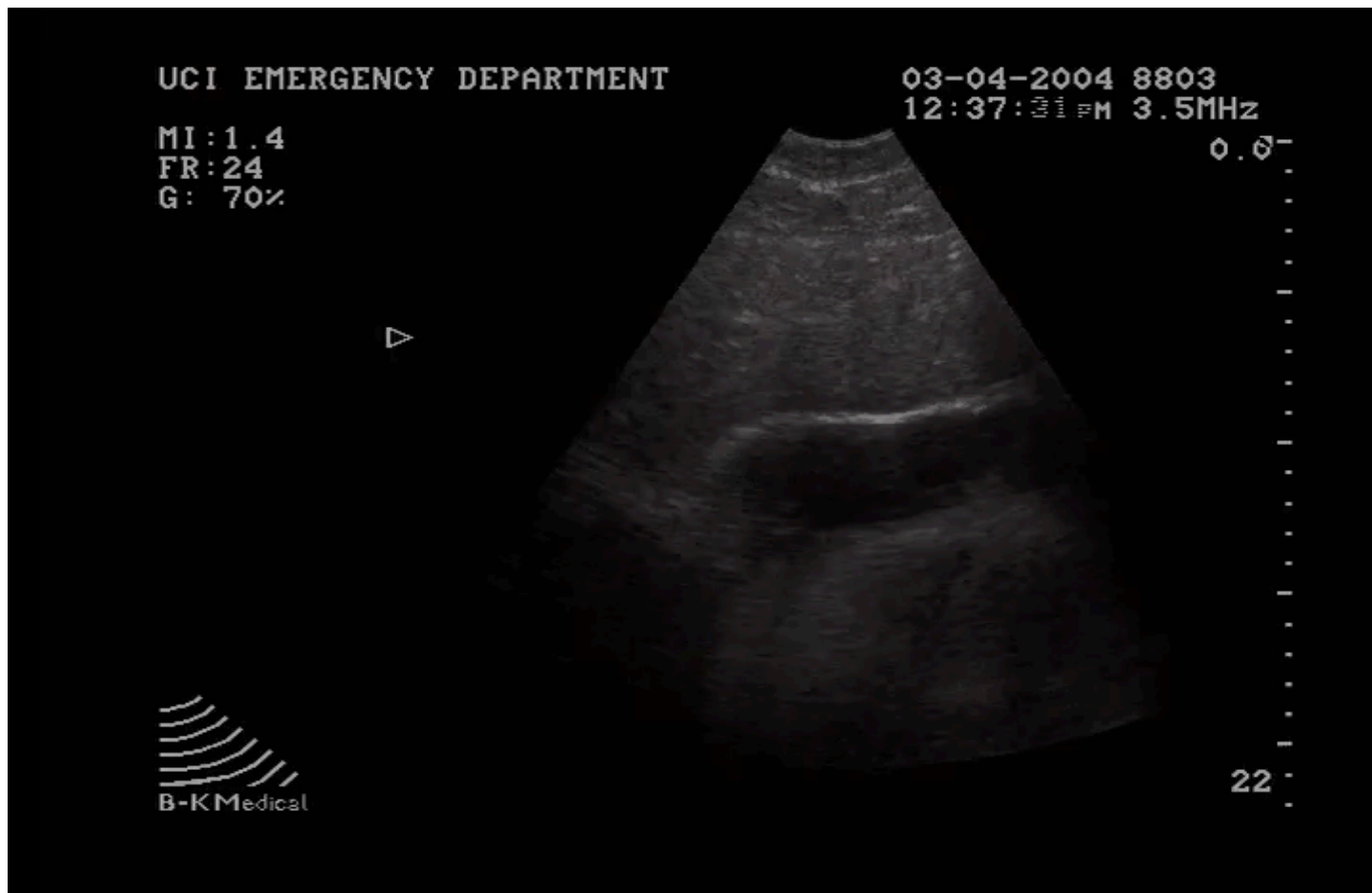


Case #1

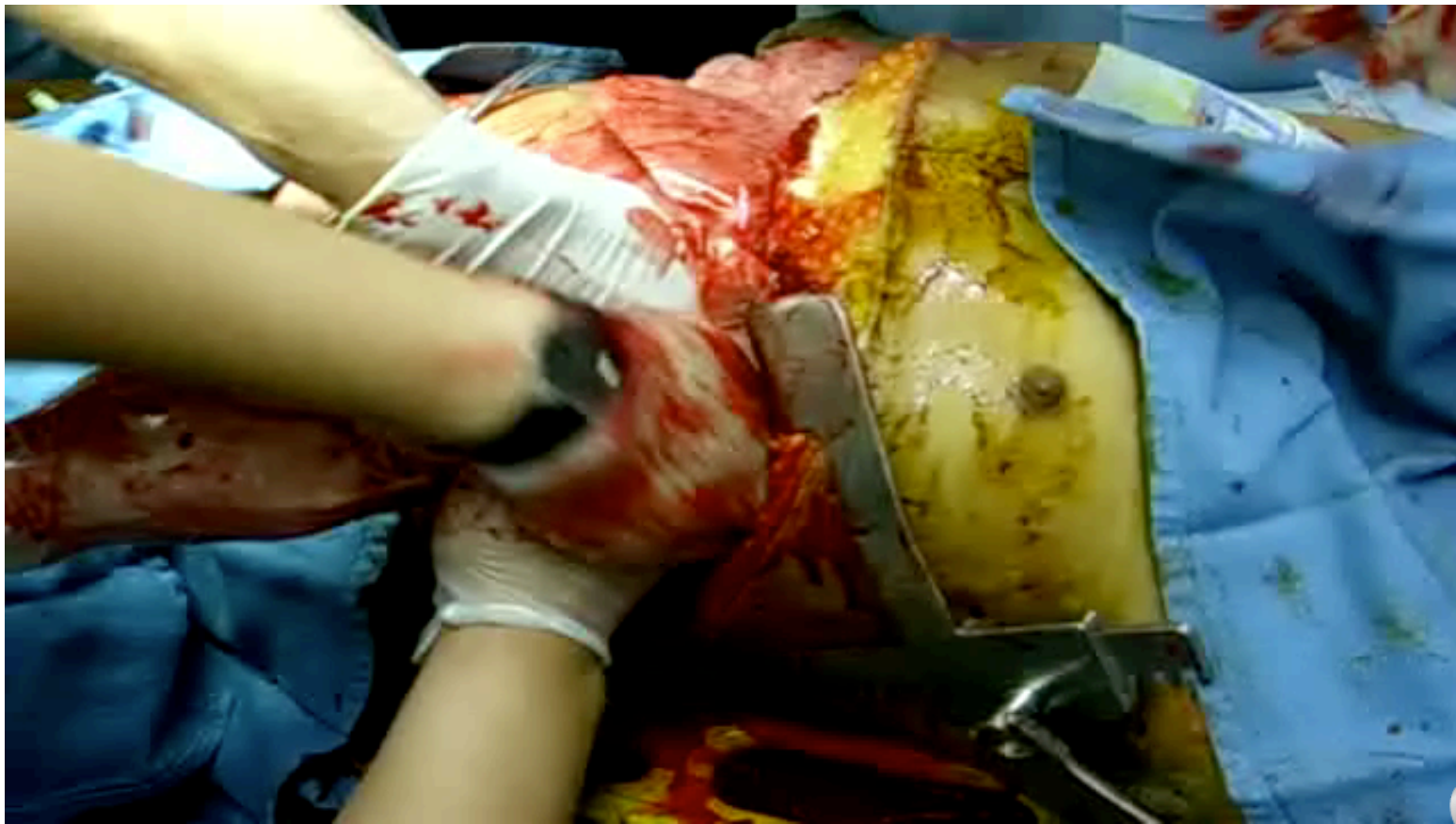
- ❑ 38 yo male was involved in a car accident.
- ❑ No seatbelt.
- ❑ Had a pulse in the ambulance, now has no pulse.

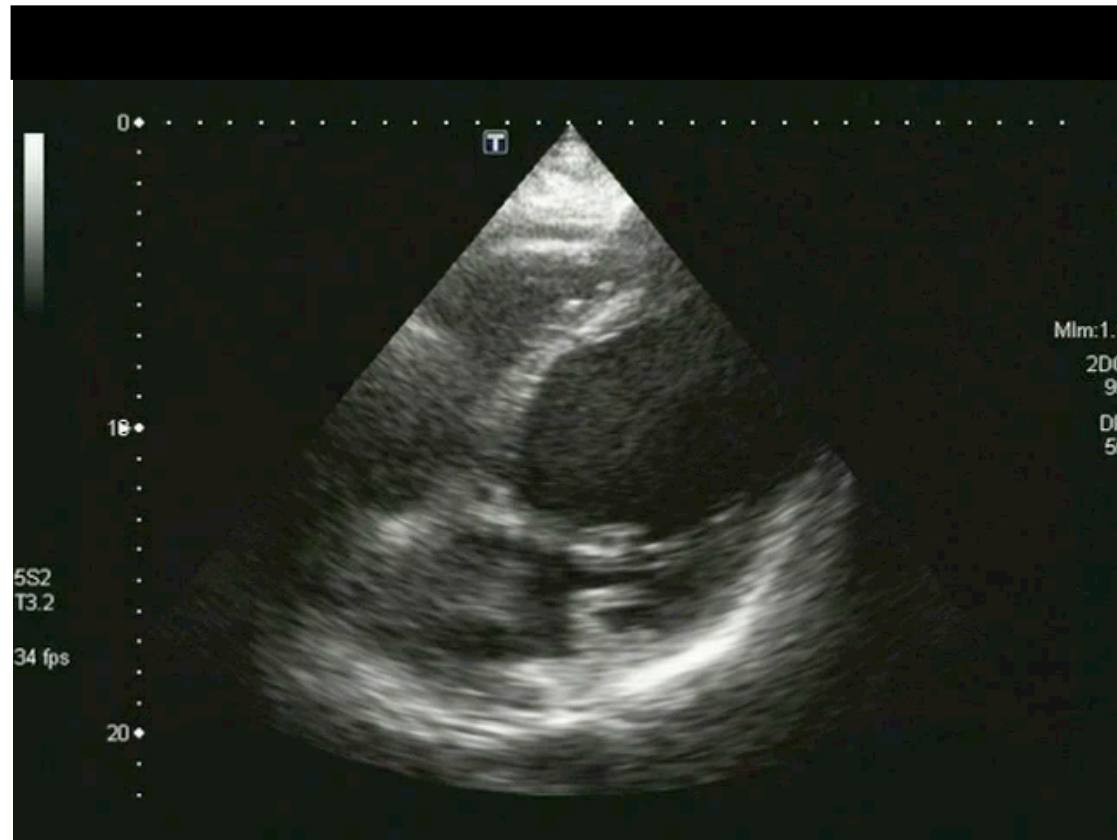


Case #1



Case #1





Cardiac Ultrasound



Goals of Cardiac Ultrasound

- ▣ **Is the heart strong or weak?**
 - ▣ LV and RV size/systolic function
- ▣ **Is there fluid around the heart?**
 - ▣ Pericardial effusion/cardiac tamponade
- ▣ **What is the fluid status of the patient?**

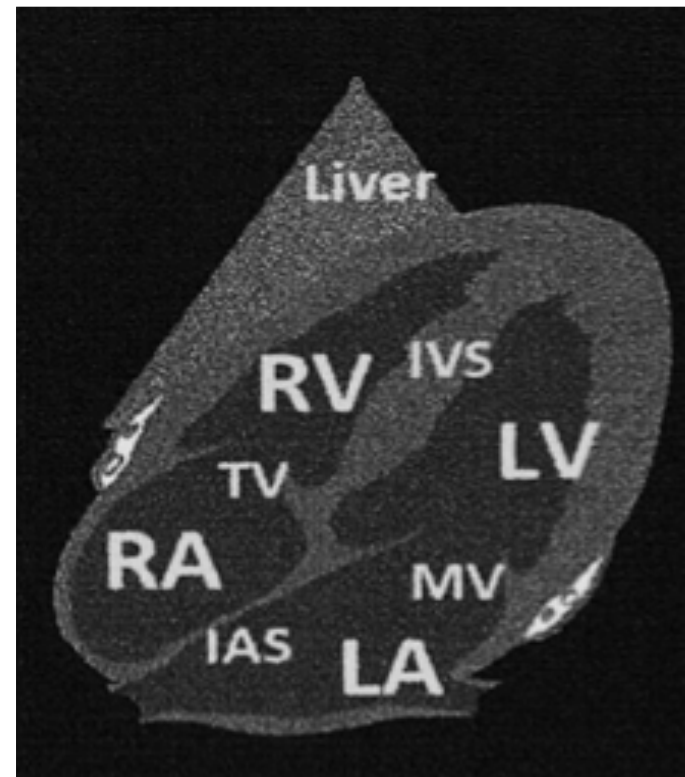
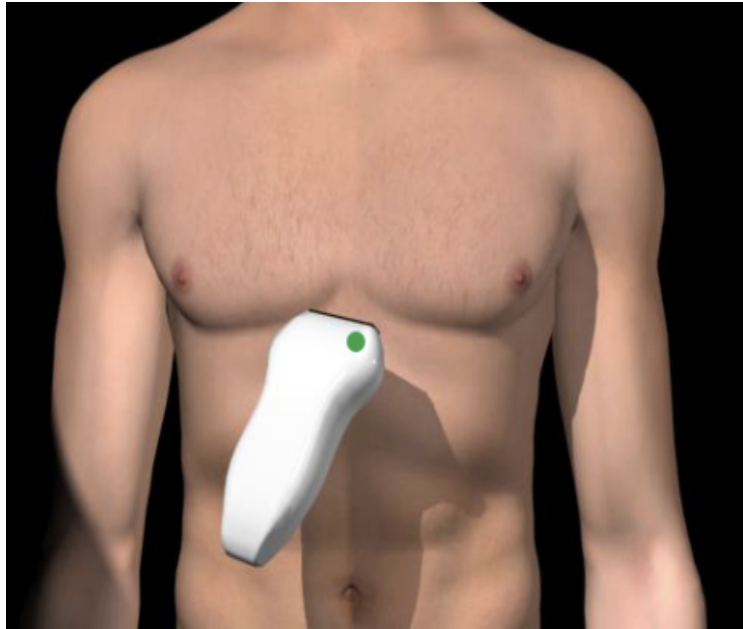


Four Views of the Heart

- ▣ Subxiphoid/subcostal
- ▣ Parasternal Long
- ▣ Parasternal Short
- ▣ Apical (Four Chamber)



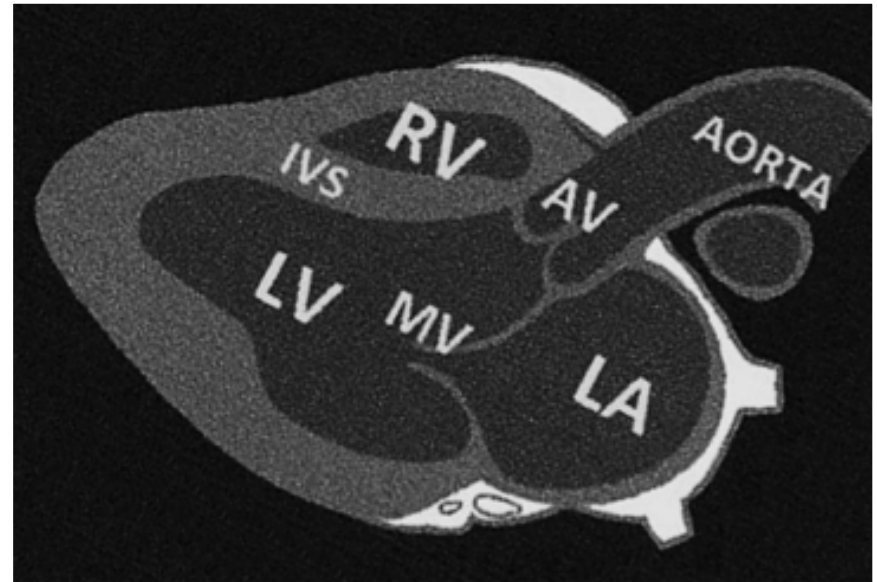
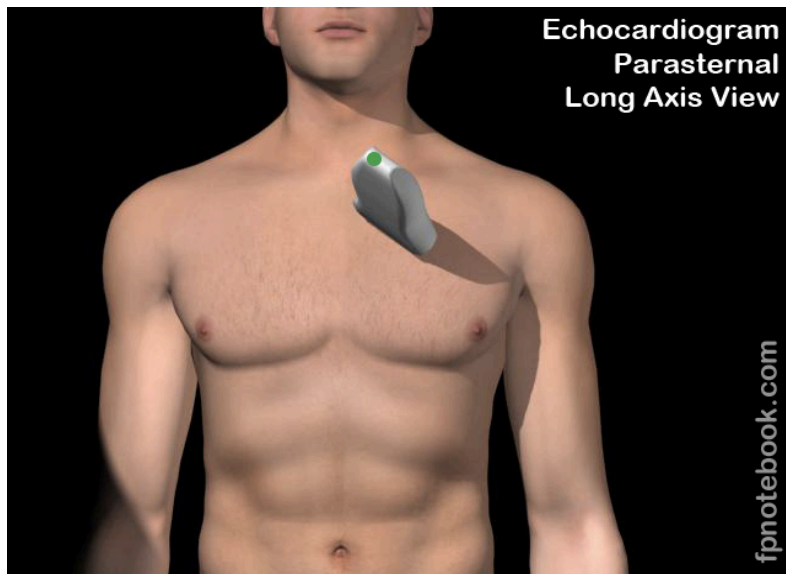
Subxiphoid View

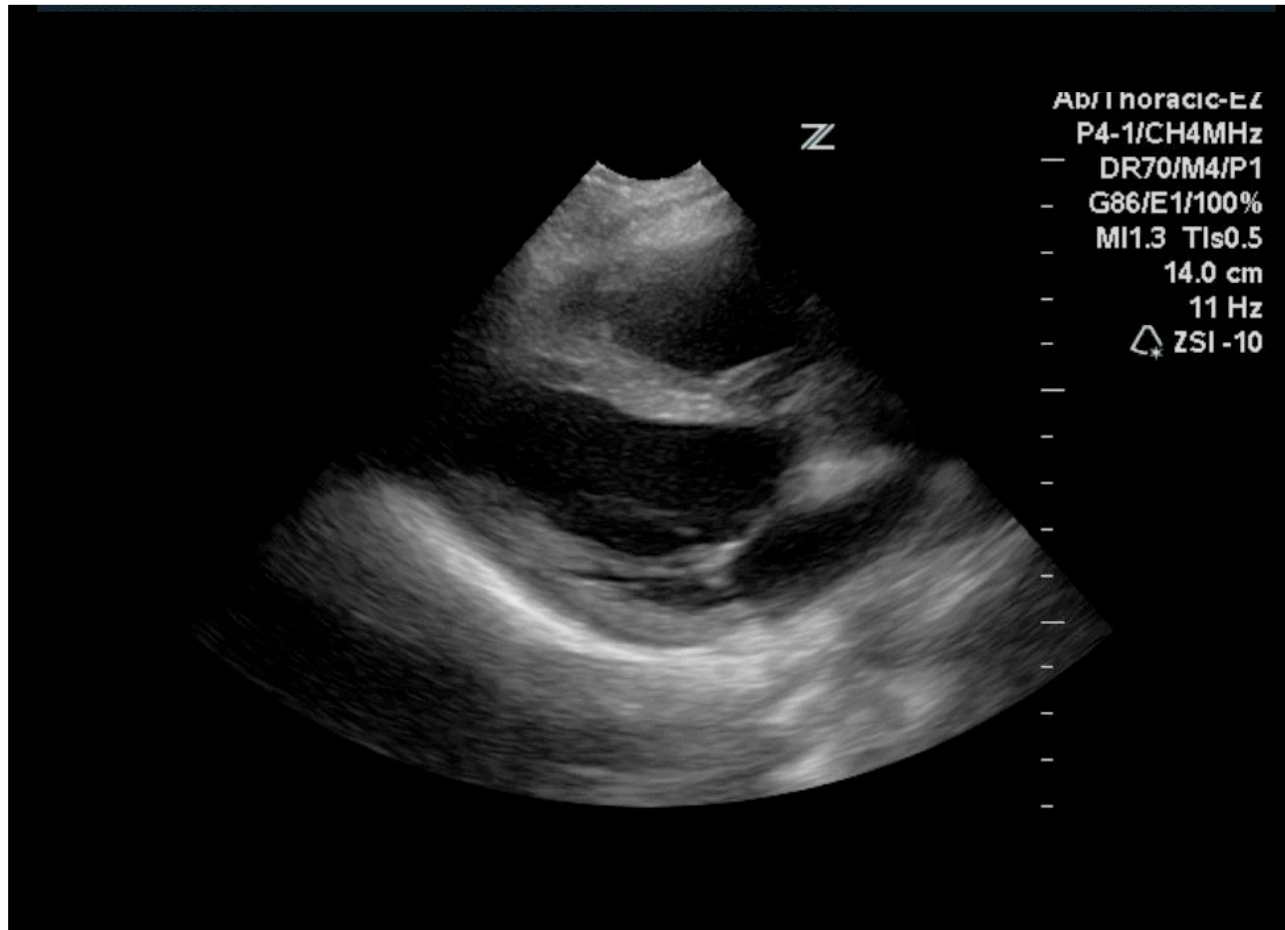

Subxiphoid View



Parasternal Long View

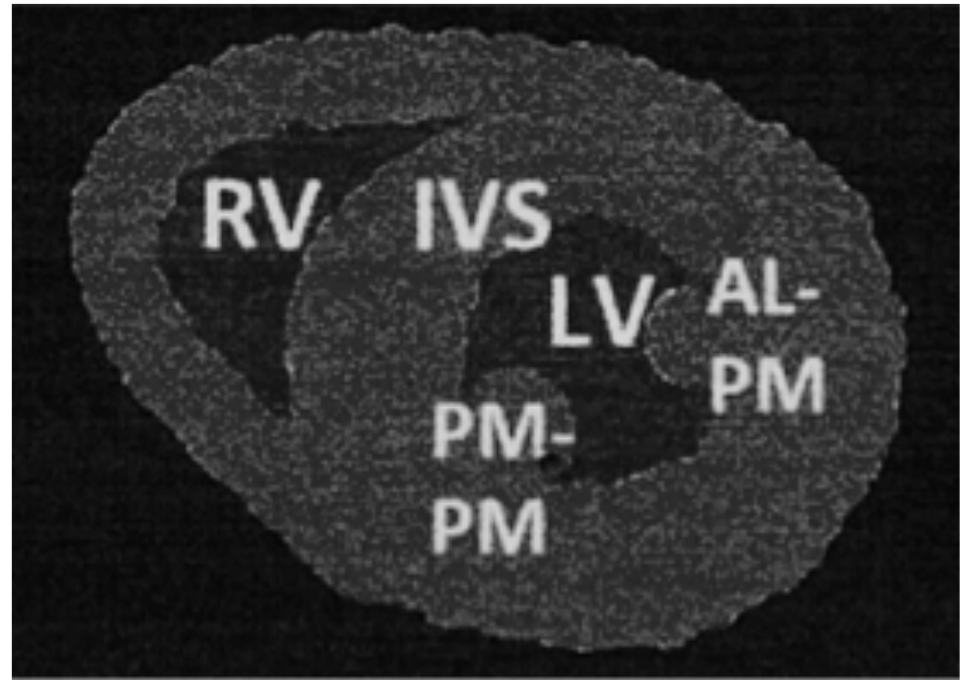
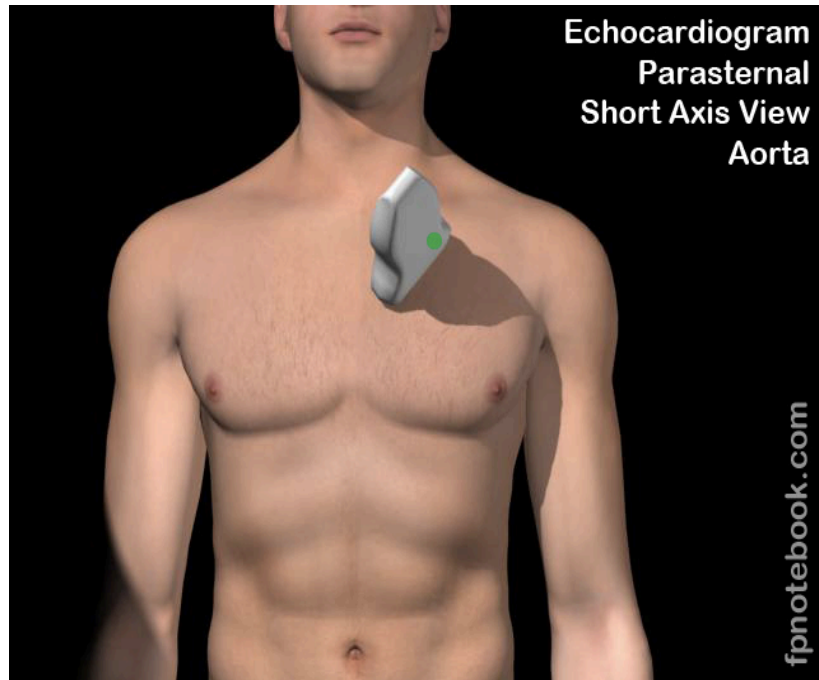


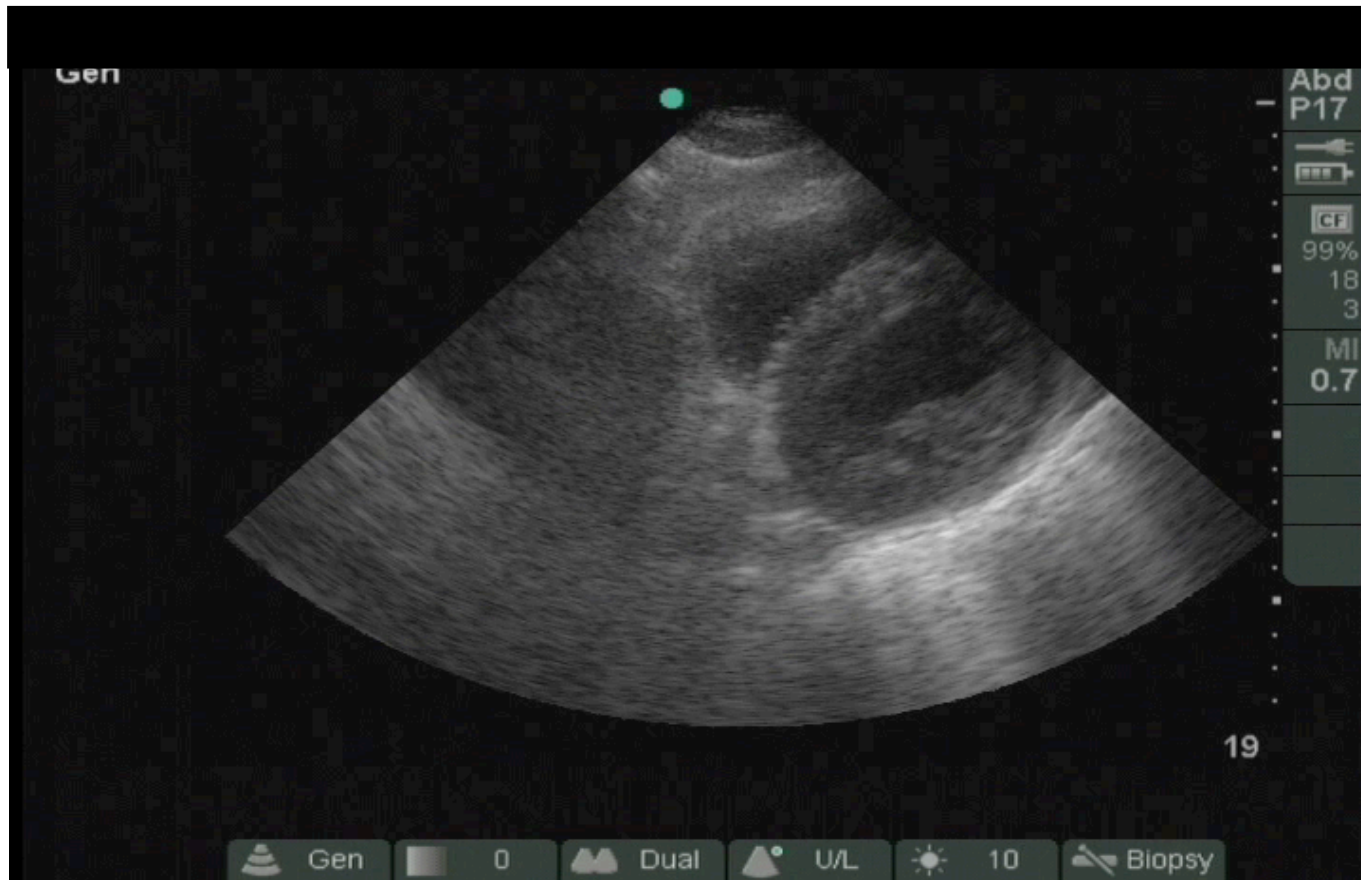


Parasternal Long View



Parasternal Short View

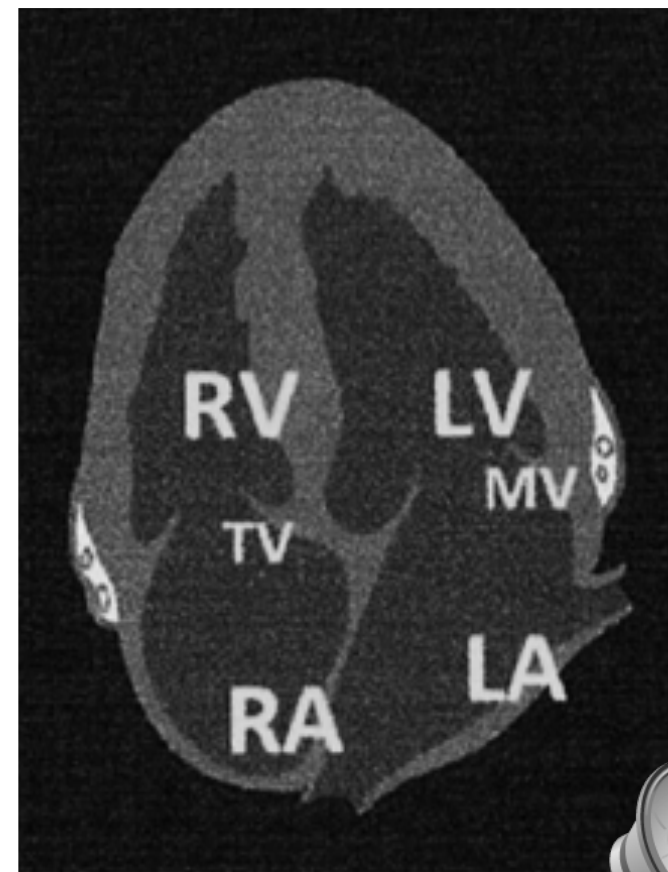
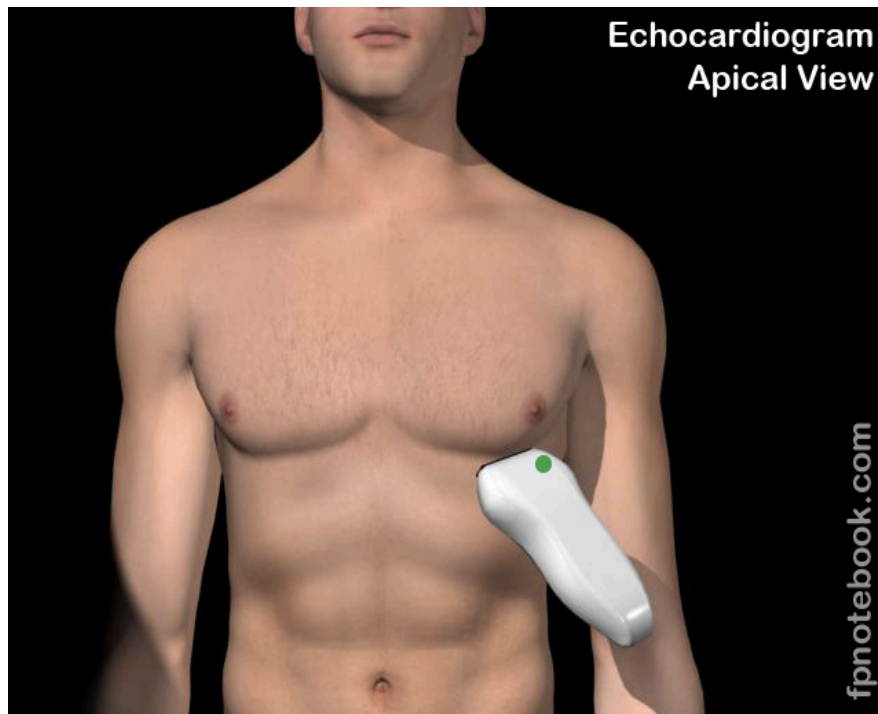


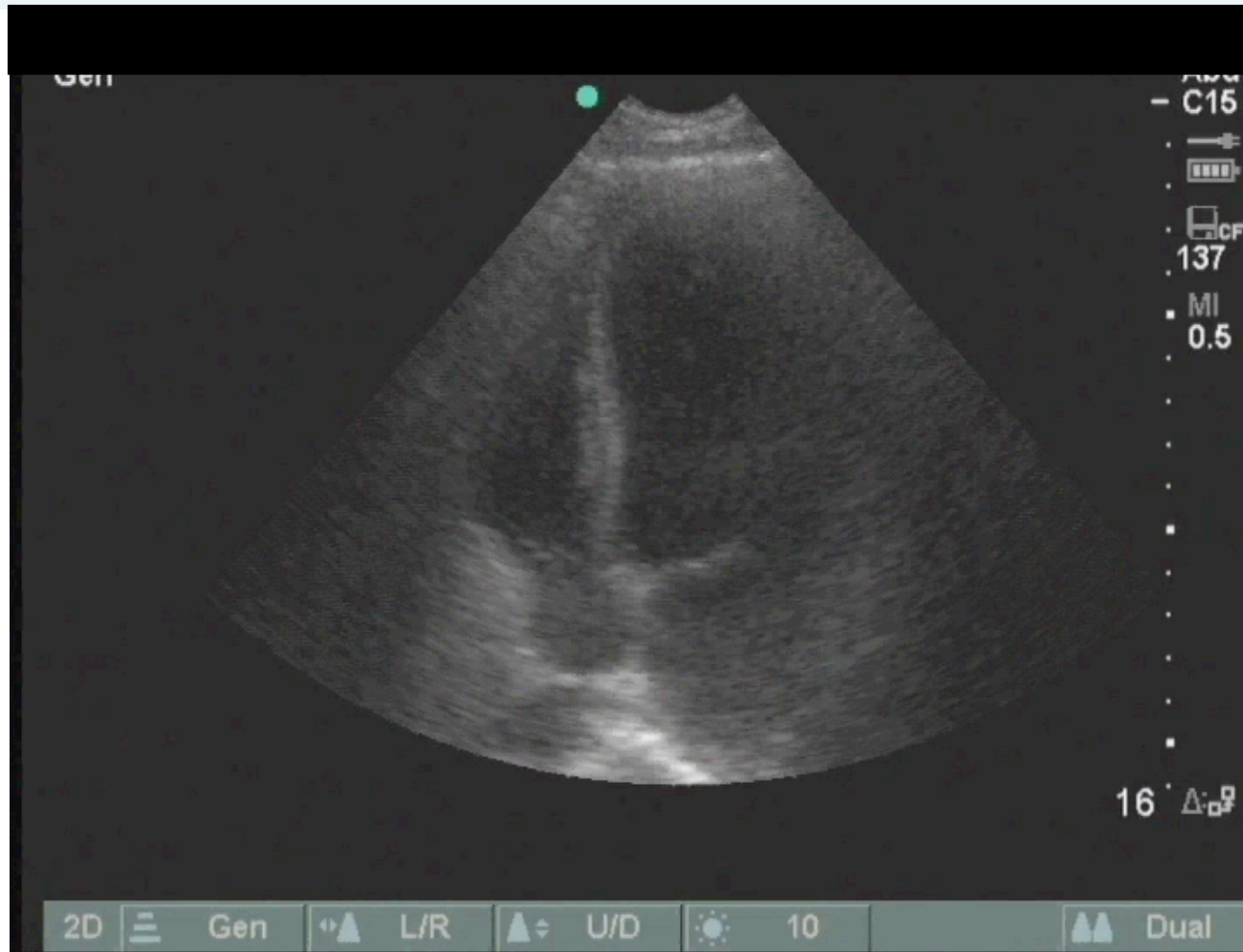


Parasternal Short View



Apical (Four Chamber) View



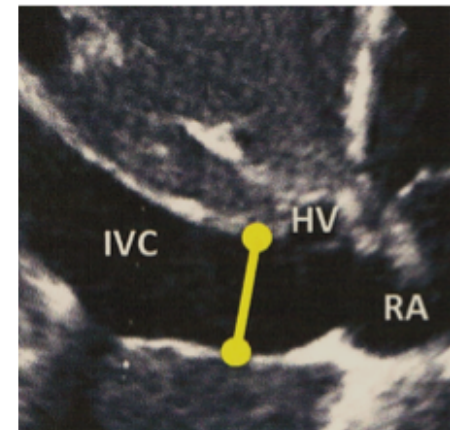


Apical (Four Chamber) View

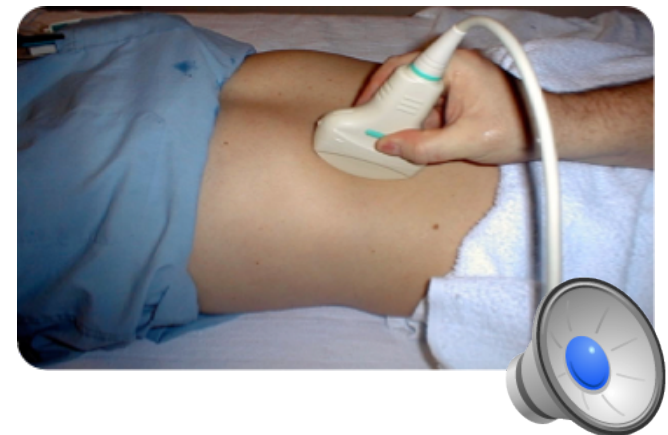


Evaluation of the IVC

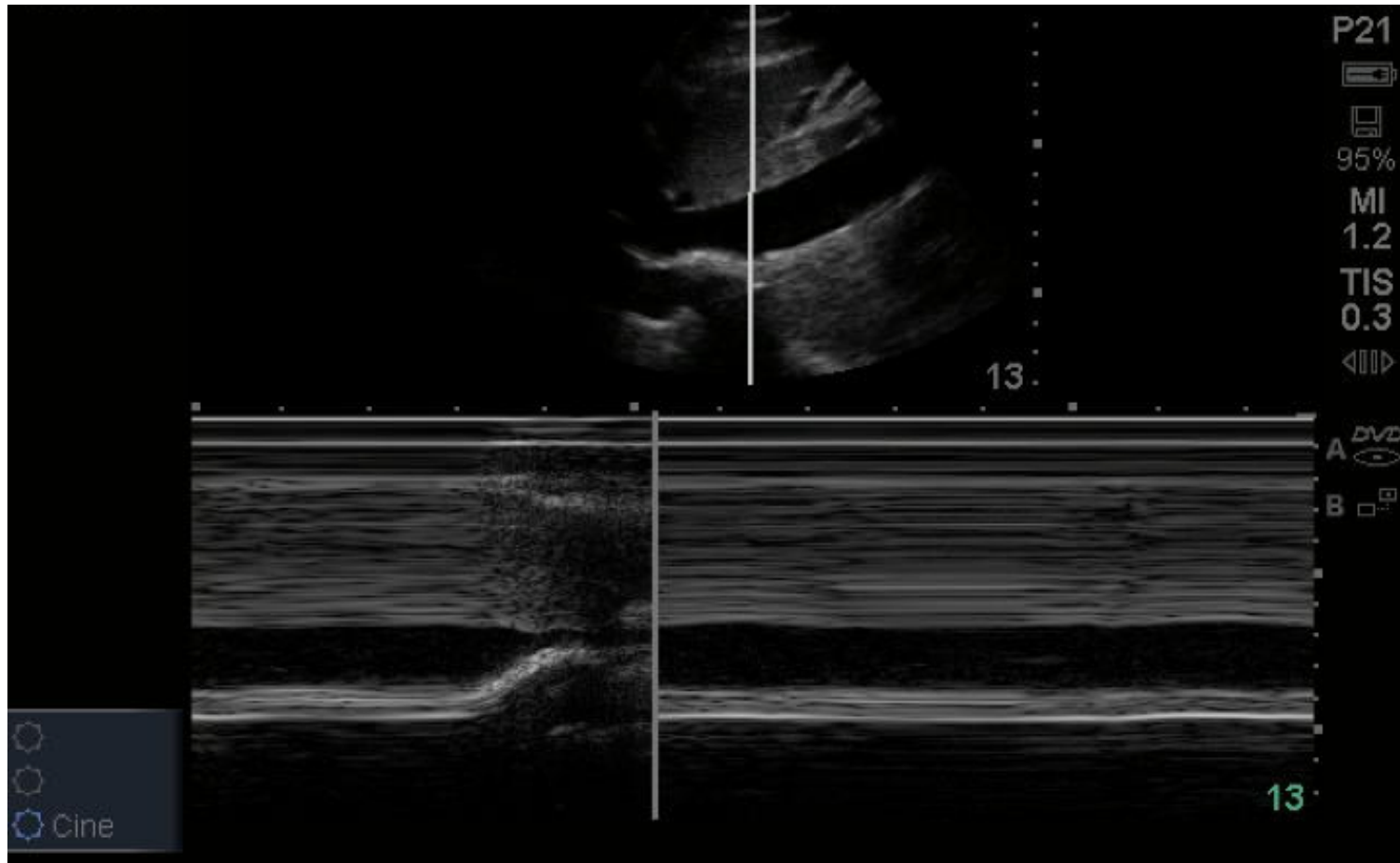
Static Parameter for
estimating $P_{RA} \approx CVP \approx$
fluid status of patient



IVC Diameter (cm)	Collapse	RA Pressure (mmHg)	CVP	Fluid Status
<2	>50%	<10	0-10	"Dry"
>2	<50%	>10	10-20	"Full"



The “M Mode” can be used to measure IVC as well

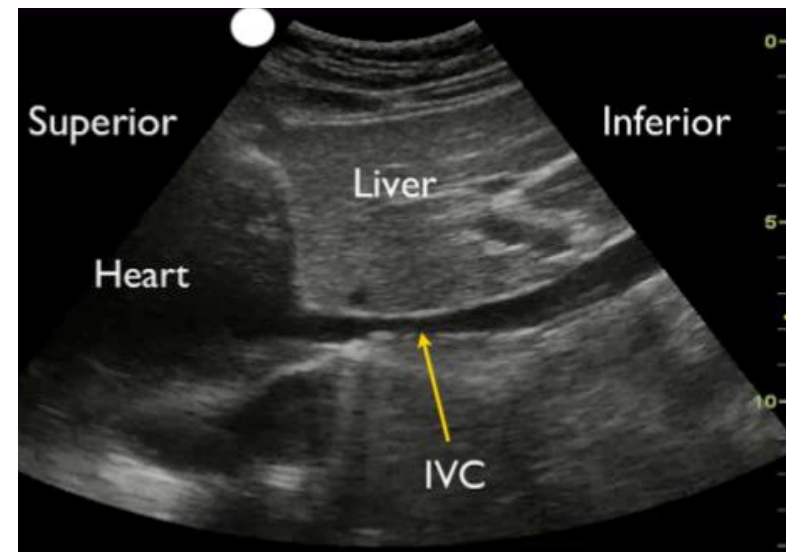
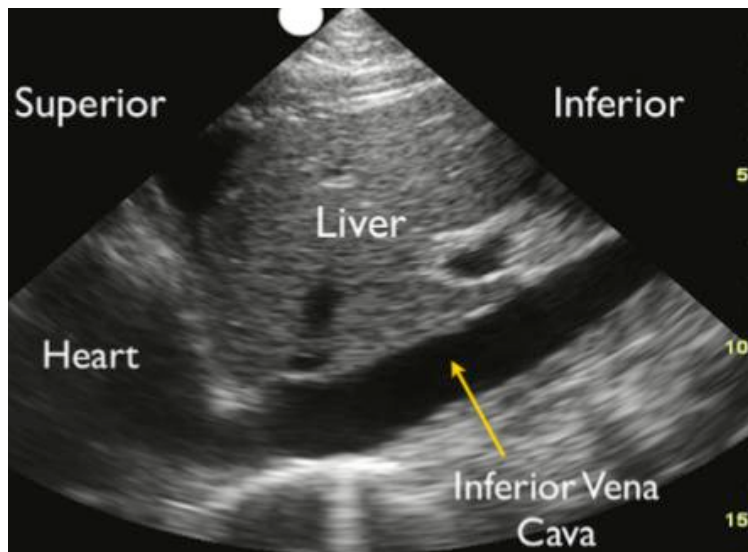


Anything that increases the RA pressure can dilate the IVC →
LV failure, RV failure, Pulmonary HTN, TR, Hypervolemia



Evaluation of the IVC

Sensitivity: 63% Specificity: 73%



“A small IVC is moderately predictive of fluid responsiveness, however a dilated IVC cannot rule out fluid responsiveness.”

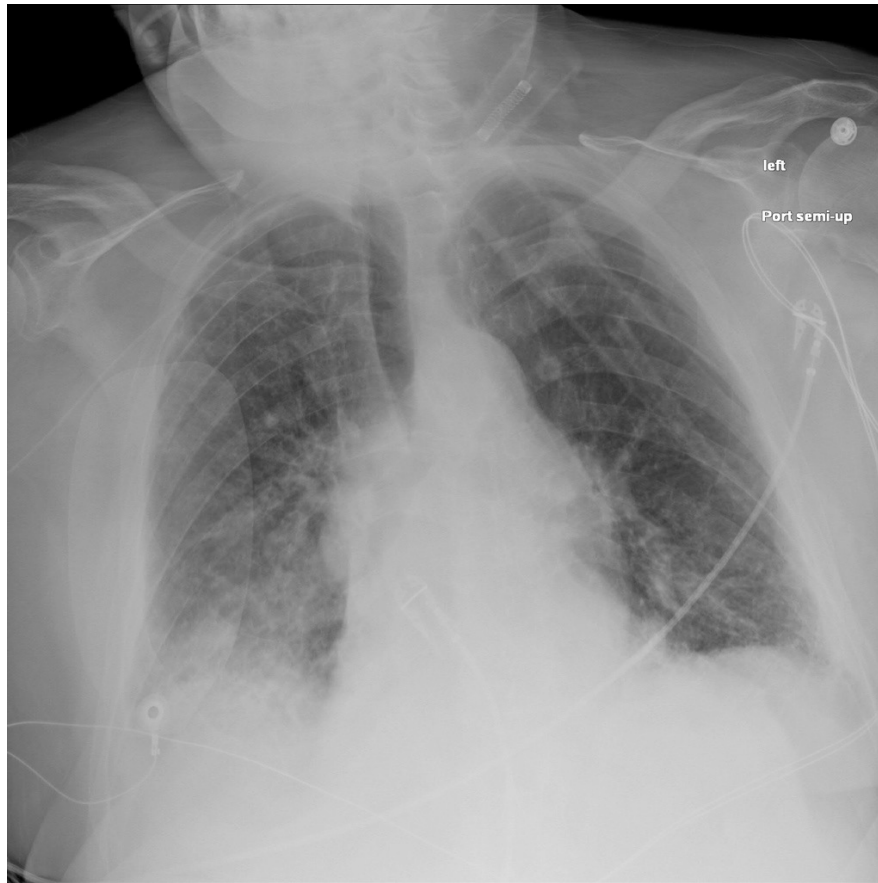

Case #2

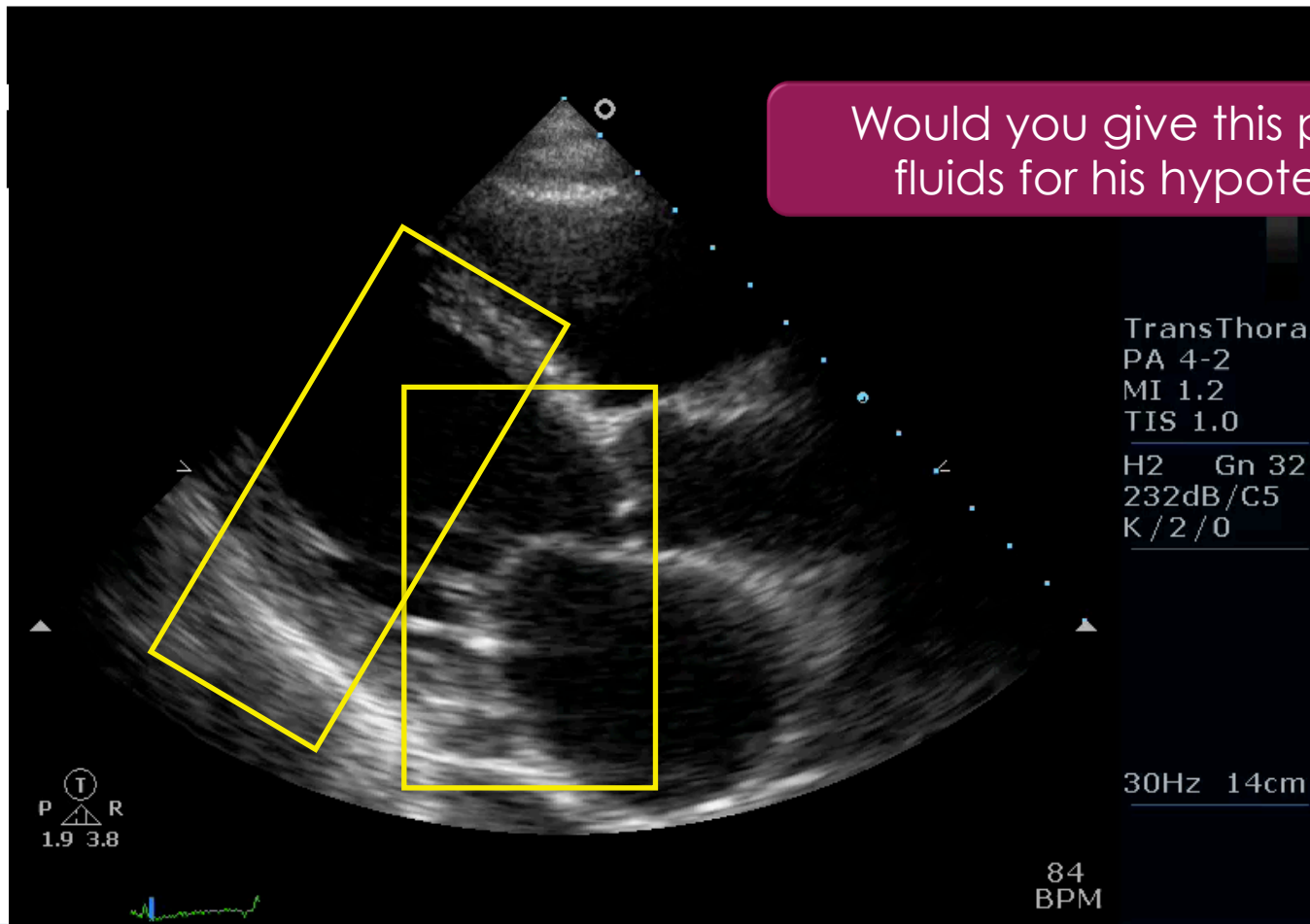
- 82 year old male presents to the ED with weakness
- BP: 84/70 HR: 104 RR: 24 Temp: 36.2 °C
- O2 sats 78% on RA, 91% on High Flow Oxygen.



Case #2



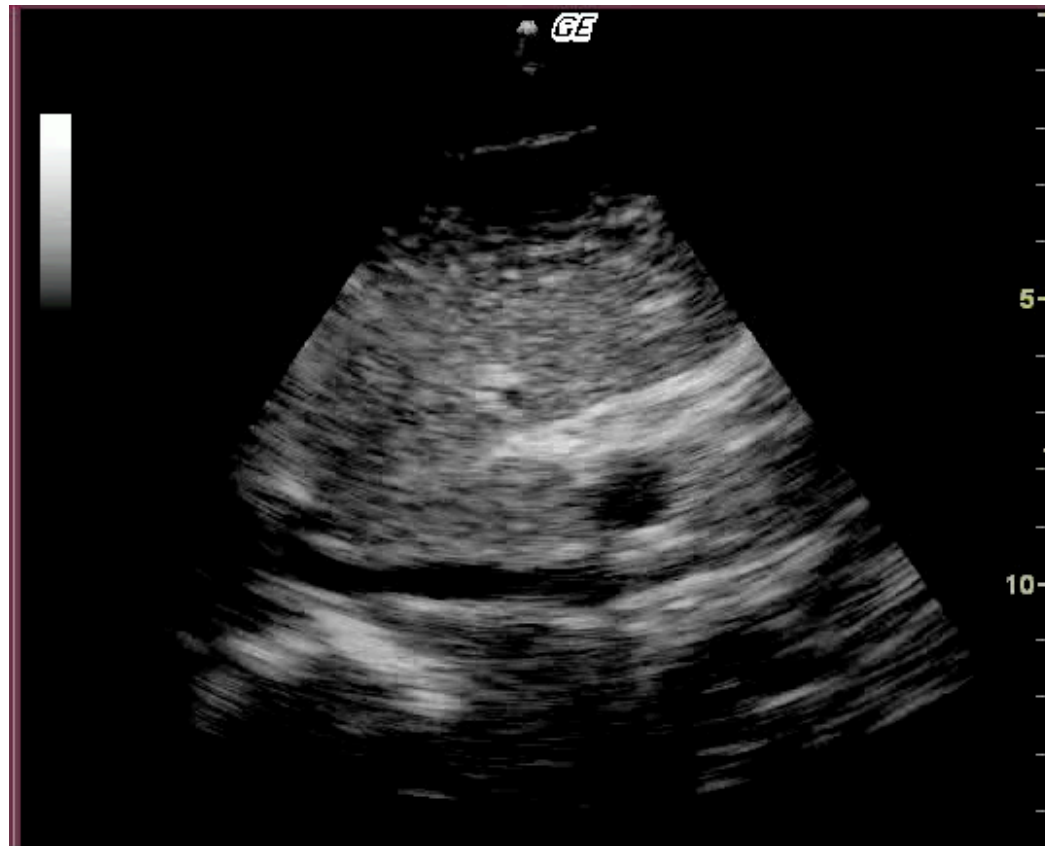
Case #2



Would you give this patient IV fluids for his hypotension??



Case #2



Patient's BP: 86/68



Case #2

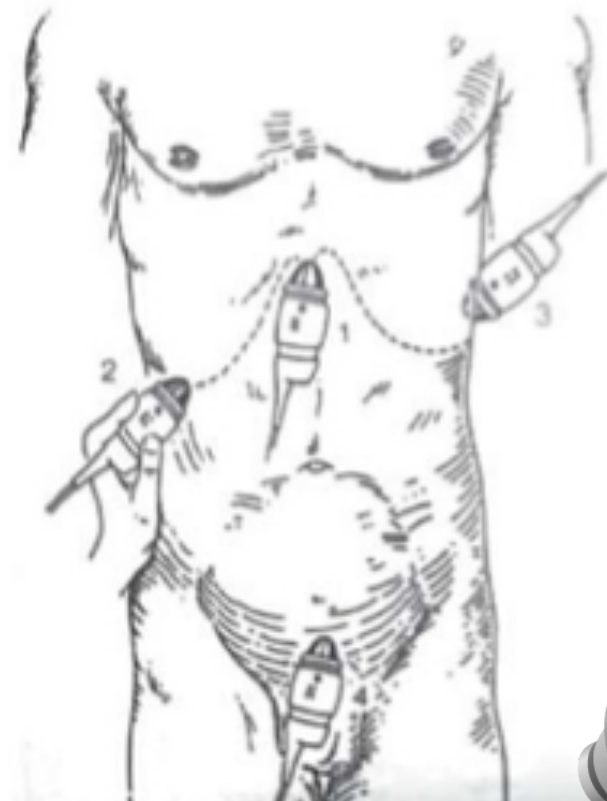- After the ultrasound, patient was given a fluid bolus.
- After 500cc of fluid:
 - BP: 100/70 HR: 98 RR:20 Temp: 38.2°C
 - Pneumonia treatment was initiated.



Focused Assessment Sonography in Trauma (FAST)

- Quick and can be repeated
- Look for free intraperitoneal fluid

A negative FAST exam does **NOT** rule out throacoabdominal injury, free fluid or a pneumothorax!! It is just used for screening!!

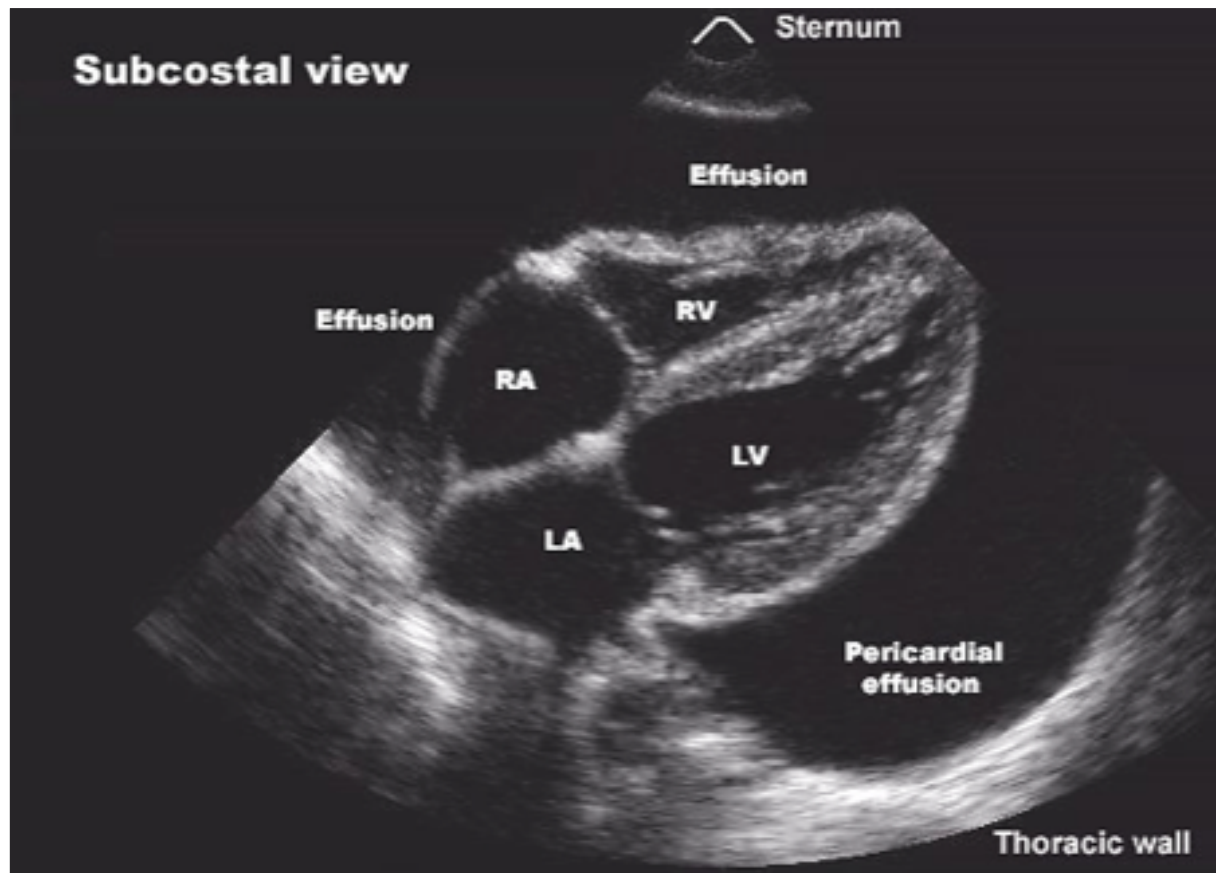


FAST

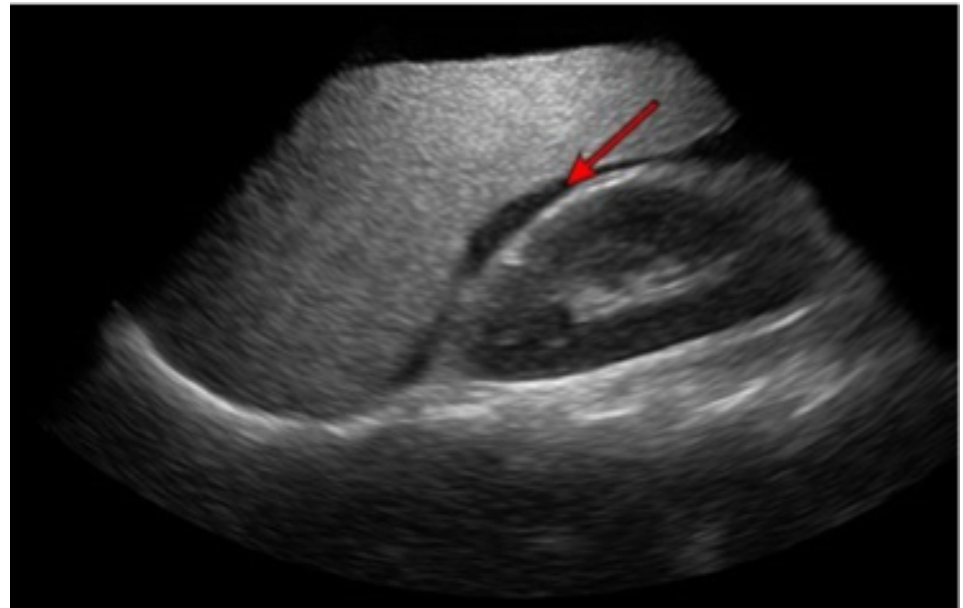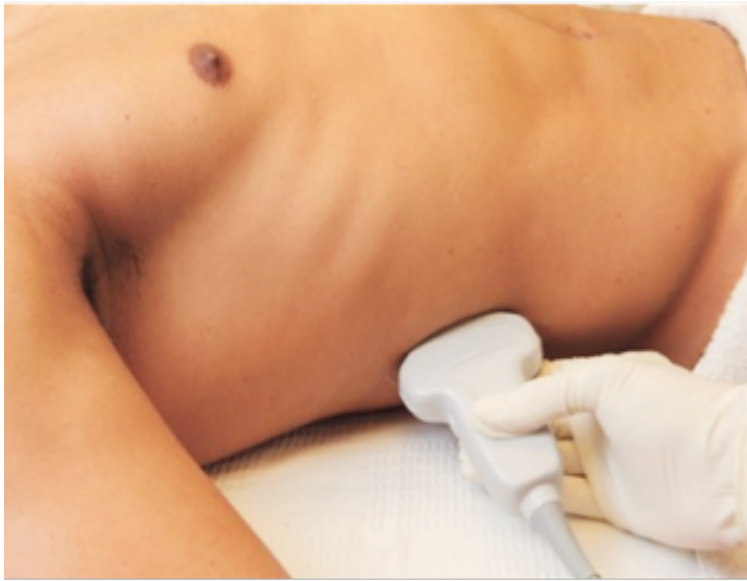- ▣ Image Acquisition
 - ▣ Low frequency probe, usually the curvilinear probe.
 - ▣ Four views:
 - ▣ Pericardial
 - ▣ Hepatorenal
 - ▣ Splenorenal
 - ▣ Rectovesicular



FAST – Pericardial



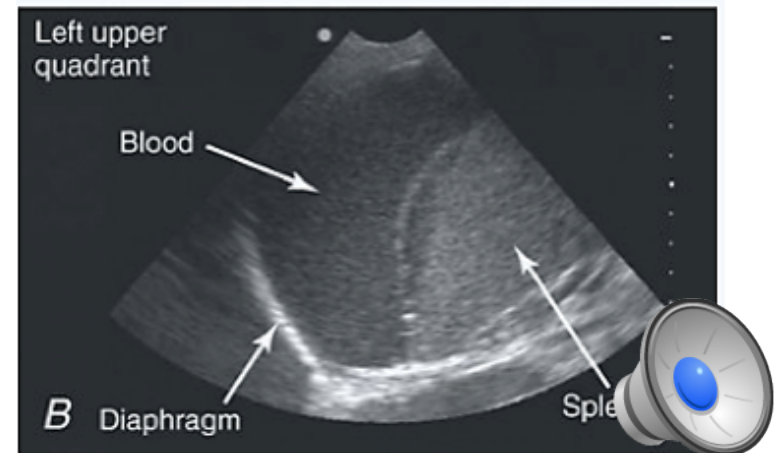
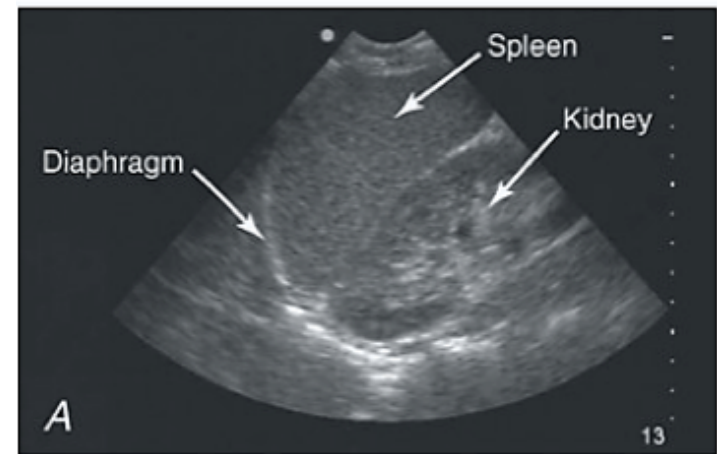
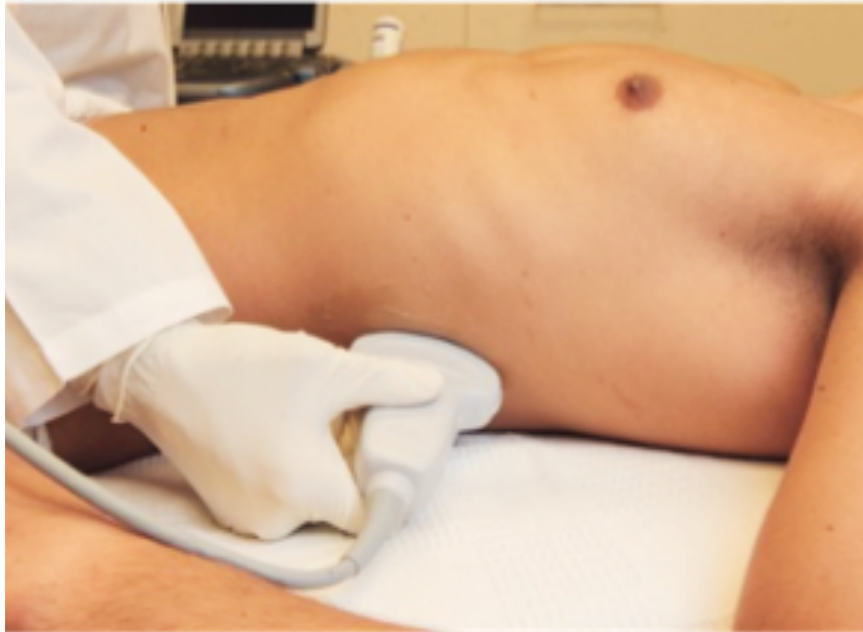FAST – Hepatorenal



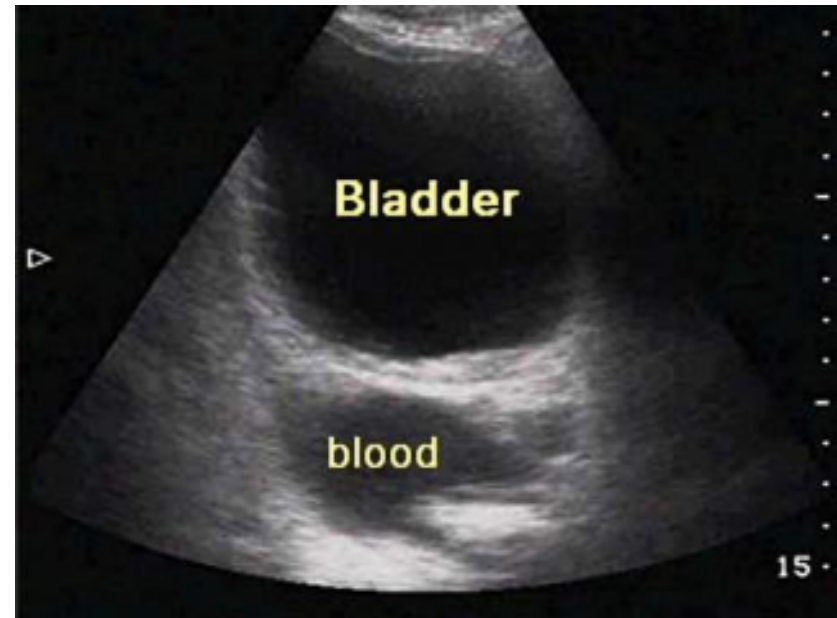
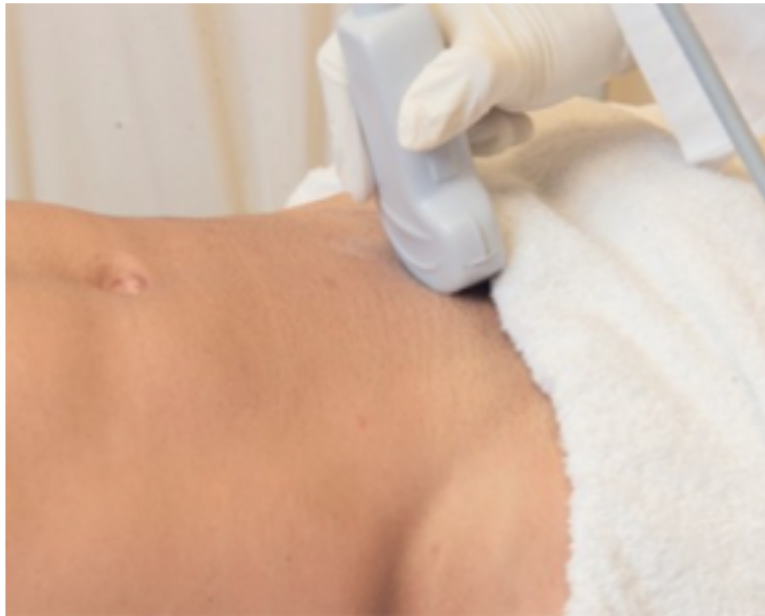Morison's pouch



FAST – Splenorenal



FAST – Rectovesicular



Lung Ultrasound

- Can assess for:
 - Pulmonary edema
 - Consolidation/pneumonia
 - Pleural effusions
 - Pneumothorax

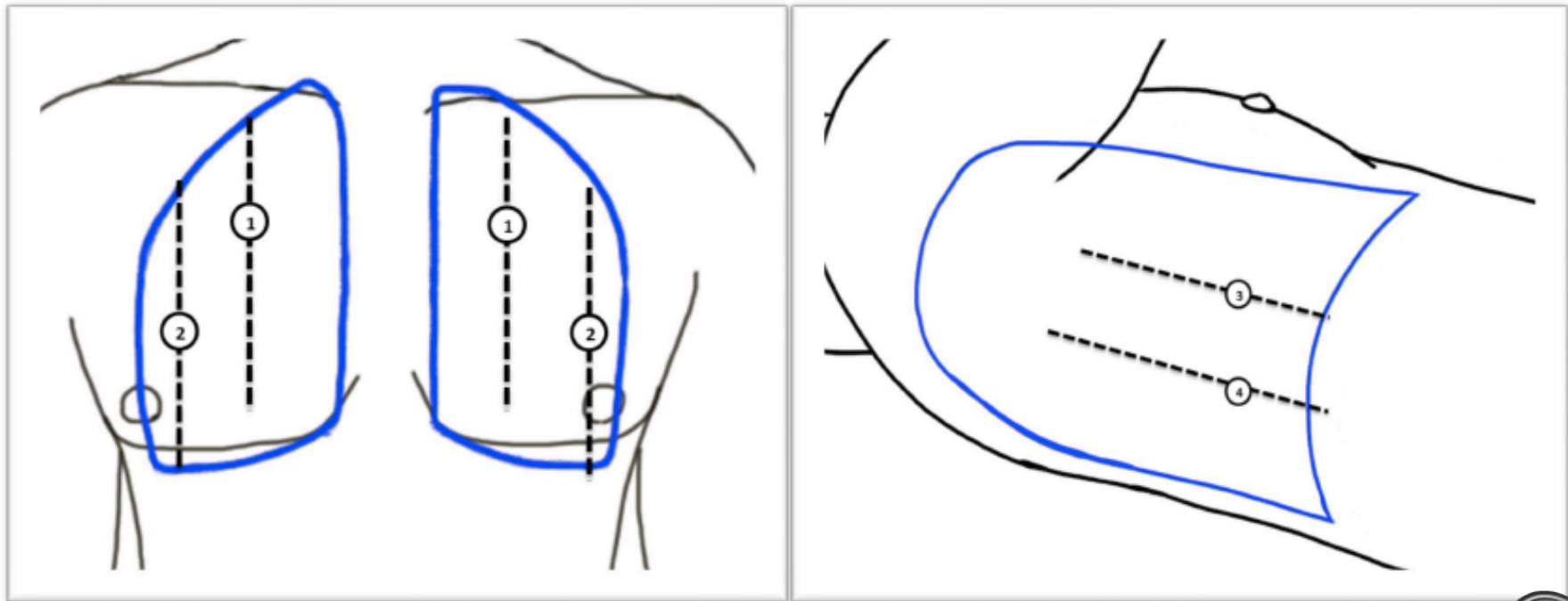
	CXR (sensitivity)	US (sensitivity)
Pulmonary edema	56.9%	85-92%
Pneumonia	38-64%	85-96%
Pneumothorax	39-50%	78-90%

In a study, lung ultrasound provided the correct diagnosis in **90.5% cases of acute respiratory failure.



BLUE Protocol

BLUE (Bedside Lung Ultrasound in Emergency) Protocol Exam Points:

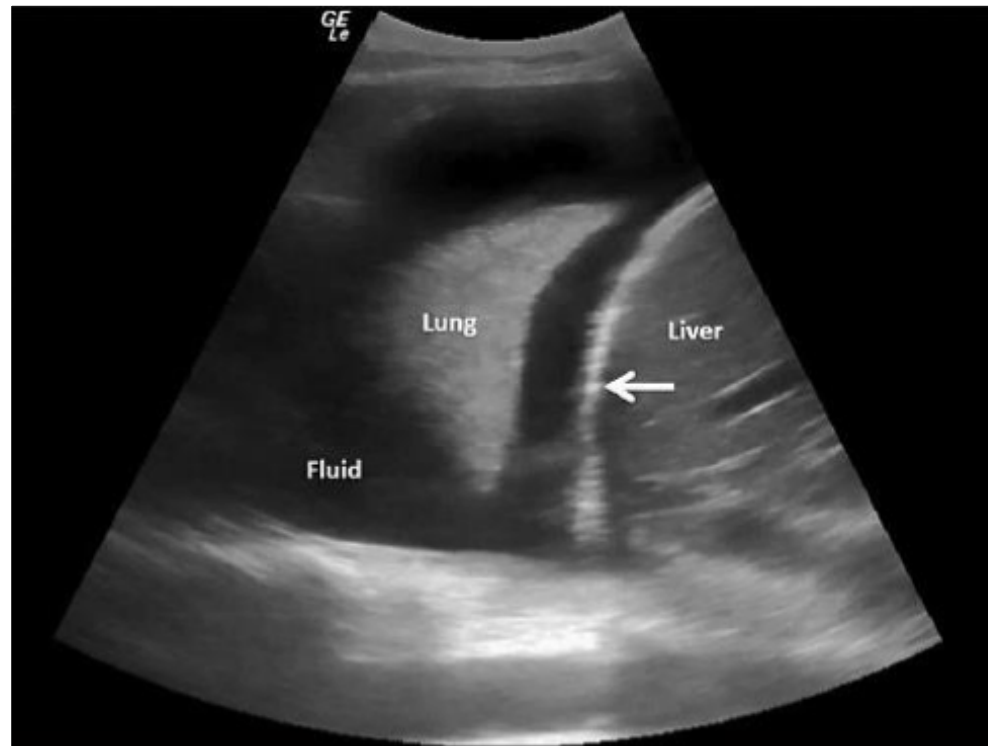


1. 2nd intercostal space, mid-clavicular line
2. 5th IC space, anterior axillary line

3. Level of diaphragm, axillary line
4. Level of diaphragm, posterior axillary line



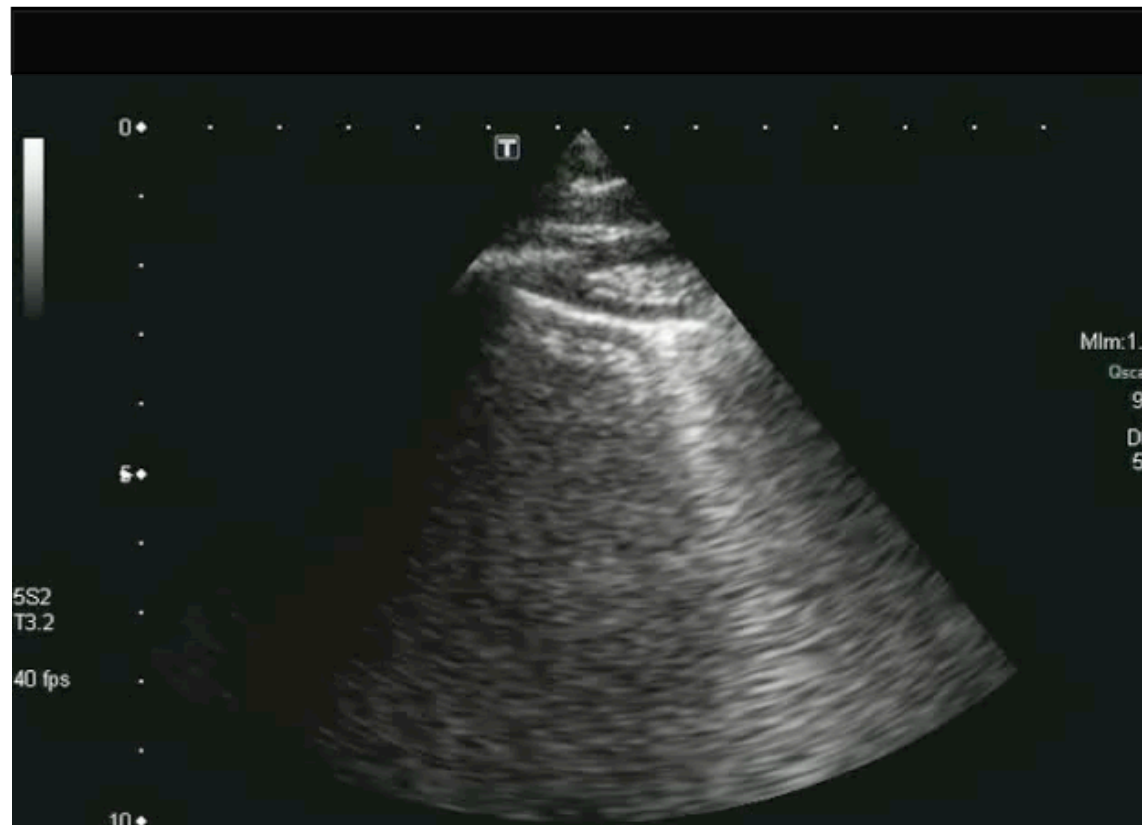
Lung Ultrasound



Pleural Effusion



Lung Ultrasound

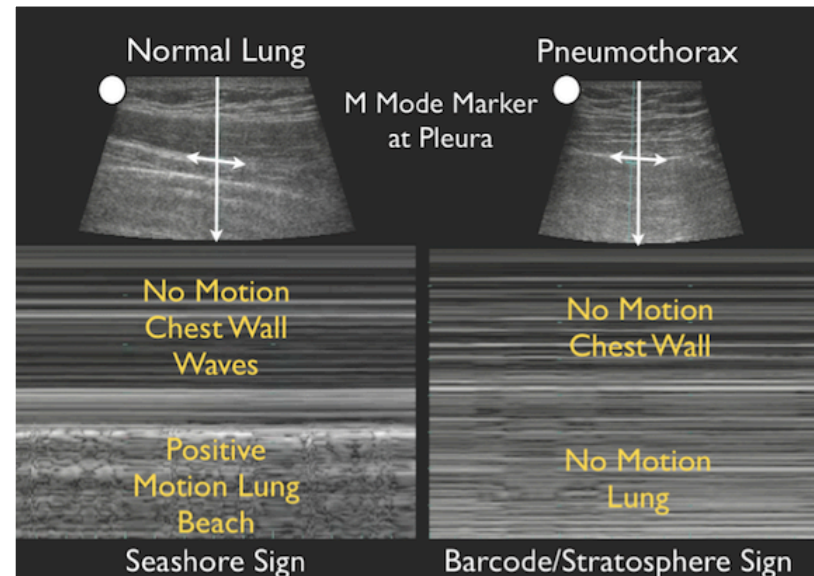


“B Lines” = Pulmonary Edema



Pneumothorax

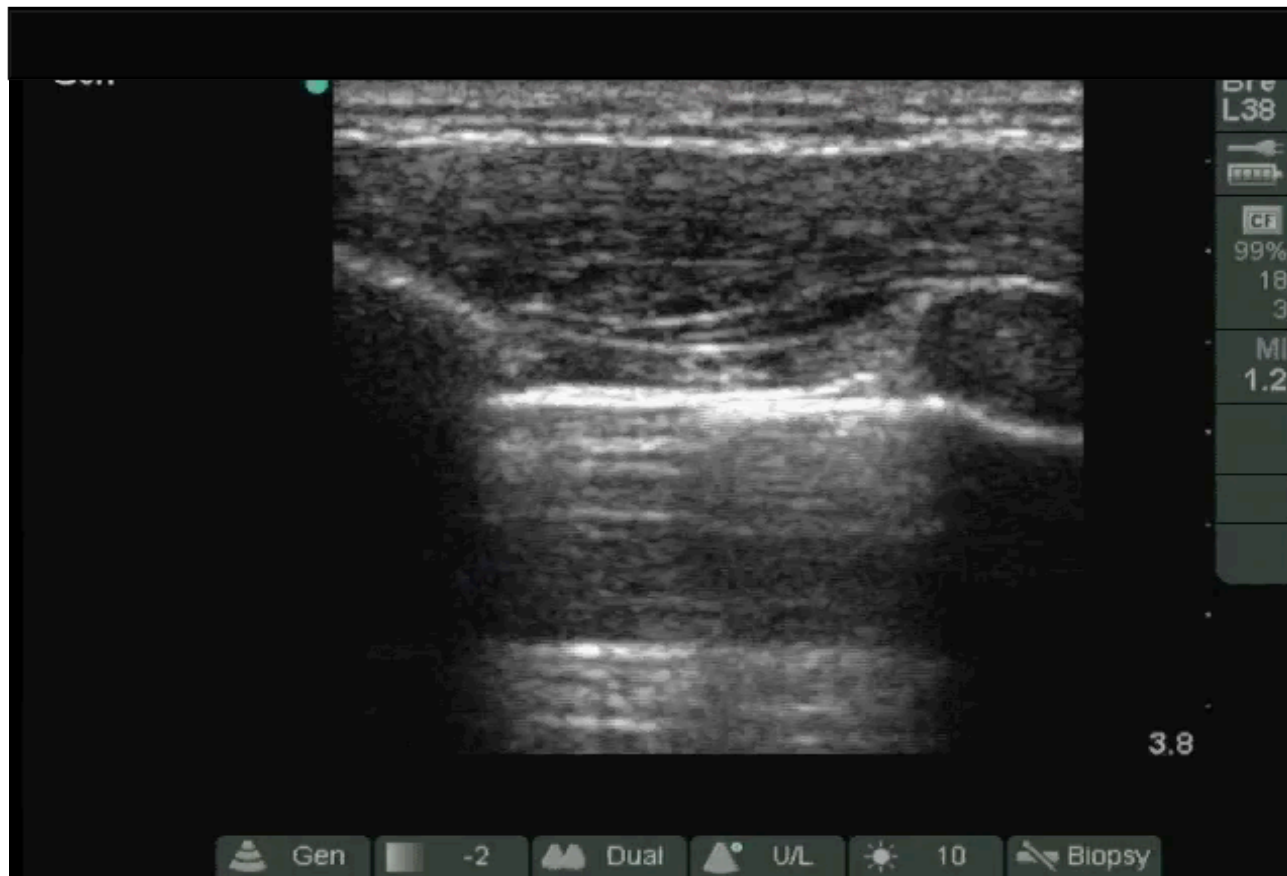- ❑ Midclavicular, longitudinal
- ❑ Find the pleura between two ribs
 - ❑ Lung sliding = normal (rules out pneumothorax)
 - ❑ No sliding = Pneumo
- ❑ “Seashore” = Normal
- ❑ Barcode = Pneumo



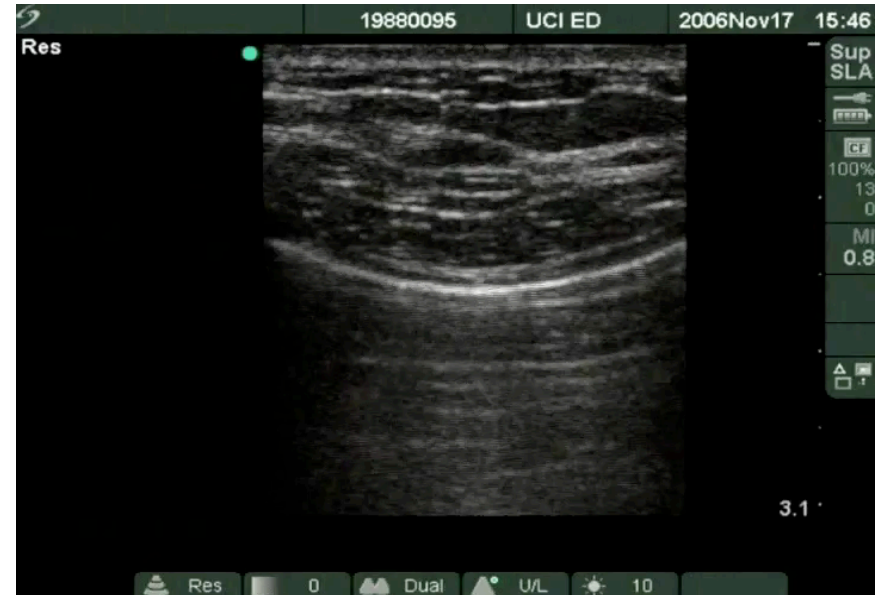
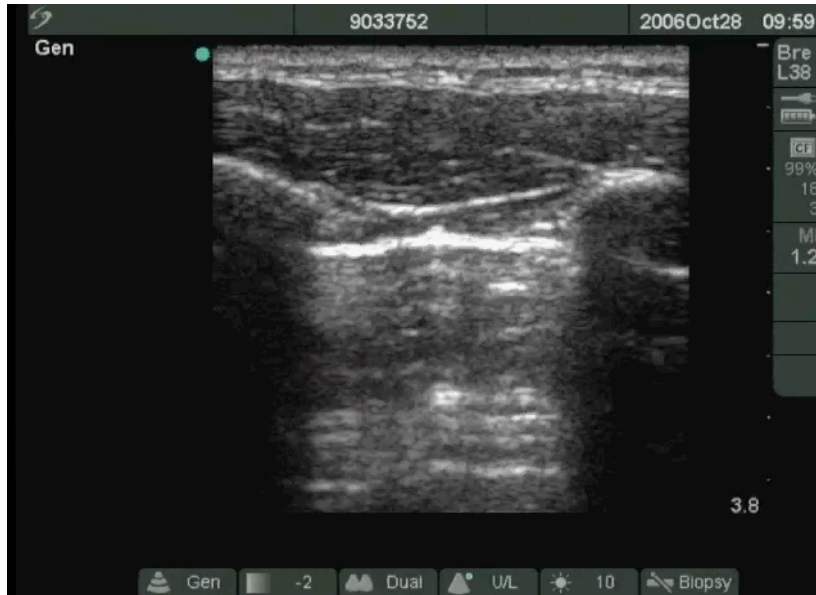Ultrasound is actually more sensitive than CXR for finding a pneumothorax!



Normal Lung Sliding



Which side demonstrates a pneumothorax?



Case #3

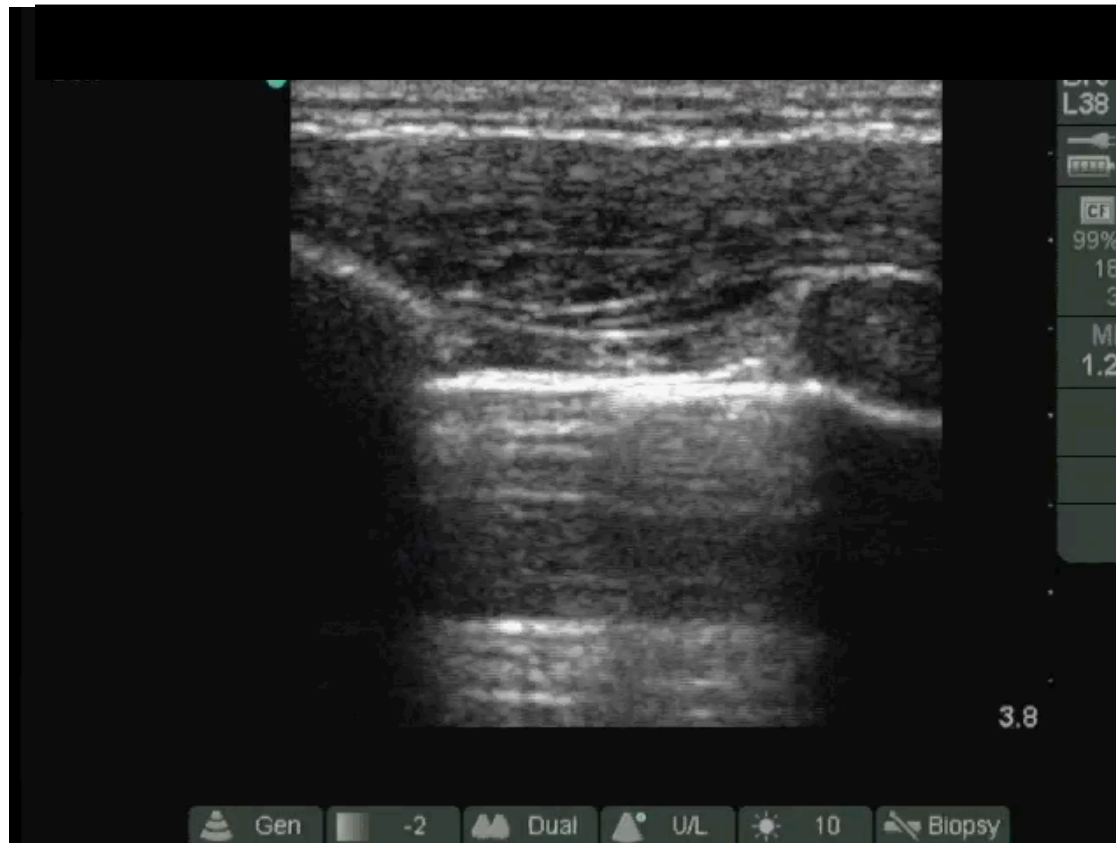
22yo female with history of asthma, collapsed in her front yard.

- ▣ Her neighbor witnessed the event and called 911, saying “I think she must’ve had an asthma attack, she’s turning blue!”
- ▣ **Tachycardic, hypotensive, and cyanotic** in field.
- ▣ Intubated. Has a weak, fast pulse.



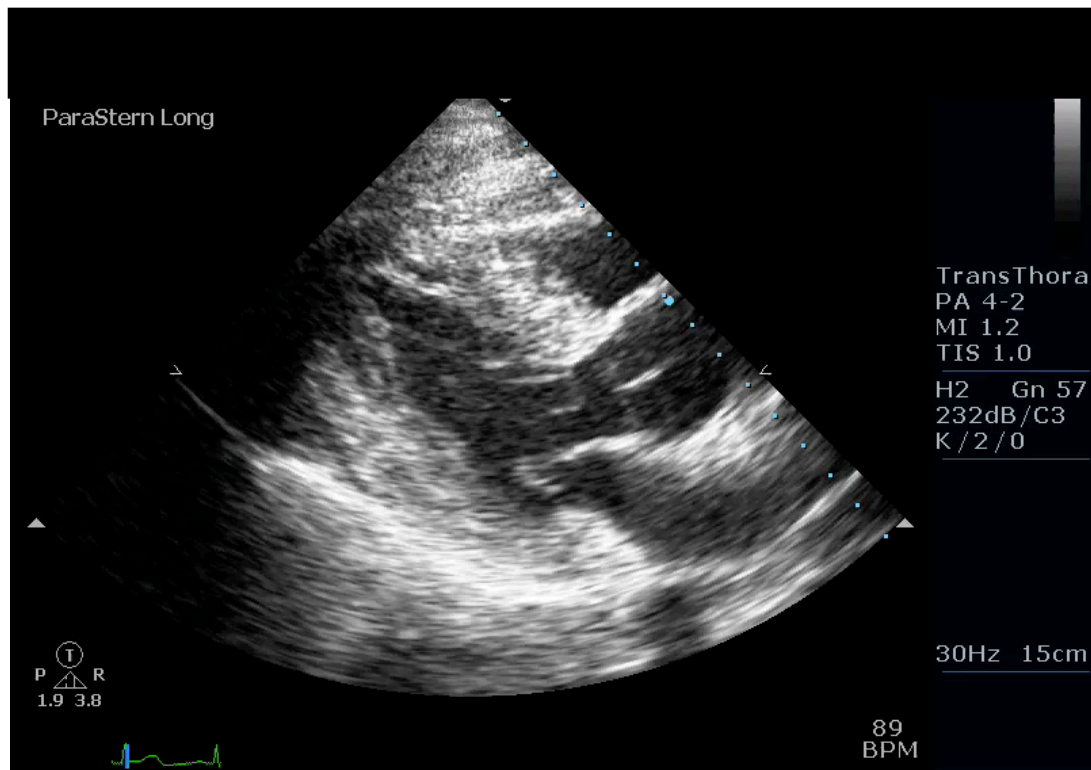
Case #3

Does she have a pneumothorax??



Case #3

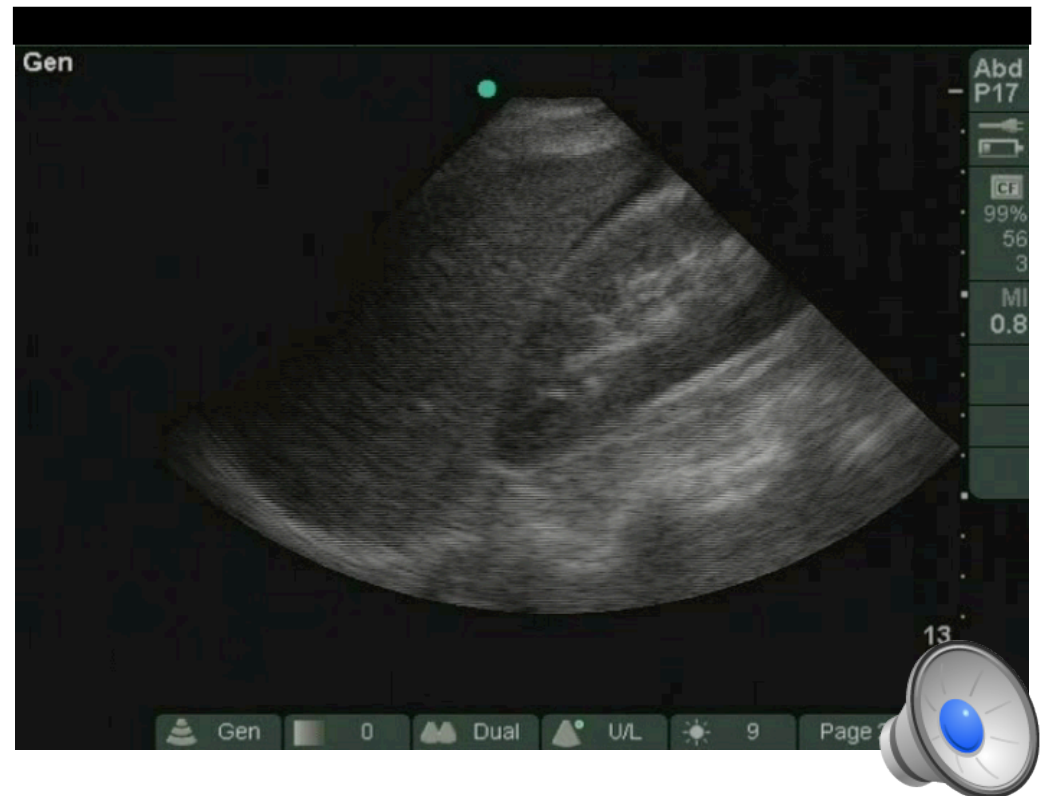Is it her heart??



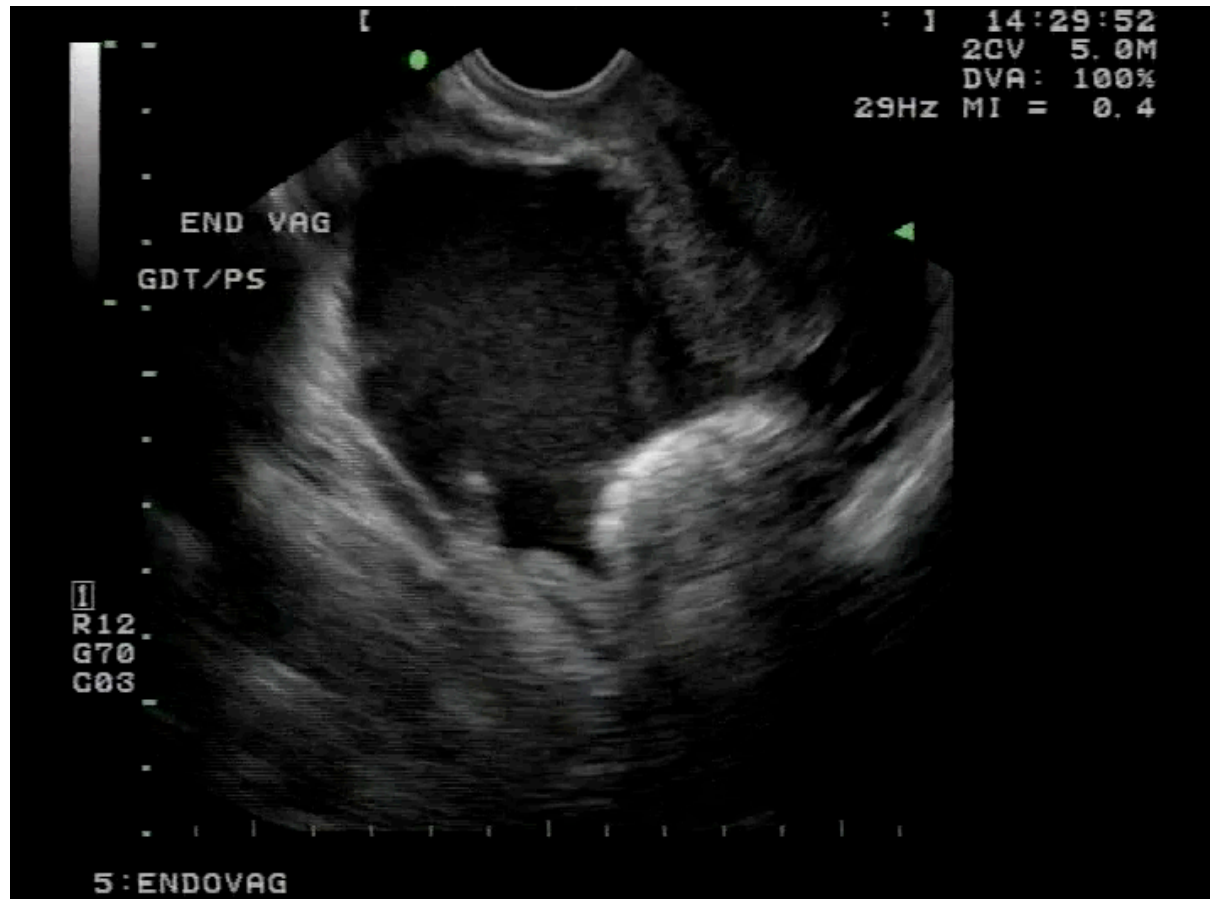Case #3

Why is she hypotensive??

- Hepatorenal view
- Free fluid in Morison's Pouch
- Ruptured ectopic pregnancy



Case #3



Reminder!

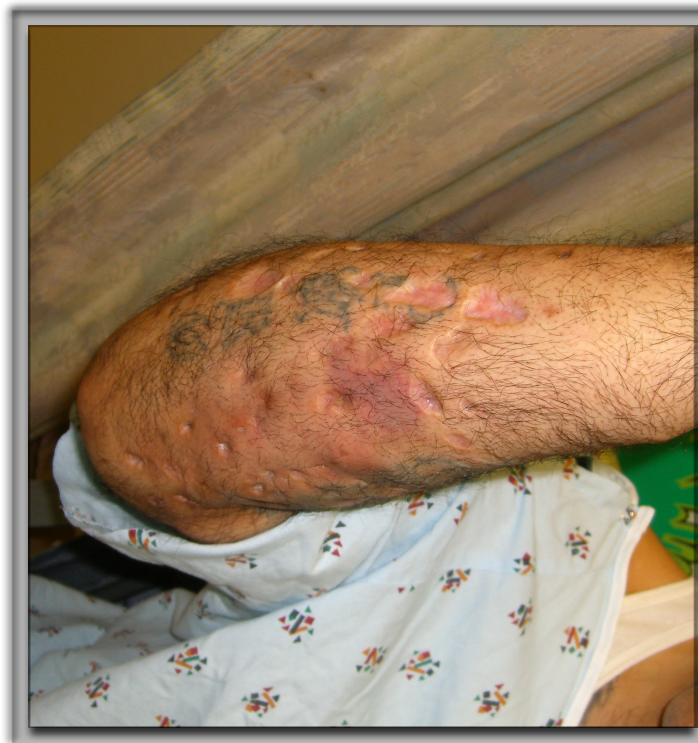If you have a patient with unexplained **hypotension**, consider:

1. Is it the pump??
2. Is it the pipes?? (hypovolemia, bleeding)



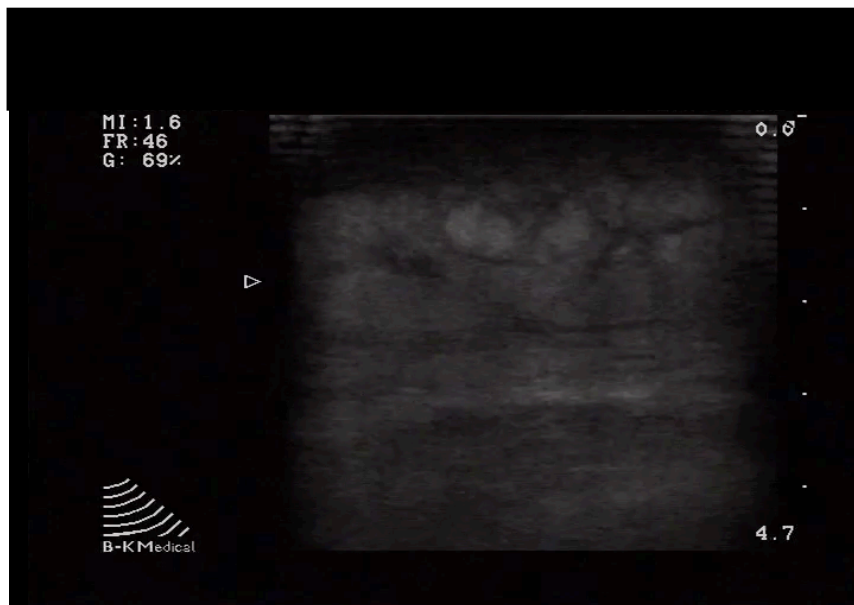
How can I use this in the office?

Should I do an I&D or apply heat and give antibiotics?

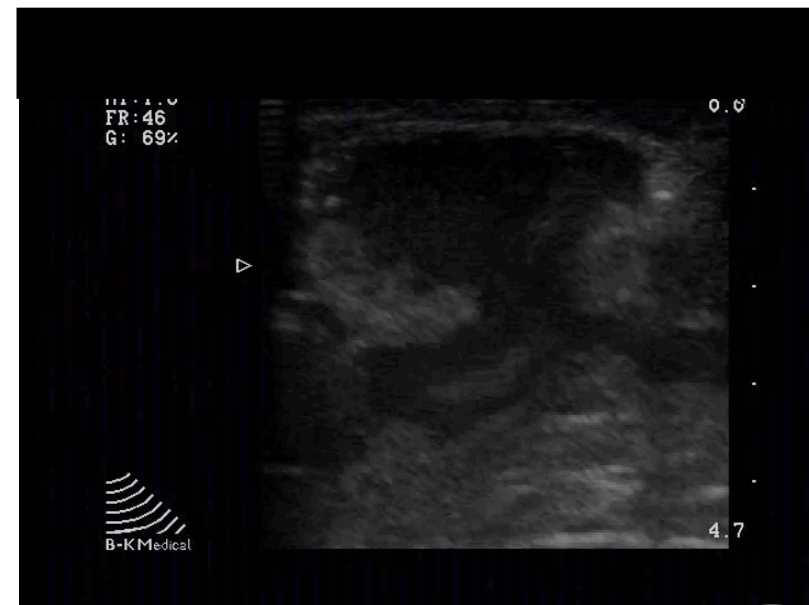


Cellulitis vs. Abscess?

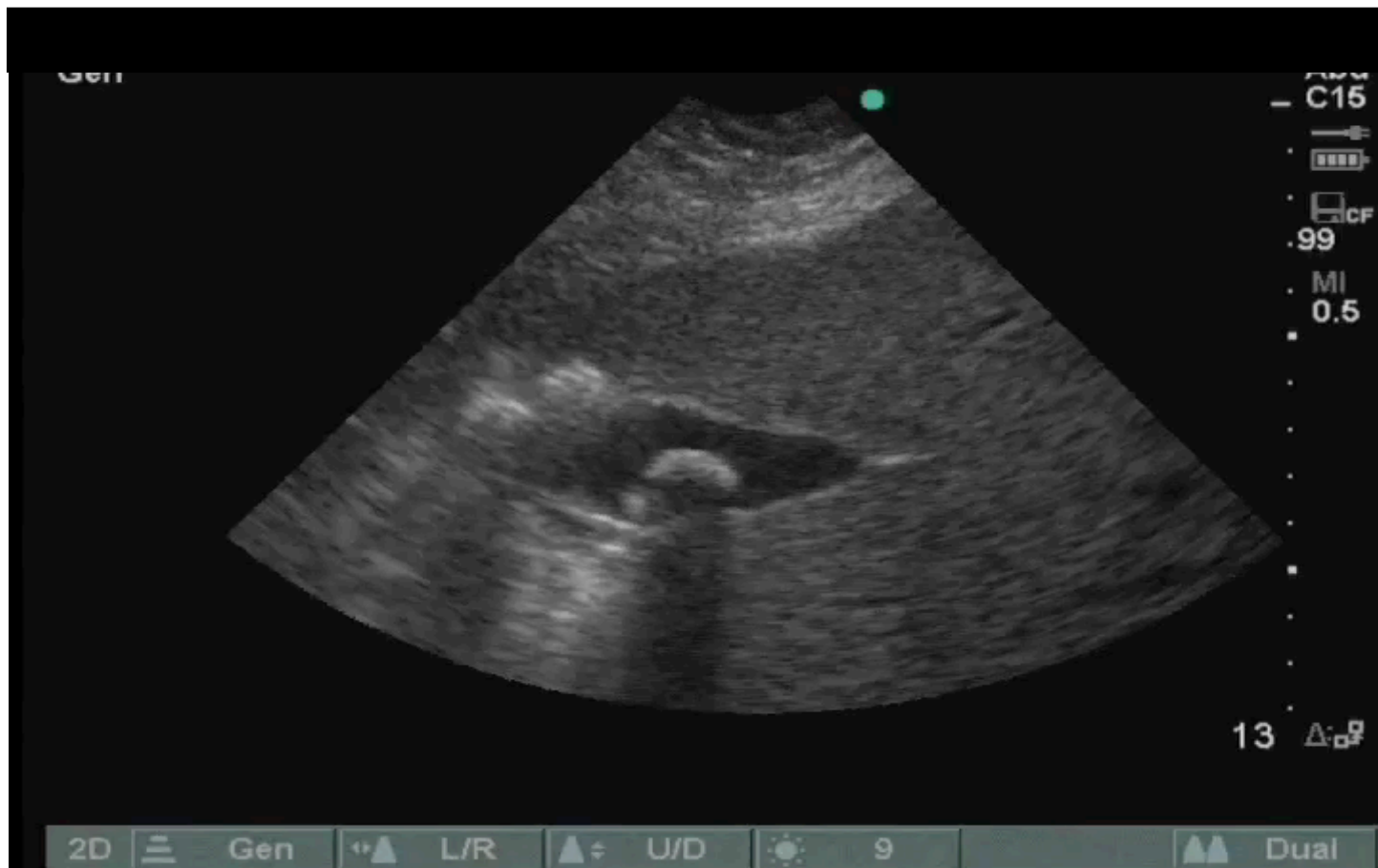Cellulitis



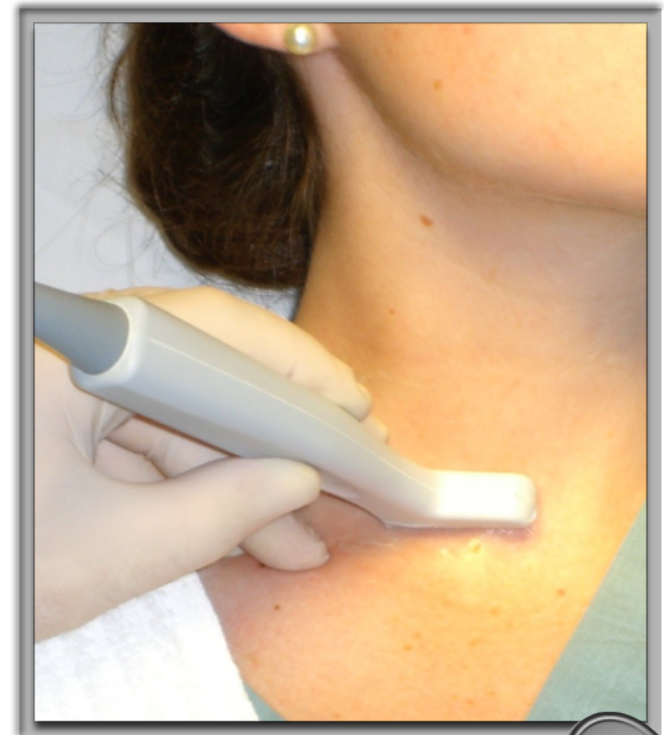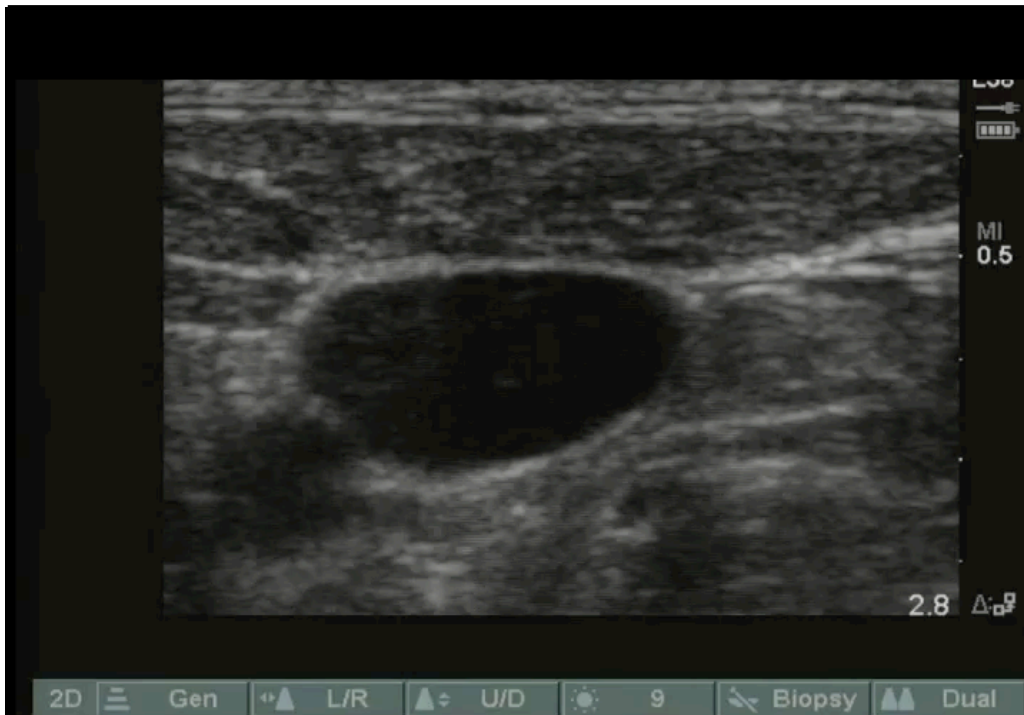Abscess



42 yo female with nausea and RUQ pain



Central Line Placement



How am I going to learn to
ultrasound?!?



Photo Copyright © Antonio Carrasquilla - IBERIAN SPOTTERS

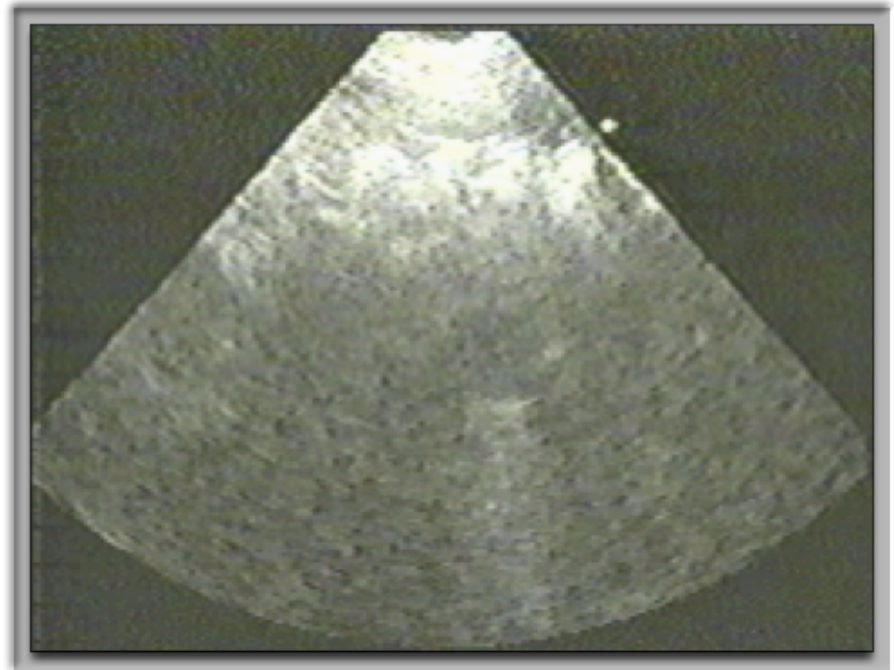
AIRLINERS.NET

Keep it simple!



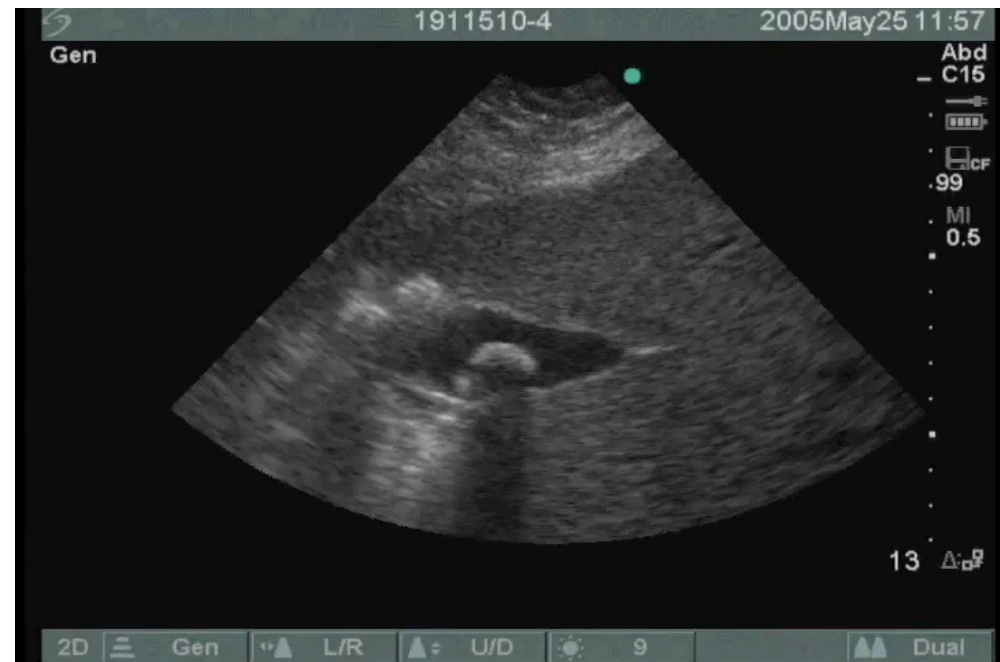Typical Learning Curve

Step #1:
Snow storm



Typical Learning Curve

Step #2:
“I see gallstones!!”



Typical Learning Curve

Step #3:

“This is exciting!
What else can I do
with this?!”



Lessons for Practice

- ▣ PRACTICE ultrasound as much as possible!
- ▣ Don't interpret something you are not sure of.
- ▣ The more you scan, the better you will get! 😊



Questions??



Anderson.Adrijana@mayo.edu



References

- Jensen MB, Sloth E, Larsen KM, Schmidt MB. Transthoracic echocardiography for cardiopulmonary monitoring in intensive care. *Eur J Anesthesiology*. 2004;21:7007.
- Lamia B, Ochagavia A, Monnet X, et al. Echocardiographic prediction of volume responsiveness in critically ill patients with spontaneously breathing activity. *Intensive Care Med*. 2007;33:1125-32.
- Critical Care Ultrasound Course Handout. SCCM Adult Ultrasound Course. 2014.
- Lichtenstein DA, Mezière GA. Relevance of Lung Ultrasound in the Diagnosis of Acute Respiratory Failure. *Chest*. 2008;134(1):117-125. doi:10.1378/chest.07-2800.
- Alrajab S, Yousef AM, Akkus N, Caldito G. Pleural ultrasonography versus chest radiography for the diagnosis of pneumothorax: review of the literature and meta-analysis. *Critical Care* 2013, 17:R208.
- Long E, Oakly E, Duke T, Babl FE. Does Respiratory Variation in Inferior Vena Cava Diameter Predict Fluid Responsiveness: A Systemic Review and Meta-Analysis. *SHOCK* 2017; 47(5):550-559.
- With special thanks to Dr. Joseph Wood, Hannelisa Callisen, PA-C and Andrew Walker, MMS, PA-C.

