

EVALUATION AND TREATMENT OF
THE RED EYE

TARA MCSWIGAN, MPAS, PA-C

DISCLOSURES

- TARA MCSWIGAN HAS NO PROFESSIONAL AFFILIATIONS NOR FINANCIAL INTERESTS TO DISCLOSE PERTAINING TO THIS TOPIC.

OBJECTIVES

- EXECUTE A PROBLEM-FOCUSED EXAMINATION OF THE RED EYE
- DIFFERENTIATE AMONG A HOST OF RED EYE PATHOLOGIES
- INITIATE PROPER PLAN OF CARE AND/OR REFERRAL FOR PROMPT MANAGEMENT

EXPERT EYE WITNESS

- FEW AREAS OF MEDICINE IMPACT THE PATIENT'S QUALITY OF LIFE AS DOES HIS ABILITY TO SEE
- RED EYES PRESENT WITH CONSIDERABLE FREQUENCY TO PRIMARY MEDICINE/URGENT CARE/EMERGENCY MEDICINE

EXPERT EYE WITNESS

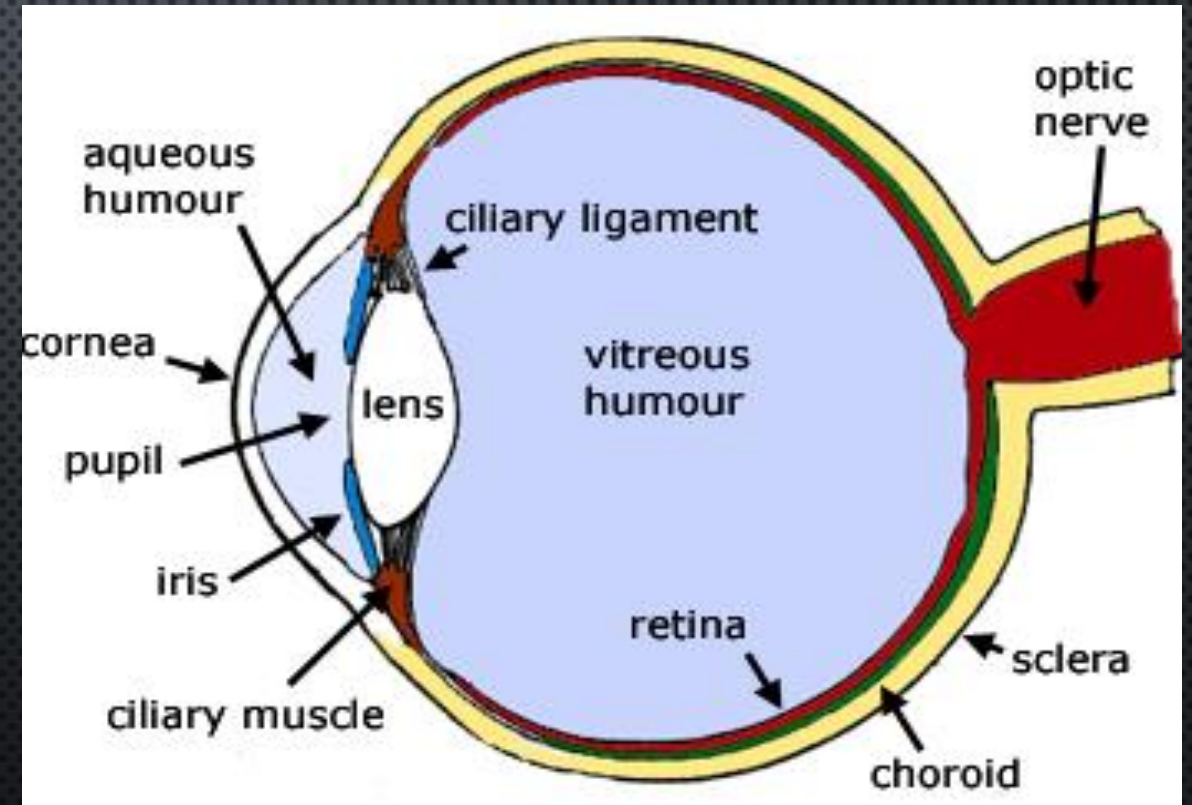
- WHAT'S SO WRONG WITH RED? SPECTRUM OF PATHOLOGY, SEVERITY, AND IMPLICATIONS
- QUICK DIFFERENTIAL/PLAN OF CARE HAS GREAT IMPACT UPON OUTCOMES

PERTINENT HISTORY

- PAINFUL CONDITION: THINK ANTERIOR EYE
- IMPACT ON VISION?
- RECENT TRAUMA/ILLNESS?
- USE OF CONTACTS?

SYSTEMATIC EXAMINATION: ANTERIOR TO POSTERIOR

- **ANTERIOR:** LIDS, LASHES, SOFT TISSUE AND ORBITAL STRUCTURES
- **MID-EYE:** CORNEA, ANTERIOR CHAMBER, IRIS, CILIARY STRUCTURES, UVEA, LENS, CONJUNCTIVA
- **POSTERIOR:** GLOBE/VITREOUS, RETINA, NEUROVASCULAR DISTRIBUTION, CUP/DISK, MACULA



<http://www.a-levelphysicstutor.com/images/optics/eye-diagram.jpg>

PERTINENT PHYSICAL: REMEMBER THE BASICS

- HOW ABOUT THOSE PUPILS?
- EXTRAOCULAR MOVEMENTS?
- ALWAYS ALWAYS CHECK VISUAL ACUITY!
- MAY NEED TO OBTAIN INTRAOCULAR PRESSURE (IOP)

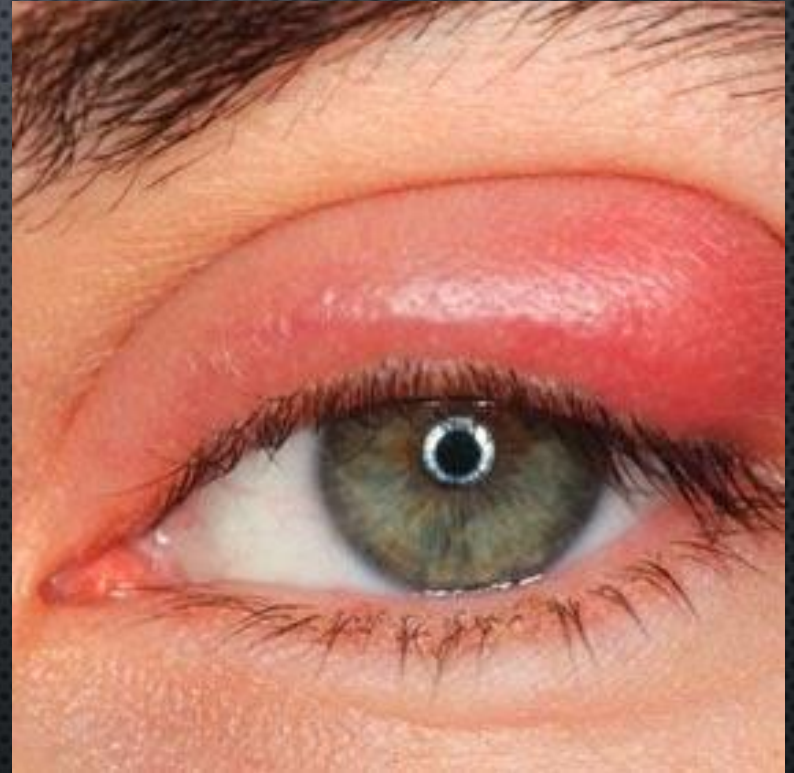NOW...**THE RED EYE!**

- FOUR QUESTIONS:
 - WHAT'S THE RED?
 - WHY'S THE RED?
 - HOW BAD IS IT?
 - TREATMENT?

SEEING RED: EXTERNAL STRUCTURES

STYE/HORDEOLUM

- WHAT'S THE RED?
 - INFLAMMATION OF LID MARGIN, UPPER > LOWER, INTERNAL AND EXTERNAL



EXAM FINDINGS

SEEING RED: EXTERNAL STRUCTURES

STYE/HORDEOLUM

- WHY'S THE RED?
 - BLOCKAGE OF OIL GLAND OF LID MARGIN,
SECONDARY INFLAMMATION OR MILD INFECTION
- HOW BAD IS IT?
 - TYPICALLY SELF-LIMITED
 - CAN EVOLVE INTO SECONDARY STAPH/STREP BLEPHARITIS

SEEING RED: EXTERNAL STRUCTURES

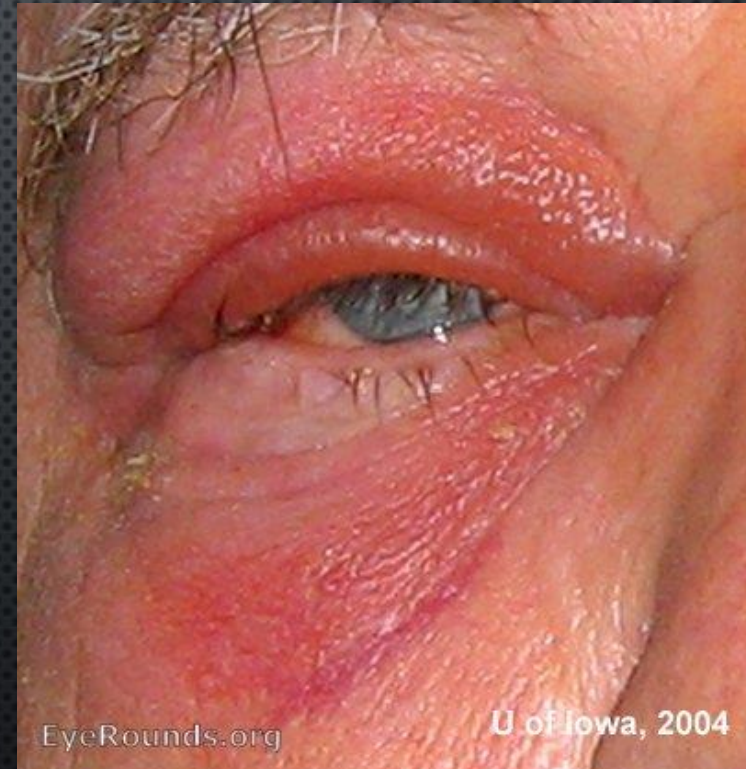STYE/HORDEOLUM

- TREATMENT:
 - WARM MOIST COMPRESSES
 - SOMETIMES TOPICAL ANTIBIOTICS [TOBRAMYCIN (TOBREX), POLYMYXIN B/TRIMETHOPRIM (POLYTRIM)]
 - RARELY ORAL ANTIBIOTICS

SEEING RED: EXTERNAL STRUCTURES

PERI-ORBITAL/ORBITAL CELLULITIS

- WHAT'S THE RED?
 - INFLAMMATION OF LIDS, SURROUNDING SOFT TISSUES, CONJUNCTIVA, AND PERIORBITAL FATTY STRUCTURES



EXAM FINDINGS

SEEING RED: EXTERNAL STRUCTURES

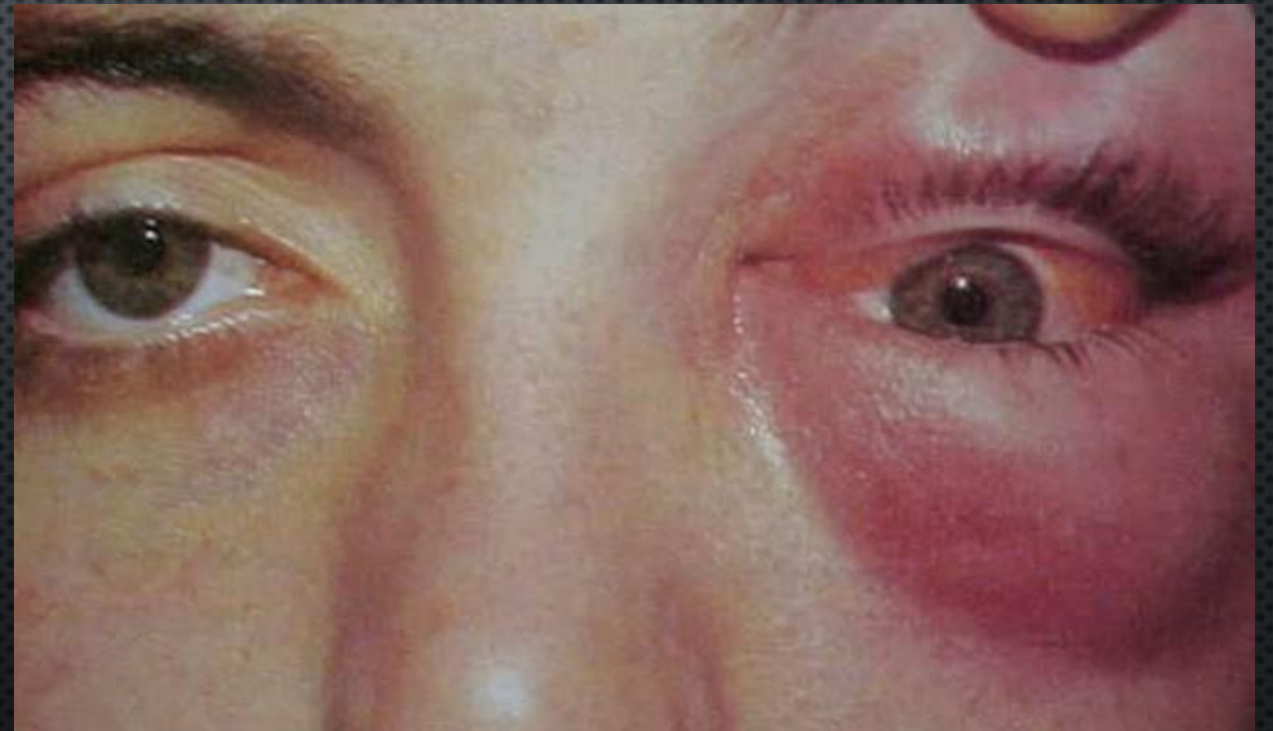PERI-ORBITAL/ORBITAL CELLULITIS

- WHY'S THE RED?
 - BACTERIAL INFECTION FROM SINUSES, OCCUPIES ASSOCIATED TISSUES (STAPHYLOCOCCUS/STREPTOCOCCUS)
- HOW BAD IS IT?
 - SERIOUS IMPLICATIONS, ESPECIALLY IF ORBITAL CELLULITIS (RISK OF CAVERNOUS THROMBOSIS)

SEEING RED: EXTERNAL STRUCTURES

PERI-ORBITAL/ORBITAL CELLULITIS

- UNIQUE EXAM FINDINGS:
 - CHEMOSIS
 - PROPTOSIS
 - PAINFUL/IMPAIRED EOM'S



SEEING RED: EXTERNAL STRUCTURES

PERI-ORBITAL/ORBITAL CELLULITIS

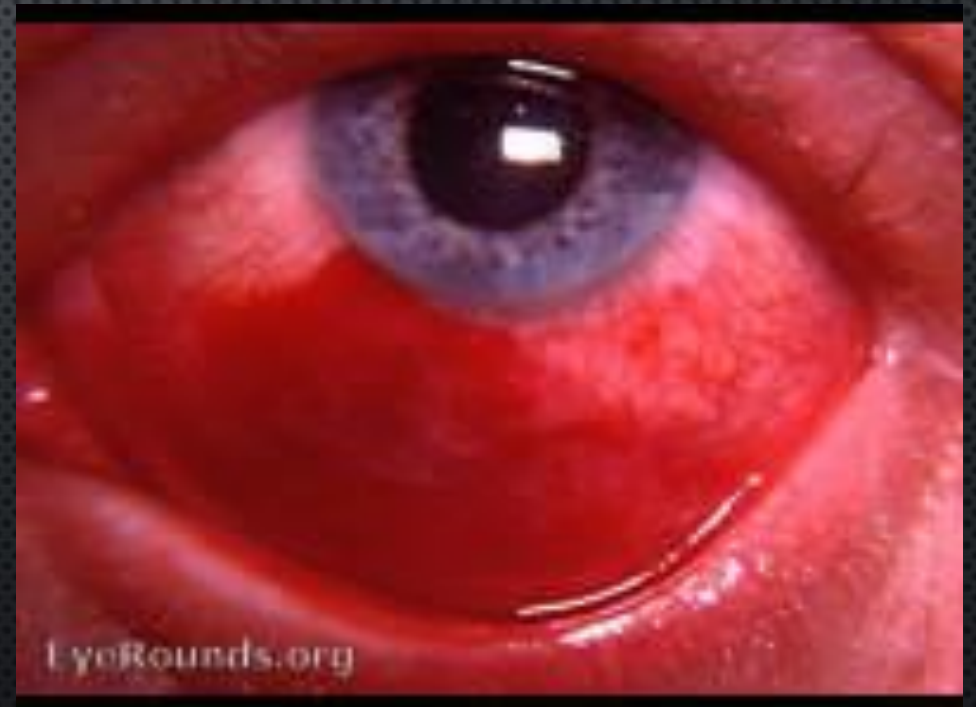- DIAGNOSIS/TREATMENT:
 - ENHANCED CT FACIAL STRUCTURES, CBC, ESR, BLOOD CULTURES
 - ADMISSION: IV ANTIBIOTICS, CONSULTATIONS WITH OPHTHALMOLOGY, ENT, NEUROLOGY

OCULAR EMERGENCY!!!

SEEING RED: CONJUNCTIVA

SUBCONJUNCTIVAL HEMORRHAGE

- WHAT'S THE RED?
 - BRIGHT-RED BLOOD ACCUMULATING OVER THE WHITE OF THE EYE/BETWEEN THE SCLERA AND BULBAR CONJUNCTIVA



EXAM FINDINGS

SEEING RED: CONJUNCTIVA

SUBCONJUNCTIVAL HEMORRHAGE

- WHY'S THE RED?
 - INCREASE OF PRESSURE CAUSES RUPTURE OF SMALL CAPILLARIES OF SCLERA, ACCUMULATION OF BLOOD ALONG THE WHITE OF THE EYE; NO ASSOCIATED PAIN
- HOW BAD IS IT?
 - MINOR ISSUE, UNSIGHTLY, BUT MAY FRIGHTEN PATIENT

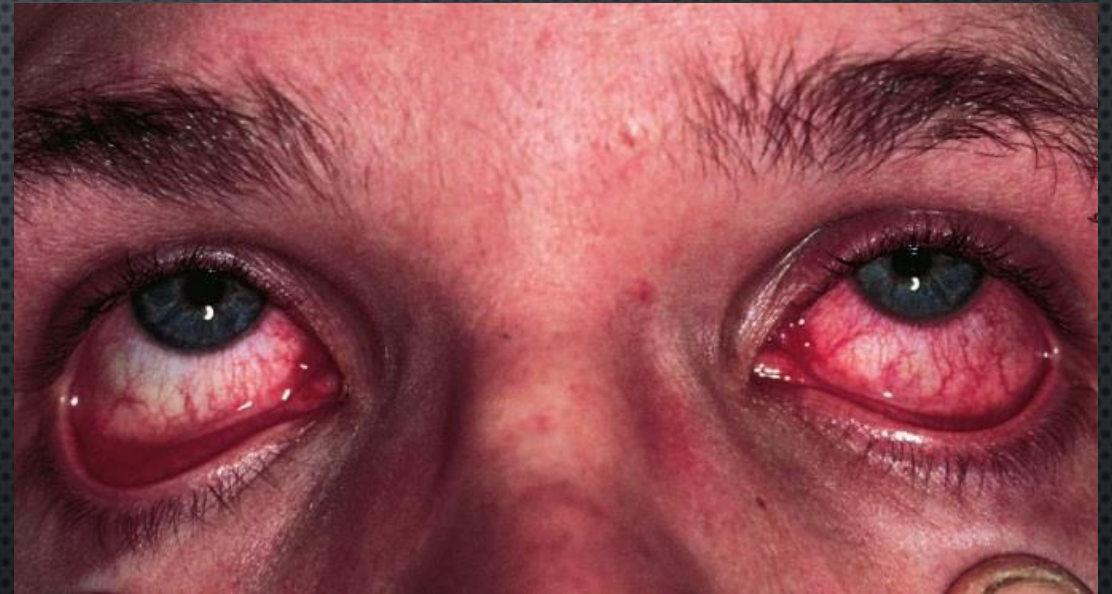SEEING RED: CONJUNCTIVA **SUBCONJUNCTIVAL HEMORRHAGE**

- TREATMENT:
 - NO INTERVENTION NEEDED/SPONTANEOUS RESOLUTION
 - EDUCATE PATIENT: BLOOD HAVE APPEARANCE OF “SPREADING” IN A DEPENDENT MANNER

SEEING RED: CONJUNCTIVA

CONJUNCTIVITIS

- WHAT'S THE RED?
 - INFLAMMATION OF BULBAR CONJUNCTIVA, RANGING FROM MINIMAL INJECTION TO DIFFUSE ERYTHEMA



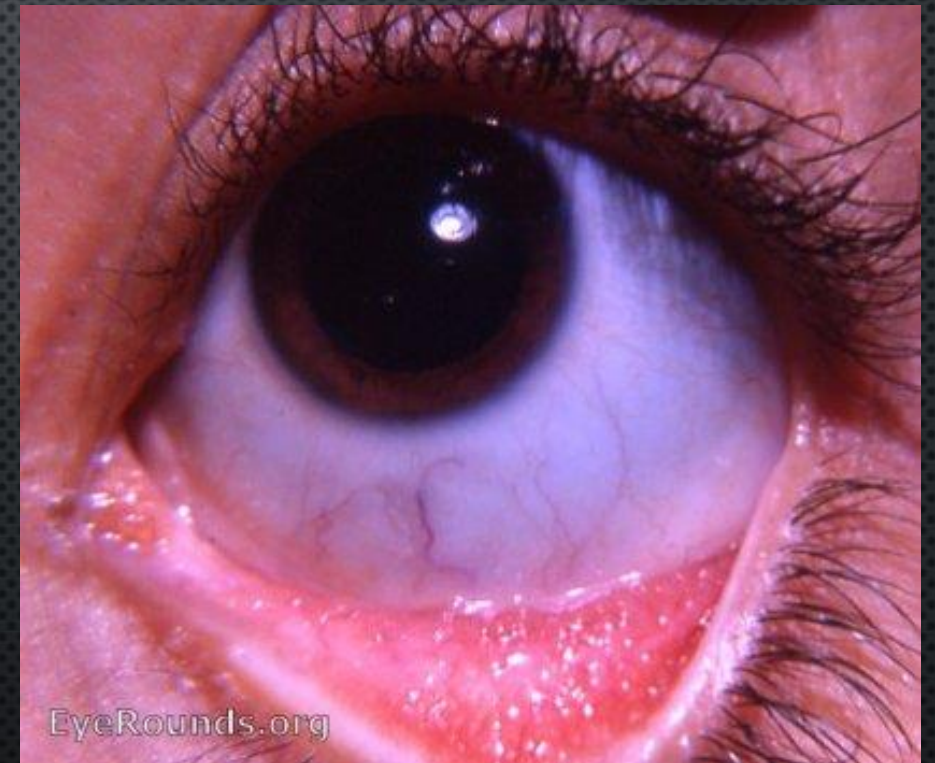EXAM FINDINGS

<https://1.bp.blogspot.com/-4rZvnlGFy9w/>

SEEING RED: CONJUNCTIVA

CONJUNCTIVITIS

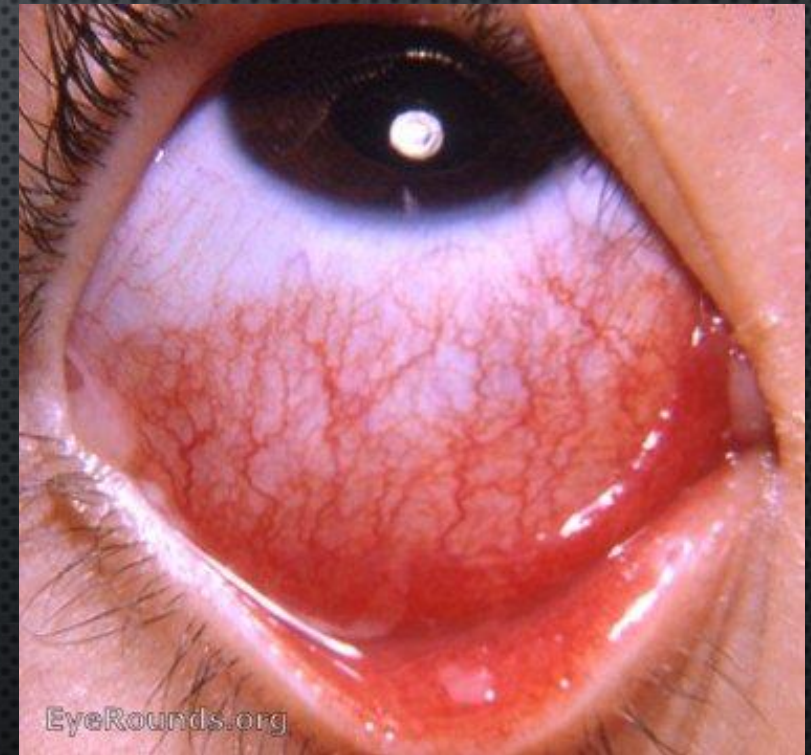- WHY'S THE RED?
 - INFECTIOUS VERSUS ALLERGIC
 - VIRAL (ADENOVIRUS) >>> BACTERIAL
 - DIFFUSE INJECTION VS LIMBAL SPARING
 - CONTACTS? CONSIDER PSEUDOMONAS



SEEING RED: CONJUNCTIVA

CONJUNCTIVITIS

- HOW BAD IS IT?
 - USUALLY SELF-LIMITED “EYE COLD,” SPONTANEOUS RESOLUTION
 - OCCASIONAL BACTERIAL, CAUTION WITH CONTACTS: ULCERATION? HYPOPYON?



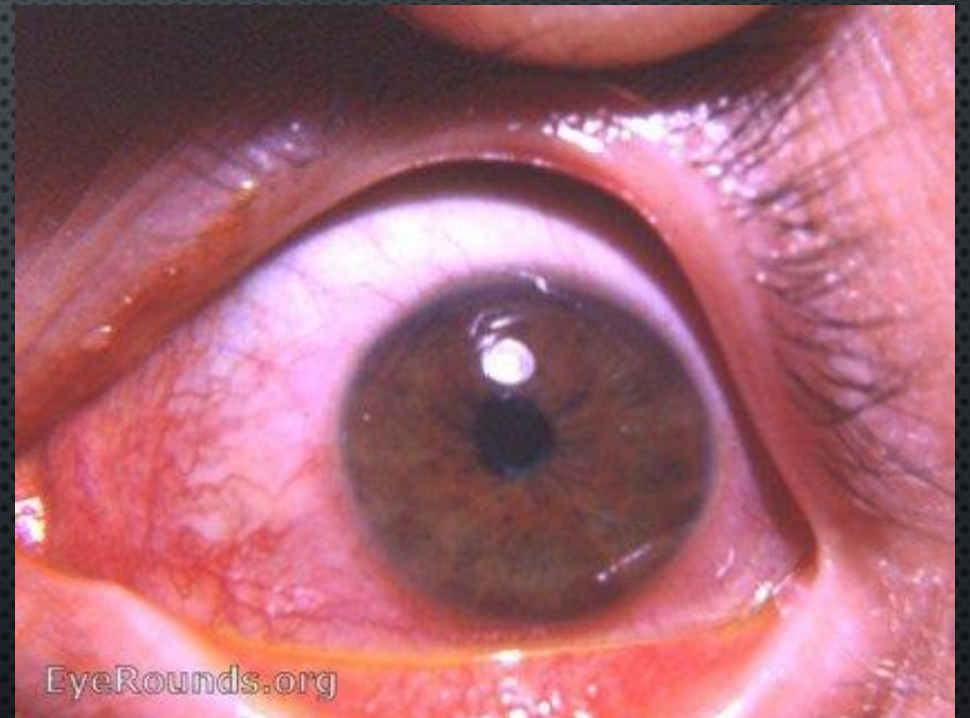SEEING RED: CONJUNCTIVA

CONJUNCTIVITIS

- TREATMENT: COMPRESSES, HYGIENE
- ALLERGIC: ORAL/TOPICAL ANTIHISTAMINES [LORATADINE (CLARITIN)/KETOTIFEN (XATIDOR)]
- VIRAL: SUPPORTIVE
- BACTERIAL:
 - TOPICAL ANTIBIOTICS (TOBREX, POLYMYCIN)
 - QUINOLONES FOR PSEUDOMONAS IF CONTACT LENS USER (CILOXAN, OFLOXACIN)

SEEING RED: CORNEA

- WHAT'S THE RED?
 - CORNEA NOT RED! CORNEAL EPITHELIAL CELLS LACK VASCULATURE
 - CORNEAL INFLAMMATION PROMPTS INJECTION OF ADJACENT CONJUNCTIVA
 - FOCAL LIMBUS: POINT TO PROBLEM



EXAM FINDINGS

SEEING RED: CORNEA

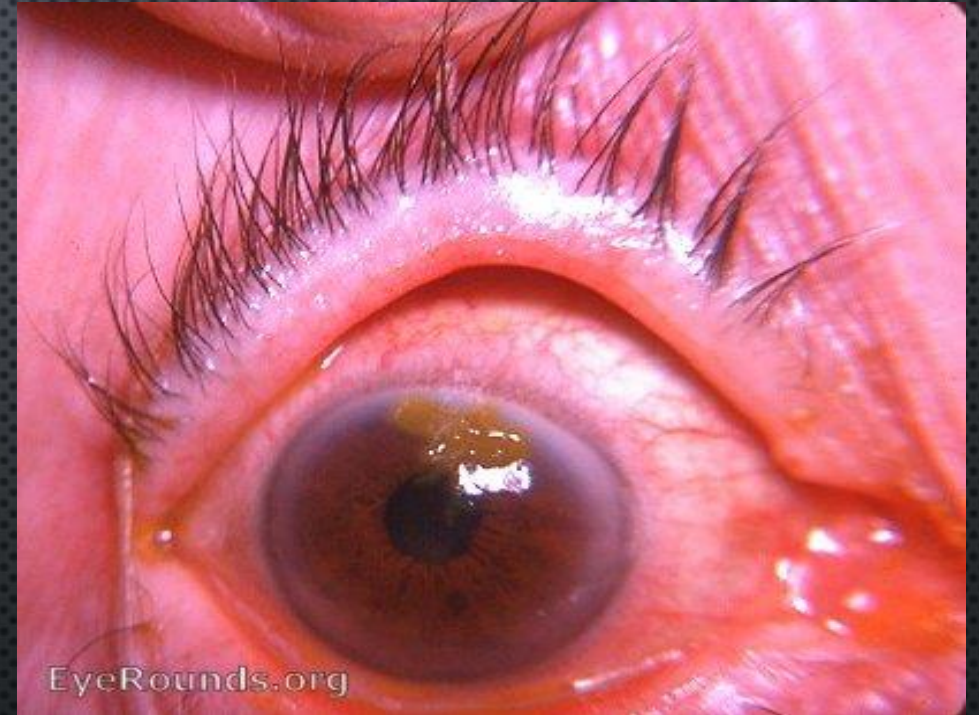HOST OF REASONS...

- WHY'S THE RED?
 - INITIAL EXAM SUGGESTIVE OF CONJUNCTIVITIS (REDNESS, TEARING, PHOTOPHOBIA)
 - WHEN THINKING CORNEA: FLUORESCEIN STAIN AND WOODS LAMP
 - CONSIDER TETRACAINE DROPS: PATIENT COMFORT/BETTER EXAM

SEEING RED: CORNEA

CORNEAL ABRASION

- WHAT? SCRATCHING OF CORNEAL SURFACE
- WHY? TRAUMA
- UNIQUE EXAM:

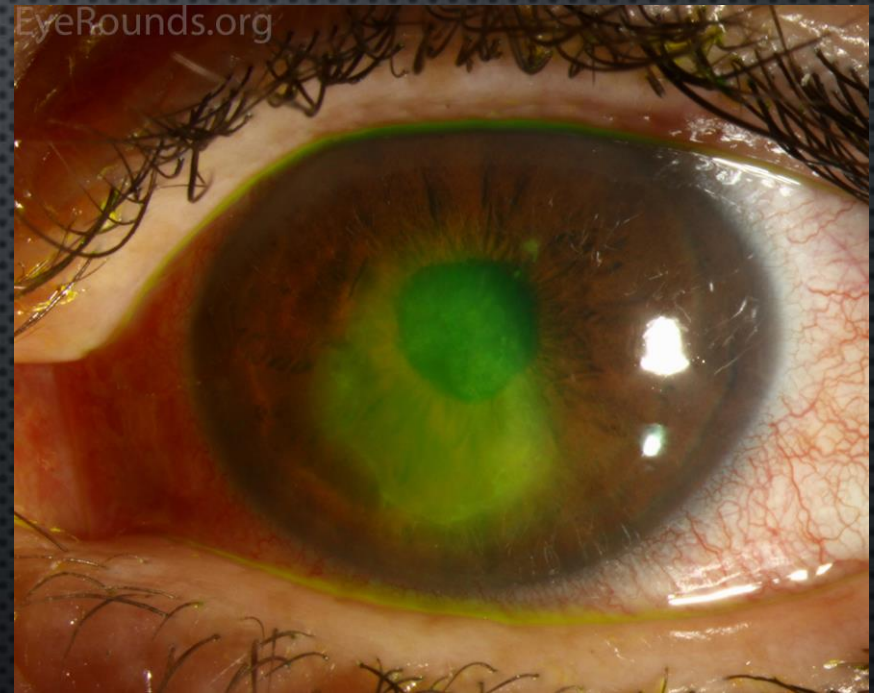

INCREASED UPTAKE OF FLUOROSCEIN NOTED
WITH LAMP, ABSORBS INTO INJURED
EPITHELIAL CELLS

SEEING RED: CORNEA

CORNEAL ABRASION

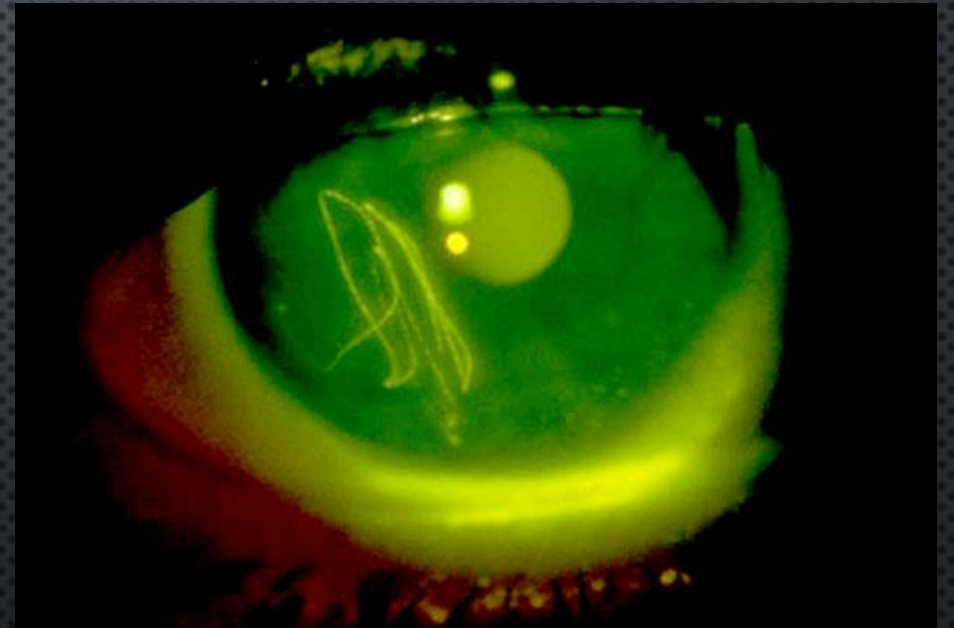
- HOW BAD IS IT?
 - DEPENDS ON EXTENT AND LOCATION OF INJURY
 - ALWAYS DOCUMENT ACUITY!



SEEING RED: CORNEA

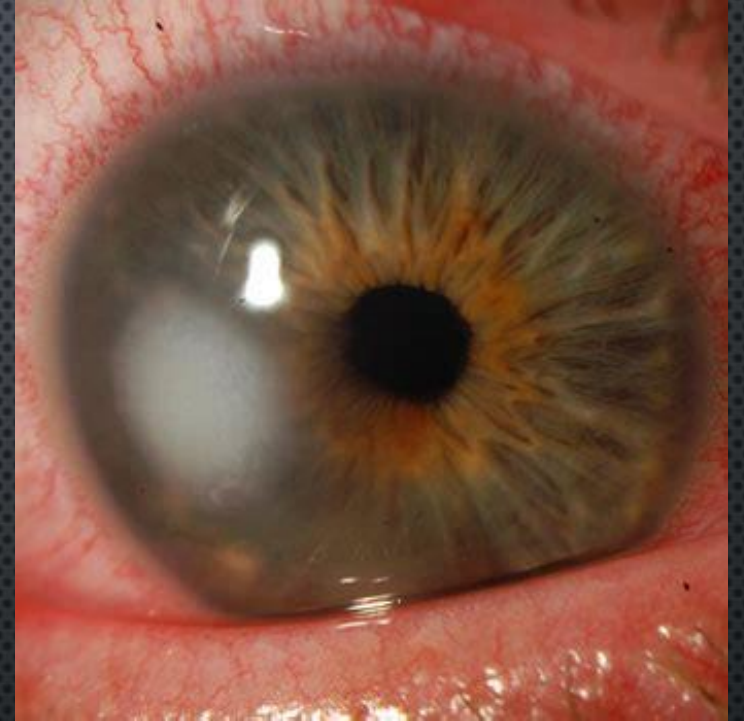CORNEAL ABRASION

- TREATMENT/PLAN
 - CONSIDER TETANUS STATUS
 - EMPIRIC ANTIBIOTIC DROPS
 - OPHTHALMOLOGIC REFERRAL



SEEING RED: CORNEA **ULCERATION**

- WHAT? ULCERATION OF CELLS
- WHY? LIKELY PSEUDOMONAS
- UNIQUE EXAM:



<https://www.eyecenters.com/wp-content>

WELL CIRCUMSCRIBED OPACITY, TYPICALLY SEEN WITH
WHITE LIGHT, ENHANCED WITH STAIN AND WOODS
LAMP

SEEING RED: CORNEA

ULCERATION: OCULAR EMERGENCY

- HOW BAD IS IT?
 - POTENTIAL SCARRING/IMPAIRMENT OF VISION IF CENTRAL VISUAL AXIS
- TREATMENT
 - QUINOLONES, PREFER 4TH GENERATION [GATIFLOXACIN (ZYMAR)/MOXIFLOXACIN (VIGAMOX)]
 - CONSULT AND REFER TO OPHTHALMOLOGY

SEEING RED: CORNEA

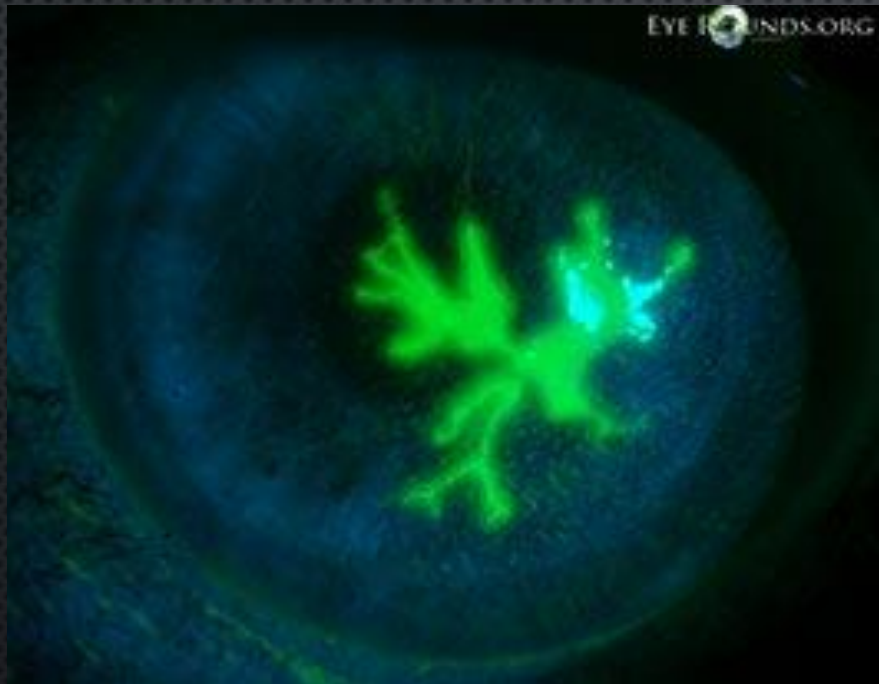HERPETIC INFECTION

- WHAT? DENDRITIC LESIONS OF CORNEA
- WHY? INFECTION FROM HSV OR HERPES ZOSTER
- UNIQUE EXAM:

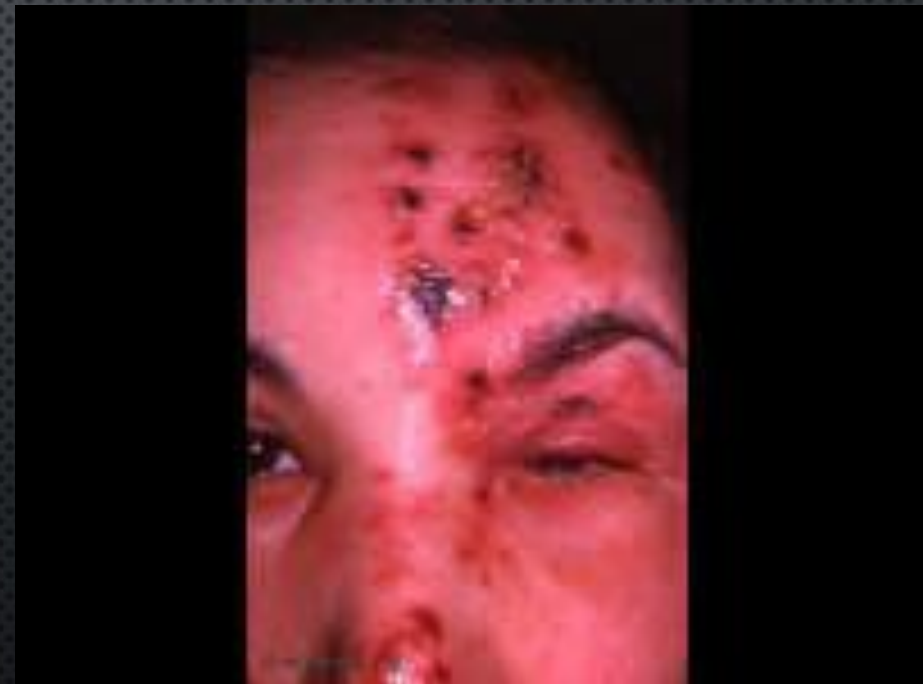HSV: TREE-BRANCH LESIONS, NOTED ONLY WITH STAIN
AND WOODS LAMP

HERPES ZOSTER: FACIAL RASH, FLARE AND CELL OF
ANTERIOR CHAMBER/SLIT LAMP EXAM

SEEING RED: CORNEA **HERPETIC INFECTION**



HERPES SIMPLEX VIRUS



HERPES ZOSTER/SHINGLES

SEEING RED: CORNEA

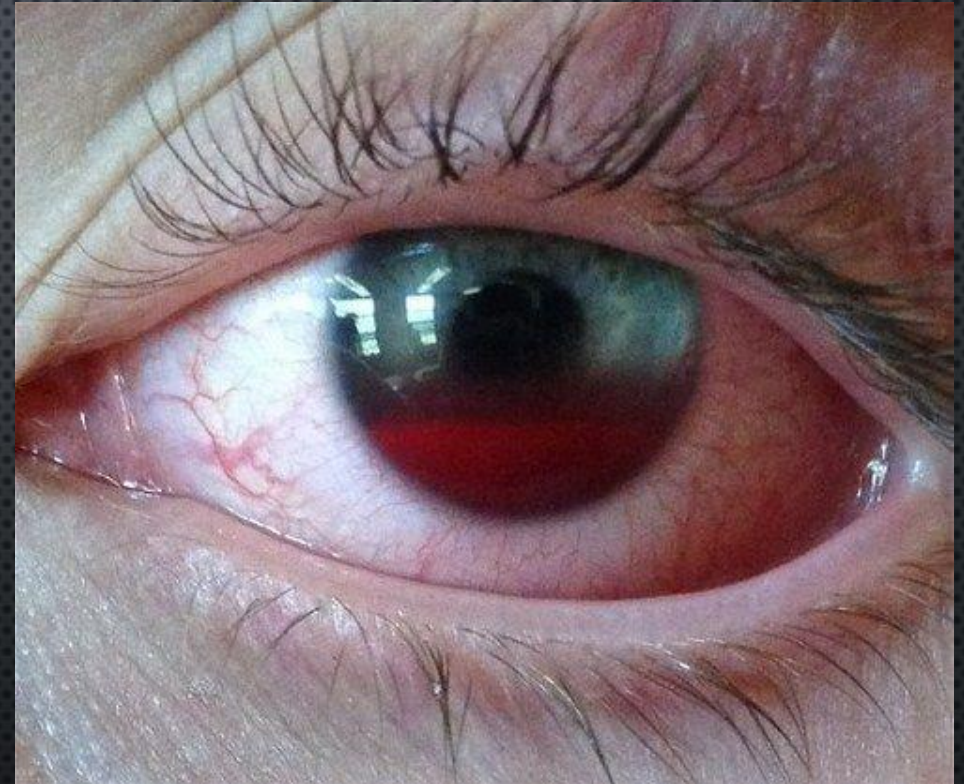HERPETIC INFECTION: OCULAR EMERGENCY

- HOW BAD IS IT?
 - POTENTIAL FOR CENTRAL SCARRING/IMPAIRED ACUITY
- TREATMENT/PLAN:
 - ORAL AND TOPICAL ANTIVIRALS
 - VALCYCLOVIR (VATREX) OR FAMCICLOVIR (FAMVIR)
 - TRIFLURIDINE (VIROPTIC) EYE DROPS
 - OPHTHALMOLOGY CONSULT AND REFERRAL

SEEING RED: ANTERIOR CHAMBER

HYPHEMA

- WHAT'S THE RED?
 - ACCUMULATION OF BLOOD IN THE ANTERIOR CHAMBER
 - FLUID LEVEL NOTED WITH PATIENT IN UPRIGHT/DEPENDENT POSITION



EXAM FINDINGS

<https://i.pinimg.com/736x/14/42/68/1442683a7e6b2266a309c9cf8f473c6b--red-blood-cells-med-school.jpg>

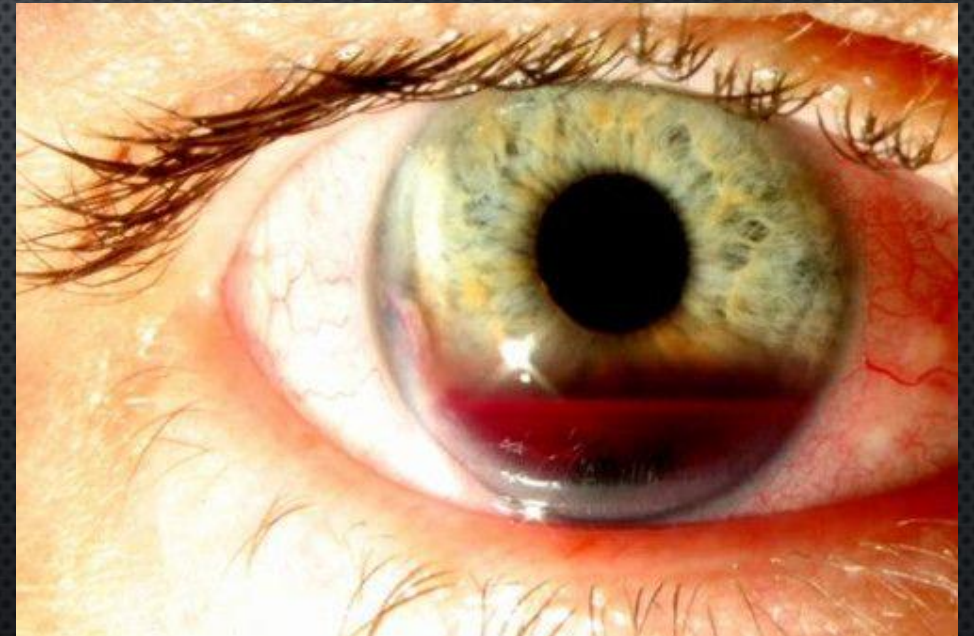SEEING RED: ANTERIOR CHAMBER **HYPHEMA**

- WHY'S THE RED?
 - BLEEDING FROM THE CILIARY MUSCLES, USUALLY AFTER TRAUMA
- HOW BAD IS IT?
 - CAN BE SPONTANEOUS/CONSIDER INR IF APPLICABLE

SEEING RED: ANTERIOR CHAMBER

HYPHEMA

- TREATMENT?
 - REST, AVOID HEAVY LIFTING
 - PT/INR
 - MAY REBLEED
 - OPHTHALMOLOGY REFERRAL

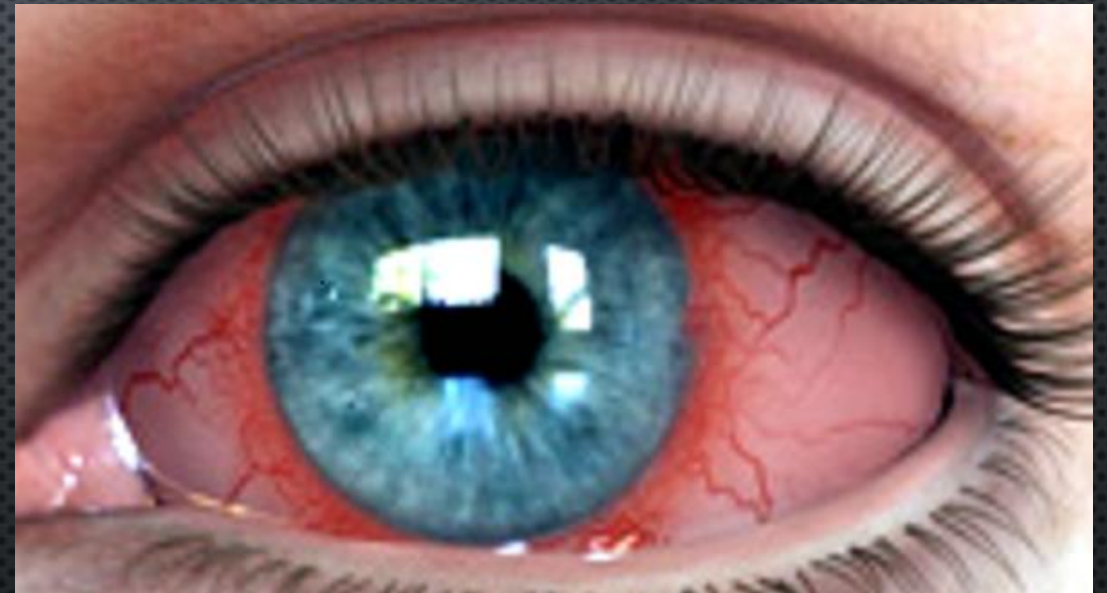

<https://i.pining.com/originals/7a/63/97/7a6397299fa64e1caf6f1cd1ac729854.jpg>

SEEING RED: MIDDLE EYE

ANTERIOR UVEITIS

- WHAT'S THE RED?
 - INFLAMMATION/INJECTION OF VESSELS SURROUNDING THE IRIS/LIMBUS
 - CILIARY SPASM: PAIN WITH DIRECT AND CONSENSUAL LIGHT



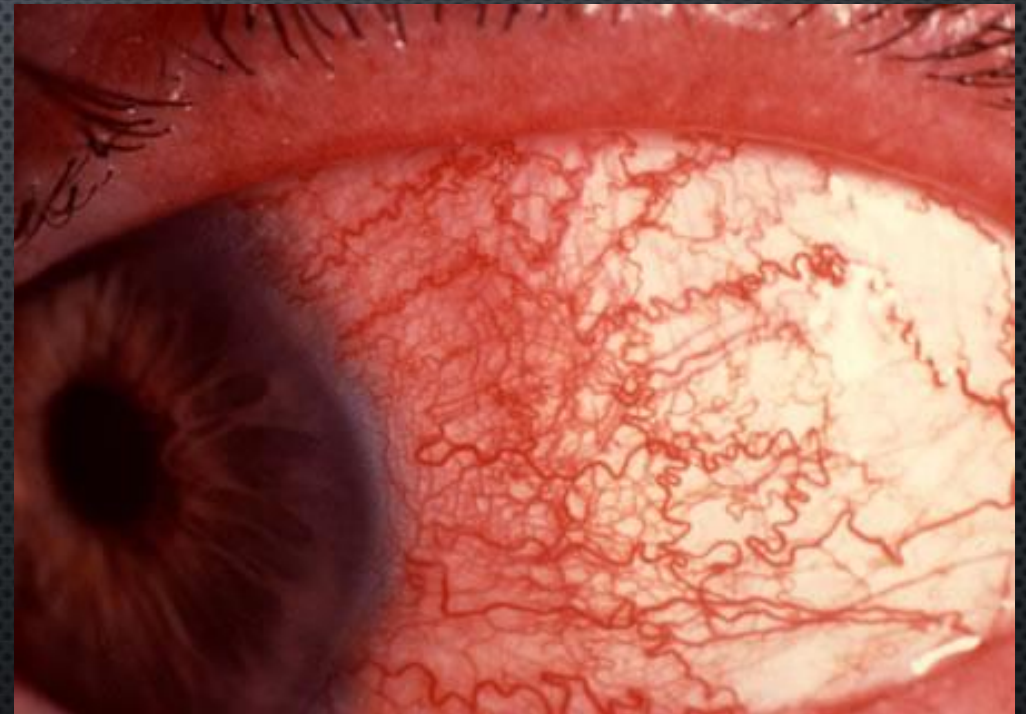
EXAM FINDINGS

<https://static1.squarespace.com>

SEEING RED: MIDDLE EYE

ANTERIOR UVEITIS

- REMEMBER THE ANATOMY!!
 - UVEA IS THE MIDDLE EYE, COMPRISED OF THE IRIS, CILIARY BODY AND CHOROID



SEEING RED: MIDDLE EYE

ANTERIOR UVEITIS

- WHY'S THE RED?
 - HOST OF PATHOLOGY, SOMETIMES IDIOPATHIC, MAY BE VIRAL
 - ALWAYS MUST CONSIDER OTHER ETIOLOGIES/AUTOIMMUNE (ANKYLOSING SPONDYLITIS, REITER'S SYNDROME, SARCOIDOSIS, RHEUMATOID ARTHRITIS, SLE)

SEEING RED: MIDDLE EYE

ANTERIOR UVEITIS

- HOW BAD IS IT?
 - MAY BE SELF-LIMITED
 - CONSIDER OTHER UNDERLYING SOURCE/IMPLICATIONS
- DIAGNOSIS/TREATMENT?
 - SUPPORTIVE, OPHTHALMOLOGIC REFERRAL
 - CONSIDER THE SOURCE: ANA, ESR, CRP

SEEING STRAIGHT

- SHOULD ANTICIPATE WIDE SPECTRUM OF RED EYES, PRESENTATIONS AND IMPLICATIONS
- CARE CAN BE SUCCESSFULLY MANAGED/INITIATED BY PHYSICIAN ASSISTANT IN ANY SETTING
- RED EYES LEAVE NO SURPRISE WHEN CONFIDENT IN OCULAR MEDICINE!

RESOURCES

**** IMAGES LABELED “EYEROUNDS.ORG,” UNIVERSITY OF IOWA, PRESENTED WITH PERMISSIONS FROM DR. THOMAS OETTING**

- ALLEGRINI, D., REPOSI, S., NOCERINO, E., PECE, A. ODONTOGENIC ORBITAL CELLULITIS ASSOCIATED WITH CAVERNOUS SINUS THROMOBOSIS AND PULMONARY EMBOLISM: A CASE REPORT. JOURNAL OF MEDICAL CASE REPORTS. 2017, 164-169.
- AZHER, TAYABA N., YIN XIAO-TAN, TAJFIROUS, DEENA, HUANG, ANDREW J. W., STUART, PATRICK. HERPES SIMPLEX KERATITIS: CHALLENGES IN DIAGNOSIS AND CLINICAL MANAGEMENT. CLINICAL OPHTHALMOLOGY. 2017, 185-191.
- DAVOUDI, SAMANAEH, HAVARRO-GOMEZ, DANIEL, SHEN, LISHUANG ET AL. NOD2 GENETIC VARIANTS AND SARCOIDOSIS-ASSOCIATED UVEITIS. AMERICAN JOURNAL OF OPHTHALMOLOGY CASE REPORTS. JUNE 2016, 39-42.
- KOCAK, ENIS D., WANG, BOB Z., HALL, ANTHONY J. BILATERAL UVEITIS FOLLOWING INTRAVENOUS IMMUNOGLOBULIN ADMINISTRATION. AMERICAN JOURNAL OF OPHTHALMOLOGY CASE REPORTS. MAR 2017, 74-76.
- PALIOURA, S, HENRY, AMESCUA, G, ALFONSO E. ROLE OF STEROIDS IN THE TREATMENT OF BACTERIAL KERATITIS. CLINICAL OPHTHALMOLOGY. JAN 2016, 179-186.

THANK-YOU!!

- TARA MCSWIGAN, MPAS, PA-C
- MCSWIGAN1977@GMAIL.COM