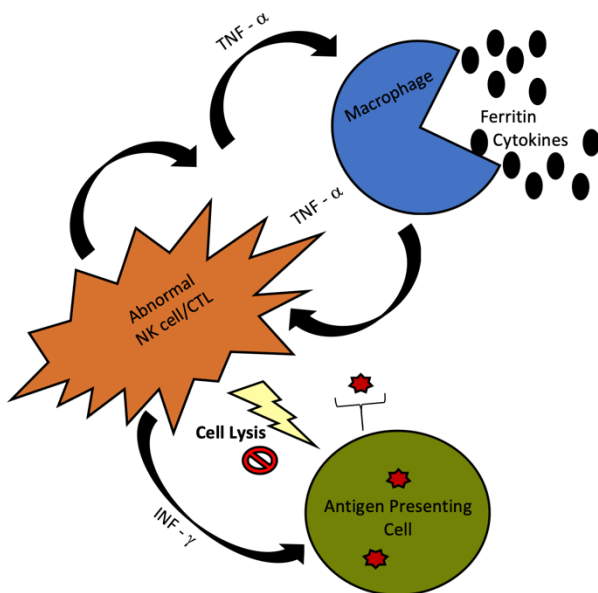


# Acquired Hemophagocytic Lymphohistiocytosis

Simone Toft Jensen, PA-C

## Introduction

Hemophagocytic Lymphohistiocytosis (HLH) is a rare, life-threatening disorder of abnormal immune activation, thought to be caused by lack of normal down regulation by natural killer (NK) cells and/or cytotoxic lymphocytes (CTLs) that result in excessive macrophage activity [1]. This persistent activation of macrophages and other immune cells leads to hemophagocytosis and excessive cytokine production [1]. HLH can be characterized as primary/familial (FHLH) or secondary/acquired (SHLH). HLH is associated with genetic defects and/or environmental causes such as infections, rheumatologic diseases, and malignancies. It is more commonly seen in children, but the incidence of adult HLH is increasing [2]. The prognosis of HLH is very poor, and without treatment, adults with acquired HLH have a median survival of days to weeks [2].



## Case

A 51-year-old female with history of chronic systolic heart failure secondary to sarcoid cardiomyopathy with an ejection fraction of 21% (currently on daily prednisone) presented to the hospital with chills and generalized weakness since her recent admission 4 days prior. In the emergency department, she was hypotensive, but fluid responsive. Her laboratory studies were notable for acute kidney injury (Cr1.5 with baseline 1.0), rising transaminases (AST287, ALT231, AlkPhos244), worsening leukopenia (3.1), and stable thrombocytopenia (104). A CT abdomen showed splenomegaly. She was admitted to the hospital and the next day she spiked a fever to 38.5 Celsius associated with worsening pancytopenia (Hgb9.9, Plt84, WBC1.8) and an elevated LDH (498). She was empirically started on IV Zosyn and had an infectious workup. Her rising transaminases were initially thought to be due to amiodarone (stopped during previous admission) or azathioprine (discontinued this admission).

## Results

On the second day of admission, she was transferred to the ICU due to worsening hypotension and was subsequently initiated on vasopressors for vasodilatory shock, of uncertain etiology. At this time, she met 4/8 of the criteria for Hemophagocytic Lymphohistiocytosis (HLH) (fever, splenomegaly, hypofibrinogenemia<150 while inflamed, and ferritin>500) and solIL-2R/CD25 and biopsies were pending. She was started on dexamethasone 20mg daily for HLH protocol, while awaiting results. Infectious disease felt that the association of HLH secondary to sarcoidosis was uncommon, and although she did not have lymphadenopathy on exam, CT or PET scan, further infectious workup was indicated. Of note, her cytomegalovirus (CMV) PCR returned positive and she was started on IV ganciclovir. Five days after admission, her bone marrow biopsy revealed evidence of hemophagocytosis, her liver biopsy revealed presence of CMV and hemophagocytosis, and therefore, she had met the 5/8 criteria for HLH. Rheumatology was consulted to further explore additional causes of HLH and her creatinine kinase as well as lupus and vasculitis serologies returned negative. It was ultimately determined that her HLH was most likely secondary to CMV viremia.

Met 6/8 criteria for diagnosis of HLH

1. **Fever**  $\geq 38.5$
2. **Splenomegaly**
3. **2+ Cytopenias**
4. **Hypertriglyceridemia &/or hypofibrinogenemia**
5. **Hemophagocytosis in BM, spleen, LN, or liver**
6. Low or absent NK cell activity
7. **Ferritin**  $>500$
8. Elevated soluble CD25

## Discussion

Hemophagocytic Lymphohistiocytosis (HLH) typically presents as a vague febrile illness, making it difficult to differentiate from common infections. It is diagnosed by a gene mutation or fulfilling 5/8 diagnostic criteria (mentioned above). Acquired HLH may respond to treatment of the trigger, and therefore infections should be rapidly diagnosed and treated. HLH-94 protocol (etoposide and dexamethasone) is indicated for severely ill patients and has shown 5-year survival in over 50% of patients [3]. In critical patients, treatment should not be delayed and in some it is possible to begin corticosteroids and observe response prior to initiating chemotherapy [3]. The patient was empirically treated by HLH-94 protocol with dexamethasone as well as covered empirically for suspected infections. After the source was determined to be CMV, treatment was tailored. This case uniquely identifies important aspects of rapid diagnosis and empiric treatment in patients with HLH.

## References

1. Filipovich A, McClain K, Grom A. Histiocytic disorders: recent insights into pathophysiology and practical guidelines. *Biol Blood Marrow Transplant.* 2010 Jan;16(1 Suppl):S82-9. doi: 10.1016/j.bbmt.2009.11.014. Epub 2009 Nov 22. PMID: 19932759.
2. Ramos-Casals M, Brito-Zerón P, López-Guillermo A, Khamashta MA, Bosch X. Adult haemophagocytic syndrome. *Lancet.* 2014 Apr 26;383(9927):1503-1516. doi: 10.1016/S0140-6736(13)61048-X. Epub 2013 Nov 27. Erratum in: *Lancet.* 2014 Apr 26;383(9927):1464. PMID: 24290661.
3. Trottestam H, Home A, Aricó M, Egeler RM, Filipovich AH, Gadner H, Imashuku S, Ladisch S, Webb D, Janka G, Henter JI; Histiocyte Society. Chemoimmunotherapy for hemophagocytic lymphohistiocytosis: long-term results of the HLH-94 treatment protocol. *Blood.* 2011 Oct 27;118(17):4577-84. doi: 10.1182/blood-2011-06-356261. Epub 2011 Sep 6. PMID: 21900192; PMCID: 3242222.