

Unusual cause of diabetes: a case study

Vasiloff J and Bowlby M

Division of PA Practice, College of Health Sciences and Professions, Ohio University

Background

While most cases of diabetes are type 1 or type 2, there are other, less common varieties. These are sometimes referred to as “secondary causes of diabetes,” many of which are rare. Some of the more common causes include cases associated with: a) pregnancy (gestational); b) diseases of the pancreas, such as chronic pancreatitis and cystic fibrosis; c) drugs or toxins, such as therapeutic glucocorticoids; and d) other endocrinopathies, including pheochromocytoma, acromegaly, and Cushing’s syndrome.

We report a case of what appeared to be typical type 2 diabetes--until the later appearance of unusual features. At that time, the patient was evaluated for secondary causes of diabetes.

Description of a Case

A 49 year old man with a 10 year history of type 2 diabetes complained of a year-long history of progressive proximal muscle weakness and crippling fatigue. Past medical history was positive for a deep venous thrombosis and a separate left ulnar arterial thrombosis--both thought to be secondary to Factor V Leiden. He also had a history of hypertension, a hip fracture with minimal trauma, and idiopathic vascular calcification. Medications included: aspirin, apixaban, amlodipine, candesartan, metformin, sitagliptin, and atorvastatin. Family history was positive for Factor V Leiden and type 2 diabetes. There was no history of smoking or drugs.

Physical Examination and Routine Laboratory

He appeared fatigued. Height was 71 inches; weight was 186lbs. T 36.9, P 88, R 12, BP 110/64. Abnormal findings included: mild facial plethora; supraclavicular fat pads; thin skin; thin extremities; central obesity; pink abdominal striae; bilateral proximal muscle strength 4/5, and left hand strength 3/5.

Complete blood count was normal except for mild neutrophilia, which was not new. Complete metabolic panel was normal. Free t4 and TSH were both normal. Urinalysis was normal except for the presence of glucose. HbA1c was 6.7%.

Endocrine Evaluation

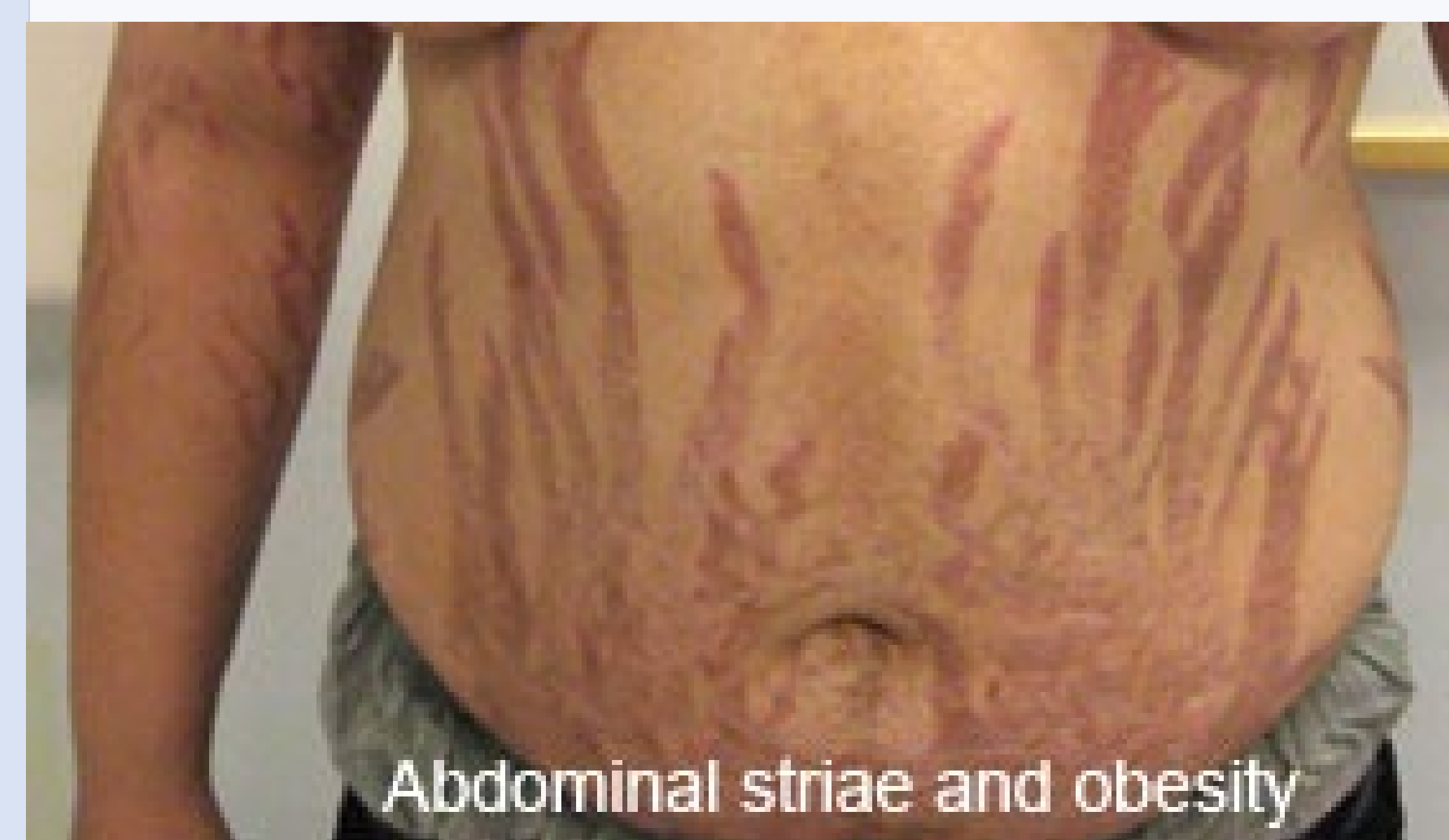
He was suspected of having Cushing's syndrome and underwent evaluation:

- 24 hour urine free cortisol was 86 mcg (nl < 45)
- Salivary cortisol at 11 pm was 518 ng/dl (nl < 100)
- Low-dose overnight dexamethasone test revealed failure to suppress morning plasma cortisol, which was 19.85 mcg/dl (nl < 1.8)
- Plasma ACTH was 169 pg/ml (nl < 63)

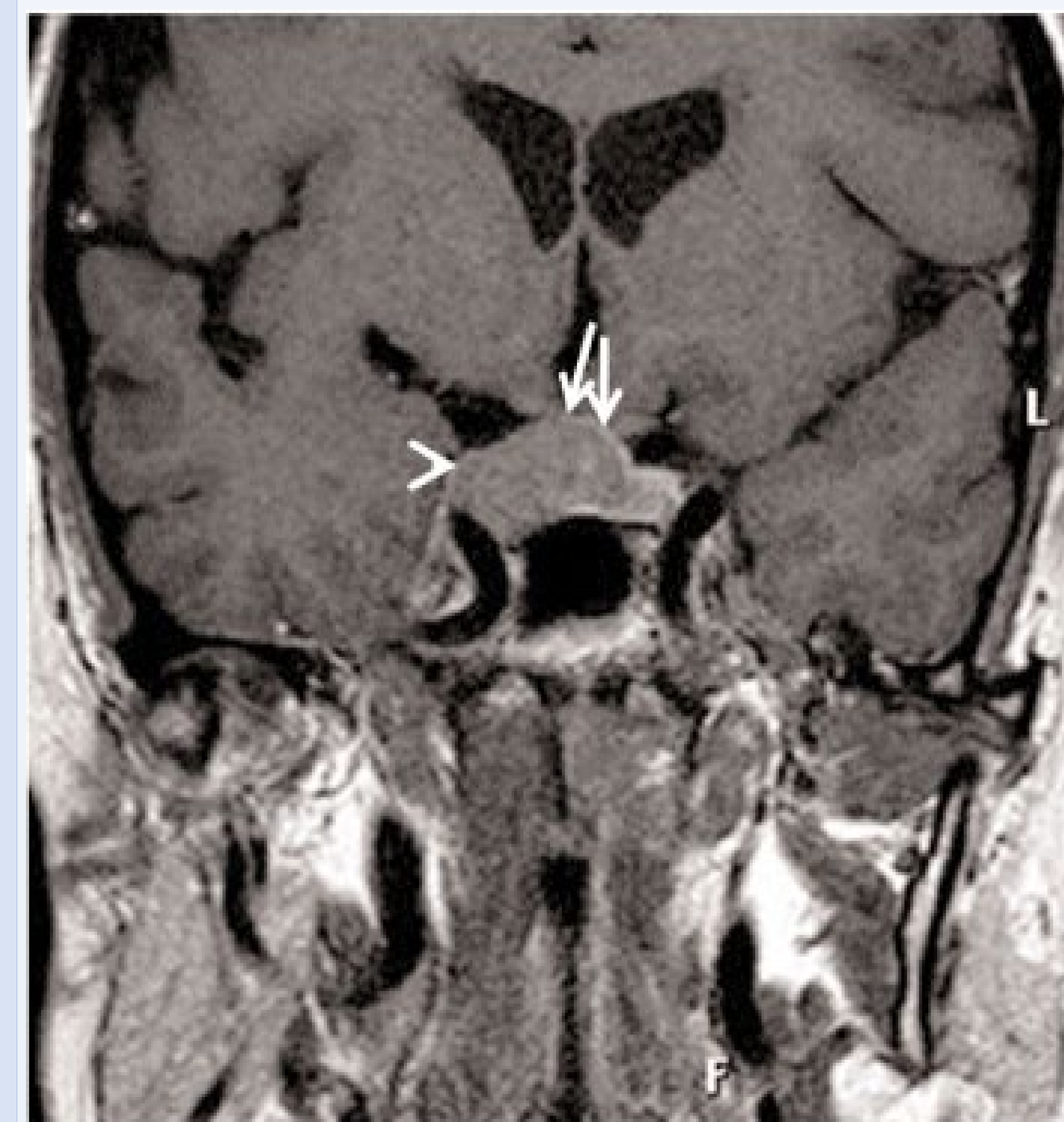
Many endocrine labs were normal:

- Prolactin
- Insulin-like growth factor (IGF) 1
- Luteinizing hormone (LH)
- Follicle stimulation hormone (FSH)
- Total testosterone

Example of pigmented abdominal striae



Example of pituitary macroadenoma



Imaging and Surgery

MRI of pituitary with gadolinium contrast revealed an 11 X 6 mm sellar mass. Surgery was postponed due to Covid 19, but did occur 3 months after diagnosis. The mass was resected by endoscopic endonasal transsphenoidal hypophysectomy. Pathological examination revealed a 1.1 cm corticotroph-type pituitary adenoma, which stained positive for radiolabeled ACTH. Thus, the pituitary was confirmed as the source of autonomous ACTH secretion.

Final Disposition

After surgery, plasma cortisol fell from >20 mcg/dl to 4.2. In addition, 3-5 months later, HbA1c dropped from 6.7% to 5.6, and weight dropped from 186 lbs to 151.

Cushing's syndrome occurs due to glucocorticoid treatment (iatrogenic), pituitary tumor, adrenal tumor, or ectopic secretion of ACTH. In pituitary Cushing's, excess ACTH over-stimulates adrenal secretion of cortisol. High cortisol, in turn, antagonizes insulin, and can cause diabetes. In this case, it is unknown whether Cushing's supervened in a patient with diabetes, or whether Cushing's alone was present from the beginning. While it is expected for type 2 diabetes to progress with time, it is paramount for clinicians to consider concurrent or other etiologies when atypical clinical features appear. In this case, treatment of Cushing's led to marked improvement in diabetes.