

Background

- Craniosynostosis is a rare condition characterized by cranial deformities that occur secondary to premature fusion of the cranial sutures
- Some procedures, such as endoscopic strip craniectomy with post-operative helmeting, are time sensitive as their efficacy wanes as the calvarium becomes more rigid with age. Generally, this procedure is performed prior to 6 months of age.
- Should patients not undergo this procedure by 6 months of age, they will require surgical correction using more invasive techniques to correct their deformity.
- The purpose of this study is to identify risk factors for delayed presentation to craniofacial clinics that would obviate certain surgical options for patients.

Methods

- Retrospective chart review was performed
 - Study Period: November 2011-September 2018
 - Inclusion: Patients with non-syndromic craniosynostosis who were surgically naïve
 - Exclusion: Patients with a diagnosis of a craniosynostosis-associated syndrome
- Patients were stratified into delayed and non-delayed presentation cohorts and comparative analysis was performed.
 - Delayed Presentation: ≥ 6 months-of-age
- Variables analyzed included were related to patient/family demographics, family structure, adoption status, health insurance, and past medical history

Results

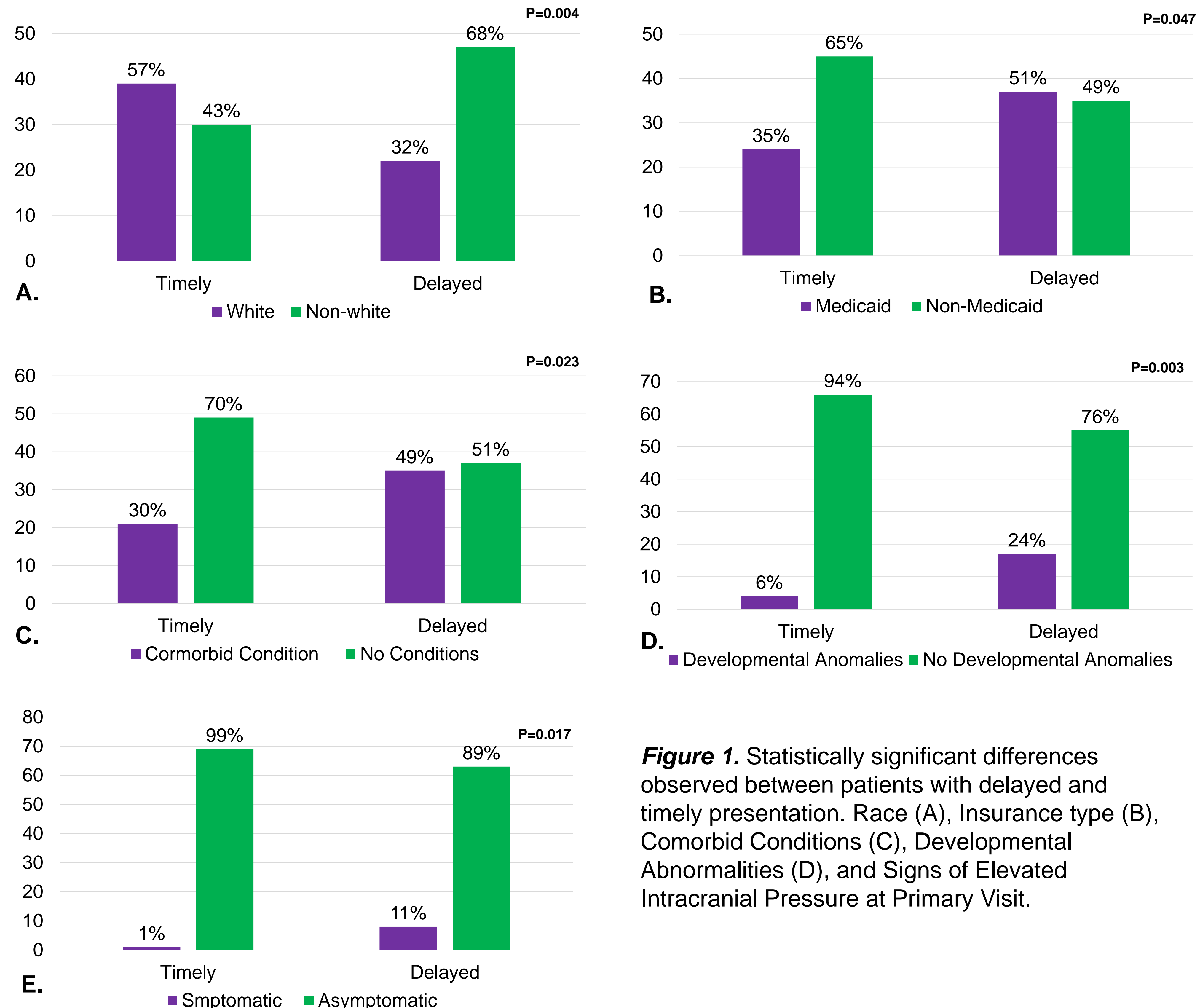


Figure 1. Statistically significant differences observed between patients with delayed and timely presentation. Race (A), Insurance type (B), Comorbid Conditions (C), Developmental Abnormalities (D), and Signs of Elevated Intracranial Pressure at Primary Visit.

Results cont.

- 208 patients were identified on chart review with 142 (68%) meeting our inclusion criteria.
- Sex, language, income, location, family makeup, being the first born, type of referring provider, and undergoing pre-appointment imaging were not associated with delayed presentation.

Discussion

- Delayed presentation of patients with non-syndromic craniosynostosis occurs frequently with minority patients. Additionally, patients with Medicaid insurance coverage are particularly at risk.
- Lack of timely care in delayed patients may explain the higher frequency in comorbid conditions and neurologic sequelae
- More studies are needed to explain why certain patient demographics are particularly at risk for presenting in delayed fashion and to develop strategies to improve outreach to these patients

References

1. Dempsey RF, Monson LA, Maricevich RS, et al. Nonsyndromic Craniosynostosis. Clin Plast Surg. 2019;46(2):123-139. doi:10.1016/j.cps.2018.11.001
2. Tuite GF, Chong WK, Evanson J, et al. The effectiveness of papilledema as an indicator of raised intracranial pressure in children with craniosynostosis. Neurosurgery. 1996. doi:10.1097/00006123-199602000-00009
3. Braun TL, Eisemann BS, Olorunnipa O, Buchanan EP, Monson LA. Safety outcomes in endoscopic versus open repair of metopic craniosynostosis. J Craniofac Surg. 2018;29(4):856-860. doi:10.1097/SCS.00000000000004299
4. Barone CM, Jimenez DF. Endoscopic craniectomy for early correction of craniosynostosis. Plast Reconstr Surg. 1999;104(7):1965-1973. doi:10.1097/00006534-199912000-00003