

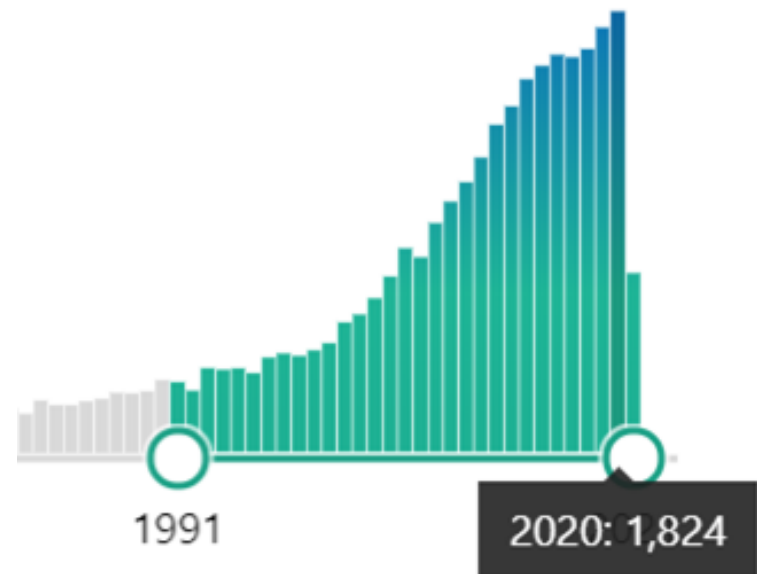
A woman with long hair is sitting on a wooden bench outdoors. She is wearing a black long-sleeved athletic top and black shorts. Her right knee is wrapped in a black and orange brace with the brand name 'TRIPOLI' visible. She is holding a white water bottle in her right hand. An orange basketball is resting on the bench next to her. The background is a blurred outdoor setting with a blue sky.

Cartilage Restoration in 2021

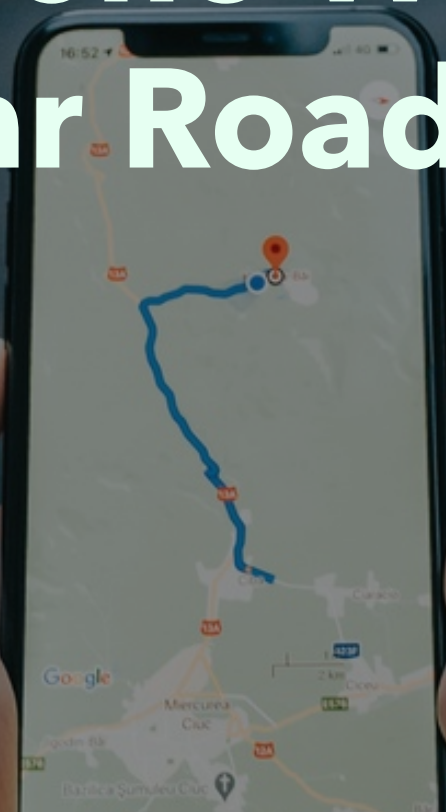
Jonathan C. Riboh, MD
Orthocarolina / Atrium Health MSKI
May 22nd 2021

Preface:

There's No Way To Master The Literature in 30 Minutes



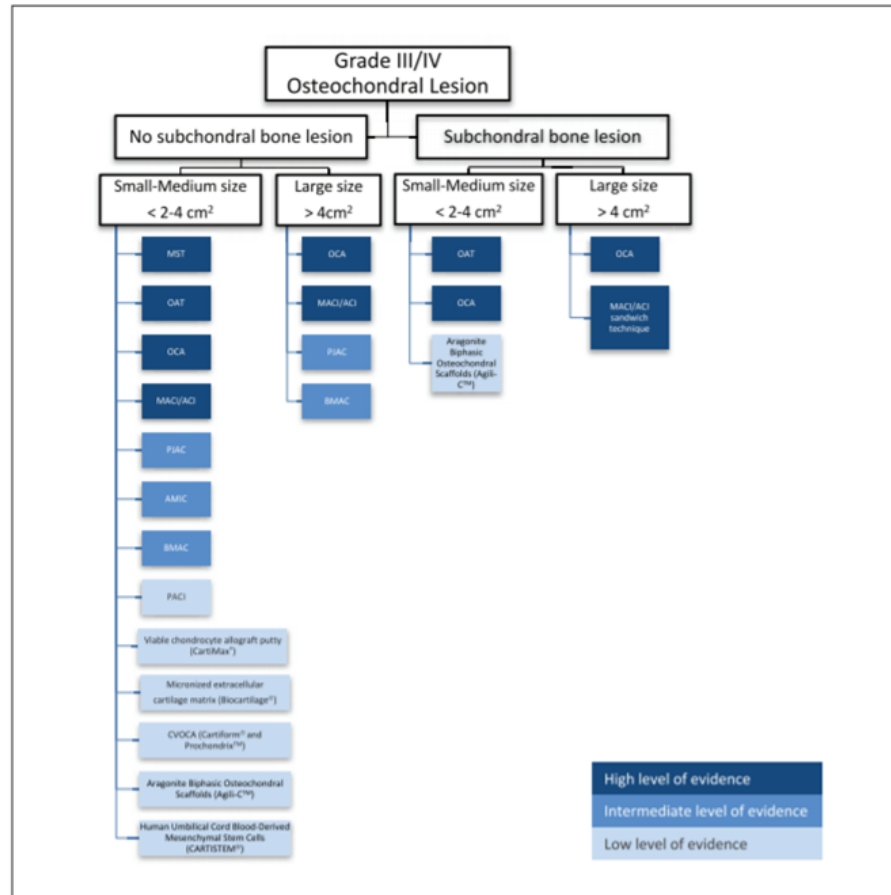
Everyone Wants A Linear Road Map!



Algorithm for Treatment of Focal Cartilage Defects of the Knee: Classic and New Procedures

Betina B. Hinckel¹, Dimitri Thomas², Evan E. Vellios³, Kyle John Hancock⁴, Jacob G. Calcei⁵, Seth L. Sherman⁶, Claire D. Eliasberg⁷, Tiago L. Fernandes⁸, Jack Farr⁹, Christian Lattermann¹⁰, and Andreas H. Gomoll¹

CARTILAGE
1-23
© The Author(s) 2021
Article reuse guidelines:
sagepub.com/journalsPermissions
DOI: 10.1177/19476035211993219
journals.sagepub.com/home/CAR
SAGE



Abstract

Objective. To create a treatment algorithm for focal grade 3 or 4 cartilage defects of the knee using both classic and novel cartilage restoration techniques. **Design.** A comprehensive review of the literature was performed highlighting classic as well as novel cartilage restoration techniques supported by clinical and/or basic science research and currently being employed by orthopedic surgeons. **Results.** There is a high level of evidence to support the treatment of small to medium size lesions (<2.4 cm²) without subchondral bone involvement with traditional techniques such as marrow stimulation, osteochondral autograft transplant (OAT), or osteochondral allograft transplant (OCA). Newer techniques such as autologous matrix-induced chondrogenesis and bone marrow aspirate concentrate implantation have also been shown to be effective in select studies. If subchondral bone loss is present OAT or OCA should be performed. For large lesions (>4 cm²), OCA or matrix autologous chondrocyte implantation (MACI) may be performed. OCA is preferred over MACI in the setting of subchondral bone involvement while cell-based modalities such as MACI or particulated juvenile allograft cartilage are preferred in the patellofemoral joint. **Conclusions.** Numerous techniques exist for the orthopedic surgeon treating focal cartilage defects of the knee. Treatment strategies should be based on lesion size, lesion location, subchondral bone involvement, and the level of evidence supporting each technique in the literature.

Keywords

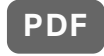articular cartilage, cartilage repair, cartilage transplantation

Introduction

Cartilage surgery is indicated in patients with symptomatic defects, with the short-term goal of improvements in pain and function, and the long-term hope of delaying the need for arthroplasty.¹ While focal cartilage defects are common and may be present in as much as 63% of the general population and 36% of athletes, the majority are not symptomatic.^{2,3} Larger defects, however, can become problematic, especially in young patients who hope to maintain a physically active lifestyle without debilitating pain. Cartilage defects may also lead to accelerated wear, worsening pain, and potential arthritis progression. For example, competitive athletes (high school or collegiate) may be at increased risk of high-grade multicompart or anterior compartment defects in comparison to recreational athletes.⁴ The high prevalence and high cost of chondral disease, which ranges from small focal defects to end-stage osteoarthritis, has significant financial implications for the health care

¹Department of Orthopedic Surgery, William Beaumont Hospital, Taylor, MI, USA
²UNC Orthopedics and Sports Medicine at Lenoir, Kinston, NC, USA
³Sports Medicine and Shoulder Surgeon Southern California Orthopedic Institute (SCOI), Van Nuys, CA, USA
⁴Desert Orthopaedic Center, Las Vegas, NV, USA
⁵Department of Orthopaedic Surgery, University Hospitals of Cleveland, Case Western Reserve University, Cleveland, OH, USA
⁶Division of Sports Medicine, Department of Orthopedic Surgery, School of Medicine, Stanford University, Palo Alto, CA, USA
⁷Hospital for Special Surgery, New York, NY, USA
⁸University of São Paulo, Institute of Orthopedics and Traumatology, Sports Medicine-FIFA, São Paulo, SP, Brazil
⁹OrthoIndy Knee Preservation and Cartilage Restoration Center, School of Medicine, Indiana University, Indianapolis, IN, USA
¹⁰Division of Sports Medicine, Department of Orthopedic Surgery, Brigham and Women's Hospital, Boston, MA, USA

Corresponding Author: Betina B. Hinckel, Department of Orthopedic Surgery, William Beaumont Hospital, 10000 Telegraph Road, Suite 100, Taylor, MI 48180, USA. Email: betinahinckel@mc.com



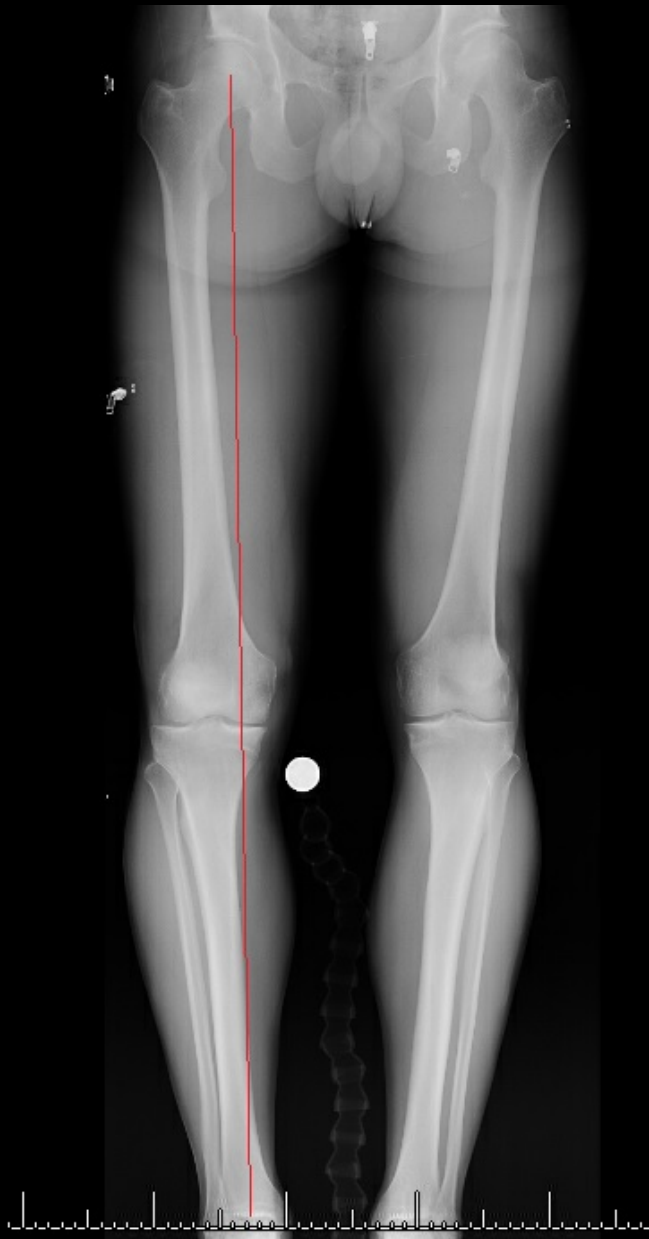An aerial photograph of a winding asphalt road that snakes through a dense, lush green forest. The road has several sharp curves and is populated with several cars. The text "But Decision Making Is Not Linear" is overlaid in the center of the image in a large, white, sans-serif font.

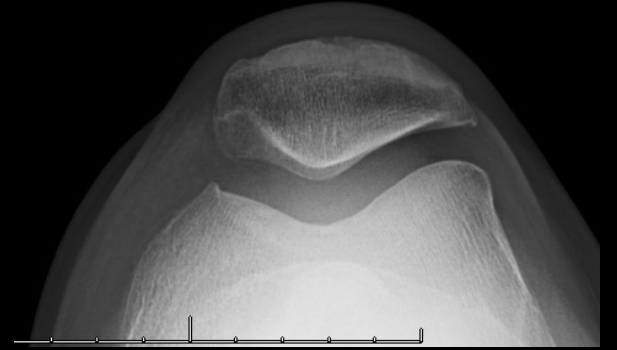
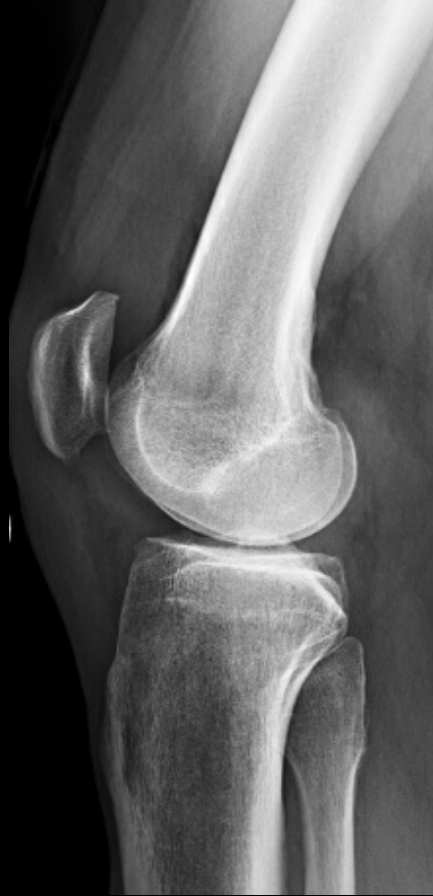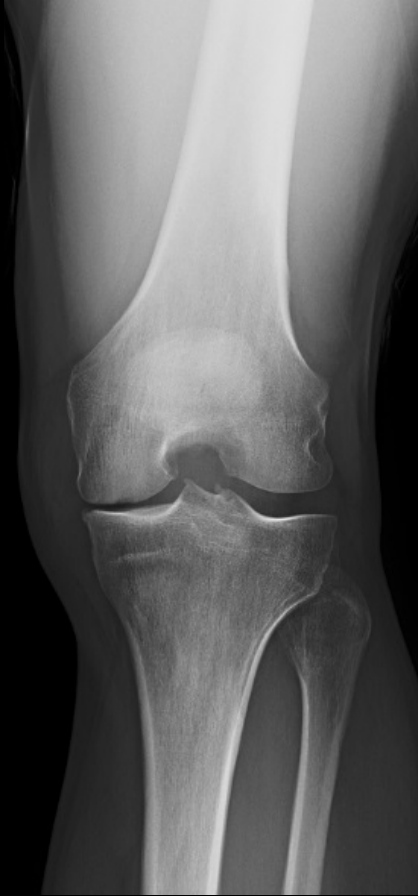**But Decision Making Is
Not Linear**

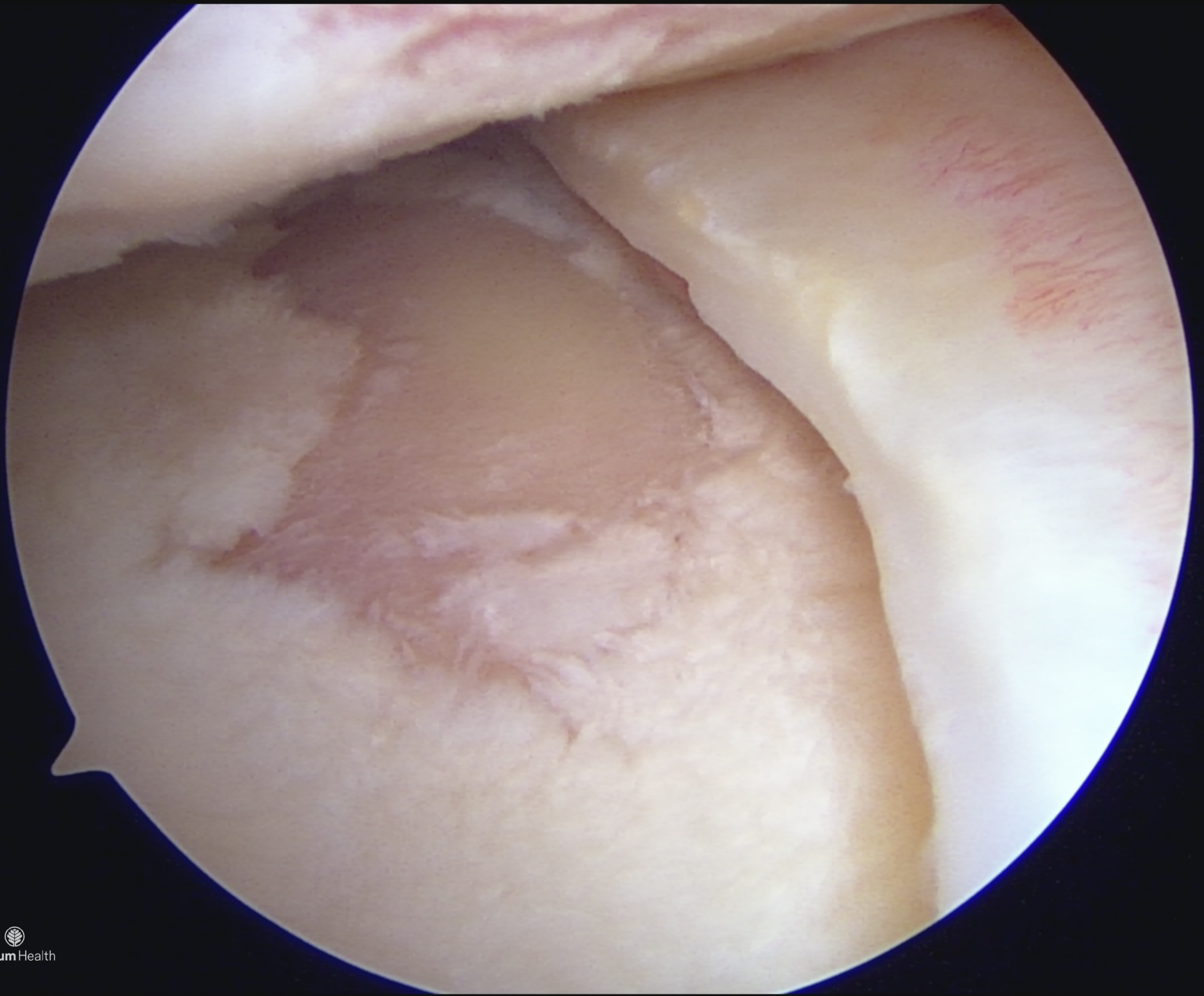
- **47 yo M** with disabling right knee pain
- Retired military
- Extremely active, plays soccer 3-4 times per week
- BMI 24
- No medical issues, non-smoker
- Goal is to return to soccer if possible

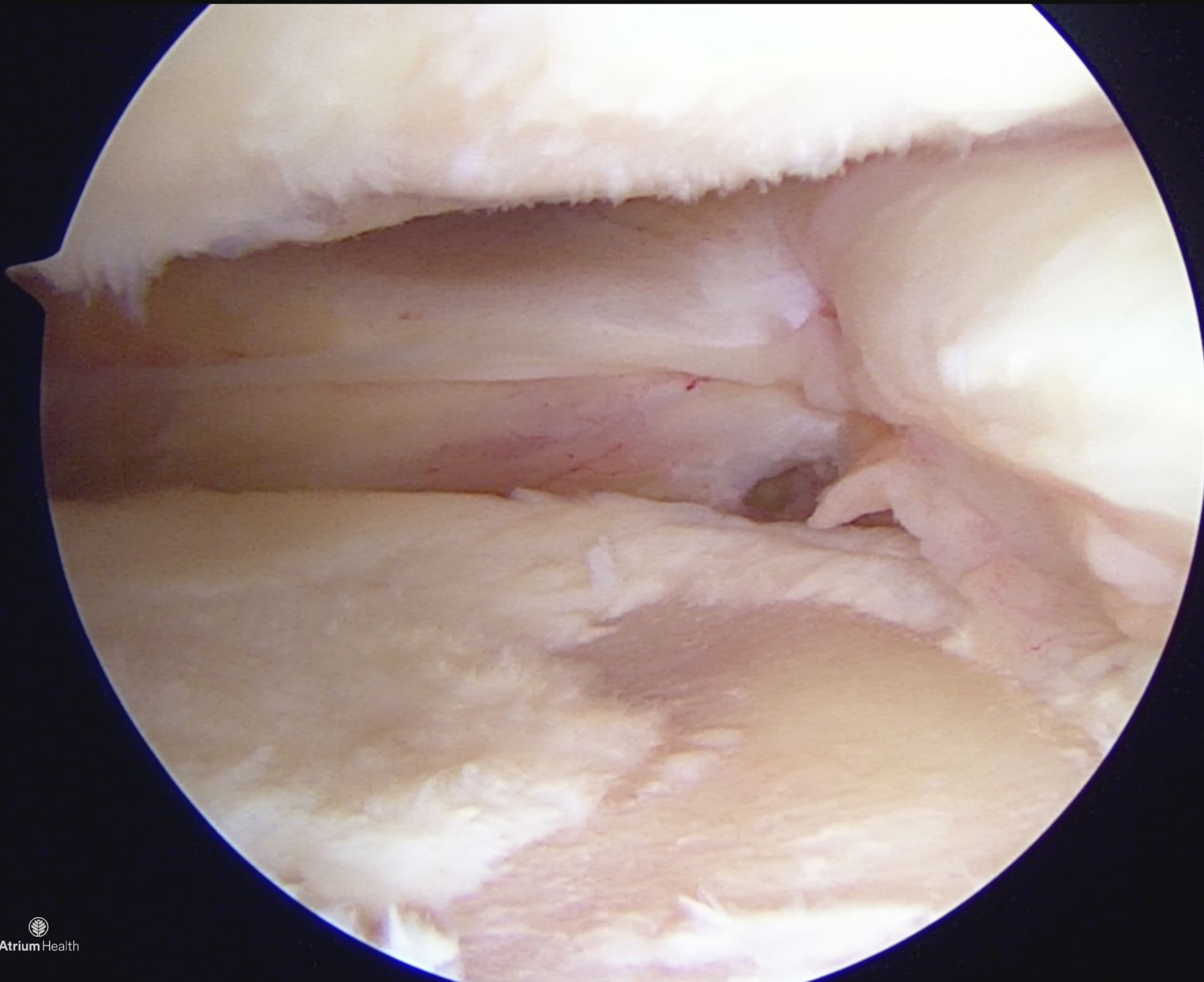


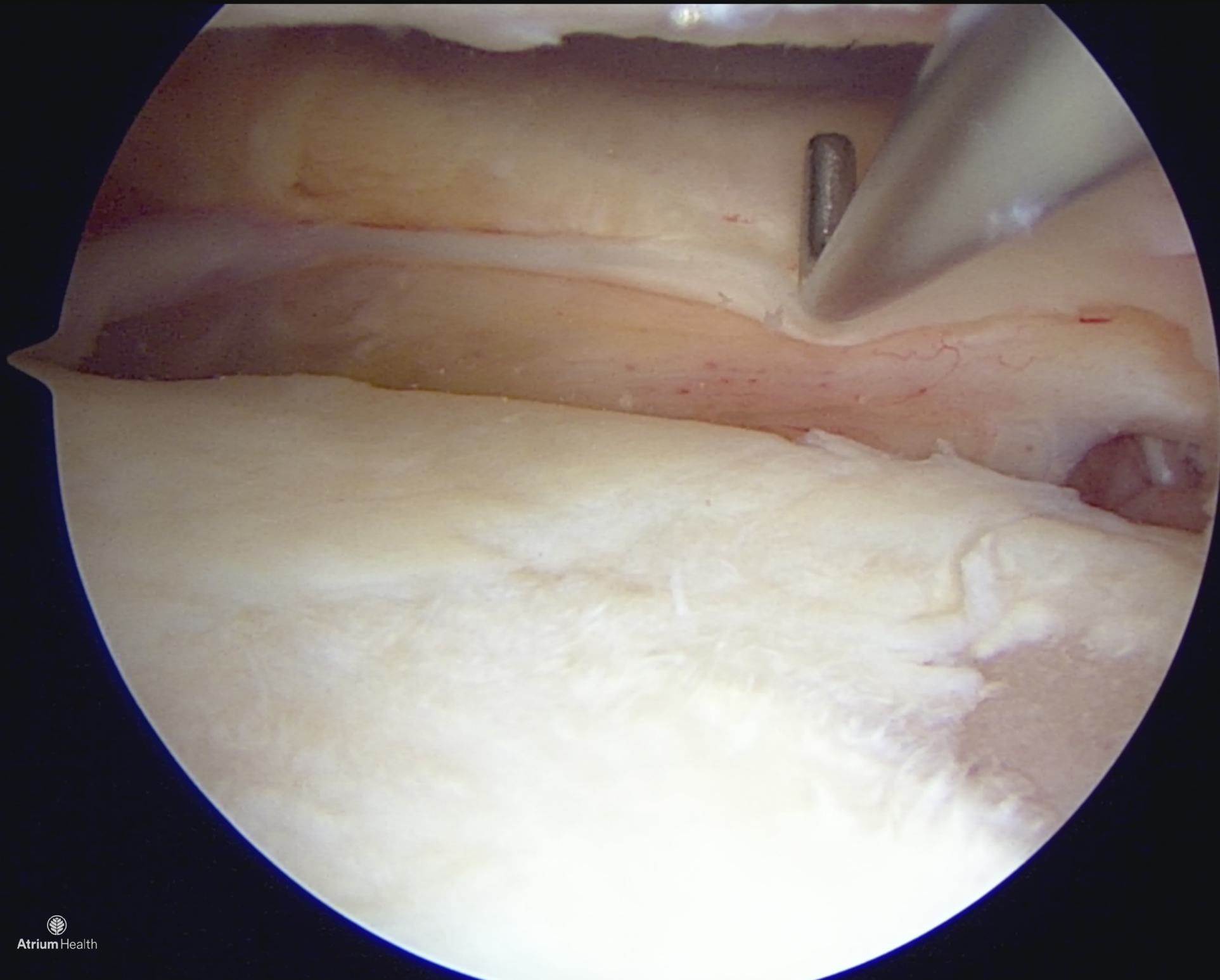
- **Right knee arthroscopy June 2020 @ Novant:** Partial medial meniscectomy for radial tear of the body
- No improvement with surgery
- Had **CSI** and **SynviscOne** @ Novant over the summer
- I treated him with **medial unloader brace** for 8 weeks with partial improvement of his symptoms
- Staging arthroscopy 12/4/2020

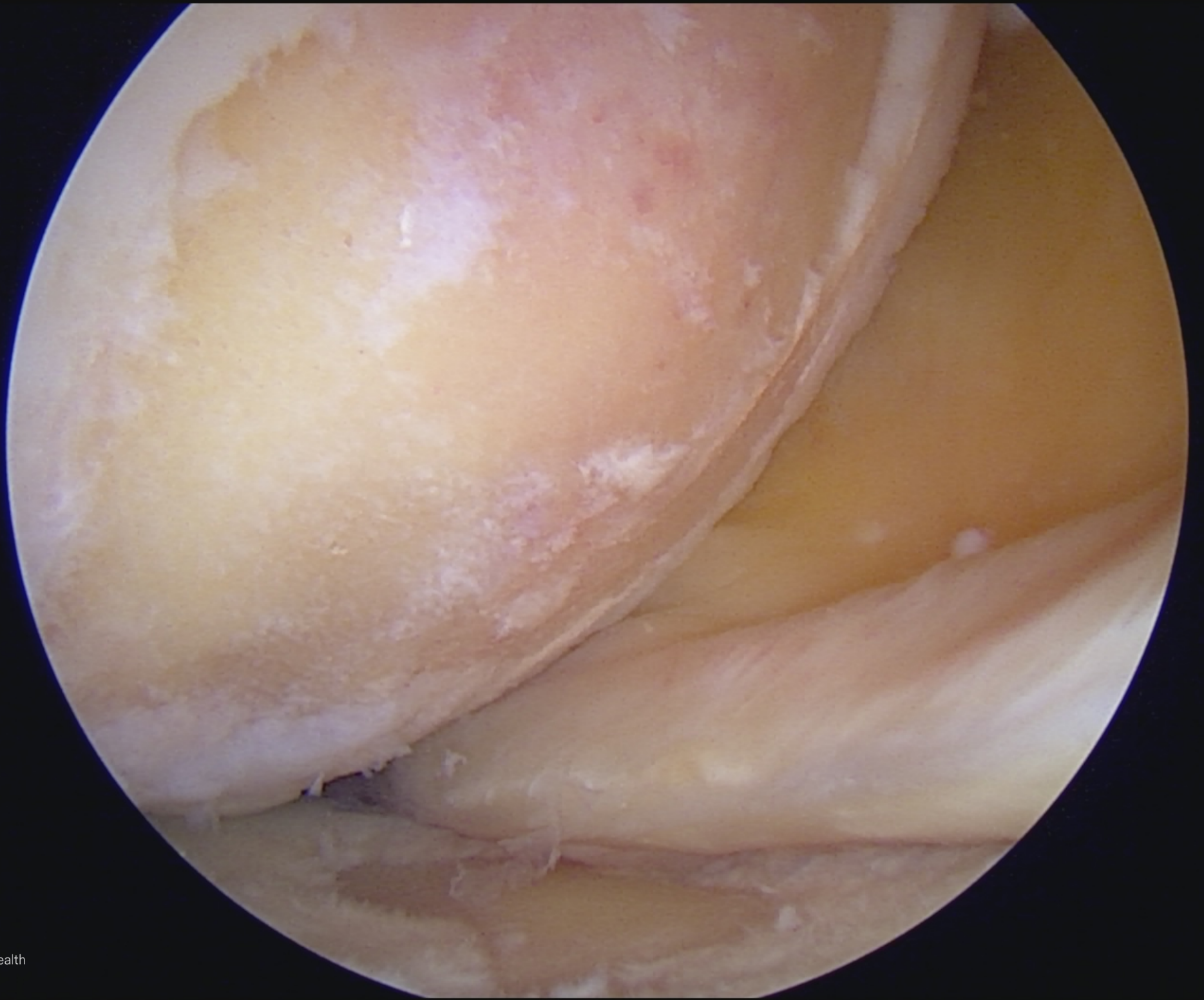


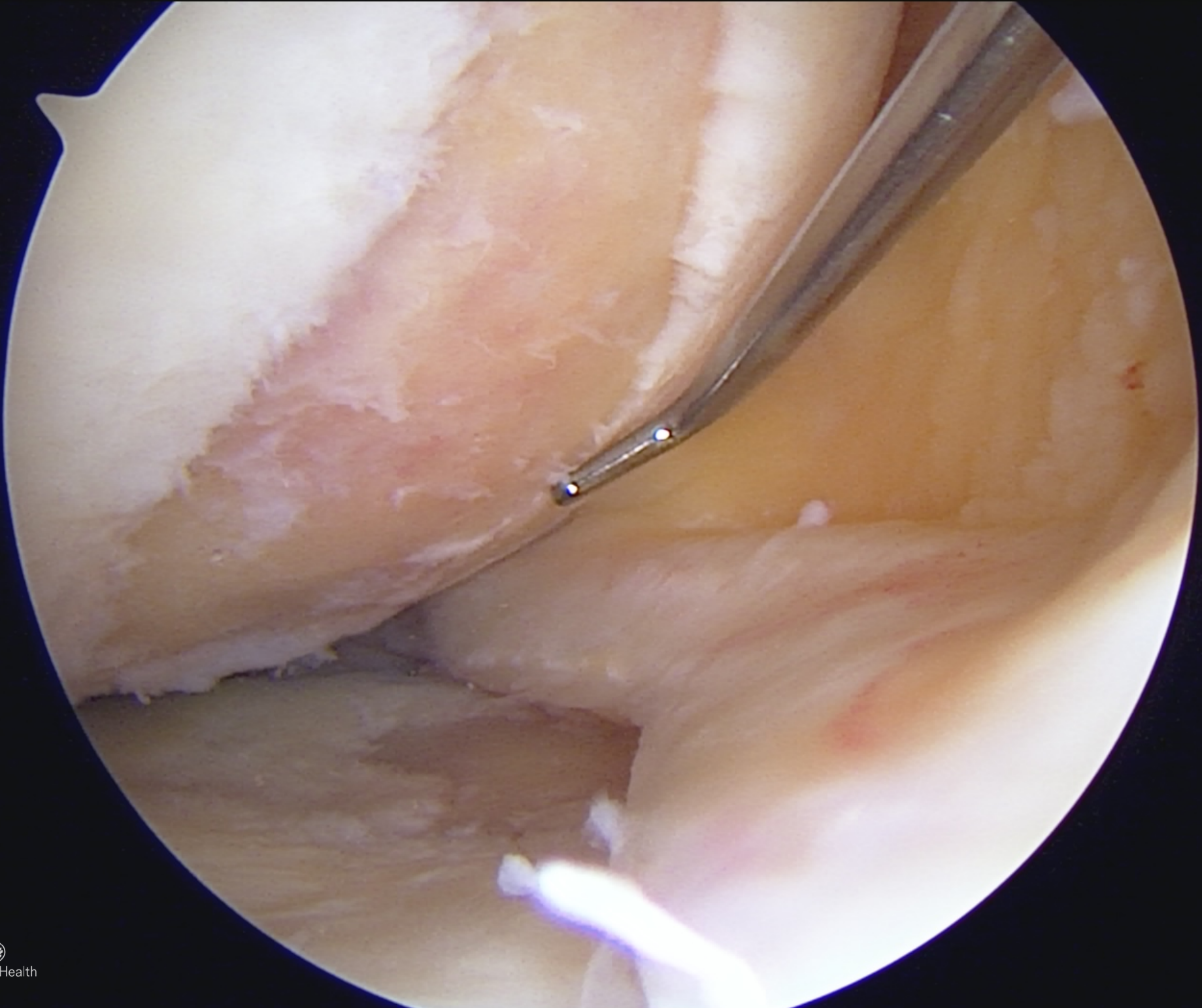












Acceptable Treatments For This Patient?

1. Skillful Neglect
2. Biologic Injection
3. Cortisone Injection
4. Unloader Brace
5. HTO alone
6. HTO + OCA
7. HTO + OCA + MAT
8. UKA



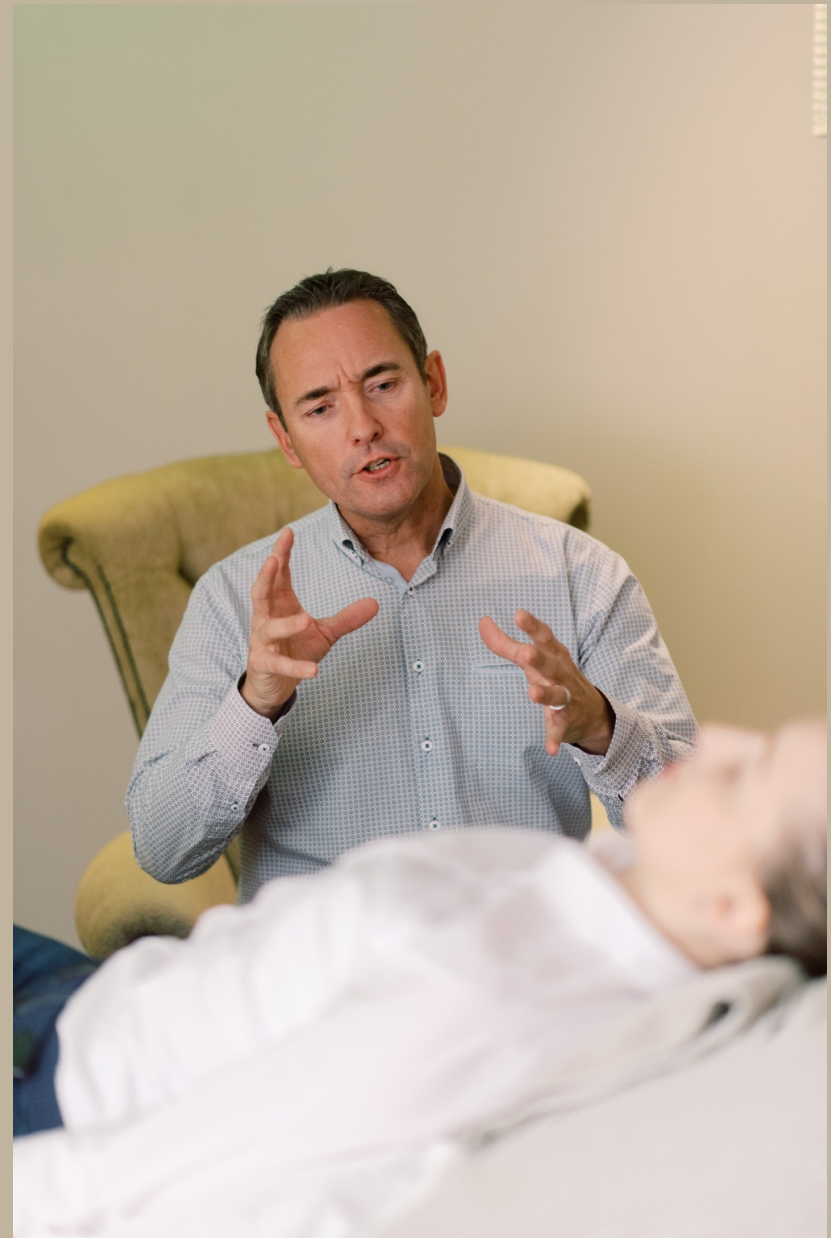Factors Influencing Decision Making

1. Symptoms
2. Cartilage Injury Size
3. Alignment
4. Meniscus Status
5. Subchondral Bone Status
6. Ligament Injury
7. Age
8. Goals
9. Sports Specific Concerns / Timing / Contracts



Dependence Upon MRI is Not Justified

- MRI can grossly over or under estimate the extent of cartilage disease
- MRI appearance does not correlate well with clinical severity
- Many asymptomatic patients and athletes have abnormal cartilage findings on MRI --> lots of false positives (40 - 80%).
- *Often corners us into explaining to patients why we're "not doing anything about their cartilage injury"*



OUTCOME OF UNTREATED TRAUMATIC ARTICULAR CARTILAGE DEFECTS OF THE KNEE

A NATURAL HISTORY STUDY

BY K. DONALD SHELBOURNE, MD, SANJIV JARI, BSC(HONS), MBChB,
FRCS(ENG), FRCS(TR & ORTH), AND TINKER GRAY, MA, ELS

Skillful Neglect Is An Acceptable Form of Treatment

Background: Articular cartilage damage has been reported in 23% of knees with an acute anterior cruciate ligament (ACL) injury and 54% of those with chronic ACL laxity. Because the purpose of surgery is to reconstruct the ACL, the chondral lesion is usually an incidental finding. It is not known if any of the numerous treatments that have been recommended for chondral defects alters the natural history of the untreated lesion. We sought to determine what effect, if any, an isolated articular cartilage defect observed at the time of ACL reconstruction would have on the radiographic, subjective, and objective results after surgery if no intervention was performed on the cartilage lesion itself.

Methods: From 1987 to 1999, 2770 ACL reconstructions were performed, and 125 of them were done in patients who had an articular cartilage defect of Outerbridge grade 3 or 4 but had both menisci intact. The mean defect size was 1.7 cm² (range, 0.5 to 6.5 cm²). Postoperative rehabilitation was not altered because of the chondral defect, and patients were allowed full weight-bearing and the full range of motion of which they were capable. A control group of patients matched on the basis of sex and age at surgery was identified from the database. No patient in the control group had a chondral defect or meniscal tear. Patients were evaluated at one, two, and five years after surgery and every five years thereafter with use of the IKDC (International Knee Documentation Committee) criteria, modified Noyes subjective questionnaire, and radiographs.

Results: Subjective follow-up was carried out more than two years after surgery (mean time, 8.7 years after surgery) for 101 patients. The results of objective evaluation were available for fifty-two patients, at a mean of 6.3 years. The patients in the control group had significantly higher subjective scores than did the patients with a defect in the medial compartment (mean, 95.2 points versus 94.0 points; $p = 0.0451$) and those with a defect in the lateral compartment (mean, 95.9 points versus 92.8 points; $p = 0.0047$). There was no significant correlation between larger defect size and lower subjective scores ($p = 0.2543$). The distribution of IKDC radiographic ratings was not significantly different between the groups. At least 79% of the patients in both groups returned to jumping, twisting, and pivoting sports at least at the recreational level.

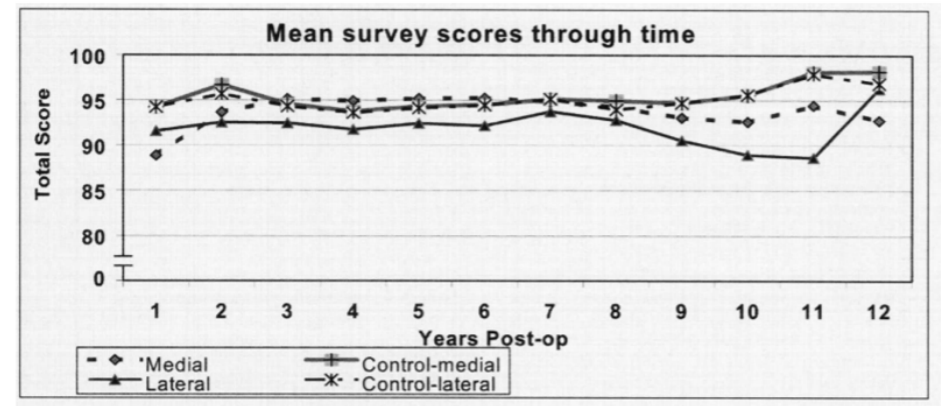
Conclusions: While statistical analysis revealed a difference in subjective scores between the defect and control groups, an average of 93 points for the patients with a lateral defect and 94 points for those with a medial defect indicates that most patients have very few symptoms. This study provides a baseline of information that can be used to compare the results of procedures designed to treat articular cartilage defects.

Chondral injuries of the knee are common. The authors of one study reported finding a chondral lesion during 63% of over 31,000 arthroscopic procedures, with an association between meniscal and articular cartilage lesions^{1,2}. Articular cartilage damage has been reported in association with 23% of acute anterior cruciate ligament (ACL) injuries and in 54% of knees with chronic ACL laxity or instability³.

Several operative techniques have been described to address chondral defects, which have been studied in animals and humans. Animal models often have articular cartilage proper-

ties that differ from those of human cartilage, and the lesions created rarely resemble the human condition. Overall, the operative treatment of isolated focal chondral lesions can be divided into three basic types: débridement and stabilization of loose or worn articular cartilage, stimulation of a repair process from the subchondral bone, and repair or replacement of the damaged articular surface. The techniques reported include arthroscopic débridement to remove loose cartilage flaps⁴, subchondral bone drilling⁵, microfracture techniques⁶, abrasion burr arthroplasty⁷, implantation of biodegradable rods⁸, use of

Skillful Neglect Is An Acceptable Form of Treatment



Skillful Neglect Is An Acceptable Form of Treatment

Try to Categorize Your Patient:

1. Do you actually think their cartilage defect is causing their symptoms?
2. Is this a focal lesion with an otherwise healthy joint?
3. OR, Is this patient already on the OA pathway with chondral, bony and synovial changes?

My best advice, **DON'T JUMP ONTO A SINKING SHIP!**



A muscular man with a beard and tattoos is performing a kettlebell exercise in a gym. He is in a low, athletic stance, with one knee on the floor and his right arm extended upwards, holding a green kettlebell. His left hand is on the floor for support. The gym background features various pieces of equipment, including a pull-up bar, a fan, and a sign with Spanish text: "REGLAS DEL BOX", "SI VAS A ENTRENAR", "PARA PODER ENTRENAR", "PAGA A TIEMPO", "AYUDA Y MOTIVA", "EL EQUIPO A SU LUGAR", and "DIVIÉRTETE!".

Athletes Have Unique Considerations

Athletes Have Unique Concerns

- Inability to perform makes them unemployable
 - Treatment chosen may affect their asset value
 - Cartilage procedures less predictable for RTS than return to ADLs
 - Need to match treatment with a timeline that matches their available timeline
 - Don't choose a treatment that burns bridges
 - Contracts / Scholarships can be influenced by treatment decisions
-
- **Athletes of Different Levels Often Treated Differently**

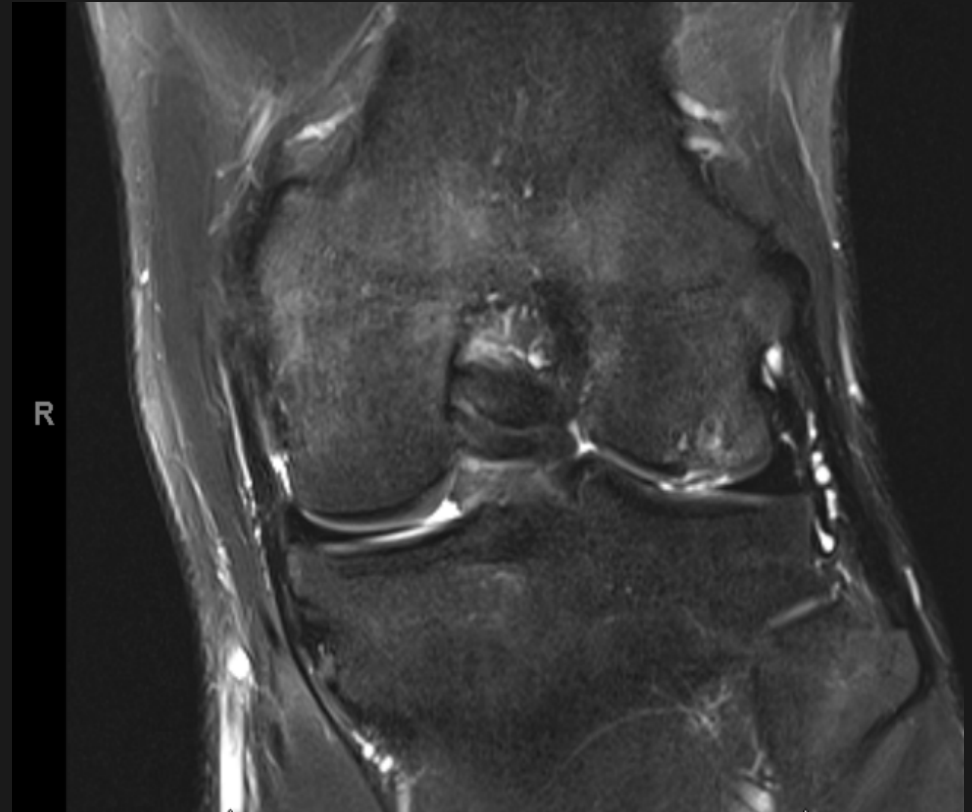


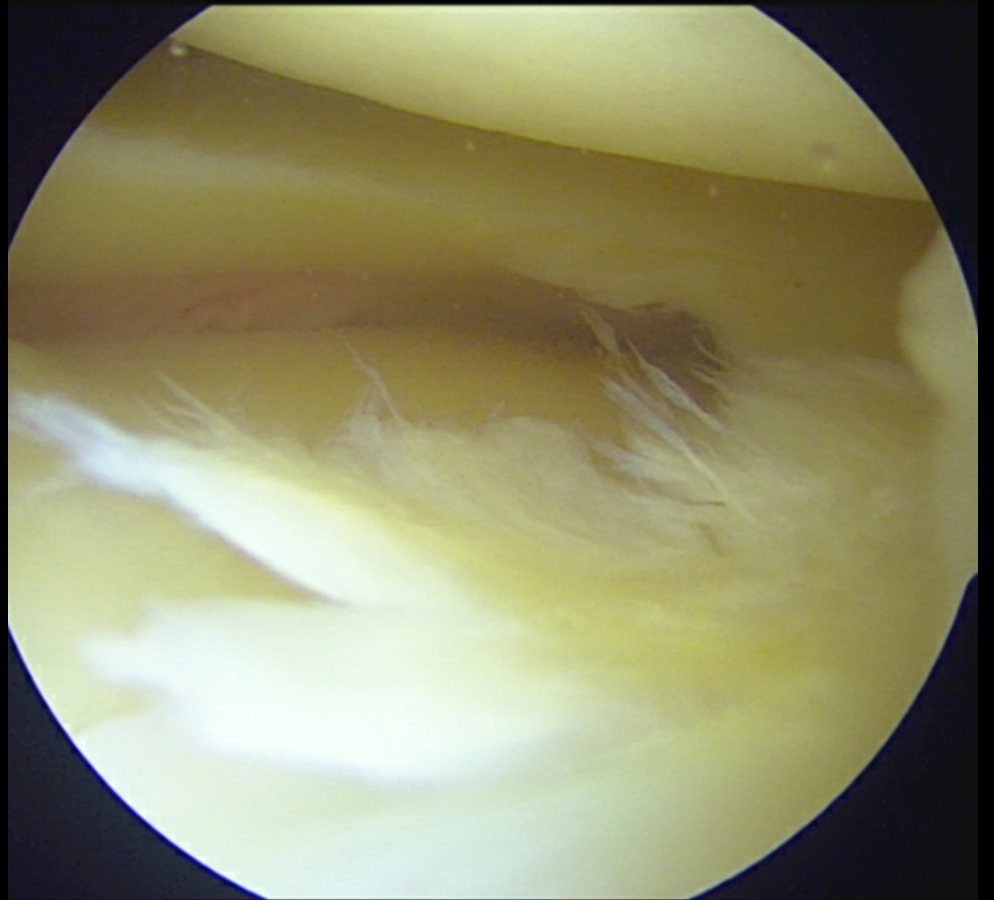
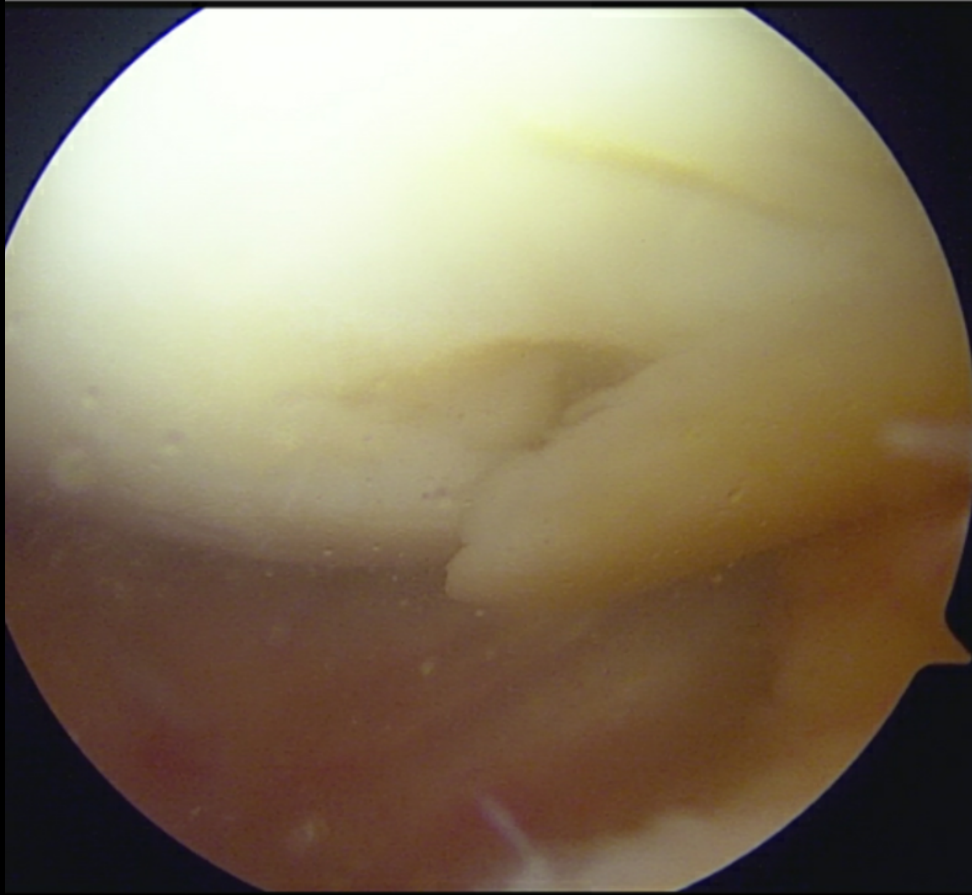
23 yo M

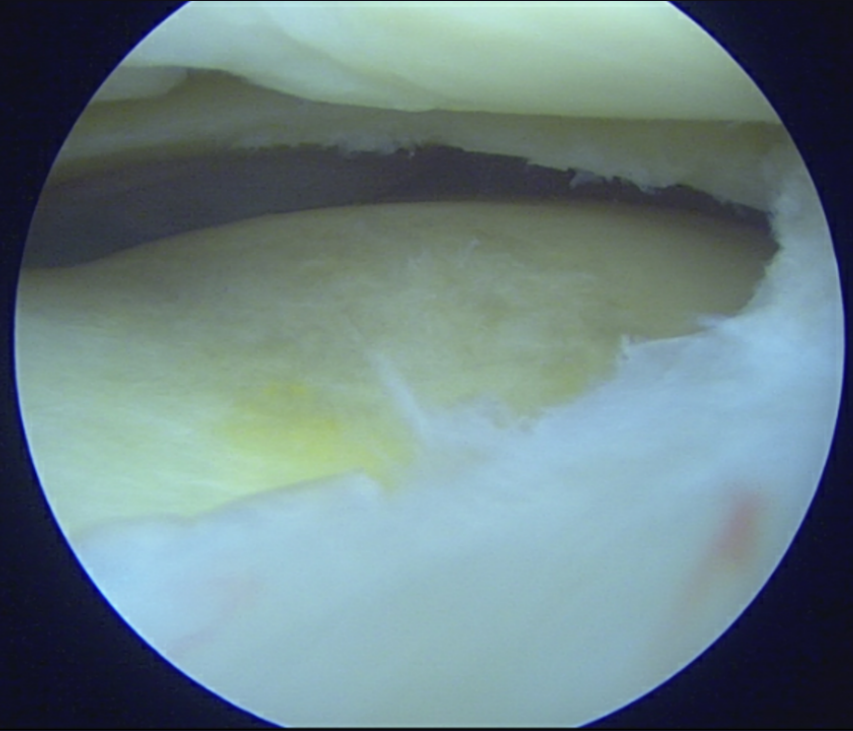
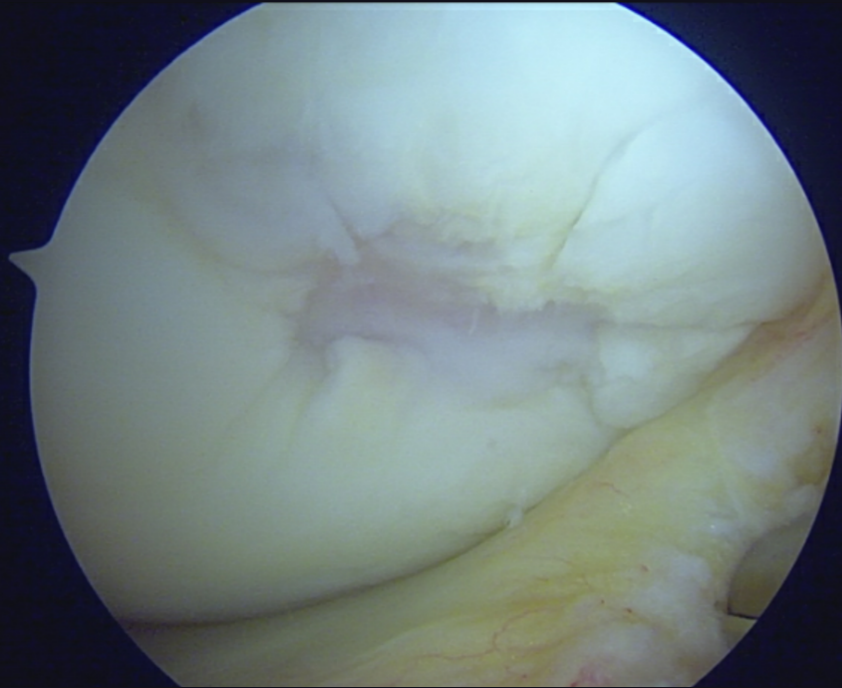
College senior at major basketball program

Entering NBA Draft in a few weeks

Symptomatic lateral femoral condyle defect (~ 10 x 10 mm)





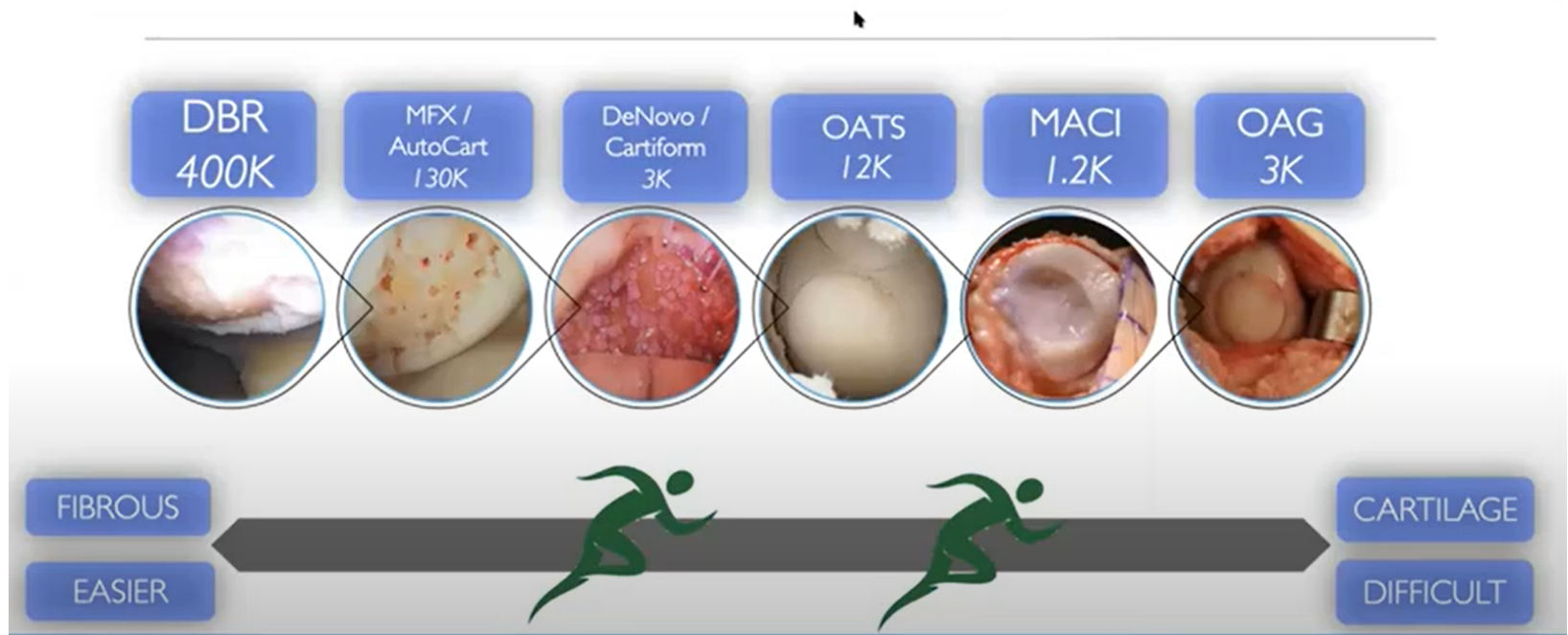


A man in a dark blue shirt is looking at a row of vending machines. The machines are filled with various snacks and drinks. The text "There Is More Than One Right Answer" is overlaid in white, bold font across the center of the image.

**There Is More Than One
Right Answer**

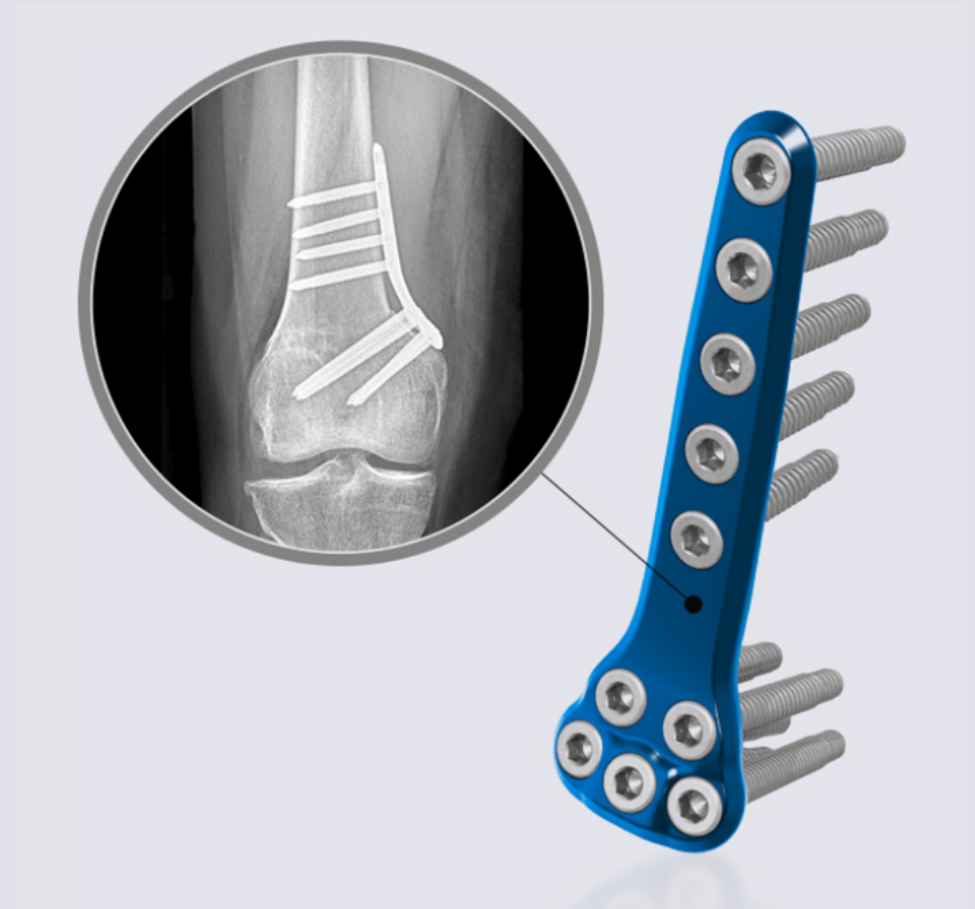Slide Courtesy of Dr.
Brian Cole

5. There is More Than One Right Answer



Correct All Comorbidities

1. Malalignment
2. Meniscal Deficiency
3. Ligamentous Instability
4. Subchondral Deficiency



**Manage Patient
Expectations:
Know The
Literature and Your
Own Experience**





Working Up The Patient With Cartilage Injury

What Every PA Should Know in 2021

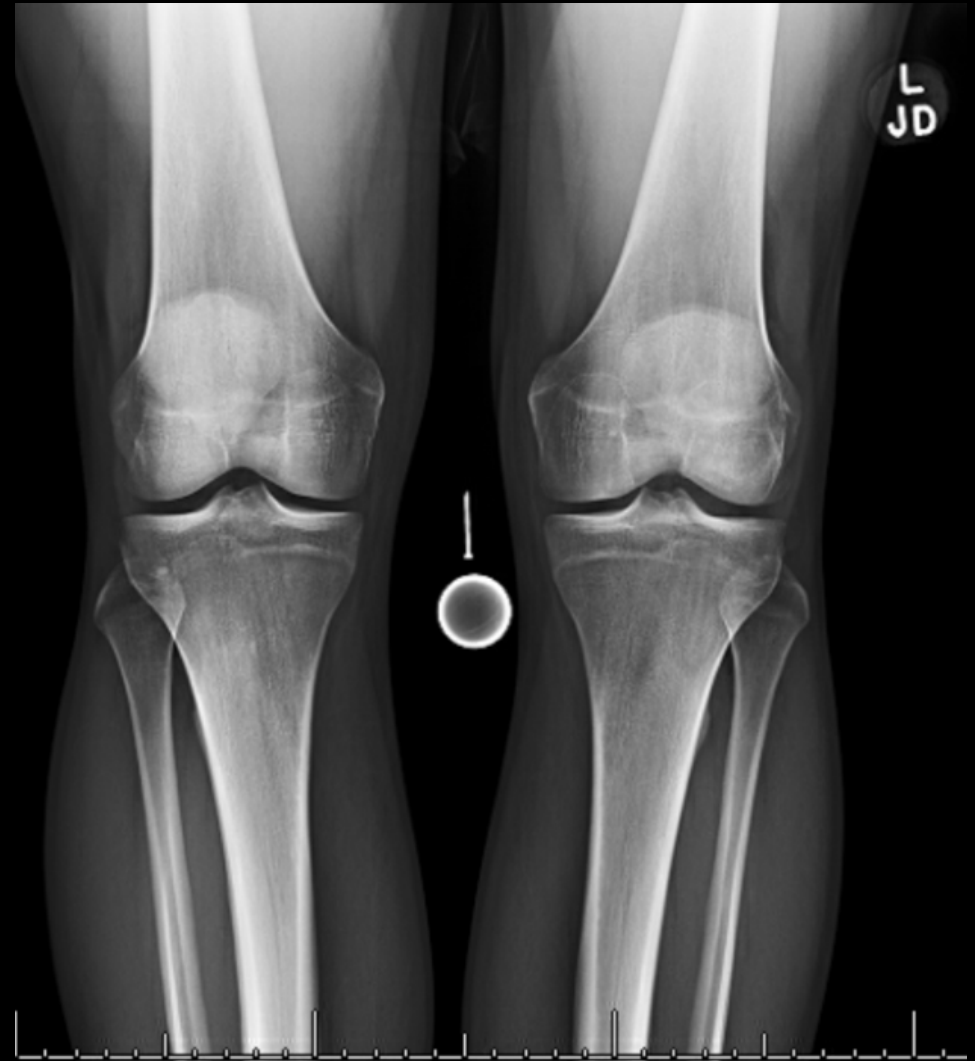When Should You Suspect Cartilage Pathology?

1. Swelling, swelling, swelling...
2. Focal weight bearing pain (tibiofemoral disease)
3. Pain with squatting activities (patellofemoral disease)
4. History of trauma or prior surgery (particularly meniscectomy)
5. Obvious malalignment



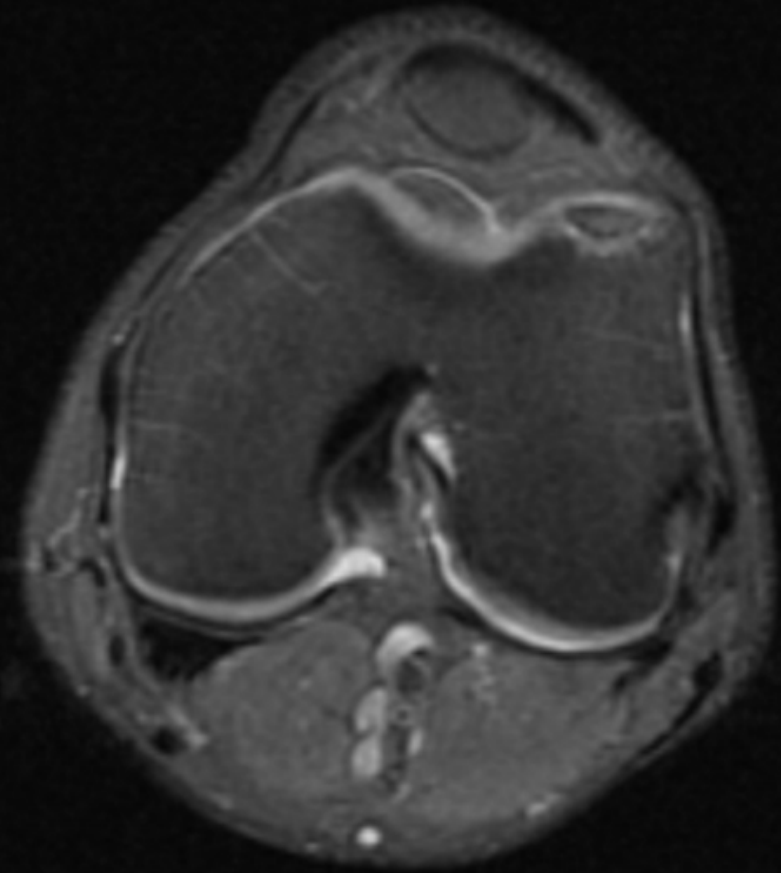
What Should Be Your Initial Workup?

1. **Great clinical exam**: focus on focal vs. generalized pain
2. **Thorough history**: focus on athletic and functional goals, ask them **"what is the 1 thing they'd like to see improved with their knee?"**
3. **Plain XR** (AP, lateral , Rosenberg, Merchant)
4. **Alignment films** if tibiofemoral disease suspected or obvious malalignment on exam
5. Surgical and injury history
6. Prior op notes / pictures if prior surgery



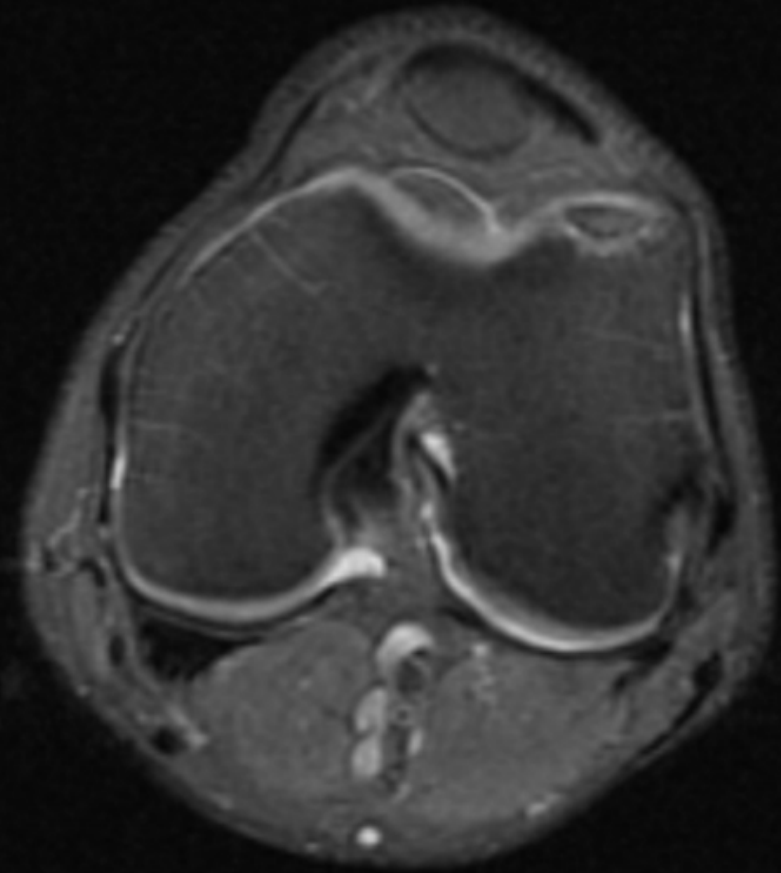
What About MRIs?

- Know Who Doesn't Need It Right Away:
 1. Older patients with diffuse pain and/or atraumatic onset
 2. Patients with classic symptoms of simple problems (PFPS, ITBS, etc.)
 3. Patients that aren't surgical candidates for medical reasons
 4. Patients with obvious arthritis on Xrays
 5. Patients with mild symptoms who haven't tried conservative measures



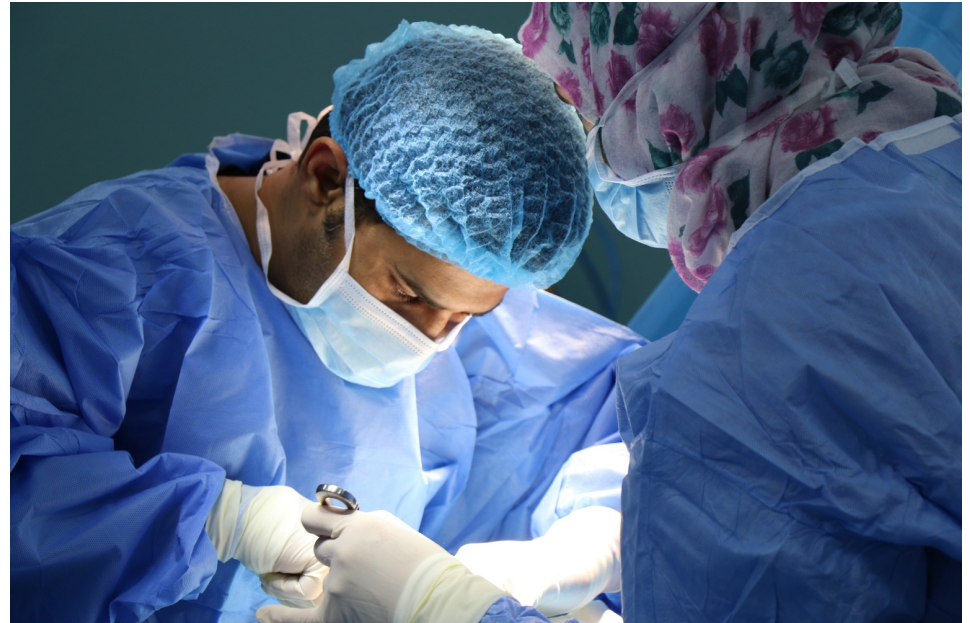What About MRIs?

- Who Does Need It Right Away?
 1. Acute injury with swelling in active patient
 2. Athlete with performance limiting symptoms
 3. Obvious osteochondral injury on XR
 4. Obvious ligamentous injury on exam
 5. Failed conservative management



Who Needs Immediate Referral?

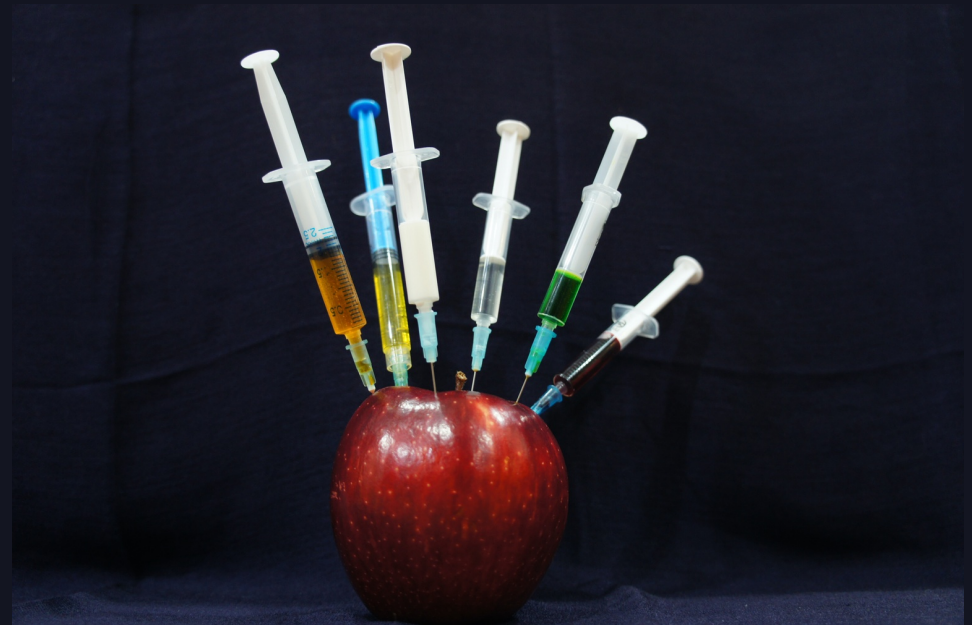1. In season athlete who isn't getting better
2. Chondral or osteochondral loose body
3. Cartilage injury + acute ligamentous injury.



What Does Conservative Treatment Look Like?

1. Activity Modification
2. Unloader brace for tibiofemoral lesions
3. Physical therapy, focus on hip and core strength, improving impact absorption and patellofemoral mechanics
4. NSAIDs
5. Cortisone injection (I don't like more than one in young patients)
6. Biologics

It's never the wrong answer to try these things!



TOP 10 TAKE HOMES

1. Cartilage restoration is a complex topic
2. There's many ways to provide good outcomes to patients
3. Work on developing your acumen for who DOES and who DOESN'T need cartilage surgery
4. Be judicious with MRIs
5. Get appropriate studies to understand relevant co-morbidities
6. Maximize non-operative treatment
7. Manage patient expectations from the get go
8. Understand the broad types of cartilage surgery: debridement, marrow stimulation, cell therapy, osteochondral transfer
9. Don't sweat the details
10. Remember that careful considerations of a unique patient's needs will always trump an algorithm!

Thank You!

Please contact me with any questions

jonathan.riboh@orthocarolina.com

