



Atrium Health
Musculoskeletal Institute

Hip Fractures

Luke Harmer MD MPH

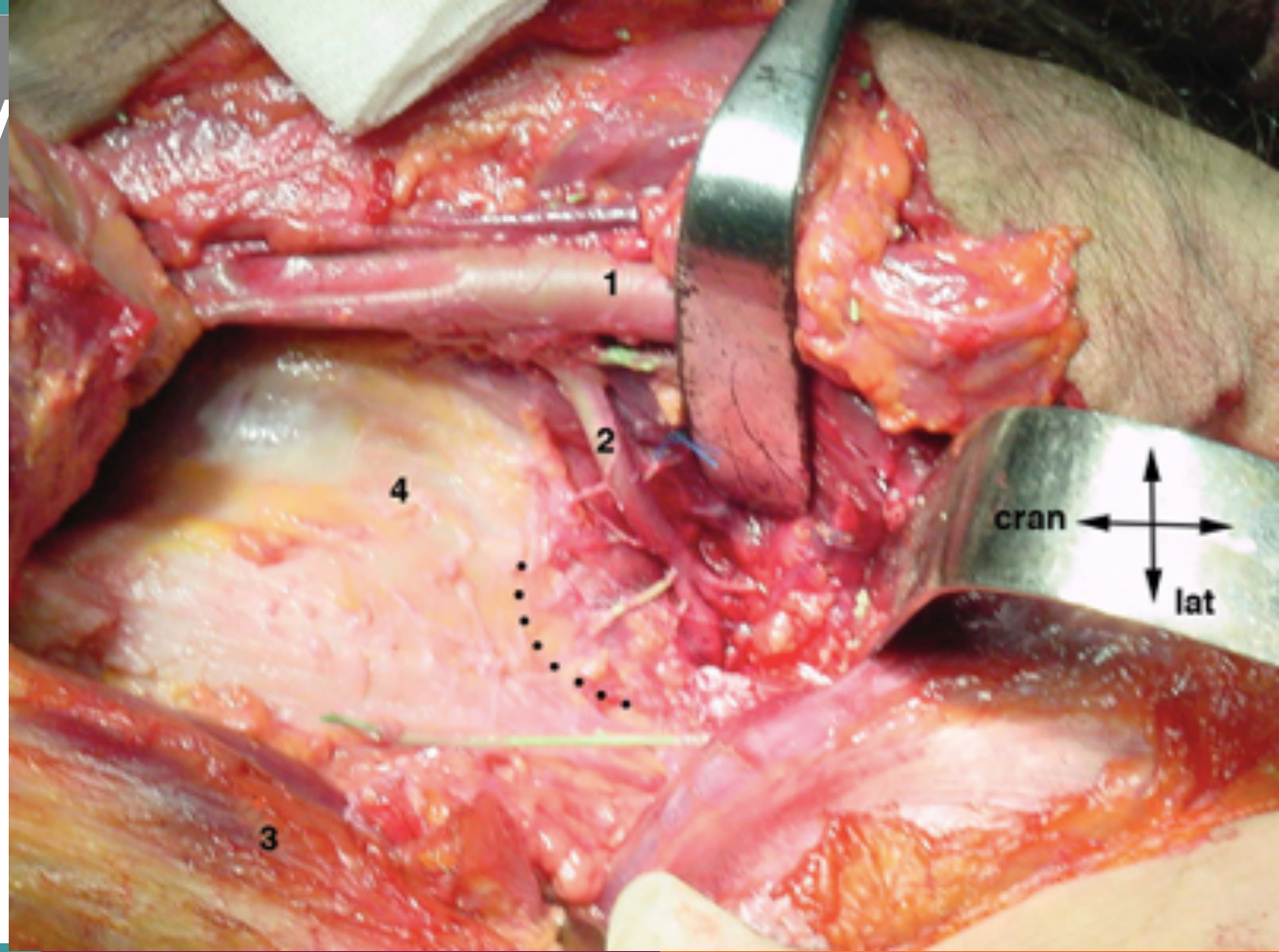
Extremities in the Carolinas – Trauma for General Orthopedics

May 17, 2021

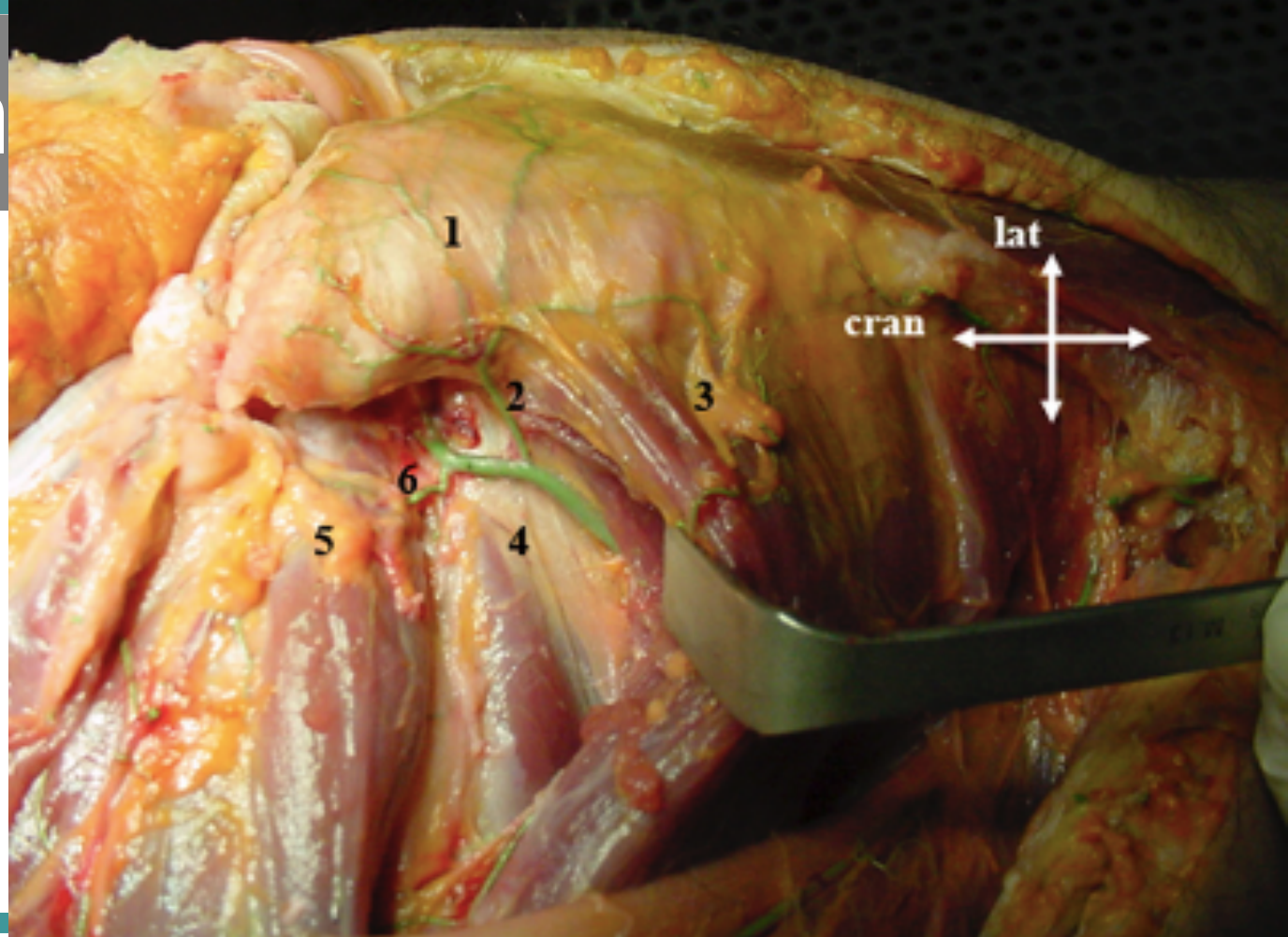
Objectives

1. Name the blood supply to the femoral head
2. Differentiate intracapsular from extracapsular fractures
3. Plan treatment for intracapsular fractures by considering displacement
4. Plan treatment for extracapsular fractures by considering stability

Anatomy



Anatom



Hip Fracture

```
graph TD; A[Hip Fracture] --> B[Intracapsular]; A --> C[Extracapsular];
```

Intracapsular

Extracapsular

Hip Fracture

```
graph TD; A[Hip Fracture] --> B[Intracapsular]; A --> C[Extracapsular]; B --> D[Displaced]; B --> E[Nondisplaced];
```

A hierarchical flowchart classifying hip fractures. The root node is 'Hip Fracture', which branches into 'Intracapsular' and 'Extracapsular'. 'Intracapsular' further branches into 'Displaced' and 'Nondisplaced'.

Intracapsular

Extracapsular

Displaced

Nondisplaced

Intracapsular Displaced

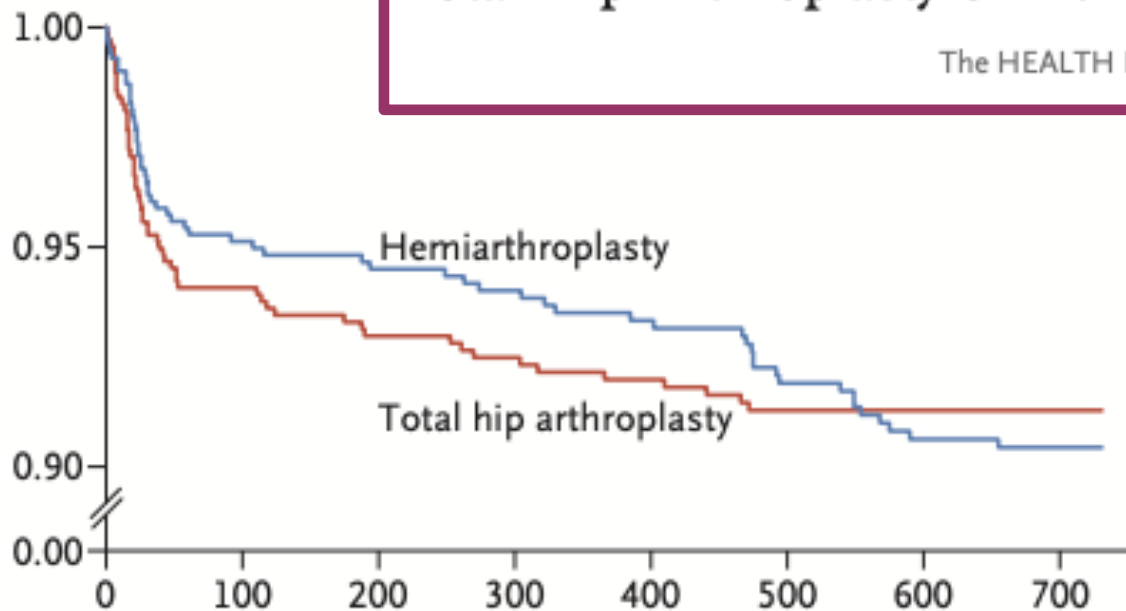
XR

Arthroplasty picture

Intracapsular Displaced

Total Hip Arthroplasty or Hemiarthroplasty for Hip Fracture

The HEALTH Investigators*



Intracapsular Displaced

- Cemented vs Press fit femoral component Norwegian paper

Intracapsular Displaced

Is Cemented or Cementless Femoral Stem Fixation More Durable in Patients Older Than 75 Years of Age? A Comparison of the Best-performing Stems

- Australian Joint Registry
- Best 3 cemented no different from best 3 press fit after 3 months

Intracapsular Undisplaced

- XR
- Reding a lateral XR

Intracapsular Undisplaced

- Reoperation 20% vs 22%
- Functional outcome no difference
- Smokers, basicervical and vertical fracture patterns better with sliding hip screw

Intracapsular Undisplaced

Screw Fixation Versus Hemiarthroplasty for Nondisplaced Femoral Neck Fractures in Elderly Patients

A Multicenter Randomized Controlled Trial

- No difference in functional outcome
- Hemiarthroplasty better for mobility and Quality of life
- Reoperation 20% vs 5%

Hip Fracture

```
graph TD; A[Hip Fracture] --> B[Intracapsular]; A --> C[Extracapsular]; B --> D[Displaced]; B --> E[Nondisplaced]; C --> F[Stable]; C --> G[Unstable];
```

A hierarchical flowchart classifying hip fractures. The root node is 'Hip Fracture', which branches into 'Intracapsular' and 'Extracapsular'. 'Intracapsular' further branches into 'Displaced' and 'Nondisplaced'. 'Extracapsular' branches into 'Stable' and 'Unstable'.

Intracapsular

Extracapsular

Displaced

Nondisplaced

Stable

Unstable

Extracapsular

- Stability
 - Lateral Wall
 - Posteromedial calcar
 - Reverse obliquity
 - Subtrochanteric

Extracapsular - Stable

Sliding Hip screw vs Sliding hip nail

Extracapsular - Unstable

Reduction!

Objectives

1. Name the blood supply to the femoral head
2. Differentiate intracapsular from extracapsular fractures
3. Plan treatment for intracapsular fractures by considering displacement
4. Plan treatment for extracapsular fractures by considering stability