

Basics of 12-Lead ECG Interpretation

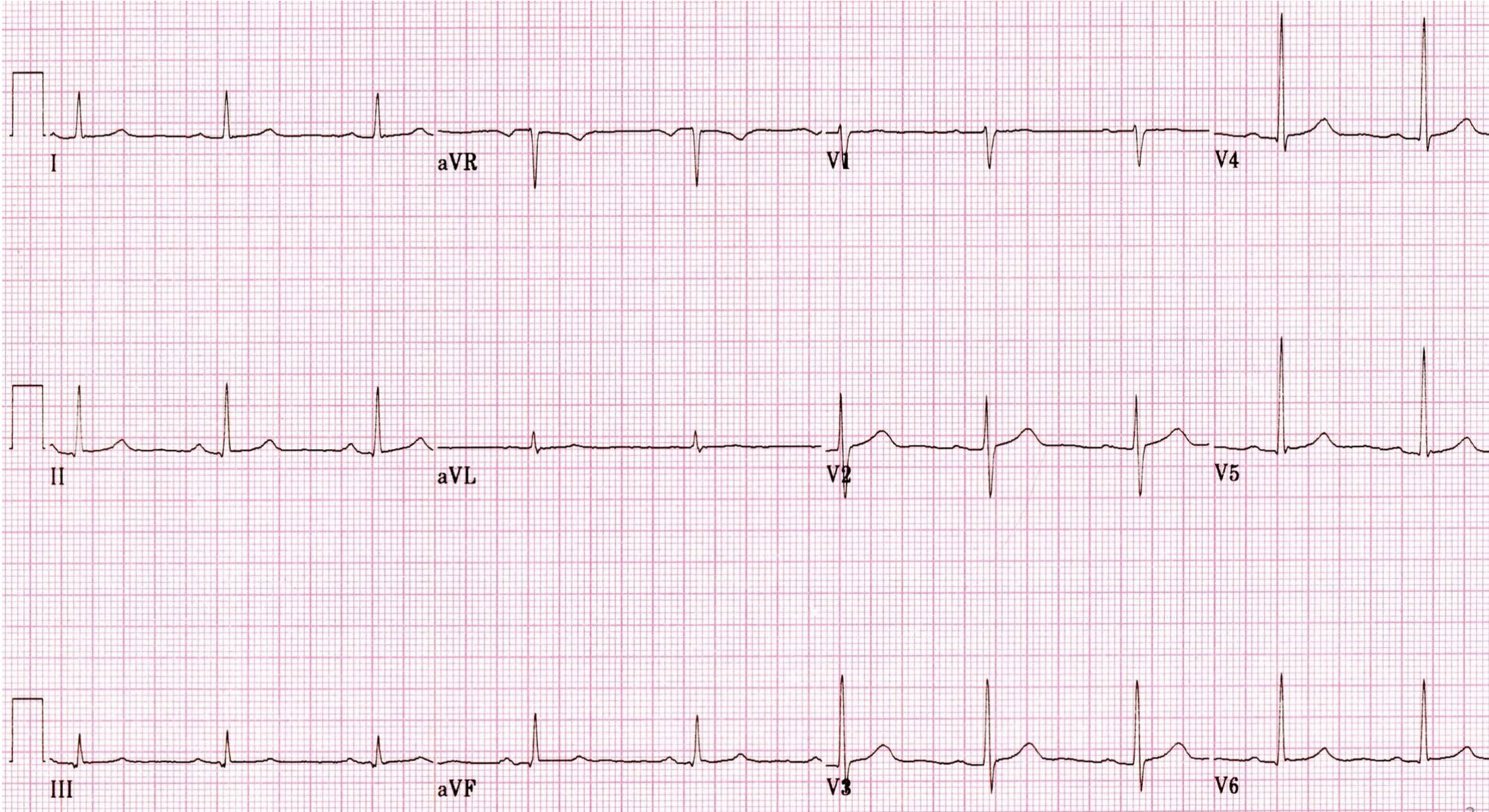
12-Lead ECG Lecture Practice Slides

Adult Hospital Medicine Boot Camp

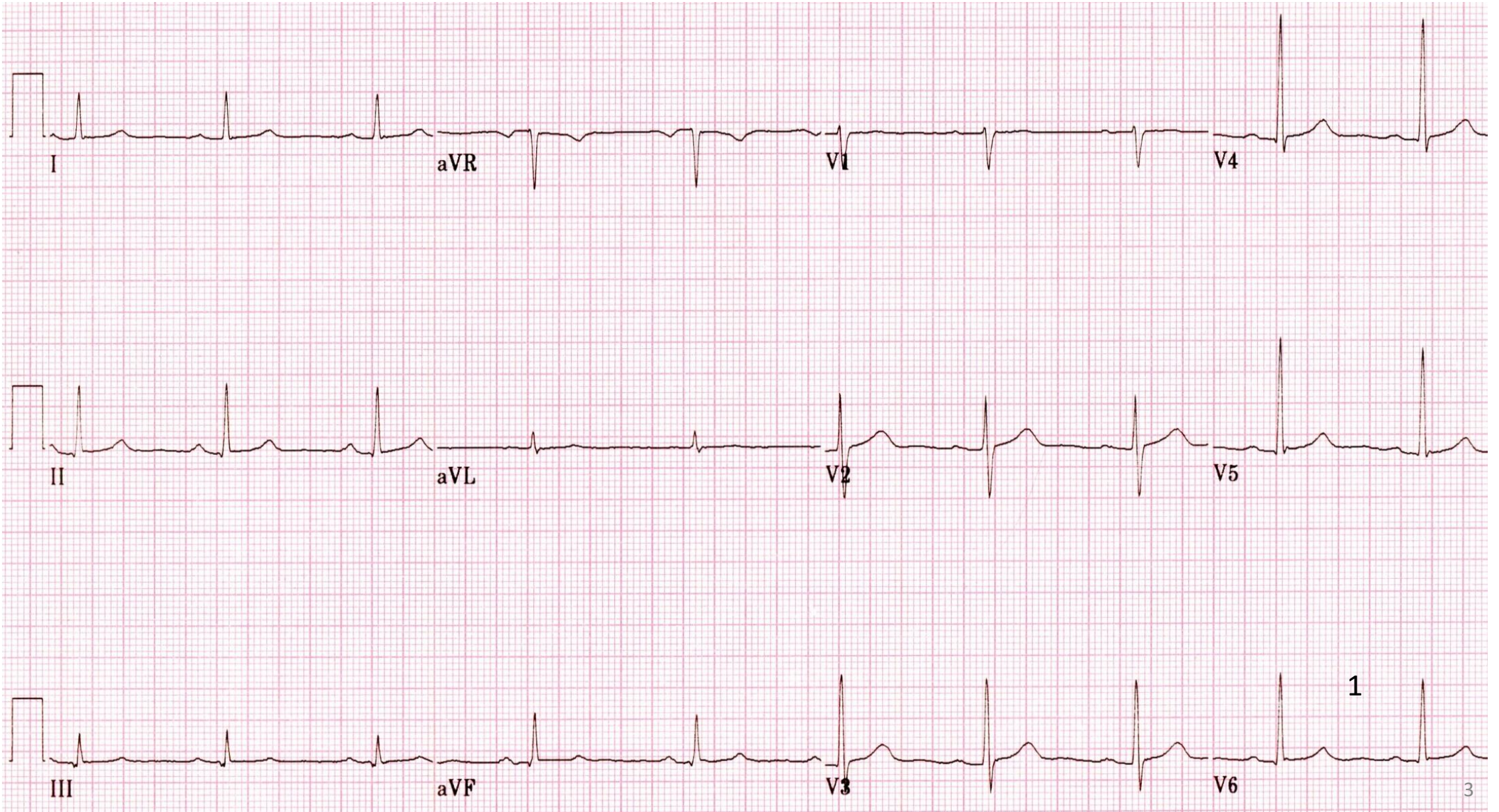
Nashville, TN

Darwin Brown, MPH, PA-C

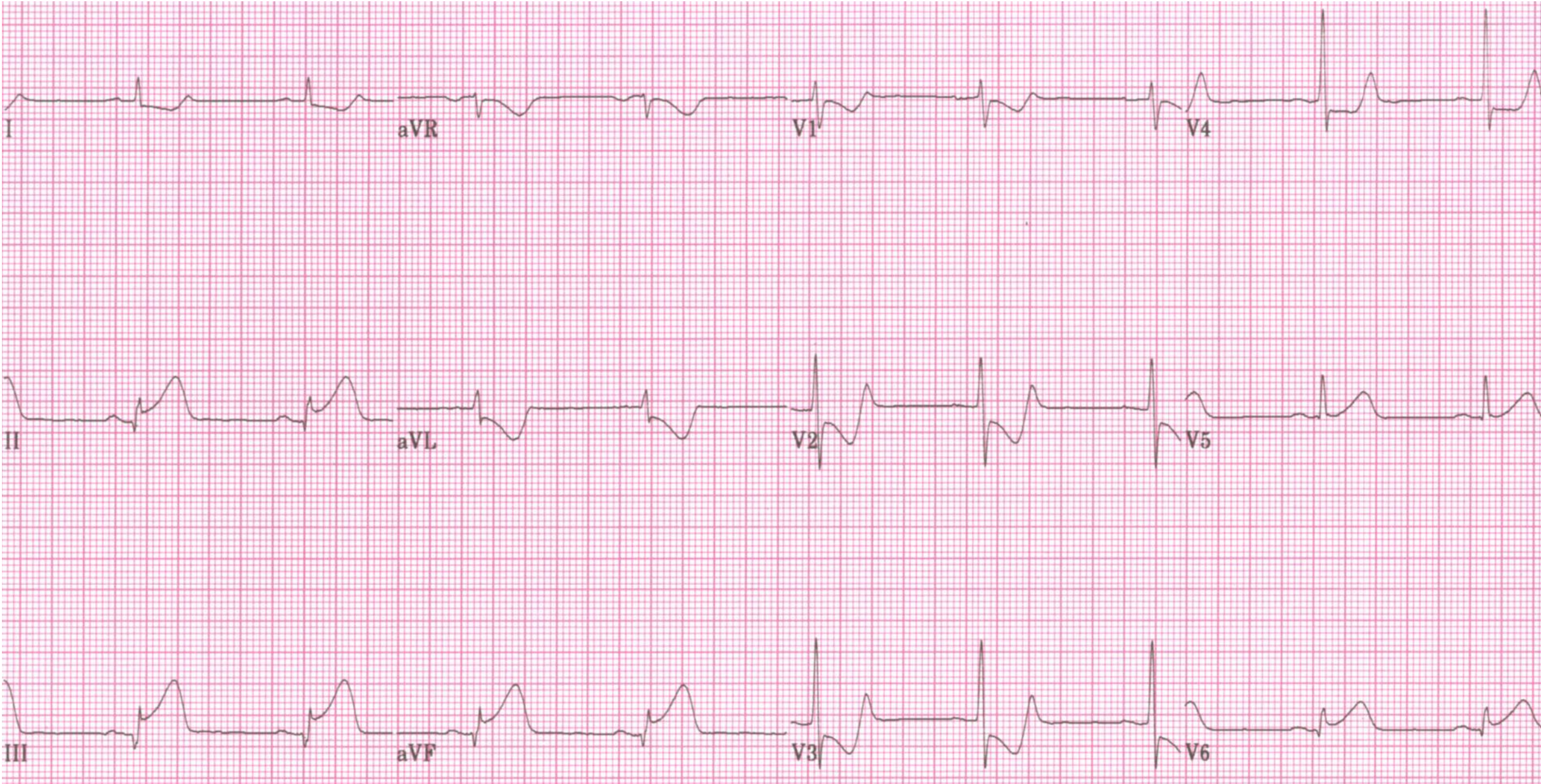
Slide 25 - Axis



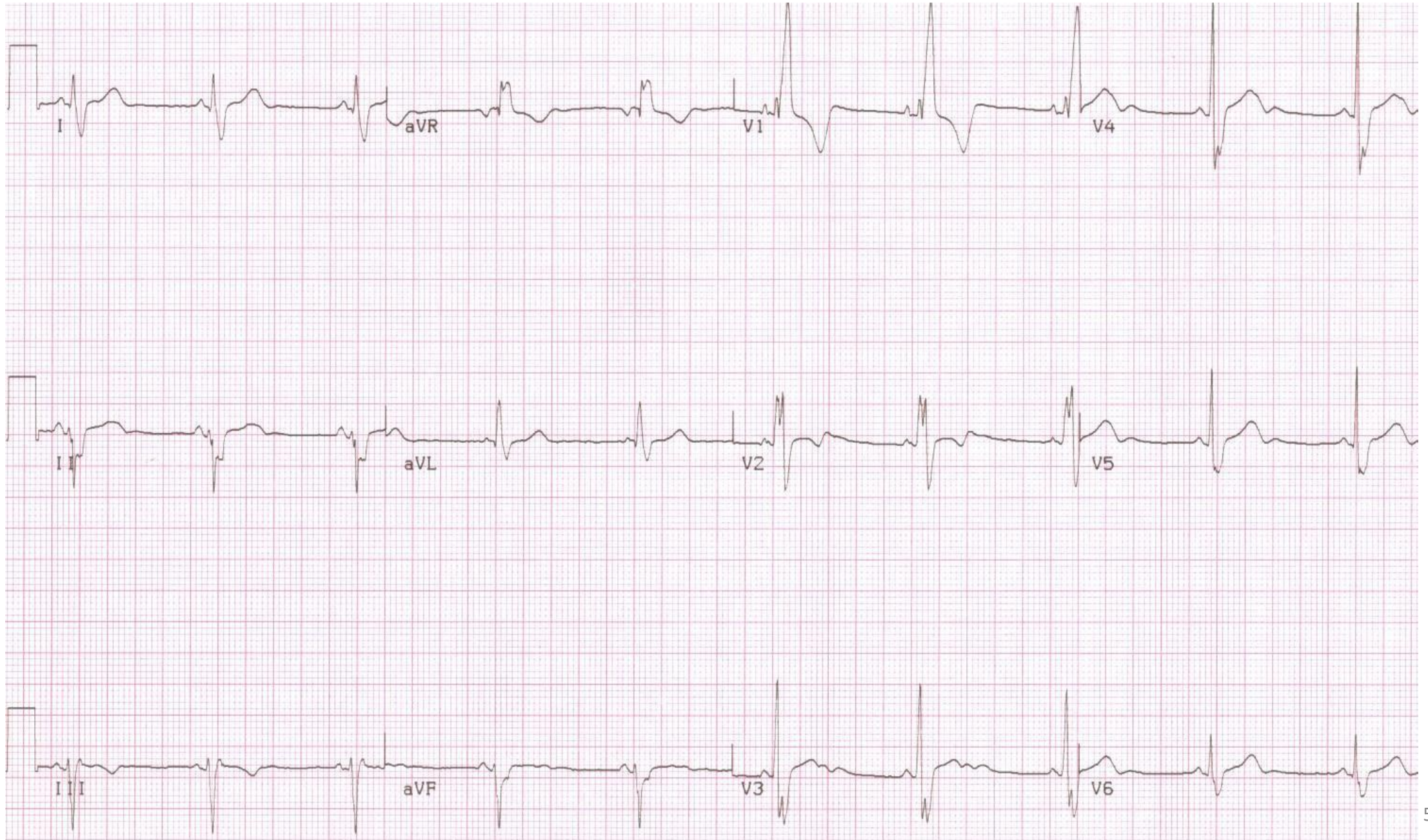Slide 35 - Practice



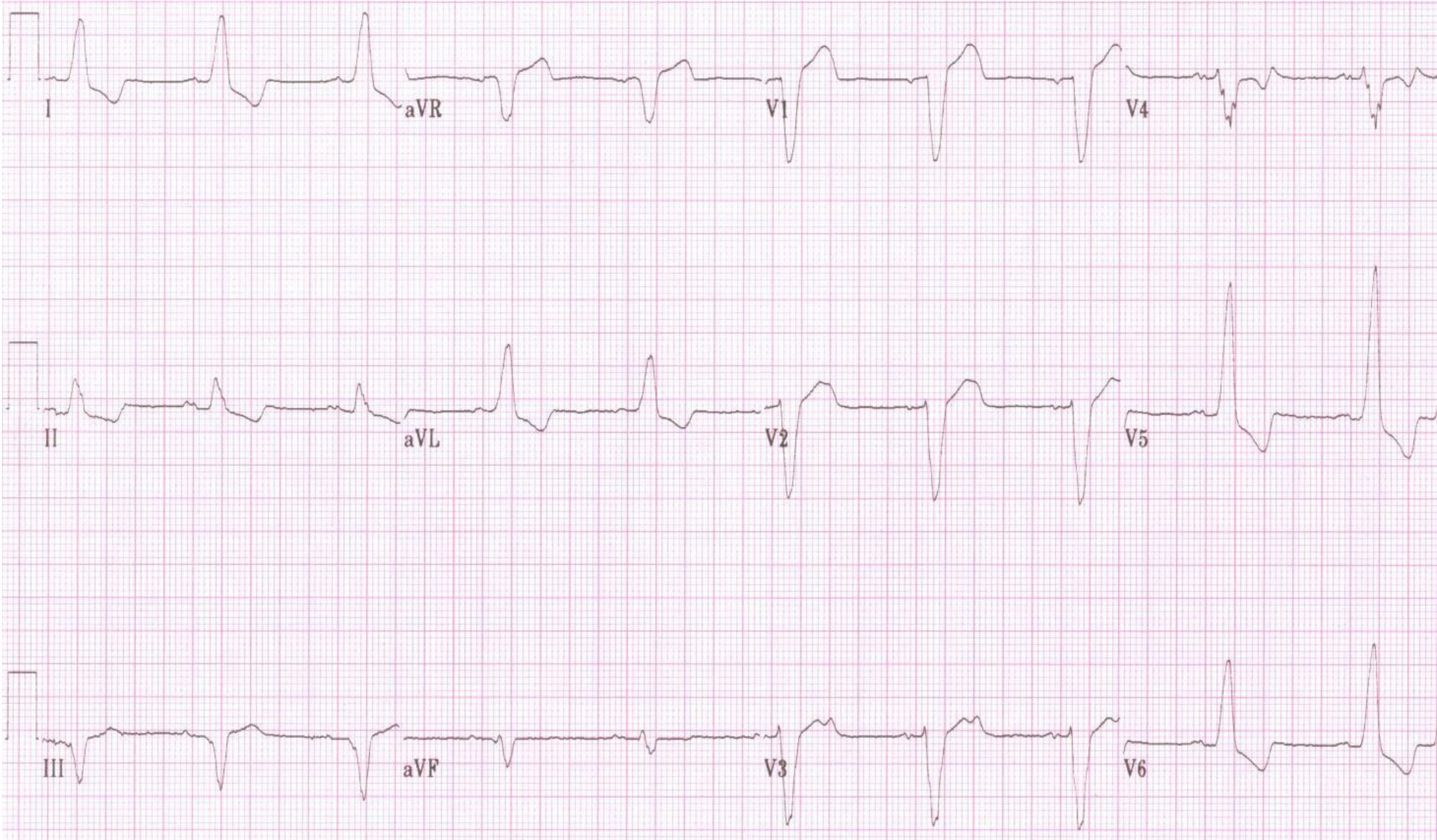
Slide 36 - Practice



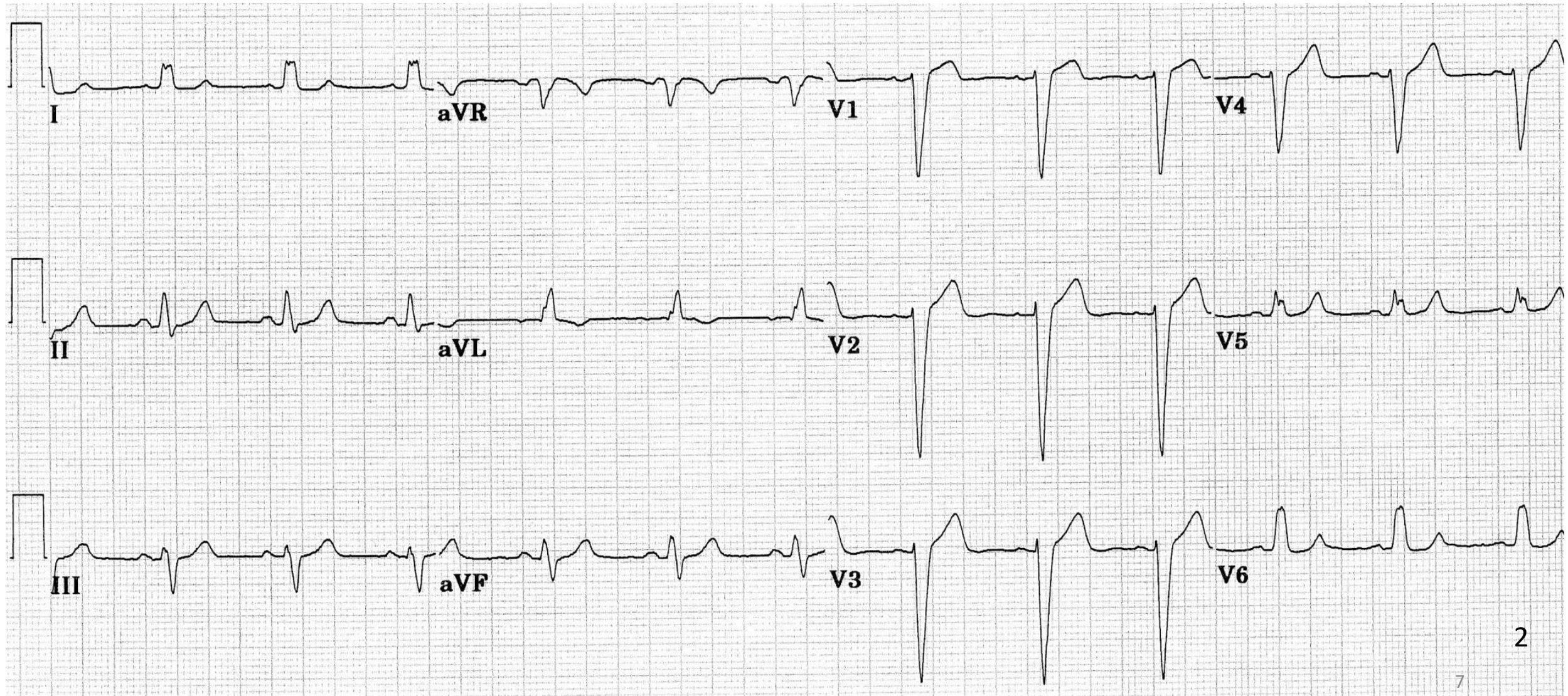
Slide 42 - RBBB



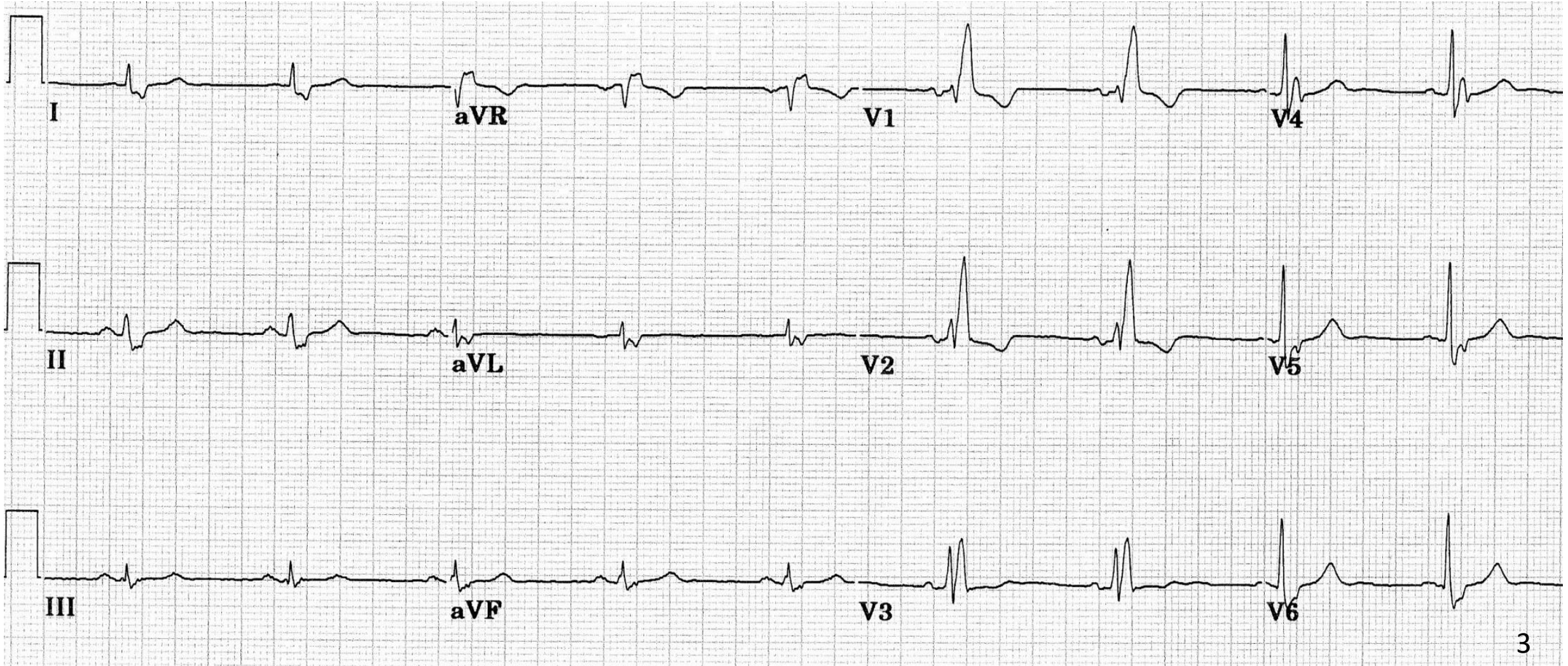
Slide 45 - LBBB



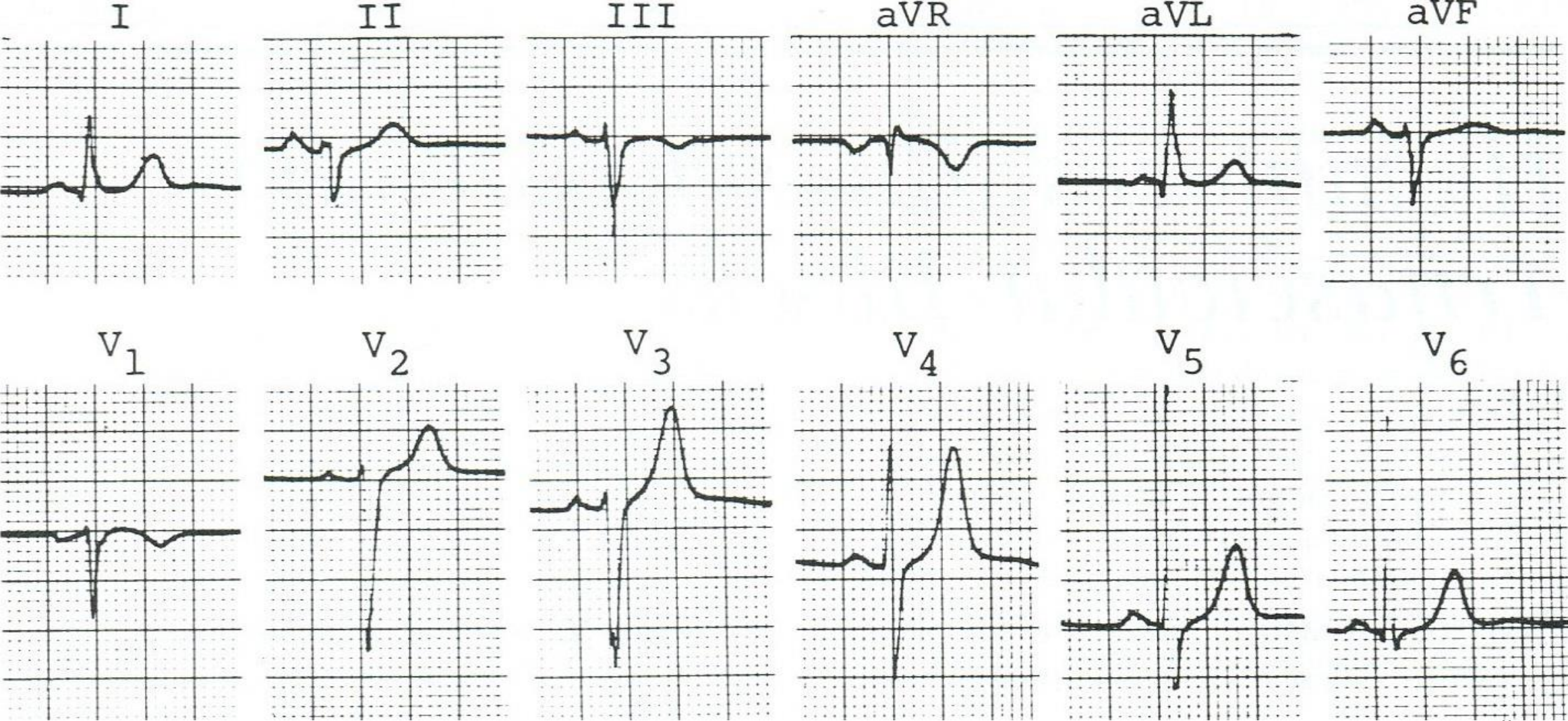
Slide 48 - Practice



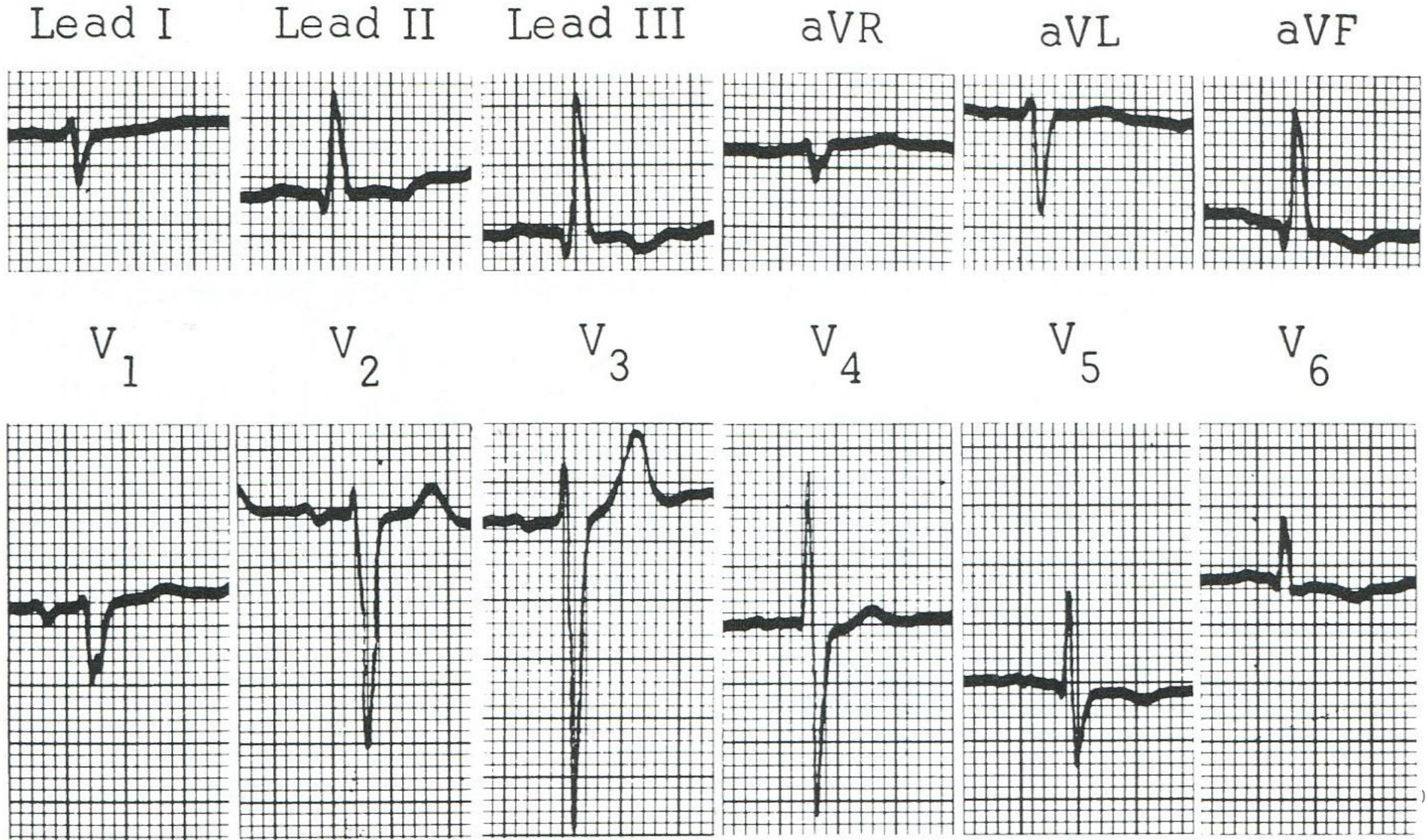
Slide 49 - Practice



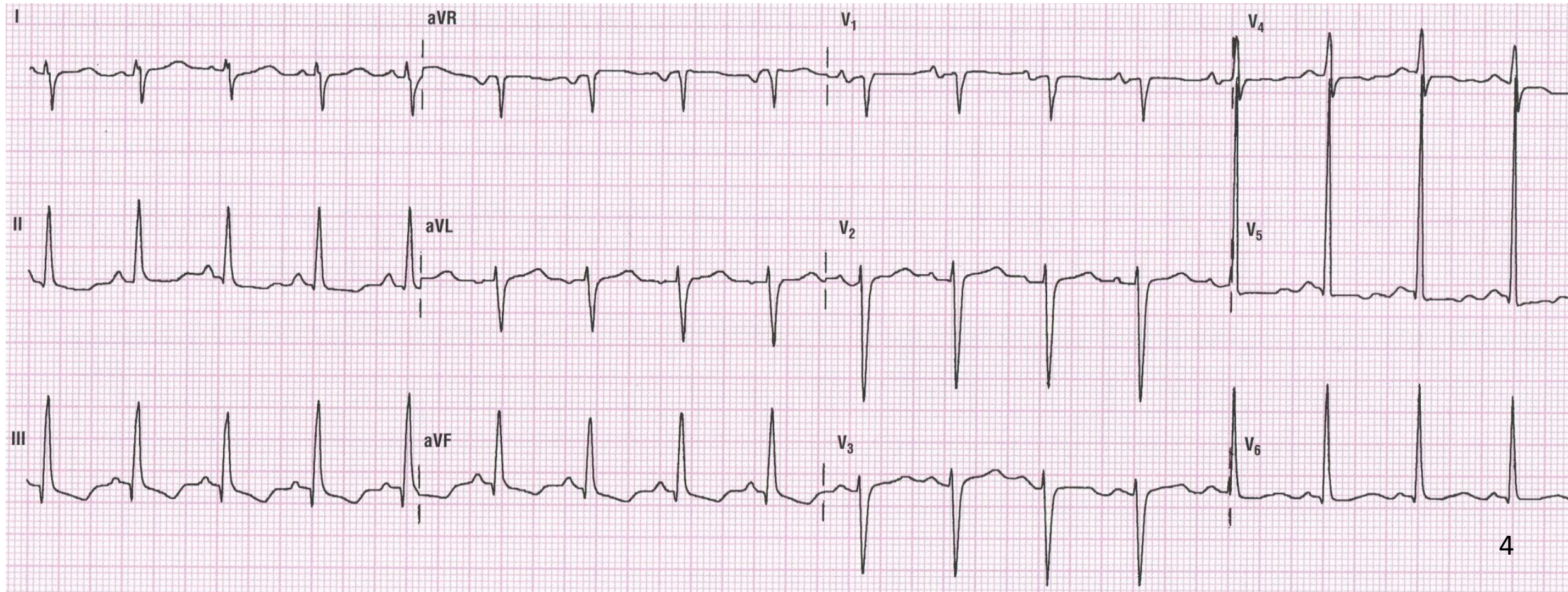
Slide 55 – LAFB Example



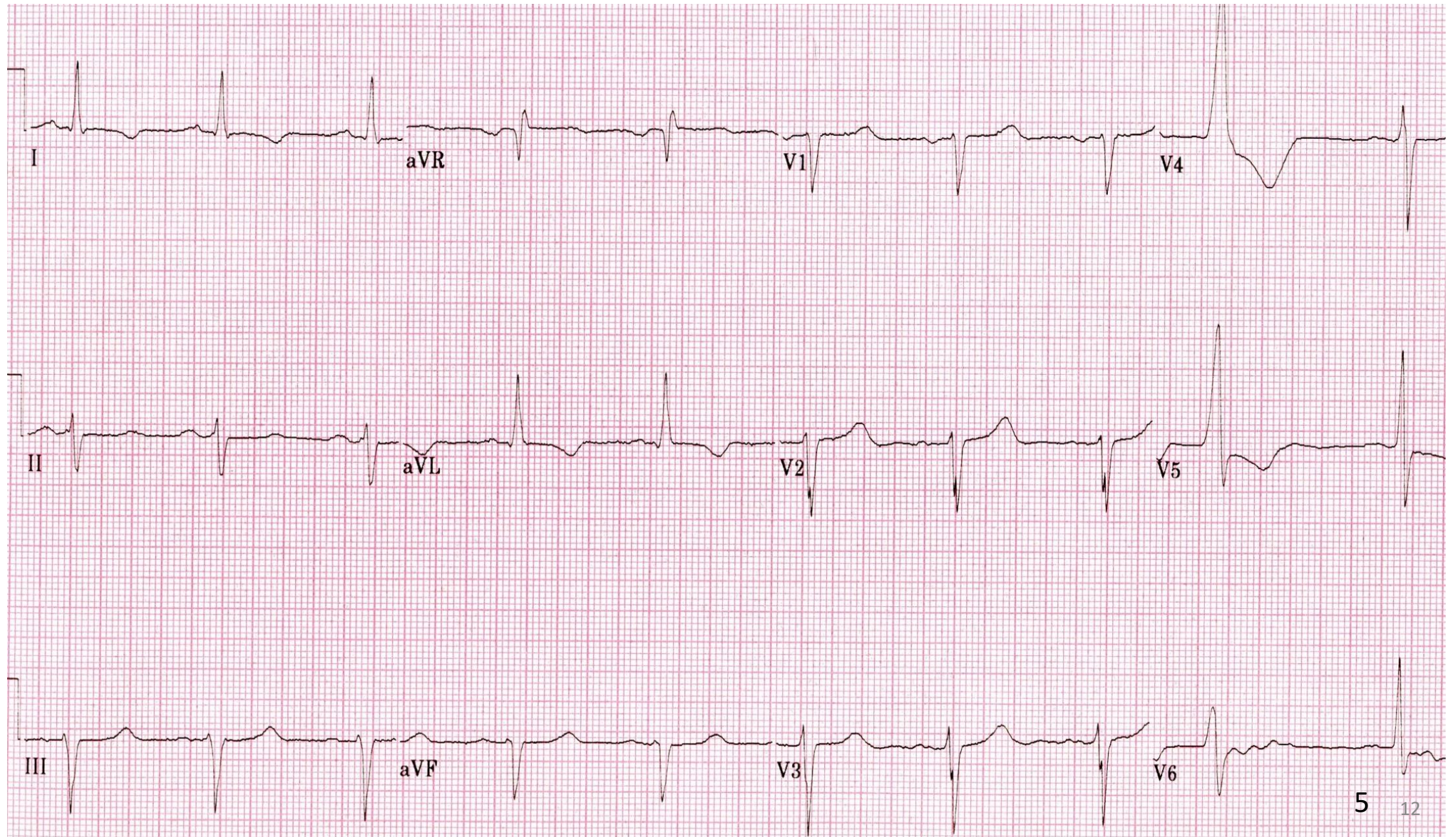
Slide 57 – LPFB - Example



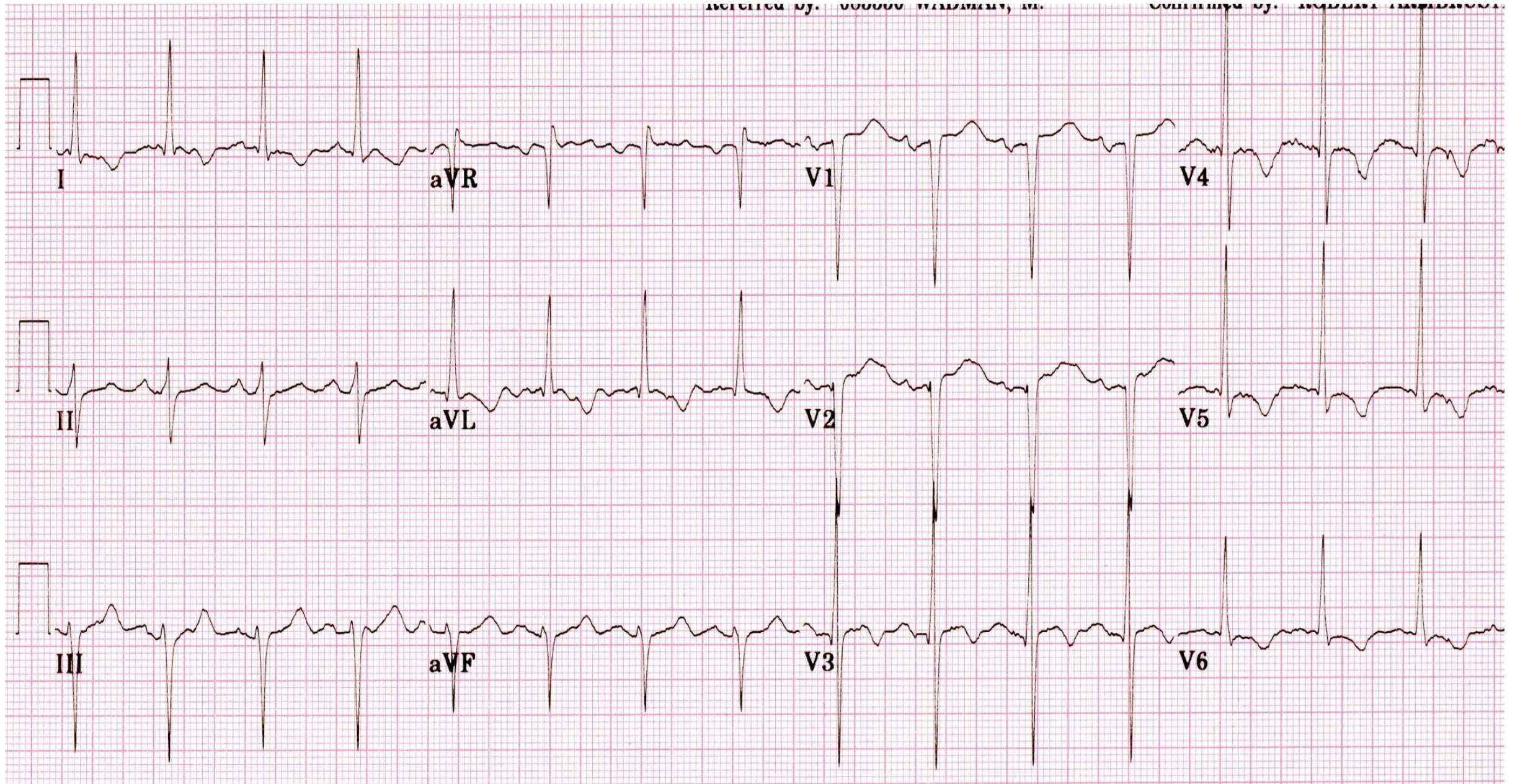
Slide 59 - Practice



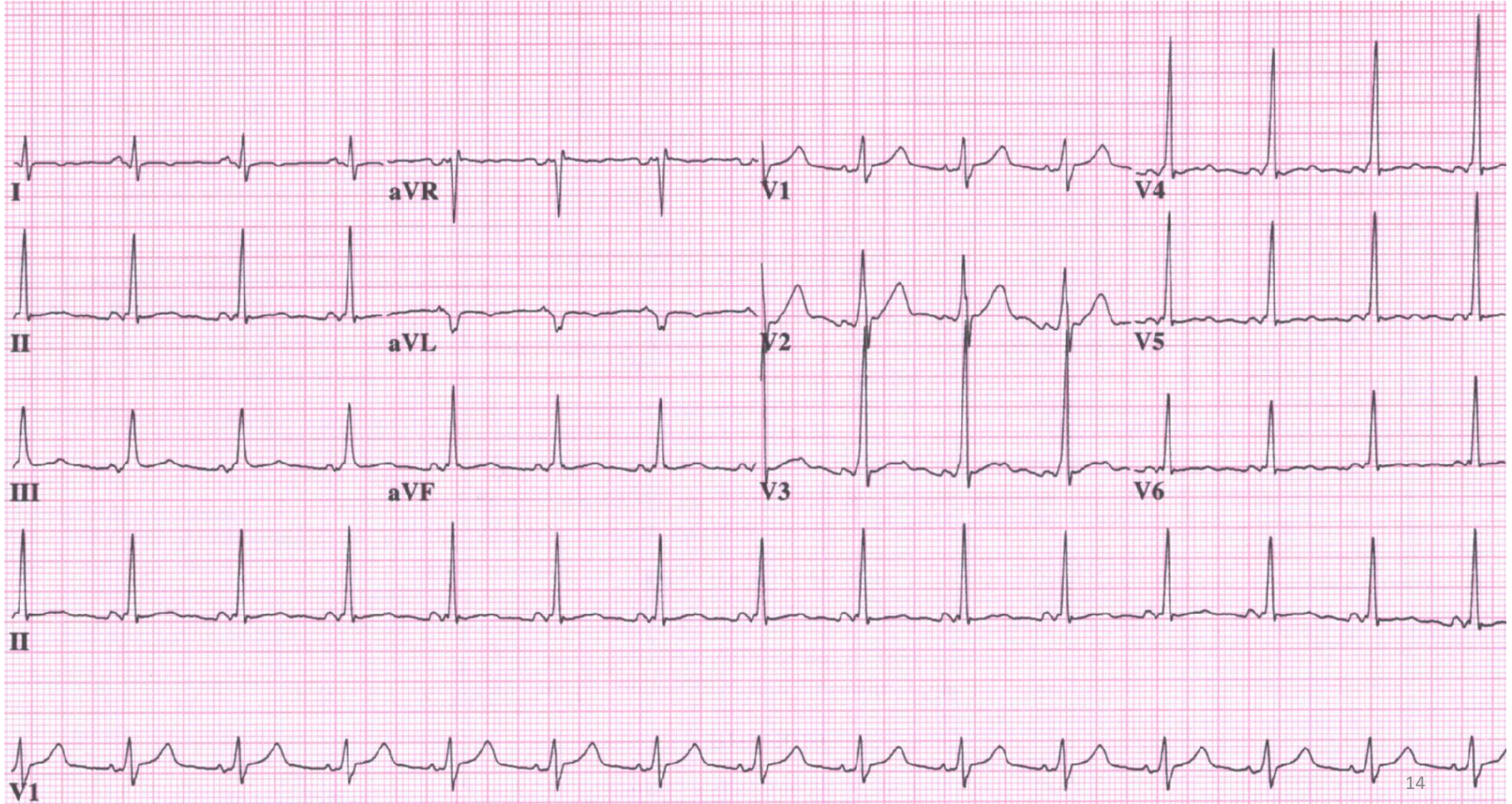
Slide 60 - Practice



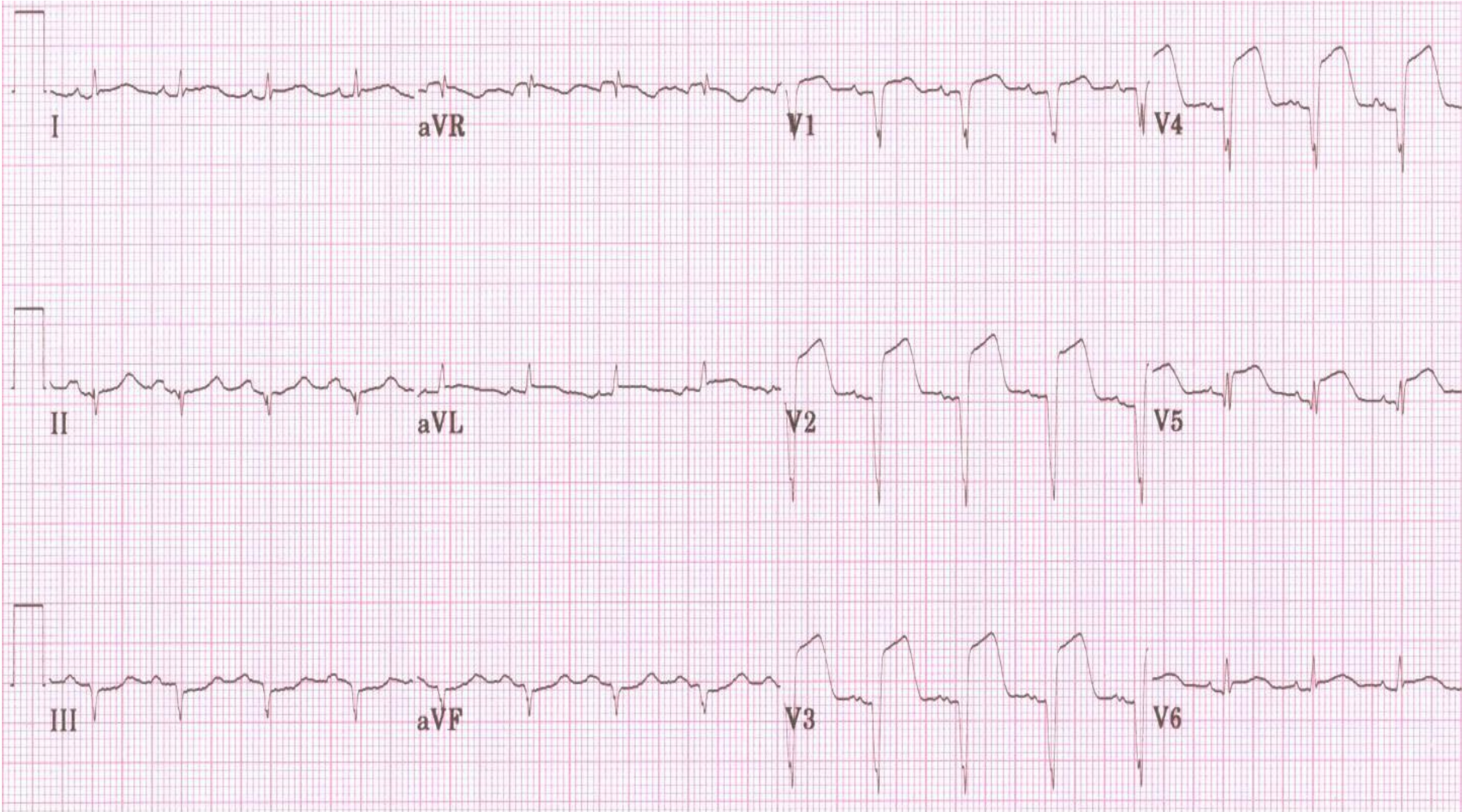
Slide 73 - Practice



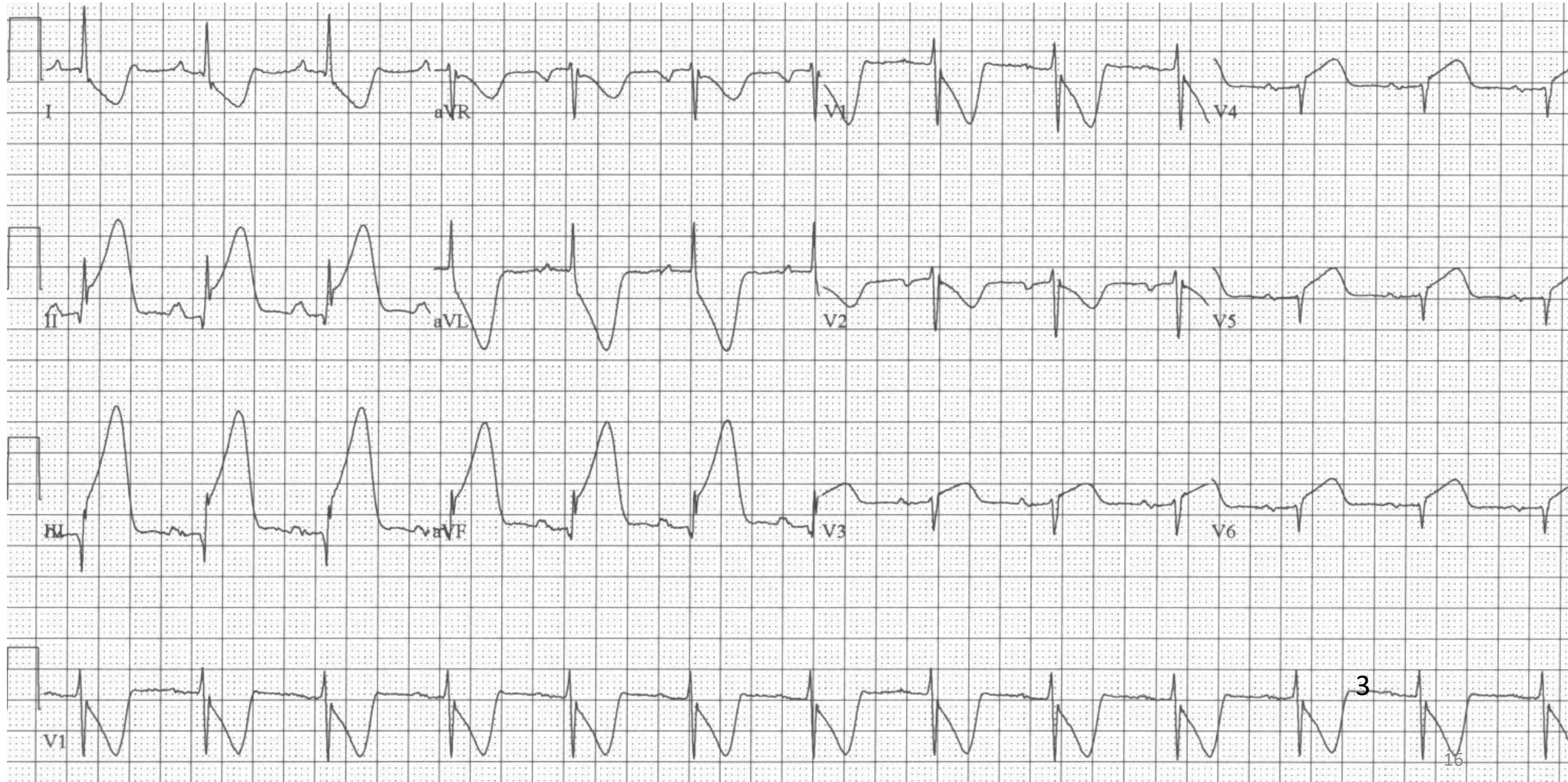Slide 77 - Practice



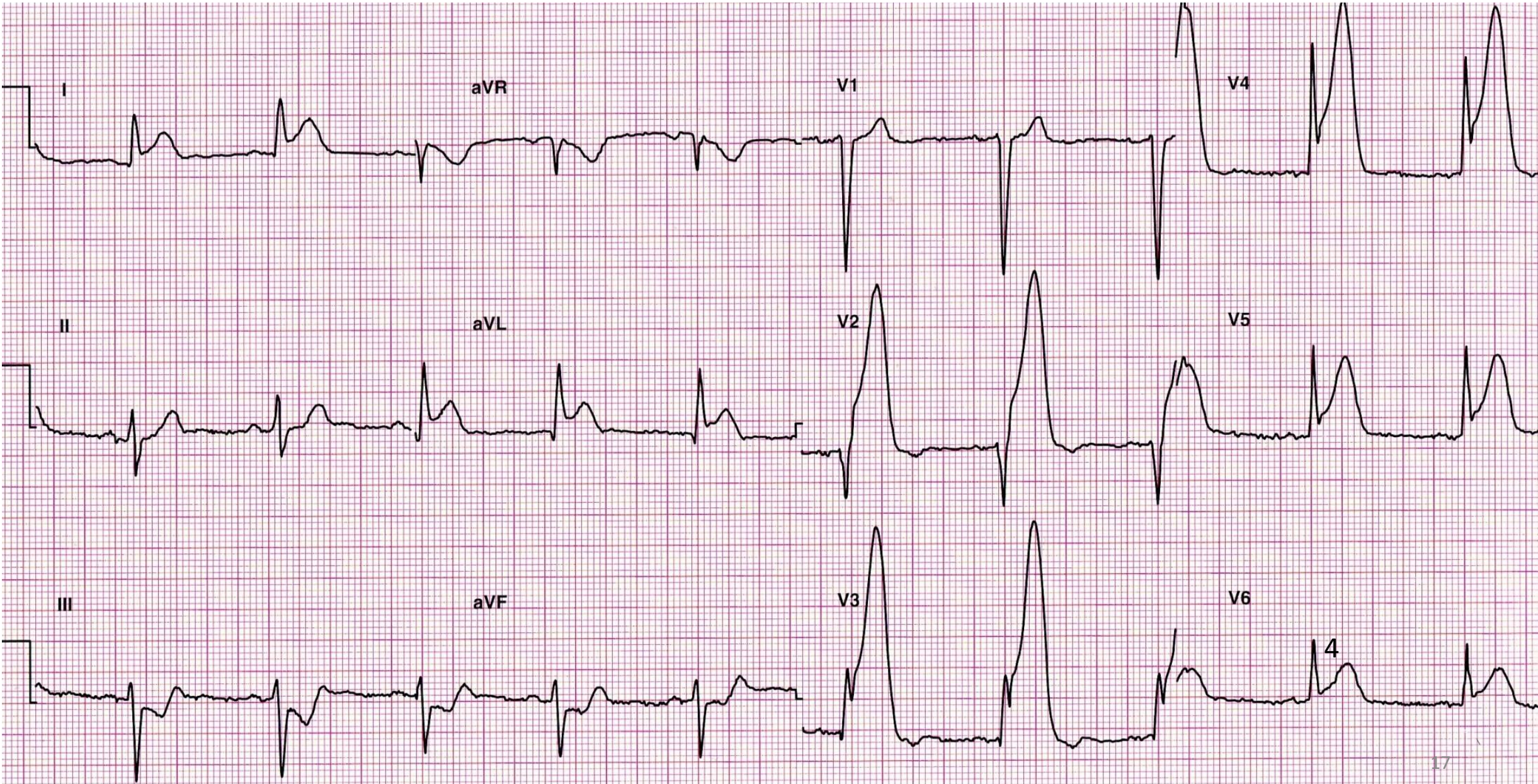
Slide 88 – Myocardial Infarction - Example



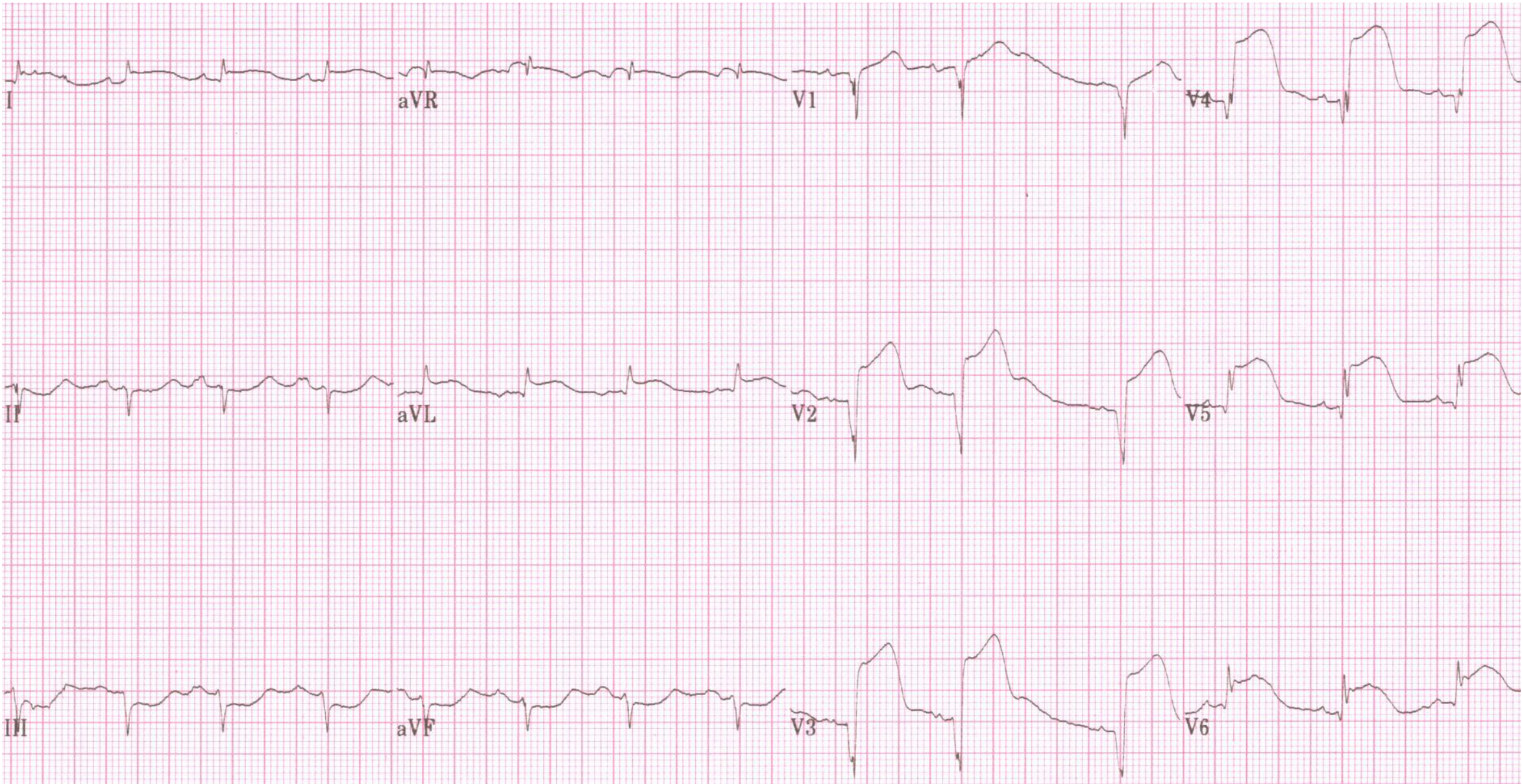Slide 90 - Practice



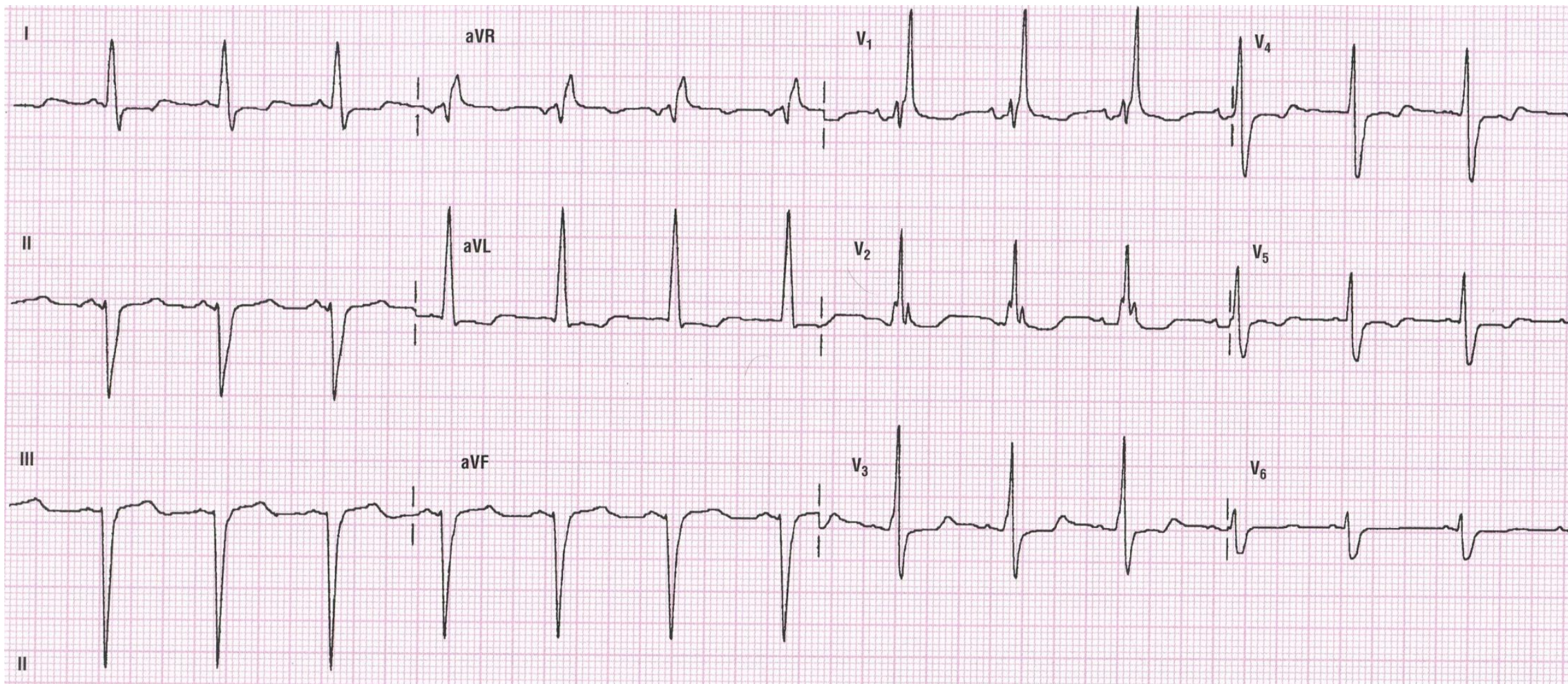
Slide 91 – Practice



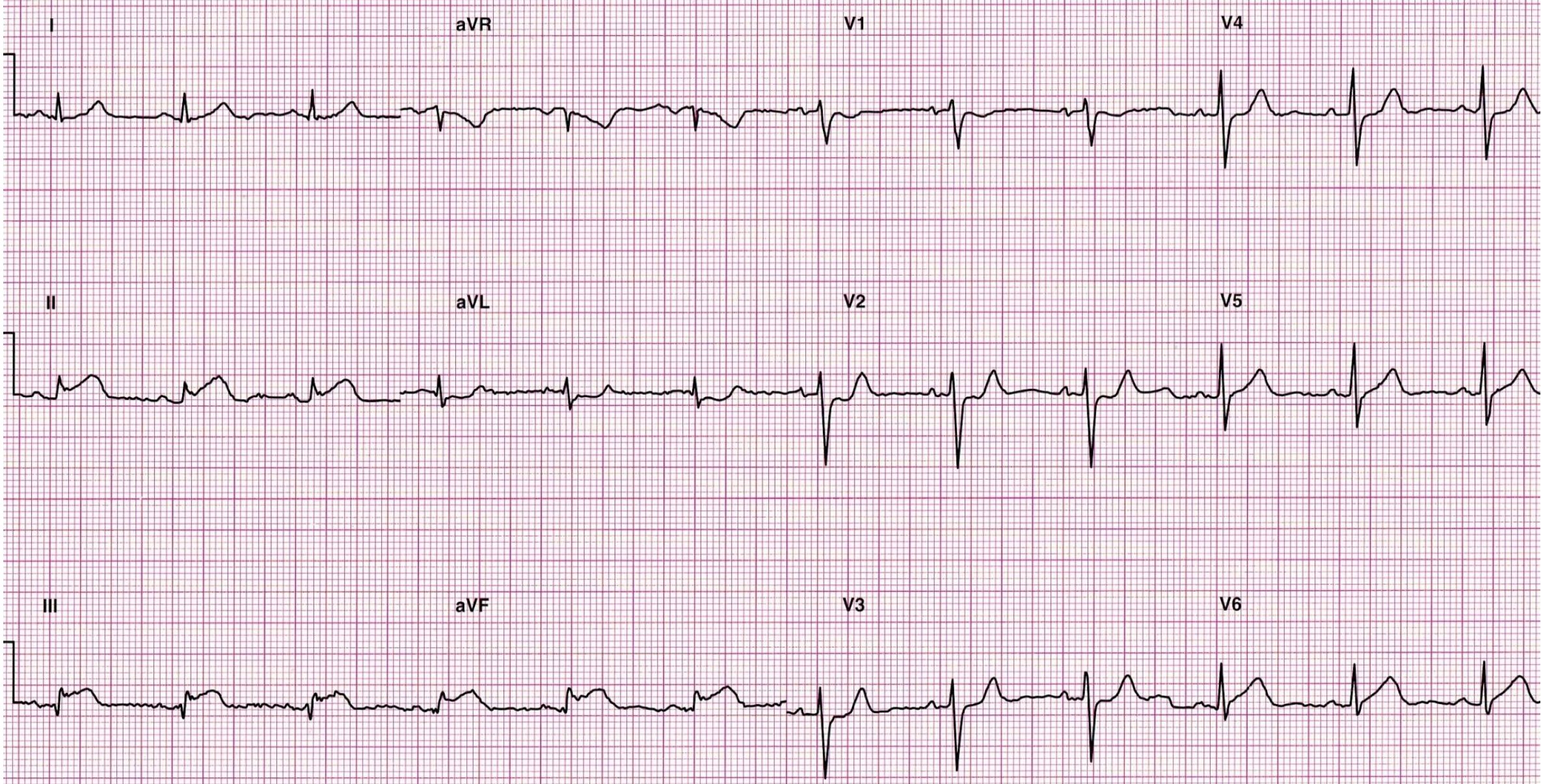
Unknown #1



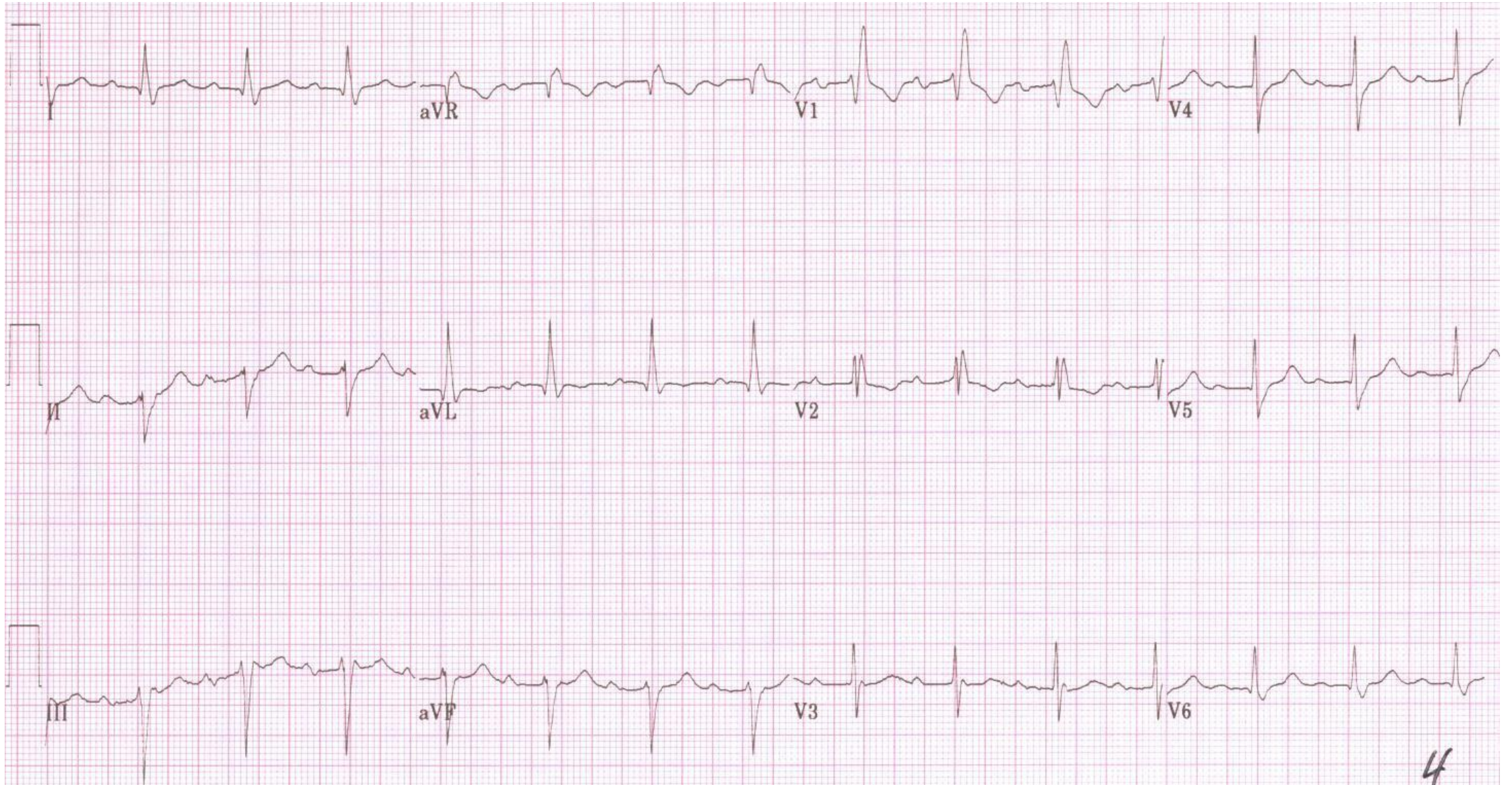
Unknown #2



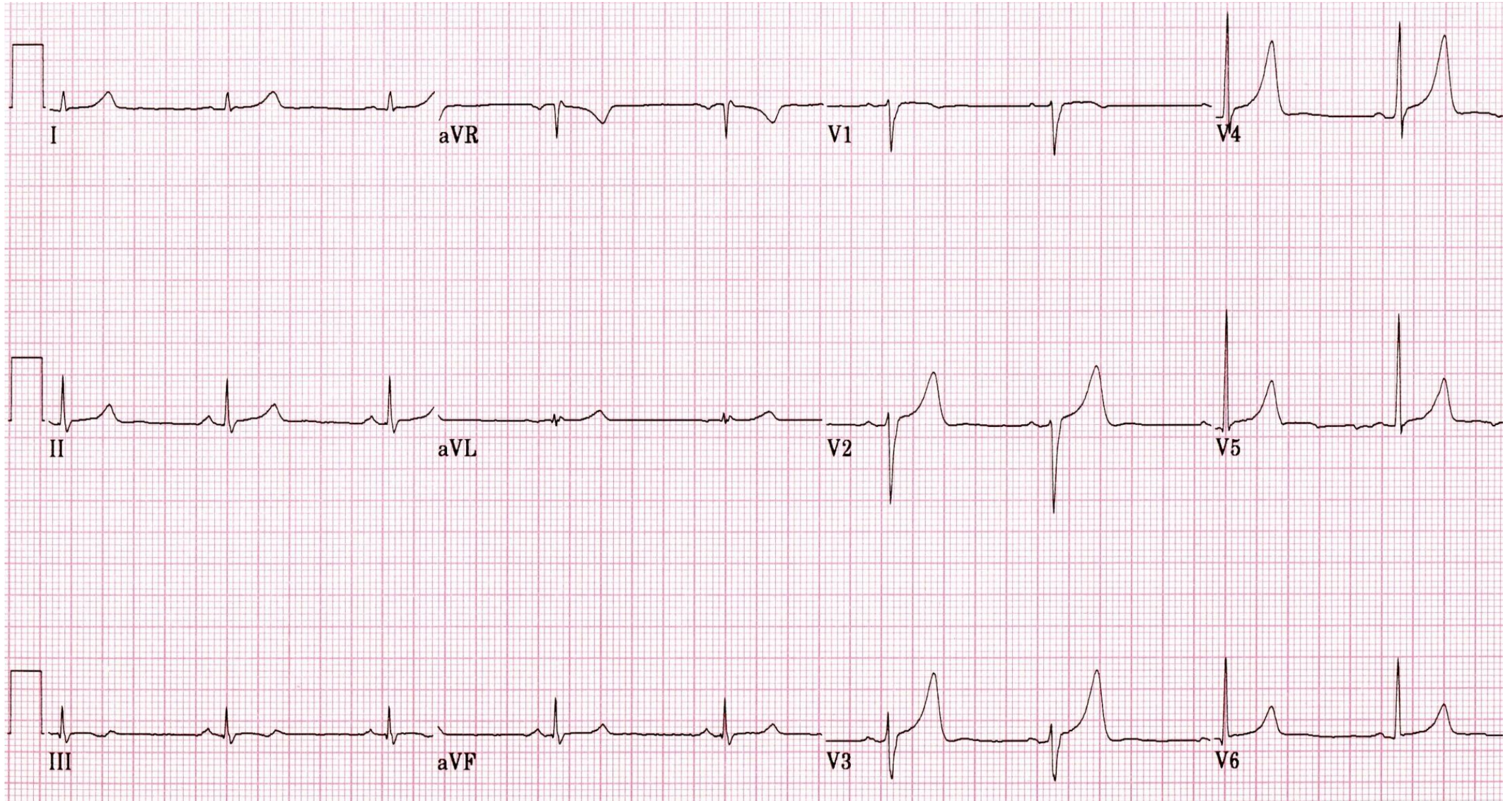
Unknown #3



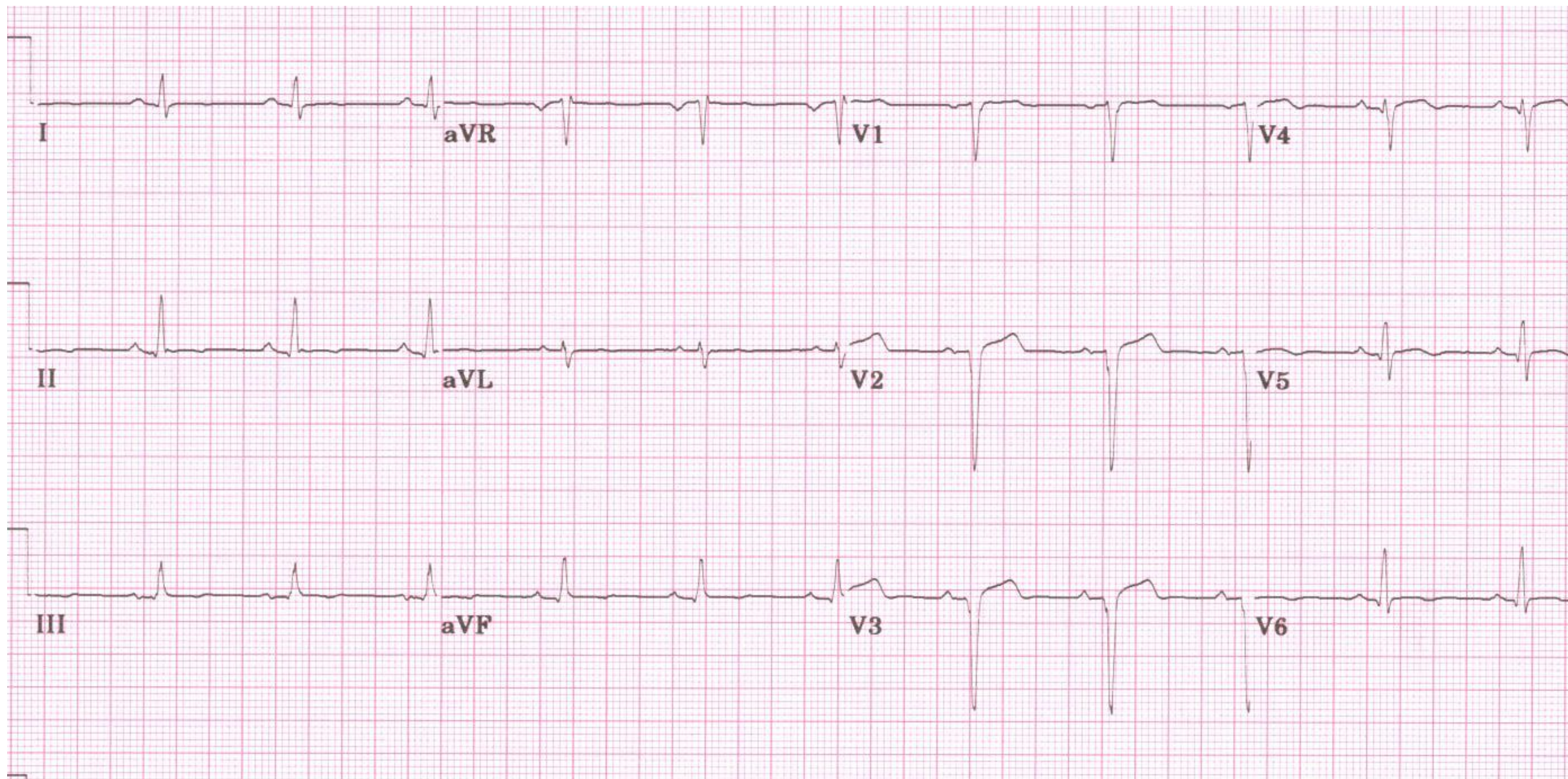
Unknown #4



Unknown #5



Unknown #6



Unknown #7

