

Neuro Emergencies: Recognition and Management Beyond FAST

Brie Marks, PA-C
Physician Assistant – Plastic and
Reconstructive Surgery
St. Luke's University Health Network

1

Disclosures:

No relevant commercial relationships to disclose

2

Objectives

At the end of this session, participants should be able to:

- Define neurological emergencies and explain the importance of early recognition of the pathology discussed
- Identify potential points of intervention before a patient deteriorates from neurological injury or disease
- Recognize the utility of imaging studies when suspecting neurological emergencies and identify which diagnostic tool is most appropriate
- List common pathogens associated with bacterial and viral meningitis and encephalitis and identify treatment considerations for special populations
- Summarize the common neurological emergencies discussed, including recognition of signs and symptoms that pathology is worsening

3

Key Terms:

- Focal examination – a neurological examination that is abnormal in regard to mental status, motor, sensory, gait, etc
- Lateralizing features - neurological examination abnormalities that can be attributed to one neurovascular territory or nerve distribution

4

Case 1

- 37 year old female with no pertinent PMH presents to the emergency department due to erratic behaviors starting 2 days ago. In the ED, she is screaming and accusing staff of kidnapping her. She is febrile and diaphoretic but physical exam is otherwise unremarkable.
- During your examination, the patient suddenly loses consciousness and then has a generalized tonic-clonic seizure.

5

What are the first steps for stabilizing this patient?

6

After initial stabilization, what is the best next step
in treatment for this patient?

- A). MRI of the brain
- B). Lumbar puncture
- C). Initiate IV antibiotics and anti-viral medications
- D). STAT psychiatry consultation

7

Answer:

Initiate IV antibiotics and antiviral medications

Why?

- This patient is presenting with classic symptoms of HSV encephalitis, which has a high incidence of mortality and needs to be treated emergently
- MRI B requires logistical coordination and will take at least 30 minutes, CT head is more appropriate for this patient
- Lumbar puncture should NEVER be performed in a patient with altered mental status or concern for a mass lesion prior to obtain a CT head
- This patient' presentation of altered mental status, fever and seizure is more concerning for an infectious process rather than a psychiatric emergency

8

CNS Infections (meningitis & encephalitis)

- A). Clinical signs and symptoms
- B). Recognition of bacterial vs viral meningitis
- C). Diagnostic evaluation
 - Imaging evaluation
 - CSF studies
- D). Treatment and supportive care

9

Meningitis vs Encephalitis

Meningitis – inflammation of the membranes surrounding the brain and spinal cord

Encephalitis – inflammation of the brain parenchyma

Meningoencephalitis – inflammation of the meninges as well as brain tissue

10

CNS Infections: Meningitis

- **Viral is most common, bacterial most deadly.**
- Additional etiologies include:
 - parasitic
 - fungal
 - candidal

Wide range of clinical presentations, from slight headache and neck soreness to clinical sequelae ultimately leading to death

11

Meningitis

- Clinical presentation is classic triad of fever, neck stiffness, and headache
 - 90% of adults will have at least 2 of the following:
 - AMS, fever, nuchal rigidity, rash (most classically with meningococcal meningitis from *Neisseria meningitidis*)
 - about 45% of all patients with meningitis and approximately 58% pneumococcal meningitis will present with classic triad
- Prodromal features are variable but may include respiratory infections, otitis, and lethargy, nausea and vomiting, photophobia, confusion, irritability, seizures

12

Meningitis: Physical Exam

- Complete physical exam including vitals
- Complete neurological exam including reflexes
 - Hyperreflexia often present
- Include fundoscopy to assess for papilledema
- Neck range of motion including chin-to-chest and Kernig's and Brudzinski
 - Kernig's: Patient laying supine, passively flex knee and hip, stretching meninges and causing pain and/or involuntary neck flexion
 - Brudzinski: Patient lying supine, passively flexing neck stretches meninges and causes hips and knees to flex involuntarily

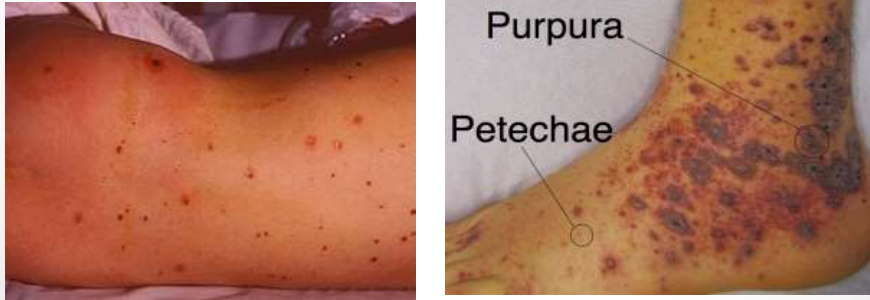
13

Bacterial meningitis

- Generally appear more ill than patients with viral meningitis
- Bacterial organisms most often implicated are:
 - Haemophilus (reduced 2/2 immunization)
 - Neisseria
 - Staph
 - Pneumococcal (strep pneumo most common overall)
- Less commonly implicated agents include:
 - E. coli
 - Klebsiella
 - Pseudomonas
 - Listeria (consider in very young and elderly patients)

14

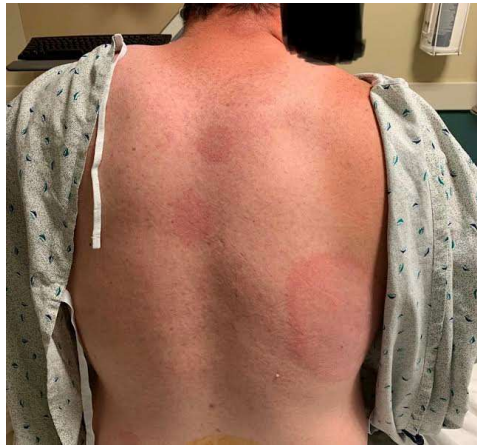Meningiococcal Rash



15

Also, in PA:

- Remember to think of lyme!



*used with patient permission

16

Viral Meningitis

- Viral causes of meningitis include:
 - enteroviruses
 - West Nile
 - Herpes simplex viruses
- **Must rule out HSV encephalitis because this is DEADLY if missed and there is available treatment**

17

Meningitis:Fungal and Candidal infections

- Most commonly seen in immunocompromised individuals (pt's with HIV/AIDS, undergoing chemotherapy, s/p organ transplantation, hematologic malignancy, etc)
 - Cryptococcal meningitis caused by *C. neoformans*
 - With this patient population, include cryptococcal antigen on CSF studies

18

Aseptic Meningitis

- Aseptic meningitis by definition is meningitis in which no causative pathogen has been identified
- Once an etiologic agent has been implicated, "aseptic" meningitis is reclassified according to its cause

19

Encephalitis

- Encephalitis is similar to meningitis in that **viral is most common , bacterial most deadly, with exception of HSV encephalitis**
- **Progressive presentation of**
 - HA, fever → Altered mental status → Delirium & Seizures → Coma → Death
- Like meningitis, etiologies include bacterial, viral, fungal, autoimmune and additionally paraneoplastic

20

CNS Infections: HSV Encephalitis

- **HSV is most common of viral etiologies (10-15%) → 70% mortality if not treated early.**
- HSV clinically typified by acute, progressive AMS (1wk)
- personality changes, bizzare behavior, hallucinations (orbitofrontal & temporal lobe signs) often mistaken for psychiatric illness.

21

CNS Infections: Diagnosis

- Diagnosis is clinical and critical
- **Always check CT head imaging prior to lumbar puncture** if you have any reason to suspect increased intracranial pressure or a focal exam
- Symptoms of increased ICP:
HA, blurred vision, cranial nerve abnormalities, altered mental status, decreased level of consciousness,

Never delay treatment to obtain a LP, but obtain an LP if it can be done **concurrently** to identify causative agent and to guide therapy

22

CSF studies

Will obtain at LEAST

- Protein
- RBC
- WBC with diff
- Glucose
- Culture and gram stain
- Comprehensive PCR (viral panel)
 - Review your hospital system's panel and ensure HSV is included, if not order separately
- Lyme in endemic area (like NE US)
- Consider fungal culture in appropriate clinical scenario
- Opening pressure if suspicious of bacterial or fungal infection

23

CNS infections: treatment

- Empiric Antibiotic Treatments
 - Ceftriaxone & Vancomycin – penetrate CNS
 - Add Ampicillin to cover Listeria
 - (elderly/newborn, pregnant, immunosuppressed)
 - May consider Doxycyclin in Lyme endemic areas, ceftriaxone also covers
- Antifungals for suspicion of fungal infection
- Acyclovir for HSV
 - Encephalitis 10mg/kg Q8h- must be IV 14-21 days
 - Meningitis, 10-14 days and potential for switch to oral dosing
- Consider antiepileptic medications
- Consider Neurology/ Infectious Disease Consultation

24

Use of Corticosteroids

- Adjunctive steroids are effective in reducing inflammation and improving clinical outcomes in some causes of meningitis such as
 - *S. pneumoniae* (mortality)
 - *H. influenzae* (hearing loss)
 - *N. meningitidis* (arthritis)
 - *M. tuberculosis* (mortality)
- Detrimental as in Listeria or Cryptococcus
- Use in viral encephalitis is unclear as there are limited studies.


(Gundamraj & Hasbun, 2020)

25

CNS infections: treatment

- Viral and aseptic meningitis is generally treated supportively only
 - Fluids, pain control, antipyretics
- Exception is HSV as mentioned

26



27

Case 2

- An 80 YOM with a PMH of HTN, DM2, CKD 3 presents to the floor after being admitted for “generalized weakness”. Initial lab values and physical exam are unremarkable with exception of fatigue.
- Over the course of hospitalization, the pt reports increasing difficulty with keeping his eyes open. 2 days after admission, the pt now requires a soft diet, complains of double vision. He now on 4L NC due to desaturation. On morning rounds, you walk into the patient’s room and he is gasping for breath.

28

What is your differential diagnosis?

29

Neuromuscular Paralysis

Guillain-Barre Syndrome/ AIDP
& Myasthenia Gravis

- A). Overview of pathophysiology
- B). Role of respiratory monitoring
- C). Acute treatment recommendations

30

Neuromuscular Paralysis: Myasthenia Gravis

Pathophysiology: autoimmune destruction/blocking of post synaptic acetylcholine (ACh) receptors

- Bimodal distribution
 - F age 15-30 & M age 60-75
- Hallmark is **fatigable weakness** that increases through out the day via depletion of ACh stores
 - Ocular, bulbar, and appendicular limb muscles effected.
 - bulbar - muscles of the lower face, neck and swallowing
 - diplopia & ptosis early primary symptoms in 50-60% patients.

31

Neuromuscular Paralysis: Myasthenic Crisis

Respiratory compromise defines “Myasthenic Crisis”

- This can occur rapidly in this patient population

Management of Crisis

- Follow NIF & VC values, continuous spO₂.
 - NIF (-20) & Forced vital capacity (12-15 ml/kg)
 - Neck flexion and extension are a bedside test for need for intubation – if a patient can't hold their head up well – intubate

• Avoid steroids in acute exacerbation

- May worsen symptoms and lead to crisis
- Steroids are often part of long term immunomodulation, continue home doses on admission

○ Adjustment of or initiation of cholinesterase inhibitors (most commonly pyridostigmine/ Mestinon) may be helpful to avoid crisis

- Common side effects of nausea/ vomiting/ diarrhea/ increased saliva, rhinorrhea

32

Intravenous Immunoglobulin (IVIG)

- **The exact mechanism of action is not clearly understood**, one thought is that the by increasing the number of antibodies that the immune system encounters, there is reduced ability for the immune system to attack the autoantibodies which are causing symptoms

Pros:

- Less invasive than PLEX, usually 1 treatment a day x 5 days, requires shorter hospital stay
- Overall less expensive than PLEX

Cons:

- If IVIG is used first and is not effective, plasmapheresis will “wash” tens of thousands of dollars out of the blood.
- Questionably less effective than PLEX

33

Plasma Exchange or Plasmapheresis (sometimes called “PLEX”)

○ Used to treat immune mediated diseases by removing the patients blood and filtering out plasma, which contains autoantibodies (these are what the body is attacking).

○ Fresh plasma is then added back as the blood re-enters the patient's body

○ The goal of PLEX is to reduce symptoms and disease burden as the harmful autoantibodies are removed

Pros:

- Considered to be fastest and most powerful treatment to regulate autoantibodies in some disease courses (specifically Myasthenia Gravis)

Cons:

- Requires large bore catheter (usually in the IJ)
- Treatments are generally done for every other day for a total of 5 treatments – requires extended hospital stay
- Follow Fibrinogen (keep >100) and calcium prior to each treatment

34

Neuromuscular Paralysis:

Guillain-Barre Syndrome/Acute Inflammatory Demyelinating Polyradiculoneuropathy (AIDP)

Pathophysiology: s/p viral, bacterial or mycoplasmal illness or less commonly a vaccination, immune systems attacks myelin sheath and ganglions due to molecular mimicry

“Confusion” off immune system wherein nerve cells are targeted due to similar biochemical structure with viral/ bacterial particles

35

Neuromuscular Paralysis:

Guillain-Barre Syndrome/Acute Inflammatory Demyelinating Polyradiculoneuropathy (AIDP)

Presentation:

- Typically ascending symptoms (starting at toes and moving upward)
 - Phrenic nerve (C3,4,5) → Diaphragm involvement & intercostal respiratory muscles → crisis
- Motor predominance but sensory variants & combinations do occur
 - **CAN be painful!****
- Loss of reflexes almost universal
- Autonomic function often impaired


36

Neuromuscular Paralysis:

Guillain-Barre Syndrome

- History & physical exam – reflexes (extremely important)
- LP demonstrates Albumino-Cytological dissociation
(**Isolated** increased protein without increased WBCs)
- Electrophysiological studies (EMG) – usually as an outpatient
- Follow serial respiratory functions tests
- Plasma exchange vs IVIG
- No role for steroids

37



38

Case 3

- An 23 year old male with a history of epilepsy walks into your urgent care after having a seizure at home. He says he feels better now and just needs you to refill his medications, which he hasn't taken in 2 weeks because 'he forget to get the script filled.'
- While he is being triaged, he has another seizure in the lobby lasting approximately 1 minute. Afterward, he is groggy and uncooperative. 2 minutes later, he seizes again which does not resolve on its own after 2 minutes.

39

Is this patient in status epilepticus?

How should you proceed?

40

Status Epilepticus

A). Definition of Status epilepticus

B). Review of American Epilepsy Society phases of Status Epilepticus and treatment options

41

What is a seizure?

- Sudden burst of electrical activity in the brain
- May be:
 - Localized, affecting only one area of the brain
 - Generalized, affecting the entire cerebrum concurrently or
 - Begin as a focal seizure and then “spread” to the rest of the brain (secondary generalization)
- Generalized tonic-clonic seizures indicate involvement of both cerebral hemispheres – will present with loss of consciousness, shaking/ jerking, increased muscle tone, and is often accompanied by incontinence and tongue bite

42

Status Epilepticus: Definition

Definition per the American Epilepsy Society:

- Single seizure lasting > 5min
- Serial seizures > 30 min, with no return to baseline.

Treatment of seizures in practice:

Most seizures are self limiting, and last less than 1 minute.

The longer a seizure lasts, the less likely it is to stop on its own, and the greater the propensity toward excitotoxicity leading to permanent neuronal damage.

Therefore, regardless of definition, if a seizure does not stop on it's own after approximately 1 minute, intervention is advised. If a patient continues to seize, escalate care

43

Status Epilepticus: Treatment

Remember ABC's first, then medications

- Initial lab work to assess for electrolyte abnormalities/ hypo- or hyperglycemia, UDS, infection
- CT scan without contrast

IV Lorazepam 0.1mg/Kg (max of 2 mg/min) or Diazepam 0.15 mg/ Kg IV up to 10mg per dose, (max 5mg/ min) or Rectal or IM diazepam

If no resolution:

- Fosphenytoin 20mg/ Kg at 100-150 mg PE (phenytoin equivalent)/ Min OR
- Valproic acid 30mg/kg at 10mg/kg/min OR
- Levetiracetam 60mg/kg (max of 4,500) over 15 min OR
- Phenytoin 20 mg/kg at 25-50/ min (CAUTION with bradycardia/ hypotension)


If no resolution at this stage, likely intubation if not already completed, and STAT neurology consultation

44

Status Epilepticus: Additional considerations

- Subclinical status - definition
 - Focal or generalized seizure activity that does not cause abnormal movements - presentation may be only confusion or lethargy.
- Always obtain an EEG on a post-ictal patient that is unresponsive or does not return to baseline as expected.
- Continuous EEG with video may be helpful to identify subclinical status epilepticus or to electrographically categorize seizure-like activity
- Determine underlying etiology as able for all seizure types

45



46

Case 4

- A 70 year old male with a remote history of migraine headaches comes into your outpatient clinic for a sick appointment. He tells you that he has been experiencing worsening headaches over the past week and they are becoming unbearable. His wife in the room says that she's noticed that the pt has become more forgetful recently and has been getting angry with her frequently, which is unlike him. She asks you to please treat his headaches because she "wants her old husband back."
- Physical exam is unremarkable except that pt states that the year is "2015" (in 2021).

47

What is the best course of action for this patient?

- A). Advise OTC pain relief and rest
- B). Order an outpatient CT head and advise pt to follow up with you in 1 month
- C). Arrange transport for the pt to ED for STAT imaging
- D). Order an outpatient MRI and advise pt to follow up in 1 week

48

Answer:

C). Arrange transfer for pt to the ED for STAT head imaging.

- In this patient population, new onset and progressively worsening headaches, as well as personality changes are a red flag for intracranial pathology such as malignancy.

49

“Dangerous” Headache

A). Primary vs secondary headache

B). Review updated guidelines of when to image with new onset headache (NEJM update Jan, 2020)

50

“Dangerous” Headache

- Primary vs secondary
 - Primary – headache itself as cause of pain (migraine, tension, cluster, etc).
- Secondary mnemonic
 - Systemic signs & symptoms (weight loss, night sweats, etc)
 - Neurological signs
 - Onset (of actual HA –sudden/ thunderclap? Waking from sleep? Positional?)
 - Older age of patient with new HA onset (> 50 yo)
 - Prior HA history but new presentation
 - Progression of HA
- **Signs of secondary HA - obtain imaging**

51

FIRST – new onset headache in very young or older adult, or new presentation headache in a patient with a headache history

- Concern for mass or bleeding

WORST - “worst headache of my life”

- Concern for aneurysm or intracranial bleed

CURSED -Neurological deficits (weakness, etc), loss of consciousness, fatigue, nausea, night sweats, neck stiffness, fever

- Concern for mass, bleed, meningitis/ encephalitis, abscess

52

Special Populations

- In hypercoagulable patients including in pregnancy, concern for venous sinus thrombosis - venous drainage is blocked, increasing ICP
- History of malignancy
- Immunocompromised patients
- Exertional headache
- Subacute head trauma
- Elderly patients and children

- Migraine or other chronic headache patients without new features or new neurological deficits do *not* require imaging

53

Headache Imaging

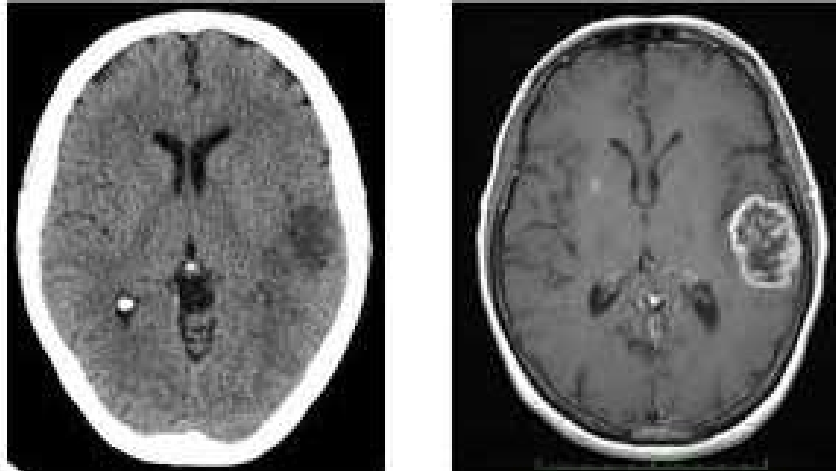
- First - obtain CT head without contrast – will see blood, edema and compression

- If necessary based on clinical context, obtain neurovascular imaging (CTA or CTV head and neck if concerned about thrombus)

- CT Head with contrast with concern for abscess or tumor, however
 - MRI brain is most sensitive test and will be needed prior to neurosurgery or other intervention if not emergent

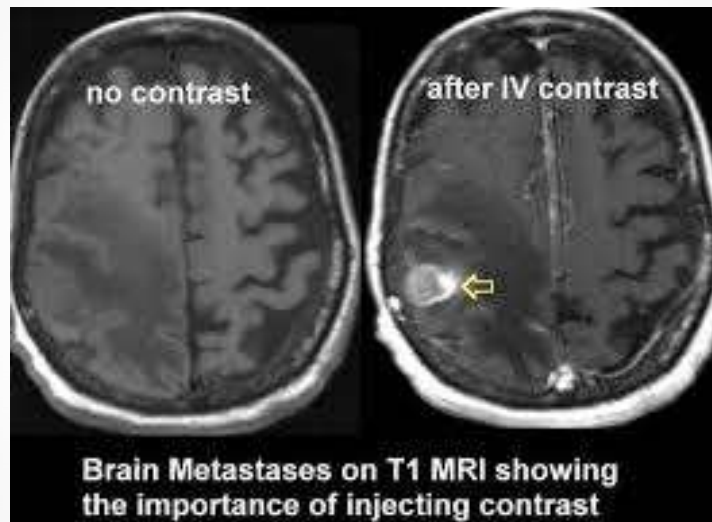
54

CT Without Contrast vs MRI with Contrast



Quora.com

55



Quora.com

56



57

Case 5

- A 45 year old with a PMH of schizophrenia, IV drug use, and multiple psychiatric inpatient hospitalizations presents to your ED. Pt reports a chief complaint of “leg weakness” and “my back hurts”. She was able to ambulate into the ED. This is the 3rd time you have seen her in your ED this month.
- On initial examination, vital signs are stable. Labs unremarkable except for a WBC count of 15k. Physical exam is positive for diffuse tenderness to palpation of the pt’s back below T12 and 4/5 weakness with dorsiflexion. You reassess the pt in 2 hours and the pt is now unable to move her feet and says her back pain is worse.

58

What is the appropriate next step for this patient?

- A). Pain medication and reassess in 1-2 hours
- B). STAT MRI and alert Neurosurgery
- C). Admit to medicine with physical therapy consultation
- D). non-emergent Orthopedic consultation for suspected hip bursitis

59

Answer:

STAT MRI and neurosurgical consultation.

Why?

- Pt demonstrates bilateral, progressive weakness with fever and leukocytosis. This is concerning for epidural abscess leading to cord compression.
- If this patient does not have surgical emergent surgical decompression, she is at risk of permanent neurological damage including paralysis.
- An MRI will better characterize the pt's spinal pathology to guide intervention.

60

Acute Spinal Cord Trauma and Compression

- A). Signs and symptoms
- B). Imaging modality of choice (MRI)
- C). Need for emergent surgical intervention
- D). Role of steroids

61

Spinal Cord Compression

Acute and potentially irreversible damage to the spinal cord caused by

- Epidural Abscess
- Epidural hematoma
- Tumors
- Degenerative changes with acute worsening
- Trauma

62

Spinal Cord Compression

- Localized severe pain, followed by radicular pain in the limbs
- As compression progresses:
 - Sensory level and neurologic deficits (decreased or absent sensation and weakness at level of dermatome and below)
 - Generalized weakness/instability of limbs with myelopathic features (changes in reflexes most common)
 - Urinary retention and constipation (cauda equina)

63

Spinal Cord Compression

- Cord deficit can originate from any level above above the lesion (example – cervical spine compression causing lower extremity weakness)
- If upper extremities are involved, defect must originate in the C spine (or brain)
- **If you see bilateral sensory and/or motor loss, think spine first!**
 - Example (decreased bilateral hand grip)

64

Spinal Cord Compression

- Imaging modality of choice is MRI
 - **One of the very few times we order STAT MRI**
 - MRI with contrast only if concern for tumor or abscess
- Ortho vs Neurosurgery consult
 - Emergent decompression
- Steroids in case of epidural metastasis
- Slow growing tumors will occlude vascular supply and produce symptoms.
 - Decadron 10mg IV q 4-6hrs
 - consult to Radiation Oncology
- **Role of steroids for acute cord compression without tumor:**
 - **Current evidence advises against the use of high dose steroids as they have not been shown to reduce morbidity or mortality (Lui et al, 2018)**

65

Spinal Cord Compression

"Neurogenic Shock":

- Autonomic dysregulation following disruption of neural pathways transmitted by the spinal cord after an acute trauma (commonly above T6) - generally occurs with 30 minutes of spinal trauma
- Depending on level of injury, may lead to hypotension due to vasodilation, bradycardia, inability to regulate body temperature

"Spinal Shock:

- Transient loss of tone and reflexes below the level of an acute spinal injury.

66

Take home points

- Neurological emergencies can occur in any practice setting and early recognition and intervention is key to preserving life and function.
- Sudden changes in neurological function require immediate investigation.
- Though the majority of seizures resolve without intervention, a seizure that does not self resolve has a high probability of evolving into status epilepticus and should be treated.
- Recently updated guidelines provide clear indications for obtain imaging in patients with headache.
- Bilateral weakness or sensory changes are suspicious for spinal compression until proven otherwise.

67

Questions?

Brie Marks, PA-C

Briemarks@gmail.com or

Brienne.marks@sluhn.org

Instagram: @briemarks_pa

68

References

- Dave, S., & Cho, J. J. (2020). Neurogenic Shock. In *StatPearls*. StatPearls Publishing.
- Glauser T, Shinnar S, Gloss D, et al. Evidence-Based Guideline: Treatment of Convulsive Status Epilepticus in Children and Adults: Report of the Guideline Committee of the American Epilepsy Society. *Epilepsy Curr* 2016; 16:48.
- Griffiths, M. J., McGill, F., & Solomon, T. (2018). Management of acute meningitis. *Clinical medicine (London, England)*, 18(2), 164–169.
<https://doi.org/10.7861/clinmedicine.18-2-164>
- Gundamraj, S., & Hasbun, R. (2020). The Use of Adjunctive Steroids in Central Nervous Infections. *Frontiers in cellular and infection microbiology*, 10, 592017.
<https://doi.org/10.3389/fcimb.2020.592017>
- Liu, S., Dong, C., & Ubogu, E. E. (2018). Immunotherapy of Guillain-Barré syndrome. *Human vaccines & immunotherapeutics*, 14(11), 2568–2579.
<https://doi.org/10.1080/21645515.2018.1493415>

69

- Liu, Z., Yang, Y., He, L., Pang, M., Luo, C., Liu, B., & Rong, L. (2019). High-dose methylprednisolone for acute traumatic spinal cord injury: A meta-analysis. *Neurology*, 93(9), e841–e850.
<https://doi.org/10.1212/WNL.0000000000007998>
- Micieli, A., & Kingston, W. (2020, July 23). An Approach to Identifying Headache Patients That Require Neuroimaging. PubMed Central (PMC).
<https://www.ncbi.nlm.nih.gov/pmc/articles/PMC6428716/>
- Rai, S., & Drislane, F. W. (2018). Treatment of Refractory and Super-refractory Status Epilepticus. *Neurotherapeutics : the journal of the American Society for Experimental NeuroTherapeutics*, 15(3), 697–712.
<https://doi.org/10.1007/s13311-018-0640-5>
- Whitehead MT et al. for the Expert Panel on Neurologic Imaging. ACR Appropriateness Criteria® headache. *J Am Coll Radiol* 2019 Nov; 16:S364.
<https://doi.org/10.1016/j.jacr.2019.05.030>
- Wilson, J. R., Tetreault, L. A., Kwon, B. K., Arnold, P. M., Mroz, T. E., Shaffrey, C., ... Fehlings, M. G. (2017). Timing of Decompression in Patients With Acute Spinal Cord Injury: A Systematic Review. *Global spine journal*, 7(3 Suppl), 95S–115S.
<https://doi.org/10.1177/2192568217701716>

70