



MAYO CLINIC

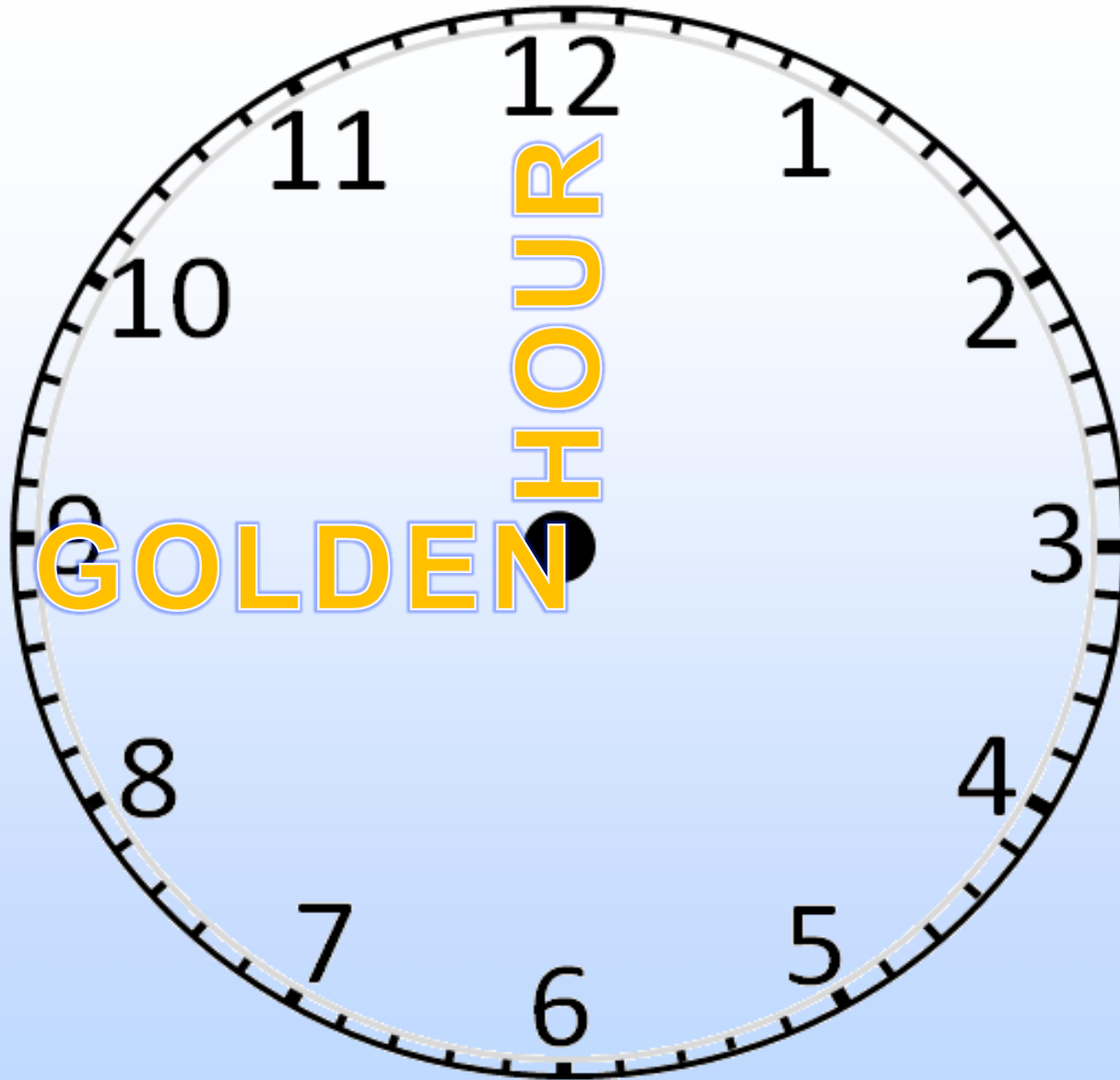
HEALTH SYSTEM

Extended Focused Assessment with Sonography for Trauma (eFAST)

Kyle Burkhamer, PA-C

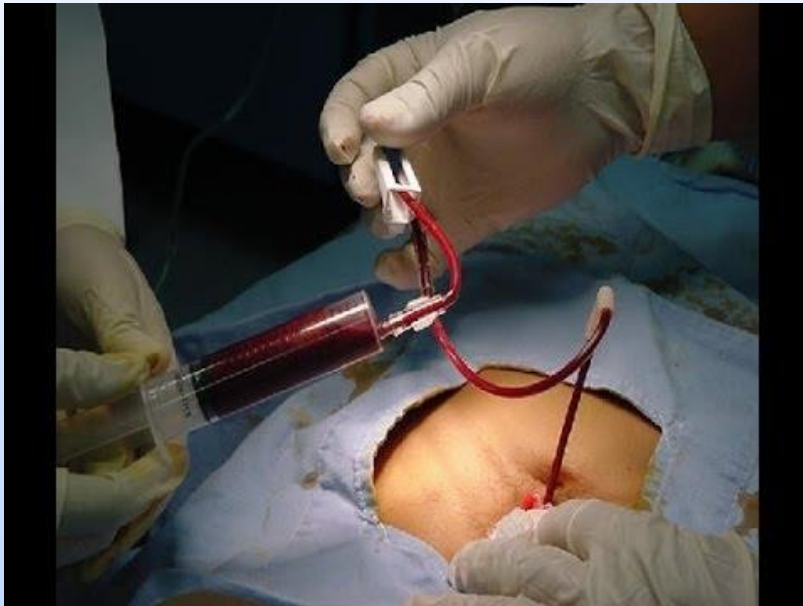Indications

- To **rapidly** evaluate the torso for evidence of traumatic free fluid or pathologic air suggestive of injury in the **peritoneal, pericardial, and pleural cavities**

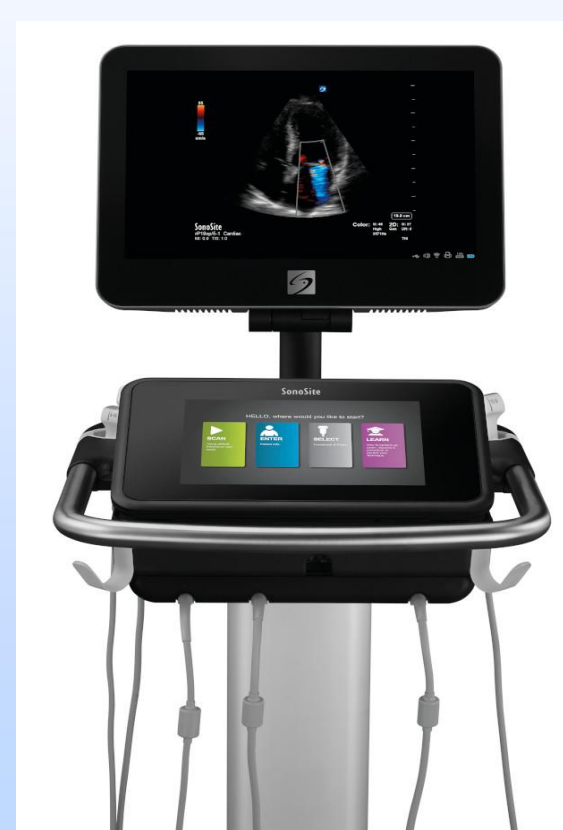

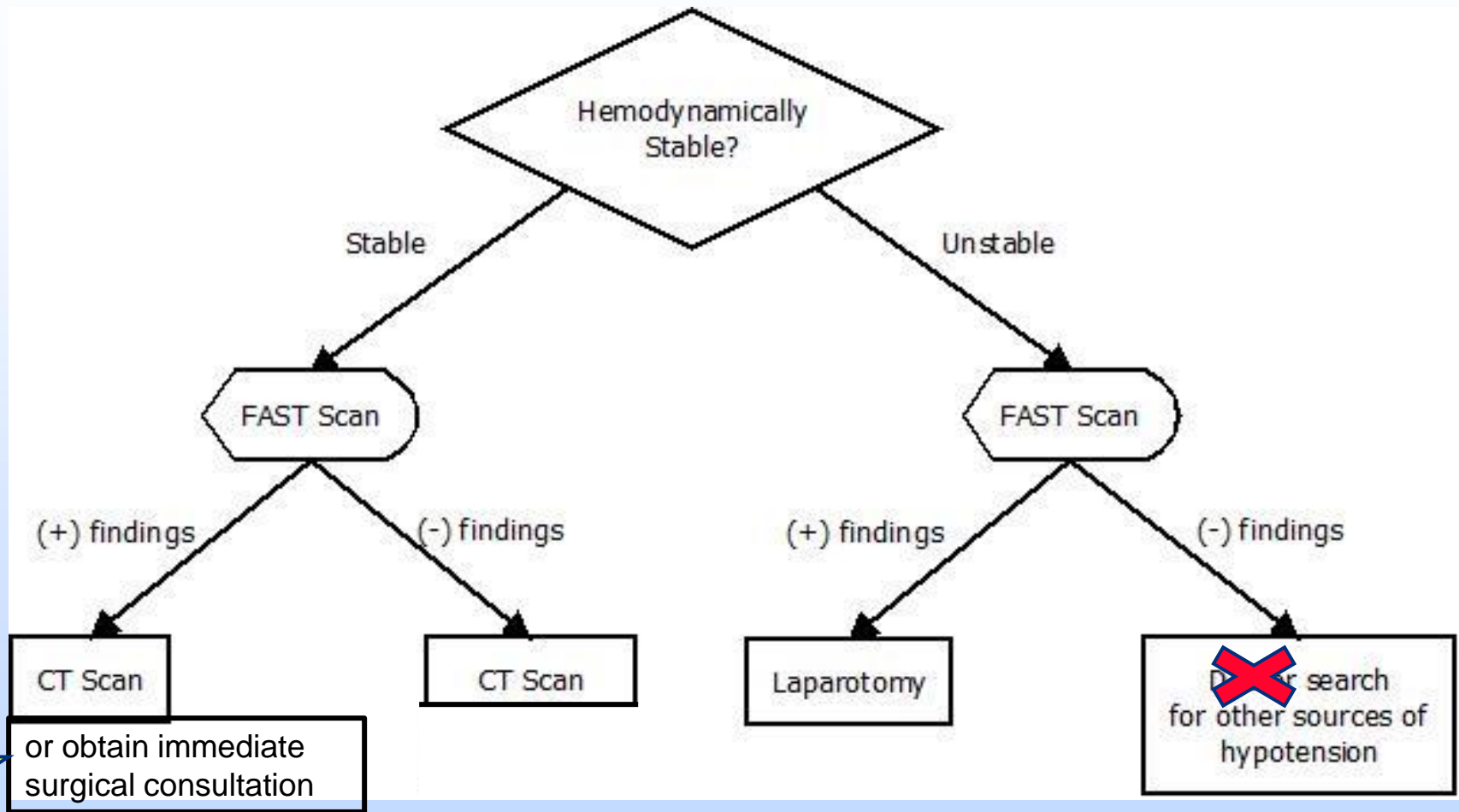
Historical relevance

Then...



Now...



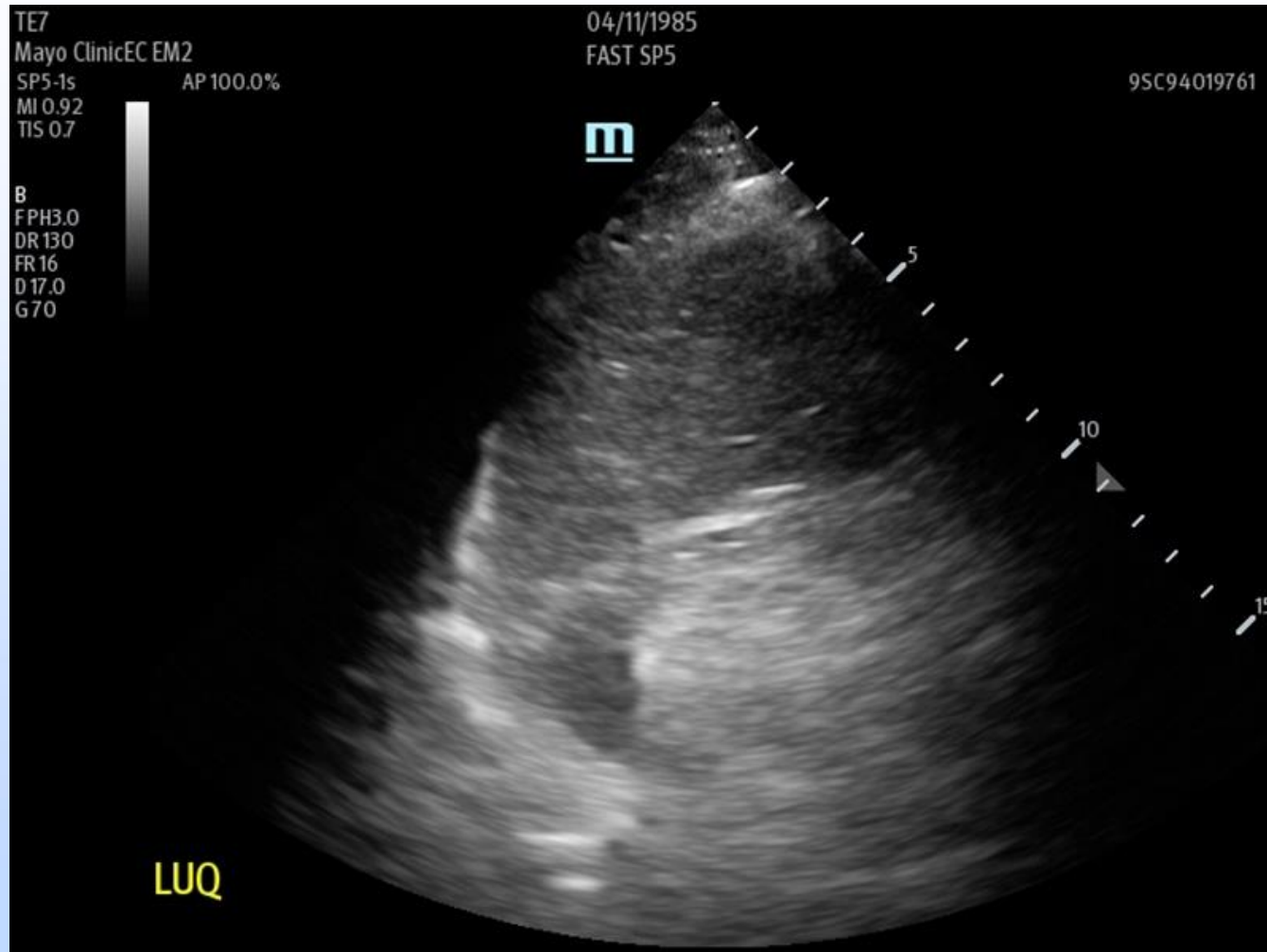


**FAST saves lives,
not CT scans**

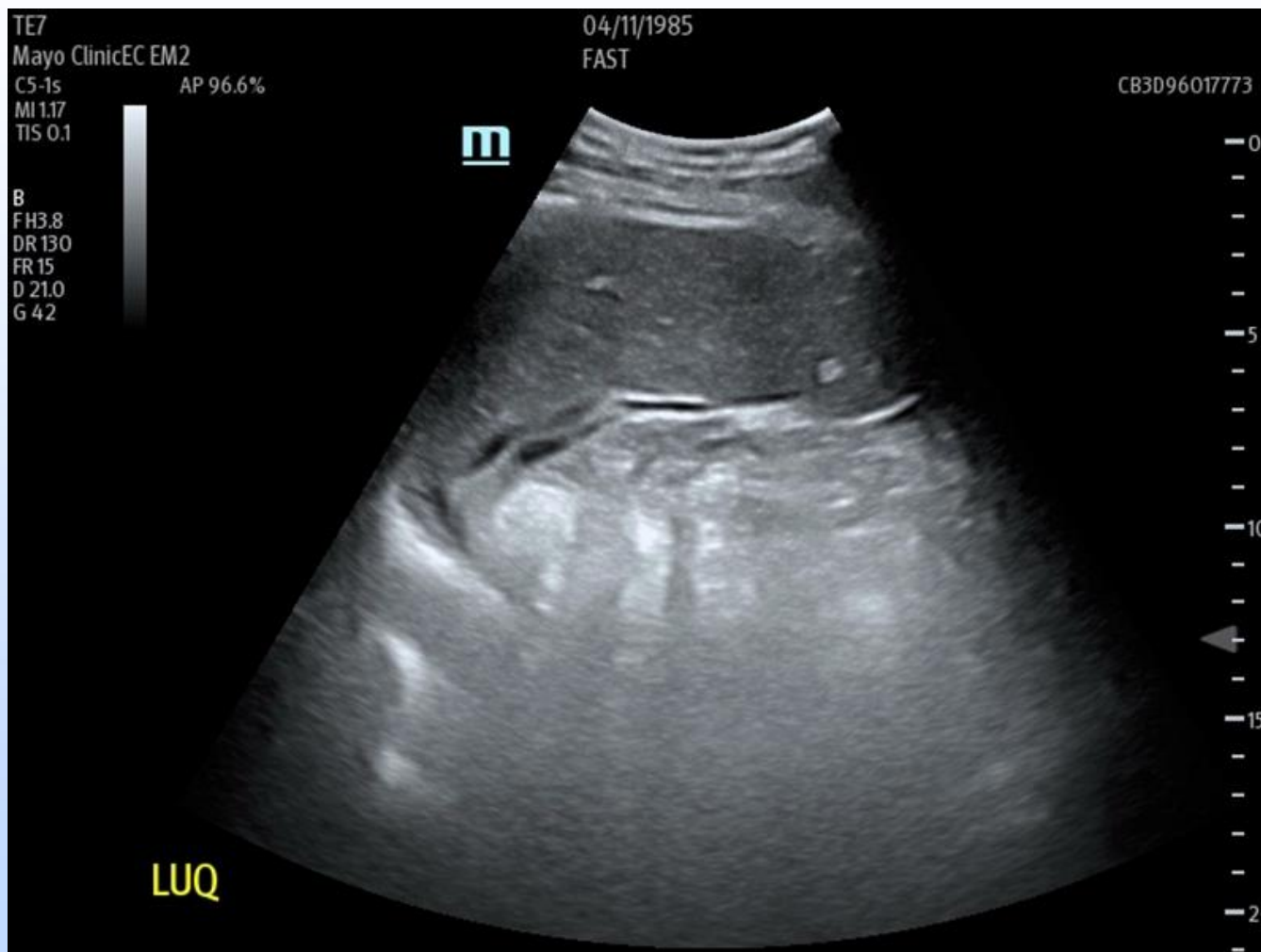
Transducer selection



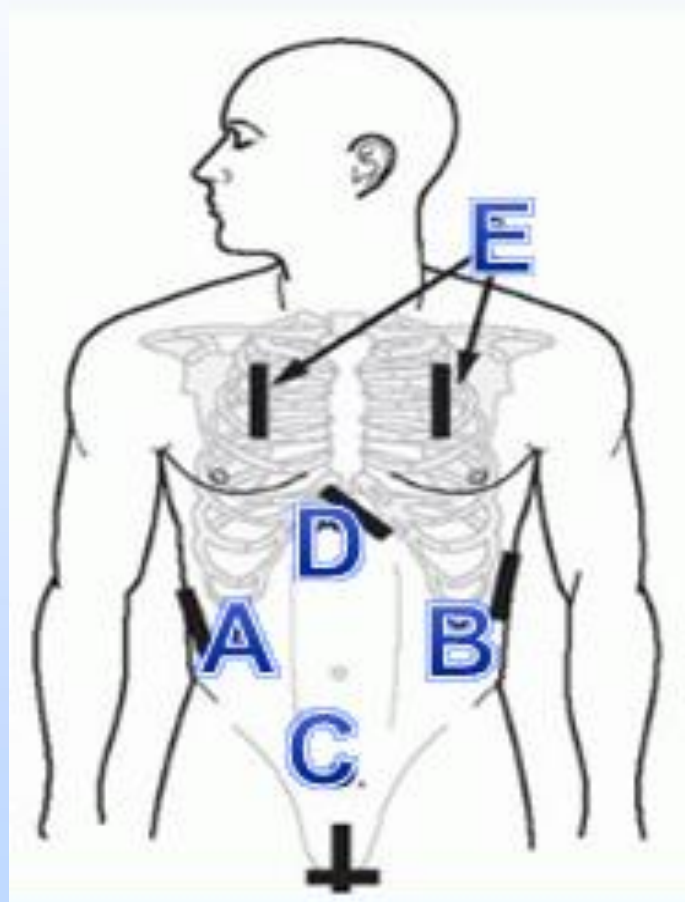
FAST – phased array



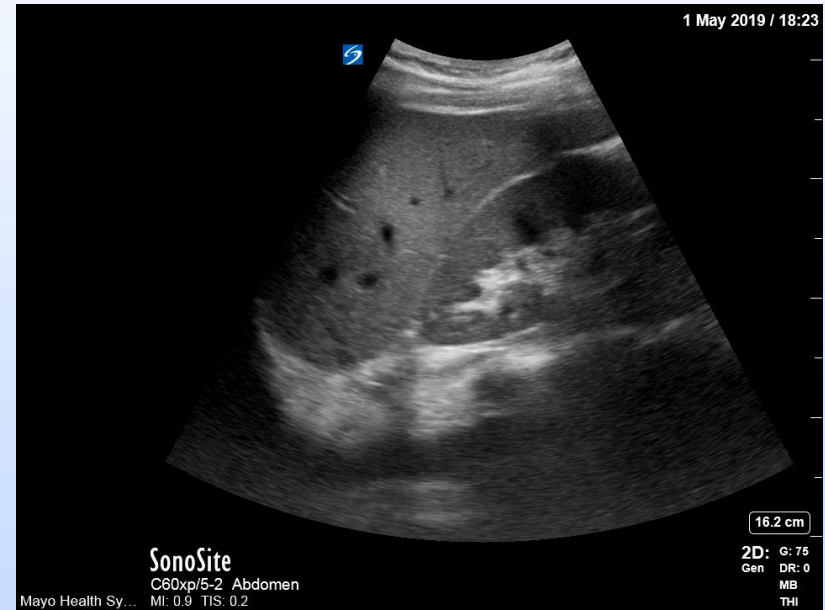
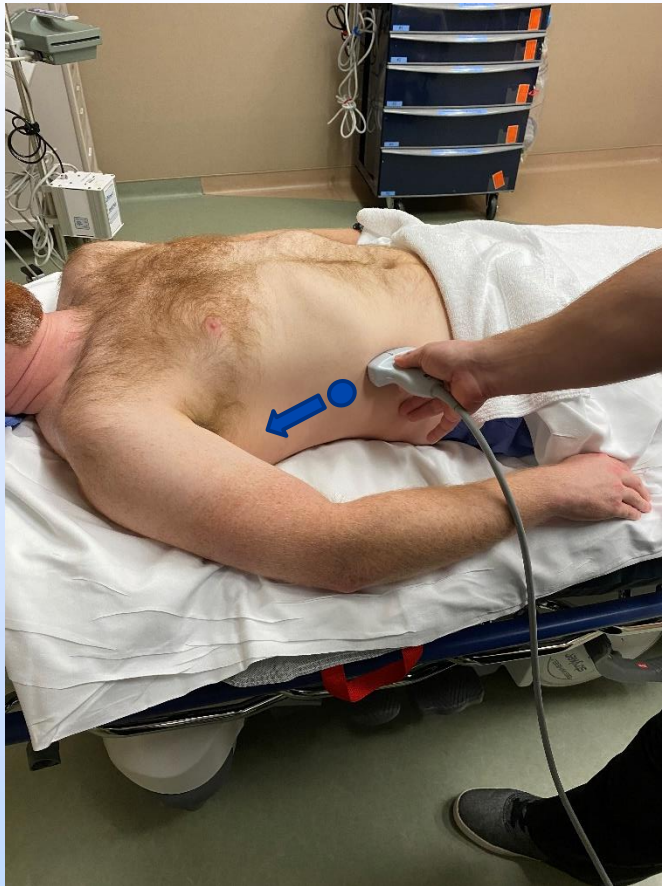FAST - curvilinear



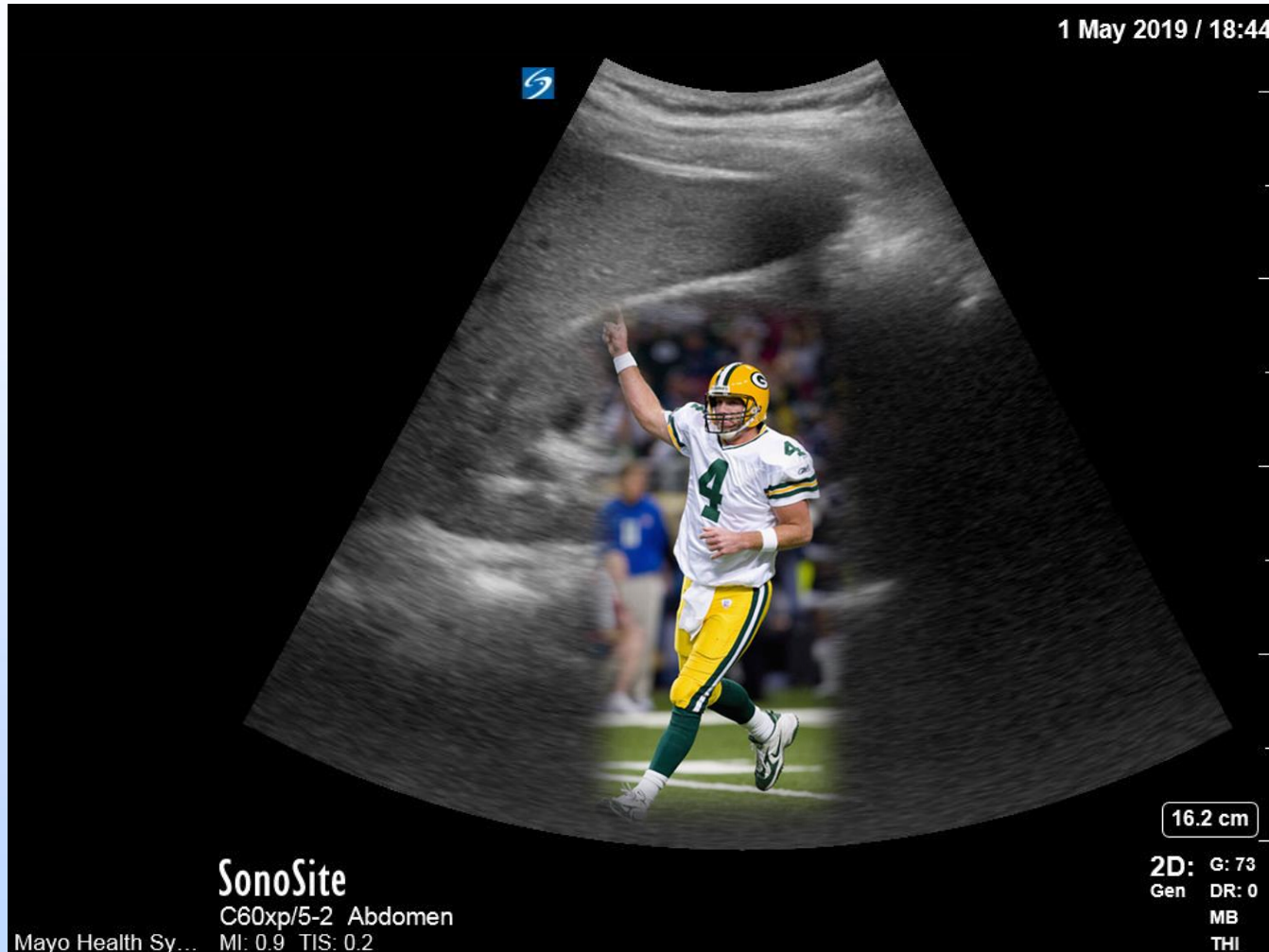Standard views



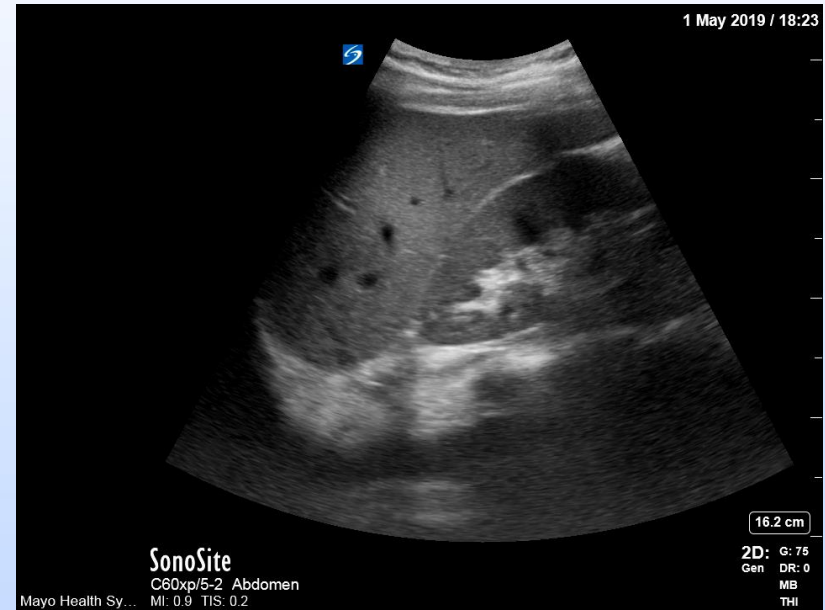
Right upper quadrant (RUQ) view



Morison's pouch



Right upper quadrant (RUQ) view



**Morison's pouch \neq
RUQ view**

- 1) RUQ (67%)
 - 2) Pelvic (48%)
 - 3) LUQ (35%)
- ORIGINAL RESEARCH**
-

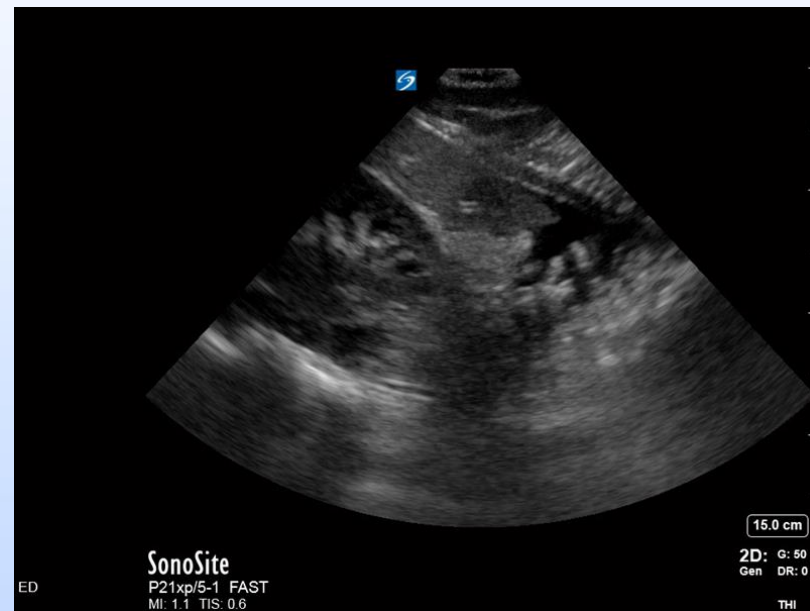
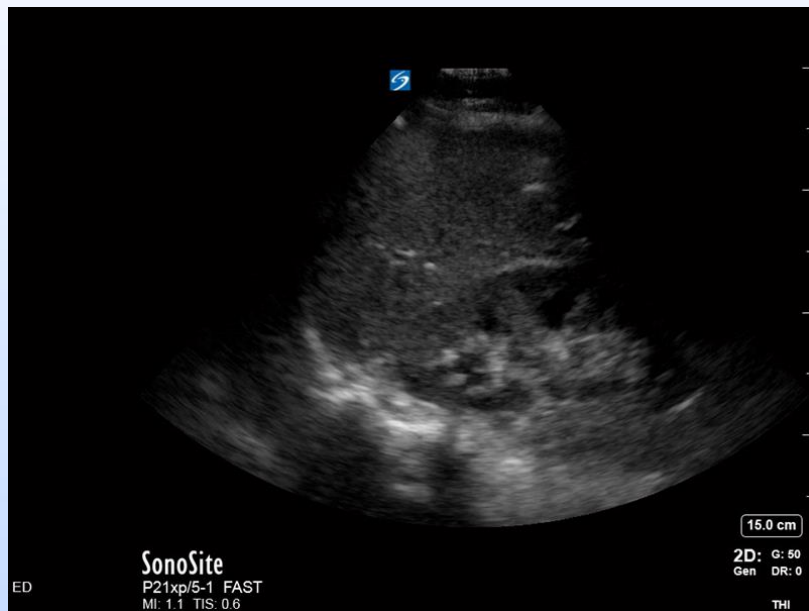
**[REDACTED] in the [REDACTED]
[REDACTED] Is the Most Sensitive Area for
Free Fluid on the FAST Exam**

Viveta Lobo, MD*
Michelle Hunter-Behrend, MD*
Erin Cullnan, MD*
Rebecca Higbee, MD*
Caleb Phillips, MS, PhD†
Sarah Williams, MD*
Philips Perera, MD*
Laleh Gharahbaghian, MD*

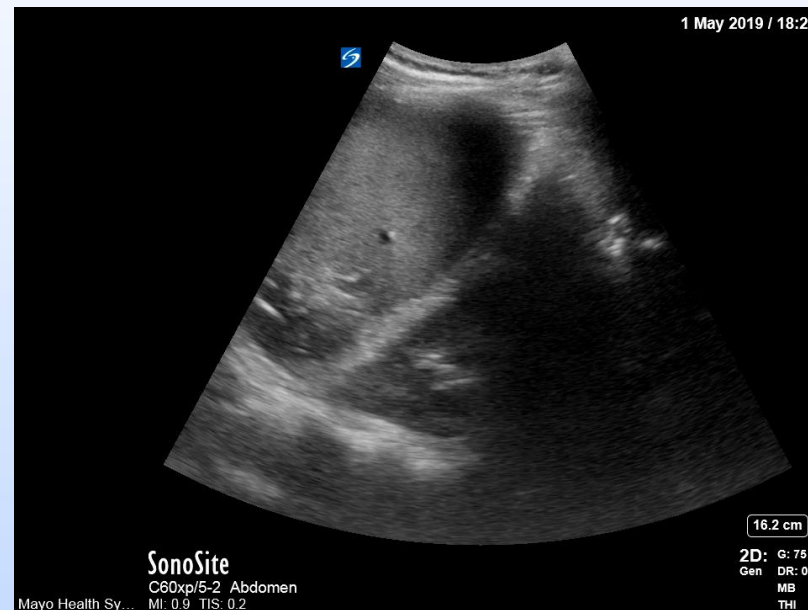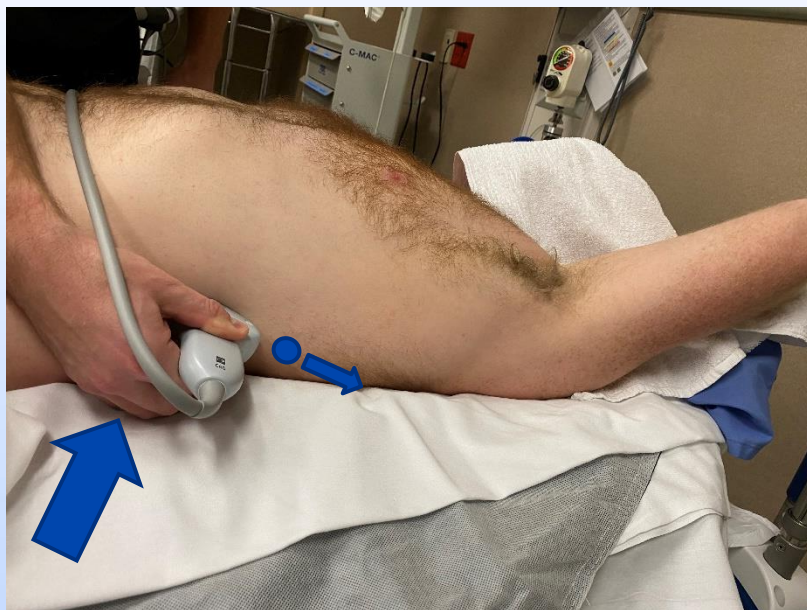*Stanford University Medical Center, Department of Emergency Medicine, Palo Alto, California

†University of Colorado, Department of Computer Science, Boulder, Colorado

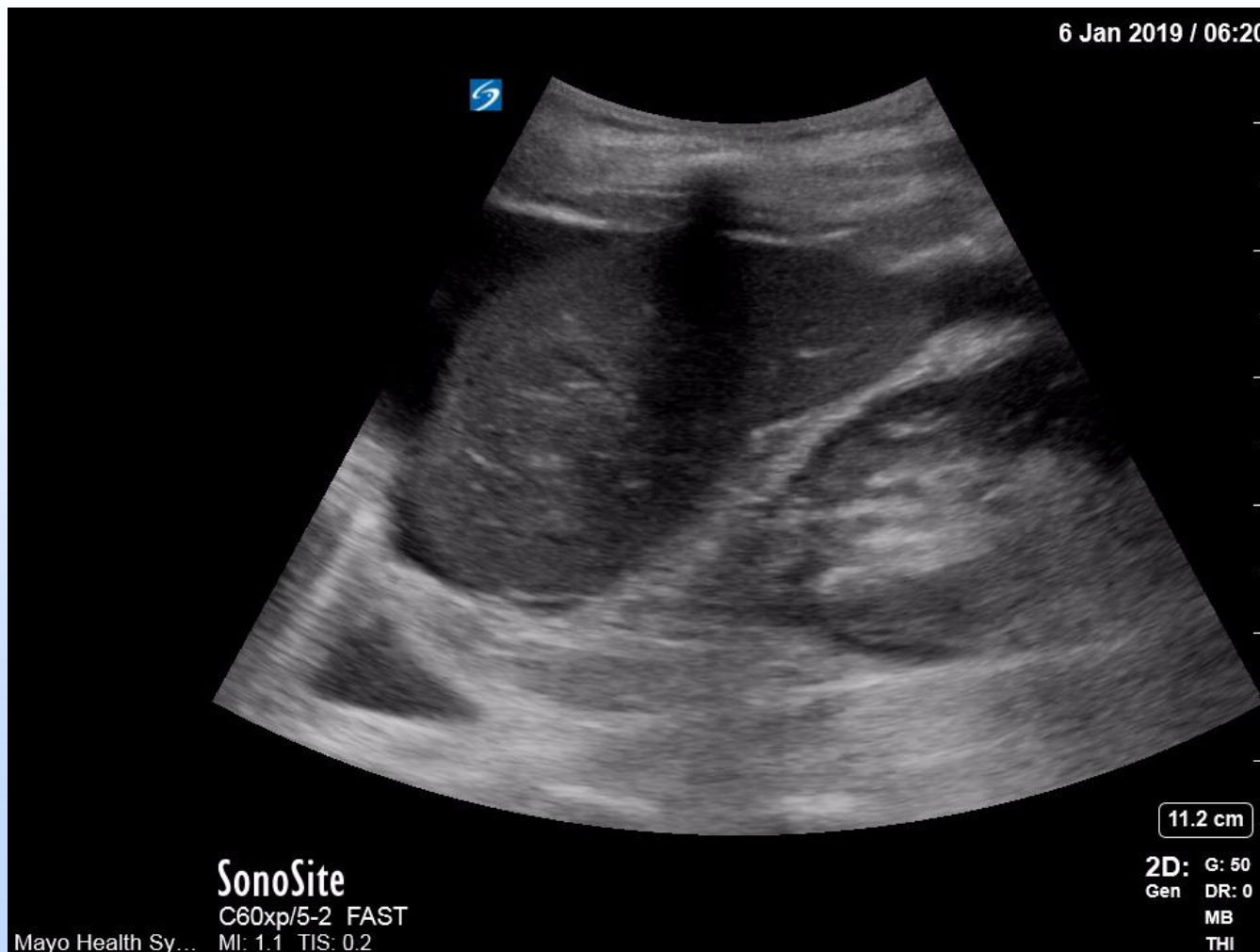
Positive RUQ FAST



Left upper quadrant (LUQ) view



Positive LUQ FAST



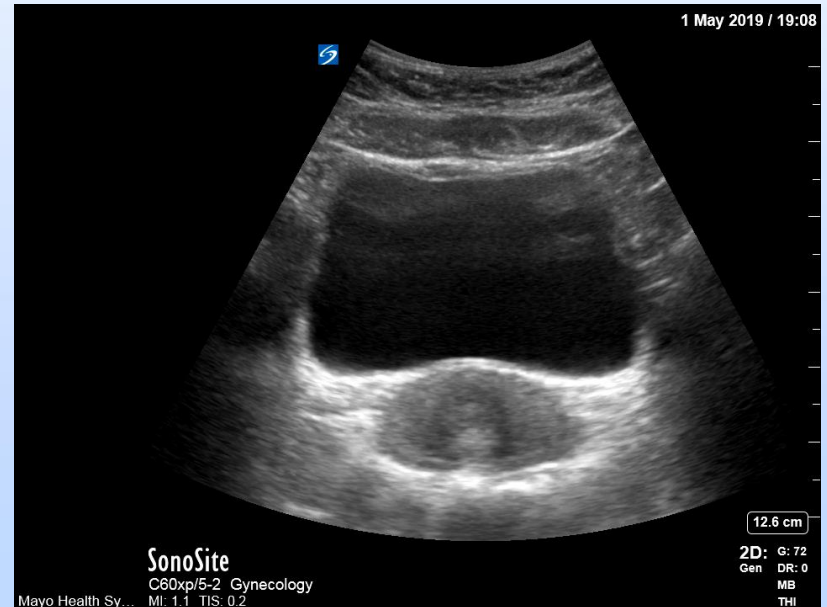
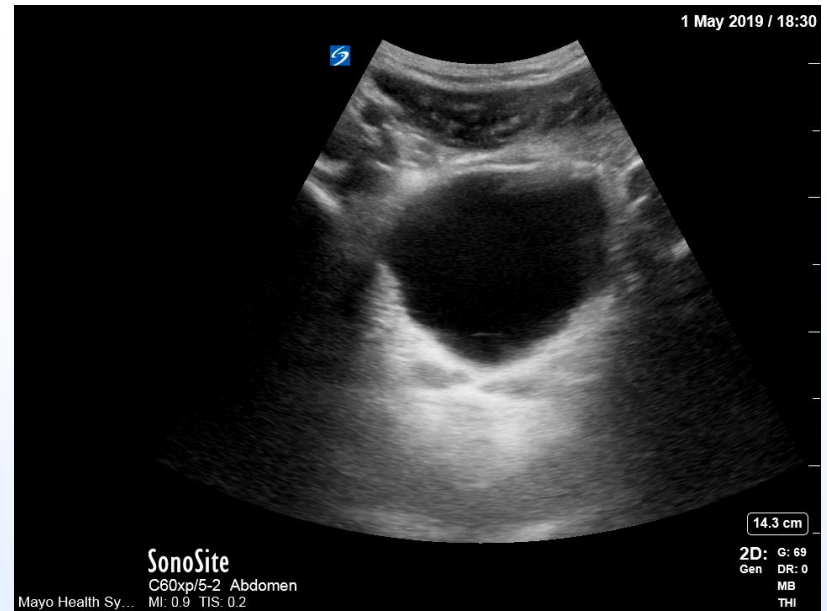
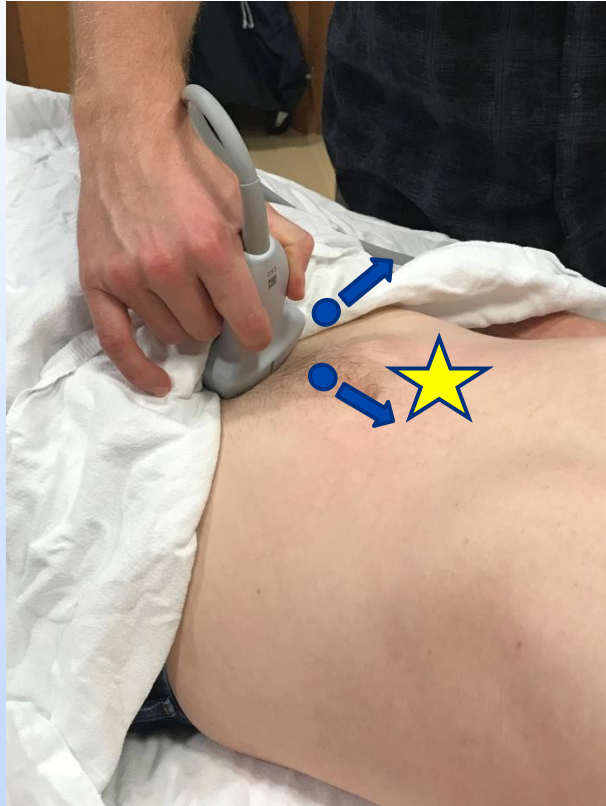RUQ and LUQ exams



Above the diaphragm

**Inferior pole of kidney/
paracolic gutter**

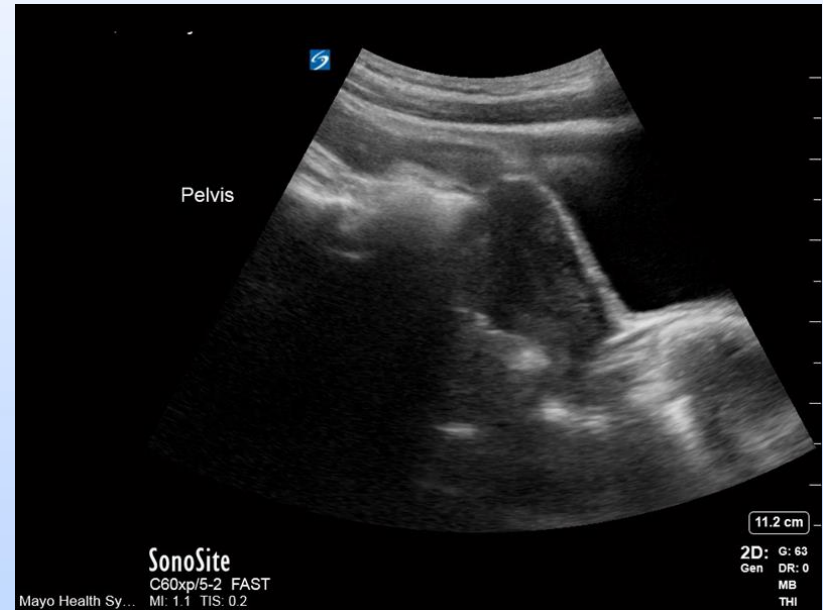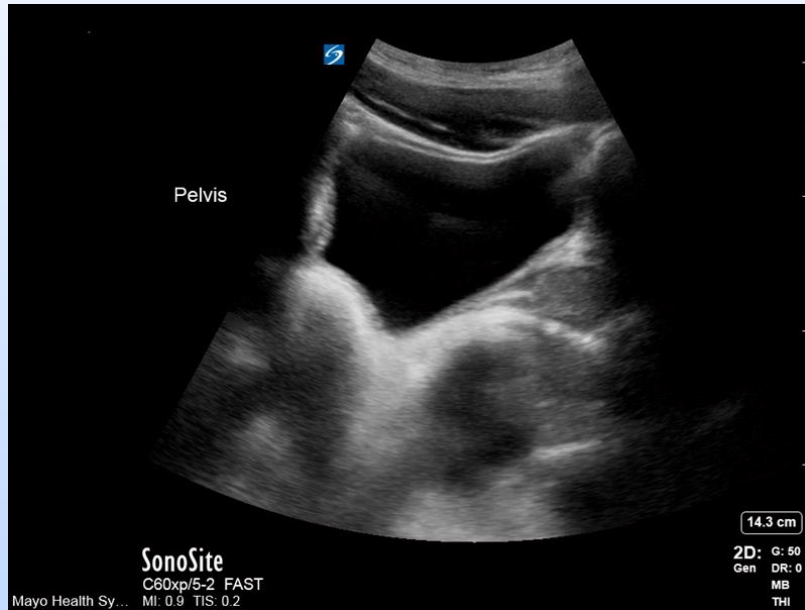
Pelvis view



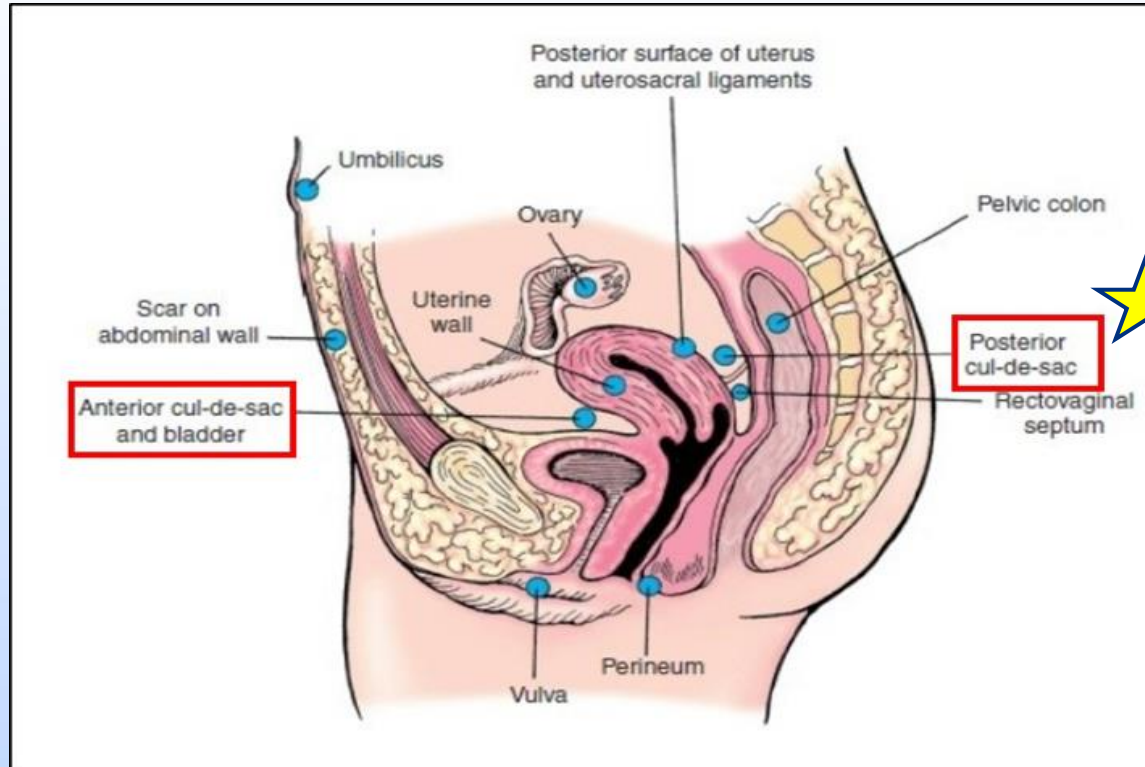
Pelvis view (sagittal)

Male

Female

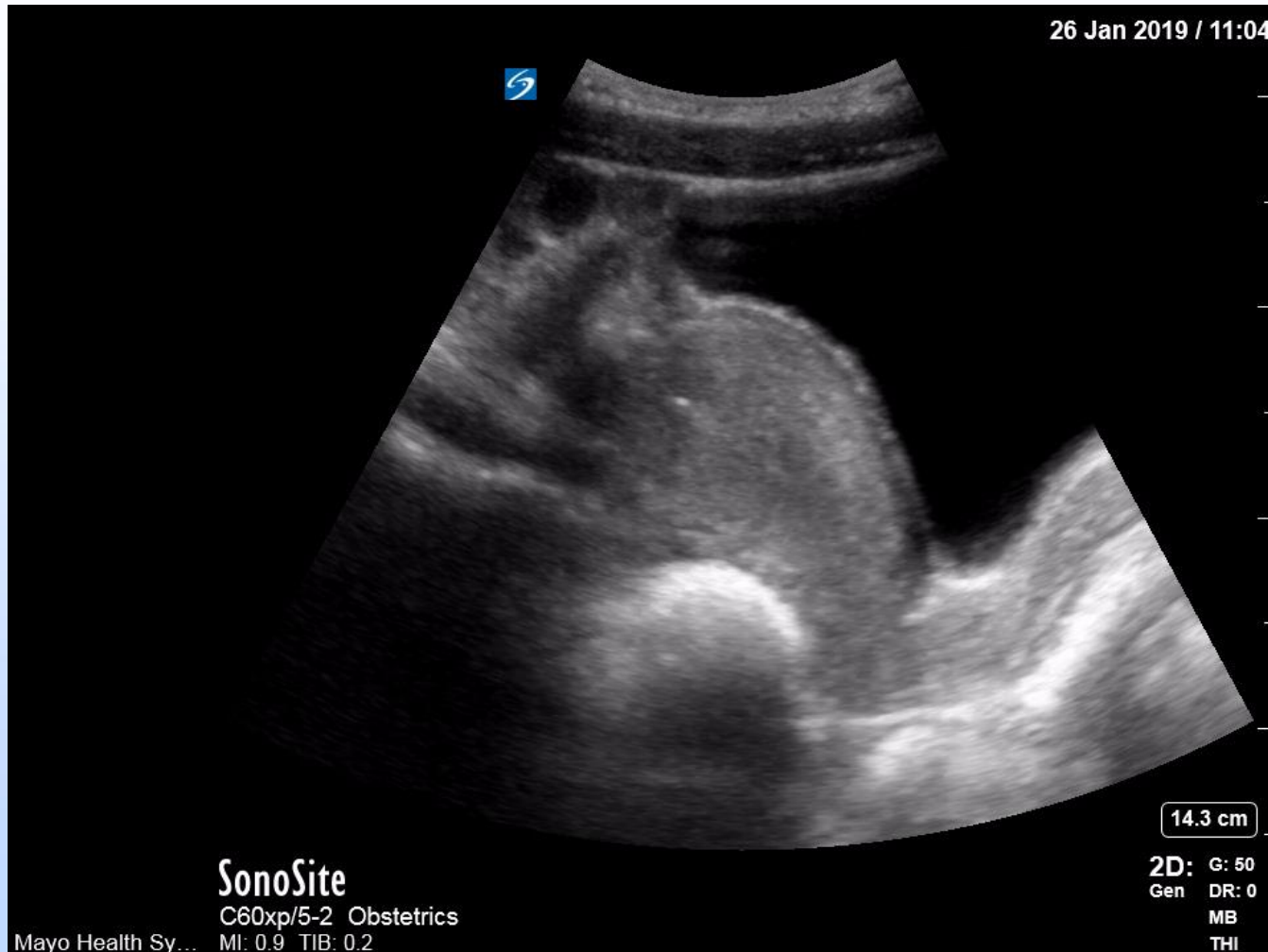


Potential spaces in the pelvis

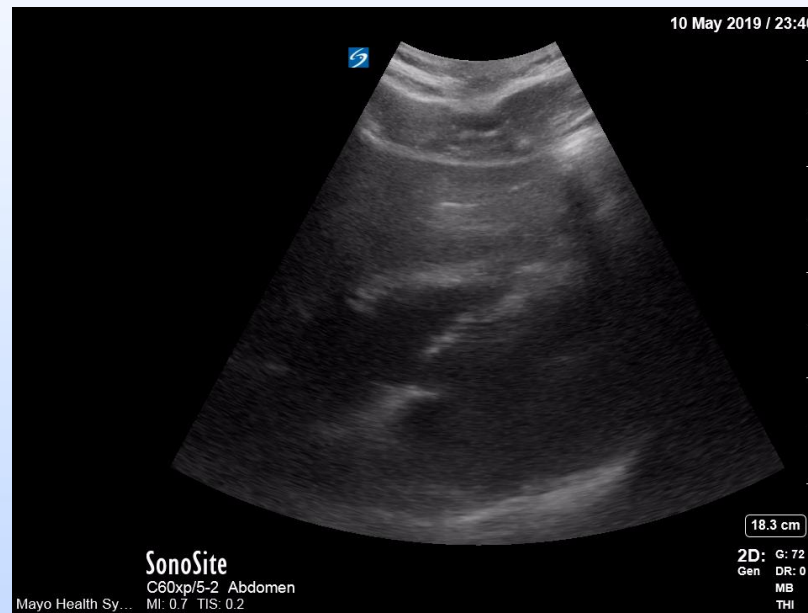
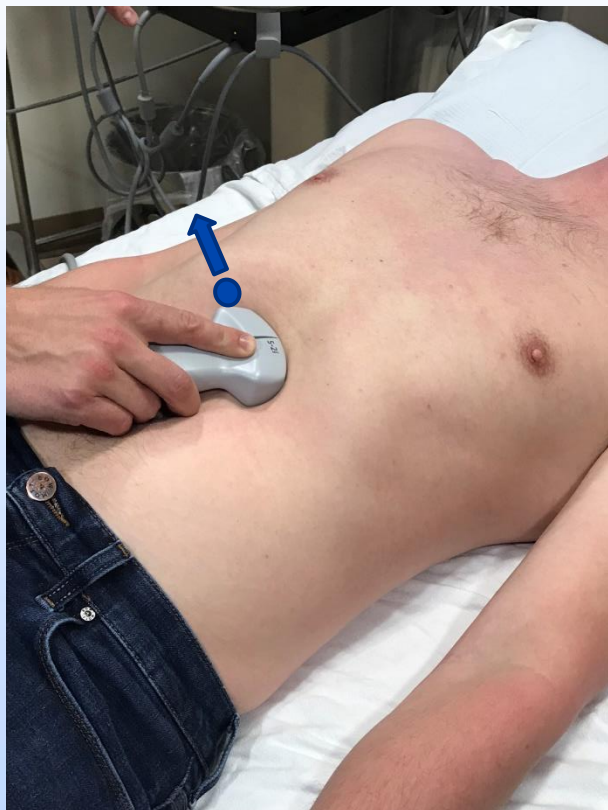
Images accessed from https://www.google.com/search?rlz=1C1GCEB_enUS815US815&biw=1920&bih=1008&itrm=isch&sa=1&ei=zC6XOzAG5GesQXciZigCA&q=anterior+and+posterior+cul+de+sac+female&oeq=anterior+and+posterior+cul+de+sac+female&gs_l=img.3..3885.9833..9955...0.0..0.202.4418.14.25j1...1...1_gws-wiz-img.....3539/067/0/030_of_gx-cq8bKM#imgcr=5NHFE5gHskE4YM;

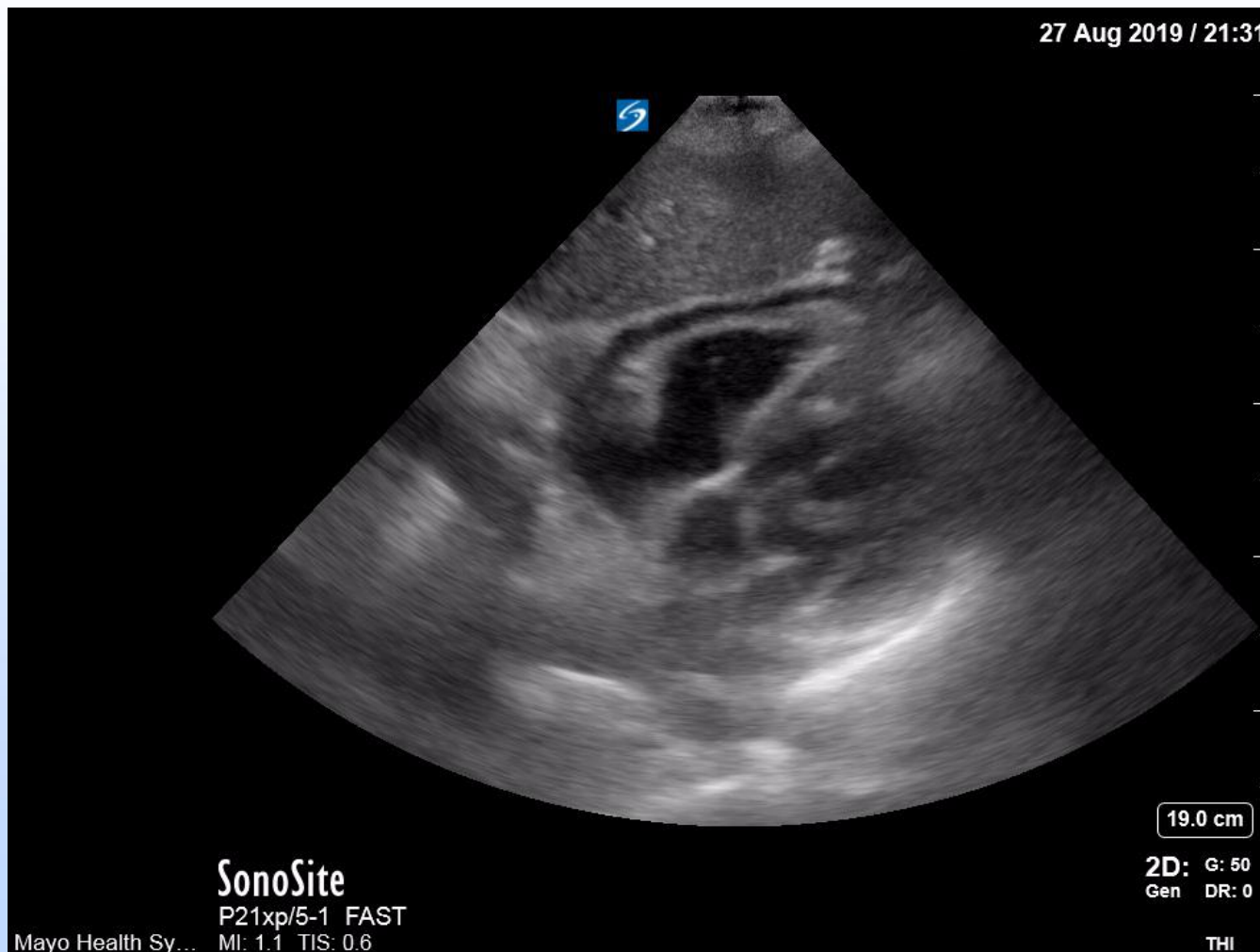
Positive pelvic FAST



Subxiphoid view

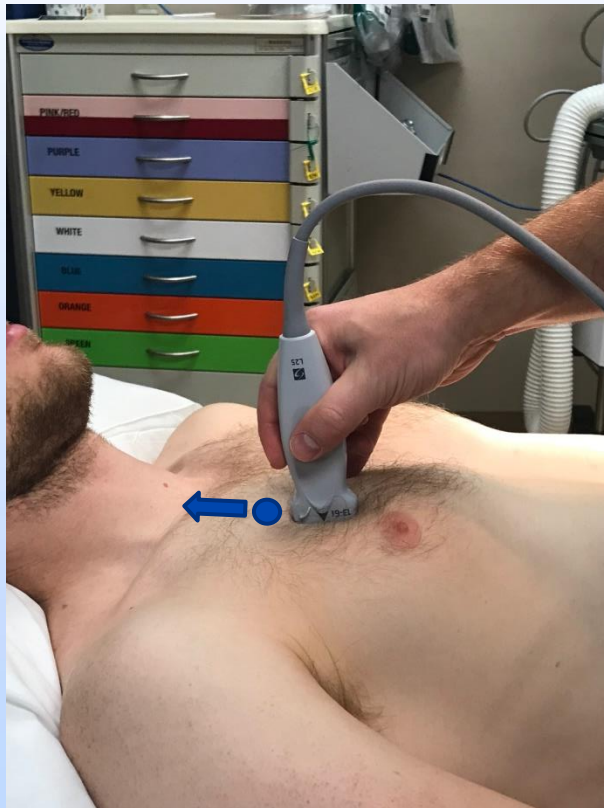


Subxiphoid view

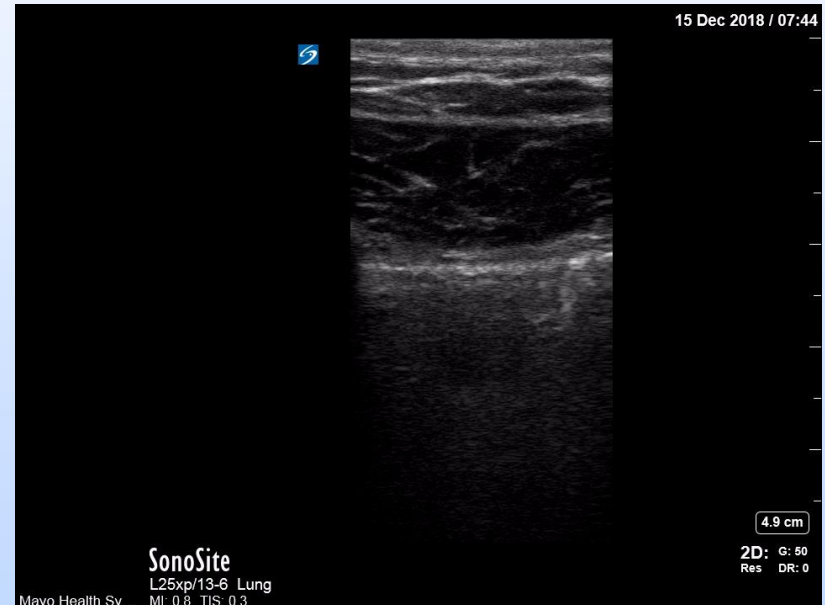


Anterior pleura (bilateral)

Transducer placement

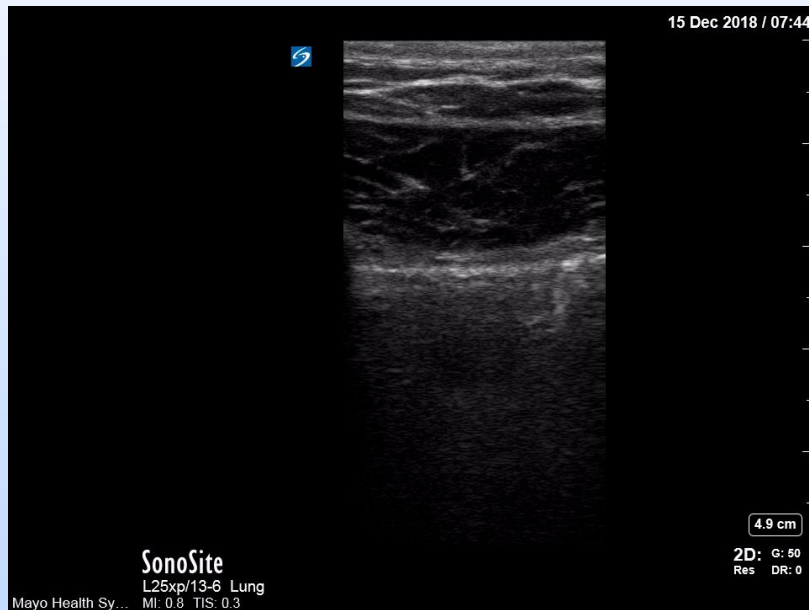


Sliding lung sign

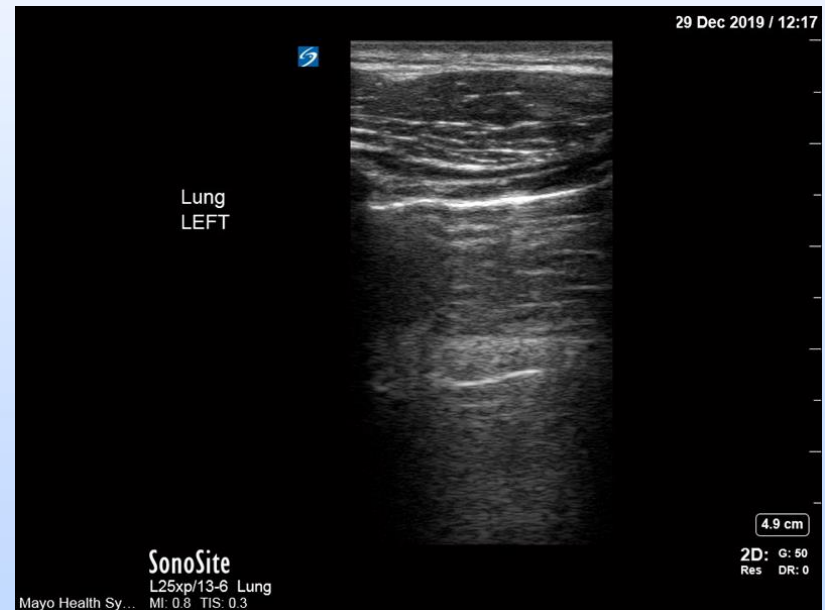

Pneumothorax

Sliding lung sign

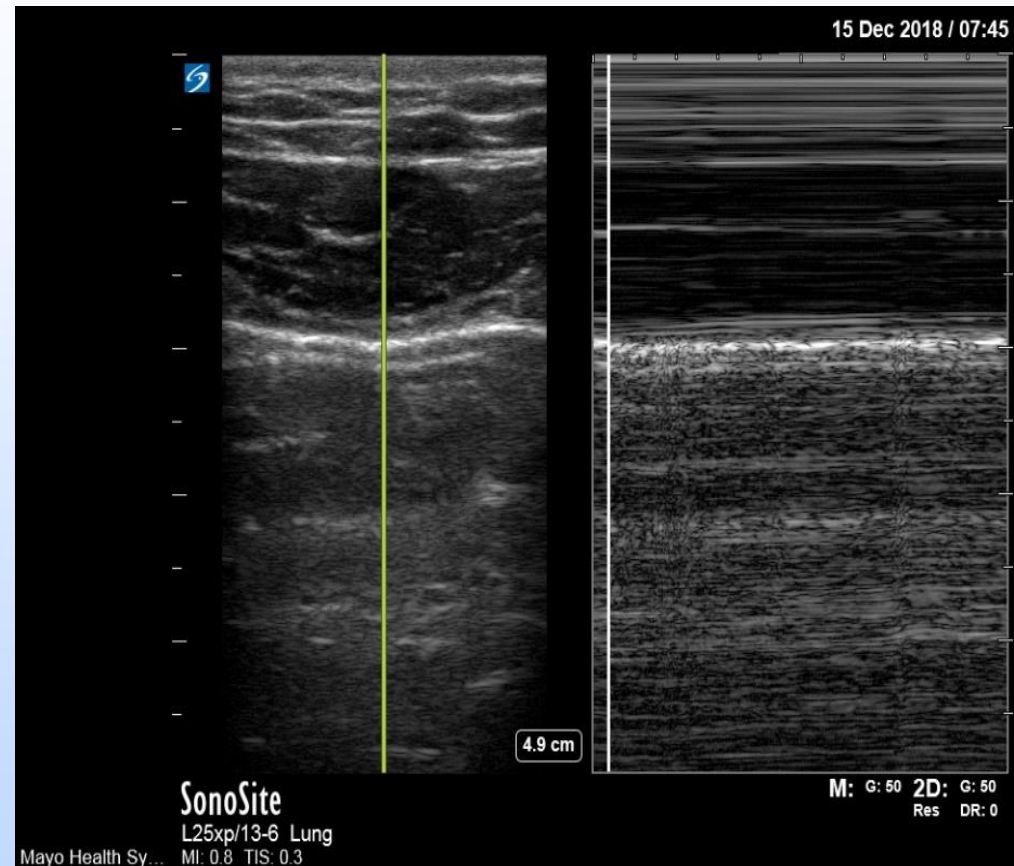


No sliding lung sign



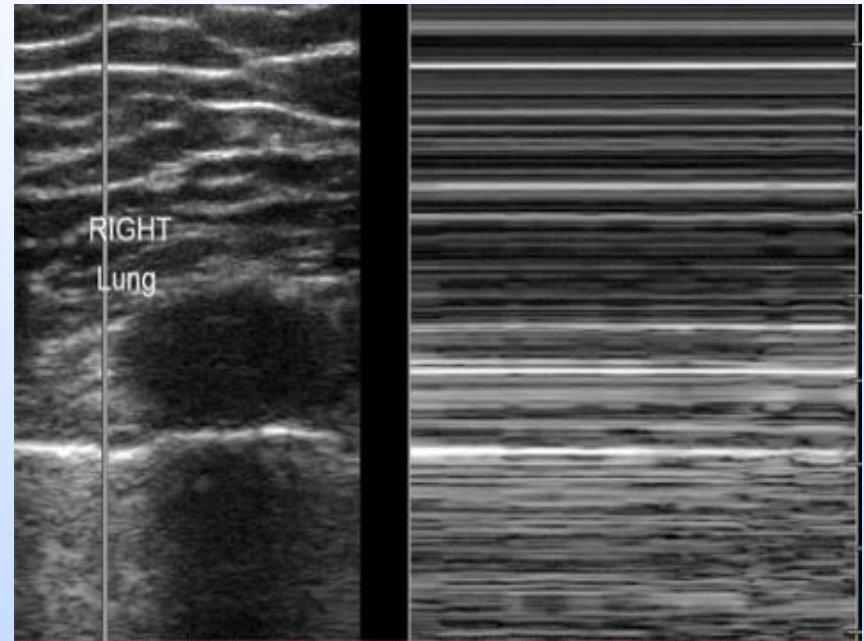
Normal lung

- M-mode
 - Seashore sign



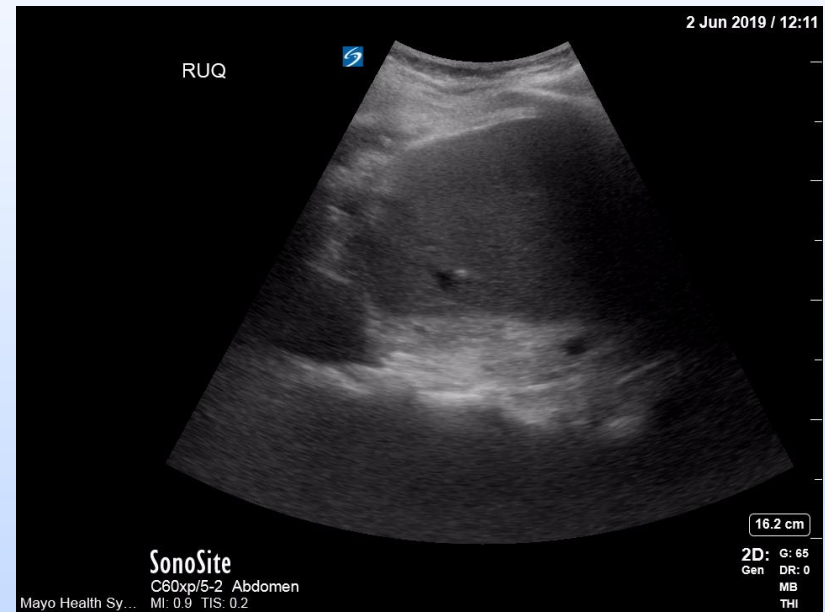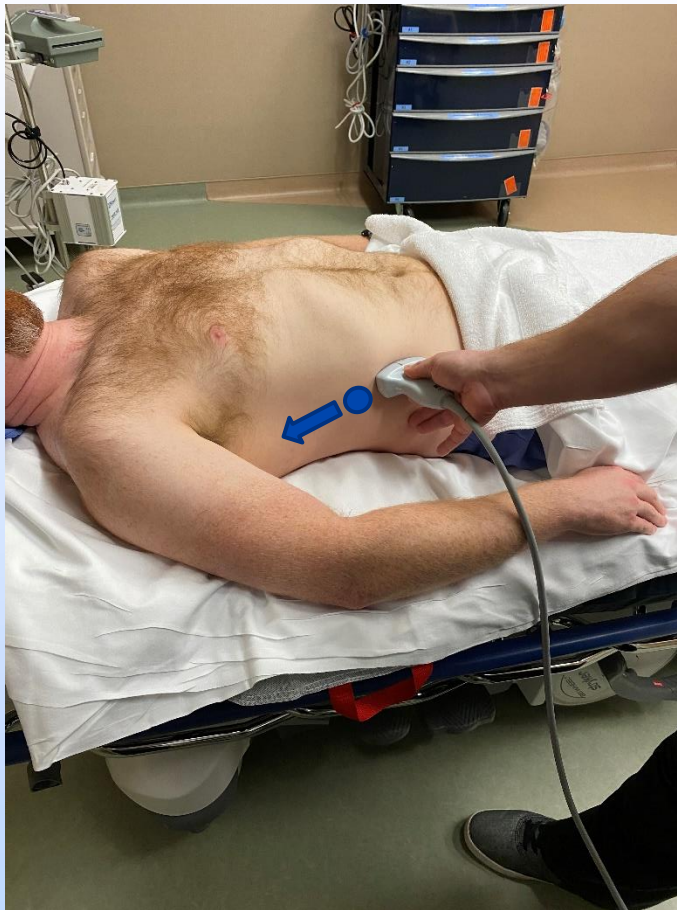Pneumothorax

- M-mode
 - Barcode (stratosphere) sign



Add lung point slides?

Hemothorax



Abdominal: SNS: 68%; SPC: 95%



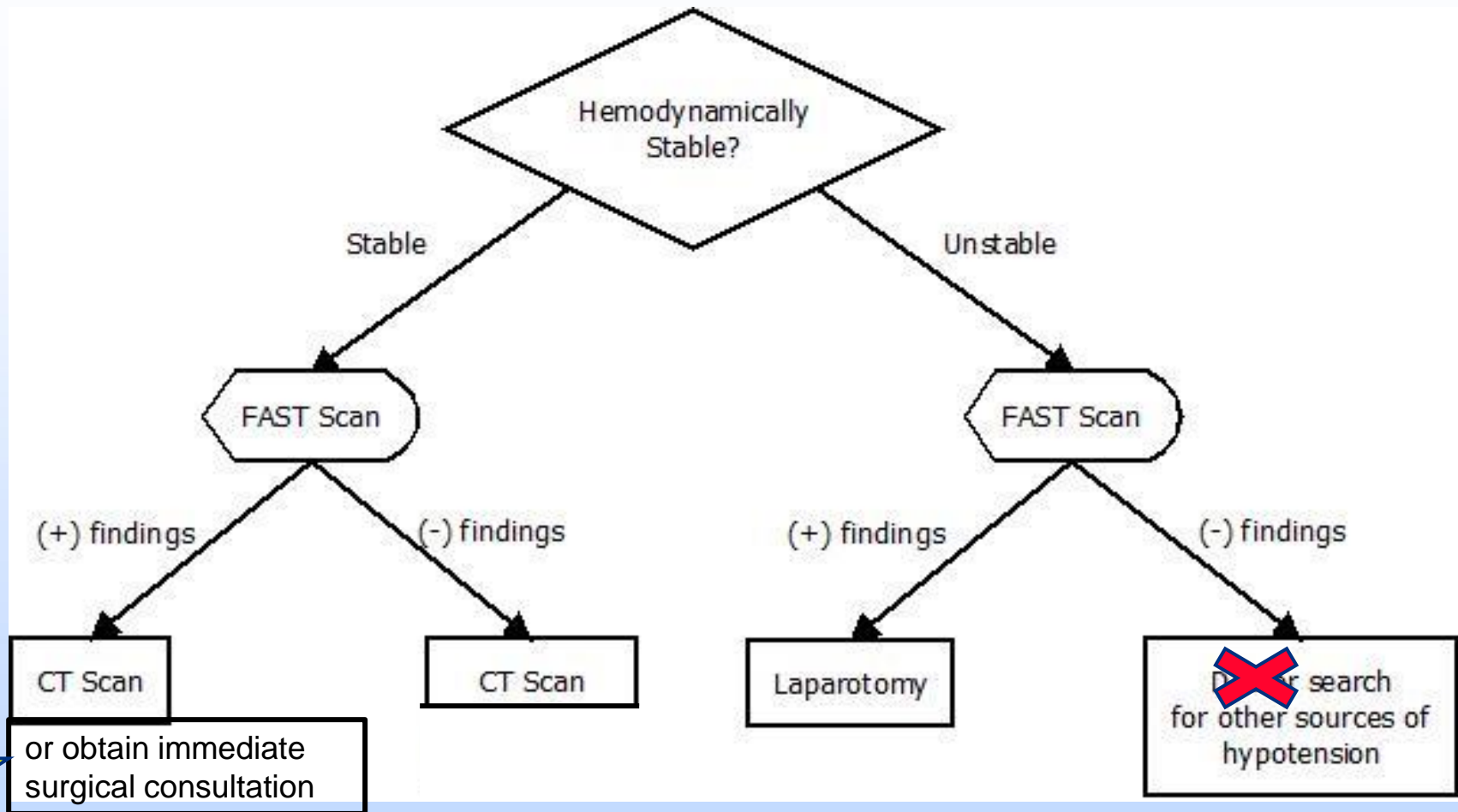
**Cochrane
Library**

Cochrane Database of Systematic Reviews

**Point-of-care ultrasonography for diagnosing
thoracoabdominal injuries in patients with blunt trauma
(Review)**

Stengel D, Leisterer J, Ferrada P, Ekkernkamp A, Mutze S, Hoening A

Chest: SNS: 96%; SPC: 99%



Questions

