

Common Orthopedic Conditions of the Knee (Part 2) Extensor Mechanism Injuries

Musculoskeletal Galaxy Conference 2022

Ljiljana Bogunovic, MD

Orthopedic Surgeon Sports Medicine

Orthopedic Associates of Wisconsin



Disclosures

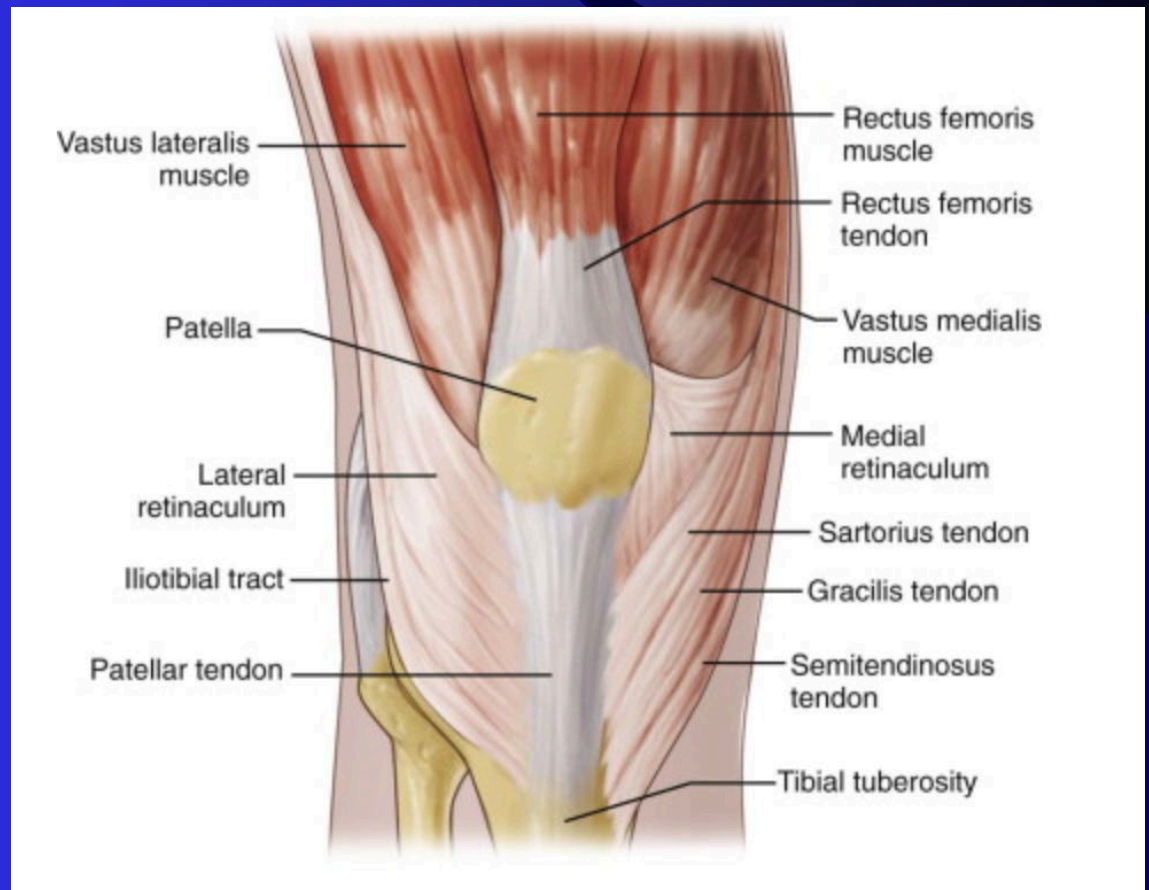
- I have no relevant commercial relationships to disclose

Learning Objectives

- Understand the diagnosis and treatment of common extensor mechanism injuries of the knee

The Extensor Mechanism

- Quadriceps Tendon
- Patella
- Patellar Tendon
- Tibial Tubercle



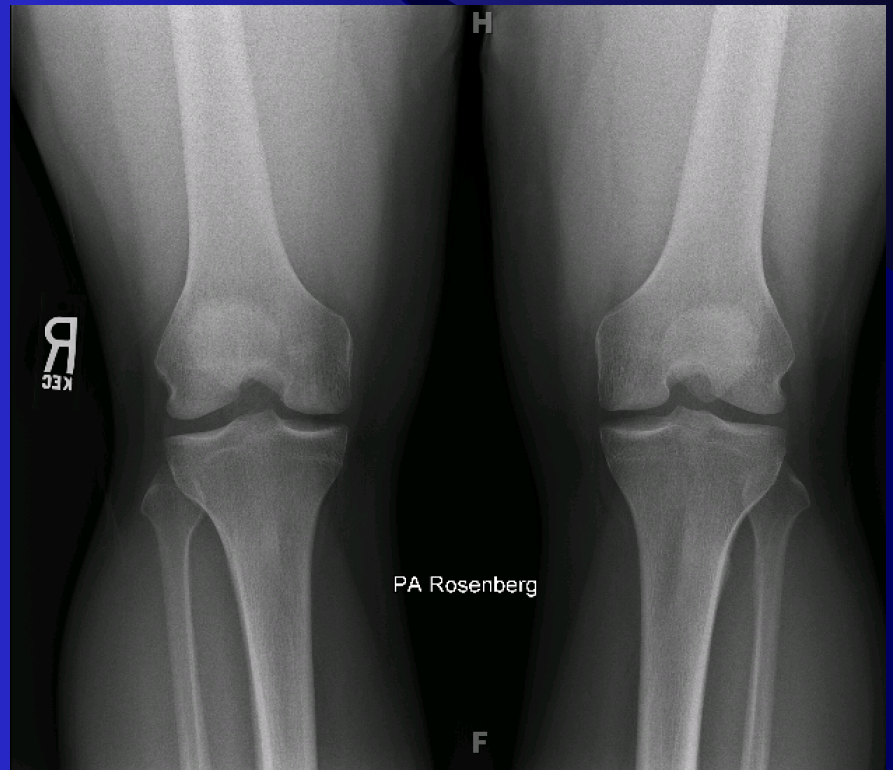
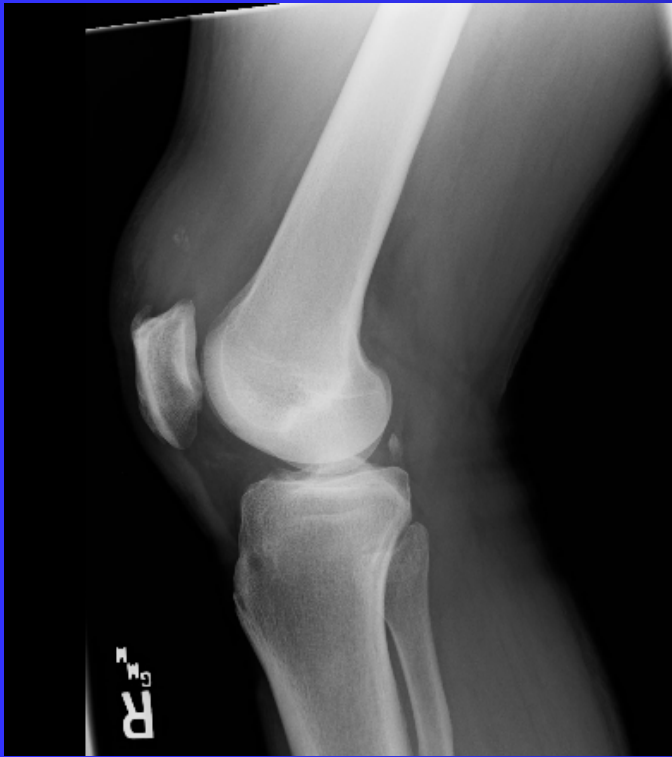Case 1

- 54 year old male with a knee injury after falling down stairs
- Pain and swelling
- Remembers feeling a pop
- Difficulty bearing weight

Physical Examination

- Effusion left knee
- Unable to actively extend the knee
- Stable to varus/valgus stress
- Negative Lachman, posterior drawer
- No joint line pain

Radiographs



Diagnosis

- Quadriceps Tendon Rupture

Patellar/Quad Tendon Tear

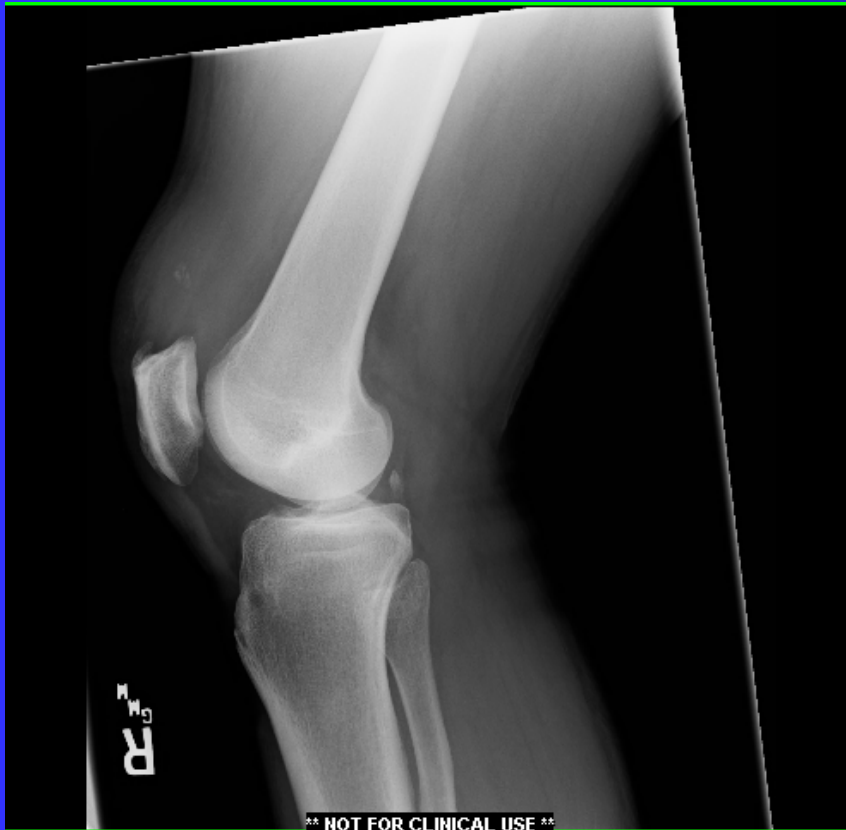- Most common after an eccentric quad load
 - Landing from jumping
 - Fall down stairs
- Patellar tendon tears more common with sports (20-40 year olds)
 - Also associated with chronic diseases
- Quad tendon tears more common in older patients (> 40 years)

Presentation

- Acute onset of pain and soft tissue swelling after a fall or acute eccentric knee flexion
- Large effusions
- Palpable defect
- Inability to actively extend the knee
- Unable to perform a straight leg raise or has a lag with a straight leg raise
 - A lag indicates a partial tear

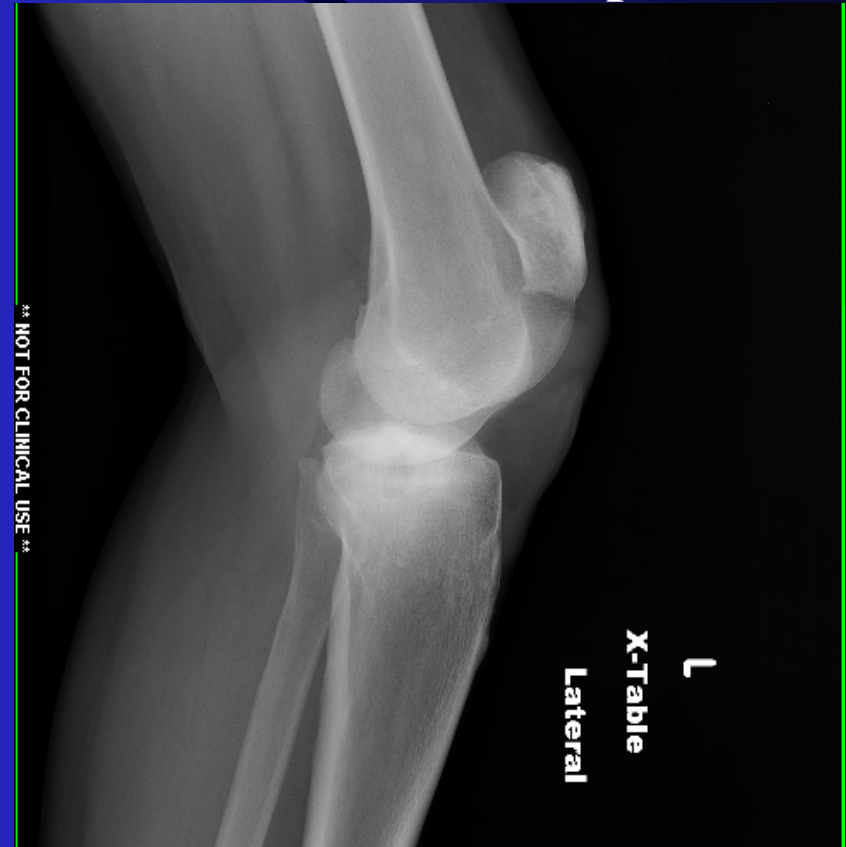
Patellar/Quad Tendon Tear

Quad tendon rupture



Patellar baja

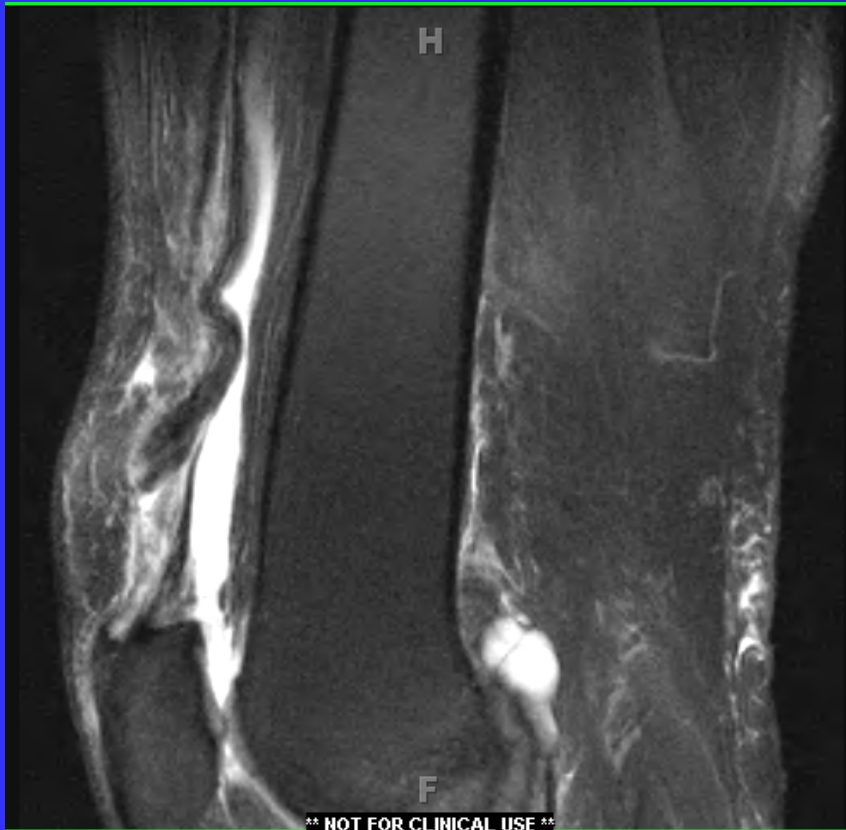Patellar tendon rupture



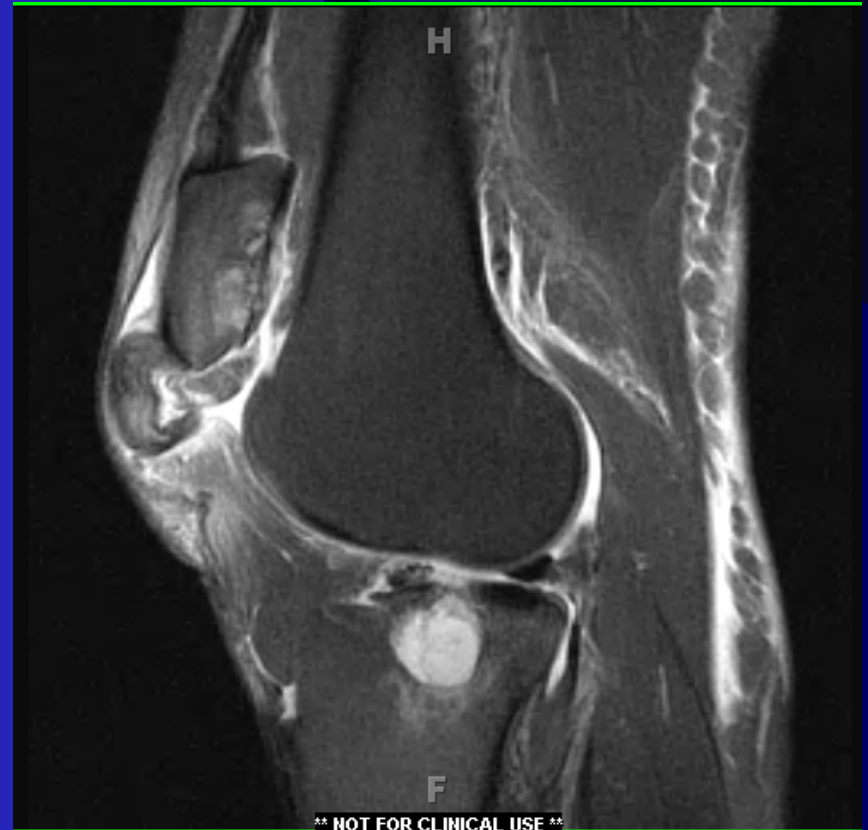Patellar alta

Patellar/Quad Tendon Tears

Quad Tendon Rupture

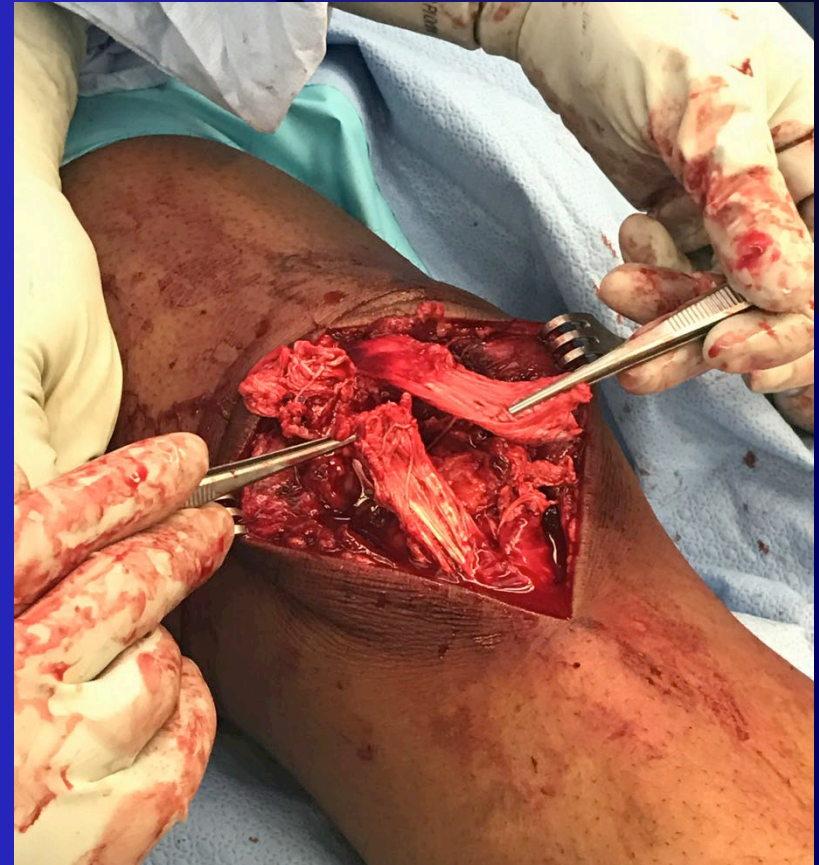

Patellar tendon rupture

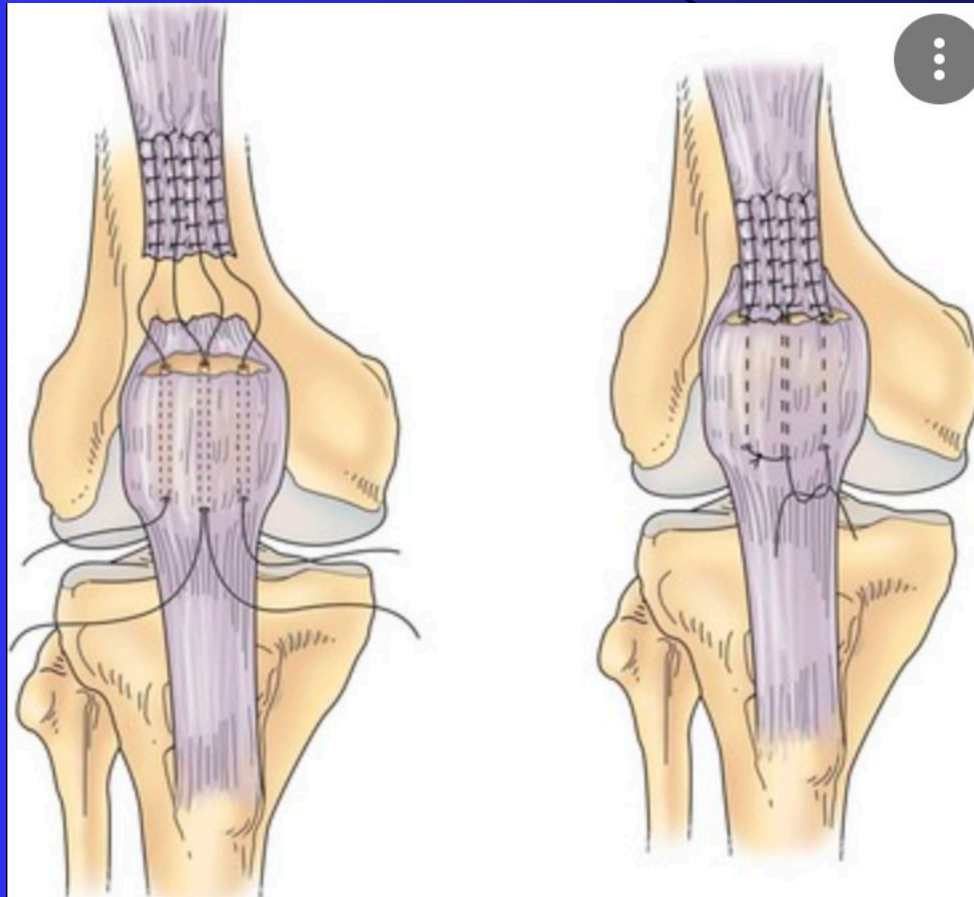


Patellar/Quad Tendon Tear

- Treatment
 - Acute repair is indicated
 - Easier within 2 weeks
 - Subacute and chronic cases may require allograft augmentation and tendon advancement

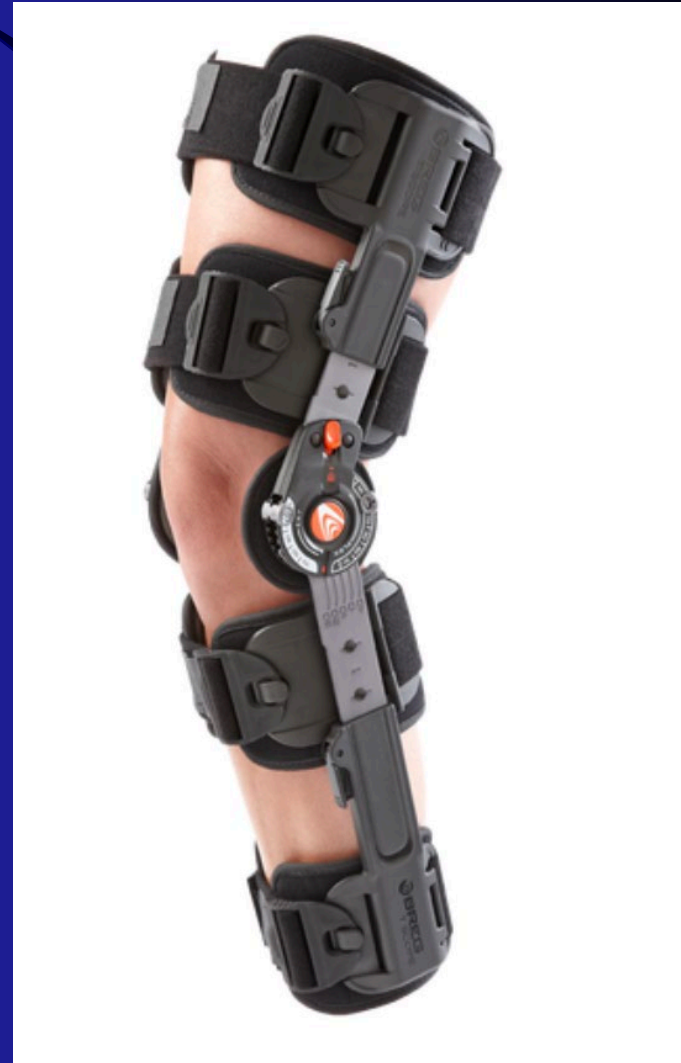

Repair



Patellar/Quad Tendon Tear

- Rehabilitation
 - WBAT with brace locked in extension
 - Early but controlled progressive ROM
 - DC brace approx. 10 weeks
 - Full recovery may take 9-12 months



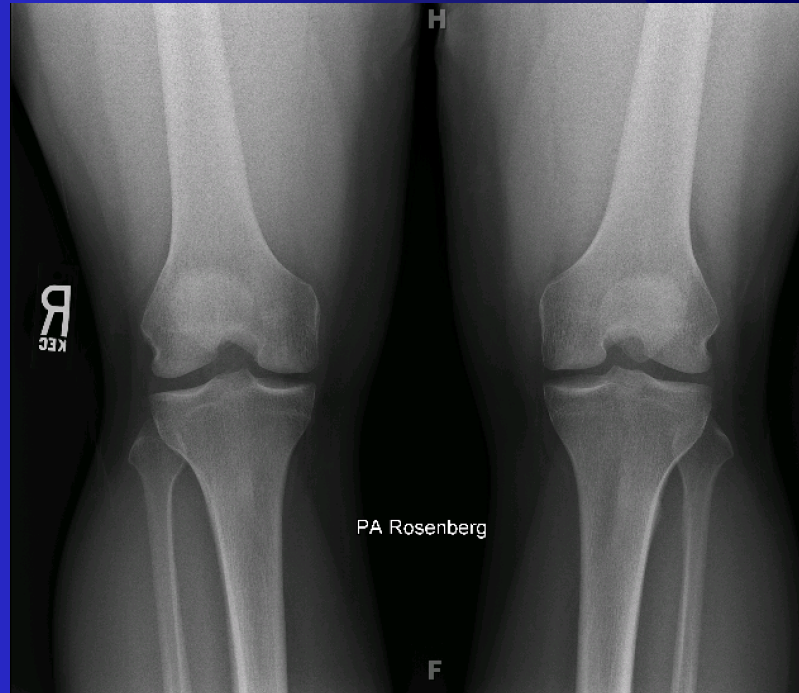
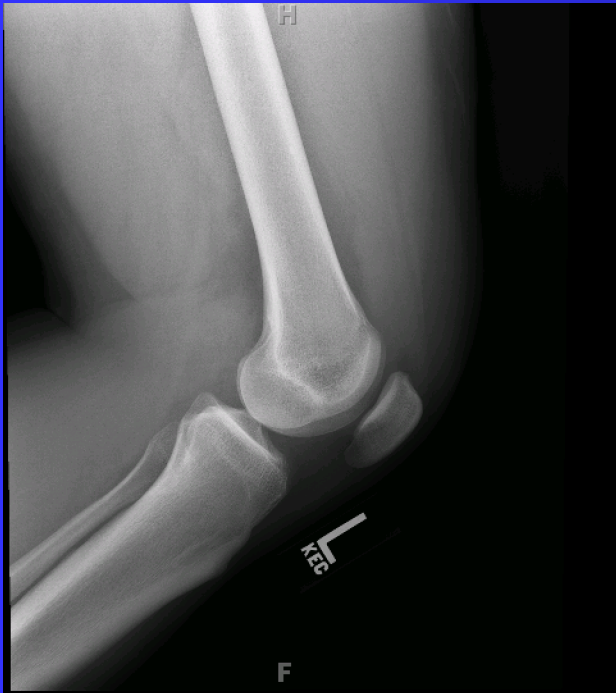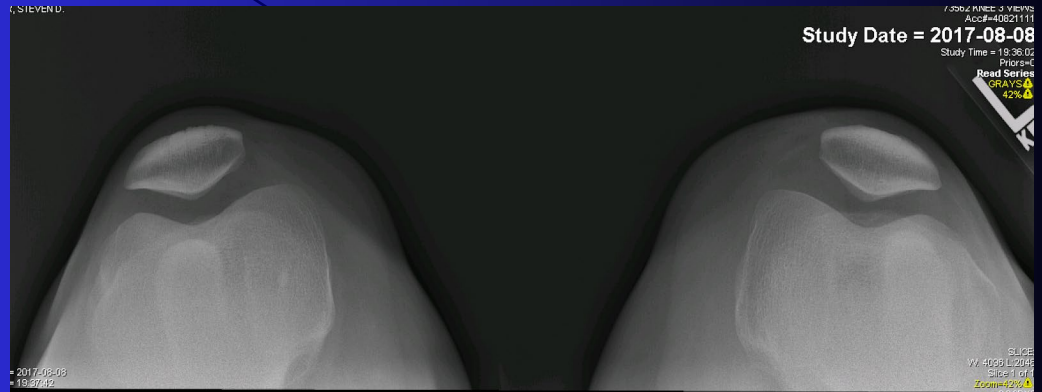
Case 2

- 16 year old female with bilateral knee pain
- No injury
- Recently started running in track
- Worse with stairs, running and jumping
- Denies swelling, instability or mechanical symptoms

Physical Examination

- No swelling
- Full motion 0-140 degrees bilaterally
- Stable to varus and valgus stress
- Negative Lachman and posterior drawer
- No joint line tenderness
- Negative patellar apprehension
- 4/5 strength with resisted hip abduction
- Tight hamstrings

Radiographs



Diagnosis

- Anterior Knee pain/Patellofemoral syndrome

Patellofemoral Pain

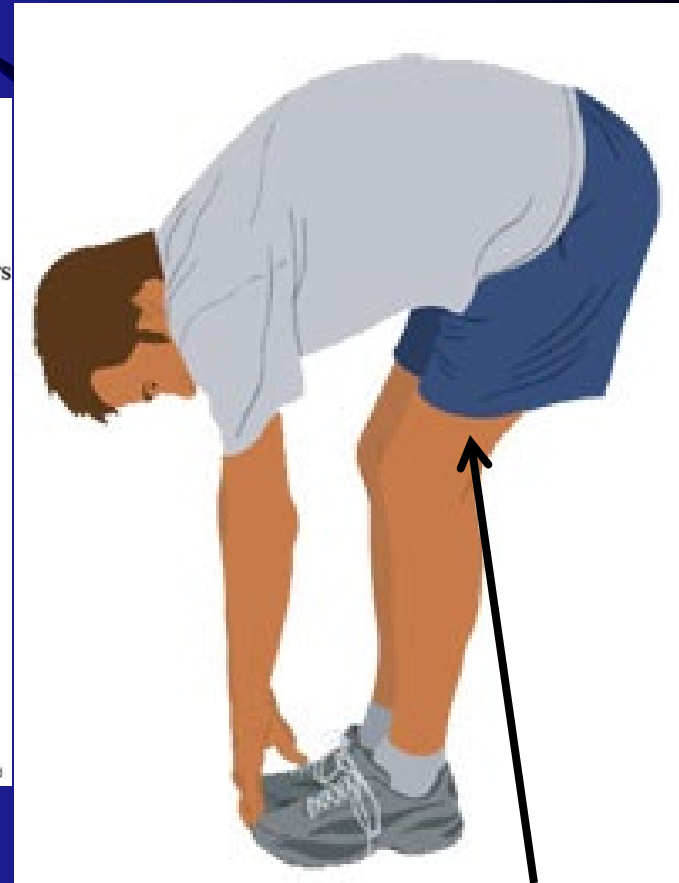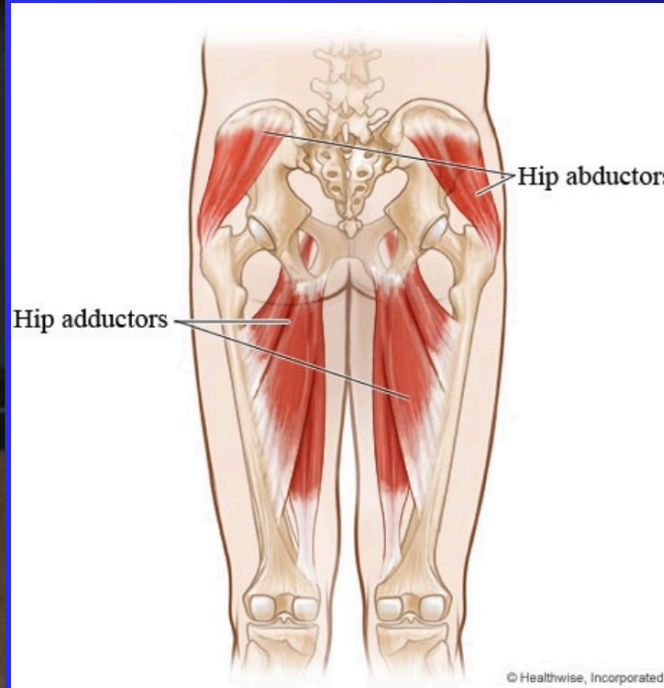
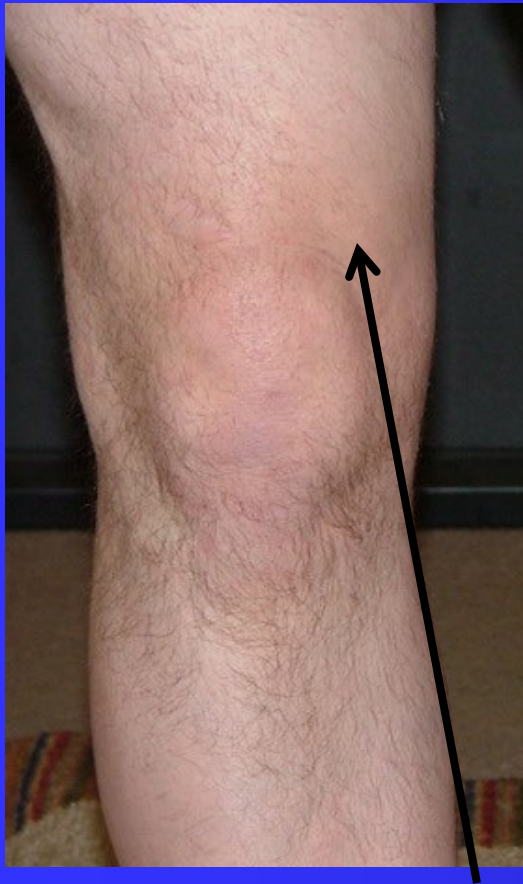- Most common condition seen in Sports Medicine Centers
 - 11% of all musculoskeletal complaints
 - 16 – 25% of running injuries
- Over twice as common in females compared to males



Presentation

- Significant anterior knee pain with:
 - Stairs
 - Prolonged bent knee activities
 - Jogging
 - Getting out of a car
- Often no discrete injury
- Pain often diffuse and around or underneath the patella
- Often related to overload on the lateral patellar facet

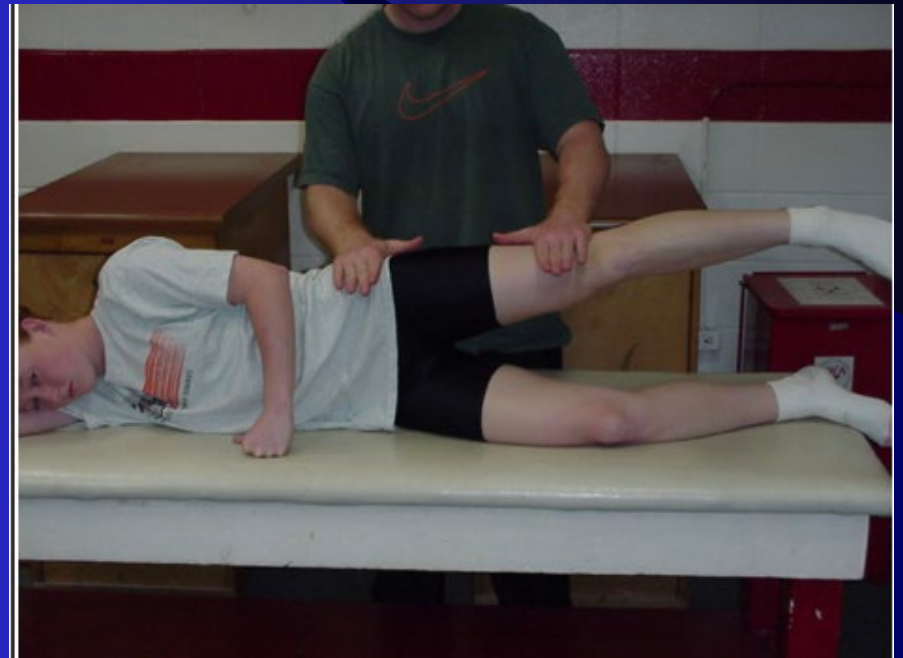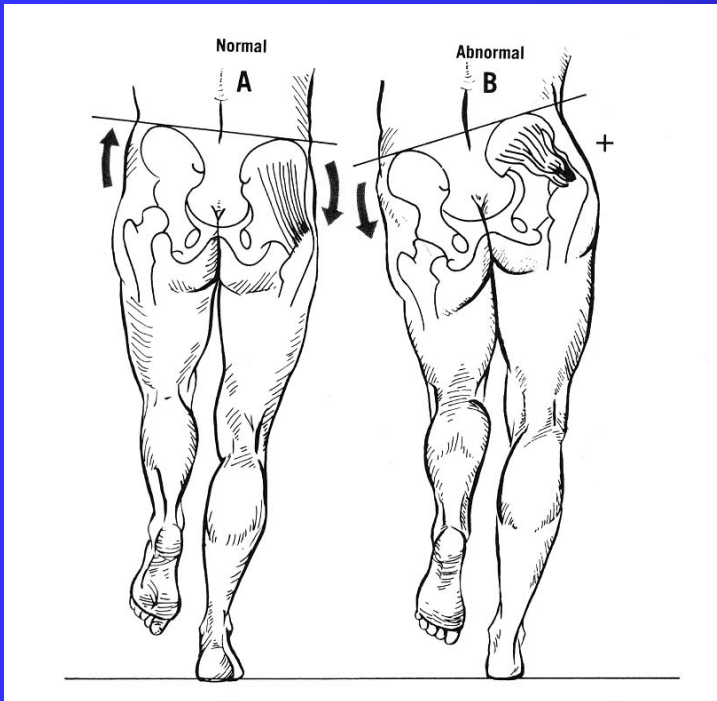
Physical Findings



Weak/Small VMO

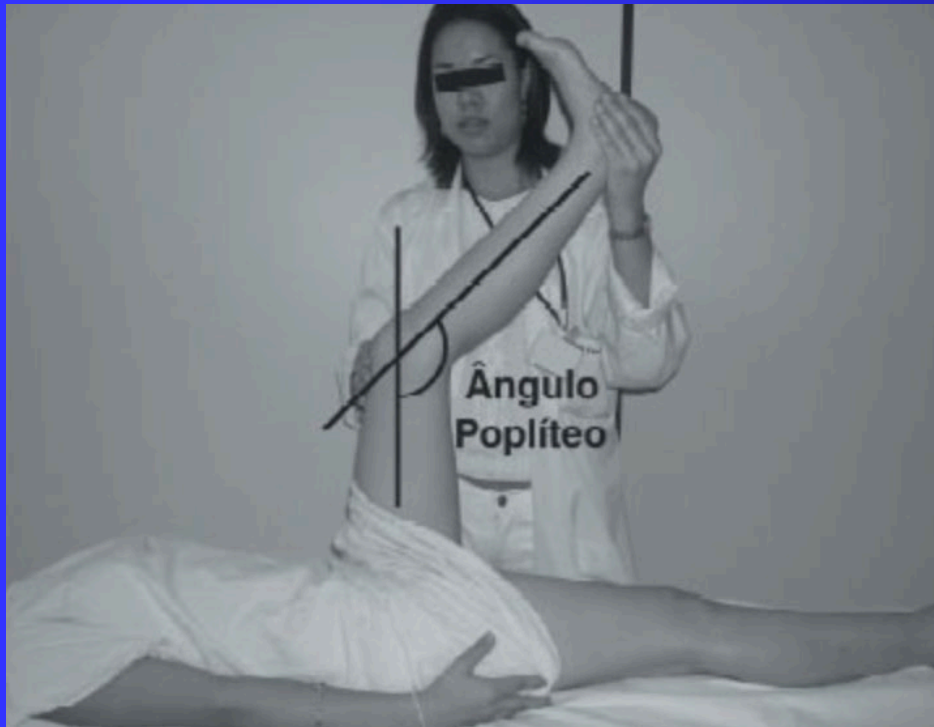Tight hamstrings

Physical Findings

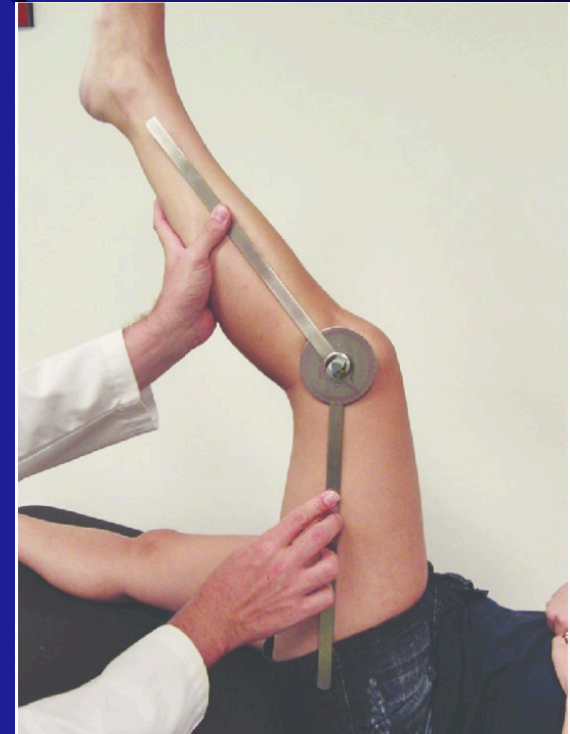


WEAK Hip Abductors

Physical Exam Findings



Side lying hip abduction



Popliteal angle measurement

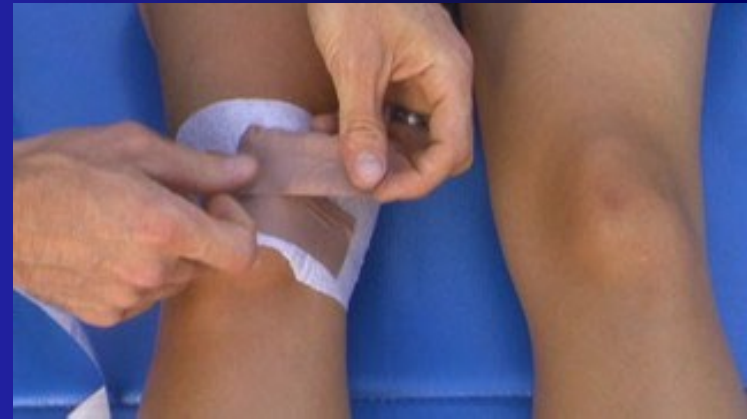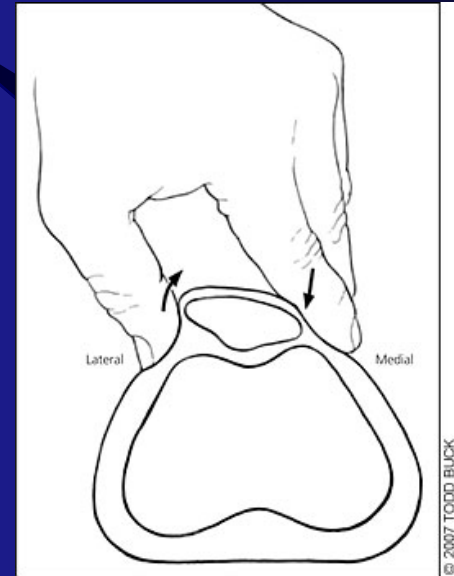
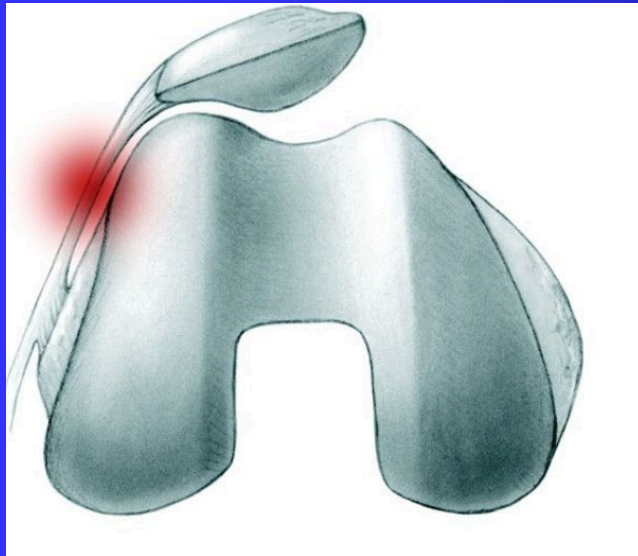
Treatment

- *Activity modification!*
 - *Keep knee from 0-30° of flexion*
- Quadriceps strengthening (focus on VMO), hip abductor and core strengthening
- Avoid open chain quad!!!
- Hamstring stretching



Patellofemoral Treatment

- Stretching of the tight lateral retinaculum
- Patellofemoral taping



Treatment

- Weight control/loss critical!
- Forces between the patella and femur
 - 3x body weight with stairs
 - Lose 5 pounds = 15 pounds off the patella/femur
 - 7x body weight with deep knee bends
 - Loss 5 pounds = 35 pounds off the patella/femur



Case 3

- 17 year old basketball player with left knee pain
- No injury
- Pain in the front of the knee
- Worse with jumping and running
- Denies swelling, instability or mechanical symptoms

Physical Examination

- No effusion
- Normal range of motion 0-140 degrees
- Stable on exam (varus/valgus & ant/post drawer)
- No joint line tenderness
- Tenderness over the patellar tendon
- Hamstring tightness
- Weak Glute strength
- Normal radiographs

Diagnosis

- Patellar Tendonitis

Patellar Tendonitis

- Inflammation involving the patellar tendon
- Common in jumping and running sports
- Insertional more common than mid substance
- Similar presentation to anterior knee except these patient have tenderness over the patellar tendon

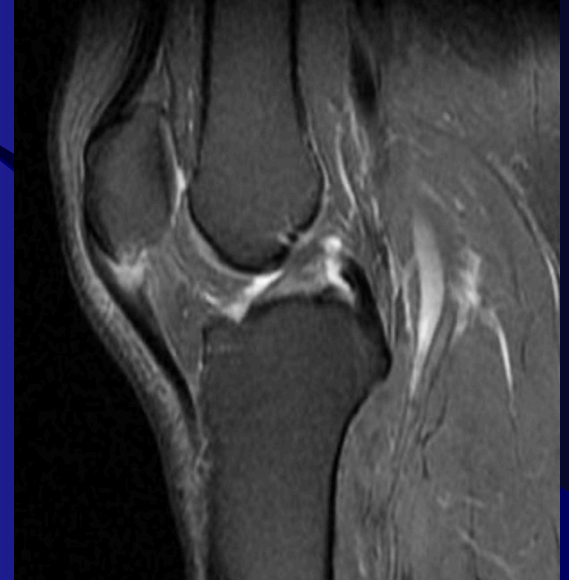
Treatment: Phase 1

- Majority improvement with nonoperative treatment
- Ice, NSAIDs (oral/topical)
- Physical therapy
 - Quad and glute strengthening, hamstring stretching
 - Modalities (ionophoresis / e stim)
- Bracing (Chopat Strap)



Treatment: Phase 2

- MRI to confirm location of tendinopathy
- Injection with PRP
(AVOID CORTISONE)
- High frequency ultrasound
 - Ultrasound
 - Tenex



Treatment: Phase 3

- Open surgical debridement
- Disease tendon excised (usually central and proximal at the insertion)
- Immobilization 1-2 weeks until quad control returns
- Return to sports 4-5 months

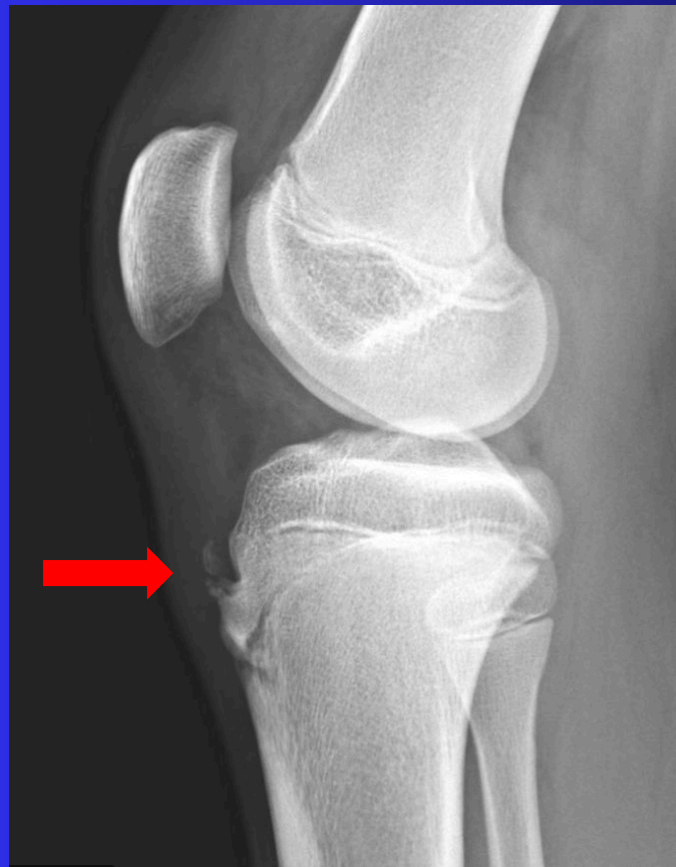
Case 4

- 11 yo male football player with swelling and pain over the front of the knee
- No specific injury
- Worse with running and jumping
- Pain with kneeling
- No instability or mechanical symptoms

Physical Examination

- No swelling
- Full motion 0-140 degrees
- Stable varus/valgus and Ant/post drawer
- No joint line pain
- Neg patellar apprehension
- Tenderness and swelling over the tibial tubercle
- Tight hamstrings

Radiographs



Diagnosis

- Osgood Schlatter Disease

Osgood Schlatter

- Inflammation at the apophysis of the tibial tubercle
- Occurs in active early teens
- Worse with bent knee activities such as running, jumping and climbing stairs
- Overuse injury in which part of the growth plate pulls away from the tibia

Treatment

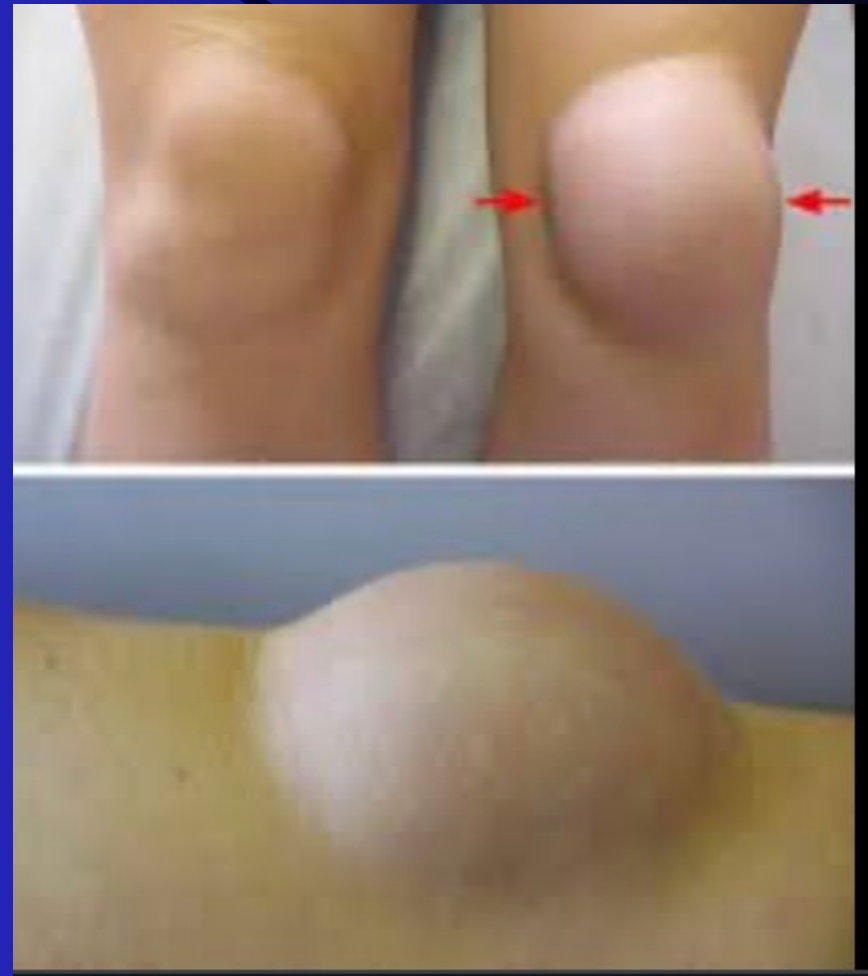- Rest
- Ice
- NSAIDS
- Avoid kneeling
- Resolves entirely with skeletal maturity

Case 5

- 54 year old carpenter with left knee swelling
- No specific injury
- Does report recent kneeling on a hard surface
- Tightness with bending
- Minimal pain

Physical Examination

- Swelling in the prepatellar bursa but no joint effusion
- Motion –135 degrees
- Ligamentously stable
- No redness, warmth and/or induration
- Normal radiographs

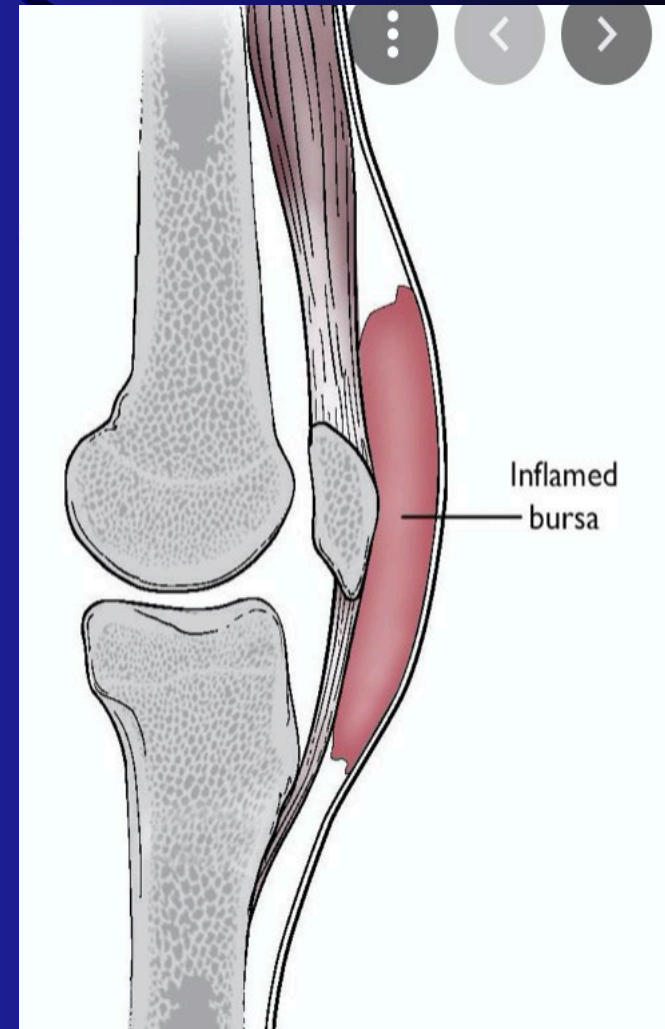


Diagnosis

- Prepatellar Bursitis

Prepatellar Bursitis

- Inflammation in the prepatellar bursa
- Soft tissue plane between the anterior knee patella and capsule and the overlying skin
- Can occur with prolonged kneeling and pressure over the anterior knee



Treatment

- Need to rule out infection
 - Warmth, redness, pain, systemic signs
 - Infected bursitis requires surgical wash out
- In the absence of infection
 - COMPRESSION (continuous)
 - Ice
 - Avoid kneeling
 - Can consider aspiration +/- cortisone injection if compression fails. Does increase risk of infection

Case 6

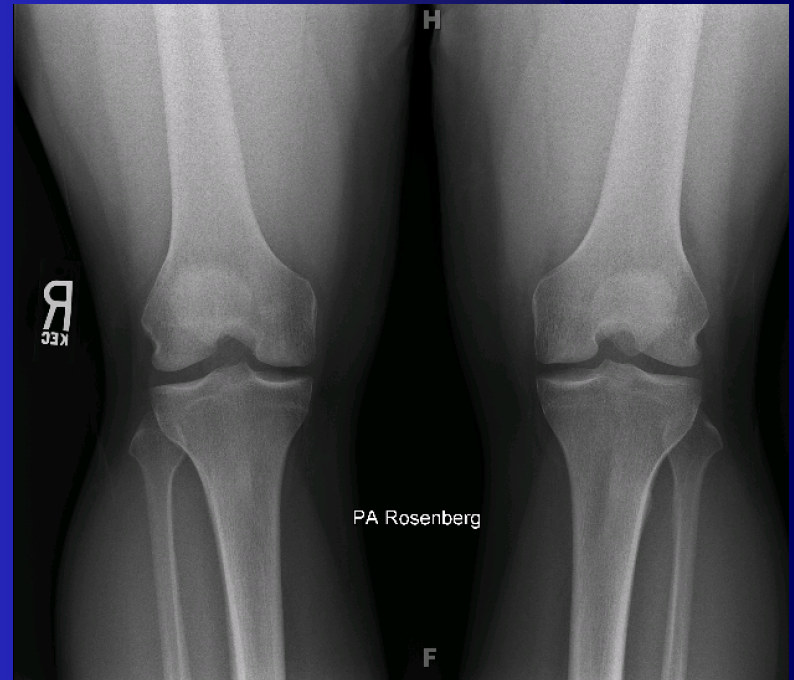
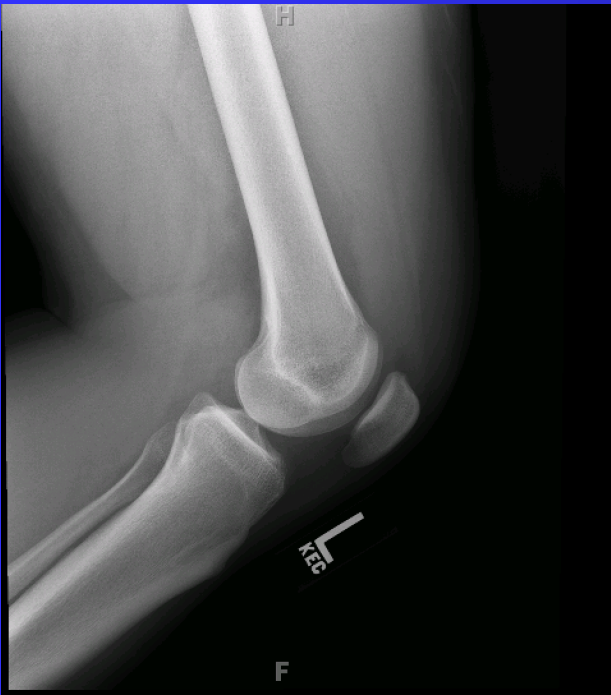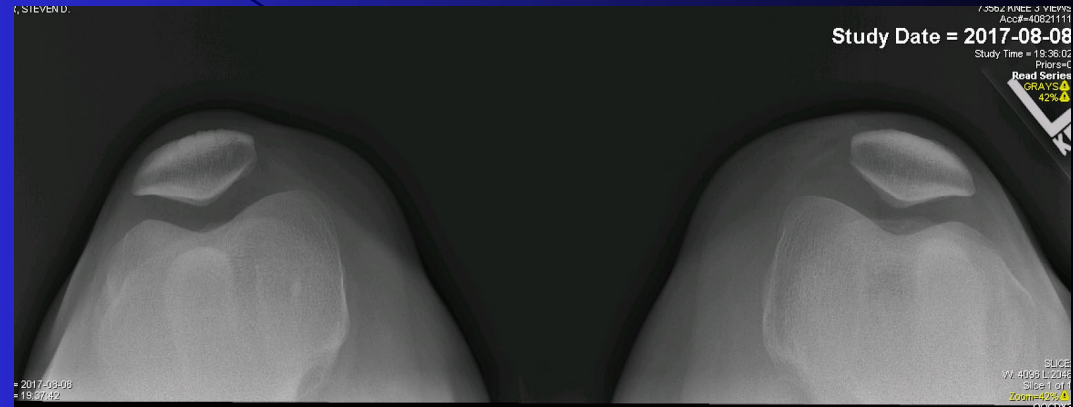
- 16 yo female soft ball player who injured her right knee while batting
 - Felt a pop
 - Immediate pain and swelling
 - Difficulty ambulating
 - No previous history of knee pain



Physical Examination

- Moderate effusion
- ROM 0-90 degrees
- Stable to varus and valgus stress
- 1A Lachman, neg posterior drawer and dial
- No joint line tenderness
- Pain over the medial patellar facet
- NVI

Radiographs



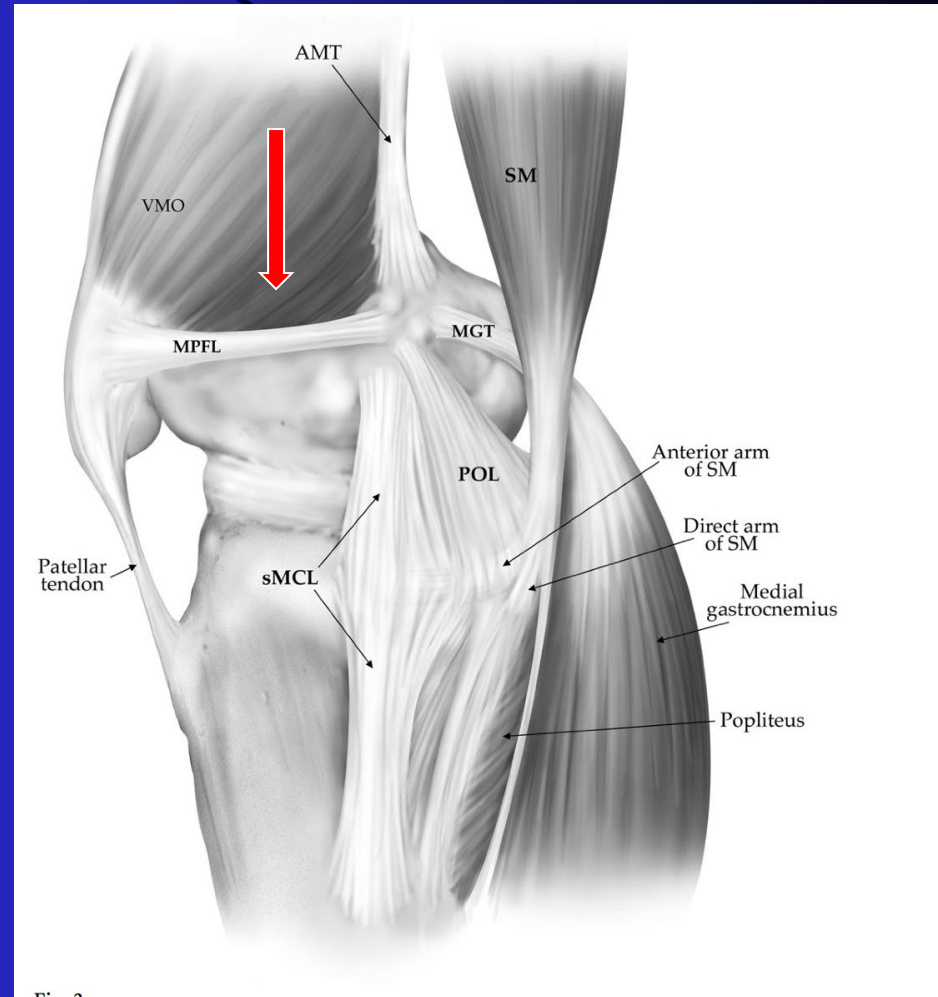
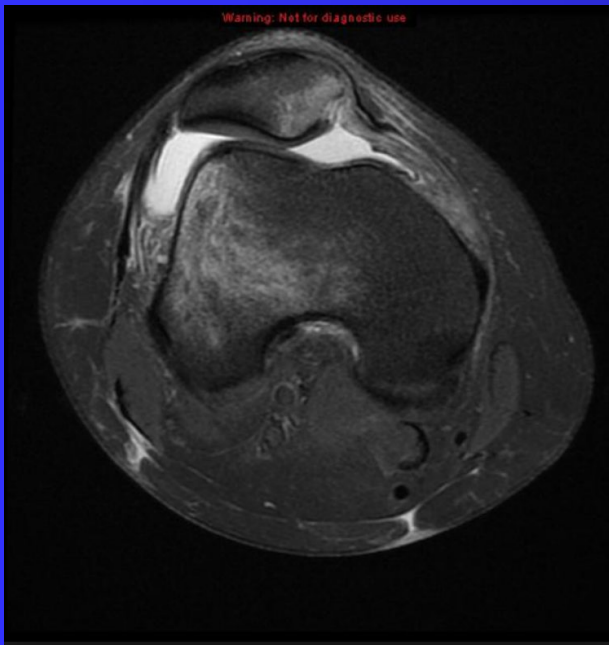
Diagnosis

- Patellar Dislocation

Patellar Dislocation

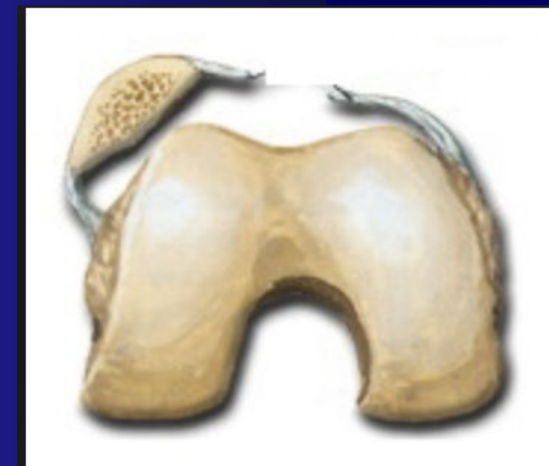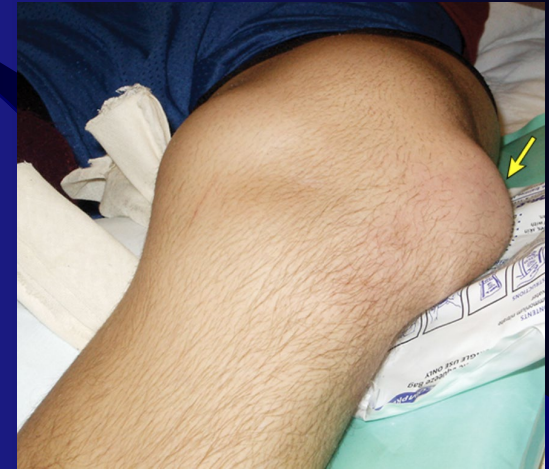
Tearing of the MPFL

Femoral >>>Patellar



PATELLA DISLOCATION

- Most common in younger patients (<30)
- Cause is multifactorial
 - Trauma (acute)
 - Underlying anatomic variants (chronic)
- Majority of patients (acute dislocators) do well with nonoperative treatment
- Can result in cartilage injury to the medial patella facet and/or lateral trochlea

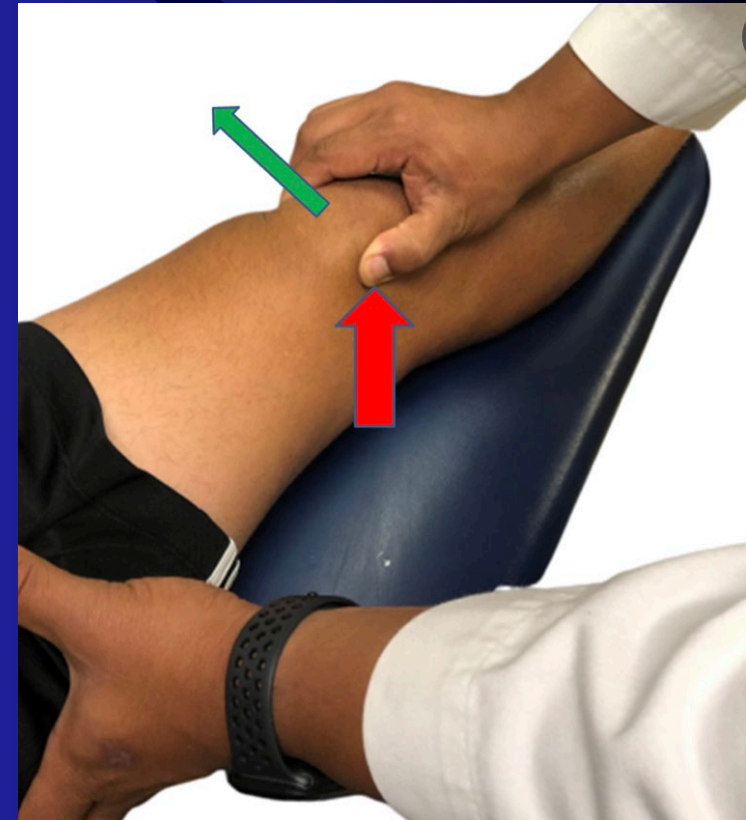

PATELLA DISLOCATION

- Presentation
 - Acute pain and swelling after a pop in the knee
 - Often the knee buckles or shifts
 - Often the patient knows that the patella popped out

Physical Examination

- Knee Effusion
- Limited range of motion
- Tenderness over the MPFL (medial epicondyle +/- medial patellar facet)
- Positive apprehension (more common in chronic setting)

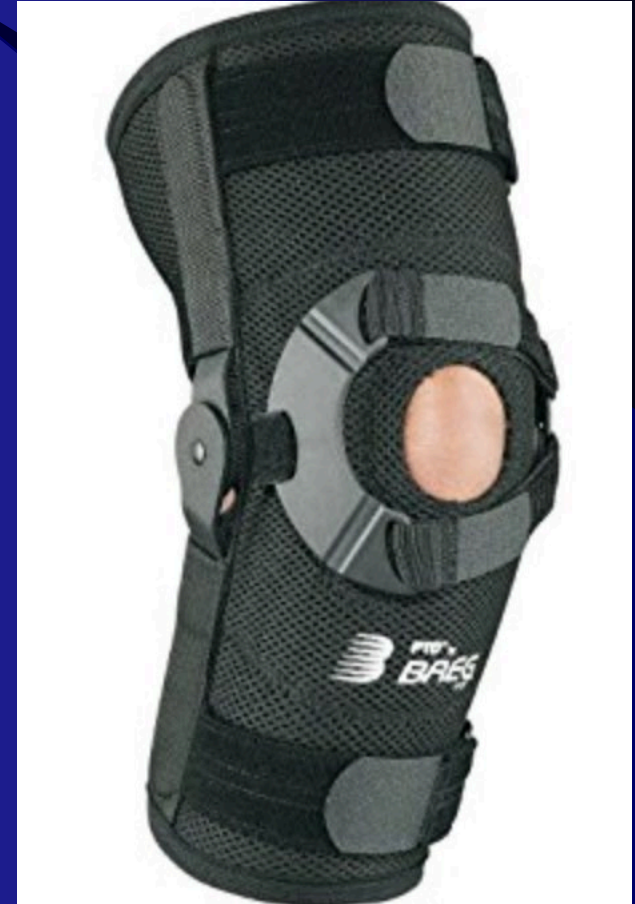

Treatment

- Limited role for operative treatment in first time dislocators in the absence of osteochondral fracture and/or MPFL avulsion

Nonoperative Treatment

- Brief immobilization in extension until quad control returns
- Ice, NSAIDs, compression, +/- aspiration
- Transition to patellar stabilization brace
- Physical therapy emphasizing quad, glute and core
- RTS ~ 6-12 weeks



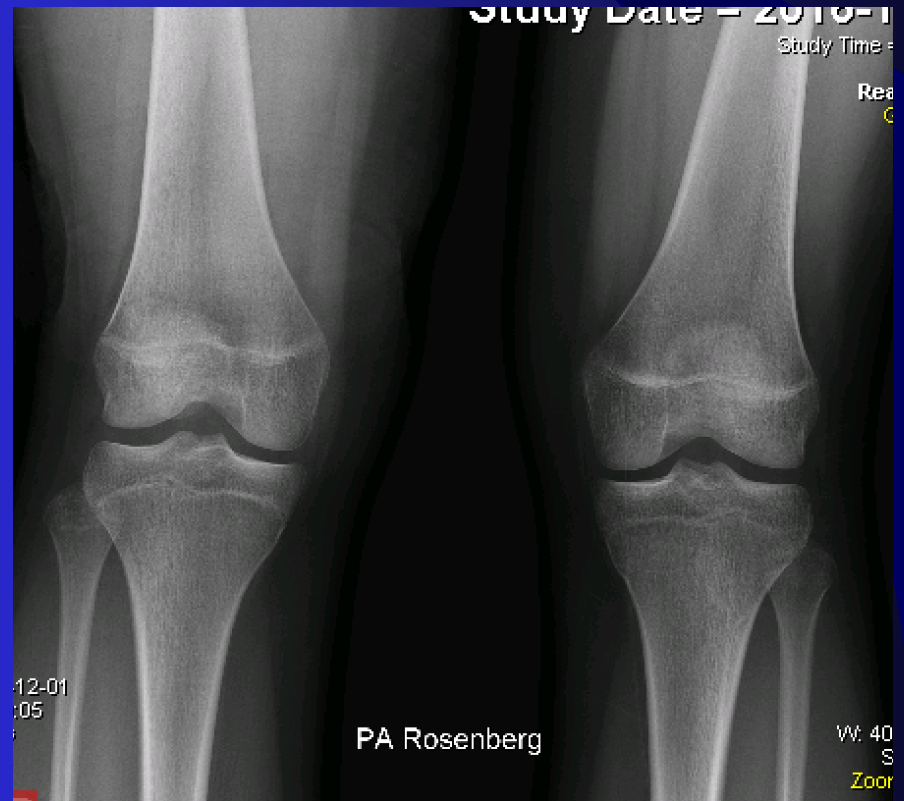
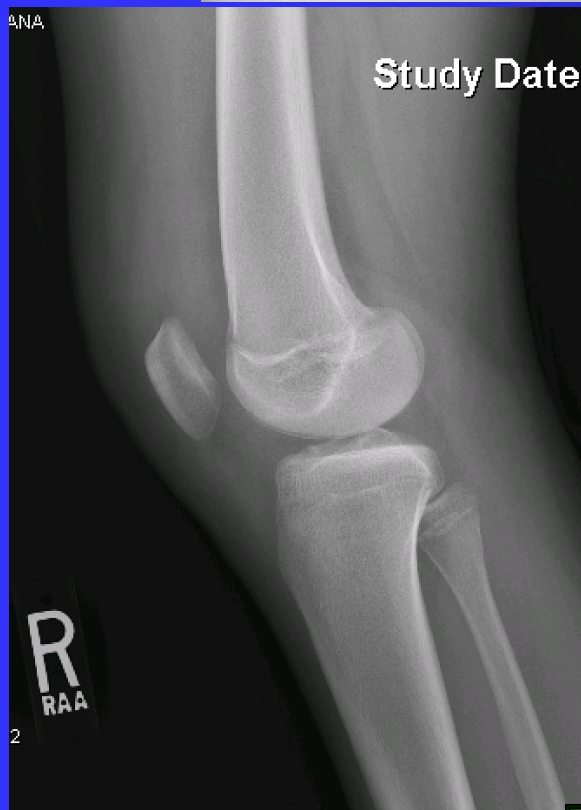
Case 7

- 14 year old soccer player with knee pain after colliding with an opponent
- Felt a pop
- Difficulty bearing weight
- No previous history of knee pain

Physical Examination

- Moderate effusion
- ROM 0-90 degrees
- Stable to varus and valgus stress
- 1A Lachman, neg posterior drawer and dial
- No joint line tenderness
- Pain over the medial patellar facet
- NVI

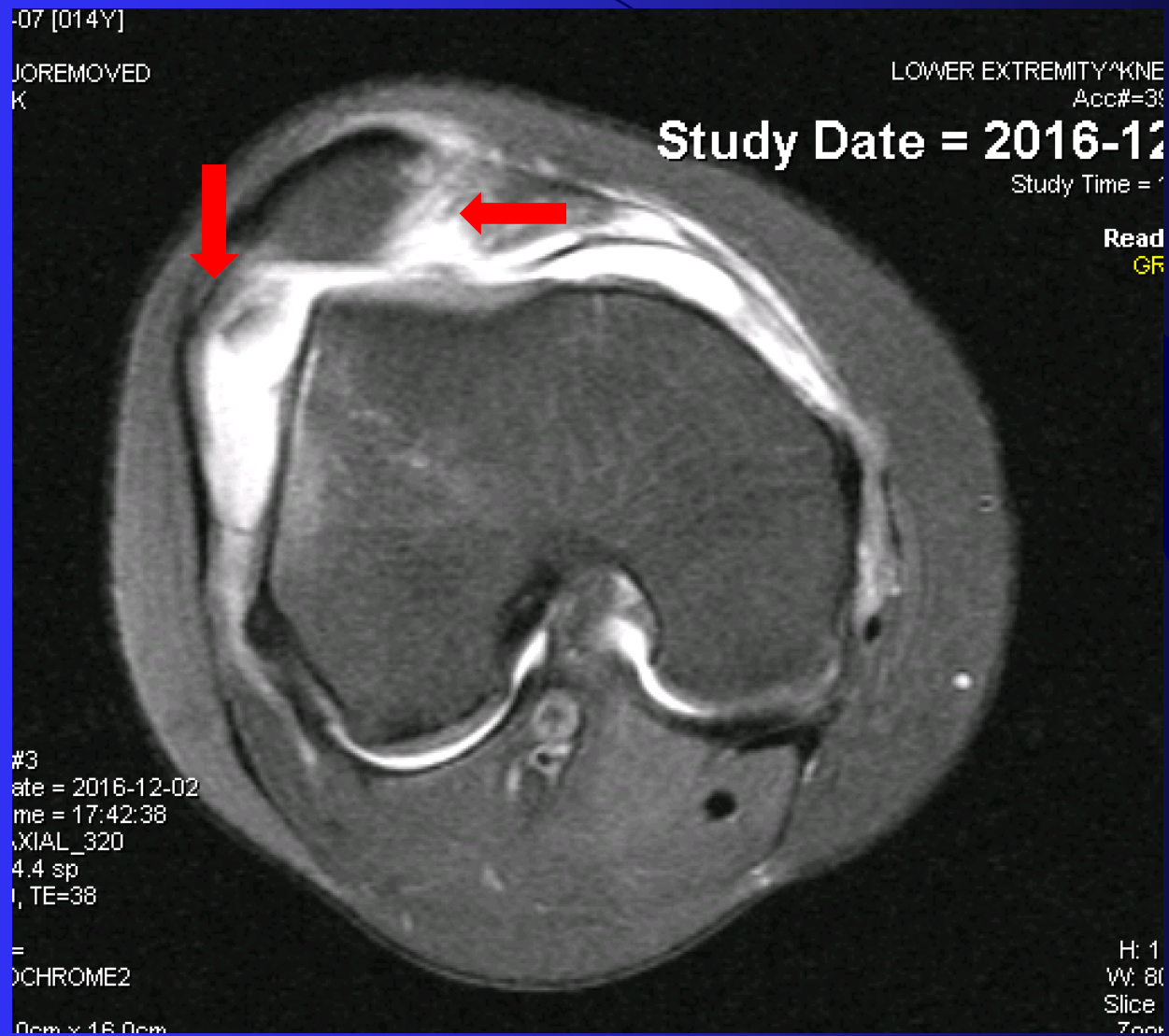
Radiographs



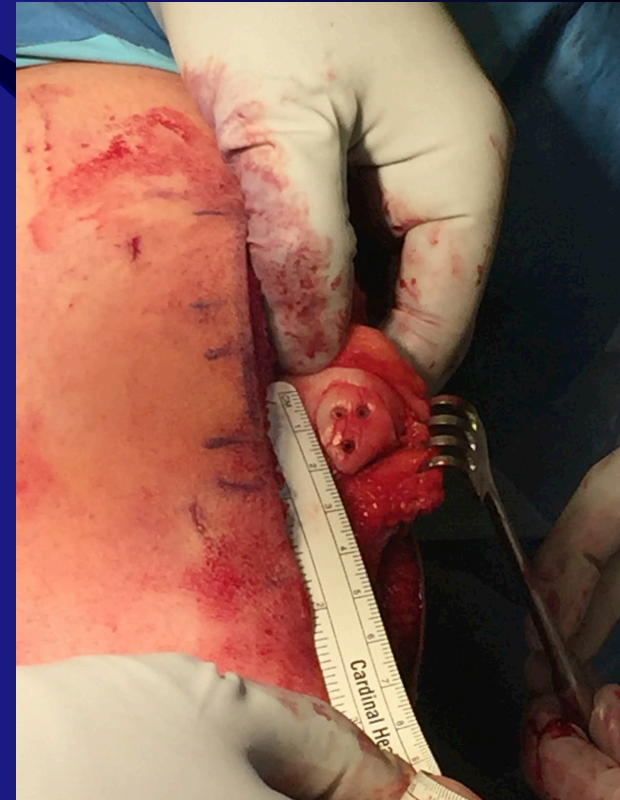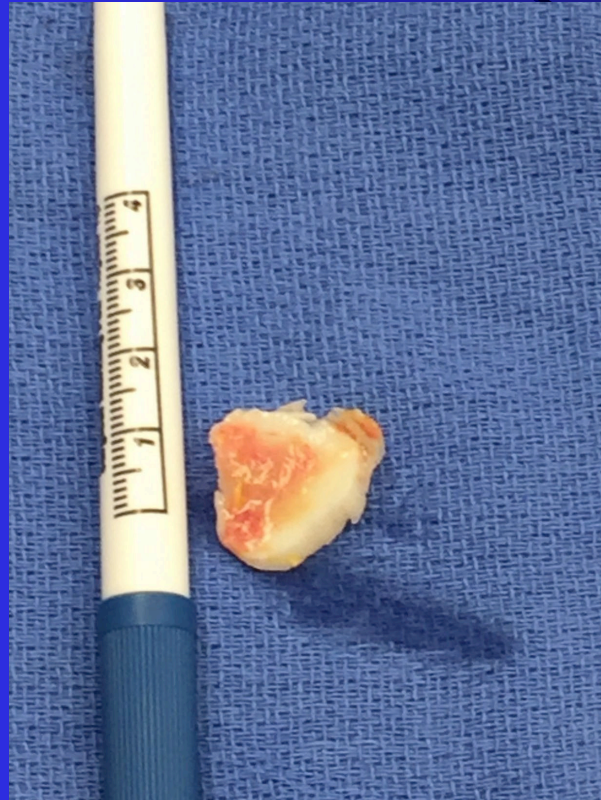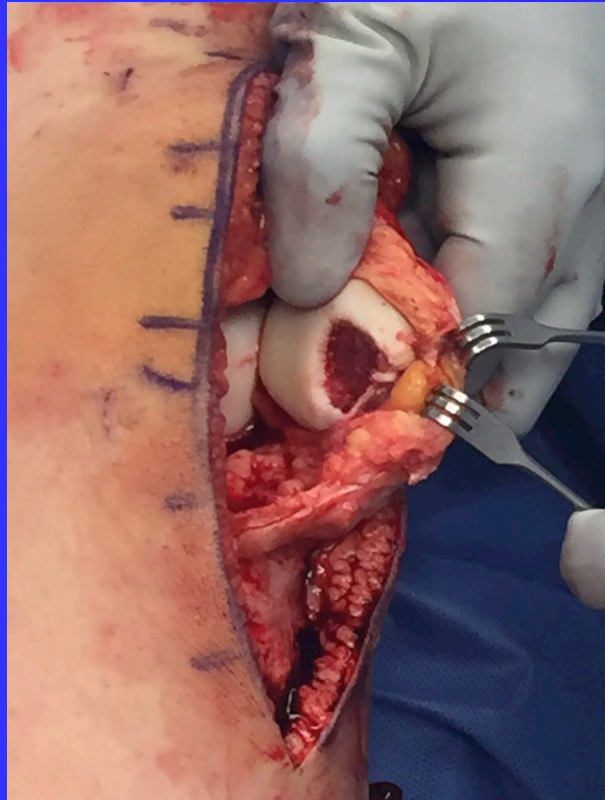
Diagnosis

- Patellar dislocation with loose osteochondral fracture

MRI



Treatment



Case 8

- 16 year old female cheerleader with recurrent patellar dislocations
 - First dislocation event 10 mo prior while doing a handspring
 - Completed a course of PT and was bracing
 - Two additional events since
 - Most recent event 3 weeks ago climbing out of a ball pit

Physical Examination

- Normal standing alignment
- Minimal swelling
- ROM -5 – 140
- Stable to varus and valgus stress
- 1+ lachman, neg ant drawer/ post drawer, neg dial
- Positive patellar apprehension
- 3 quadrants of lateral glide with soft endpoint on the injured side compared to 1 quadrant on the uninjured side
- 45 degrees of internal rotation of the hip at 90 degrees of flexion

Diagnosis

- Recurrent Patellar Instability

Recurrent Patellar Instability

- Report frequent dislocations with minimal trauma
- Females > males
- Ligamentously lax
- Associated structural abnormalities
 - Trochlear dysplasia
 - Patella alta
 - Elevated Tibial tubercle-trochlear groove distance
 - Excessive femoral anteversion
 - Genu valgum

Q angle

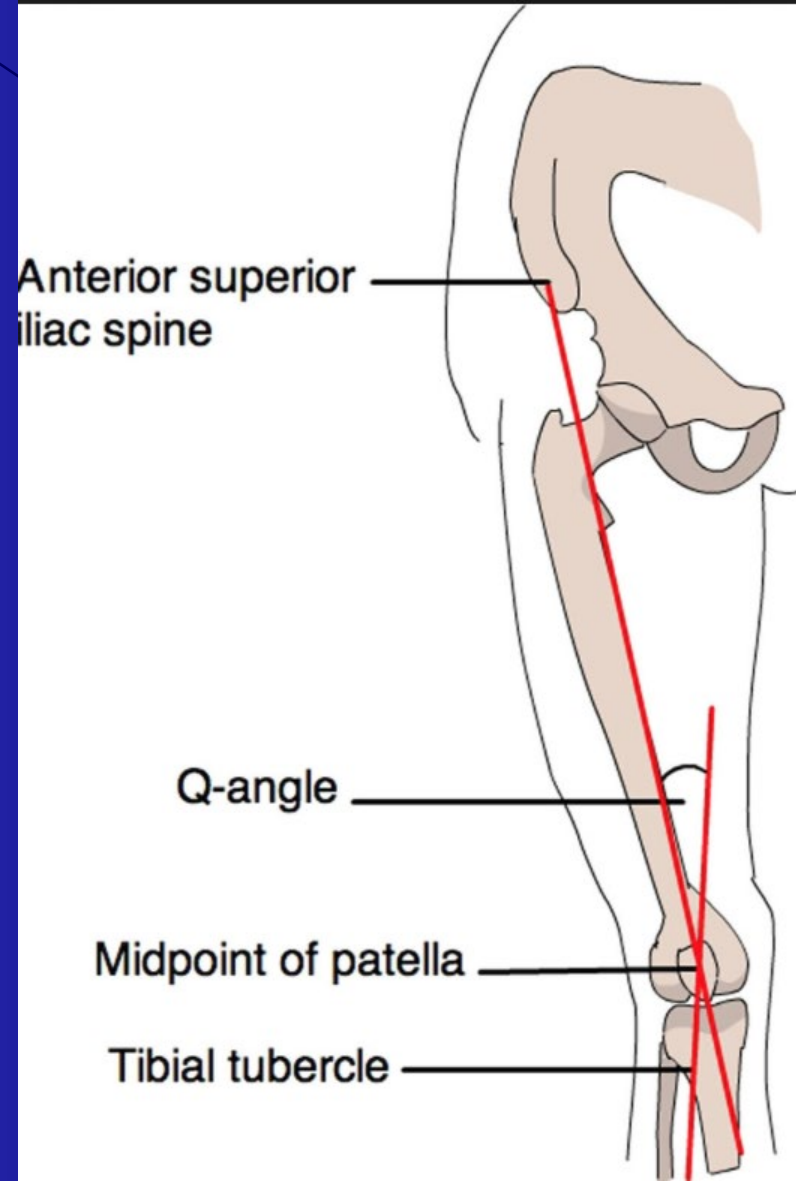
Average Q angles

Males: 14°

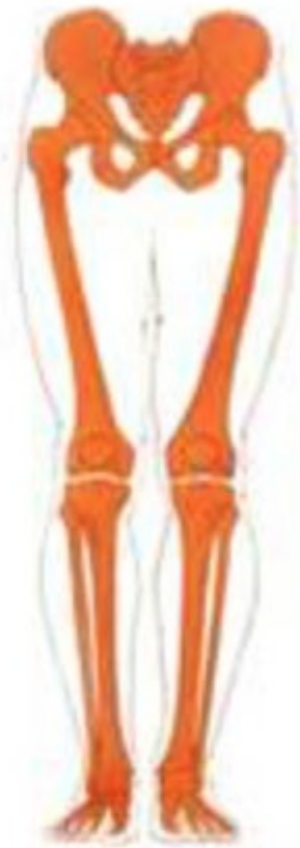Females: 18°

Increased By

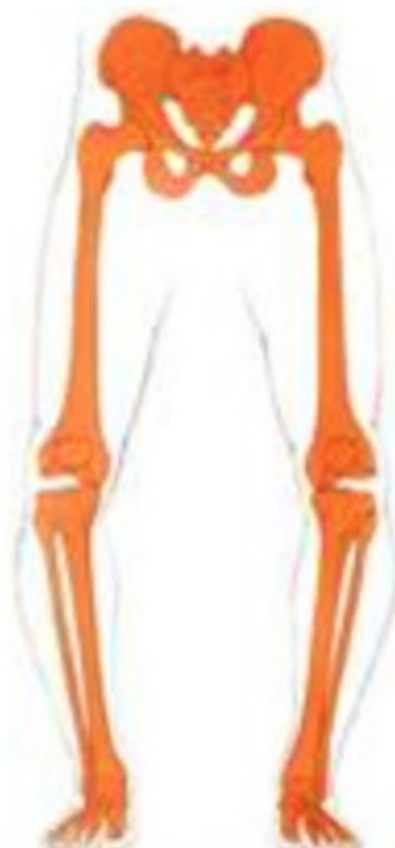- Genu valgum
- Increased femoral anteversion
- External tibial torsion
- Laterally positioned tibial tubercle (TT-TG)
- Tight lateral retinaculum



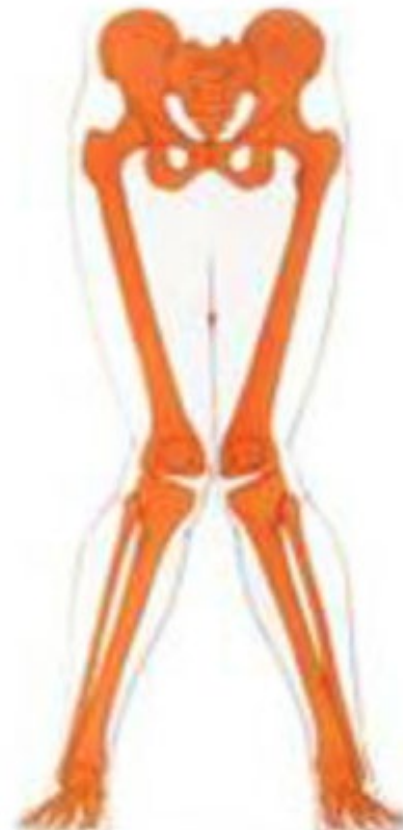Standing Alignment



NORMAL

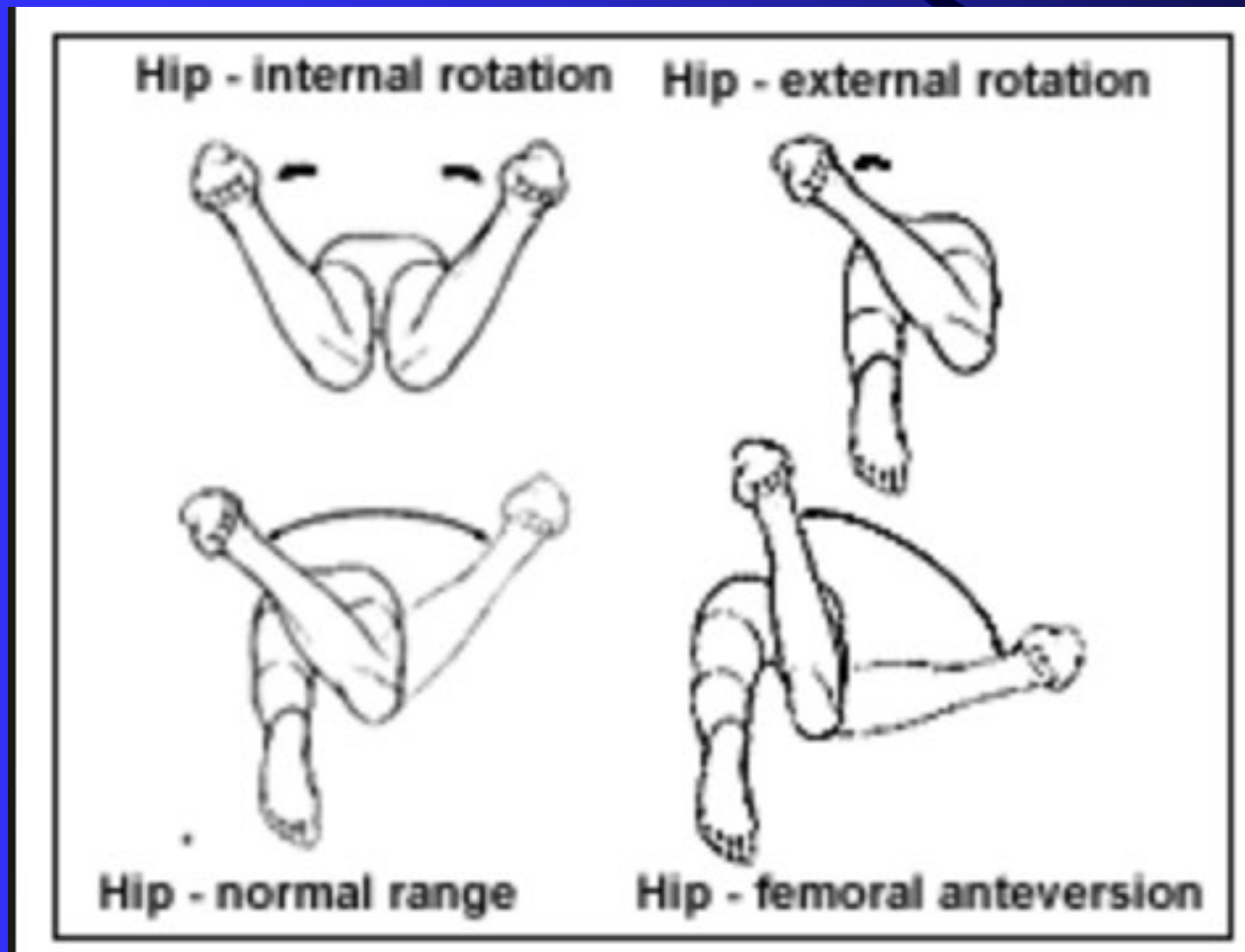


GENU VARUM

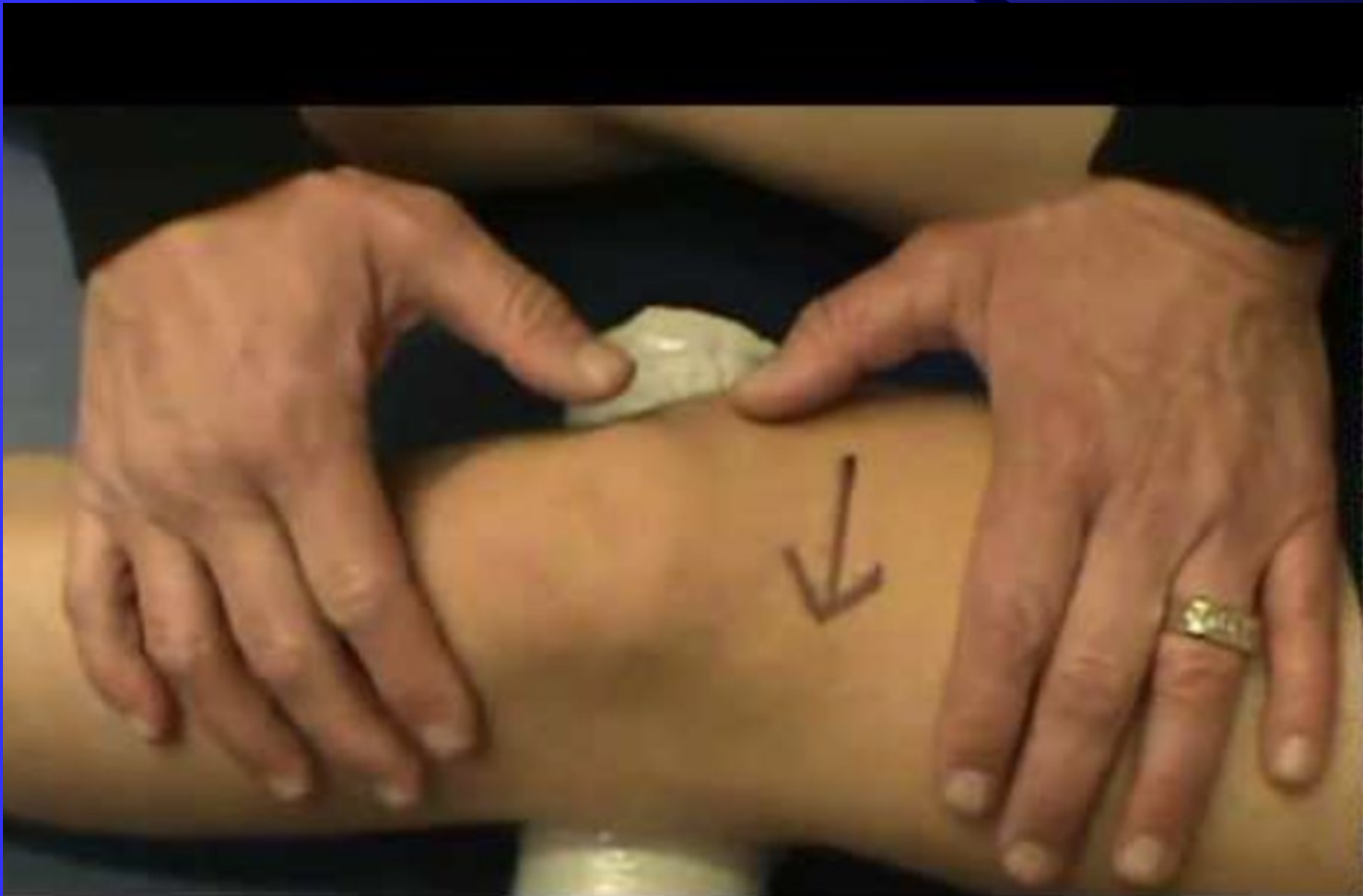

GENU VALGUM

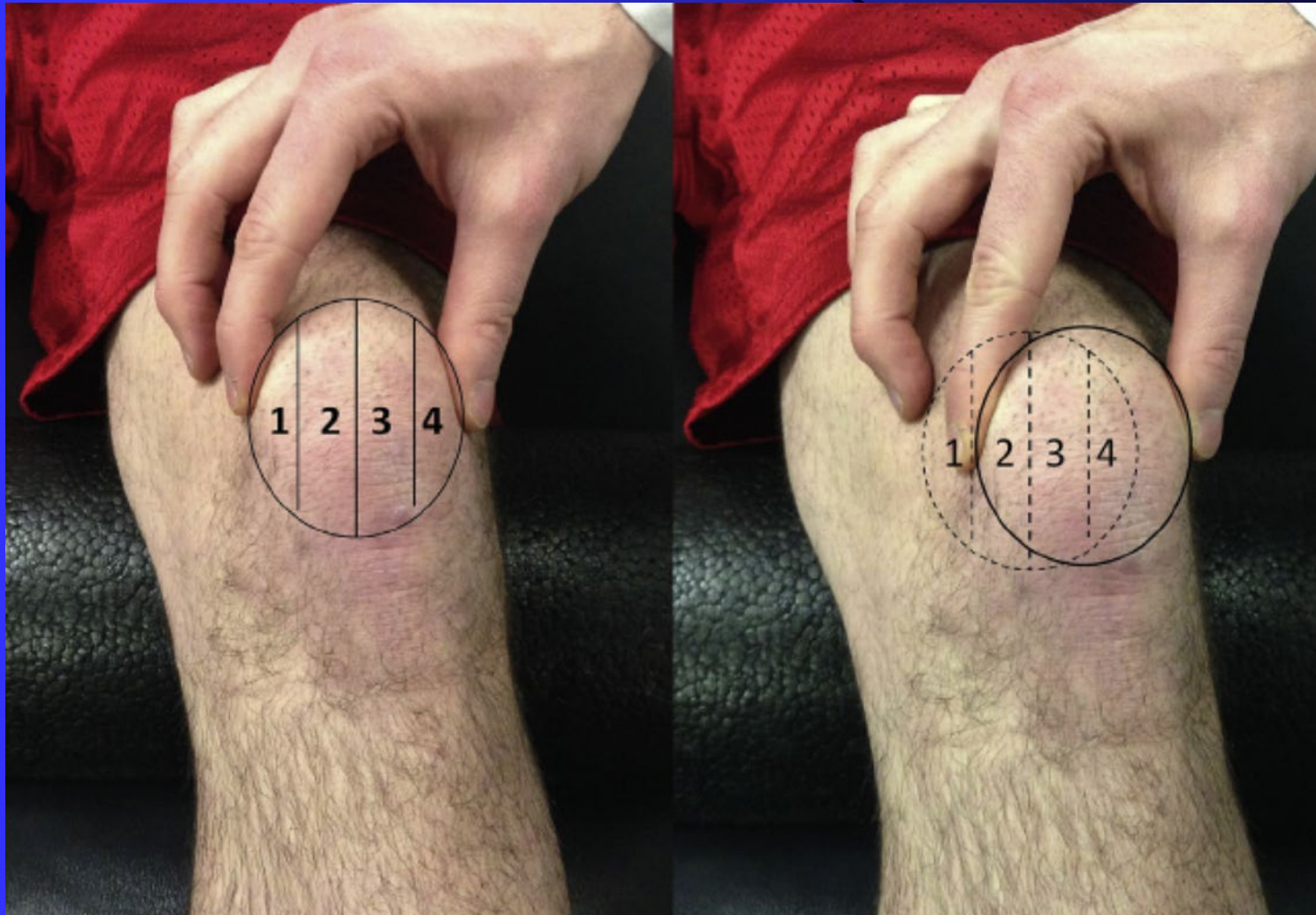
Hip Range of Motion



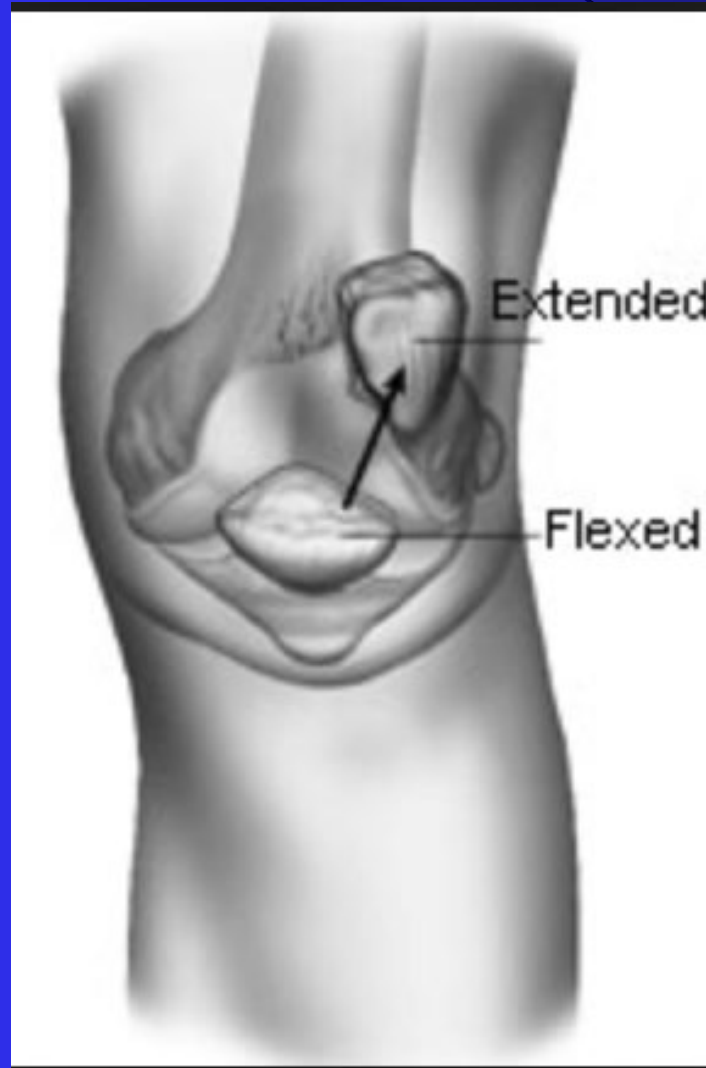
Patellar Apprehension



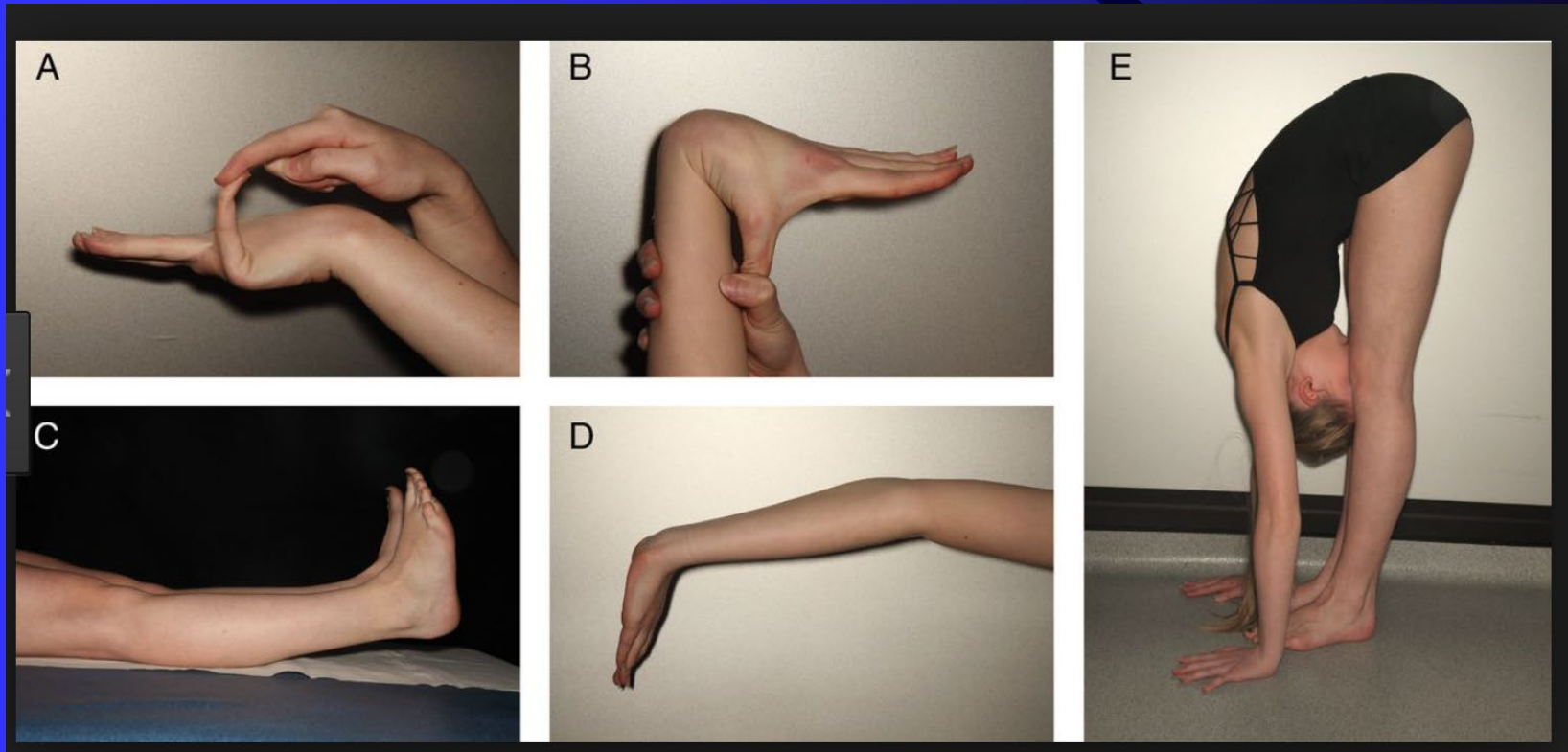
Patellar Glide



J Sign



Beighton Score



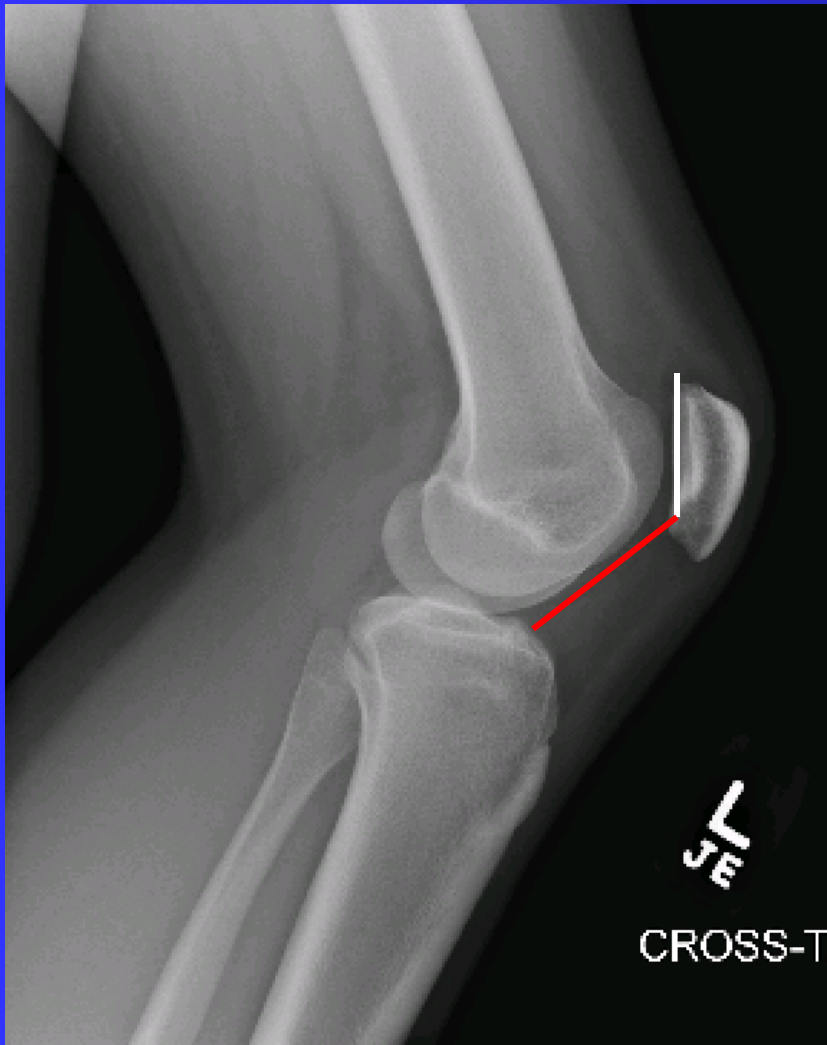
Patellar Height

Caton

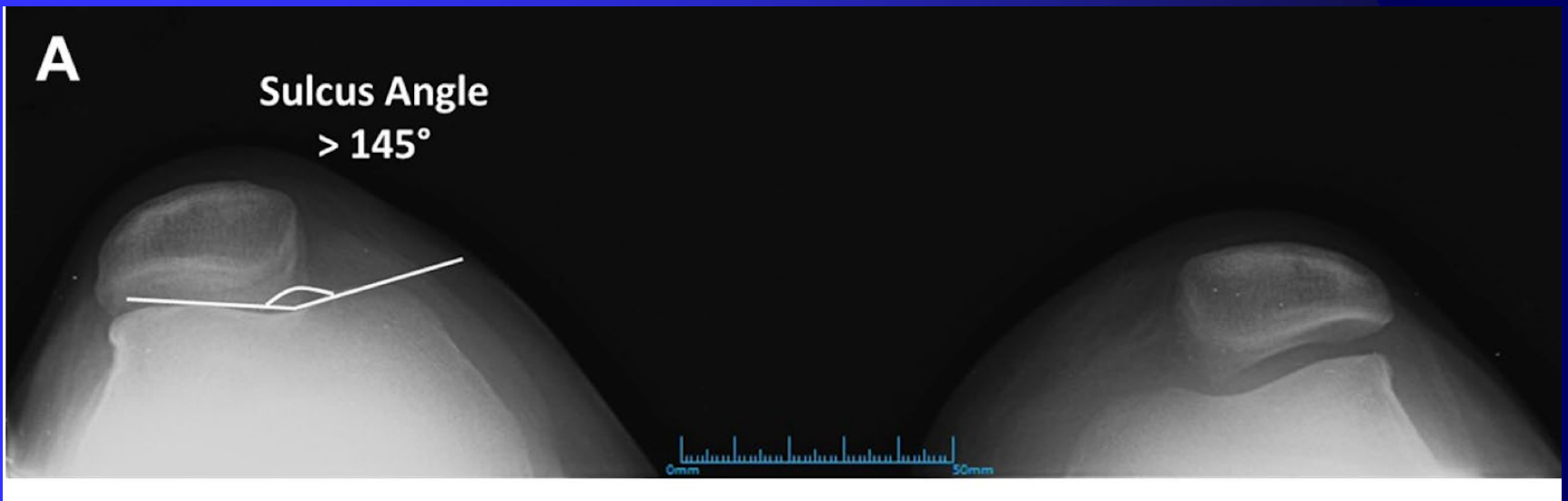
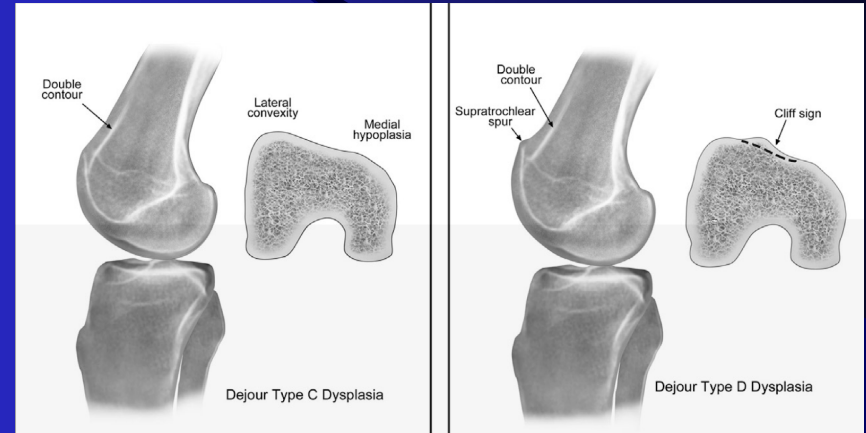
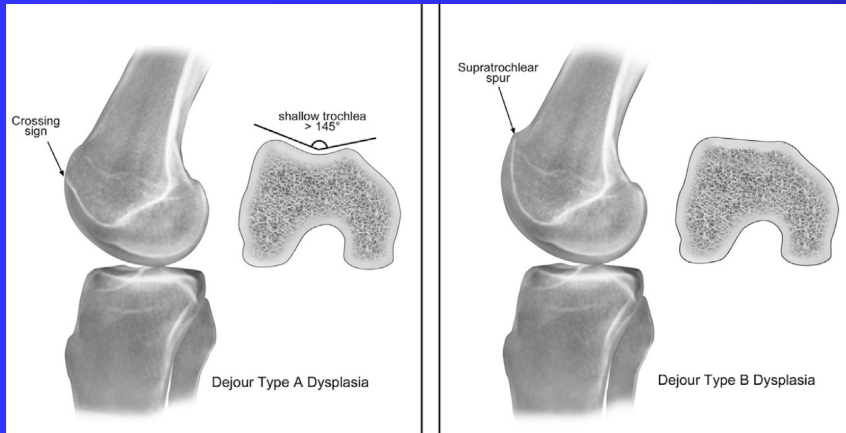
Deschamps

Normal 0.6-1.3

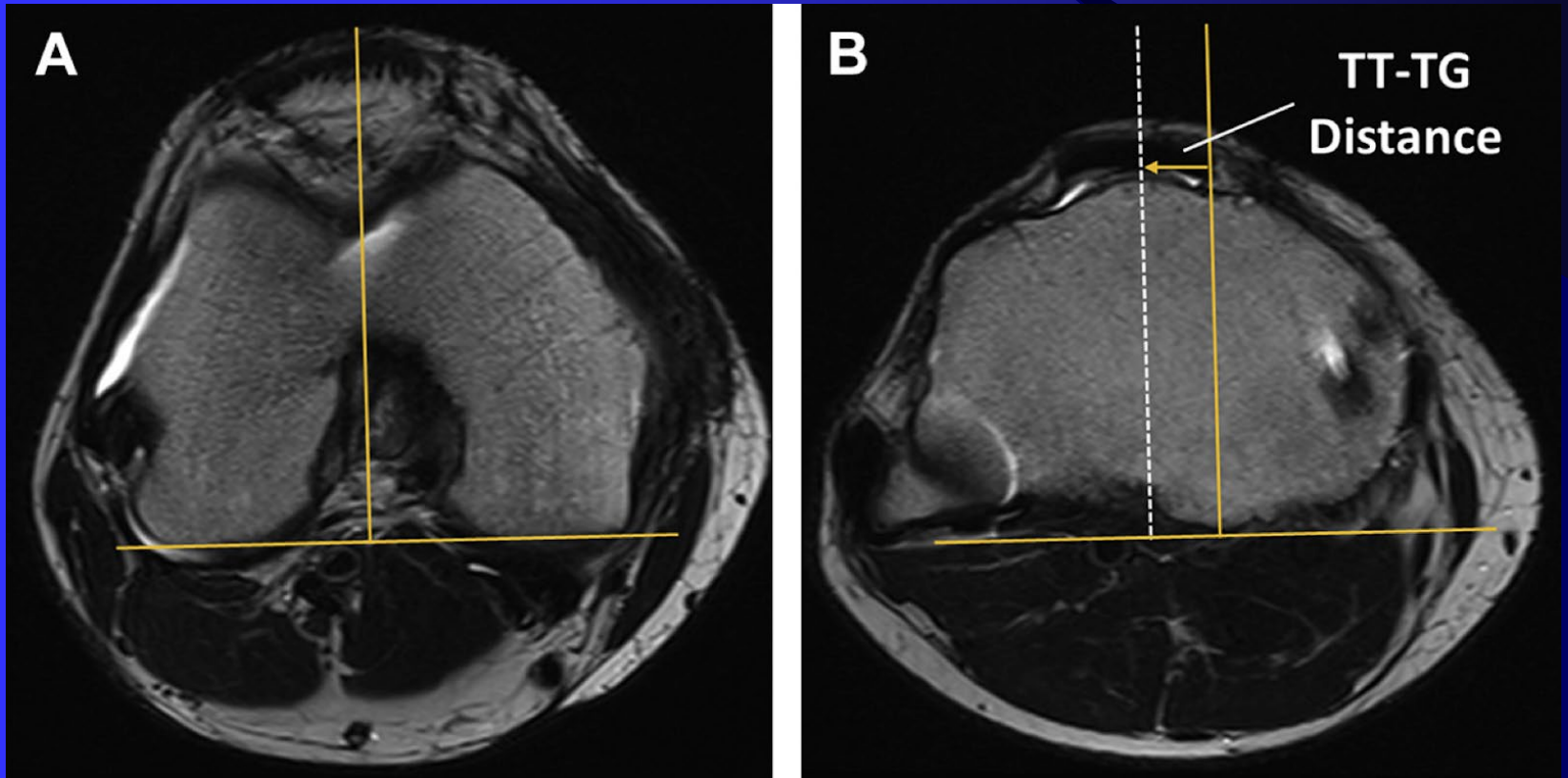
Tendon / Patella = 1.3



Trochlear Dysplasia



TT-TG



Factors Contributing to Instability

- Valgus alignment
- Patella Alta ✓
- Trochlear Dysplasia ✓
- Elevated TT- TG ✓
- History of previous dislocation ✓
- Generalized ligamentous laxity ✓
- Excessive femoral anteversion ✓

Surgical Plan

- Tibial Tubercle osteotomy to decrease elevated TT-TG and patella alta
- MPFL reconstruction to reconstruct attenuated Medial patellofemoral ligament

Tibial Tubercle Osteotomy

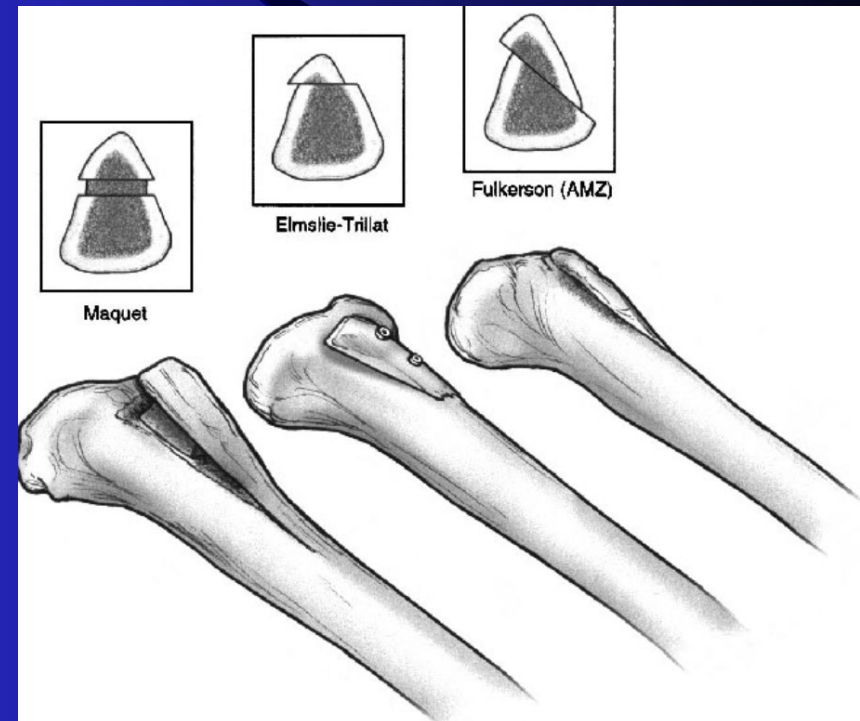
- Maquet
- Straight anterior
- + decrease PF contact pressure
- - High risk skin necrosis

Emslie-Trillat

- Straight medial
- + Decrease q angle

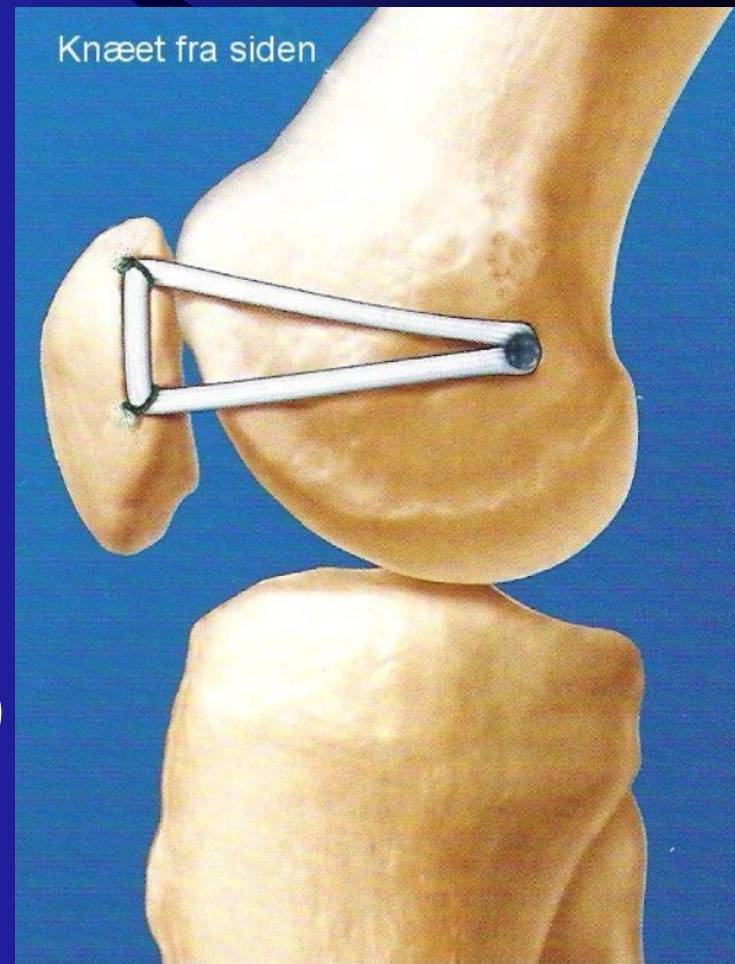
Fulkerson

- Anterior/medialization
- + shifts contact pressure to medial and inferior



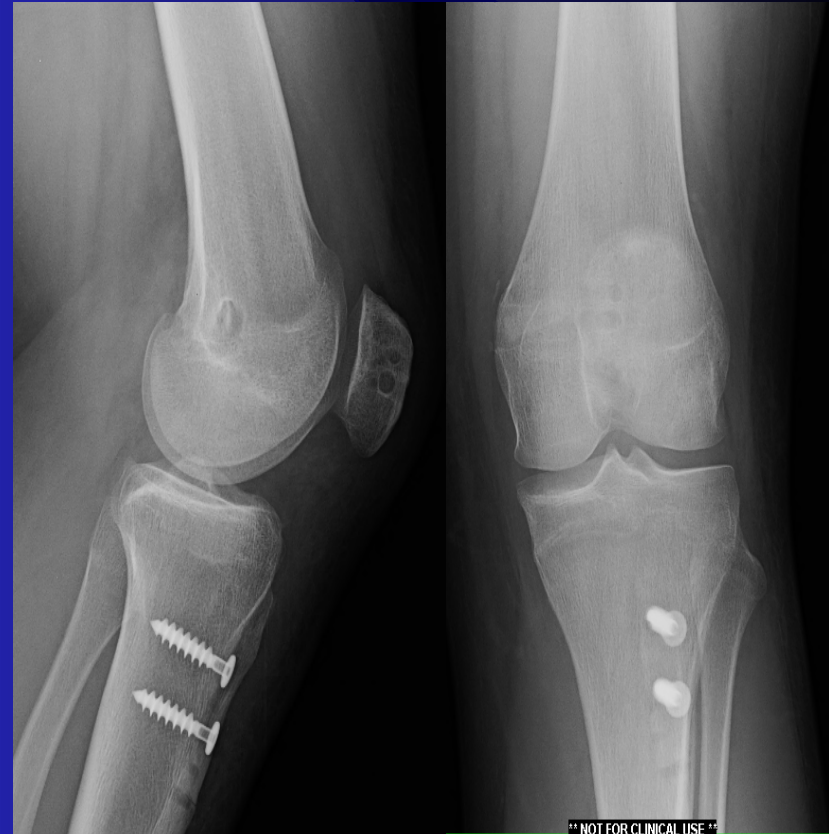MPFL Reconstruction

- Hamstring autograft
 - Semi-T
- Suture anchors in patella
- Tunnel in femur
- Make sure to check isometry
- Tension between 60 and 30 degrees
- Do NOT over tension



MPFL/TTO

- Brace locked in extension for 2 weeks than progressive flexion to 90 degrees over 6 weeks
- ASA x 4 weeks for DVT prophylaxis
- Toe touch WB x 6 weeks
- DC brace at 6 weeks
- Return to sports approximately 10 – 12 months



Outcomes

- Recurrent dislocation rates are low but not zero
 - 10-20% after surgery
- Recurrent dislocations rates are similar after first time dislocations

Take Home Points

- Inability to actively extend the knee is concerning for a patellar or quad tendon rupture
- Anterior knee pain is a common diagnosis in adolescents and characterized by normal knee examination, hamstring tightness and gluteus weakness
- Osgood Schlater is seen in skeletally immature patients and often resolves with rest
- Nonoperative treatment is appropriate following a first time knee dislocation without associated fracture
- Operative intervention with stabilization indicated for recurrent patellar instability.

References

- Post W. Anterior Knee Pain: Diagnosis and Treatment. JAAOS. 2005;13(8)534-543
- Diduch D, Kandil A, Burrus T. Lateral Patellar Instability in the Skeletally Mature Patient: Evaluation and Surgical Management. JAAOS. 2018;26(12)429-439
- Matava M. Patellar Tendon Ruptures. 1996;4(6)287-296
- Ilan D, Tejwani N, Keschner M, Liebman M. Quadriceps Tendon Ruptures. JAAOS. 2003;11(3)192-200

Thank You



Email with further questions:
Lily.Bogunovic@gmail.com

